

Case Report

Bilateral Serous Detachments with Roth Spots after COVID-19 Vaccination: A Case Report

Maarten B. Jalink^{a, b} Ricardo Geraerds Thesingh^a

^aDepartment of Ophthalmology, Central Military Hospital, Utrecht, The Netherlands;

^bDepartment of Ophthalmology, University Medical Center Utrecht, Utrecht, The Netherlands

Keywords

COVID-19 · Vaccination · Serous detachment · Roth spots

Abstract

With the rise of novel types of vaccines during the pandemic, new side effects are encountered. The aim of this paper is to describe an atypical case of bilateral serous detachments with Roth spots after COVID-19 vaccination using an mRNA vaccine. A healthy, 38-year-old male presented with a central scotoma and metamorphopsia in his left eye, 4 days after his second COVID-19 booster shot. Bilateral serous detachments were seen, with one area showing Roth spots. Patient's symptoms resolved spontaneously without any treatment. Although serous detachment after COVID-19 vaccination has been described in the context of other diseases, such as Vogt-Koyanagi-Harada disease, central serous chorioretinopathy, and posterior scleritis, this is the first report of serous detachments with Roth spots as an isolated entity.

© 2023 The Author(s).

Published by S. Karger AG, Basel

Introduction

The COVID-19 pandemic has had a profound impact on global health, with millions of individuals dying from the disease [1]. In response, numerous vaccines have been developed and deployed in an effort to curb the spread of the virus and protect individuals from becoming seriously ill [2]. While these vaccines have been shown to be effective at preventing illness and reducing transmission, there have been reports of adverse effects following vaccination. In particular, there have been a number of cases of ocular complications, including uveitis, acute macular neuroretinopathy, and idiopathic orbital inflammation in

Correspondence to:
Maarten B. Jalink, maartenjalink@hotmail.com

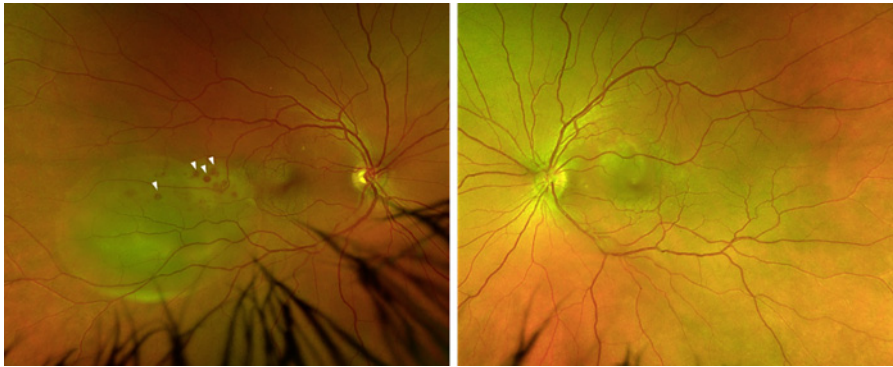


Fig. 1. Fundus image of both eyes using Optos ultra-wide field fundus imaging (Optos PLC, Dunfermline, UK). In the right eye, Roth spots can be seen in the larger detached area (white arrows).

individuals who have received COVID-19 vaccines [3–5]. Vaccine-related complications are not new and were seen prior to the pandemic as well, but the sheer number of vaccinations caused an increase of such. In this paper, we report the first case of a patient with atypical, bilateral, serous detachments with Roth spots after vaccination against COVID-19 with an mRNA vaccine. The CARE Checklist has been completed by the authors for this case report, attached as online supplementary material at www.karger.com/doi/10.1159/000529668.

Case Presentation

A healthy, 38-year-old, Caucasian male without any significant refractive error presented with a sudden central, relative scotoma and metamorphopsia in his left eye since 1 day. Patient had not experienced any stressful events. He had no symptoms in his right eye. His eyes were not red and he did not experience painful eye movements. Patient did not use any medication (including steroid ointments or nose spray). He received his second COVID-19 booster shot (Spikevax[®], COVID-19 mRNA vaccine; ModernaTX Inc., Cambridge, MA, USA) 3 days prior to presentation and reported no side effects of current or previous vaccinations. Patient had no extraocular symptoms, like headache, joint pain, or aphthous mouth ulcers.

At presentation, visual acuity (Snellen) was 20/20 (right eye) and 6/20 (left eye) and intraocular pressure was 18–16 mm Hg. Slit-lamp examination showed no signs of inflammation in the anterior segment and a trace (0.5+) of cells in the vitreous of both eyes [6]. On fundoscopy of the right eye, two peripheral serous detachments were seen, one minor detachment nasally and temporally a larger area with retinal hemorrhages and Roth spots (Fig. 1). Fundoscopy of the left eye revealed a single serous detachment in the macula without any hemorrhages.

Optical coherence tomography (OCT) exposed sub-retinal fluid in these areas but no other (sub-retinal) abnormalities (Fig. 2). Fluorescein angiography showed dye leakage into the sub-retinal space (pooling) of all detached areas (Fig. 3). The superior part of the larger detachment in the right eye became more hyperfluorescent (staining), with areas of hypo-fluorescence matching the location of the Roth spots. B-scan ultrasonography disclosed sub-retinal fluid and ruled out a sub-retinal tumor. There was no fluid in Tenon's capsule, no T-sign, and the choroidal/scleral thickness was normal. Comprehensive laboratory workup was performed, screening for hematological, autoimmune, and infectious diseases (Table 1). All results were normal. Patient was found to be HLA-B51 positive.

Ten days after initial presentation, patient's complaints had spontaneously diminished and visual acuity of the left eye became 14/20. Sub-retinal fluid had severely diminished on

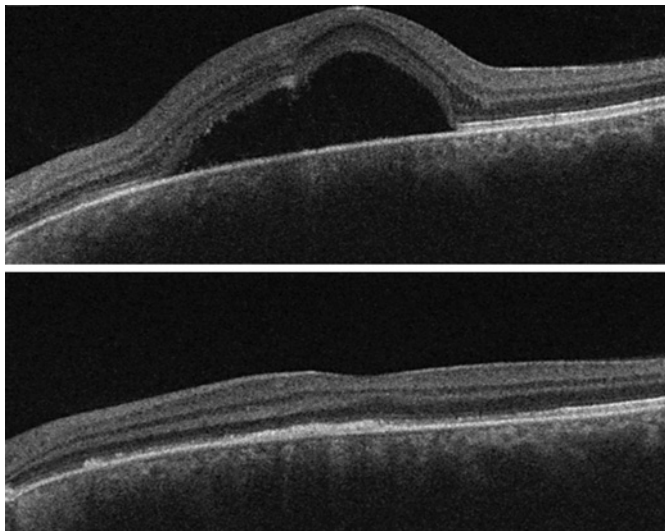


Fig. 2. OCT scan of the left eye (DRI-OCT Triton, Topcon Inc., Tokyo, Japan) on presentation (top) and 24 days (bottom) after initial presentation, showing diminishing of sub-retinal fluid. Central choroidal thickness was measured at 255 μm (right eye) and 260 μm (left eye).

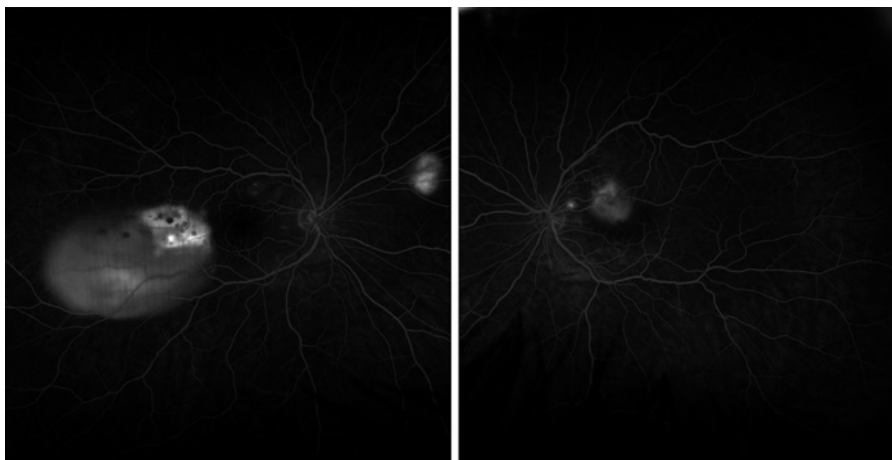


Fig. 3. Fluorescein angiography of both eyes using Optos ultra-wide field fundus imaging, made at 5 min after injecting fluorescein.

OCT scan in all areas. Twenty-four days after presentation, patient reported that his symptoms continued to fade and visual acuity of the left eye became 18/20. Patient only noted seeing colors a bit duller; the Hardy Rand and Rittler (HRR) color test was normal. Fundoscopy showed vanishing of the Roth spots in the right eye and some residual pigment epithelial alterations in the left eye (Fig. 4). Sub-retinal fluid remained absent on OCT scan of both eyes.

Conclusion and Discussion

Serous detachment is seen in various cases after COVID-19 vaccination, all in associated diseases. Central serous chorioretinopathy (CSCR) is a common, idiopathic cause of sub-retinal fluid in mostly young patients. Serous detachments were described within 1 week after

Table 1. Laboratory results

Blood count	
Hemoglobin	9.5 mmol/L
Thrombocytes	234 × 10 ⁹ /L
Leukocytes	7.7 × 10 ⁹ /L
Eosinophils	0.33 × 10 ⁹ /L
Basophils	0.03 × 10 ⁹ /L
Neutrophils	4.50 × 10 ⁹ /L
Lymphocytes	2.53 × 10 ⁹ /L
Monocytes	0.33 × 10 ⁹ /L
Metabolic panel	
Sodium	141 mmol/L
Potassium	4.3 mmol/L
Calcium	2.33 mmol/L
Albumine	42.4 g/L
Creatinine	68 µmol/L
Ureum	4.0 mmol/L
Angiotensin-converting enzyme	53 U/L
Infectious markers	
C-reactive protein	1 mg/L
Erythrocyte sedimentation rate	5 mm after 1 h
Immune serology	
HLA-B	08
HLA-B	51
Soluble IL-2 receptor	2,076 pg/mL
M-protein screening	Negative
Infectious serology	
HIV-1/2	Negative
QuantiFERON (TBC)	Negative
<i>Treponema pallidum</i> (CMIA)	Negative
TBC, tuberculosis; CMIA, chemiluminescent microparticle immunoassay.	

vaccination with either a vector or an mRNA COVID-19 vaccine, both in patients already diagnosed with CSCR and patients who were never had any complaints [7, 8]. Vogt-Koyanagi-Harada disease has been reported 14–35 days after mRNA and inactivated virus COVID-19 vaccines [9–12]. Symptoms included headache and granulomatous panuveitis and all patients had good response to steroid treatment. In 1 case, posterior scleritis developed, including thickening of the posterior sclera with fluid in Tenon’s capsule as seen on ultrasound [13]. Finally, acute idiopathic maculopathy, a rare inflammatory disease of the outer retina, was seen in 1 patient, 7 days after vaccination with an mRNA vaccine [14]. This patient had unilateral, central, serous detachment with intraretinal hemorrhages. Fluorescein angiography showed focal staining in the late stage and diffuse pooling within the serous detachment. This is somewhat similar to the angiography of our patient; however, in our case this area of pooling and staining was seen in the periphery and not in the macula, which is typical for acute idiopathic maculopathy.

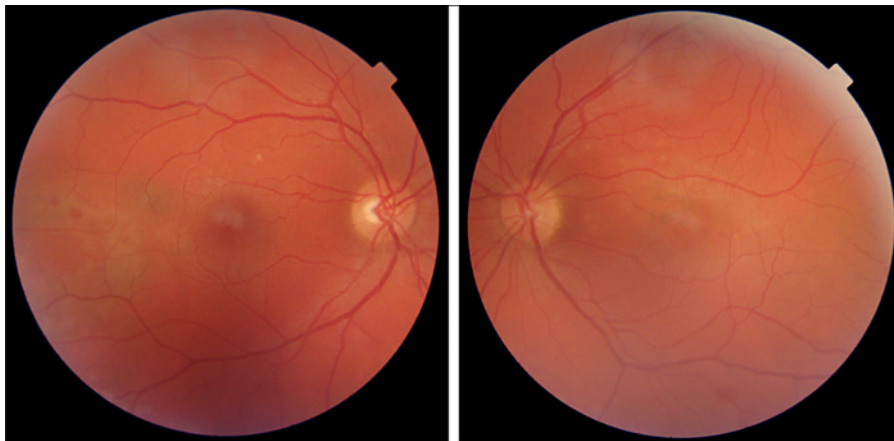


Fig. 4. Fundus photography (DRI-OCT Triton, Topcon Inc., Tokyo, Japan) of both eyes, 24 days after initial presentation.

While our patient had similar serous detachments as one would expect in CSCR, the presence of Roth spots and hemorrhages makes this case atypical. Also, the quick resolution of sub-retinal fluid does not fit the diagnosis. Blood work excluded other diagnoses, such as leukemia, tuberculosis, or sarcoidosis. Ultrasound showed no signs of intra-ocular malignancy or posterior scleritis. Patient was found to be HLA-B51 positive. HLA-B51 is linked to Behçet disease, which could give rise to serous detachments [15]. However, there were no other ocular or systemic symptoms to support this diagnosis. Likewise, our patient had no other symptoms indicating Vogt-Koyanagi-Harada disease. Patient's history did not reveal any leads on any other disorders. Given the rapid onset of symptoms after vaccination, negative workup, absence of other symptoms, and quick and spontaneous resolution of sub-retinal fluid, we found a reaction to COVID-19 vaccination the most probable cause for our patient's symptoms.

Several possible pathophysiologic mechanisms for vaccine-related adverse events are theorized [16]. These include molecular mimicry between vaccine peptide fragments and tissue peptides, leading to a diverted immune reaction in certain (ocular) tissues, and a strong immune reaction to the adjuvants that are added to the vaccine to potentiate vaccine-mediated immune responses [16]. Since this is the first report of such a case; the actual cause of this adverse event remains speculative.

In conclusion, this case report presents a patient who developed atypical bilateral serous detachments following vaccination against COVID-19 with an mRNA vaccine. This report adds to the growing list of ocular side effects of COVID-19 vaccines. It is important for individuals who have received a COVID-19 vaccine to be aware of the potential for ocular complications and to seek prompt medical attention if they experience any symptoms.

Statement of Ethics

Ethical approval is not required for this study in accordance with local or national guidelines. Written informed consent was obtained from the patient for publication of the details of their medical case and any accompanying images.

Conflict of Interest Statement

The authors declare no conflict of interest.

Funding Sources

No funding was required for the realization of this paper.

Author Contributions

Maarten B. Jalink and Ricardo Geraerds Thesingh have made a significant contribution to this paper. Maarten B. Jalink and Ricardo Geraerds Thesingh have both seen and treated the patient that was mentioned in this report. Maarten B. Jalink drew the initial draft, which was expanded upon by Ricardo Geraerds Thesingh.

Data Availability Statement

All data generated or analyzed during this study are included in this article. Further inquiries can be directed to the corresponding author.

References

- 1 COVID-19 Excess Mortality Collaborators. Estimating excess mortality due to the COVID-19 pandemic: a systematic analysis of COVID-19-related mortality, 2020–21. *Lancet*. 2022 Apr 16;399(10334):1513–36.
- 2 Watson OJ, Barnsley G, Toor J, Hogan AB, Winskill P, Ghani AC. Global impact of the first year of COVID-19 vaccination: a mathematical modelling study. *Lancet Infect Dis*. 2022 Sep;22(9):1293–302.
- 3 Singh RB, Parmar UPS, Kahale F, Agarwal A, Tsui E. Vaccine-associated uveitis after COVID-19 vaccination: vaccine adverse event reporting system database analysis. *Ophthalmology*. 2022 Aug 31;6420(22):S016100672–8.
- 4 Jalink MB, Bronkhorst IHG. A sudden rise of patients with acute macular neuroretinopathy during the COVID-19 pandemic. *Case Rep Ophthalmol*. 2022 Feb 14;13(1):96–103.
- 5 Jalink MB, Burger BB, Kalmann R. Orbital inflammation and dacryoadenitis after COVID-19 vaccination. *Case Rep Ophthalmol*. 2022 Oct 11;13(3):789–92.
- 6 Jabs DA, Nussenblatt RB, Rosenbaum JT; Standardization of Uveitis Nomenclature SUN Working Group. Standardization of uveitis nomenclature for reporting clinical data. Results of the first international workshop. *Am J Ophthalmol*. 2005 Sep;140(3):509–16.
- 7 Sanjay S, Acharya I, Kawali A, Shetty R, Mahendradas P. Unilateral recurrent central serous chorioretinopathy (CSCR) following COVID-19 vaccination- A multimodal imaging study. *Am J Ophthalmol Case Rep*. 2022 Sep;27:101644.
- 8 Hanhart J, Roditi E, Wasser LM, Barhoum W, Zadok D, Brosh K. Central serous chorioretinopathy following the BNT162b2 mRNA vaccine. *J Fr Ophtalmol*. 2022 Jun;45(6):597–602.
- 9 Yamaguchi C, Kunikata H, Hashimoto K, Yoshida M, Ninomiya T, Hariya T, et al. De novo Vogt-Koyanagi-Harada disease after vaccination for COVID-19, successfully treated with systemic steroid therapy and monitored with laser speckle flowgraphy. *Am J Ophthalmol Case Rep*. 2022 Jun 11;27:101616.
- 10 Chen X, Wang B, Li X. Acute-onset Vogt-Koyanagi-Harada like uveitis following Covid-19 inactivated virus vaccination. *Am J Ophthalmol Case Rep*. 2022 Jun;26:101404.
- 11 Brunet de Courssou JB, Tisseyre M, Hadjadj J, Chouchana L, Broca F, Terrier B, et al. De novo Vogt-Koyanagi-Harada disease following covid-19 vaccine: a case report and literature overview. *Ocul Immunol Inflamm*. 2022 Jul;30(5):1292–5.
- 12 Joo CW, Kim YK, Park SP. Vogt-Koyanagi-Harada disease following mRNA-1273 (Moderna) COVID-19 vaccination. *Ocul Immunol Inflamm*. 2022 Jul;30(5):1250–4.
- 13 Younus O, Mulla U. Posterior scleritis following COVID-19 vaccination: a case report. *Ocul Immunol Inflamm*. 2022 Feb 28:1–3.
- 14 Bleicher ID, Brill D, Wu F, Sobrin L, Patel N. Acute idiopathic maculopathy following SARS-CoV-2 vaccination. *Ocul Immunol Inflamm*. 2022 Sep 2:1–4.
- 15 Vrabec TR. Exudative retinal detachment in Behçet disease. *Arch Ophthalmol*. 2001 Sep;119(9):1383–6.
- 16 Ng XL, Betzler BK, Ng S, Chee SP, Rajamani L, Singhal A, et al. The eye of the storm: COVID-19 vaccination and the eye. *Ophthalmol Ther*. 2022 Feb;11(1):81–100.