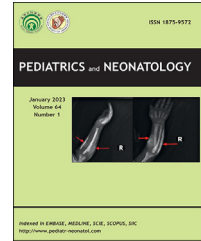


Available online at www.sciencedirect.com

ScienceDirect

journal homepage: <http://www.pediatr-neonatol.com>

Original Article

Cranial ultrasound screening in term and late preterm neonates born by vacuum-assisted delivery: Is it worthwhile?



Dario Gallo ^a, Ilia Bresesti ^{a,d,*}, Angela Bossi ^a,
 Donatella Lissoni ^b, Antonella Cromi ^{b,d},
 Maria Luisa Tataranno ^c, Lorenza Bertù ^d, Fabio Ghezzi ^{b,d},
 Massimo Agosti ^{d,a}

^a Division of Neonatology, "F. Del Ponte" Hospital, Woman and Child Department, University of Insubria, Varese, Italy

^b Division of Obstetrics and Gynaecology, "F. Del Ponte" Hospital, University of Insubria, Varese, Italy

^c Department of Neonatology, Wilhelmina Children's Hospital, University Medical Center Utrecht, Utrecht University, Utrecht 3584, the Netherlands

^d Department of Medicine and Surgery, University of Insubria, Varese, Italy

Received Apr 5, 2022; received in revised form Jun 7, 2022; accepted Jun 22, 2022

Available online 19 September 2022

Key Words

Cranial ultrasound;
 Head injury;
 Intracranial
 hemorrhage;
 Term infant;
 Vacuum extraction

Background: Vacuum extraction is the most common choice to assist vaginal delivery, but there are still concerns regarding the neonatal injuries it may cause. This study aimed to evaluate the rate of intracranial injuries assessed by cranial ultrasound (cUS) among infants born by vacuum extraction, and the relationship with maternal and perinatal factors.

Methods: This was a single-center retrospective study carried out in a level-3 neonatal unit. A total of 593 term and late preterm infants born by vacuum-assisted delivery were examined with a cUS scan within 3 days after birth.

Results: Major head injuries were clinically silent and occurred in 2% of the infants, with a rate of intracranial haemorrhage of 1.7%. Regardless of obstetric factors, the risk of cranial injury was increased in infants requiring resuscitation at birth ($p = 0.04$, OR 4.1), admitted to NICU ($p = 0.01$, OR 5.5) or with perinatal asphyxia ($p < 0.01$, OR 21.3). Maternal age ≥ 40 years correlated both with adverse perinatal outcomes ($p < 0.05$) and the occurrence of major injury ($p = 0.02$, OR 4.6).

Conclusion: Overall, vacuum extraction is a safe procedure for neonates. Head injuries are usually mild and asymptomatic, and with spontaneous recovery. However, the rate of major

* Corresponding author. Division of Neonatology, "F. Del Ponte" Hospital, Woman and Child Department, University of Insubria, Via Filippo del Ponte 19, Varese, 21100, Italy.

E-mail address: ilia.bresesti@uninsubria.it (I. Bresesti).

cranial injuries in our cohort warrants further investigation to support a cUS screening, particularly for infants requiring respiratory support at birth. Also, maternal age might be taken into account when evaluating the risk for neonatal complications after vacuum application.

Copyright © 2022, Taiwan Pediatric Association. Published by Elsevier Taiwan LLC. This is an open access article under the CC BY-NC-ND license (<http://creativecommons.org/licenses/by-nc-nd/4.0/>).

1. Introduction

Operative vaginal delivery accounts for 4–5% of all deliveries in Italy, with significant variations between hospitals.¹ Vacuum extraction (VE) is the preferred type of assisted vaginal delivery in case of maternal and foetal indications since forceps are less frequently used.²

Vacuum-assisted delivery is associated with an increased incidence of neonatal morbidities, such as cephalohematoma, subgaleal and intracranial haemorrhage (ICH).³ This risk seems to be related to abnormalities in labor, rather than the vacuum application per se,⁴ although the evidence is conflicting.⁵

Neonatal screening with cranial ultrasound (cUS) and skull X-ray showed higher rates of intracranial haemorrhage,⁶ but these findings date back to 2000, and management of vacuum-assisted delivery has changed since then. Hence, the risk has not been investigated from use of more recent vacuum cups.

In the present study, we evaluated the use of a cUS screening in a cohort of term or late preterm neonates born by instrumental vacuum vaginal delivery. We aimed to investigate the rate of intracranial injuries after vacuum application. Moreover, we correlated maternal and neonatal characteristics with the incidence of cranial injury of different degrees detected with cUS screening.

2. Methods

We conducted a retrospective study involving term and late preterm neonates born by vacuum-assisted vaginal delivery between January 2015 and December 2020, at “Filippo Del Ponte Hospital,” Varese, Italy.

Infants ≥ 34 weeks' gestation were eligible for the study. Exclusion criteria included major congenital malformations and/or known prenatal brain anomalies.

Vacuum extraction was indicated to expedite vaginal delivery in case of a non-reassuring foetal heart tracing, absence of progression of the second stage of delivery or maternal exhaustion. VE was performed by a consultant or an appropriately trained and supervised fellow in obstetrics, and in accordance with the National and RCOG recommendations.⁷ The Kiwi omnicup hand-pump was used during the whole study period.⁸

As per our unit policy, neonates delivered by VE were clinically evaluated at birth by a consultant neonatologist and underwent a cUS scan between the 2nd and 3rd day of life.

Cranial ultrasound scans were performed by an experienced paediatric radiologist, with an HS70A ultrasound machine (Samsung Healthcare) and a convex

multifrequency transducer (frequency set at 7.5 MHz). Each examination included coronal and parasagittal views through the anterior fontanel.

Pathological findings were confirmed by an expert neonatologist and, if indicated, further evaluations were planned. Brain magnetic resonance imaging (MRI) was performed in case of dubious diagnosis and in all neonates with hypoxic-ischemic encephalopathy. Both maternal and neonatal data were collected.

Primary outcome was the incidence of major head injuries, defined by subgaleal hematoma and intracranial haemorrhage. This included intraventricular haemorrhage (IVH), graded according to Volpe classification,⁹ and subdural (SDH) and cerebellar bleeding. Cephalohematoma and scalp laceration, diagnosed both clinically and by cUS, were reported as minor injuries.

Secondary outcomes were umbilical cord blood acidosis (arterial cord pH ≤ 7), Apgar score at 5 min ≤ 5 , need for resuscitation at birth, Neonatal Intensive Care (NICU) admission and hypoxic-ischemic encephalopathy (HIE). HIE was diagnosed by cord blood acidosis (pH ≤ 7 or Apgar score at 5 min ≤ 5) associated with an altered neurological examination, according to Shalak.¹⁰

Incidental findings detected by cUS, such as choroid plexus cyst, germinolytic cyst, thalamic-striatal vessels echogenicity, and asymmetry of the lateral ventricles, were not considered significant for the purpose of the study.

Local Ethics Committee approved the study and informed consent was obtained prior to enrolment.

2.1. Statistical analysis

All variables are expressed as absolute and relative frequency (categorical variables), mean and standard deviation (continuous variables).

To study the association between neonatal head injuries and maternal and neonatal features, as well as the secondary outcomes, univariate and multivariate logistic regression were used and Odds Ratios (OR) with 95% confidence interval were calculated.

Statistical analysis was performed using SAS version 9.4.

3. Results

During the study period, 598 infants ≥ 34 weeks' gestation were delivered by VE. Four patients had missing data and one neonate had congenital malformation. A total of 593 neonates were included in the analysis. Clinical characteristics of the study cohort are reported in [Table 1](#).

Delivery by VE remained constant over time, ranging from 2.7% to 5% per year.

Overall, head injuries after vacuum extraction occurred in 55 infants (9%), all of whom were at term. Major injuries were identified in 11 infants (1.9%), with an incidence of intracranial haemorrhage of 1.7%. In one infant, cUS revealed an occipital parenchymal lesion that appeared as a malacic area in MRI, consistent with a previous ischemic insult. Minor injuries were more frequently detected, consisting of cephalohematoma ($n = 31$) and skin scraping ($n = 14$) (Table 2).

Maternal and neonatal features and the relation with major injuries are outlined in Table 3.

An increased risk for major injury was observed when maternal age was ≥ 40 years (OR 4.6, CI 1.3–16.2 $p = 0.02$), and this was confirmed using multivariate analysis (OR 5.2, $p < 0.01$). We found no relation with obstetric factors such as foetal macrosomia, parity, use of Kristeller manoeuvre and a non-reactive pattern at cardiotocographic trace during the second stage of labor. This pattern was the indication for vacuum extraction in 26% of the cases.

3.1. Neonatal outcomes

Neonatal outcomes are reported in Table 4. Forty-five infants (7.6%) reported non-significant or minor anomalies. Resuscitation at birth with positive pressure ventilation (PPV) was required in 52 infants (9%), and 8 infants (1%) had an Apgar score at 5 min ≤ 5 . Cord ph ≤ 7.0 at birth was noted in 19 infants (4%) and HIE occurred in 8 neonates (1%). Late preterm infants did not experience any adverse outcome. One infant was admitted to the NICU due to low birth weight. The univariate analysis showed a significant association between the occurrence of major head injuries and the need for PPV at birth (OR 4.1, CI 1.05–15.85), NICU admission (OR 5.5, CI 1.4–21.7) and HIE (OR 21.3, CI 3.8–120.4). Regarding maternal characteristics, maternal age ≥ 40 years was a risk factor for adverse neonatal outcomes (Table 5).

4. Discussion

In this cohort of neonates ≥ 34 weeks' gestation undergoing vacuum-extraction, we found an incidence of intracranial haemorrhage of 1.7% and of major head injuries of 1.9%. Head injuries involved solely infants at term.

Maternal age ≥ 40 years correlated both with adverse perinatal outcomes and the occurrence of major head

Table 2 Proportion of patients with head injuries.

Head injuries	n (%)
Total	55 (9.3)
Major injuries	11 (1.9)
Intracranial haemorrhage	10 (90)
IVH grade 1/GMH	7 (64)
Subdural	2 (18)
Cerebellar	1 (8)
Subgaleal hematoma	1 (10)
Minor injuries	45 (7.6)

injuries. Regardless of maternal and obstetric characteristics, the risk of head injury was significantly increased in infants requiring resuscitation at birth, those admitted to NICU or those with perinatal asphyxia.

Our rate of intracranial haemorrhage is higher than that reported in the literature. Although comparison is limited by different study designs, previous studies compared the incidence of neonatal intracranial injury between vacuum and forceps delivery and found a rate of 0.12%–0.26%.^{11–13} In an observational study of 1000 deliveries assisted with the Omnicup device, Baskett et al. reported an incidence of 0.4%, and one case of subgaleal haemorrhage.¹⁴ Furthermore, a large population-based study by Ekeus et al. found a rate of 0.19%.⁵ Of note, diagnosis of intracranial haemorrhage was clinically driven in all reports. Conversely, Simonson et al. performed a cUS screening of neonates born by VE and found a higher rate (0.87%), but the type of vacuum cup was not reported.⁶

The majority of cases of intracranial bleeding are clinically silent in neonates, even though long-term follow up may be necessary.¹⁵ The increased rate of ICH in our study has no univocal explanation. Having performed cUS scans at day 2 or 3 after birth, could have detected intraventricular bleeding that earlier scans might have missed. Moreover, dubious medical reports were always reviewed by a neonatologist with expertise in cUS, resulting in increased sensitivity.

In our cohort, seven infants had intraventricular haemorrhage of low grade and one a cerebellar haemorrhage, and all were asymptomatic. Ultrasonography follow up showed regular reabsorption of bleeding. Subdural haemorrhage occurred in two infants with perinatal asphyxia and it was confirmed by brain MRI showing bleeding of minor extent. In one neonate, cUS reported an abnormal echogenicity of parenchyma in the right occipital lobe. Brain MRI confirmed a malacic area, with no diffusion restriction on DWI, suspected to be of prenatal origin.

Major injuries included one case of subgaleal hematoma. It is a serious complication of VE, since blood can spread in the large aponeurotic space.¹⁶ Use of new vacuum cups and improved technique for assisted vacuum delivery have decreased its incidence and severity.¹⁷ In our study, subgaleal hematoma did not have clinical consequences and resolved spontaneously in a few days.

Intracranial bleeding is not a rare finding in otherwise healthy infants undergoing a cUS scan, with incidence ranging from 0.19% up to 3.5%.^{18–20} In term neonates, haemorrhage can originate from residual germinal matrix

Table 1 Clinical characteristics of the study population.

Neonatal characteristics	n (%), (SD)
Full term	582 (98%)
Preterm	11 (2%)
Gestational age, mean (SD)	40 (± 1)
Birth weight, mean (SD)	3300 (± 450)
Gender	
M	331 (56)
F	262 (44)

Table 3 Maternal and neonatal clinical features and association with major head injuries.

Characteristics	Total n = 593 (SD, %)	All head injuries n = 55 (SD, %)	No injuries n = 538 (SD, %)	Univariate analysis		
				OR	95% CI	p
<i>Maternal characteristics</i>						
Age	33.1 (±5)	33.0 (±6)	33.1 (±5)	1.03	0.9–1.15	0.66
Age ≥ 40 ys	67 (11)	8 (12)	44 (9)	4.59	1.3–16.2	0.02
BMI	26.1 (±4)	26.3 (±6)	26.1 (±4)	1.04	0.9–1.2	0.58
BMI > 30	88 (17)	11 (23)	77 (16)	1.91	0.5–7.3	0.35
Pre-CS	59 (10)	3 (6)	56 (11)	0.87	0.1–6.9	0.89
Induction of labor	224 (39)	22 (41)	202 (39)	1.89	0.6–6.3	0.30
Fundal pressure	104 (18)	14 (26)	90 (17)	1.05	0.2–4.9	0.95
NR ctg-IIs	143 (26)	11 (21)	132 (26)	1.25	0.3–4.9	0.75
Parity						
0	488 (85)	49 (91)	439 (85)			
1	72 (13)	5 (9)	67 (13)	0.58	0.1–4.6	0.60
>2	12 (2)	0 (0)	12 (2)			
Height (cm)	164 (±6)	164.5 (±7)	164 (±6)	0.98	0.9–1.1	0.7
<i>Neonatal characteristics</i>						
Full term	582 (98)	55 (100)	527 (98)			0.1
Late preterm	11 (2)	0	11 (2)			
Gender						
M	331 (56)	26 (47)	305 (57)			
F	262 (44)	29 (53)	233 (43)	0.72	0.2–2.5	0.6
Weight (gr)	3312 (447)	3402 (446)	3302 (446)			
≤3000	139 (23)	8 (6)	131 (94)	1.0		
3001–3600	301 (51)	29 (10)	272 (90)	2.81	0.3–23.5	0.34
>3600	153 (26)	18 (12)	135 (88)	3.71	0.4–33.6	0.24
Macrosomia	29 (5)	4 (7)	25 (5)	1.98	0.25–16	0.52

Ys, years; BMI, body mass index; Pre-CS, Pre-caesarean section; NR Ctg-IIs, non-reassuring cardiotocography during second stage of labor; cm, centimeters; gr, grams.

^aNo patients.

tissue, choroid plexus or bridging veins in case of subdural haemorrhage.²¹ Towner and co-workers observed similar rates of ICH after instrumental vaginal delivery and caesarean section during labor, assuming the abnormal labor to be the common risk factor.⁴ This was not confirmed by equally large studies of Pollina et al. and Ekeus et al., who assumed the vacuum application per se to be an important variable.^{5,22}

In our study, minor injuries were more frequently detected, with overall incidence of 7.6%, similar to that reported by Ghidini et al.²³ and they were of scarce clinical significance.

Regarding obstetric characteristics, advanced maternal age correlated both with adverse neonatal outcomes and the occurrence of major injuries. Similar results have been reported before. Infants of older mothers had lower Apgar scores,²⁴ higher rates of foetal distress, meconium aspiration²⁵ and NICU admission.²⁶ Furthermore, we found a relationship between adverse neonatal outcomes and major head injuries, regardless of maternal and obstetric characteristics.

The risk of intracranial haemorrhage in perinatal asphyxia has been widely described. Hypothermia and rewarming cause fluctuations of cerebral blood flow, which might predispose to bleeding.²⁷ In addition, respiratory and hemodynamic instability of asphyxiated infants

Table 4 Proportion of patients with secondary outcomes and association with major injuries.

Neonatal outcomes	n (%)	Major injuries		
		OR	95% CI	p
Cord blood acidosis	19 (3.2)	^a		
PPV	52 (8.8)	4.1	1.1–15.9	0.04
AS5 ≤ 5	8 (1.4)	8.2	0.9–73.1	0.06
NICU admission	40 (6.8)	5.5	1.4–21.7	0.01
HIE	8 (1.4)	21.3	3.8–120.4	< 0.01

PPV, positive pressure ventilation; AS5, Apgar score at 5th minute; NICU, neonatal intensive care unit; HIE, hypoxic ischemic encephalopathy.

^a No patients.

enhances this risk.²⁸ Conversely, few reports have investigated features associated with intracranial injury in healthy term infants. A case–control study by Jhawar et al. reported an association between intracranial haemorrhage and birth resuscitation and low Apgar scores.²⁹ Hong et al. retrospectively reviewed data of term neonates with ICH diagnosed by brain MRI, and found a correlation between a low Apgar score at 5 min with poor clinical outcomes.³⁰

Table 5 Association between clinical features and secondary outcomes.

Characteristics	Cord acidosis		PPV		AS5 ≤5		NICU		HIE	
	OR	p	OR	p	OR	p	OR	p	OR	p
<i>Maternal characteristics</i>										
Age	1	0.67	1.1	0.01	1	0.19	1.1	< 0.01	1.3	< 0.01
Age ≥ 40 ys	0.4	0.40	2.3	0.03	4.8	0.03	3.3	< 0.01	14	< 0.01
BMI	1	0.59	1	0.23	1	0.64	1	0.55	1.1	0.39
BMI > 30	0.7	0.58	0.8	0.68	2	0.40	0.7	0.55	2	0.40
Pre-CS	1.7	0.43	0.5	0.32	ne		0.7	0.58	ne	
Induction of labor	0.9	0.83	1.9	0.03	2.6	0.19	1.4	0.36	2.6	0.19
Kristeller	0.9	0.84	1.8	0.07	2.9	0.15	1	0.99	2.9	0.15
NR ctg-IIs	3.4	0.01	1.6	0.18	2.2	0.31	1.4	0.39	1.2	0.86
Parity ≥ 1	1.6	0.43	1.8	0.12	2	0.41	1.6	0.29	0.8	0.86
Height (cm)	1	0.33	1	0.53	1	0.92	1	0.30	1	0.79
<i>Neonatal characteristics</i>										
Gender-Female	0.7	0.51	0.8	0.39	0.8	0.70	1.0	0.91	1.3	0.74
Weight (gr)										
≤3000	^a		^a		^a		^a		^a	
3001–3600	0.7	0.39	0.8	0.47	2.3	0.44	1.0	0.97	2.3	0.44
>3600	0.3	0.09	0.4	0.06	1.8	0.62	0.7	0.49	1.8	0.62
Macrosomia	^a		1.2	0.76	2.8	0.35	0.5	0.48	2.8	0.34

PPV, positive pressure ventilation; AS5, Apgar score at 5th minute; NICU, neonatal intensive care unit; HIE, hypoxic ischemic encephalopathy; Ys, years; BMI, body mass index; Pre-CS, Pre-caesarean section; NR Ctg-IIs, non-reassuring cardiotocography in the second stage of labor; cm, centimeters; gr, grams.

^a No patients.

It is noteworthy that almost one in ten neonates (9%) of our cohort needed resuscitation manoeuvres at birth, and head injuries were more likely to occur in these infants. In a large population study conducted in a high resource setting comparable to ours, the incidence of resuscitation at birth was 4.6%, almost half what we found.³¹

Our study has several limitations. First, this is a retrospective single-center study. Indication to perform vacuum extraction and its timing was based on clinical decision of the obstetric in charge. Duration of vacuum application, number of pulls and cup detachments were not always recorded, although in a recent study they were not associated with the occurrence of neonatal head injury.²³

Moreover, we lack a control cohort since term neonates born by vaginal delivery or caesarean section undergo a cUS only if clinically indicated. This is of particular relevance since the reported incidence of intracranial haemorrhage in term infants screened with cUS is highly variable. Hence, we are not able to define the additional risk due to vacuum application.

4.1. Conclusions and future perspectives

When vacuum extraction is indicated to assist vaginal delivery, it is generally a safe procedure for neonates. Neonatal head injuries are usually mild and asymptomatic and with spontaneous recovery. However, the rate of major cranial injuries in our cohort warrants further investigation to support a cUS screening, particularly for infants requiring respiratory support at birth.

Also, maternal age might be taken into account when evaluating the risk for brain complications after vacuum

application. Further research is needed to confirm our findings.

Declaration of competing interest

No conflict of interests declared.

References

1. Euro-Peristat Project. *European Perinatal Health Report. Core indicators of the health and care of pregnant women and babies in Europe in 2015*. November 2018, Euro-Peristat. Available at www.europeristat.com. Accessed April 5, 2022.
2. Baskett TF. Operative vaginal delivery – an historical perspective. *Best Pract Res Clin Obstet Gynaecol* 2019;56: 3–10.
3. Walsh CA, Robson M, McAuliffe FM. Mode of delivery at term and adverse neonatal outcomes. *Obstet Gynecol* 2013;121: 122–8.
4. Towner D, Castro MA, Eby-Wilkens E, Gilbert WM. Effect of mode of delivery in nulliparous women on neonatal intracranial injury. *N Engl J Med* 1999;341:1709–14.
5. Ekéus C, Högberg U, Norman M. Vacuum assisted birth and risk for cerebral complications in term newborn infants: a population-based cohort study. *BMC Pregnancy Childbirth* 2014;14:36.
6. Simonson C, Barlow P, Dehennin N, Sphel M, Toppet V, Murillo D, et al. Neonatal complications of vacuum-assisted delivery. *Obstet Gynecol* 2007;109:626–33.
7. Murphy DJ, Strachan BK, Bahl R, Royal College of Obstetricians and Gynaecologists. Assisted vaginal birth: green-top guideline No. 26. *BJOG* 2020;127:e70–112.
8. Vacca A. Vacuum-assisted delivery. *Best Pract Res Clin Obstet Gynaecol* 2002;16:17–30.

9. Volpe JJ, Inder TE, Darras BT, et al. *Neurology of the newborn*. 5th ed. Philadelphia: Elsevier; 2008. p. 517–88.
10. Shalak LF, Laptook AR, Velaphi SC, Perlman JM. Amplitude-integrated electroencephalography coupled with an early neurologic examination enhances prediction of term infants at risk for persistent encephalopathy. *Pediatrics* 2003;111:351–7.
11. Wen SW, Liu S, Kramer MS, Marcoux S, Ohlsson A, Sauvé R, et al. Comparison of maternal and infant outcomes between vacuum extraction and forceps deliveries. *Am J Epidemiol* 2001;153:103–7.
12. Demissie K, Rhoads GG, Smulian JC, Balasubramanian BA, Gandhi K, Joseph KS, et al. Operative vaginal delivery and neonatal and infant adverse outcomes: population based retrospective analysis. *BMJ* 2004;329:24–9.
13. Werner EF, Janevic TM, Illuzzi J, Funai EF, Savitz DA, Lipkind HS. Mode of delivery in nulliparous women and neonatal intracranial injury. *Obstet Gynecol* 2011;118:1239–46.
14. Baskett TF, Fanning CA, Young DC. A prospective observational study of 1000 vacuum assisted deliveries with the OmniCup device. *J Obstet Gynaecol Can* 2008;30:573–80.
15. Szpecht D, Frydryszak D, Miszczyk N, Szymankiewicz M, Gadzinowski J. The incidence of severe intraventricular hemorrhage based on retrospective analysis of 35939 full-term newborns—report of two cases and review of literature. *Childs Nerv Syst* 2016;32:2447–51.
16. Davis DJ. Neonatal subgaleal hemorrhage: diagnosis and management. *CMAJ* 2001;164:1452–3.
17. Vacca A. Operative vaginal delivery: clinical appraisal of a new vacuum extraction device. *Aust N Z J Obstet Gynaecol* 2001;41:156–60.
18. Luciano R, Bersani I, Mancini G, Vento G, Mercuri E. Cranial ultrasound evaluation in term neonates. *Early Hum Dev* 2020;143:104983.
19. Ballardini E, Tarocco A, Rosignoli C, Baldan A, Borgna-Pignatti C, Garani G. Universal head ultrasound screening in full-term neonates: a retrospective analysis of 6771 infants. *Pediatr Neurol* 2017;71:14–7.
20. Hsu CL, Lee KL, Jeng MJ, Chang KP, Yang CF. Cranial ultrasonographic findings in healthy full-term neonates: a retrospective review. *J Chin Med Assoc* 2012;75:389–95.
21. Rooks VJ, Eaton JP, Ruess L, Petermann GW, Keck-Wherley J, Pedersen RC. Prevalence and evolution of intracranial hemorrhage in asymptomatic term infants. *AJNR Am J Neuroradiol* 2008;29:1082–9.
22. Pollina J, Dias MS, Li V, Kachurek D, Arbesman M. Cranial birth injuries in term newborn infants. *Pediatr Neurosurg* 2001;35:113–9.
23. Ghidini A, Stewart D, Pezzullo JC, Locatelli A. Neonatal complications in vacuum-assisted vaginal delivery: are they associated with number of pulls, cup detachments, and duration of vacuum application? *Arch Gynecol Obstet* 2017;295:67–73.
24. Hsieh TT, Liou JD, Hsu JJ, Lo LM, Chen SF, Hung TH. Advanced maternal age and adverse perinatal outcomes in an Asian population. *Eur J Obstet Gynecol Reprod Biol* 2010;148:21–6.
25. Blomberg M, Birch Tyrberg R, Kjølhed P. Impact of maternal age on obstetric and neonatal outcome with emphasis on primiparous adolescents and older women: a Swedish Medical Birth Register Study. *BMJ Open* 2014;4:e005840.
26. Kahveci B, Melekoglu R, Evruke IC, Cetin C. The effect of advanced maternal age on perinatal outcomes in nulliparous singleton pregnancies. *BMC Pregnancy Childbirth* 2018;18:343.
27. Bashir RA, Vayalthrikkovil S, Espinoza L, Irvine L, Scott J, Mohammad K. Prevalence and characteristics of intracranial hemorrhages in neonates with hypoxic ischemic encephalopathy. *Am J Perinatol* 2018;35:676–81.
28. Al Yazidi G, Boudes E, Tan X, Saint-Martin C, Shevell M, Wintermark P. Intraventricular hemorrhage in asphyxiated newborns treated with hypothermia: a look into incidence, timing and risk factors. *BMC Pediatr* 2015;15:106.
29. Jhavar BS, Ranger A, Steven D, Del Maestro RF. Risk factors for intracranial hemorrhage among full-term infants: a case-control study. *Neurosurgery* 2003;52:581–90. discussion 588–90.
30. Hong HS, Lee JY. Intracranial hemorrhage in term neonates. *Childs Nerv Syst* 2018;34:1135–43.
31. Bjorland PA, Øymar K, Erdsdal HL, Rettedal SI. Incidence of newborn resuscitative interventions at birth and short-term outcomes: a regional population-based study. *BMJ Paediatr Open* 2019;3:e000592.