

## Intraoperative mapping of epileptogenic foci and tumor infiltration in neuro-oncology patients with epilepsy

Dongqing Sun<sup>○</sup>, Eline V. Schaft<sup>○</sup>, Bibi M. van Stempvoort, Tineke A. Gebbink, Maryse van 't Klooster<sup>○</sup>, Pieter van Eijsden<sup>○</sup>, Sandra M.A. van der Salm<sup>○</sup>, Jan Willem Dankbaar, Maeike Zijlmans<sup>†,○</sup>, and Pierre A. Robe<sup>†,○</sup>; on behalf of the RESPECT group

All author affiliations are listed at the end of the article

<sup>†</sup>These authors contributed equally to this work.

Corresponding Author: Maeike Zijlmans, MD, PhD, Department of Neurology and Neurosurgery, University Medical Center Utrecht Brain Center, University Medical Center Utrecht, Heidelberglaan 100, 3584 CX Utrecht, The Netherlands ([g.j.m.zijlmans@umcutrecht.nl](mailto:g.j.m.zijlmans@umcutrecht.nl)).

### Abstract

**Background.** Epileptogenesis and glioma growth have a bidirectional relationship. We hypothesized people with gliomas can benefit from the removal of epileptic tissue and that tumor-related epileptic activity may signify tumor infiltration in peritumoral regions. We investigated whether intraoperative electrocorticography (ioECoG) could improve seizure outcomes in oncological glioma surgery, and vice versa, what epileptic activity (EA) tells about tumor infiltration.

**Methods.** We prospectively included patients who underwent (awake) ioECoG-assisted diffuse-glioma resection through the oncological trajectory. The ioECoG-tailoring strategy relied on ictal and interictal EA (spikes and sharp waves). Brain tissue, where EA was recorded, was assigned for histopathological examination separate from the rest of the tumor. Weibull regression was performed to assess how residual EA and extent of resection (EOR) related to the time-to-seizure recurrence, and we investigated which type of EA predicted tumor infiltration.

**Results.** Fifty-two patients were included. Residual spikes after resection were associated with seizure recurrence in patients with isocitrate dehydrogenase (IDH) mutant astrocytoma or oligodendroglioma (HR = 7.6[1.4–40.0], *P*-value = .01), independent from the EOR. This was not observed in IDH-wildtype tumors. All tissue samples resected based on interictal spikes were infiltrated by tumor, even if the MRI did not show abnormalities.

**Conclusions.** Complete resection of epileptogenic foci in ioECoG may promote seizure control in IDH-mutant gliomas. The cohort size of IDH-wildtype tumors was too limited to draw definitive conclusions. Interictal spikes may indicate tumor infiltration even when this area appears normal on MRI. Integrating electrophysiology guidance into oncological tumor surgery could contribute to improved seizure outcomes and precise guidance for radical tumor resection.

### Key Points

- Residual epileptic activity in intraoperative electrocorticography is associated with seizure recurrence in IDH-mutant tumors.
- Spikes indicated tumor infiltration in brain tissue without distinct MRI-abnormality.

Glioma-related epilepsy is one of the symptoms of diffuse low- and high-grade gliomas.<sup>1,2</sup> The burden of epilepsy and anti-seizure medication significantly reduce the quality of life and induce additional cognitive impairments.<sup>3–5</sup> The current treatment paradigm is to aim for maximal tumor

resection, performed in a safe fashion when needed with the help of awake craniotomy to define functional brain tissue.<sup>6</sup> Removal of all epileptogenic tissue, which can extend beyond the tumor borders both locally and distantly, is crucial for achieving postoperative seizure freedom.<sup>4,7–11</sup>

## Importance of the Study

Intraoperative electrocorticography (ioECoG) can record interictal epileptic activity directly from the cortex to delineate the epileptogenic foci. Evidence on the surplus of ioECoG-tailored surgery in diffuse-glioma patients is limited in neuro-oncology. We prospectively studied the potential of ioECoG to guide glioma surgery in the neuro-oncology setting, and aimed to answer 2 questions: (1) Could ioECoG map the epileptogenic foci and improve seizure outcome? and (2) What does epileptic activity reveal about tumor infiltration? We demonstrated that complete resection of epileptogenic

foci identified through ioECoG was associated with favorable seizure outcomes in patients with IDH-mutant gliomas, independent from the extent of resection. The presence of interictal spikes signified tumor infiltration even in areas without distinct abnormalities on MRI in both IDH-mutant and IDH-wildtype gliomas. These findings suggest that integrating intraoperative electrophysiology guidance into oncological tumor surgery may contribute to improved seizure outcomes and precise guidance for radical tumor resection.

Intraoperative electrocorticography (ioECoG) is used to identify the epileptogenic tissue by recording epileptic activities directly from the cortex, which translates to surgical decisions in real time.<sup>12–15</sup> This method is called “ioECoG-tailoring.” Incomplete resection of tissue with epileptic activity is associated with postoperative seizure recurrence, and ioECoG may contribute to favorable seizure outcomes.<sup>13,16–18</sup>

Literature on ioECoG-tailoring in diffuse glioma patients is sparse and mainly conducted in epilepsy surgery settings. The results of these studies are not generalizable to oncology patients as both trajectories involve different presurgical evaluation, surgical approaches, and patient selection. People in the oncological neurosurgery trajectory typically exhibit shorter epilepsy duration, thus limited epilepsy-related plasticity and diminished epileptogenic network. Their seizures are not always refractory to medication, in contrast to the epilepsy surgery population.<sup>19–21</sup> This suggests a need for exploring the surplus of ioECoG-tailored surgery in oncological neurosurgery.

There may be a bidirectional relationship between epilepsy and glioma growth, and seizure reduction and cytoreduction are associated.<sup>4,7,22–25</sup> Epileptic activity in ioECoG may signify tumor infiltration in the peritumoral regions and support the pursuit of a greater extent of resection (EOR) effectively. Greater EOR correlates with prolonged survival and favorable seizure outcome, but gross-total resection (GTR) and supramaximal resection are difficult to achieve as glioma cells permeate beyond the borders of MRI abnormalities.<sup>4,22,26–30</sup> Extending the resection outside the macroscopic abnormalities should ideally be guided by tools that help identify tumor infiltration.<sup>31</sup> We hypothesize that ioECoG can assist in distinguishing glioma-infiltrated tissue from healthy brain tissue based on the electrophysiological signature of glioma cells.

We propose that seizure reduction should be an aim of oncological surgery in addition to cytoreduction. We hypothesize that these aims work synergistically. We studied the potential of ioECoG-tailoring to delineate epileptogenic foci and improve seizure outcomes. Additionally, we aimed to investigate whether epileptic activity in ioECoG could identify tissue infiltrated by tumor cells that would have been unrecognized otherwise.

## Materials and Methods

### Patient Cohort

ioECoG-tailoring was prospectively performed in all patients who underwent surgical resection of diffuse glioma with GRE in the University Medical Center Utrecht unless ioECoG was unavailable due to logistical difficulties. We included all patients in the neurooncological trajectory operated with ioECoG in 2016–2022. Patients with histopathological diagnoses other than diffuse gliomas or patients with pre-existing medically intractable epilepsy disorders in their medical history were excluded.

### Ethical Approval

All patients were participants of the *Registration database for Epilepsy surgery patients in het UMC Utrecht and Stichting Epilepsie Instellingen Nederland (RESPECT database)*, which is registered by the institute’s Medical Research Ethical Committee under protocol number 18-109. Patients who were included after 2018 gave informed consent for data collection. For all data before 2018, the need for informed consent was waived.

### Anesthetic Techniques

All but 1 patient was operated under “awake” conditions with local anesthesia to enable intraoperative functional brain mapping using direct electrical stimulation. Patients were operated with fully awake procedures under local anesthesia. Microscope view, intraoperative ultrasound and neuronavigation were used for surgical guidance. Patients were positioned in park bench positions, allowing the patients to lay in a comfortable fashion facing the neuropsychologist and/or anesthesiologists during surgery. Local anesthesia (a mix of 5 mg/mL chirocaine 1:1 v:v and 2% lidocaine with adrenaline 1:200 000) was injected at the pin sites during the placement of the Mayfield clamp and around the planned surgical site before the incision. After removal of the bone flap, anesthetics mix-soaked gelatin foam was applied onto the dura at the level of the

meningeal arteries. Patients received titrated pain sedation with short-acting opioids (eg remifentanyl) and low-dose propofol. One patient was operated under general anesthesia with propofol. This patient remained asleep throughout the procedure and did not undergo functional mapping. Propofol administration was stopped before each ioECoG recording until a continuous background pattern with minimal propofol effects was obtained.

### IoECoG Recording & Tailoring

IoECoG was recorded using 4 × 4 silicone grids embedded with 4.2 mm<sup>2</sup> contact surface electrodes with 1 cm spacing (DIXI Medical) or 8 × 16 grids with 1 mm<sup>2</sup> contact surface electrodes with 3 mm spacing (PMT). IoECoG signals were recorded with a 24 or 128-channel EEG system (Micromed) at 2048 Hz sample frequency. IoECoG findings and interpretation were available through clinical reports. The location of the ioECoG electrodes was captured by photographs taken during surgery. IoECoG was recorded multiple times during surgery to tailor the resection of epileptogenic tissue. We classified all ioECoG recordings before the final resection as tailorECoG and all recordings after the final resection as postECoG. IoECoG recordings were analyzed and interpreted by a dedicated clinical neurophysiology team of a physician assistant or technician and a supervising clinical neurophysiologist during surgery. The tailoring strategy during surgery focused on finding the presumed epileptogenic tissue based on epileptic activity in the normal frequency range (ie sporadic spikes, continuous spiking patterns, sporadic sharp waves, continuous pattern of sharp waves, and seizures). Epileptic activity in the postECoG was referred to as residual epileptic activity. In clinical practice, ioECoG guided the tumor resection in the following ways:

1. In case of epileptic activity was recorded and the epileptogenic tissue was located within the borders of the original resection plan based on MRI, the neurosurgeon started with resection of this area first before removing the other parts of the tumor. This way, the epileptogenic focus was removed before potential cortical reorganization;
2. In case of epileptic activity was recorded outside the borders of the original resection plan, this tissue was subsequently resected, provided this area exhibited no eloquent functions and was in proximity to the tumor. Epileptic activity distant from the planned resection area was not removed.
3. In case of the absence of epileptic activity, the original resection plan was executed.

### Clinical, Imaging, and Histopathological Data

Clinical data collected from the electronic patient records were sex, age at surgery, seizure type before surgery, previous brain surgery, affected hemisphere, and anatomical location of the tumor. We collected postoperative seizure outcomes at the longest available follow-up. Seizure freedom was defined as free from seizures and

auras after surgery in concordance with ILAE class I.<sup>32</sup> The seizure-free period (SF-period) was defined as the period between the surgery and the first postoperative seizure. Patients with only acute postoperative seizures (ie seizures within the first 7 days after surgery) were considered seizure-free.

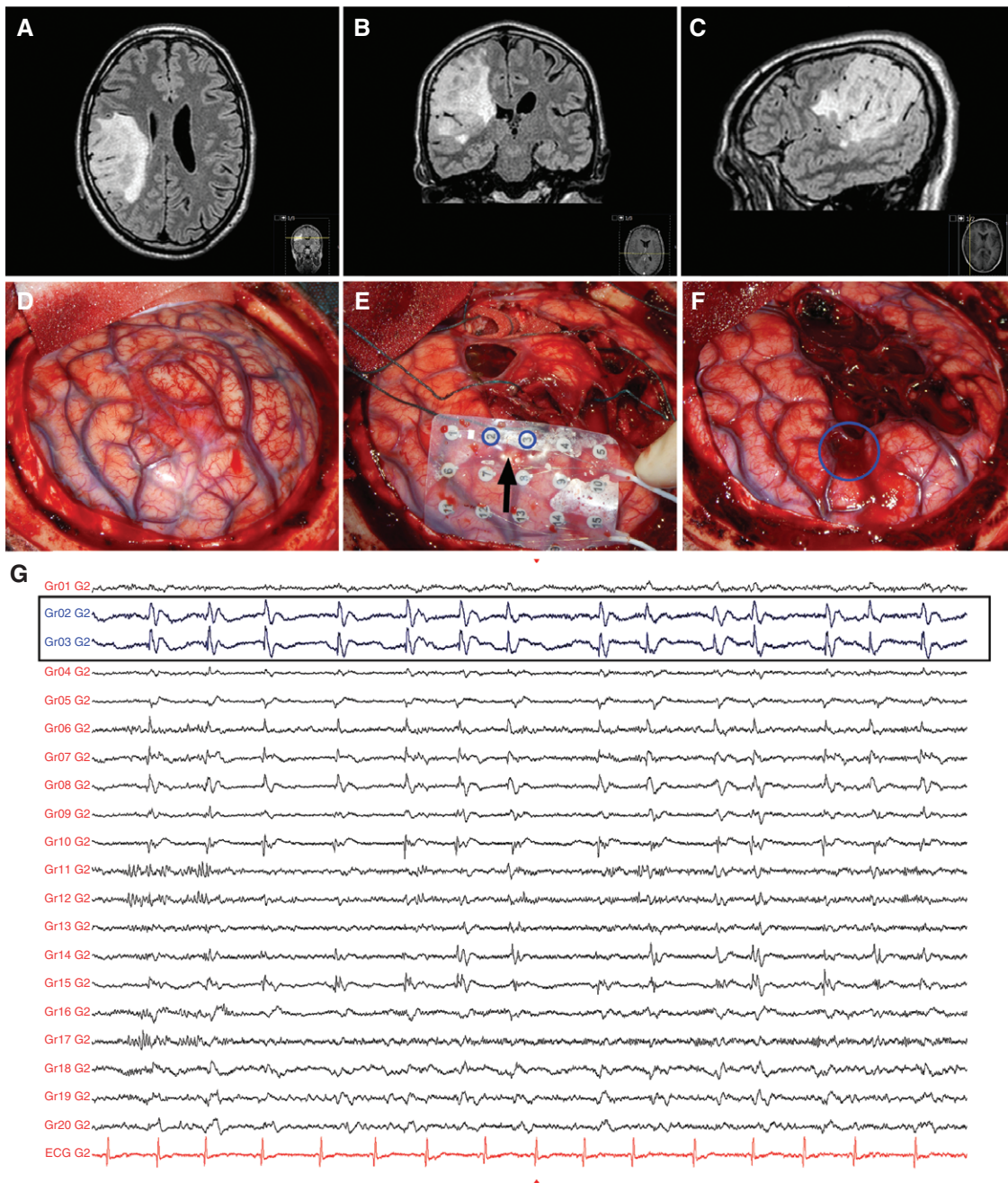
Routinely performed pre and postoperative 3D MRIs were available for imaging postprocessing analyses. Pre and postoperative (residual) tumor volumes (in cm<sup>3</sup>) were rendered with ITK Snap V3.6.0 using the pre and postoperative (within 24–72 h after surgery) 3D navigation MRI. We primarily used 3D T2-weighted fluid-attenuated inversion recovery (FLAIR) series for rendering nonenhancing tumors and MRI-T1 with gadolinium series for contrast-enhancing tumors. The extent of resection (EOR) was calculated as (preoperative tumor volume – postoperative residual tumor volume) / preoperative tumor volume × 100%. Gross-total resection was defined as no residual hyperintensity on postoperative 3D FLAIR series for nonenhancing tumors and no residual contrast enhancement on postoperative contrast-enhanced T1-weighted series for contrast-enhancing tumors. The resection was considered to be subtotal when GTR was not reached. Radiographic images were reviewed by DS and supervised by the neurosurgeon (PR) and the neuroradiologist (JWD).

Histopathological diagnosis was determined according to the revised 2021 WHO classification of tumors of the central nervous system (CNS).<sup>33</sup> We collected tumor type and WHO grade. In case brain tissue that was resected based on epileptic activity in ioECoG could be removed “en bloc” during surgery, this tissue was analyzed for histopathology separate from the rest of resected tumor tissue (Figure 1). We did not analyze the extent of tumor infiltration in our specimen. The epileptic tissue could be located either within or outside the borders of the MRI abnormalities. The location of epileptogenic tissue was determined by neurosurgeons directly during surgery based on neuronavigation MRIs and cortical landmarks and confirmed retrospectively by comparing the gyri and sulci pattern on intraoperative photographs to the preoperative and neuronavigation MRIs (Figure 1). MRI abnormalities were identified using the T2-FLAIR series for nonenhancing tumors and MRI-T1 with gadolinium series for contrast-enhancing tumors.

### Statistical Analyses

The data were not normally distributed thus we applied nonparametric statistical methods. We reported continuous variables as medians with interquartile ranges (IQR) and categorical variables as frequencies and percentages (%). We investigated the association between the baseline characteristics and the presence of epileptogenic activity in tailorECoG. The following tests were used: the chi-square test, Fisher’s exact test, or the Fisher’s–Freeman–Halton test for categorical variables, and the Mann–Whitney *U* test for continuous variables. We investigated potential associations between MRI abnormalities, discharge types and pattern types in ioECoG with tumor infiltration in the tissue samples designated for separate histopathological examination. We compared (1) the group with MRI abnormalities





**Figure 1.** Example of iECoG-tailored surgery. A—C: Oligodendroglioma WHO grade II in the right parietal lobe on the presurgical MRI FLAIR. D: The tumor is exposed after craniotomy. E: Intraoperative electrocorticography was placed on the cortex after partial tumor resection (tailorECoG). The numbers 1–20 on the grid mark the positions of the electrodes. One of the epileptogenic foci was found under electrodes 2 and 3 (within rectangle) which was outside the MRI-abnormality, just over the sulcus. F: Final result after iECoG-tailored tumor surgery. The epileptogenic focus was resected en bloc (blue) and analyzed for histopathology. G: 20 s of iECoG data (high pass filter 1.6 Hz, low pass filter 80.0 Hz, gain 50  $\mu\text{V}/\text{cm}$ , Notch filter on). Continuous spikes pattern was recorded in multiple electrodes. Signal recorded in electrodes 2 and 3 (blue) was most prominent and resected during surgery.

to the group without MRI abnormalities; (2) the spike group to the sharp-waves group and the electrographic seizure group, and (3) the continuous patterns group to the sporadic interictal discharge group. For these analyses, we used the Fisher's exact test and the Fisher's–Freeman–Halton test. To evaluate the association between residual

activity and seizure outcome, we performed time-to-event analysis, in other words, time-to-seizure recurrence ( $T_{\text{SR}}$  in months) analysis. For this analysis, we categorized the patients into 2 groups based on tumor classification (group I: astrocytoma, IDH-mutant or oligodendroglioma, IDH-mutant; and group II: glioblastoma, IDH-wildtype). For the

univariable analysis, we carried out Kaplan–Meier modeling with log-rank testing in covariates that could be associated with seizure outcome including seizure type, reoperation, tumor location, tumor grade, the extent of resection, and residual spikes. For the multivariable analysis, we used the Weibull regression model, a parametric regression model for multivariable analysis including variables with a *P*-value of  $\leq .10$  from the univariable analyses. Residual spikes and EOR were included in the multivariable Weibull model regardless of the *P*-value in the univariable analyses given their important association with seizure outcomes described in the literature. A *P*-value of  $< .05$  was considered statistically significant. Statistical analyses were performed in IBM SPSS Statistic (Version 26.0.: IBM Corp), and Rstudio (RStudio, Inc.).

## Results

### Patient Cohort

We included 52 patients with GRE who underwent ioECoG-tailored oncological neurosurgery (Table 1). Twenty-two patients were diagnosed with astrocytoma, IDH-mutant. Thirteen patients were diagnosed with oligodendroglioma, IDH-mutant. Sixteen patients were diagnosed with glioblastoma, IDH-wildtype. The pathology analyses were inconclusive in determining the nature of the anomaly in 1 patient. Reoperation was conducted in 5 patients diagnosed with IDH-mutant astrocytoma, in 3 patients diagnosed with IDH-mutant oligodendroglioma, and in 2

**Table 1.** Patient Characteristics

Main Characteristics	Complete Cohort (N = 52)		EA in TailorECoG (N = 42)	
			EA Present (%)	P-Value
<b>Clinical characteristics</b>				
Sex (n, %)	Male	29 (56)	22 (52)	
	Female	23 (44)	20 (48)	.48 <sup>c</sup>
Age (y)	(median, IQR)	45 [37–59]	45 [37–58]	.68 <sup>d</sup>
Seizure type before surgery (n, %) <sup>a</sup>	Focal	24 (46)	22 (52)	
	(sec.) generalized	27 (52)	20 (48)	.15 <sup>c</sup>
Reoperation (n, %)	Yes	10 (19)	8 (19)	1.00 <sup>e</sup>
Hemisphere (n, %)	Left	30 (58)	24 (57)	
	Right	22 (42)	18 (43)	1.00 <sup>c</sup>
Tumor location (n, %)	Frontal	27 (52)	19 (45)	
	Temporal	14 (28)	14 (33)	
	Parietal	3 (6)	3 (7)	
	Multilobar	8 (15)	6 (14)	.09 <sup>e</sup>
Preoperative tumor volume (cm <sup>3</sup> )	(median, IQR)	25 [16–56]	29 [16–57]	.78 <sup>d</sup>
Rest tumor volume (cm <sup>3</sup> )	(median, IQR)	7 [0–19]	7 [0–22]	.59 <sup>d</sup>
EOR (%)	(median, IQR)	77 [58–100]	76 [56–100]	.68 <sup>d</sup>
Postoperative seizure outcome at last available follow-up (n, %) <sup>b</sup>	Seizure free	28 (54)	22 (55)	
	Seizure recurrence	22 (42)	18 (45)	1.00 <sup>c</sup>
Follow-up period (months) <sup>b</sup>	(median, IQR)	23 [13–37]	26 [12–37]	.80 <sup>d</sup>
<b>Pathology according to WHO 2021</b>				
Tumor classification	Astro, IDH-mutant	22 (42)	16 (44)	
	Oligo, IDH-mutant	13 (25)	9 (25)	
	GBM, IDH-WT	16 (31)	11 (31)	1.00
	Gliosis	1 (2)	Not included	
Tumor grade (n, %)	2	26 (50)	19 (53)	
	3	7 (14)	4 (11)	
	4	18 (35)	13 (36)	.71 <sup>e</sup>
	Other	1 (2)	Not included	

**Abbreviations:** %: percentage listed in brackets; EOR: extent of resection; GBM: glioblastoma; IDH: isocitrate dehydrogenase mutation status; IQR: interquartile range; *n*: number of patients; sec: secondary; WHO: World Health Organization; WT: wildtype; *y*: year.

<sup>a</sup>1 missing data.

<sup>b</sup>2 lost to follow-up.

<sup>c</sup> = Fisher's exact test.

<sup>d</sup> = Mann–Whitney *U* test.

<sup>e</sup>Fisher–Freeman–Halton test.

patients diagnosed with IDH-wildtype glioblastoma. The median [IQR] postoperative follow-up period was 23 [13–37] months. Fifteen patients (32%) had 1 or more seizures within 6 months after surgery.

### Epileptic Activity in Intraoperative Electrographic Activity

**Epileptic Activity on TailorECoG.**—TailorECoG was recorded in all 52 patients. Epileptic activity was recorded in the tailorECoG of 42 patients. The presence of epileptic activity was not correlated to the baseline characteristics (Table 1). Interictal spikes were recorded in 30 patients (58%). We found sporadic spikes in 19 patients and continuous spiking patterns in 11 patients. Sixteen out of these 30 patients also showed interictal sharp waves. Seven patients had interictal sharp waves without interictal spikes.

Spontaneous electrographic seizures were recorded in 8 patients (15%). Seizures were asymptomatic in 3 patients and associated with focal symptoms in 5 patients (focal sensory seizures in 2 patients and focal motor seizures in 3 patients). Intraoperative seizures were observed in 2 out of 22 patients (9%) diagnosed with IDH-mutated astrocytoma, 2 out of 13 patients (15%) with IDH-mutated oligodendroglioma, and 4 out of 16 (31%) patients with IDH-wildtype glioblastoma ( $P = .34$ , Fisher's–Freeman–Halton test).

### Residual Epileptic Activity in PostECoG

PostECoG was recorded in 51 patients. PostECoG was not performed in 1 patient; this patient did not show epileptic activity in the tailorECoG. Residual interictal spikes were recorded in 10 patients: 9 patients showed sporadic spikes and 1 patient showed a continuous spiking pattern. Eight patients had residual sharp waves without spikes. Electrographic seizures were not recorded in the postECoG.

### PostECoG Epileptic Activity and Seizure Outcome

**Patients Diagnosed with IDH-Mutated Tumors.**—We investigated the association between residual epileptic activity in postECoG and seizure recurrence. Thirty-four patients with IDH-mutated astrocytoma or IDH-mutated oligodendroglioma underwent postECoG. Residual epileptic activity was recorded in eleven (32%) patients. Residual spikes were recorded in 6 (18%) patients and 2 of them also showed sharp waves. Sharp waves without spikes were recorded in 4 (11%) patients. One patient with residual spikes was lost to follow-up.

Univariable Kaplan–Meier modeling revealed a significant association between residual spikes and seizure recurrence. Patients with residual spikes experienced earlier seizure recurrence than patients without residual spikes. The mean duration until seizure recurrence in the residual spike groups was 12 months [IQR = 1–23] in contrast to 48 months [IQR = 37–60] for patients without residual spikes; ( $P = .05$ , log-rank test; Figure 2A). Seizure type, reoperation, tumor location, tumor grade and the EOR were not significantly associated with seizure recurrence and did not

meet the inclusion criteria for the multivariable analyses. Multivariable analysis included residual spikes and EOR. The presence of residual spikes was significantly associated with early seizure recurrence after surgery (HR [95% CI] = 7.6 [1.4–40.0],  $P$ -value = .01, Table 2). Subtotal resection was not associated with seizure recurrence (HR [95% CI] = 3.4 [0.6–21.0],  $P$ -value = .17, Table 2).

### Patients Diagnosed with IDH-Wildtype Glioblastomas

Sixteen patients with glioblastoma, IDH-wildtype underwent postECoG. Residual epileptic activity was recorded in 7 (44%) patients. Residual spikes were recorded in 4 (25%) patients. Residual sharp waves without spikes were recorded in 3 (21%) patients. One patient without residual epileptic activity was lost to follow-up.

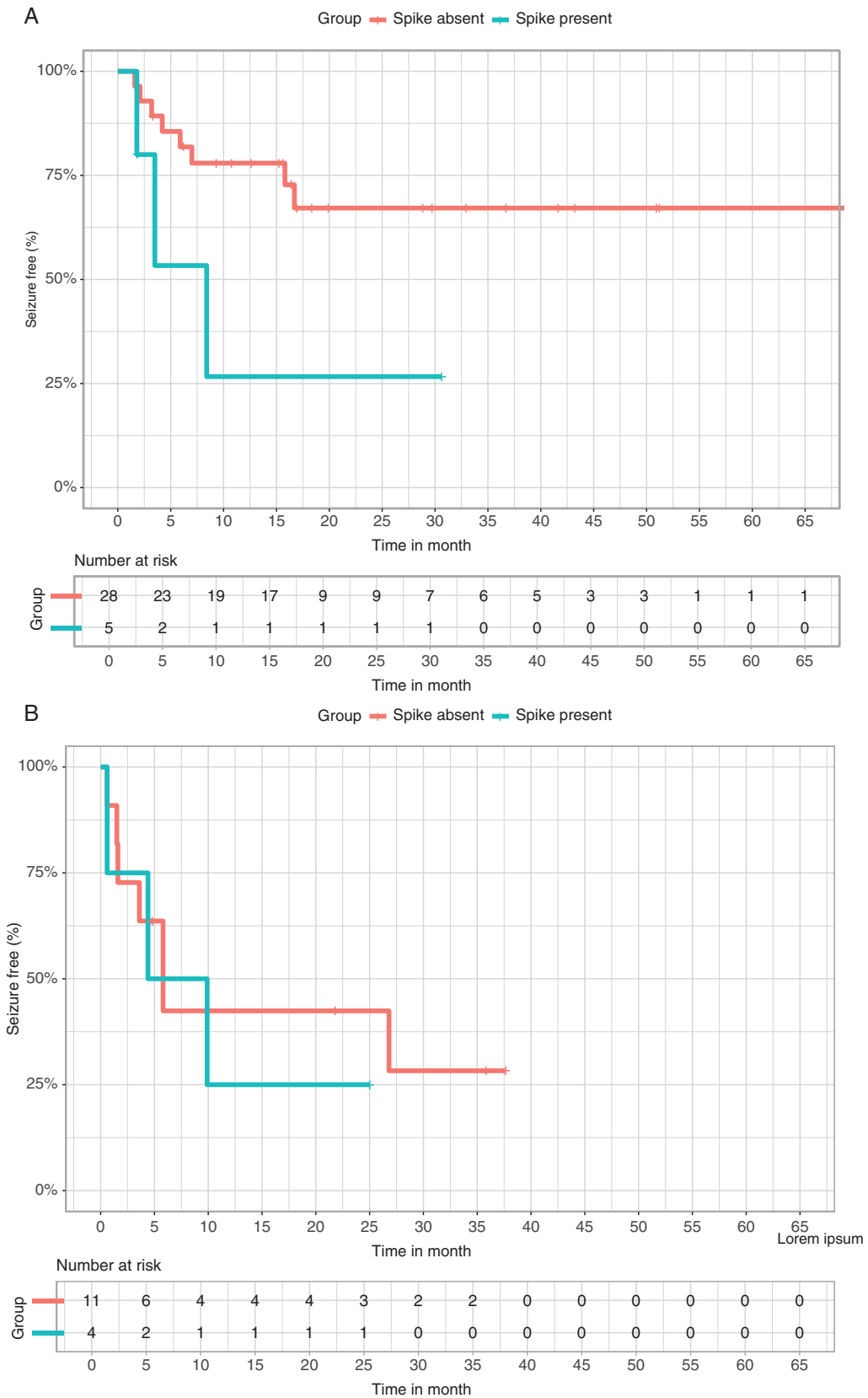
We performed univariable Kaplan–Meier analyses and no covariates showed  $P$ -value  $\leq .10$ . Patients with and without residual spikes have a similar time to seizure recurrence (respectively 10 months [IQR = 1–19] and 16 months [IQR = 7–26],  $P = .66$ , log-rank test; Figure 2B). We included residual spikes and EOR in the multivariable analyses. The presence of residual spikes and EOR were not significantly associated with seizure recurrence (Table 2).

### Histopathological Analyses of Tissue Samples Showing Epileptic Activity

**Recorded Electrographic Activity.**—Interictal spikes, interictal sharp waves, or electrographic seizures were recorded in the tailorECoG of 42 patients. In 24 patients, tissue resected based on epileptic activity could not be separated from tissue resected based on the original surgical plan. Eventually, 26 specimens from 18 patients could be analyzed for histopathology separate from the tissue resected based on the original surgical plan (Table 3). Sixteen samples were resected based on *interictal spike discharges*: 7 showed a continuous spiking pattern and 9 showed only sporadic spikes. One of these samples showed both interictal spike discharges (continuous spiking pattern) and electrographic seizures. This sample was assigned to the interictal spikes discharge group for the subsequent analyses. Seven samples were resected based on *interictal sharp-wave discharges*: 1 continuous pattern and 6 sporadic sharp wave. Four samples were resected based on *electrographic seizure discharges*.

### Tumor Infiltration in Tissue Samples

In the whole group, 19 out of 26 samples were infiltrated by tumor cells. Seventeen samples were obtained from areas that appeared normal on MRI, and out of these, 13 samples showed tumor infiltration (76%). Nine resected samples were resected from areas with MRI abnormalities, and 6 samples showed tumor infiltration (67%). The presence of abnormalities on MRI was not associated with tumor infiltration ( $P = .66$ , Fisher's exact test, Table 4). All 16 samples resected based on interictal spike discharges showed tumor infiltration (100%). Two out of 7 samples resected



**Figure 2.** Time-to-seizure recurrence. A: Time-to-seizure recurrence based on residual spikes in postECoG of patients with IDH-mutant tumors (red/longest curves = residual spikes absent, blue/shortest curves = residual spikes present). B: Time-to-seizure recurrence based on residual spikes in postECoG in patients with IDH-wildtype tumors (red = residual spikes absent, blue = residual spikes present).

**Table 2.** Multivariable Weibull Analyses of Factors Associated with Seizure Recurrence

	Parameters		HR	[95% CI]	P-Value
IDH-mutated gliomas	Residual spikes	No	1		
		Yes	<b>7.6</b>	<b>[1.4–40.0]</b>	<b>.01</b>
	EOR	GTR	1		
		Subtotal resection	3.4	[0.6–21.0]	.17
IDH-wildtype glioblastomas	Residual spikes	No	1		
		Yes	1.4	[0.3–5.9]	.68
	EOR	GTR	1		
		Subtotal resection	1.0	[0.2–3.8]	.96

**Abbreviations:** 95% CI: 95% confidence interval; EOR: extent of resection; GTR: gross-total resection; HR: hazard ratio. Bold:  $P < .05$ .

**Table 3.** Overview of Tissue Samples Resected Based on ioECoG Findings

Patient ID And sample Number	Histopathology Tumor Type	Characteristics of Tissue Samples Resected Based on ioECoG			
		MRI Characteristics	TailorECoG Epileptic Activity		Tumor Cell Infiltration
			Discharge	Pattern	
A_1	GBM_IDHwt	Abnormal	Spikes & ES	Continuous & ES	Yes
B_1	AA, IDH+	Normal	Spikes	Continuous	Yes
C_1	AA, IDH+	Normal	Spikes	Continuous	Yes
D_1	OG_IDH+	Normal	Spikes	Continuous	Yes
D_2	OG, IDH+	Normal	Spikes	Continuous	Yes
E_1	GBM, IDHwt	Normal	Spikes	Continuous	Yes
E_2	GBM, IDHwt	Normal	Spikes	Continuous	Yes
F_1	AA, IDH+	Abnormal	Spikes	Sporadic	Yes
G_1	OG, IDH+	Abnormal	Spikes	Sporadic	Yes
H_1	AA, IDH+	Normal	Spikes	Sporadic	Yes
I_1	AA, IDH+	Normal	Spikes	Sporadic	Yes
J_1	OG, IDH+	Normal	Spikes	Sporadic	Yes
K_1	OG, IDH+	Normal	Spikes	Sporadic	Yes
D_3	GBM, IDHwt	Normal	Spikes	Sporadic	Yes
D_4	GBM, IDHwt	Normal	Spikes	Sporadic	Yes
L_1	GBM, IDHwt	Normal	Spikes	Sporadic	Yes
M_1	AA, IDH+	Abnormal	Sharp waves	Continuous	Yes
N_1	AA, IDH+	Abnormal	Sharp waves	Sporadic	Yes
O_1	OG, IDH+	Abnormal	Sharp waves	Sporadic	No
F_2	AA, IDH+	Normal	Sharp waves	Sporadic	No
N_2	OG, IDH+	Normal	Sharp waves	Sporadic	No
P_1	OG, IDH+	Normal	Sharp waves	Sporadic	No
A_2	GBM, IDHwt	Normal	Sharp waves	Sporadic	No
Q_1	OG, IDH+	Abnormal	ES	ES	Yes
R_1	GBM, IDHwt	Abnormal	ES	ES	No
R_2	GBM, IDHwt	Abnormal	ES	ES	No

**Abbreviations:** AA: astrocytoma; blue: abnormal on MRI; continuous: continuous pattern; discharge: ioECoG discharge; ES: electrographic seizure; GBM: glioblastoma; green: normal on MRI; IDH: IDH status; M: mutated; OG: oligodendroglioma; pattern: pattern of the interictal discharges; WT: wild type.



**Table 4.** Tumor Infiltration of Tissue Samples Resected Based on Epileptic Activity

Characteristics of Tissue Samples		Tumor Infiltrated	No Tumor Infiltration	P-Value
MRI-findings	Abnormal	6 (67)	3 (33)	.66 <sup>a</sup>
	Normal	13 (76)	4 (24)	
Type of epileptic activity	Interictal spikes	16 (100)	0 (0)	<.001 <sup>b,*</sup>
	Interictal sharp waves	2 (29)	5 (71)	
	Electrographic seizures	1 (33)	2 (67)	
Pattern of epileptic activity	Continuous interictal activity	8 (100)	0 (0)	.06 <sup>b</sup>
	Sporadic interictal activity	10 (67)	5 (33)	
	Ictal activity	1 (33)	2 (67)	

**Abbreviation:** %: percentage listed in brackets.

<sup>a</sup>Fisher's exact test.

<sup>b</sup>Fisher–Freeman–Halton test.

<sup>\*</sup>Indicates statistical significance.

based on interictal sharp waves were infiltrated by tumor cells (29%). Two out of 3 samples with electrographic seizures showed tumor infiltration (33%). The presence of interictal spike discharges was associated with tumor infiltration ( $P < .001$ , Fisher–Halton–Freeman test, Table 4). The interictal discharge pattern (continuous interictal discharges versus sporadic interictal discharges) was not associated with tumor infiltration. All tissue samples resected based on continuous patterns of interictal discharges showed tumor infiltration (100%), and 10 out of 15 samples resected based on sporadic patterns of interictal discharges showed tumor infiltration (67%,  $P = .06$ , Fisher–Halton–Freeman test, Table 4).

## Discussion

ioECoG may guide the mapping of epileptogenic foci and tumor infiltration during neurooncological surgery. On the aspect of epilepsy foci mapping, we observed that the complete resection of spikes was linked to favorable seizure outcome, as demonstrated by a significantly prolonged period of seizure freedom in this group compared to patients with residual epileptogenic foci in postECoG, with a mean difference of seizure recurrence of 36 months in patients with IDH-mutant astrocytoma and oligodendroglioma. In the context of tumor tissue mapping, interictal spikes in ioECoG appeared to be distinctive electrophysiological features of glioma infiltration in both IDH-mutant and IDH-wildtype tumors. All tissue samples resected based on interictal spikes contained infiltrative tumor cells, even when this area appeared normal on MRI.

Residual spikes in postECoG were associated with poor seizure outcomes in patients with IDH-mutant gliomas. ioECoG is frequently studied in epilepsy surgery and is suggested to render a higher chance of seizure freedom compared to lesionectomy alone in low-grade tumors.<sup>16,18,34–36</sup> Whether the application of ioECoG is necessary to accomplish favorable seizure outcomes in epilepsy surgery is unresolved, as other studies did not convey the

same results.<sup>37–39</sup> Low-grade diffuse gliomas represented small subsets in these studies and were often not studied in separate cohorts. Electrophysiological features and seizure outcomes in low-grade tumors vary.<sup>40,41</sup> We evaluated ioECoG-tailored surgery in a cohort of diffuse glioma patients within the neuro-oncological trajectory. In patients with IDH-mutated tumors, incomplete resection of spikes was associated with an early seizure recurrence with a hazard ratio of 7.6 compared to the group without residual spikes in postECoG. We suspect that postresection ioECoG predicted seizure outcome so fiercely in this cohort because diffuse glioma patients in neuro-oncology trajectory typically proceed to surgery promptly regardless of their responses to anti-seizure medication. This brief history of seizures, in contrast to the long-term refractory epilepsy in epilepsy surgery cohorts, limits epilepsy-related plasticity and diminishes the epileptogenic network, which may reduce the risks of areas outside the original seizure onset zone acquiring the potential to generate seizures.<sup>19–21</sup> Complete resection of epileptic foci identified by ioECoG may help to directly improve seizure control in patients with IDH-mutant tumor-associated epilepsy who undergo tumor resection through the neuro-oncology trajectory.

Studies conducted in low-grade glioma surgery without ioECoG have shown that GTR was the key to seizure control.<sup>4,23,37,42–45</sup> In our IDH-mutated tumor cohort, however, the EOR was not associated with seizure outcome. We hypothesize that the targeted resection of the epileptogenic foci using ioECoG-tailoring determined the seizure outcome rather than the EOR in our cohort, while in surgery without ioECoG, expanding the EOR increases the likelihood of resecting the epileptogenic foci. ioECoG-tailoring helps to precisely target the epileptogenic foci for resection, limiting the benefits of GTR on seizure freedom. Among those patients without epileptogenic focus in ioECoG, GTR could retain its capacity to achieve seizure freedom.

In our glioblastoma, IDH-wildtype cohort, residual spikes, and EOR were not associated with seizure outcome. These results should be interpreted cautiously given the limited sample size of our cohort, but are relevant

when pondering the potential cost-effectiveness of ioECoG for patients with IDH-wildtype glioblastomas. Several factors may contribute to the different results between the IDH-wildtype tumor group and the IDH-mutated tumor group. Due to the aggressive nature of the disease, seizure outcomes in glioblastoma, IDH-wildtype patients may be clouded by tumor recurrence and radio-necrosis. The follow-up period is short, considering the short life expectancy.<sup>29</sup> Furthermore, the seizure pathophysiology behind glioblastoma, IDH-wildtype differs from tumors with IDH-mutation. Epileptogenesis in glioblastoma involves acute tissue damage, increased permeability of the blood-brain barrier, and strongly altered local electrolyte and neurotransmitter balance, while deafferent cortical networks are believed to play a more pivotal role in the seizure onset of IDH-mutant tumors.<sup>11,46</sup>

We found that ioECoG could assist in identifying glioma infiltration not only in regions concordant with MRI abnormalities but also in regions without evident MRI abnormalities. Interictal spikes appeared to be a distinct electrophysiological feature of glioma cells, and their presence signified tumor infiltration in 100% of our cases. Tissue samples showing sharp waves or electrographic seizures did not hold this value. Epileptogenesis and tumor growth have shared mechanisms, and their interaction is reciprocal. Gliomas induce neuronal hyperexcitability and promote epileptogenesis through increased glutamate release and reduced inhibitory interneurons in the surrounding microenvironment.<sup>47,48</sup> Neuronal hyperexcitability in gliomas can be recorded. Slices of glioma-infiltrated tissue could generate interictal-like discharges.<sup>49</sup> Tumor infiltrated brain areas have distinguishable electrophysiological characteristics in in-human electrocorticography, expressed by increased high-gamma power and higher power law component compared to healthy tissue.<sup>10,25</sup> Building upon these findings, we showed that interictal spikes could feature as markers for glioma-related neuronal hyperexcitability, enabling the identification of tumor infiltration even before distinct abnormalities are visible on MRI.

This study presents prospectively collected data on ioECoG-tailoring in oncological neurosurgery trajectory and is, to our knowledge, the first to correlate ioECoG discharges directly to pathology findings in glioma patients. This study has limitations. We recorded ioECoG prospectively but collected the postoperative seizure outcome retrospectively from the patient's health records, which could introduce some imprecision in the dates of recurrent seizures. Our cohort consisted of various underlying tumor pathologies, which allowed us to compare IDH-mutant tumor with IDH-wildtype tumor cases. The limited size of the IDH-wildtype cohort restricts the generalizability of our results. Whether ioECoG-assisted resection of IDH-wildtype should be applied in common practice should be investigated further. To resemble the clinical practice, we analyzed the presence of the epileptic activity instead of calculating the rate of the interictal discharges, and we did not analyze ioECoG biomarkers that were not (yet) incorporated into daily practice. The lack of standardized ioECoG recording and analysis techniques across centers is an inherent limitation of invasive EEG and especially ioECoG. The issue of objective and/or quantifiably analysis may be mitigated by technical innovations like intraoperative

MRI, neuronavigation MRI that can project the location of ioECoG and analyses aided by artificial intelligence to standardize ioECoG localization and signal interpretation. For research, we standardize the ways we report and structure our data.<sup>50</sup> Our study methods did not include control tissue samples of the nonepileptic peritumoral area. The nonresected, nonepileptic peritumoral area surrounding the visible edges of the tumor could be infiltrated by tumor cells. This is the basis of the concept of supramaximal resection of brain tumors. Supramaximal resections can result in removing functional brain tissue involved in cognitive functions that are not always testable preoperatively and may not always recover completely. In this context, defining areas where tumor infiltration is present, on the basis of ioECoG, may help with the preoperative decision of removing "supramarginal" brain tissue, especially in light of the fact that this tissue show signs of epileptogenicity. We did not clarify to what extent the removal of the spike-positive tumor cells contributed to the resected volume compared to nonepileptic peritumoral tissue in all patients. The effect of spikes predicting tumor infiltration may be overestimated, as the correlation could be partially "coincidental." We did compare it to peritumoral tissue showing sharp waves and we showed that spikes generating tissue were infiltrated by tumor while this was not the case for sharp waves.

ioECoG could be a beneficial and multifunctional tool in oncological neurosurgery, employed to assist in epileptogenic foci mapping and tumor tissue mapping. We showed that ioECoG-guided surgery may have a positive effect on reducing seizure recurrence. Seizures negatively impact the quality of life of brain tumor patients.<sup>3</sup> We believe that (short-term) improvement in seizure management can be clinically significant for these patients. Longer follow-up duration is desired to assess the long-term effects of ioECoG-tailoring on seizure outcome. In future studies, it would be valuable to explore whether the combination of spikes with other electrophysiological biomarkers, such as high-frequency oscillations, spectral power, and connectivity measures, further improves the delineation of epileptogenic foci and distinguish tumor infiltrated tissue from healthy tissue. We recommend considering integrating intraoperative electrophysiology guidance into neuro-oncological surgery for the value of epilepsy and tumor mapping. This could provide valuable, real-time information to optimize GTR and guide the pursuit of supramaximal tumor resection of adult diffuse gliomas.

## Keywords

brain neoplasm | invasive electroencephalogram | neuronal excitability | peritumoral tissue | tumor-associated seizures

## Funding

The European Research Council, ERC Starting Grant (883880) to D.S., E.S., M.v.t.K. and M.Z.; the public-private partnership

Allowance by Health Holland, Top Sector Life Sciences and Health Grant (LSHM19080) to M.v.t.K.; The unrestricted grant of the T & P Bohnenn Fund to P.A.R. EpilepsieNL to M.Z.

## Conflict of interest statement

The authors have no conflicts of interest to declare.

## Authorship statement

D.S., B.M.v.S., T.A.G., M.v.t.K., P.v.E., M.Z., and P.A.R. contributed to the conception and design of the study; D.S., E.V.S., B.M.v.S., T.A.G., J.W.D., M.Z., and P.A.R. contributed to the acquisition and analysis of data; D.S., E.V.S., B.M.v.S., T.A.G., M.v.t.K., P.v.E., S.M.A.v.d.S., J.W.D., M.Z., and P.A.R. contributed to drafting the text and preparing the tables and figures.

## Data availability

Data used for this manuscript are available upon reasonable request.

## Affiliations

Department of Neurology and Neurosurgery, UMC Utrecht Brain Center, University Medical Center Utrecht, Utrecht, The Netherlands (D.S., E.V.S., B.M.v.S., T.A.G., M.v.t.K., P.v.E., S.M.A.v.d.S., M.Z., P.A.R.); Department of Radiology and Nuclear Medicine, University Medical Center Utrecht, Utrecht, The Netherlands (J.W.D.); Stichting Epilepsie Instellingen Nederland, The Netherlands (M.Z.)

## References

- Duffau H, Taillandier L. New concepts in the management of diffuse low-grade glioma: proposal of a multistage and individualized therapeutic approach. *Neuro Oncol.* 2015;17(3):332–342.
- van Breemen MS, Wilms EB, Vecht CJ. Epilepsy in patients with brain tumours: epidemiology, mechanisms, and management. *Lancet Neurol.* 2007;6(5):421–430.
- Klein M, Engelberts NHJ, Van der Ploeg HM, et al. Epilepsy in low-grade gliomas: the impact on cognitive function and quality of life. *Ann Neurol.* 2003;54(4):514–520.
- Pallud J, Audureau E, Blonski M, et al. Epileptic seizures in diffuse low-grade gliomas in adults. *Brain.* 2014;137(Pt 2):449–462.
- Birbeck GL, Hays RD, Cui X, Vickrey BG. Seizure reduction and quality of life improvements in people with epilepsy. *Epilepsia.* 2002;43(5):535–538.
- Duffau H. Surgery of low-grade gliomas: towards a ‘functional neurooncology’. *Curr Opin Oncol.* 2009;21(6):543–549.
- Sun D, van Klink NEC, Bongaarts A, et al. High frequency oscillations associate with neuroinflammation in low-grade epilepsy associated tumors. *Clin Neurophysiol.* 2022;133(Jan):165–174.
- Slegers RJ, Blumcke I. Low-grade developmental and epilepsy associated brain tumors: a critical update 2020. *Acta Neuropathol Commun.* 2020;8(1):1–11.
- Armstrong TS, Grant R, Gilbert MR, Lee JW, Norden AD. Epilepsy in glioma patients: mechanisms, management, and impact of anticonvulsant therapy. *Neuro Oncol.* 2016;18(6):779–789.
- Ghinda DC, Lambert B, Lu J, et al. Scale-free analysis of intraoperative ECoG during awake craniotomy for glioma. *Front Oncol.* 2021;10(Feb):3497.
- Pallud J, Capelle L, Huberfeld G. Tumoral epileptogenicity: how does it happen?. *Epilepsia.* 2013;54(Suppl. 9):30–34.
- Zweiphenning W, Klooster MA van t, van Klink NEC, et al. Intraoperative electrocorticography using high-frequency oscillations or spikes to tailor epilepsy surgery in the Netherlands (the HFO trial): a randomised, single-blind, adaptive non-inferiority trial. *Lancet Neurol.* 2022;21(11):982–993.
- Sun D, van ’t Klooster MA, van Schooneveld MMJ, et al. High frequency oscillations relate to cognitive improvement after epilepsy surgery in children. *Clin Neurophysiol.* 2020;131(5):1134–1141.
- Greiner HM, Horn PS, Tenney JR, et al. Preresection intraoperative electrocorticography (ECoG) abnormalities predict seizure-onset zone and outcome in pediatric epilepsy surgery. *Epilepsia.* 2016;57(4):582–589.
- Wu JY, Sankar R, Lerner JT, et al. Removing interictal fast ripples on electrocorticography linked with seizure freedom in children. *Neurology.* 2010;75(19):1686–1694.
- Yao PS, Zheng SF, Wang F, Kang DZ, Lin YX. Surgery guided with intraoperative electrocorticography in patients with low-grade glioma and refractory seizures. *J Neurosurg.* 2018;128(3):840–845.
- van’t Klooster MA, Van Klink NEC, Leijten FSS, et al. Residual fast ripples in the intraoperative corticogram predict epilepsy surgery outcome. *Neurology.* 2015;85(2):120–128.
- Berger MS, Ghatan S, Haglund MM, Dobbins J, Ojemann GA. Low-grade gliomas associated with intractable epilepsy: seizure outcome utilizing electrocorticography during tumor resection. *J Neurosurg.* 1993;79(1):62–69.
- Chen X, Wang Y, Kopetzky SJ, Butz-Ostendorf M, Kaiser M. Connectivity within regions characterizes epilepsy duration and treatment outcome. *Hum Brain Mapp.* 2021;42(12):3777–3791.
- Scharfman HE. Epilepsy as an example of neural plasticity. *Neuroscientist.* 2002;8(2):154–173.
- Jarero-Basulto J, Gasca-Martínez Y, Rivera-Cervantes M, et al. Interactions between epilepsy and plasticity. *Pharmaceuticals.* 2018;11(1):17.
- Molinari AM, Hervey-Jumper S, Morshed RA, et al. Association of maximal extent of resection of contrast-enhanced and non-contrast-enhanced tumor with survival within molecular subgroups of patients with newly diagnosed glioblastoma. *JAMA Oncol.* 2020;6(4):495–503.
- Still MEH, Roux A, Huberfeld G, et al. Extent of resection and residual tumor thresholds for postoperative total seizure freedom in epileptic adult patients harboring a supratentorial diffuse low-grade glioma. *Neurosurgery.* 2019;85(2):E332–E340.
- Avila EK, Tobochnik S, Inati SK, et al. Brain tumor-related epilepsy management: a Society for Neuro-oncology (SNO) consensus review on current management. *Neuro Oncol.* 2024;26(1):7–24.
- Venkatesh HS, Morishita W, Geraghty AC, et al. Electrical and synaptic integration of glioma into neural circuits. *Nature.* 2019;573(7775):539–545.
- Delgado-López PD, Corrales-García EM, Martino J, Lastra-Aras E, Dueñas-Polo MT. Diffuse low-grade glioma: a review on the new

- molecular classification, natural history and current management strategies. *Clin Transl Oncol*. 2017;19(8):931–944.
27. Yordanova YN, Moritz-Gasser S, Duffau H. Awake surgery for WHO Grade II gliomas within “noneloquent” areas in the left dominant hemisphere: toward a “supratotal” resection. Clinical article. *J Neurosurg*. 2011;115(2):232–239.
  28. Pallud J, Varlet P, Devaux B, et al. Diffuse low-grade oligodendrogliomas extend beyond MRI-defined abnormalities. *Neurology*. 2010;74(21):1724–1731.
  29. Li YM, Suki D, Hess K, Sawaya R. The influence of maximum safe resection of glioblastoma on survival in 1229 patients: can we do better than gross-total resection? *J Neurosurg*. 2016;124(4):977–988.
  30. Orringer DA, Pandian B, Niknafs YS, et al. Rapid intraoperative histology of unprocessed surgical specimens via fibre-laser-based stimulated Raman scattering microscopy. *Nat Biomed Eng*. 2017;1(2):0027.
  31. Dimou J, Beland B, Kelly J. Supramaximal resection: a systematic review of its safety, efficacy and feasibility in glioblastoma. *J Clin Neurosci*. 2020;72(Feb):328–334.
  32. Zuberi SM, Wirrell E, Yozawitz E, et al. ILAE classification and definition of epilepsy syndromes with onset in neonates and infants: position statement by the ILAE Task Force on Nosology and Definitions. *Epilepsia*. 2022;63(6):1349–1397.
  33. Louis DN, Perry A, Wesseling P, et al. The 2021 WHO classification of tumors of the central nervous system: a summary. *Neuro Oncol*. 2021;23(8):1231–1251.
  34. Qiu B, Ou S, Song T, et al. Intraoperative electrocorticography-guided microsurgical management for patients with onset of supratentorial neoplasms manifesting as epilepsy: a review of 65 cases. *Epileptic Disord*. 2014;16(2):175–184.
  35. Warsi NM, Mohammad AH, Zhang F, et al. Electrocorticography-guided resection enhances postoperative seizure freedom in low-grade tumor-associated epilepsy: a systematic review and meta-analysis. *Neurosurgery*. 2023;92(1):18–26.
  36. Fallah A, Weil AG, Sur S, et al. Epilepsy surgery related to pediatric brain tumors: Miami Children’s hospital experience. *J Neurosurg Pediatr*. 2015;16(6):675–680.
  37. Englot DJ, Berger MS, Barbaro NM, Chang EF. Predictors of seizure freedom after resection of supratentorial low-grade gliomas: a review. *J Neurosurg*. 2011;115(2):240–244.
  38. Robertson FC, Ullrich NJ, Manley PE, et al. The impact of intraoperative electrocorticography on seizure outcome after resection of pediatric brain tumors: A cohort study. *Neurosurgery*. 2019;85(3):375–383.
  39. Wray CD, McDaniel SS, Saneto RP, Novotny EJ, Ojemann JG. Is postresective intraoperative electrocorticography predictive of seizure outcomes in children? Clinical article. *J Neurosurg Pediatr*. 2012;9(5):546–551.
  40. Widjaja E, Jain P, Demoe L, et al. Seizure outcome of pediatric epilepsy surgery: systematic review and meta-analyses. *Neurology*. 2020;94(7):311–321.
  41. van Klink NEC, Zweiphenning WJEM, Ferrier CH, et al. Can we use intraoperative high-frequency oscillations to guide tumor-related epilepsy surgery? *Epilepsia*. 2021;62(4):997–1004.
  42. Chang EF, Potts MB, Keles GE, et al. Seizure characteristics and control following resection in 332 patients with low-grade gliomas. *J Neurosurg*. 2008;108(2):227–235.
  43. Kerkhof M, Vecht CJ. Seizure characteristics and prognostic factors of gliomas. *Epilepsia*. 2013;54 Suppl 9(Dec):12–17.
  44. Li L, Fang S, Li G, et al. Glioma-related epilepsy in patients with diffuse high-grade glioma after the 2016 WHO update: seizure characteristics, risk factors, and clinical outcomes. *J Neurosurg*. 2022;136(1):67–75.
  45. Xu DS, Awad AW, Mehalechko C, et al. An extent of resection threshold for seizure freedom in patients with low-grade gliomas. *J Neurosurg*. 2018;128(4):1084–1090.
  46. Rudà R, Bello L, Duffau H, Soffietti R. Seizures in low-grade gliomas: natural history, pathogenesis, and outcome after treatments. *Neuro Oncol*. 2012;14(Suppl 4):iv55–iv64.
  47. Venkatesh HS, Johung TB, Caretti V, et al. Neuronal activity promotes glioma growth through neuroligin-3 secretion. *Cell*. 2015;161(4):803–816.
  48. Taylor KR, Barron T, Hui A, et al. Glioma synapses recruit mechanisms of adaptive plasticity. *Nature*. 2023;623(7986):366–374.
  49. Pallud J, Le Van Quyen M, Bielle F, et al. Cortical GABAergic excitation contributes to epileptic activities around human glioma. *Sci Transl Med*. 2014;6(244):244ra89.
  50. Demuru M, van Blooijis D, Zweiphenning W, et al; RESPECT group. A practical workflow for organizing clinical intraoperative and long-term iEEG Data in BIDS. *Neuroinformatics*. 2022;20(3):727–736.