


**ORIGINAL RESEARCH**

# Anatomical Markers Associated With the Presence of Intracranial Aneurysms in Individuals Screened for Aneurysms

Iris N. Vos, MSc<sup>†</sup>; Rick J. van Tuijl, PhD<sup>†</sup>; Liselore A. Mensing, PhD; Maud E. H. Ophelders, BSc; Mireille R. E. Velthuis, BSc; Nicolaas P. A. Zuithoff, PhD; Gabriel J. E. Rinkel, PhD; Hugo J. Kuijff, PhD; Jaco J. M. Zwanenburg, PhD; Irene C. van der Schaaf, PhD; Birgitta K. Velthuis, PhD<sup>††</sup>; Ynte M. Ruigrok, PhD<sup>††</sup> 

**BACKGROUND:** Hemodynamic stress is linked to the development of intracranial aneurysms (IAs) and may be influenced by anatomic variation of intracranial arteries. We assessed diameters and bifurcation angles of intracranial arteries forming the circle of Willis in a cohort of individuals screened for the presence of IAs.

**METHODS:** Individuals with and without IAs identified at screening with magnetic resonance angiography were compared. Diameters and bifurcation angles of the following arteries were measured using semiautomatic methods: A1 and A2 segments of the anterior cerebral artery, M1 and M2 segments of the middle cerebral artery, P1 segments of the posterior cerebral artery, posterior communicating artery (Pcom), internal carotid artery, vertebral artery, and basilar artery. We employed univariate general linear models to assess group differences. This included subgroup comparisons between individuals with IAs at specific locations and matched controls, and comparisons on group level between individuals with and without IAs, corrected for age and sex.

**RESULTS:** In 94 of the 1049 individuals (9.0%) included, IAs were detected. Individuals with middle cerebral artery IAs had wider ipsilateral M2–M2 bifurcation angles compared with controls ( $121 \pm 25^\circ$  versus  $97 \pm 19^\circ$ ;  $P < 0.01$ ). Individuals with anterior communicating artery IAs showed smaller angles for the A1–A2 bifurcation ( $106 \pm 16^\circ$  versus  $120 \pm 17^\circ$ ;  $P = 0.02$ ), while those with Pcom IAs had wider Pcom–C7 bifurcation angles ( $147 \pm 14^\circ$  versus  $127 \pm 17^\circ$ ;  $P = 0.02$ ) and smaller diameters below the ipsilateral internal carotid artery top ( $2.86 \pm 0.36$  mm versus  $3.10 \pm 0.33$  mm;  $P = 0.03$ ) compared with controls.

**CONCLUSION:** We found associations between wider M2–M2 bifurcation angles or narrower A1–A2 bifurcation angles and IA presence, consistent with prior literature. Moreover, we uncovered previously unexplored associations, including wider Pcom–C7 bifurcation angles and smaller internal carotid artery diameters in individuals with Pcom IAs. Future research should explore the potential of these markers in predicting IAs in at-risk populations during follow-up screenings.

**Key Words:** arterial diameters ■ bifurcation angles ■ circle of Willis ■ imaging markers ■ intracranial aneurysms ■ magnetic resonance angiography

Correspondence to: Ynte M. Ruigrok, Department of Neurology and Neurosurgery, UMC Utrecht Brain Center, room G03.228, University Medical Center Utrecht, Heidelberglaan 100, 3584 CX Utrecht, The Netherlands. E-mail: I.J.M.Ruigrok@umcutrecht.nl

Supplementary Material for this article is available at <https://www.ahajournals.org/doi/suppl/10.1161/SVIN.124.001299>

<sup>†</sup>I. N. Vos and R. J. van Tuijl shared first authorship.

<sup>††</sup>B. K. Velthuis and Y. M. Ruigrok shared last authorship.

© 2024 The Authors. *Stroke: Vascular and Interventional Neurology* published by Wiley Periodicals LLC on behalf of American Heart Association; The Society for Vascular and Interventional Neurology. This is an open access article under the terms of the Creative Commons Attribution-NonCommercial-NoDerivs License, which permits use and distribution in any medium, provided the original work is properly cited, the use is non-commercial and no modifications or adaptations are made.

*Stroke: Vascular and Interventional Neurology* is available at: [www.ahajournals.org/journal/svin](http://www.ahajournals.org/journal/svin)

**R**upture of an intracranial aneurysm (IA) causes aneurysmal subarachnoid hemorrhage (aSAH), a severe subtype of stroke with high death and morbidity in survivors.<sup>1</sup> The development of an IA and the subsequent risk of aSAH have been associated with multiple factors, including hypertension, smoking, and a positive family history of aSAH.<sup>2</sup> Repeated screening for IAs to prevent aSAH has been proven cost effective in first-degree family members of patients with aSAH.<sup>3,4</sup>

Although the pathogenesis of the disease remains largely unknown, hemodynamic stress in intracranial arteries forming the circle of Willis (CoW) is considered to play an important role.<sup>5–7</sup> Variation in artery diameters or bifurcation angles may affect hemodynamic stress,<sup>8</sup> thereby contributing to the development of IAs. Prior research exploring this anatomic variation has led to the identification of several potential imaging markers.<sup>9–14</sup> However, the level of supporting evidence remains limited. This was further demonstrated by a recent systematic review<sup>15</sup> on imaging markers for IAs, which revealed large heterogeneity of marker definitions and study outcomes as well as poor methodological quality of many included studies. Only asymmetry of the A1 segments of anterior cerebral arteries (ACAs) could be identified as an anatomic imaging marker for anterior communicating artery (Acom) IAs with certainty. Possible evidence was found for other markers such as increased artery diameter ratios of the A1–A2 segments or wider M2–M2 segment bifurcation angles of the middle cerebral artery (MCA). The study concluded that more long-term prospective investigations in larger populations were needed to identify additional anatomic imaging markers for IAs. Knowledge on these imaging markers will lead to more insight in the pathogenesis of IA formation. Moreover, in first-degree relatives of patients with aSAH, these imaging markers may help to improve the risk prediction of relatives at high risk of IAs at follow-up screening using imaging data derived at the first screening.<sup>16,17</sup>

Our study aims to provide additional evidence for anatomic markers of IA and identify new potential markers using a standardized approach. We test 2 hypotheses in 2 cohorts with individuals screened for IAs: artery diameters or bifurcation angles associated with (1) IA presence at specific locations, and (2) IA presence in general.

## METHODS

### Study Participants

The data that support the findings of this study are available from the corresponding author upon reasonable request. Two cohorts of individuals screened for the presence of IAs with magnetic resonance angiography

## Nonstandard Abbreviations and Acronyms

<b>ACA</b>	anterior cerebral artery
<b>Acom</b>	anterior communicating artery
<b>aSAH</b>	aneurysmal subarachnoid hemorrhage
<b>CoW</b>	circle of Willis
<b>ERASE</b>	Early Recognition of Persons at High Risk of Aneurysmal Subarachnoid Hemorrhage
<b>FDR</b>	false discovery rate
<b>F-PCA</b>	fetal-type posterior cerebral artery
<b>IA</b>	intracranial aneurysm
<b>ICA</b>	internal carotid artery
<b>MCA</b>	middle cerebral artery
<b>PCA</b>	posterior cerebral artery
<b>Pcom</b>	posterior communicating artery
<b>UIA</b>	unruptured intracranial aneurysm
<b>UMCU</b>	University Medical Center Utrecht
<b>VAC</b>	vascular asymmetry coefficient

## CLINICAL PERSPECTIVE

### What Is New?

- There is limited evidence for imaging markers associated with intracranial aneurysm presence.
- We observed several associations between artery diameters or bifurcation angles and intracranial aneurysm presence, some aligning with prior literature and others revealing previously unexplored associations.

### What Are the Clinical Implications?

- Long-term serial screening for intracranial aneurysms is currently recommended for first-degree family members of patients with aneurysmal subarachnoid hemorrhage. However, the screening process is suboptimal due to insufficient understanding of who is at risk. Imaging markers can improve this process by identifying individuals at higher risk of developing intracranial aneurysms during initial screening. As a result, high-risk individuals may undergo more frequent follow-up screenings, while those at lower risk may have their screening frequency reduced.

(MRA) at the University Medical Center Utrecht (UMCU) were included. Cohort A, collected as part of clinical practice, included individuals with a positive family history for aSAH in first-degree relatives. Cohort B was collected as part of research and included participants of the ERASE (Early Recognition of Persons at High Risk of Aneurysmal Subarachnoid Hemorrhage) study<sup>18</sup> for IAs in first-degree relatives of patients with an unruptured IA (UIA). Details of both cohorts are explained further below. This study followed the Strengthening the Reporting of Observational studies in Epidemiology guidelines<sup>19</sup> for cohort studies.

### Cohort A

Individuals screened for IAs because of familial aSAH at the UMCU were recorded in a prospectively collected database. Information from August 1996 to February 2020 for individuals aged >18 years was retrieved. Those admitted to the UMCU with aSAH or with UIA visiting the neurology outpatient clinic were routinely asked about family history. If aSAH occurred in their first-degree relatives, the patients were informed that their relatives are welcome to visit the outpatient clinic to be informed about screening for IAs. Second, individuals were also referred for screening by general practitioners or by neurologists and neurosurgeons from other hospitals. For the current study, we included individuals in whom a 3-dimensional T1-weighted gradient echo time-of-flight MRA acquisition on a 1.5 or 3.0 Tesla magnetic resonance imaging (Philips Healthcare, Best, The Netherlands) was performed (Table S1). Individuals with endovascular or surgical treatment of IAs in their past medical history were excluded, as treatment may lead to artefacts on the MRA. Individuals with polycystic kidney disease or other disease known to predispose for aneurysm development were also excluded. As it is advised to repeat screening as IAs develop during life,<sup>20</sup> multiple MRA scans may be available per individual, in which case we used the data of the most recent MRA. In individuals who underwent endovascular or surgical treatment of UIAs found at screening, we used the latest MRA performed before the treatment.

### Cohort B

This cohort includes 461 first-degree relatives of index patients with UIAs who visited the neurology outpatient clinic of the UMCU, Leiden University Medical Center, or Amsterdam University Medical Center in the Netherlands between April 2017 and October 2021.<sup>18</sup> Index patients were defined as adults with an incidental finding of saccular UIA(s) on MRA, computed tomography angiography, or conventional angiography and no family history of aSAH (defined as no first-degree relative [parent, sibling, or child] with aSAH), nor a medical his-

tory of aSAH, polycystic kidney disease, or other disease known to predispose for aneurysm development. Eligible index patients were informed about the study and written informed consent to contact their false discovery rates (FDRs) was obtained. Exclusion criteria for relatives were (1) age <18 years or >70 years at time of screening; (2) a medical history of UIAs, polycystic kidney disease, Ehlers–Danlos syndrome, or fibromuscular dysplasia; (3) previous screening for IAs; (4) severe comorbidity resulting in a reduced life expectancy that would potentially interfere with decision making about UIA treatment; (5) relative contraindications for MRA such as pregnancy, a pacemaker, or claustrophobia; and (6) cognitive deficits or language barrier. All participants underwent a 3-dimensional T1-weighted gradient echo time-of-flight MRA acquisition on a 3.0 Tesla magnetic resonance imaging using a 32-channel head coil (Philips Healthcare, Best, The Netherlands). Three individuals had to be excluded as no MRI could be performed due to claustrophobia. Another 15 individuals were excluded due to poor image quality.

### Standard Protocol Approvals, Registrations, and Patient Consents

For cohort A, we received a “non–World Meteorological Organization declaration” from the local ethics review committee. The Medical Ethical Review Committee of the UMCU approved the study protocol (approval number 16–777) of cohort B.

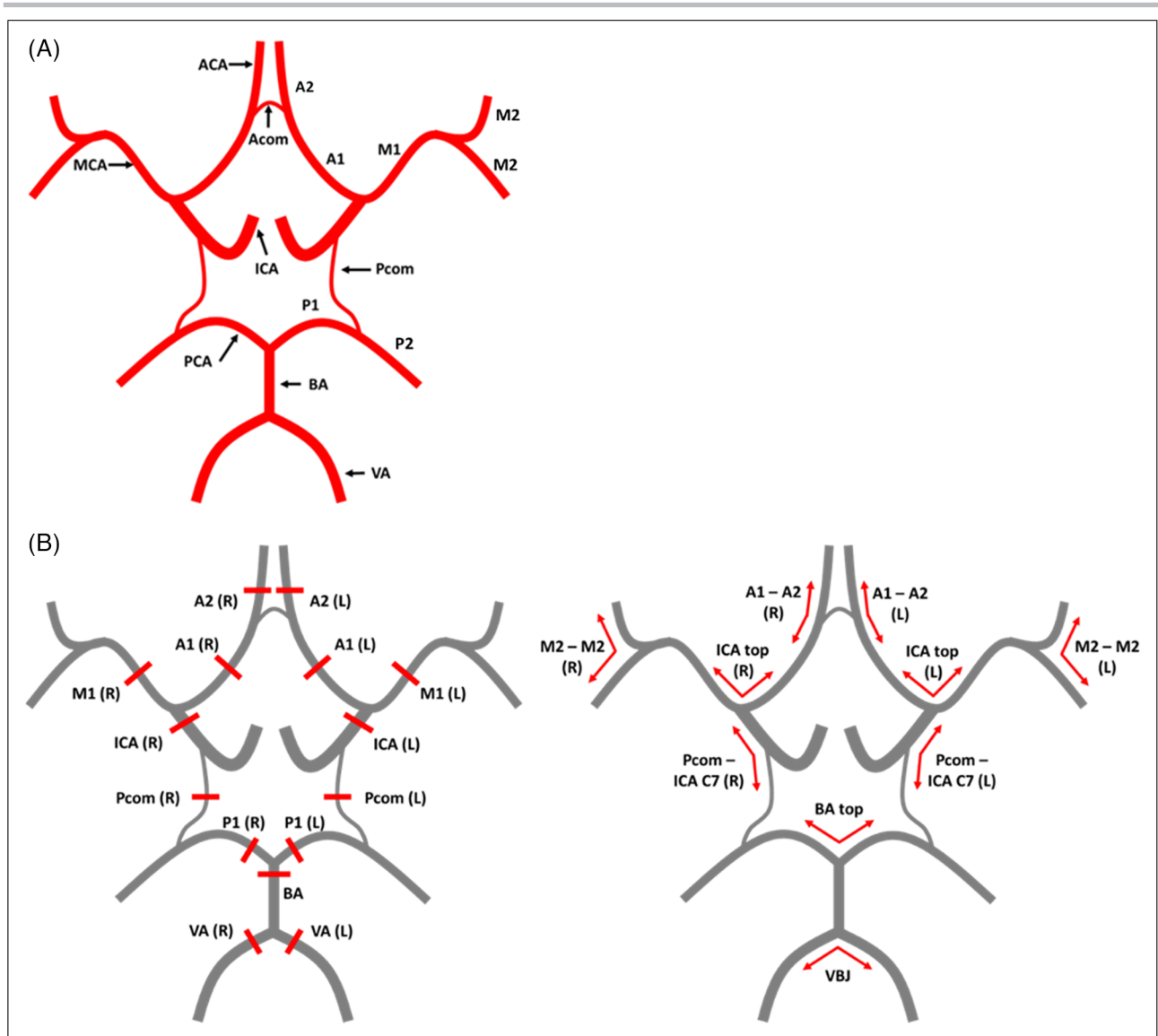
### Imaging Markers

We included artery diameters of, and bifurcation angles between, the main intracranial arteries of the CoW (Figure). Additionally, we addressed A1 asymmetry of the ACA and the proportion of fetal-type posterior cerebral arteries (F-PCAs) due to their previous identification as (potential) imaging markers.<sup>15,21</sup>

### Assessment of Artery Diameters

Artery diameters were measured using a validated semiautomatic approach<sup>22</sup> applying a full-width-at-half-maximum analysis. Annotations were performed by 2 observers (I.V. and M.O.) on the following arteries (both left and right): A1 segments of ACAs, M1 segments of MCAs, P1 segments of posterior cerebral arteries (PCAs) and posterior communicating arteries (Pcoms) at 50% of total segment length; internal carotid arteries (ICAs) at 5 mm below the top; vertebral arteries at 5 mm below the vertebrobasilar junction; and A2 segments of ACA at 5 mm after the Acom. In addition, we annotated the basilar artery at 5 mm below the basilar top.

The full-width-at-half-maximum method is known to produce biased estimates for smaller arteries. Based on our findings in earlier work,<sup>22</sup> we kept a detection limit



**Figure 1. Overview of annotations.** **A**, Schematic representation of the CoW arteries. **B**, L: Diameter annotations of the CoW arteries included in this study. R: Angle annotations of the CoW bifurcations included in this study. A1, A1-segment of the anterior cerebral artery (ACA); A1–A2, angle between A1 and A2 segments of the ACA; A2, A2-segment of the ACA; BA top, BA top bifurcation angle; BA, basilar artery; CoW, circle of Willis; ICA top, ICA top bifurcation angle; ICA, internal carotid artery; L, left; M1, M1-segment of the middle cerebral artery; M2–M2, bifurcation angle between 2 M2-segments; P1, P1-segment of the posterior cerebral artery; Pcom/C7, angle between Pcom and distal ICA (C7 segment); Pcom, posterior communicating artery; R, right; VA, vertebral artery; VBJ, vertebrobasilar junction angle.

of 1.2 mm. Arteries with a diameter below the detection limit are automatically assigned a constant value of 0.6.

### Assessment of Bifurcation Angles

To measure artery bifurcation angles, segmentation of the intracranial arteries was performed using a validated 3-dimensional U-Net.<sup>23</sup> Artery centerlines were obtained by performing skeletonization through successive erosion of border voxels.<sup>24</sup> Bifurcation angles were computed on the basis of these centerlines using the direction of vectors originating from a bifurcation

within distances of 5 mm. The following bifurcations were annotated (both left and right; see the Figure) by 2 observers (l.v. and R.v.T.): bifurcation between A1 and A2 segments of the ACA, bifurcation at the ICA top, bifurcation between Pcom and distal ICA (C7 segment), and the bifurcation between both M2 segments of the MCA. If the Acom was not visible, the angle between the A1 and A2 segments of the ACA at the point of highest curvature was assessed. If other arteries were not visible, such as an A1 or Pcom, that angle was not annotated. Finally, we annotated angle bifurcations at the basilar artery top and vertebrobasilar junction.

## Asymmetry

Asymmetry of the A1 segments was assessed using the vascular asymmetry coefficient (VAC), based on 2 studies<sup>25,26</sup> included in the systematic review by Kancheva et al.<sup>15</sup> The asymmetry was classified as follows on the basis of VAC values: <10%, symmetrical; 10%– to 40%, asymmetrical; and >40%, hypoplastic. Undetectable A1 segments were labeled aplastic.

## Fetal-Type PCAs

F-PCAs, a CoW anatomic variant where the PCA originates predominantly from the ICA, (ie, the Pcom is larger in diameter than the P1 segment of the PCA) has been associated with the presence of Pcom IAs in a recent study.<sup>21</sup> We assessed the proportion of ipsilateral F-PCA in individuals with Pcom IAs, as well as the proportion of unilateral and bilateral F-PCA in the entire IA group.

## Statistical Analysis

Baseline demographic and clinical characteristics were reported using mean values and SDs for continuous variables. Counts and percentages were used for categorical variables. Matching and data analyses were performed using IBM Statistics SPSS version 27 (IBM, Armonk, NY).

First, we categorized individuals within the IA group on the basis of the specific location of their IAs. Next, we examined how the arterial diameter and bifurcation angle of the artery near the IA location varied between each subgroup and a control group matched specifically for that group. We included only subgroups with a minimum sample size of 15 for this analysis to maintain adequate statistical power. To establish comparable control groups, we implemented a 1:2 matching procedure using case–control matching in SPSS.<sup>27</sup> Individuals from the IA group were paired with those from the group without IA on the basis of sex and age ( $\pm 2$  years). For each subgroup resulting from the matching process, we applied univariate general linear model analyses with artery diameters and bifurcation angles on the ipsilateral side as the dependent variables. For patients with an Acom IAs, we used the dominant versus nondominant side for artery diameter comparisons and the wider versus narrower side for bifurcation angle comparisons. Artery diameters falling below the detection limit were reevaluated by an experienced radiologist (B.V.) in cohort A and under the supervision of an experienced radiologist (M.V.) in cohort A, and manually adjusted if needed. We examined the VAC scores for A1 asymmetry and the occurrence of F-PCAs using odds ratios (ORs) with their corresponding 95% CIs. Analyses were corrected for age and sex to avoid any bias due to residual confounding.<sup>28</sup> Benjamini–Hochberg FDR<sup>29</sup>

was used to report *P* values corrected for multiple comparisons.

Second, we tested for differences in artery diameters and bifurcation angles between the entire group with IA and without IA, using univariate general linear models. Sex and age were added as covariates, and the FDR method was used to correct for multiple testing.

Validity of model assumptions of a general linear model (ie, homogeneity of variance and normality) was assessed with inspection of residual plots. Intra- and interobserver variability was investigated using Bland–Altman plots and the intraclass correlation coefficient. The statistical significance threshold was set at  $P < 0.05$ . Any missing data were handled using listwise deletion in models.

## RESULTS

A total of 605 individuals fulfilled the inclusion criteria in cohort A and 443 individuals in cohort B. Demographic and clinical characteristics are shown in Table 1. From the 1049 individuals who were included in this study, 125 IAs were detected in 94 individuals (9.0%; 69 in cohort A and 25 in cohort B).

Mean values of the artery diameters and bifurcation angles are reported in Table S2. Results of the analyses focusing on specific IA locations are presented in Table 2. Differences between the MCA IA subgroup and control group were observed for the M2–M2 bifurcation angle ( $121 \pm 25^\circ$  versus  $97 \pm 19^\circ$ ;  $P < 0.01$ ; FDR corrected) on the ipsilateral side. Individuals with Acom IAs showed smaller A1–A2 angles on the narrower side when compared with their matched controls ( $106 \pm 16^\circ$  versus  $120 \pm 17^\circ$ ;  $P = 0.02$ ). In the Pcom IA subgroup, we observed a larger ipsilateral Pcom–C7 bifurcation angle in individuals with IA ( $147 \pm 14^\circ$  versus without ( $127 \pm 17^\circ$ ;  $P = 0.02$ ). In addition, the ICA diameters 5 mm below the ICA top were smaller in individuals with Pcom IAs than their controls ( $2.86 \pm 0.36$  mm versus  $3.10 \pm 0.33$  mm;  $P = 0.03$ ). After FDR correction, the adjusted *P* values for the A1–A2 angle, Pcom–C7 angle and ICA diameters no longer indicated statistical significance ( $P > 0.05$ ).

Both aplasia and pronounced hypoplasia (VAC > 40%) of 1 of the A1 arteries were observed in 2 of 17 individuals with Acom IAs (see Table S3). In the group of 34 matched controls, only 1 case of aplasia (OR, 5.4 [95% CI, 0.4–75.0]) and 1 case of pronounced hypoplasia was found (OR, 5.1 [95% CI, 0.4–61.6]). Asymmetry of the A1 arteries (VAC > 10% and  $\leq 40\%$ ) was found in 5 individuals with Acom IAs and 13 individuals without IAs (OR, 0.7 [95% CI, 0.2–2.7]). Finally, symmetry of the A1 arteries (VAC  $\leq 10$ ) was observed in 8 individuals with Acom IAs versus 19

**Table 1. Demographic and Clinical Characteristics of the Study Cohort**

Characteristic	Cohort A+B	Cohort A	Cohort B
No. of individuals	1049	606	443
Women, n (%)	597 (57)	351 (58)	246 (56)
Age, y, $\pm$ SD	46 $\pm$ 14	46 $\pm$ 14	47 $\pm$ 13
Smoking*			
Current, n (%)	207 (20)	107 (18)	100 (23)
Ever, n (%)	236 (22)	86 (14)	150 (34)
Never, n (%)	422 (40)	229 (38)	193 (44)
Hypertension†			
Yes, n (%)	189 (18)	100 (17)	89 (20)
No, n (%)	650 (62)	296 (49)	354 (80)
IAs			
Individuals with IAs, n (%)	94 (9)	69 (11)	25 (6)
Women, n (%)	67 (72)	51 (74)	16 (64)
Individuals with multiple IAs, n (%)	19 (2)	17 (3)	2 (0)
Identified IAs, n	125	98	27
Location			
Middle cerebral artery, n (%)	43 (34)	33 (34)	10 (37)
Internal carotid artery, n (%)‡	35 (28)	28 (29)	7 (26)
Anterior communicating artery, n (%)	17 (14)	12 (12)	5 (19)
Posterior communicating artery, n (%)	17 (14)	13 (13)	4 (15)
Pericallosal artery, n (%)	5 (4)	5 (5)	0 (0)
Anterior cerebral artery, n (%)§	2 (2)	2 (2)	0 (0)
Basilar artery, n (%)	2 (2)	2 (2)	0 (0)
Superior cerebellar artery, n (%)	2 (2)	1 (1)	1 (4)
Posterior inferior cerebellar artery, n (%)	1 (1)	1 (1)	0 (0)
Temporalis anterior artery, n (%)	1 (1)	1 (1)	0 (0)
Mean IA size, mm, $\pm$ SD	2.74 $\pm$ 1.26	2.66 $\pm$ 1.21	2.98 $\pm$ 1.37

IA indicates intracranial aneurysm.

\*Characteristics unknown for 183 individuals from cohort A.

†Characteristics unknown for 209 individuals from cohort A.

‡include both proximal (vicinity ophthalmic artery) and distal (vicinity ICA top) UIAs.

§include 2 proximal A1 segment UIAs and 1 UIA at the A1–A2 junction.

individuals without (OR, 0.9 [95% CI, 0.3–3.0]). Overall VAC scores individuals with Acom IAs (19.3 $\pm$ 22.9) did not differ from their matched controls (11.7 $\pm$ 15.2;  $P = 0.19$ ; Table 2).

The observed proportion of bilateral F-PCAs in the entire group with IAs was 11%, but this was not different from the entire group without IAs (6%; OR, 1.9 [95% CI, 0.9–3.9];  $P = 0.12$ ; Table S4).

No statistically significant differences were observed in artery diameters when comparing the group with IAs with the whole group without IAs (results shown in Table S5). We found wider M2–M2 bifurcation angles in the group with IAs compared with the group without IAs (left M2–M2: 102 $\pm$ 22° versus 94 $\pm$ 19°;  $P = 0.04$ ; right M2–M2: 103 $\pm$ 23° versus 94 $\pm$ 18°;  $P = 0.01$ ; FDR corrected; Table S6).

Assessment of the intra- and interrater variability yielded excellent agreement for both the artery diameters and bifurcation angles, with intraclass correla-

tion coefficient values ranging between 0.97 and 0.98 (Figure S1).

## DISCUSSION

For the subgroup analysis based on IA locations, we found wider ipsilateral M2–M2 bifurcation angles in individuals with MCA IAs compared with their matched controls. Individuals with Acom IAs showed smaller angles at the A1–A2 bifurcation on the narrower side than the control group. Individuals with Pcom IAs exhibited wider Pcom–C7 bifurcation angles and smaller diameters below the ICA top in comparison with the matched controls. Finally, comparing the IA group with the entire group without IAs showed wider left and right M2–M2 bifurcation angles in individuals with IAs.

We observed a larger M2–M2 angle in individuals with MCA IAs, which is in line with previous

**Table 2. Analysis of Artery Diameters and Bifurcation Angles Associated With the Presence of Intracranial Aneurysms Categorized by Aneurysm Location and Compared With Matched Control Groups**

Location of aneurysm	Measurement on ipsilateral side	N (with IA versus without IA)	Mean±SD (with IA versus without IA)	*P value	P value corrected with FDR
MCA	M1 artery diameter	41 vs 82	2.51±0.24 vs 2.53±0.26	0.57	0.74
	M2–M2 bifurcation angle	37 vs 72	121±25 vs 97±19	<0.01‡	<0.01‡
ICA	ICA artery diameter	30 vs 68	3.14±0.37 vs 3.13±0.43	0.84	0.84
	ICA top bifurcation angle	34 vs 66	111±15 vs 113±15	0.40	0.65
Acom	A1 (DS) artery diameter	17 vs 34	2.15±0.23 vs 2.09±0.18	0.29	0.63
	A1 (NDS) artery diameter	15 vs 33	1.76±0.47 vs 1.83±0.30	0.55	0.74
	A1 asymmetry†	15 vs 33	19.3±22.9 vs 11.7±15.2	0.19	0.49
	A1–A2 (WS) bifurcation angle	11 vs 31	130±22 vs 136±17	0.38	0.65
	A1–A2 (NS) bifurcation angle	11 vs 31	106±16 vs 120±17	0.02‡	0.09
Pcom	Pcom artery diameter	16 vs 34	1.77±0.28 vs 1.81±0.33	0.69	0.75
	Pcom–C7 bifurcation angle	6 vs 9	147±14 vs 127±17	0.02‡	0.09
	P1 artery diameter	14 vs 32	1.86±0.23 vs 1.89±0.33	0.69	0.75
	ICA artery diameter	15 vs 33	2.86±0.36 vs 3.10±0.33	0.03‡	0.10

A1 indicates A1-segment of the anterior cerebral artery; A2, A2-segment of the anterior cerebral artery; Acom, anterior communicating artery; C7, C7 segment of the internal carotid artery; DS, dominant side; IA, intracranial aneurysm; ICA, internal carotid artery; M1, M1-segment of the middle cerebral artery; M2, M2-segment of the middle cerebral artery; MCA, middle cerebral artery; NDS, nondominant side; NS, narrower side;

P1, P1-segment of the posterior cerebral artery; Pcom, posterior communicating artery; and WS, wider side.

\*With adjustments for age and sex.

†Mean and SD of the vascular asymmetry coefficient are reported.

‡indicates statistical significance ( $P < 0.05$ ).

literature<sup>13,30,31</sup> and supports the defined moderate evidence (at least 2 high-quality studies with a relevant OR) for wider MCA M2 bifurcation angles as a marker for development of MCA IA found in the systematic review<sup>15</sup> on anatomic imaging markers for IAs. We observed no statistically significant distinctions in M1 diameters on the side ipsilateral to the MCA IA compared with those in matched controls. This diameter has been linked previously to MCA IAs with low evidence as reported in the systematic review.<sup>15</sup> The larger M2–M2 angle (both left and right) that we observed on a group level may be attributed to individuals with MCA IAs, who substantially increased the overall average of the IA group.

In addition, our results showed a smaller angle on the narrower side of the A1–A2 bifurcation in individuals with Acom IAs compared with their matched controls. This trend resembles findings previously reported in the literature.<sup>11,25</sup> Wider Pcom–C7 angles in individuals with Pcom IAs have not been described in earlier studies, although larger sample sizes are necessary to strengthen the statistical power and confirm observations in this study. A narrower angle between the C6 (ophthalmic segment of the ICA extending to origin of Pcom) and C7 (terminal segment of the ICA) has been suggested previously as a potential imaging marker for Pcom IAs.<sup>12</sup> Accurate measurement of the C6–C7 angle relies on precise identification of the ophthalmic artery's origin, which can be challenging due to the relatively small artery size and introduces subjectivity into the measurement process. Conse-

quently, we opted to use the Pcom–C7 angle, which may provide a more robust marker for Pcom IA development. We observed statistically significantly lower ICA diameters (measured 5 mm below the ICA top) in individuals with Pcom IAs compared with the control group. To our knowledge, the ICA diameter has not been studied in relation to Pcom IAs. The initial findings described in this paragraph did not withstand the stringent correction for multiple testing (adjusted  $P > 0.05$ ).

We found no statistically significant differences in Pcom diameters in individuals with Pcom IAs compared with their controls. This finding contradicts earlier reports,<sup>10</sup> which could be attributed to the choice of controls: The earlier study includes patients with non-Pcom IAs in the control group, whereas we include only individuals without IAs as controls.

In the systematic review,<sup>15</sup> A1 asymmetry was identified as an imaging marker for the development of Acom IAs with a high level of converging evidence. We observed no statistically significant differences in A1 asymmetry between the subgroup with IAs and the controls. These observations may be attributed to differences in patient selection and control groups between this study and earlier studies.<sup>25,26</sup> For instance, Bourcier et al<sup>25</sup> included only individuals with at least 2 first-degree relatives with IAs, whereas we combined 2 cohorts with the inclusion criteria of at least 1 first-degree relative with an IA or aSAH. Interestingly, their reported level of A1 asymmetry in the IA group (20.5%) was similar to ours (19.3%) but lower for controls (7.9%

versus 11.7%). Conversely, in the study from Kaspera et al,<sup>26</sup> the level of A1 asymmetry observed in controls (11.5%) was similar to ours (11.7%) but substantially higher in the IA group (32.6% versus 19.3%). In contrast with our study and Bourcier's study, a positive family history of IAs was 1 of the exclusion criteria.

In addition, A1–A2 diameter ratios were previously identified as possible imaging marker for Acom IAs. Artery diameters of the A2 segments were not included in the current study and may be included in future work to assess the A1–A2 diameter ratios.

In contrast to the Pcom IA subgroup, the ICA diameter or ICA top bifurcation angle was not statistically significantly different when comparing individuals with ICA IAs with controls. Given that most ICA IAs developed in segments further away from the ICA top (also T-junction), it is expected that the ICA diameter just below the ICA top and the ICA top bifurcation angle have limited impact. Other factors, such as the ICA curvature or basilar artery tortuosity,<sup>15</sup> may play a more prominent role in the development of ICA IAs and may be considered in future studies.

Except for the M2–M2 bifurcation angle, we did not identify any statistically significant variations at group-level between individuals with and without IAs following FDR correction. Our motivation for this analysis was to explore potential generic markers associated with IA presence, given the interconnection of all arteries in the CoW, and the occurrence of multiple IAs in some individuals.

Strengths of our study were the use of 2 large cohorts of individuals screened for IAs. Moreover, for our measurements of the diameters and bifurcation angles, we used a semiautomated method with high reproducibility and repeatability, providing more robust outcomes than manual measurements.<sup>22</sup> This method can be extended to extract other CoW characteristics, such as the tortuosity or average diameter of arteries, on the basis of the obtained artery centerlines. Given the large heterogeneity in marker definitions and the methodological quality in previous studies, such semiautomatic methods can offer a standardized approach to identify anatomic markers for IA with stronger evidence, particularly for larger populations.

The residual analysis showed no serious deviations from normality or signs of heteroscedasticity. There were some minor deviations noted for the Pcom diameter, primarily due to the presence of values below the detection limit. The intraclass correlation coefficient and Bland–Altman plots demonstrated strong agreement between and within raters. This supports the rationale for using semiautomatic methods to improve the repeatability and reproducibility of studies aimed at identifying imaging markers.

There are several limitations to the current study. First, the detection limit hindered accurate measurement of arterial diameters <1.2 mm. While prior research demonstrated good agreement between manual measurements and the employed semiautomatic method, some variability may still occur. Second, we combined 2 cohorts that selected eligible individuals based on different criteria (positive family history for aSAH or first-degree relative with UIA). The assumption that anatomic markers for IAs are comparable across both groups may require further investigation. Third, this study comprised a cohort of individuals at increased risk for developing IAs. These imaging markers can also be evaluated in a cohort of healthy individuals who are not specifically selected for IA screening, for example, in a population-based cohort. This would help determine whether these markers also contribute to the development of IAs independently of a positive family history. To obtain results with more statistical power, future studies including a larger group of individuals with IAs are warranted. Fourth, the predominance of smaller IAs in our data raises the possibility of a selection bias. Individuals with larger IAs, who are more likely to have undergone surgical treatment—an exclusion criterion in our study—are underrepresented. Consequently, our findings may be related specifically to smaller and less aggressive IA types. Finally, we did not incorporate other risk factors like smoking or hypertension in our matching procedure due to missing data in a substantial number of individuals.

Future research should investigate the extent to which these markers can contribute to the prediction of IAs in at-risk population groups during follow-up screening. Assessing imaging markers during the initial screening could improve the follow-up screening process by increasing the screening frequency for individuals at the highest risk for IAs while reducing or discontinuing screening for low-risk individuals. The use of semiautomatic methods, as demonstrated here, can enhance the repeatability and reproducibility in future studies.

## ARTICLE INFORMATION

Received January 2, 2024; Accepted April 3, 2024

### Affiliations

Image Sciences Institute, University Medical Center Utrecht, Utrecht, Netherlands (I.N.V., R.J.T., H.J.K., J.J.M.Z.); Department of Radiology, University Medical Center Utrecht, Utrecht, Netherlands (R.J.T., M.R.E.V., J.J.M.Z., I.C.S., B.K.V.); Department of Neurology and Neurosurgery, UMC Utrecht Brain Center, University Medical Center Utrecht, Utrecht University, Netherlands (L.A.M., M.E.H.O., G.J.E.R., Y.M.R.); Julius Center for Health Sciences and Primary Care, University Medical Center Utrecht, Utrecht, Netherlands (N.P.A.Z.)

### Acknowledgments

None.



## Sources of Funding

This project has received funding from the European Research Council under the European Union's Horizon 2020 research and innovation program (grant agreement No. 852173).

## Disclosures

None.

## Supplemental Materials

Tables S1–S6  
STROBE Checklist  
Figure S1

## REFERENCES

- Macdonald RL, Schweizer TA. Spontaneous subarachnoid haemorrhage. *Lancet*. 2017;389:655-666. doi: 10.1016/s0140-6736(16)30668-7
- Etmann N, Rinkel GJ. Unruptured intracranial aneurysms: development, rupture and preventive management. *Nat Rev Neurol*. 2016;12:699-713. doi: 10.1038/nrneuro.2016.150
- Bor AS, Koffijberg H, Wermer MJH, Rinkel GJE. Optimal screening strategy for familial intracranial aneurysms: a cost-effectiveness analysis. *Neurology*. 2010;74:1671-1679. 2010.
- Takao H, Nojo T, Ohtomo K. Screening for familial intracranial aneurysms. Decision and cost-effectiveness analysis. *Acad Radiol*. 2008;15:462-471. doi: 10.1016/j.acra.2007.11.007
- Szajer J, Ho-Shon K. A comparison of 4D flow MRI-derived wall shear stress with computational fluid dynamics methods for intracranial aneurysms and carotid bifurcations—a review. *Magn Reson Imaging*. 2018;48:62-69. doi: 10.1016/j.mri.2017.12.005
- Lu D, Kassab GS. Role of shear stress and stretch in vascular mechanobiology. *J R Soc Interface*. 2011;8:1379-1385. doi: 10.1098/rsif.2011.0177
- Meng H, Tutino VM, Xiang J, Siddiqui A. High WSS or low WSS? Complex interactions of hemodynamics with intracranial aneurysm initiation, growth, and rupture: toward a unifying hypothesis. *AJNR Am J Neuroradiol*. 2014;35:1254-1262. doi: 10.3174/ajnr.A3558
- Alnæs MS, Isaksen J, Mardal KA, Romner B, Morgan MK, Ingebrigtsen T. Computation of hemodynamics in the circle of Willis. *Stroke*. 2007;38:2500-2505. doi: 10.1161/strokeaha.107.482471
- Bourcier R, Lenoble C, Guyomarch-Delasalle B, Dumas-Duport B, Papagiannaki C, Redon R, Desal H. Is there an inherited anatomical conformation favoring aneurysmal formation of the anterior communicating artery? *J Neurosurg*. 2017;126:1598-1605. doi: 10.3171/2016.4.jns153032
- Can A, Ho AL, Emmer BJ, Dammers R, Dirven CMF, Du R. Association between vascular anatomy and posterior communicating artery aneurysms. *World Neurosurg*. 2015;84:1251-1255. doi: 10.1016/j.wneu.2015.05.078
- İdil Soylu A, Ozturk M, Akan H. Can vessel diameters, diameter ratios, and vessel angles predict the development of anterior communicating artery aneurysms: A morphological analysis. *J Clin Neurosci*. 2019;68:250-255. doi: 10.1016/j.jocn.2019.07.024
- Hu T, Wang D. Association between anatomical variations of the posterior communicating artery and the presence of aneurysms. *Neurol Res*. 2016;38:981-987. doi: 10.1080/01616412.2016.1238662
- Sadatomo T, Yuki K, Migita K, Imada Y, Kuwabara M, Kurisu K. Differences between middle cerebral artery bifurcations with normal anatomy and those with aneurysms. *Neurosurg Rev*. 2013;36:437-445. doi: 10.1007/s10143-013-0450-5
- Bor ASE, Velthuis BK, Majoie CB, Rinkel GJE. Configuration of intracranial arteries and development of aneurysms: a follow-up study. *Neurology*. 2008;70:700-705. doi: 10.1212/01.wnl.0000302176.03551.35
- Kancheva AK, Velthuis BK, Ruigrok YM. Imaging markers of intracranial aneurysm development: a systematic review. *J Neuroradiol*. 2022;49:219-224. doi: 10.1016/j.neurad.2021.09.001
- Rinkel GJ, Ruigrok YM. Preventive screening for intracranial aneurysms. *Int J Stroke*. 2022;17:30-36. doi: 10.1177/17474930211024584
- Zuurbier CC, Bourcier R, Constant Dit Beaufils P, Redon R, Desal H; ICAN Investigators; Bor ASE, Rinkel GJE, Greving JP, Ruigrok YM. Risk prediction of new intracranial aneurysms at follow-up screening in people with a positive family history. *Stroke* 54;2023:1015-1020.
- Mensing LA, van Tuijl RJ, Greving JP, Velthuis BK, van der Schaaf IC, Wermer MJH, Verbaan D, Vandertop WP, Zuihthoff NPA, Rinkel GJE, et al. Aneurysm prevalence and quality of life during screening in relatives of unruptured intracranial aneurysm patients: a prospective study. *Neurology*. 2023;101:e904-e912. doi: 10.1212/WNL.0000000000207475
- Vandenbroucke JP, Von Elm E, Altman DG, Gøtzsche PC, Mulrow CD, Pocock SJ, Poole C, Schlesselman JJ, Egger M; STROBE Initiative. Strengthening the Reporting of Observational Studies in Epidemiology (STROBE): explanation and elaboration. *Int J Surg*. 2007;18:805-835.
- Bor ASE, Rinkel GJE, van Norden J, Wermer MJH. Long-term, serial screening for intracranial aneurysms in individuals with a family history of aneurysmal subarachnoid haemorrhage: a cohort study. *Lancet Neurol*. 2014;13:385-392. doi: 10.1016/s1474-4422(14)70021-3
- Arrambide-Garza FJ, Alvarez-Lozada LA, de León-Gutiérrez H, Villarreal-Silva EE, Alvarez-Villalobos NA, Quiroga-Garza A, Elizondo-Ormaña RE, Guzman-Lopez S. Fetal-type posterior cerebral artery and association of rupture in posterior communicating artery aneurysms: A systematic review and meta-analysis. *Clin Neurol Neurosurg*. 2023;231:107815. doi: 10.1016/j.clineuro.2023.107815
- Vos IN, Ophelders MEH, Ruigrok YM, Velthuis BK, Kuijff HJ. Assessment of manual and automated intracranial artery diameter measurements. *Proc SPIE*. 2022;12035:10-15. doi: 10.1117/12.2611777
- de Vos V, Timmins K, van der Schaaf I, Ruigrok Y, Velthuis B, Kuijff HJ. Automatic cerebral vessel extraction in TOF-MRA using deep learning. *Proc SPIE*. 2021;11596:651-660. doi: 10.1117/12.2581226
- Selle D, Preim B, Schenk A, Peitgen HO. Analysis of vasculature for liver surgical planning. *IEEE Trans Med Imaging*. 2002;21:1344-1357. doi: 10.1109/tmi.2002.801166
- Bourcier R, Lenoble C, Guyomarch-Delasalle B, Dumas-Duport B, Papagiannaki C, Redon R, Desal H. Is there an inherited anatomical conformation favoring aneurysmal formation of the anterior communicating artery? *J Neurosurg*. 2017;126:1598-1605. doi: 10.3171/2016.4.JNS153032
- Kaspera W, Ładziński P, Larysz P, Hebda A, Ptaszkiewicz K, Kopera M, Larysz D. Morphological, hemodynamic, and clinical independent risk factors for anterior communicating artery aneurysms. *Stroke*. 2014;45:2906-2911. doi: 10.1161/strokeaha.114.006055
- Thoemmes F, Thoemmes F, Running Head: PROPENSITY SCORE MATCHING IN SPSS Propensity Score Matching in SPSS. arXiv (Cornell University); 2012.
- Sjölander A, Greenland S. Ignoring the matching variables in cohort studies - when is it valid and why? *Stat Med*. 2013;32:4696-4708. doi: 10.1002/sim.5879
- Benjamini Y, Hochberg Y. Controlling the false discovery rate: a practical and powerful approach to multiple testing. *J R Stat*. 1995;57:289-300.
- Zhang W, Wang J, Li T, Mei M. Morphological parameters of middle cerebral arteries associated with aneurysm formation. *Neuroradiology*. 2021;63:179-188. doi: 10.1007/s00234-020-02521-w
- Baharoglu MI, Lauric A, Safain MG, Hippelheuser J, Wu C, Malek AM. Widening and high inclination of the middle cerebral artery bifurcation are associated with presence of aneurysms. *Stroke*. 2014;45:2649-2655. doi: 10.1161/STROKEAHA.114.005393