


## REVIEW ARTICLE

# IDEAL monitoring of musical skills during awake craniotomy: From step 1 to step 2

C. H. Ferrier<sup>1,2</sup> | C. Ruis<sup>2,3</sup> | D. Zadelhoff<sup>3</sup> | P. A. J. T. Robe<sup>1,2</sup> |  
M. J. E. van Zandvoort<sup>1,2,3</sup> 

<sup>1</sup>Utrecht Brain Center, University Medical Center Utrecht, Utrecht, The Netherlands

<sup>2</sup>Department of Neurology and Neurosurgery, University Medical Center Utrecht, Utrecht, The Netherlands

<sup>3</sup>Experimental Psychology/Helmholtz Institute, Utrecht University, Utrecht, The Netherlands

## Correspondence

M. J. E. van Zandvoort, Department of Neurology & Neurosurgery, University Medical Center Utrecht, Heidelberglaan 100, Utrecht NL-3584CX, The Netherlands.

Email: [m.j.e.vanzandvoort@umcutrecht.nl](mailto:m.j.e.vanzandvoort@umcutrecht.nl)

## Funding information

T&P Bohnenn fund

## Abstract

The aim of awake brain surgery is to perform a maximum resection on the one hand, and to preserve cognitive functions, quality of life and personal autonomy on the other hand. Historically, language and sensorimotor functions were most frequently monitored. Over the years other cognitive functions, including music, have entered the operation theatre. Cases about monitoring musical abilities during awake brain surgery are emerging, and a systematic method how to monitor music would be the next step. According to the IDEAL framework for surgical innovations our study aims to present future recommendation based on a systematic literature search (PRISMA) in combination with lessons learned from three case reports from our own clinical practice with professional musicians ( $n = 3$ ). We plead for structured procedures including individual tailored tasks. By embracing these recommendations, we can both improve clinical care and unravel music functions in the brain.

## KEYWORDS

awake brain craniotomy, cognitive monitoring, IDEAL framework, musical monitoring

## INTRODUCTION

Awake craniotomy with cognitive monitoring to preserve quality of life and personal autonomy has gained acceptance over the years with a strong emphasis on language and sensorimotor functions. Traditionally, it is performed in patients with a tumour or focus of epilepsy in eloquent language areas of the brain (Coello et al., 2013). Later, other cognitive functions were added to the arsenal, although still underexposed (Ruis, 2018). The last decades, interest in the relation between music and neurosurgery

This is an open access article under the terms of the [Creative Commons Attribution-NonCommercial-NoDerivs](https://creativecommons.org/licenses/by-nc-nd/4.0/) License, which permits use and distribution in any medium, provided the original work is properly cited, the use is non-commercial and no modifications or adaptations are made.

© 2023 The Authors. *Journal of Neuropsychology* published by John Wiley & Sons Ltd on behalf of The British Psychological Society.

is growing. For example, Gasenzer et al. (2017a) described four historically famous musicians who underwent a neurosurgical procedure and the effect of this procedure on their lives and musical careers. Moreover, patients who listened to music preoperatively, intraoperatively and postoperatively demonstrate a significant reduction in fear, blood pressure and heart rate as compared to controls who did not listen to music (Wu et al., 2017). Another study reported patients were more at ease before, during and after awake surgery when they listened to music (Jadavji-Mithani et al., 2015). Gasenzer and colleagues found that outcomes and quality of life in neurosurgical patients were better in musicians as opposed to non-musicians when music was incorporated in intraoperative testing (Gasenzer et al., 2021). Over the last decade various case reports about monitoring music during awake brain surgery have been published. These reports all demonstrate the feasibility of various methods to monitor musical abilities. However, they are highly heterogeneous in methodology, musical abilities monitored and most of all are presented as unique cases. We set out to gather from experience from others through published studies and case reports, and lessons learned from our own clinical experience, in monitoring musical abilities during awake brain surgery and how this can be done according to the five stages of the IDEAL-framework (Idea, Development, Exploration, Assessment and Long-term study; McCulloch et al., 2009). This methodology offers the opportunity to critically assess novel ideas to ensure they confer true patient benefit.

Music has been part of human history for thousands of years and researchers assume that musical abilities of humans played a key role in the evolution of language as we know to this day (Wallin et al., 2000). Music has been shown to be incredibly valuable for the understanding of emotion, cognition and the brain mechanisms underlying these domains (Koelsch, 2011). Engaging in and making music stimulates important social functions, such as social cohesion, collaboration and communication in general (Koelsch et al., 2010). The neural basis of music in the brain is highly variable depending on the specific domain of music that one is interested in. For instance, feature extraction of music, such as periodicity, timbre, intensity or location is associated with the auditory brainstem and the thalamus (Koelsch, 2011). However, Gestalt formation, such as, melodic and rhythmic grouping is associated with the auditory association cortex (Griffiths & Warren, 2002). To assign meaning to heard music, the medial temporal gyrus, and the superior temporal sulcus, among other areas, are correlated (Lau et al., 2008). These areas are all associated with parts of the network involved in the perception and appreciation of music. However, an important distinction to make is that musical abilities not only involve perception of music through listening; making music, playing an instrument, concerns a whole different ability. Brain areas associated with small and precise movements are important for playing an instrument and include the (pre)motor cortex, auditory cortex, and supplementary motor cortex (Zatorre et al., 2007). Although understanding of language seems to be important for the ability to sing, speech and singing appear to use different pathways in the brain (Roux et al., 2009). The authors found a clear distinction between singing and speech when direct stimulation of the Broca area was performed. Moreover, direct cortical stimulation of primary sensorimotor areas without visible motor responses could also interfere with singing most likely due to interference of the fine articulatory mechanisms necessary for singing (Roux et al., 2009). Taken together, music asks for an integration of multiple cognitive functions, including motor functions, proprioception, hearing and emotion.

Probably the first mention of awake craniotomy with local anaesthesia and intraoperative music performance in a musician was that of a professional pianist who underwent brain surgery in 1942. Postoperatively she reported that she mentally played a Mozart piano concerto during surgery probably as a distraction, but also to monitor her own musical skills (Gasenzer et al., 2017b). Nowadays, several case reports about monitoring music during awake brain surgery are described in the literature, for instance a singer (Riva et al., 2016) and a violin player (Piai et al., 2019). However, an overview or review about monitoring the musical domain during awake brain surgery is missing. Scerrati et al. (2020) have recently conducted a review about musicians (patients suffering from dystonia, brain tumour or epilepsy) who underwent awake craniotomy. They concluded that intraoperative monitoring of musical skills can avoid neurological disturbances, but they did not focus on the preservation of musical abilities and as such, autonomy and quality of life of the patient through music.

A systematic way how to monitor music in order to preserve musical abilities based on the literature and the experience in our group would be the next step. The IDEAL framework for surgical innovations provides guidance to evaluate both literature and lessons learned in our own clinic. We aim to present recommendation to monitor musical abilities during awake surgery based on a systematic literature search following 'Preferred Reporting Items for Systematic reviews and Meta-Analyses' (PRISMA) in combination with our own case reports ( $n=3$ ). In this study, our focus will be on stage 1 of the IDEAL-framework: Idea. First, we will describe a systematic search in the literature on how music is monitored so far during awake craniotomy in brain tumour or epilepsy patients. We will include studies that describe patients that play an instrument as well as patients who sing, read scores or listen to music. Next, we evaluate three of our own cases. Based on both the above, we will formulate recommendations for the future and guidance to stage 2 (Development) of the IDEAL framework.

## METHODS SYSTEMATIC SEARCH

A systematic search was conducted using PubMed up to June 2021. The search strategy consisted of a framework, in which diseases (tumour or epilepsy) were combined with the procedure (e.g. surgery), wakefulness (awake) and music (music or sing). This resulted in the following search: (((((((("Brain Neoplasms"[MeSH Terms] OR "brain neoplasm\*" [Title/Abstract]) OR "brain tumour\*" [Title/Abstract]) OR "brain tumour\*" [Title/Abstract]) OR "Glioma"[MeSH Terms] OR "glioma\*" [Title/Abstract]) OR "glioblastoma\*" [Title/Abstract]) OR "Epilepsy"[MeSH Major Topic] OR "Epilepsy" [Title/Abstract] OR "epilepsies" [Title/Abstract]) AND (((((((("Neurosurgical Procedures"[MeSH Terms] OR "Cytoreduction Surgical Procedures"[MeSH Terms]) OR "cytoreduction surgical procedure\*" [Title/Abstract]) OR "reduction" [Title/Abstract] OR "debulking" [Title/Abstract]) OR "remove" [Title/Abstract]) OR "removal" [Title/Abstract] OR "surgery" [Title/Abstract] OR "neurosurgery" [Title/Abstract]) OR "craniotomy" [Title/Abstract]) AND (((((((("anaesthesia, local" [MeSH Terms] OR "local anaesthesia" [Title/Abstract]) OR "local anaesthesia" [Title/Abstract]) OR "Transcranial Direct Current Stimulation" [MeSH Terms] OR "stimulat\*" [Title/Abstract]) OR "awake" [Title/Abstract]) OR "penfield" [Title/Abstract]) OR "monitoring, intraoperative" [MeSH Terms] OR "intraoperative monitoring" [Title/Abstract])) AND (((("music" [MeSH Terms] OR "music\*" [Title/Abstract]) OR "singing" [Title/Abstract]) OR "song" [Title/Abstract]) OR "singing" [MeSH Terms]).

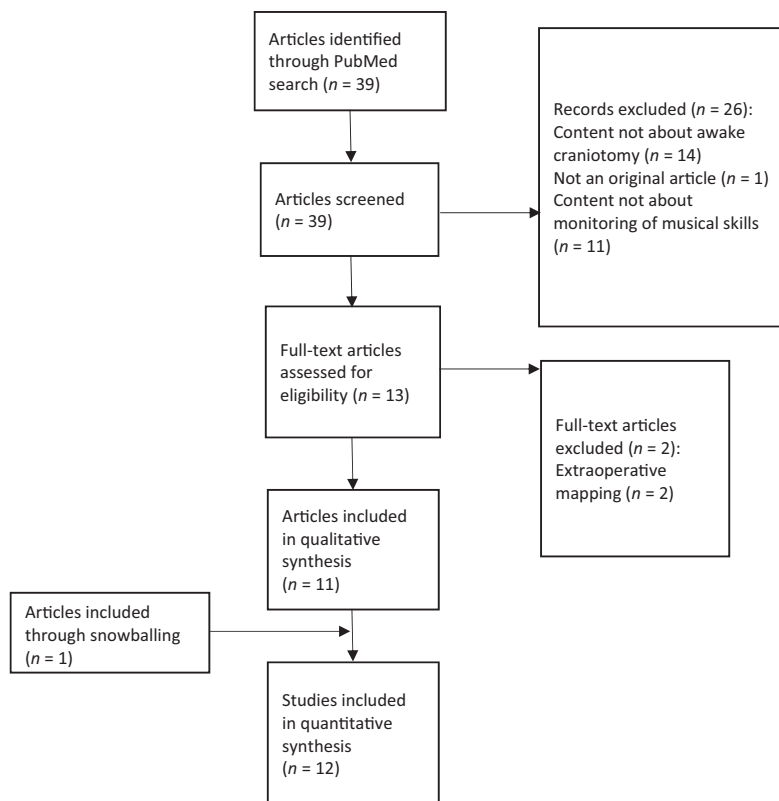
The screening of titles, abstracts and full articles was based on these specific inclusion criteria:

- The articles must be an original article written in English.
- The articles must include intraoperative measurements of musical skills during awake craniotomy (e.g., playing an instrument, singing or musical score reading).
- The procedure of the intraoperative measurements must be described clearly in the article.
- The awake craniotomy is performed in brain tumour or epilepsy patients.

After the selection of relevant papers from the search in PubMed, the references lists of the included articles were used to identify possible missing articles. Moreover, the "cited by" function in Google Scholar was used to further identify possible missing papers. When a full-text version of an article was not available, the original author was contacted and access to the article was requested.

## RESULTS SYSTEMATIC SEARCH

The search in PubMed resulted in 39 articles. [Figure 1](#) shows the PRISMA-flow diagram that was used for this systematic review. Twenty-six of the original 39 articles were excluded for multiple reasons, including: the content of these articles was not about awake craniotomy (e.g. transcortical magnetic stimulation (TMS) or positron emission tomography (PET) studies), the articles were not an original article, or the article content was not about monitoring musical skills. Studies that described extra-operative



**FIGURE 1** The Preferred Reporting Items for Systematic Reviews and Meta-Analyses (PRISMA) flow diagram for this systematic review.

mapping and/or stimulation were also excluded, because during extra-operative monitoring there is usually more time for tests to be performed in comparison to awake craniotomy and it is a different procedure. For eligibility screening, 13 articles were assessed in full text resulting in further inclusion of 11 articles. Reference list searching or the 'cited by' function of Google Scholar did not result in any more articles suitable to include in this study.

To give a background, the included articles are summarized below. [Table 1](#) shows the included studies, the operation indication, the instruments and the tasks that were used to monitor music.

Next, we analysed the similarities and differences of the included studies in more detail. The results can be found in [Table 2](#). We focused on the described procedures (see article summaries [Appendix S1](#)). To start with, nine of the 11 included studies described single case studies in which most patients appeared to be professionally trained musicians. Over the years studies have become more patient oriented, specifically aimed to preserve the individual patient's musical ability, and the monitoring became more tailored to the patient. The monitoring described was focused on music; however, in most cases, other cognitive domains were taken into account as well, such as language, praxis, speech and motor functions. Three studies monitored both production and perception of music, whereas the other studies focused on either of both. Huge heterogeneity was found in the use of renowned standardized batteries to test musical abilities, as for performing a pre-operative baseline and/or postoperative measurement. Five studies included a musical expert in the multidisciplinary team, and in five studies functional MRI (fMRI, three with music tests) is mentioned to further plan the monitoring.

**TABLE 1** Overview of included studies with mention of type of operation, music instruments (including the singing voice) and music tasks that were used to monitor musical abilities during surgery.

Article	Operation indication	Music instrument	Music task
Roux et al. (2007)	Lesion resections: Brain tumour ( $n = 5$ ; meningioma ( $n = 1$ ); cavernoma ( $n = 1$ ))	-	Score reading (existing musical pieces)
Roux et al. (2009)	Tumour resection ( $n = 5$ )	Voice	Singing (familiar songs)
Riva et al. (2016)	Resection right temporal ganglioglioma associated with focal cortical dysplasia	-	Recognition of melody, pitch, rhythm, and meter. Score reading
Hegde et al. (2016)	Right temporal lobectomy for epileptic focus mesial temporal and hippocampal atrophy	Voice	Singing, recognition of tone, melody, song and Indian ragas
Garcea et al. (2017)	Resection low-grade tumour right posterior lateral temporal	Voice	Singing (melody repetition by humming)
Katlowitz et al. (2017)	Right temporal lobectomy for epileptic focus mesial temporal	Voice	Singing (scales and familiar song)
Leonard et al. (2019)	Resection low-grade astrocytoma left insula	Guitar	Strumming chords
Piai et al. (2019)	Resection low-grade glioma left supplementary motor area	Violin	Playing a familiar piece by heart
Bass et al. (2020)	Resection low-grade glioma right posterior lateral temporal	Voice	Repetition of presented melodies by humming and singing familiar song
Scerrati et al. (2021)	Resection glioblastoma right parietal post Rolandic region	Clarinet	Playing Mozart clarinet concerto
Dziedzic et al. (2021)	Resection cavernoma left posterior superior temporal gyrus	Piano	Playing memorized music (arpeggios) and from score

TABLE 2 Overview of studies that report on intraoperative music testing.

Study	<i>n</i>	Patient oriented	Professional musician	Tailored	Instrument	Production	Perceptual	Expert in team	fMRI music	Preparation	Pre op	Post op	Standardized battery	Other domains
Roux et al. (2007)	7	N	Y ( <i>n</i> = 1), N ( <i>n</i> = 6)	N	-	N	Y	Y	N	N	Y	Y	N	L
Roux et al. (2009)	5	N	N	N	Voice	Y	N	N	N	N	Y	N	N	L
Riva et al. (2016)	1	Y	Y	N	-	N	Y	Y	N	Y	Y	Y	Y (MBEA <sup>a</sup> )	L+M
Hegde et al. (2016)	1	Y	Y	N	-	N	Y	N	Y	Y	Y	Y	N	N
Garcea et al. (2017)	1	Y	Y	N	Voice	Y	N	Y	Y	Y	Y	N	Y (MBEA <sup>b</sup> )	L
Katlowitz et al. (2017)	1	Y	Y	Y	Voice	Y	N	N	N	N	N	N	N	S
Leonard et al. (2019)	1	Y	Y	Y	Guitar	Y	N	N	N	N	N	N	N	L+S
Piai et al. (2019)	1	Y	Y	Y	Violin	Y	N	Y	N	Y	Y	N	N	M
Bass et al. (2020)	1	Y	Y	Y	Voice	Y	Y	Y	Y	Y	Y	Y	Y (Schön)	N
Scerrati et al. (2020)	1	Y	Y	Y	Clarinet	Y	N	N	N	N	N	N	N	N
Dziedzic et al. (2021)	1	Y	N	Y	Piano	Y	Y	N	N	N	N	N	N	P

Note: *n*: number of patients described in the study; *Patient oriented*: Yes = procedure was started based on request of the patient to preserve musical abilities, No = study oriented, patients were included (prospective or retrospective) based on their compatibility with an ongoing study; *Professional musician*: Yes = the patient was a musician at professional level, No; *Tailored*: Yes = intraoperative music monitoring consisted of production of music and was tailored to the routine musical practice of the patient (e.g. a clarinetist played the clarinet during operation), No = intraoperative monitoring was at a more generic level; Instrument: the instrument used during intraoperative monitoring; *Production*: Yes = patients were asked to produce music during intraoperative monitoring, No; *Perceptual*: Yes = patients were asked to listen to and judge different aspects of music during intraoperative monitoring, No; *Expert in team*: Yes = a musical expert was member of the multidisciplinary team and involved in the intraoperative monitoring, Not mentioned; *Preparation*: Yes = intraoperative music testing (partly) similar to intraoperative music testing, Not mentioned; *Pre op*: Yes = a baseline of musical abilities was tested before operation, Not mentioned; *Post op*: Yes = formal objective post-operative testing of musical abilities was performed, Not mentioned; *fMRI*: Yes = fMRI for music function was part of the pre-surgical work-up, Not mentioned; *Standardized battery*: Yes = during intraoperative monitoring a structured standardized battery for musical abilities, or derivative (<sup>a</sup>Montreal Battery for Evaluation of Amusia, Schön) was used, Not mentioned; *Other domains*: testing in addition to music tested during intraoperative monitoring (Language, Motor function, Praxis, Speech).

## LESSONS LEARNED FROM OUR OWN CLINICAL EXPERIENCE IN THREE CASE REPORTS

Based on stage 1 from the IDEAL framework we present three case reports from our own clinical centre. This study was presented to the Medical Research Ethics Committee UMC Utrecht, who concluded that the Medical Research Involving Human Subjects Act (WMO) did not apply to this study and therefore an official approval of this study by the Medical Research Ethics Committee UMC Utrecht was not required. Two of the patients had passed away at the moment of writing this manuscript. The third was informed about the study and gave informed consent.

### CASE REPORTS

#### Case 1: The organist

A 35-year-old professional organist underwent awake craniotomy for debulking of a glioma in the superior part of the left parietal lobe. About a year prior to surgery, he started to suffer from focal sensory seizures of the right arm with intact awareness. Over time, seizure frequency increased from once per several weeks to numerous seizures per day. After start of levetiracetam seizure frequency decreased again. MRI showed a tumour without contrast enhancement in the superior part of the left parietal lobe posterior the postcentral gyrus with a maximal diameter of 4.8 cm.

He was a professional organ player making a living with music by giving concerts and teaching music. He had his first organ lessons at the age of 12. From the age of 22 he had formal music training for organ and church music on the conservatory. During and after his conservatory training, he followed several masterclasses, and he played a wide range of music from composers from Middle Ages to 21st century.

Next to intraoperative monitoring according to best clinical practice in our centre (language functions, proprioception, clock reading, body representation, inhibition, calculation, sensorimotor functions of the hand) musical abilities were monitored. We designed specific intraoperative music performance tests (see below) to monitor function of the right hand while playing music bars from score and improvising. Score reading and improvising have been part of his music education and are essential to his music profession as an organist and professional music teacher. The patient was a highly skilled organist and was easily able to play melody and chords with one hand simultaneously as he considered this as part of his normal routine.

During the operation a portable keyboard (M-Audio Oxygen 49 MIDI keyboard) was used to perform music resembling organ playing. The keyboard was attached to a chair on wheels in upright position in such a way that the keyboard could be easily positioned in front of him, and he could perform in park bench position. The size of and intervals between the keys were comparable to those of the organs he used to play on. The keyboard was connected to a laptop with appropriate software (MacBook and Garage band) to produce organ sound that could be clearly heard in the operation room via computer speakers. In the weeks prior to surgery the patient practiced in sitting position on the same keyboard and he assured us he felt familiar with the response and touch of the keys and that performing during surgery using this set up would be no problem for him.

#### Intra-operative tests: Score reading and improvising tests

Playing from score was tested by presenting musical bars with short melodies consisting of four single (quarter) notes. These were melodies from an existing musical test battery (Schön et al., 2001). Single bars were presented as written music on an iPad and the patient played the melody with his right hand. The musical sequences were presented and judged by the surgical monitoring team that

included a professional musician (classical pianist) with medical training who joined the team for this occasion. To test improvising abilities the patient was asked to improvise musical sequences with his right hand in such a way music contains both melody and chords resembling church music he was used to play.

During stimulation, we found robust (three times similar stimulation site with identical error) interference with his musical abilities. This could be objectified in his performance (playing) as judged by both the multidisciplinary team (clinical neuropsychologist, neurologist, neurosurgeon and musical expert) and subjectively by the patient himself. He felt during these brief, specific moments it was not what he intended to do, less creative, less musical. At another moment he felt his hand slowing. Those sites were respected and not resected.

After recovery, he regained his pre-surgical level of performance as judged by himself and with a stable performance on the pre-surgical testing battery for music. At 6 months post-surgery he was again playing in church and was able to hold a concert. He no longer taught pupils, this however, was not due to loss of his musicality but by choice. He followed his deepest wish and followed an academic study to become pastor.

## Case 2: Tenor singer

A 39-year-old professional tenor singer underwent awake craniotomy for debulking of a contrast enhancing tumour in the right fronto-temporo-insular region. About a year prior to surgery, he started to suffer from focal sensory seizures with hot and cold sensations in the left arm and –leg with intact awareness and always followed by a cough. MRI showed a contrast enhancing tumour in the right fronto-temporo-insular region with a diameter of 7 cm.

At the time of surgery, he was a professional tenor singer. He had a formal dance education from age 7–18 years in his home country. At age 18 he was in a student choir, and he had professional lessons from age 21. At the age of 26 years, he came to the Netherlands for formal music education (tenor classical singing) at the conservatory. In the course of his disease, he was participating in a professional opera production.

Next to intraoperative monitoring according to best clinical practice in our centre (language functions inhibition, working memory, sensorimotor functions of the hand) musical abilities were monitored. We designed intraoperative music performance tests to monitor singing. The patient self-proposed to sing parts of ‘Gute Nacht’ from Schubert’s song cycle ‘Winterreise’. His pianist recorded the piano part of first and last couplets of the song so he could sing along during the operation while the accompanying music was played from a laptop that was connected to a speaker. It was the patient’s own request to sing both in major and minor keys, hence the choice for first and last couplets that are respectively in minor and major key. Prior to surgery, the patient was instructed to practice at home singing while lying on the left side (simulating left park bench position). Two weeks prior to surgery we practiced this set up in the hospital and recorded his performance on an iPad and portable microphone (Roland RO-05 Wave/MPR3 recorder). During surgery, music performance was incorporated in a battery of intraoperative cognitive monitoring tests. To test his singing, the piano music was played via laptop and the patient could sing along while the neurosurgeon was stimulating in the brain. His performance was recorded by video, mobile devices and a portable microphone. Robust disturbances of his singing were found, this was both observed by the multidisciplinary team as instantly by the patient himself. At one moment he was no longer able to sing (indicative of a speech arrest), at another moment he felt he was out of tune. This was not directly clear to the team, but robustly reported by the patient. Sites that appeared related to his musical performance were respected during resection. Later, after surgery, when the various moments of his singing in the recordings were assembled as a choir (composed of the same line at different moments in time), he clearly felt out of tune with himself at the same moments he reported this during stimulation. This proved his subjective feeling of error. After recovery, he was again able to perform professionally on stage, was given roles in opera’s and returned to his own level of musical functioning.



### Case 3: Guitar player

A-29-year-old professional guitar player underwent awake craniotomy for a glioma in the left parietal and temporal lobe. Three months prior to surgery he experienced his first epileptic seizure with distorted hearing followed by apraxia, confusion, and disturbed speech. He had amnesia for the whole event. After start of levetiracetam seizures were well controlled. MRI showed a non-contrast enhancing tumour in the left temporoparietal region with a diameter of 6 cm.

He considered himself as a professional autodidact guitar player and he was an experienced studio musician. He was the co-founder and front man (guitar and vocals) of a death metal band. The band was highly acclaimed in the death metal scene. He was also trained as a psychiatric nurse but music was a very important part of his life.

Next to intraoperative monitoring according to best clinical practice in our centre (language function, proprioception, clock reading, body representation, inhibition, calculation, sensorimotor functions of the hand) musical abilities were monitored. We designed intraoperative music performance tests to monitor function of his guitar playing. During the surgery he would use his own guitar (Alvarez MD 95) that has been attached to a guitar performer stand (König & Meyer 14761). We decided to use improvisation and playing chords from popular songs with familiar western chord progressions for monitoring of music performance. He was instructed to practice at home playing the guitar in lying position simulating right park bench position. He prepared chord progressions of songs with which he felt confident to perform under the pressure of awake surgery (for example 'Trains' by Porcupine tree). He recorded his performance with his mobile phone to familiarize the surgical team with the music he would perform during surgery. Around 1 week prior to the operation we also tested the ability to perform in lying position with guitar performer stand together with the anaesthesiologist to assure monitoring of vital functions and sufficient arterial and venous access during the surgery. During surgery music performance was incorporated in the battery of intraoperative cognitive monitoring tests. On the neurosurgeon's request guitar playing was tested. For this occasion, a guitarist (former neurosurgical resident) who was familiar with the music joined the team for optimal monitoring of intraoperative music performance. During stimulation musical performance could be robustly disturbed as judged by both the patient and multidisciplinary team. Several months after his surgery he was able to perform on stage with his band at his own level of performance.

## DISCUSSION

Over the last decade preservation of musical abilities during awake brain surgery has gained interest given the emerging number of case reports that have been published. These reports all demonstrate the feasibility of various methods to monitor musical abilities. Music to express oneself and as a window for emotions is important for all human beings, for some it is even crucial. We set out to gather knowledge from experience from others through published studies and case reports, and lessons learned from our own experience, in monitoring musical abilities during awake brain surgery and how this can be done according to the IDEAL framework including a literature study following to the PRISMA-guidelines.

The systematic literature search created an overview of the methods that have been published. Only studies that described the procedures of intraoperative monitoring of musical skills during awake craniotomy in patients with a brain tumour and/or epilepsy were included. Nevertheless, methods were only scarcely explained, especially the rationales behind the choices made for tasks were imprecise. This is most likely the price paid in ad hoc tailoring to the needs and experience of the patient involved. Not seldom the tasks performed preoperatively were different from the pre- and post-surgery evaluation. To date, available standardized test batteries to test musical abilities, such as the Montreal Battery of Evaluation of Amusia (MBEA; Peretz et al., 2003) and tests developed by Schön et al. (2001), tap on features of musical abilities but they do not reflect musicality itself. That means that even professional musicians can 'fail' on components of these batteries notwithstanding their outstanding level of

musical competence and performance. The use of these batteries in pre- and post-surgery evaluations can serve as a baseline but not as the only measurement performed to preserve individual musicality. Performing music at the patient's own level on their own instrument (including voice) remains the strongest source of behavioural data to judge changes in musical ability. For this reason, the inclusion of a musical expert in the multidisciplinary team, next to the use of the subjective judgement from the patient self, are equally important to detect changes in performance under stimulation. During our procedure of monitoring musical abilities under direct cortical and subcortical stimulation, the sites of the simulation were not reliably recorded. The set-up of the procedure was primarily clinical, and patient oriented in nature. Robustness of the produced error on stimulation, that is, three times on one site with identical error, was interpreted as clinically relevant. This was agreed upon before the operation in a shared decision-making process with the patient. Since we do not know for sure whether function will recover, we decided together as a team, including the patient, to respect potential critical sites. No clear-cut sites in the brain that represent musical abilities have been claimed to date, therefore we explored the area of planned resection under continuous testing. All three patients returned to their pre-operative level of musical functioning as we could judge based on their performance and subjective reports. Interpretation in terms of neuroanatomical underpinnings of musicality in the brain, is beyond the scope of this paper

Our cases stress the 'uniqueness' of each musical monitoring procedure. We conclude, based on the literature review and our own cases, that in order to preserve the musical abilities of the patient, tailoring to the musicality of that patient is the key. That has repercussions with respect to the process of standardization of procedures. However, clear-cut descriptions and use of a structured methodology do not hamper a tailored way of monitoring. This structure can help to use the data from unique cases to study how musicality is presented in the brain. Moreover, they can be highly hypotheses generating. This is the context in which we place our recommendations. First of all, they warrant good clinical practice, and secondly, they optimize valuable data to inform cognitive neuroscience to scrutinize research on the music and the brain

According to the IDEAL framework for neurosurgical innovations stage 1 (Idea) we present recommendations to guide the procedure of musical monitoring to the second stage. Stage 2 (Development and exploration):

- *Patient oriented.* Music should only be monitored on explicit wish of the patient and after shared decision making together with the patient. Preferably only in professional (or semi-professional) musicians for whom music is fundamental to quality of life and who can perform stable and reliable under the pressure of an awake monitoring context. Music can be an essential part of someone's life, for example for professional musicians. However, adding tests for monitoring music during such procedures, is an extra burden for patients and should not have negative consequences for the monitoring of other important cognitive domains such as language or motor functions. Music should not be seen, in our opinion, as a highly sensitive cognitive function that encompasses other cognitive functions, and, as such warrant their preservation. Nor as a tool to sooth the patient during the procedure as distraction sec. There should be a balance between the importance of music for a patient, on the one hand, and the investments that should be made to monitor this function during an awake brain surgery, on the other hand.
- *Tasks to monitor music should be tailored to the patient.* Music can be tested in many ways. Patients can be asked to perform music themselves, or they can be instructed to listen to music. Producing music or perceiving music requires totally different cognitive functions and cannot be generalize to each other. Both for production and for perception of music different, specific tasks are described in literature underlining the importance of personal tailoring. For example, producing a C scale can be an automatism for a professional musician, while playing a more complex song requires musical skills. Moreover, distinguishing familiar from unfamiliar melodies is not the same as determining whether a melody is a march or a waltz. We must be aware of those differences. Both the patient and the team involved in the awake brain surgery should carefully discuss and sort out which tasks are

most important for someone to maintain his or her musical skills. Moreover, extensive preparation is required so a patient knows what is going to be tested and the team has a thorough impression of the skills and level of the patient.

- In line with the abovementioned tailorship, *playing one's own instrument* is preferred. However, there are several limitations during surgery. First, freedom of movement of the patient is limited. The patient is lying, and the head of the patient is fixed in a clamp. Patient's position can be a complication in playing an instrument. Moreover, several instruments are too big to handle during the procedure. For instance, a professional drums player is not able to carry its entire drum kit into the operation room. A possible solution for this problem is the use of digital instruments.
- During surgery, *a musical expert should be part of the team*. Being an interested layman may not be enough to notice subtle changes or mistakes which are nevertheless key in creative musicality. The expert can help in accurate judging the musical output of the patient. In addition, the expert can help in how to handle the instrument (e.g., replacing a guitar string when necessary).
- *Musical abilities should be evaluated pre and postoperative and the preoperative procedure should be trained*. The musical abilities of the patient on the tasks that were used during surgery need to be tested preoperative as well as postoperative. Maybe more important, is a patient still able to produce or perceive music comparable to the level that he or she had before surgery? The postoperative evaluation is important for the patient, but also for the team involved in the awake brain surgery. Monitoring music during awake brain surgeries remains a very specialized intervention and there is no standard protocol. A precise postoperative evaluation can be informative and useful in optimizing the procedures for the future.
- *Finally, a structured and clear-cut description of the followed procedure and monitoring process should be recorded*. Moreover, we would be in favour of *an international database* of musical monitoring studies to learn from each other and to generate hypotheses for cognitive neuroscience to further understand musicality and its representation in the brain.

## AUTHOR CONTRIBUTIONS

Cyrille Ferrier wrote the paper, had a close collaboration with all three presented cases collaborated on the review part. Carla Ruis was the instigator of the systematic review, collaborated on one of the cases and wrote the paper. Dennis Zadelhoff provided the systematic review and writing. Pierre Robe was the supervisor of and responsible for all the three cases and wrote the article. Martine van Zandvoort was responsible for the research group, instigator of IDEAL combined with the review, responsible for two of the three cases and wrote the article.

## ACKNOWLEDGEMENTS

We thank our patients for their willingness to cooperate and share their musicality with us.

## FUNDING INFORMATION

T&P Bohnenn fund for Neuro-oncology.

## CONFLICT OF INTEREST STATEMENT

None declared.

## DATA AVAILABILITY STATEMENT

The data that support the findings of this study are available on request from the corresponding author. The data are not publicly available due to privacy or ethical restrictions.

## ORCID

M. J. E. van Zandvoort  <https://orcid.org/0000-0003-3992-2750>

## REFERENCES

- Bass, D. I., Shurtleff, H., Warner, M., Knott, D., Poliakov, A., Friedman, S., Collins, M. J., Lopez, J., Lockrow, J. P., Novotny, E. J., Ojemann, J. G., & Hauptman, J. S. (2020). Awake mapping of the auditory cortex during tumor resection in an aspiring musical performer: A case report. *Pediatric Neurosurgery*, 55(6), 351–358.
- Coello, A. F., Duvaux, S., De Benedictis, A., Matsuda, R., & Duffau, H. (2013). Involvement of the right inferior longitudinal fascicle in visual hemianopia: A brain stimulation mapping study: Case report. *Journal of Neurosurgery*, 118(1), 202–205.
- Dziedzic, T. A., Bala, A., Podgórska, A., Piwowska, J., & Marchel, A. (2021). Awake intraoperative mapping to identify cortical regions related to music performance. *Journal of Clinical Neuroscience*, 83, 64–67.
- Garcea, F. E., Chernoff, B. L., Diamond, B., Lewis, W., Sims, M. H., Tomlinson, S. B., Teghipco, A., Belkhir, R., Gannon, S. B., Erickson, S., Smith, S. O., Stone, J., Liu, L., Tollefson, T., Langfitt, J., Marvin, E., Pilcher, W. H., & Mahon, B. Z. (2017). Direct electrical stimulation in the human brain disrupts melody processing. *Current Biology*, 27(17), 2684–2691.
- Gaszenzer, E. R., Kanat, A., & Nakamura, M. (2021). The influence of music on neurosurgical cases: A neglected knowledge. *Journal of Neurological Surgery Part A: Central European Neurosurgery*, 82(6), 544–551.
- Gaszenzer, E. R., Kanat, A., & Neugebauer, E. (2017a). The unforgettable neurosurgical operations of musicians in the last century. *World Neurosurgery*, 101, 444–450.
- Gaszenzer, E. R., Kanat, A., & Neugebauer, E. A. (2017b). First report of awake craniotomy of a famous musician: Suprasellar tumor surgery of pianist Clara Haskil in 1942. *Journal of Neurological Surgery Part A: Central European Neurosurgery*, 78(3), 260–268.
- Griffiths, T. D., & Warren, J. D. (2002). The planum temporale as a computational hub. *Trends in Neurosciences*, 25(7), 348–353.
- Hegde, S., Bharath, R. D., Rao, M. B., Shiva, K., Arimappamagan, A., Sinha, S., Rajeswaran, J., & Satishchandra, P. (2016). Preservation of cognitive and musical abilities of a musician following surgery for chronic drug-resistant temporal lobe epilepsy: A case report. *Neurocase*, 22(6), 512–517.
- Jadavji-Mithani, R., Venkatraghavan, L., & Bernstein, M. (2015). Music is beneficial for awake craniotomy patients: A qualitative study. *Canadian Journal of Neurological Sciences*, 42(1), 7–16.
- Katowitz, K. A., Oya, H., Howard, M. A., III, Greenlee, J. D., & Long, M. A. (2017). Paradoxical vocal changes in a trained singer by focally cooling the right superior temporal gyrus. *Cortex*, 89, 111–119.
- Koelsch, S. (2011). Toward a neural basis of music perception—a review and updated model. *Frontiers in Psychology*, 2, 110.
- Koelsch, S., Offermanns, K., & Franzke, P. (2010). Music in the treatment of affective disorders: An exploratory investigation of a new method for music-therapeutic research. *Music Perception*, 27(4), 307–316.
- Lau, E. F., Phillips, C., & Poeppel, D. (2008). A cortical network for semantics:(de) constructing the N400. *Nature Reviews Neuroscience*, 9(12), 920–933.
- Leonard, M. K., Desai, M., Hungate, D., Cai, R., Singhal, N. S., Knowlton, R. C., & Chang, E. F. (2019). Direct cortical stimulation of inferior frontal cortex disrupts both speech and music production in highly trained musicians. *Cognitive Neuropsychology*, 36(3–4), 158–166.
- McCulloch, P., Altman, D. G., Campbell, W. B., Flum, D. R., Glasziou, P., Marshall, J. C., Nicholl, J., Aronson, J. K., Barkun, J. S., Blazeby, J. M., Boutron, I. C., Campbell, W. B., Clavien, P. A., Cook, J. A., Ergina, P. L., Feldman, L. S., Flum, D. R., Maddern, G. J., Nicholl, J., ... Balliol Collaboration. (2009). No surgical innovation without evaluation: The IDEAL recommendations. *The Lancet*, 374(9695), 1105–1112.
- Peretz, I., Champod, A. S., & Krista Hyde, K. (2003). Varieties of musical disorders. The Montreal battery of evaluation of amusia. *Annals of the New York Academy of Sciences*, 999, 58–75.
- Piai, V., Vos, S. H., Idelberger, R., Gans, P., Doorduyn, J., & ter Laan, M. (2019). Awake surgery for a violin player: Monitoring motor and music performance, a case report. *Archives of Clinical Neuropsychology*, 34(1), 132–137.
- Riva, M., Casarotti, A., Comi, A., Pessina, F., & Bello, L. (2016). Brain and music: An intraoperative stimulation mapping study of a professional opera singer. *World Neurosurgery*, 93, 486–e13.
- Roux, F. E., Borsa, S., & Démonet, J. F. (2009). “The mute who can sing”: A cortical stimulation study on singing. *Journal of Neurosurgery*, 110(2), 282–288.
- Roux, F. E., Lubrano, V., Lotterie, J. A., Giussani, C., Pierroux, C., & Demonet, J. F. (2007). When “abegg” is read and (“A, B, E, G, G”) is not: A cortical stimulation study of musical score reading. *Journal of Neurosurgery*, 106(6), 1017–1027.
- Ruis, C. (2018). Monitoring cognition during awake brain surgery in adults: A systematic review. *Journal of Clinical and Experimental Neuropsychology*, 40(10), 1081–1104.
- Scerrati, A., Labanti, S., Lofrese, G., Mongardi, L., Cavallo, M. A., Ricciardi, L., & De Bonis, P. (2020). Artists playing music while undergoing brain surgery: A look into the scientific evidence and the social media perspective. *Clinical Neurology and Neurosurgery*, 196, 105911.
- Scerrati, A., Mongardi, L., Cavallo, M. A., Labanti, S., Simioni, V., Ricciardi, L., & De Bonis, P. (2021). Awake surgery for skills preservation during a sensory area tumor resection in a clarinet player. *Acta Neurologica Belgica*, 121(5), 1235–1239.
- Schön, D., Semenza, C., & Denes, G. (2001). Naming of musical notes: A selective deficit in one musical clef. *Cortex*, 37(3), 407–421.
- Wallin, N. L., Merker, B., & Brown, S. (2000). *The origins of music*. MIT Press.

- Wu, P. Y., Huang, M. L., Lee, W. P., Wang, C., & Shih, W. M. (2017). Effects of music listening on anxiety and physiological responses in patients undergoing awake craniotomy. *Complementary Therapies in Medicine*, *32*, 56–60.
- Zatorre, R. J., Chen, J. L., & Penhune, V. B. (2007). When the brain plays music: Auditory–motor interactions in music perception and production. *Nature Reviews Neuroscience*, *8*(7), 547–558.

## SUPPORTING INFORMATION

Additional supporting information can be found online in the Supporting Information section at the end of this article.

### Appendix S1

**How to cite this article:** Ferrier, C. H., Ruis, C., Zadelhoff, D., Robe, P. A. J. T., & van Zandvoort, M. J. E. (2024). IDEAL monitoring of musical skills during awake craniotomy: From step 1 to step 2. *Journal of Neuropsychology*, *18*(Suppl. 1), 48–60. <https://doi.org/10.1111/jnp.12347>