



Contents lists available at ScienceDirect

Radiotherapy and Oncology

journal homepage: www.thegreenjournal.com

Original Article



Brachytherapy for rhabdomyosarcoma: Survey of international clinical practice and development of guidelines

Raquel Dávila Fajardo^{a,b,c,*}, Giovanni Scarzello^d, Mark N Gaze^e, Tom Boterberg^f, Alison Cameron^g, Joerg Fuchs^h, Florent Guérinⁱ, Peter Hoskin^e, Matthew J Krasin^j, Petra Kroon^{a,c}, Henriette Magelssen^k, Claes Mercke^l, Johannes H.M. Merks^{b,c}, Frank Paulsen^m, Pascal Pommierⁿ, Monica Ramos^o, Helen Rees^g, Tim Rogers^g, Maximilian Schmid^p, Guido Seitz^q, Olga Slater^r, Naima Smeulders^s, Jakob Stenman^t, Sheila Terwisscha^b, Cyrus Chargari^{u,1}, Henry C Mandeville^v

^a Department of Radiation Oncology, University Medical Center, Utrecht, the Netherlands^b Princess Máxima Center for Pediatric Oncology, Utrecht, the Netherlands^c Division Imaging and Oncology, University Medical Center, Utrecht, the Netherlands^d Veneto Institute of Oncology IOV - IRCCS, Padua, Italy^e Department of Oncology, University College London Hospitals NHS Foundation Trust, London, United Kingdom^f Department of Radiation Oncology, Ghent University Hospital, Ghent, Belgium^g Bristol Cancer Institute, University Hospitals Bristol and Weston NHS Foundation Trust, Bristol, United Kingdom^h Department of Pediatric Surgery and Pediatric Urology, University Children's Hospital, Tuebingen, Germanyⁱ Department of Paediatric Surgery, Paris-Saclay University, Assistance Publique-Hôpitaux de Paris, Bicêtre Hospital, Paris, France^j Department of Radiation Oncology, St. Jude Children's Research Hospital, Memphis, USA^k Department of Oncology, Oslo University Hospital, Norway^l Department of Oncology-Pathology, Karolinska Institute, Karolinska University Hospital, Stockholm, Sweden^m Department of Radiation Oncology, University Hospital, Tuebingen, Germanyⁿ Department of Radiation Oncology, Centre Leon Berard, Lyon, France^o Department of Radiation Oncology, Vall d'Hebron University Hospital, Barcelona, Spain^p Medical University of Vienna, Department of Radiation Oncology, Comprehensive Cancer Center, Vienna, Austria^q Department of Pediatric Surgery and Urology, University Hospital Giessen-Marburg, Campus Marburg, Marburg, Germany^r Department of Paediatric Oncology, Great Ormond Street Hospital for Children NHS Foundation Trust, London, United Kingdom^s Department of Paediatric Urology, Great Ormond Street Hospital for Children NHS Foundation Trust, London, United Kingdom^t Childhood Cancer Research Unit, Department of Women's and Children's Health, Karolinska Institute, Karolinska University Hospital, Stockholm, Sweden^u Department of Radiation Oncology, Gustave Roussy Comprehensive Cancer Center, Villejuif, France^v The Royal Marsden Hospital and Institute of Cancer Research, Sutton, United Kingdom

Abbreviations: BT, brachytherapy; CTV, clinical target volume; EBRT, external beam radiotherapy; EpSSG, European paediatric Soft tissue Sarcoma Study Group; GTV, gross target volume; Gy, gray; HDR, high dose brachytherapy; LDR, low dose rate brachytherapy; OAR, organs at risk; PDR, pulsed dose brachytherapy; PTV, planning target volume; RMS, rhabdomyosarcoma; RT, radiotherapy.

* Corresponding author at: Radiation Oncologist, University Medical Center Utrecht and Princess Máxima Center for Pediatric Oncology, Room number OS.4.311, Heidelberglaan 100 3584 CX, Utrecht, the Netherlands.

E-mail addresses: R.DavilaFajardo@umcutrecht.nl (R. Dávila Fajardo), Giovanni.scarzello@iov.veneto.it (G. Scarzello), mgaze@nhs.net (M.N. Gaze), tom.boterberg@ugent.be (T. Boterberg), Alison.cameron@UHBW.nhs.uk (A. Cameron), peterhoskin@nhs.net (P. Hoskin), P.S.Kroon-3@umcutrecht.nl (P. Kroon), HENMA@ous-hf.no (H. Magelssen), clas.mercke@regionstockholm.se (C. Mercke), J.H.M.Merks@prinsesmaximacentrum.nl (J.H.M. Merks), frank.paulsen@med.uni-tuebingen.de (F. Paulsen), pascal.pommier@lyon.unicancer.fr (P. Pommier), monica.ramos@vallhebron.cat (M. Ramos), Helen.Rees@uhbristol.nhs (H. Rees), Maximilian.a.schmid@meduniwien.ac.at (M. Schmid), guido.seitz@med.uni-marburg.de (G. Seitz), olga.slater@gosh.nhs.uk (O. Slater), Naima.Smeulders@gosh.nhs.uk (N. Smeulders), jakob.stenman@ki.se (J. Stenman), J.TerwisschavanScheltinga@prinsesmaximacentrum.nl (S. Terwisscha), cyrus.chargari@gustaveroussy.fr (C. Chargari).

¹ Present address: Department of Radiation Oncology, Pitié Salpêtrière University Hospital, Paris, France.

<https://doi.org/10.1016/j.radonc.2024.110273>

Received 15 November 2023; Received in revised form 7 March 2024; Accepted 4 April 2024

Available online 7 April 2024

0167-8140/© 2024 The Authors. Published by Elsevier B.V. This is an open access article under the CC BY license (<http://creativecommons.org/licenses/by/4.0/>).

ARTICLE INFO

Keywords:

Rhabdomyosarcoma
Brachytherapy
Soft Tissue Sarcoma

ABSTRACT

Background and purpose: The purpose of this study was to address the lack of published data on the use of brachytherapy in pediatric rhabdomyosarcoma by describing current practice as starting point to develop consensus guidelines.

Materials and methods: An international expert panel on the treatment of pediatric rhabdomyosarcoma comprising 24 (pediatric) radiation oncologists, brachytherapists and pediatric surgeons met for a Brachytherapy Workshop hosted by the European paediatric Soft tissue Sarcoma Study Group (EpSSG). The panel's clinical experience, the results of a previously distributed questionnaire, and a review of the literature were presented. **Results:** The survey indicated the most common use of brachytherapy to be in combination with tumor resection, followed by brachytherapy as sole local therapy modality. HDR was increasingly deployed in pediatric practice, especially for genitourinary sites. Brachytherapy planning was mostly by 3D imaging based on CT. Recommendations for patient selection, treatment requirements, implant technique, delineation, dose prescription, dose reporting and clinical management were defined.

Conclusions: Consensus guidelines for the use of brachytherapy in pediatric rhabdomyosarcoma have been developed through multicenter collaboration establishing the basis for future work. These have been adopted for the open EpSSG overarching study for children and adults with Frontline and Relapsed RhabdoMyoSarcoma (FaR-RMS).

Introduction

Brachytherapy can be a highly effective treatment with very limited morbidity for some carefully selected children with rhabdomyosarcoma (RMS). However, access may be limited by the need for highly specialized experienced teams that are needed to deliver the service [1]. RMS is the most common soft tissue sarcoma of childhood, accounting for around 3.5 % of all malignant diseases in children [2,3]. RMS derives from embryonal mesenchyme and can arise at almost any anatomical site. Current multimodal treatment strategies including chemotherapy, surgery, and radiotherapy achieve an overall 5-year survival rate of 80 % [4]. However, survival rates differ widely depending on the tumor location, age, stage and risk group [4,5]. Local therapy, including surgery and radiotherapy, can be challenging in young children and for specific locations, due to the potential long-term morbidity that can be induced.

Brachytherapy is a radiotherapy modality that uses sealed radioactive sources that are placed as close as possible to the site to be treated. It can be applied when the radiation source can be located within a body cavity, e.g. vagina or uterus (intracavitary brachytherapy), when the source can be placed in the tumor volume through inserted needles or catheters (interstitial brachytherapy), or can be put in close contact with it through specific applicators, surface molds or flaps (superficial or contact brachytherapy). The main brachytherapy advantages reside in the physics of the dose distribution around a radiation source, where a high concentration of dose is deposited immediately around the source with a rapid dose fall-off occurring away from the source (in accordance with the inverse-square law). This attribute minimizes the volume of normal surrounding tissue exposed to irradiation which contributes to lowering the potential long-term side effects compared with external beam radiotherapy (EBRT).

In Europe, the use of brachytherapy for the local treatment of RMS has increased over the last three decades, with the individual experiences of different institutions on the use of brachytherapy in pediatric RMS, combined with surgery or not, having been reported [6–18]. In the previous EpSSG RMS 2005 study protocol, the use of brachytherapy was permitted although no specific recommendations regarding source, dose prescription, fractionation schedule, brachytherapy technique or dose reporting were provided. In order to address this issue and set the basis for uniformity and further collaborative work, pediatric radiation oncologists and brachytherapists from pediatric brachytherapy treatment centers throughout Europe and the USA met to present their brachytherapy approaches in pediatric RMS, in a workshop hosted by the EpSSG. Subsequent collaborative work has resulted in guidelines that have been implemented in the current EpSSG overarching study for children and adults with Frontline and Relapsed RhabdoMyoSarcoma

(FaR-RMS) (ClinicalTrials.gov) [19].

Materials and methods

Data collection and consensus development

Prior to the initial Brachytherapy Workshop, a survey was conducted among the invited international pediatric radiation oncologists, brachytherapists and pediatric surgeons with expertise and experience in the treatment of soft tissue sarcomas, from 11 working groups (17 institutions) across Europe and the USA, to document details of the current practice in the treatment of RMS in pediatric patients with brachytherapy. Representatives from 9 of the 11 groups responded. The survey included questions regarding indications for brachytherapy, technical aspects (e.g., source, treatment time, prescribed dose, target definitions, optimization features, planning imaging and reporting parameters), supportive care and logistic/organizational facets. After completion of the survey, representatives of all 11 groups participated in a 2-day EpSSG workshop in May 2015, hosted at the Institute of Cancer Research, in Sutton (United Kingdom). In addition to the information from the survey, an overview of the literature, and the experience of each group was presented. In total, 25 clinicians from 17 centers collaborated in the Workshop (Table 1).

Utilizing the data and the conclusions reached at the open discussion from Workshop sessions, an initial draft of the overarching guideline document was produced by the corresponding author then reviewed and edited by the wider writing committee. A consensus statement of currently accepted best practice across different countries internationally was drafted in May 2018 and incorporated into the radiotherapy guideline of the ongoing FaR-RMS study (NCT04625907), which opened in September 2020. The FaR-RMS study incorporates prospective collection of dosimetric brachytherapy data using the SIOP Europe-EORTC QUARTET platform to support prospective and retrospective radiotherapy quality assurance (<https://siop.eu/activities/joint-projects/quartet/>) [20,21]. These recommendations are not intended to be used as a brachytherapy manual but rather to provide general guidelines for daily practice.

Results

Outcomes from the international brachytherapy workshop survey

Participating centers reported that the most commonly disease sites treated with brachytherapy were: 1. perineal, 2. head and neck, 3. bladder-prostate and vagina, 4. extremities, and 5. vulva (Q4). The majority of treated cases were embryonal RMS (Q6). Intraoperative

Table 1
Brachytherapy Workshop participating centers.

Collaborative group	Country	Center	Number of participants
EpSSG	Austria	Medical University Vienna	1
	Belgium	Ghent University Hospital	1
	France	Centre Léon Bérard	1
		Hôpital Universitaire Bicêtre	1
		Institut de Cancérologie Gustave Roussy	1
	Italy	Istituto Oncologico Veneto IRCCS	1
	Norway	Oslo University Hospital	1
	Spain	Vall d'Hebron	1
	The Netherlands	Princess Máxima Center	4
		University Medical Center	2*
	United Kingdom	Royal Marsden Hospital	1
		University College London Hospitals	2
COG	USA	Great Ormond Street Hospital for Children	2
		University Hospitals Bristol	2
CWS	Germany	St Jude Children's Research Hospital	1
	Sweden	Hospital of the university of Tübingen	3
		Karolinska University Hospital	2

Abbreviations: EpSSG: European Paediatric Soft Tissue Sarcoma Study Group; COG: Children's Oncology Group; CWS: Cooperative Weichteilsarkom Studiengruppe.

* These two participants have double affiliation, Princess Máxima Center and University Medical Center, and are also included in the count of Princess Máxima Center.

implant placing was more frequently used than image-guided interstitial insertion (Q9). High dose rate (HDR) with an Iridium¹⁹² (¹⁹²Ir) source was mostly employed (Q10). The survey respondents confirmed that the majority of specialist centers routinely used 3D imaging for planning purposes (Q11), mostly CT but increasingly MRI imaging (Q12). Verification implant position during treatment was assessed mainly by CT scan, followed by conventional X-ray, MRI and ultrasound (Q13). Brachytherapy in combination with surgery was predominantly the treatment selected by the teams, but brachytherapy alone was also widely used (Q16). Brachytherapy had also been used for re-irradiation (Q23), mainly after previous EBRT (Q25). Not all centers had a dedicated pediatric ward for brachytherapy patients (Q32). All survey respondents indicated the routine involvement of pediatric oncology in the process (Q35), and specialist pediatric anesthesia was used for all cases (Q36); two centers did not respond to these questions. An extended overview of the survey questions, as well as the most relevant results of the survey, can be found in [Figures S1 and S2](#).

Requirements for a pediatric brachytherapy service

A multidisciplinary approach for the safe and effective delivery of pediatric brachytherapy is essential. Treatment should be undertaken at a specialist referral center by clinicians with both expertise in brachytherapy and in the management of children with cancer [22]. An expert pediatric multi-disciplinary team including radiology, pathology, pediatric- and radiation oncology, and surgery appropriate to the anatomical site to be treated is needed to carefully select patients for consideration for brachytherapy in different anatomical sites. For treatment delivery, an experienced brachytherapy team including physicians (radiation

oncologists, surgeons, radiologists, anesthetists, pediatric oncologists), physicists and radiotherapy technologists is indispensable. Success of brachytherapy is dependent on many factors in addition to the accurate implant placement. Most experience has been built with intraoperative implant placement or intracavity treatments, but interstitial image-guided placement may also be considered. Image guidance is recommended to ensure appropriate placement of the brachytherapy implants and should be used for planning purposes.

Brachytherapy indications for rhabdomyosarcoma

Disease sites where brachytherapy may be the optimal local treatment for carefully selected patients with RMS include genitourinary (bladder neck – prostate, vagina, vulva and cervix), perineum, extremities, orbit and other head and neck sites. It can be used alone or in combination with minimally invasive or function-preserving conservative, or radical surgery, simultaneously, as one procedure, or sequentially, as two separate ones. Tumor size at the time of local therapy is an important factor as lesions smaller than 5 cm in maximal dimension following chemotherapy are more suitable for brachytherapy, although no firm size threshold exists and brachytherapy can be undertaken for larger lesions if the feasibility of a technically good implant is assessed and approved by an experienced pediatric brachytherapy team. After previous radiotherapy, brachytherapy can play a role in the salvage of local recurrent disease [23].

Pre-treatment investigations

Physical examination at presentation and prior local treatment is mandatory; that includes cystoscopy in cases of bladder neck – prostate RMS and vaginoscopy/gynecological examination under anesthesia for vaginal RMS. Radiological full staging, including regional nodal- and distant evaluation, and MRI investigation to assess local extension and invasiveness are required. A full bladder MRI is critical in bladder neck – prostate RMS and should be performed at diagnosis and re-assessment.

Timing

Early contact with the brachytherapy reference center is recommended. A decision should be taken after response assessment following three cycles of induction chemotherapy (week 9), although up to six cycles (week 16) may be delivered for selected cases of localized disease to obtain additional tumor reduction to enable brachytherapy to be undertaken. Tumor site, size and extent after induction chemotherapy, invasiveness and brachytherapy feasibility will be considered in the multidisciplinary meeting to determine eligibility.

Source type and dose rate

The most frequently used radioactive source is ¹⁹²Ir. Remote after-loading systems should be used. Both pulsed dose rate (PDR) as well as HDR can be considered. Non-permanent manually loaded low dose rate (LDR) sources are no longer available, and permanent LDR implants should not be used.

Technique

Depending on the tumor site, either intracavitary or interstitial brachytherapy, or a combination of both, will be most suitable. General anesthesia, or sedation, is required for catheter placement and/or treatment.

Genitourinary

Bladder neck – prostate. As reported by Chargari et al. [12], with the

largest experience so far, brachytherapy may be considered for cases where the tumor does not extend above the level of the bladder trigone at the time of local therapy. With a suprapubic approach, a partial prostatectomy with urethral preservation and/or a partial cystectomy of the bladder neck is performed, with a ureteral extravasical reimplantation if necessary. Intraoperatively, transperineal interstitial implantation of flexible catheters follows. They will encompass the prostate and bladder neck. Depending on the anatomy, usually 4 to 6 catheters, parallel and equidistant to each other in two planes, generate the best dosimetry. Temporary testicular transposition to the abdominal wall should be considered where required to protect fertility during the irradiation, but may not be necessary and can potentially lead to a devascularization of the testis [24]. Similarly, temporary oophoropexy can be considered in female patients with bladder neck RMS, as well as for the vagina-uterus sites, in order to protect ovarian function during the irradiation [25]. As an alternative, conservative surgery may precede the brachytherapy, which can then be performed by transrectal ultrasound guided *trans*-perineal insertion of treatment catheters to treat prostate, urethral and bladder neck tumors (Fig. 1) [6].

Vagina – uterus. The use of an individual customized mold applicator is recommended [13,16,26,28,29]. In cases with deep paravaginal tumor extension, a combined intracavitary-interstitial approach may be required. After acquisition of a vaginal impression to define the extension of the tumor at time of the local therapy, a customized mold applicator will be created following the same technique as in adult patients [26]. An adequate number of flexible catheters are placed at the surface of the mold applicator to achieve a good dosimetric coverage of the target volume (Fig. 2). Alternatively, a standard intra-uterine tube and/or vaginal applicator can be used, with or without interstitial catheters, with small sizes suitable for children.

Vulva. Interstitial plastic tubes technique can be used in pediatric patients as applied in adults. Geometrical placing of the catheters should be done using the classic systems of interstitial brachytherapy [30] to ensure optimal dosimetry [16].

Perineum

Intraoperative perineal implant or image-guided procedure, mostly with endorectal ultrasound, but also MRI, or a combination of both, may be considered. An anorectal spacer may be considered to reduce the dose to the anal sphincter and rectum [31].

Extremities

The most common technique is the intraoperative placement of flexible catheters. In most cases, after gross tumor resection, an interstitial single-plane implant with parallel, equidistant catheters, will offer adequate dosimetry of the tumor bed. Brachytherapy for grossly unresected tumors or with microscopic residual margins will most likely require a multiple-plane implant. A template, mesh or fixation applicator can be used to ensure parallelism [32]. A mold technique like the AMORE protocol (see section *Head and Neck*) can in some cases be a good alternative.

Orbit

Brachytherapy can be used as local treatment for orbital RMS in first line treatment, especially when complete remission after induction chemotherapy has not been achieved and can also be a good alternative as part of a salvage treatment for those that have previously received upfront radiotherapy. Preservation of a functional the ipsilateral eyeball, should be a priority. A brachytherapy technique for this localization has previously been described [33,34] but the largest published experience so far was described by Blank et al. [14] where after macroscopic tumor resection, assuming potential microscopic residual disease, irradiation of the tumor bed is achieved by means of a mold brachytherapy technique (Fig. 3).

Head and neck

Head and neck non-parameningeal (NPM), as well as highly selected parameningeal (PM) located tumors, can be treated with brachytherapy. The largest published experience including PM tumors is the Dutch experience with the ‘AMORE’ protocol, which consists of consecutive Ablative surgery, MOld technique with afterloading brachytherapy and immediate REconstruction. After macroscopic radical resection of the tumor individual molds containing flexible catheters between layers are constructed to fill in the surgical bed. Once brachytherapy has been

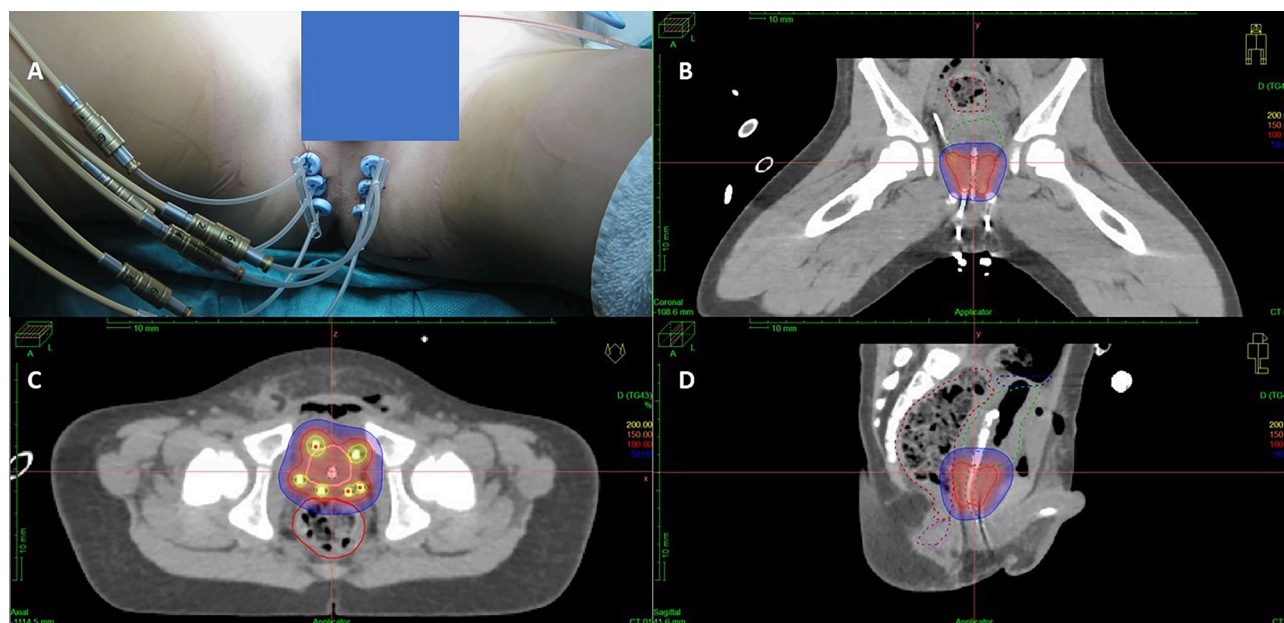


Fig. 1. Intraoperative, *trans*-perineal brachytherapy catheters placing for the treatment of bladder neck/prostate rhabdomyosarcoma (a) and the brachytherapy dose distribution (b): the yellow isodose surface corresponds to 200% of the prescribed dose, the orange to the 150%, the red to the 100%, and the dark blue to the 50%, respectively.

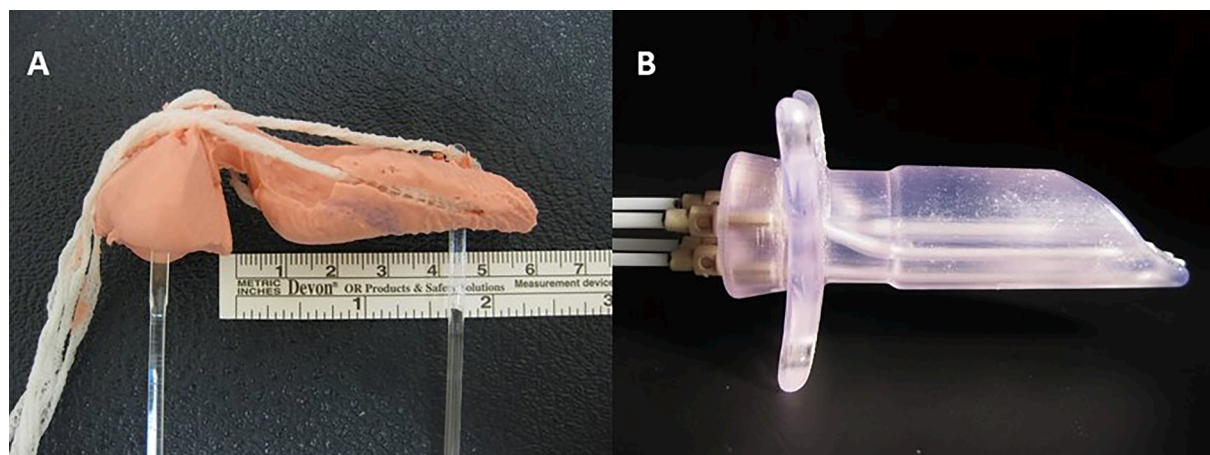


Fig. 2. Vaginal impression (a) used as template for an individual vaginal mold (b).

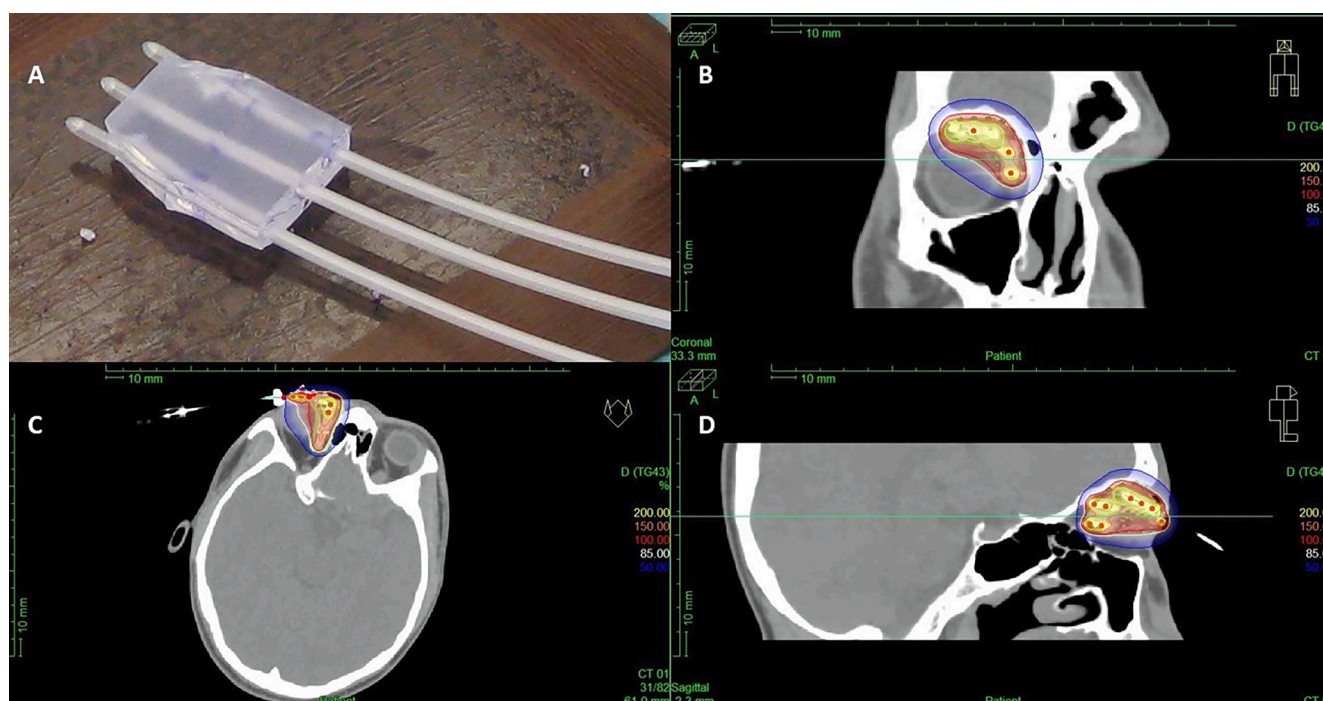


Fig. 3. Silicon mold/catheters (a) to be placed in the surgical defect/tumor bed for eyeball-conservative tumor resection of an orbit rhabdomyosarcoma and intraoperative brachytherapy. Brachytherapy dose distribution (b,c,d): orange isodose surface – 150% of the prescribed dose, red – 100%, white – 85%, and dark blue – 50%, respectively; green dotted line: clinical target volume (CTV).

applied, the molds are removed and a surgical reconstruction with or without muscle flaps takes place [15,35]. The use of surgical navigation and endoscopic catheters placement, when feasible, has recently become a common practice in specialist centers (Fig. 4).

In case of head and neck NPM RMS (e.g., oral cavity, oropharynx, nasopharynx and cheek) appropriate brachytherapy implants with plastic tubes or specific applicators, as used in adult brachytherapy practice, can be considered [36] (Fig. 5).

Planning

Target definition

The definitions of gross tumor volume (GTV) and clinical tumor volume (CTV) in brachytherapy are identical to the definitions given for EBRT in ICRU Report 50 and ICRU Report 62, since they are oncologic concepts, and therefore independent of the radiation treatment

modality, with a GTV to CTV margin of 5 mm generally used. In brachytherapy, planning target volume (PTV) is in principle identical to CTV. In order to delineate the CTV, the anatomical situation and tumor extension at time of local treatment after induction chemotherapy should be considered. In case of residual macroscopic tumor, the CTV will include the GTV, i.e. the remaining tumor volume at time of brachytherapy, plus an appropriate margin. The GTV at diagnosis as well as the anatomical movement of other structures after tumor shrinkage have to be taken into account to define this margin, although often a compromise has to be made in order to reduce the risk of morbidity. In case of residual microscopic disease after macroscopic tumor resection, the CTV is defined as the tumor bed (GTV) with a margin usually 5 mm. Again, anatomical changes should be taken into account. The target volume as well as the organs at risk (OARs) should be defined based on post-implant imaging, by preference MRI due to its higher soft tissue contrast in comparison to CT. Whenever a MR-only procedure cannot be

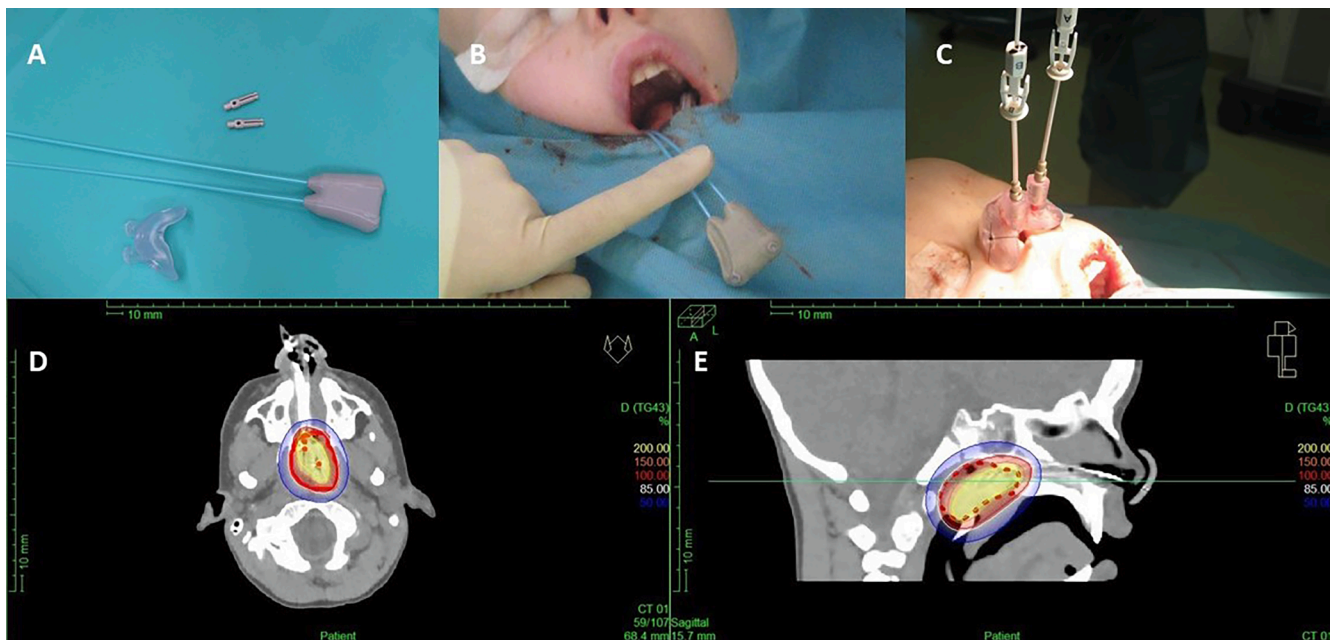


Fig. 4. Individualized 3D-printed mold in place after ablative surgery for rhabdomyosarcoma arising from the nasopharynx (a,b,c) and brachytherapy dose distribution (d,e): red isodose surface – 100% of the prescribed dose, white – 85%, and dark blue – 50%, respectively; orange dotted line: clinical target volume (CTV).

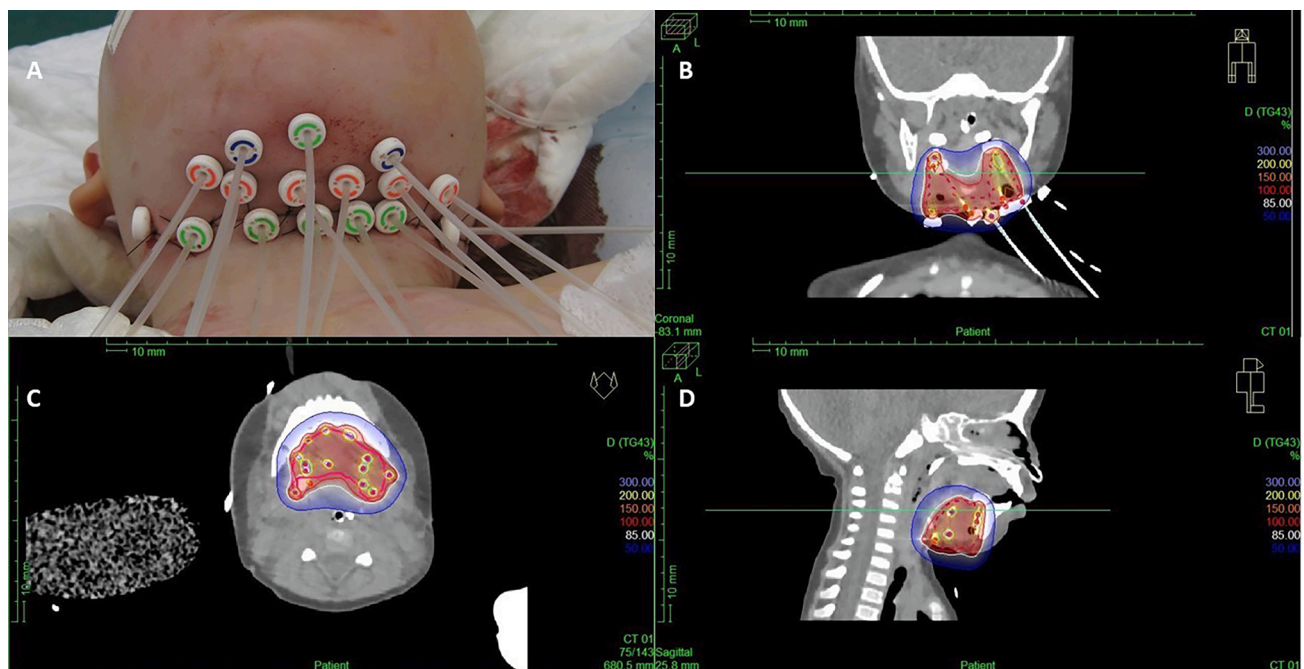


Fig. 5. Combined surgical resection and interstitial brachytherapy for the treatment of a floor of the mouth rhabdomyosarcoma (a) and dose distribution (b,c,d): red isodose surface – 100% of the prescribed dose, white – 85%, and dark blue – 50%, respectively; pink dotted line: clinical target volume (CTV).

guaranteed, a CT scan will be required in order to accurately perform the catheter reconstruction for interstitial brachytherapy.

Organs at risk

All the potential organs at risk located within 5–10 cm of the irradiated area depending on the expected isodose pattern should be contoured. For instance, for tumors located in the pelvic area the following organs should be contoured: rectum, bladder, urethra/ureters, sigmoid, bowel, ovaries, uterus, testes, growth plates, bone and cartilage structures close to the implant. For head and neck tumors, depending on the exact location: the eyeball, optic nerve, lens, lacrimal gland, parotid

gland, submandibular gland, cochlea, chiasm, closely located bone structures (e.g., maxilla, mandibula, orbit, ethmoid and sphenoid) are delineated.

Dose prescription

Interstitial brachytherapy. The current routinely used computerized treatment planning systems allow for a better individual optimization of the dose distribution, although the classic systems of interstitial brachytherapy, e.g. the Paris system [30], do ensure a good dosimetric distribution prior to optimization. Optimization should be undertaken

carefully to avoid high-dose areas; however, optimization cannot fully compensate for inadequate implantation.

Intracavitary technique / mold. The mold applicator is individually made for each patient and follows the exact anatomy at the time of the implant (the vaginal contours in a vaginal RMS, or the tumor bed in an AMORE-like procedure, as an example) [15,27]. After defining a CTV based on the intraoperative clinical assessment, the calculation of the dose distribution is usually achieved by using dose reference points created at the surface of the CTV. Special attention should be given not to accept high dose regions at the surface of the CTV in close contact with the mold.

Reporting parameters

For reporting purposes, at least the following parameters should be collected:

- Source: HDR / PDR.
- Implant: Intracavitary / interstitial.
- Prescribed dose (PD) (Gy), number of pulses (PDR) or fractions (HDR), and time between them.
- Treatment time (overall and per pulse/fraction).
- Number of catheters.
- Total Reference Air Kerma TRAK (cGy.m²).
- Implant (volume of reference isodose): V_{100%} (cm³).
- Dose parameters CTV (excluding mold if applicable) – EQD2(α/β): D_{98%}, D_{90%} and D_{50%} (Gy), V_{100%}, V_{150%} and V_{200%} (cm³).
- Indices:

- Dose Homogeneity Index [DHI=(CTV V_{100%}-CTV V_{150%})/CTV V_{100%}].
- Dose Non-uniformity Ratio [DNR = CTV V_{150%}/CTV V_{100%}].
- Conformal Index [COIN = c1 x c2].

Where

- Conformity Index [c1 = CTV V_{100%}/VCTV].
- Healthy Tissues Conformity Index [c2 = CTV V_{100%}/Implant V_{100%}]
- j. Dose parameters OARs – EQD2(α/β): D_{2cc}, D_{1cc}, D_{0.5cc} and D_{0.1cc} (Gy).

Schedule

Based on the current experience, the following dose prescriptions can be considered when brachytherapy is standing alone. No distinction is made between the presence or absence of macroscopic residual disease.

PDR

French experience: 120-143x42cGy, every hour (T_{1/2} = 1.5 h) [49.6–59.1 Gy (EQD2 α/β 10) / 48.4–57.7 Gy (EQD2 α/β 3)].

Dutch experience: 32-36x125cGy, every 2.1 h (T_{1/2} = 1.5 h) [41.8–47.5 Gy (EQD2 α/β 10) / 44.2–50.9 Gy (EQD2 α/β 3)].

Dutch experience (genito-urinary): 105-120x50cGy, every hour (T_{1/2} = 1.5 h) [53.1–60.7 Gy (EQD2 α/β 10) / 53.9–60.7 Gy (EQD2 α/β 3)].

HDR

British experience: 5x5.5 Gy BID [35.5 Gy (EQD2 α/β 10) / 46.8 Gy (EQD2 α/β 3)].

German experience: 12x3Gy BID [39 Gy (EQD2 α/β 10) / 43.2 Gy (EQD2 α/β 3)].

Italian experience: 12x3Gy BID [39 Gy (EQD2 α/β 10) / 43.2 Gy (EQD2 α/β 3)].

Swedish experience (genito-urinary): 14x3Gy BID [45.5 Gy (EQD2 α/β 10) / 50.4 Gy (EQD2 α/β 3)].

Recurrent disease

In selected patients, brachytherapy can also be considered in recurrent pediatric RMS, after previous EBRT or brachytherapy. The same approach as in first line treatment applies during the intraoperative implant. During the brachytherapy planning special attention will be paid to the dose to the OARs and to avoid areas of high dose. [15,23,37].

Management

Given the rarity and complexity of pediatric brachytherapy treatments, cases of RMS that are suitable for such an approach should be jointly managed with tertiary pediatric oncology expertise to guarantee optimal care. The provision of a designated pediatric ward for broad oncologic care and nutritional support, and the involvement of a pediatric anesthetics team that can ensure appropriate comfort during treatment are mandatory. The combination of all these aspects within the brachytherapy facility contributes to the success of this treatment approach. The additional provision of services, such as the involvement of a health play specialist team, who have a key role in the preparation phase, as well as during the actual treatment period in helping the child to manage concerns or emotions related to the treatment through the use of play techniques. Given the rarity of these treatments it is recommended that children are closely followed up and have access to long term late effects surveillance to ensure the early detection and treatment of local therapy related consequences.

Discussion

RMS is a rare pediatric malignancy of embryonal mesenchymal origin that can originate in a variety of locations in the human body. The local treatment (surgery and/or radiotherapy) of certain anatomical sites, especially at young ages, can result in undesirable long-term side effects. Brachytherapy is a radiotherapy modality that can help to minimize the local treatment morbidity [38,39]. The experience of a number of institutions using brachytherapy in specific situations as part of the treatment of RMS in children has been reported, although, to date, consensus on aspects such as indication, technique, prescription, planning and reporting were lacking. The purpose of this workshop was to describe current brachytherapy practice as a starting point to develop consensus guidelines.

Brachytherapy is a well-recognized alternative radiotherapy modality in the treatment of adult sarcoma patients. The general brachytherapy concepts and its physical and radiobiological benefits (i.e., shorter overall treatment time, safe delivery of high dose to the tumor or tumor bed with a rapid dose fall-off, minimization of dose to normal tissues, and delivery of precisely conformal radiation) are applicable to all subjects independent of age. However, the existing guidelines on brachytherapy for sarcomas do not necessarily fulfill the requirements of brachytherapy in the pediatric RMS population, nor represent the specificities and practicalities of the treatment in this group of patients [40–43]. Similarly, the available recommendations for genitourinary and head and neck brachytherapy are not fully applicable for pediatric RMS brachytherapy, although they serve as an invaluable source for reporting and 3D image based delineation concepts [28,44–49]. The recommendations detailed in this manuscript strive to: a) provide a comprehensive guide for pediatric oncology treating teams, b) increase the awareness to the pediatric oncology community of brachytherapy as a treatment modality, c) set the platform for future collaborative work.

According to the conducted survey, the commonest utilization of brachytherapy was tumor resection with adjuvant brachytherapy, followed by brachytherapy as sole local therapy modality. An increasing use of HDR is noted in pediatric brachytherapy, especially for genitourinary sites. To report the experience with HDR is a relevant aspect since PDR facilities are less frequently available. 3D imaging based on CT is widely used for planning, however the potential advantages of

using MRI for planning purposes are currently underutilized. The following aspects can be considered a limitation to this work: 1. not all the working groups responded to the initial survey (9/11), however, all groups were represented during the Workshop sessions; 2. the given recommendations are mainly based on expert opinions, although consistent evidence has been presented as well.

Our recommendations aim to integrate the technical aspects of brachytherapy with the understanding of the pediatric RMS behavior. The advice described in this report is based on the clinical experience and the dosimetric concepts used by different institutions as a way to enable various working groups to use a common language, serving as a base for future efforts working towards prescription homogenization and more precise delineation notions that incorporate the developments of MRI image-based 3D treatment planning.

Conclusion

Brachytherapy used alone or in combination with surgery continues to be an alternative for the local treatment of carefully selected patients with pediatric RMS. The dosimetric advantages of this radiotherapy modality can have an impact on the reduction of late toxicity in pediatric RMS survivors. Given the rarity of cases and expertise that is required to deliver pediatric brachytherapy, (inter)national centralization of care is strongly encouraged. The first guidelines for the use of brachytherapy in RMS for the international FaR-RMS study have been established incorporating findings from this International Paediatric Brachytherapy Workshop survey.

CRedit authorship contribution statement

Raquel Dávila Fajardo: Conceptualization, Data curation, Formal analysis, Investigation, Methodology, Project administration, Resources, Software, Validation, Visualization, Writing – original draft, Writing – review & editing, Supervision. **Giovanni Scarzello:** Conceptualization, Validation, Writing – review & editing. **Mark N Gaze:** Conceptualization, Supervision, Validation, Writing – review & editing. **Tom Botenberg:** Writing – review & editing. **Alison Cameron:** Writing – review & editing. **Joerg Fuchs:** Writing – review & editing. **Florent Guérin:** Writing – review & editing. **Peter Hoskin:** Writing – review & editing. **Matthew J Krasin:** Writing – review & editing. **Petra Kroon:** Data curation, Resources, Writing – review & editing. **Henriette Magelssen:** Writing – review & editing. **Claes Mercke:** Writing – review & editing. **Johannes H.M. Merks:** Writing – review & editing. **Frank Paulsen:** Writing – review & editing. **Pascal Pommier:** Writing – review & editing. **Monica Ramos:** Writing – review & editing. **Helen Rees:** Writing – review & editing. **Tim Rogers:** Writing – review & editing. **Maximilian Schmid:** Writing – review & editing. **Guido Seitz:** Writing – review & editing. **Olga Slater:** Writing – review & editing. **Naima Smeulders:** Writing – review & editing. **Jakob Stenman:** Writing – review & editing. **Sheila Terwisscha:** Writing – review & editing. **Cyrus Chargari:** Writing – review & editing. **Henry C Mandeville:** Conceptualization, Data curation, Formal analysis, Investigation, Methodology, Project administration, Resources, Software, Supervision, Validation, Writing – original draft, Writing – review & editing.

Declaration of competing interest

The authors declare that they have no known competing financial interests or personal relationships that could have appeared to influence the work reported in this paper.

Acknowledgments

We thank Dr. Christine Haie-Meder, dr. Helene Martelli and dr. Bradley Pieters for their invaluable contribution to the brachytherapy workshop.

Conflicts of interest

Dr. Mark N. Gaze is supported by the National Institute for Health Research University College London Hospitals Biomedical Research Centre and by the Radiation Research Unit at the Cancer Research UK City of London Centre Award [C7893/A28990].

Prof. Dr. Peter Hoskin is supported by the NIHR Manchester Biomedical Centre.

Dr. Henry C. Mandeville is supported by the National Institute for Health Research Biomedical Research Centre at The Royal Marsden NHS Foundation Trust and The Institute of Cancer Research.

Appendix A. Supplementary material

Supplementary data to this article can be found online at <https://doi.org/10.1016/j.radonc.2024.110273>.

References

- [1] Zakem SJ, Cost CR, Cost NG, Robin TP, Milgrom SA. Brachytherapy in children, adolescents, and young adults: An underutilized modality in the United States? *Pediatr Blood Cancer* 2022 Mar;69:e29412.
- [2] Howlader N, Noone AM, Krapcho M, Miller D, Brest A, Yu M, Ruhl J, Tatalovich Z, Mariotto A, Lewis DR, Chen HS, Feuer EJ, Cronin KA (eds). SEER Cancer Statistics Review, 1975-2018, National Cancer Institute. Bethesda, MD, https://seer.cancer.gov/csr/1975_2018/, based on November 2020 SEER data submission, posted to the SEER web site, April 2021. Accessed March 22, 2022.
- [3] Ward E, DeSantis C, Robbins A, Kohler B, Jemal A. Childhood and adolescent cancer statistics, 2014. *CA Cancer J Clin* 2014;64:83–103. <https://doi.org/10.3322/caac.21219>.
- [4] Gianni Bisogno MD, Veronique Minard-Colin MD, Zanetti I, Ferrari A, Gallego S, Fajardo RD, et al. Nonmetastatic rhabdomyosarcoma in children and adolescents: Overall results of the European pediatric soft tissue sarcoma study group RMS2005 study. *J Clin Oncol* 2023;41:2342–9.
- [5] Siegel R, Miller KM, Fuchs HE, Jemal A. Cancer statistics 2021. *CA Cancer J Clin* 2021;71:7–33. <https://doi.org/10.3322/caac.21654>.
- [6] Gaze MN, Smeulders N, Ackwerh R, Allen C, Bal N, Boutros M, et al. A national referral service for paediatric brachytherapy: An evolving practice and outcomes over thirteen years. *Clin Oncol (R Coll Radiol)* 2023 Apr;35:237–44.
- [7] Ellerkamp V, Schmidt A, Warmann SW, Eckert F, Schaefer J, Paulsen F, et al. Detailed functional results after bladder-preserving surgery and high-dose rate brachytherapy in pediatric bladder/prostate rhabdomyosarcoma. *J Cancer Res Clin Oncol* 2022. <https://doi.org/10.1007/s00432-022-04209-5>.
- [8] Lobo S, Gaze MN, Slater O, Hoskin P, Sands G, Sullivan T, et al. Bladder function after conservative surgery and high-dose rate brachytherapy for bladder-prostate rhabdomyosarcoma. *Pediatr Blood Cancer* 2022:e29574.
- [9] Stenman J, Wickart-Johansson G, Sundquist F, Nilsson J, Ljungman G, Österlundh G, Jalnäs M, Pal N, Mercke C. Five-Year Follow-up After Multimodal Treatment Incorporating HDR Brachytherapy for Bladder Prostate Rhabdomyosarcoma in Children. *Int J Radiat Oncol Biol Phys* 2022 Feb 1;S0360-3016:00080-3. doi: 10.1016/j.ijrobp.2022.01.034.
- [10] (a) Chargari C, Haie-Meder C, Espenel S, Garcia MA, Ben-Arush M, Bolle S, Borjesson A, Cesen M, Costa Lago R, Defachelles AS, De Moerloose B, Devalck C, Edslev P, Farinha NJ, Francotte N, Glosli H, Gouy S, Guillen Burrieza G, Helfre S, Irtan S, Kattamis A, Lacerda A, Levy A, Lyngsie Hjalgrim L, Mansuy L, Mascard E, Moalla S, Orbach D, Owens C, Philippe-Chomette P, Pizer B, Pluchart C, Renard M, Wesenberg Rognlén AG, Rome A, Sarnacki S, Safwat A, Schiavetti A, Serre J, Verite C, Von Der Weid N, Wysocki M, Valteay-Couanet D, Deutsch E, Minard-Colin V, Martelli H, Guérin F. Brachytherapy for Pediatric Patients at Gustave Roussy Cancer Campus: A Model of International Cooperation for Highly Specialized Treatments. *Int J Radiat Oncol Biol Phys* 2022;113:602-613. (b) Crook JM, Haie-Meder C, Demanes DJ, JJ Mazon, Martinez AA, Rivard MJ. American Brachytherapy Society-Groupe Européen de Curiothérapie-European Society of Therapeutic Radiation Oncology (ABS-GEC-ESTRO) consensus statement for penile brachytherapy. *Brachytherapy* 2013;12:191-198. doi.org/10.1016/j.brachy.2013.01.167.
- [11] Schmidt A, Warmann SW, Eckert F, Ellerkamp V, Schaefer J, Blumenstock G, et al. The role of reconstructive surgery and brachytherapy in pediatric bladder/prostate rhabdomyosarcoma. *J Urol* 2020;204:825–34. <https://doi.org/10.1097/JU.0000000000001127>.
- [12] Chargari C, Haie-Meder C, Guérin F, Minard-Colin V, de Lambert G, Mazon R, et al. Brachytherapy combined with surgery for conservative treatment of children with bladder neck and/or prostate rhabdomyosarcoma. *Int J Radiat Oncol Biol Phys* 2017;98:352–9. <https://doi.org/10.1016/j.ijrobp.2017.02.026>.
- [13] Fuchs J, Paulsen F, Bleif M, Lamprecht U, Weidner N, Zips D, et al. Conservative surgery with combined high dose rate brachytherapy for patients suffering from genitourinary and perianal rhabdomyosarcoma. *Radiother Oncol* 2016;121:262–7.
- [14] Blank LE, Koerooder K, Van der Grient H, et al. Brachytherapy as part of the multidisciplinary treatment of childhood rhabdomyosarcomas of the orbit. *Int J Radiat Oncol Biol Phys* 2010;77:1463–9.

- [15] Blank LE, Koerooder K, Pieters B, et al. The AMORE protocol for advanced-stage and recurrent non-orbital rhabdomyosarcoma in the head-and-neck region of children: A radiation oncology view. *Int J Radiat Oncol Biol Phys* 2009;74: 1555–62.
- [16] Magné N, Oberlin O, Martelli H, et al. Vulval and vaginal rhabdomyosarcoma in children: update and reappraisal of Institut Gustave Roussy brachytherapy experience. *Int J Radiat Oncol Biol Phys* 2008;72:878–83.
- [17] Nag S, Tippin DB. Brachytherapy for pediatric tumors. *Brachytherapy* 2003;2: 131–8.
- [18] Chargari C, Martelli H, Guérin F, Bacorro W, de Lambert G, Escande A, et al. Pulsed-dose rate brachytherapy for pediatric bladder prostate rhabdomyosarcoma: Compliance and early clinical results. *Radiother Oncol* 2017;124:285–90. <https://doi.org/10.1016/j.radonc.2017.07.010>.
- [19] FaR-RMS: An Overarching Study for Children and Adults With Frontline and Relapsed RhabdoMyoSarcoma - Full Text View - ClinicalTrials.gov.
- [20] Sarah M. Kelly, Rachel Effeneay, Mark N. Gaze, Valerie Bernier-Chastagner, Anne Blondeel, Enrico Clementel, Coreen Corning, Karin Dieckmann, Samira Essiaf, Lorenza Gandola, Geert O. Janssens, Pamela R. Kearns, Denis Lacombe, Yasmin Lassen-Ramshad, Hans Merks, Elizabeth Miles, Laetitia Padovani, Giovanni Scarzello, Rudolf Schwarz, Beate Timmermann, Rick R. van Rijn, Gilles Vassal, Tom Boterberg, Henry C. Mandeville, on behalf of the QUARTET Project and the SIOPE Radiation Oncology Working Group. QUARTET: A SIOPE Europe project for quality and excellence in radiotherapy and imaging for children and adolescents with cancer. *Eur J Cancer* 2022;172:209-220.
- [21] <https://siope.eu/activities/joint-projects/quartet/>.
- [22] Royal College of Radiologists, Society and College of Radiographers, Institute of Physics and Engineering in Medicine, Children's Cancer and Leukaemia Group. Good Practice Guide for Paediatric Radiotherapy, second edition. London, The Royal College of Radiologists, 2018. https://www.rcr.ac.uk/system/files/publication/field_publication_files/bfco182_good_pract_paed_rt_second_ed.pdf.
- [23] Vaarwerk B, Hol MLF, Schoot RA, Breunis WB, de Win MML, Westerveld H, et al. AMORE treatment as salvage treatment in children and young adults with relapsed head-neck rhabdomyosarcoma. *Radiother Oncol* 2019;131:21–6.
- [24] De Lambert G, Chargari C, Minard-Colin V, Haie-Meder C, Guérin F, Martelli H. Testicular transposition in children undergoing brachytherapy for bladder and/or prostate rhabdomyosarcoma. *J Pediatr Surg* 2018;53:1428–31.
- [25] De Lambert G, Haie-Meder C, Guérin F, Boubnova J, Martelli H. A new surgical approach of temporary ovarian transposition for children undergoing brachytherapy: Technical assessment and dose evaluation. *J Pediatr Surg* 2014 Jul; 49:1177–80.
- [26] Nicolas Magné 1, Christine Haie-Meder. Brachytherapy for genital-tract rhabdomyosarcomas in girls: technical aspects, reports, and perspectives. *Lancet Oncol*. 2007;8:725-9.
- [27] Magné N, Chargari C, SanFilippo N, Messai T, Gerbaulet A, Haie-Meder C. Technical aspects and perspectives of the vaginal mold applicator for brachytherapy of gynecologic malignancies. *Brachytherapy* 2010;9:274–7.
- [28] Haie-Méder C, Potter R, Van Limbergen E, Briota E, De Brabandere M, Dimopoulos J, et al. Recommendations from gynaecological (GYN) GEC-ESTRO working group* (I): concepts and terms in 3D image based 3D treatment planning in cervix cancer brachytherapy with emphasis on MRI assessment of GTV and CTV. *Radiother Oncol* 2005;74:235–45. <https://doi.org/10.1016/j.radonc.2004.12.015>.
- [29] Terlizzi M, Minard V, Haie-Meder C, Espenel S, Martelli H, Guérin F, et al. Implementation of image-guided brachytherapy for pediatric vaginal cancers: Feasibility and early clinical results. *Cancers (Basel)* 2022 Jul 1;14:3247.
- [30] Pierquin B, Dutreix A, Paine CH, Chassagne D, Marinello G, Ash D. The Paris system in interstitial radiation therapy. *Acta Radiol Oncol Radiat Phys Biol* 1978; 17:33–48.
- [31] Timothy Rogers, Ilaria Zanetti, Beatrice Coppadoro, Hélène Martelli, Meriel Jenney, Veronique Minard-Colin, Sheila E. J. Terwisscha van Scheltinga, Clare Skerriitt, Raquel Dávila Fajardo, Florent Guérin, Anna Kelsey, Johannes H. M. Merks, Henry Mandeville, Gabriela Guillén, Heidi Glosli, Federica De Corti, Gianni Bisogno. Perianal/perineal rhabdomyosarcoma: Results of the SIOPE MMT 95, Italian RMS 96, and EPOSS RMS 2005 studies. *Pediatr Blood Cancer* 2022;69: e29739.
- [32] Nag SMD, Tippin DMD, Ph D, Ruymann FBMD. Long-term morbidity in children treated with fractionated high-dose-rate brachytherapy for soft tissue sarcomas. *J Pediatr Hematol Oncol* 2003;25:448–52.
- [33] Abramson DH, Fass D, McCormick B, Servodidio CA, Piro JD, Anderson LL. Implant brachytherapy: A novel treatment for recurrent orbital rhabdomyosarcoma. *J AAPOS* 1997;1:154–7.
- [34] Rainer Joachim Strege 1, György Kovács, Jens Eduard Meyer, Detlef Holland, Alexander Claviez, Maximilian H Mehdorn; Interdisciplinary Group of Orbitazentrum UK S-H. Perioperative intensity-modulated brachytherapy for refractory orbital rhabdomyosarcomas in children. *Strahlenther Onkol*. 2009 Dec; 185:789-98.
- [35] J Buwalda 1, P F Schouwenburg, L E C M Blank, J H M Merks, M P Copper, S D Strackee, P A Voûte, H N Caron. A novel local treatment strategy for advanced stage head and neck rhabdomyosarcomas in children: results of the AMORE protocol. *Eur J Cancer*. 2003 Jul;39:1594-602. doi: 10.1016/s0959-8049(03) 00363-0.
- [36] Renaud Mazon 1, Odile Oberlin, Isabelle Dumas, Frédéric Kolb, Jennifer Goulart, Eleonor Rivin, Christine Haie-Méder. Brachytherapy in children with rhabdomyosarcomas of the nasolabial fold. *Pediatr Blood Cancer*. 2014 Jul;61: 1162-7.
- [37] Goodman KA, Wolden SL, LaQuaglia MP, Alektiar K, D'Souza D, Zelefsky MJ. Intraoperative high-dose-rate brachytherapy for pediatric solid tumors: a 10-year experience. *Brachytherapy* 2003;2:139–46.
- [38] Lautz TB, Martelli H, Fuchs J, Chargari C, Smeulders N, Granberg CF, Wolden SL, Sparber-Sauer M, Hawkins DS, Bisogno G, Koscielniak E, Rodeberg DA, Seitz G; INSTRuCT group. Local treatment of rhabdomyosarcoma of the female genital tract: Expert consensus from the Children's Oncology Group, the European Soft-Tissue Sarcoma Group, and the Cooperative Weichteilsarkom Studiengruppe. *Pediatr Blood Cancer*. 2023;70:e28601.
- [39] Martelli H, Borrego P, Guérin F, Boubnova J, Minard-Colin V, Dumas I, et al. Quality of life and functional outcome of male patients with bladder-prostate rhabdomyosarcoma treated with conservative surgery and brachytherapy during childhood. *Brachytherapy* 2016;15:306–11.
- [40] Campbell SR, Shah C, Scot JG, Mesko N, Nystrom L, Kolar M, et al. American brachytherapy society (ABS) consensus statement for soft-tissue sarcoma brachytherapy. *Brachytherapy* 2021;20:1200–18. <https://doi.org/10.1016/j.brachy.2021.05.011>.
- [41] Naghavi AO, Fernandez DC, Mesko N, Juloori A, Scott JG, Shah C, Harrison LB. American Brachytherapy Society consensus statement for soft tissue sarcoma brachytherapy. *Brachytherapy* 2001;7:466-489. doi.org/10.1016/j.brachy.2017.02.004.
- [42] Holloway CL, DeLaney TF, Alektiar KM, Devlin PM, O'Farrell DA, Demanes DJ. American Brachytherapy Society (ABS) consensus statement for sarcoma brachytherapy. *Brachytherapy* 2013;12:179-190. dx.doi.org/10.1016/j.brachy.2012.12.002.
- [43] Nag S, Shasha D, Janjan N, Petersen I, Zaider M. The American brachytherapy society recommendations for brachytherapy of soft tissue sarcomas. *Int J Radiat Oncol Biol Phys* 2001;49:1033–43. [https://doi.org/10.1016/S0360-3016\(00\) 01534-0](https://doi.org/10.1016/S0360-3016(00) 01534-0).
- [44] Schmid MP, Fokdal L, Westerveld H, Chargari C, Rohl L, Morice P, et al. Recommendations from gynaecological (GYN) GEC-ESTRO working group – ACROP: Target concept for image guided adaptive brachytherapy in primary vaginal cancer. *Radiother Oncol* 2020;145:36–44. <https://doi.org/10.1016/j.radonc.2019.11.005>.
- [45] Hoskin PJ, Colombo A, Henry A, Nihoff P, Paulsen Hellebust T, Siebert FA, Kovac G. GEC/ESTRO recommendations on high dose rate afterloading brachytherapy for localised prostate cancer: An update. *Radiotherapy and Oncology* 2013;107:325-332. dx.doi.org/10.1016/j.radonc.2013.05.002.
- [46] Juanita M Crook 1, Christine Haie-Meder, D Jeffrey Demanes, Jean-Jacques Mazon, Alvaro A Martinez, Mark J Rivard. American Brachytherapy Society- Groupe Européen de Curiethérapie-European Society of Therapeutic Radiation Oncology (ABS-GEC-ESTRO) consensus statement for penile brachytherapy. *Brachytherapy*. 2013 May-Jun;12(3):191-8. doi: 10.1016/j.brachy.2013.01.167.
- [47] Beriwal S, Demanes DJ, Erickson B, Jones E, De los Snatos JF, Cormack RA, Yashar C, Rownd JJ, Viswanathan AN. American Brachytherapy Society consensus guidelines for interstitial brachytherapy for vaginal cancer. *Brachytherapy* 2012;11 (1):68-75. doi.org/10.1016/j.brachy.2011.06.008.
- [48] Mazon J, Ardiet JM, Haie-Méder C, Kovacs G, Levendag P, Peiffert D, et al. GEC-ESTRO recommendations for brachytherapy for head and neck squamous cell carcinomas. *Radiother Oncol* 2009;91:150–6. <https://doi.org/10.1016/j.radonc.2009.01.005>.
- [49] Potter R, Haie-Méder C, Van Limbergen E, Barillot I, De Brabandere M, Dimopoulos J, et al. Recommendations from gynaecological (GYN) GEC ESTRO working group (II): Concepts and terms in 3D image-based treatment planning in cervix cancer brachytherapy—3D dose volume parameters and aspects of 3D image-based anatomy, radiation physics, radiobiology. *Radiother Oncol* 2006;78: 67–77. <https://doi.org/10.1016/j.radonc.2005.11.014>.