

Clinical benefits and potential risks of adalimumab in non-JIA chronic paediatric uveitis

Carlyn V. Kouwenberg,  Viera Koopman-Kalinina Ayuso and Joke H. de Boer

Department of Ophthalmology, University Medical Centre Utrecht, Utrecht, The Netherlands

ABSTRACT.

Purpose: To describe the treatment results with adalimumab in chronic paediatric uveitis, not associated with juvenile idiopathic arthritis (JIA).

Methods: Medical records of children with non-JIA-uveitis were reviewed retrospectively. Children without an underlying systemic disease were pre-screened with brain magnetic resonance imaging (MRI) to exclude white matter abnormalities/demyelination.

Results: Twenty-six patients were pre-screened with brain MRI, of whom adalimumab was contraindicated in six patients (23%) with non-anterior uveitis. Forty-three patients (81 eyes) were included. Disease inactivity was achieved in 91% of the patients after a median of three months (3–33). Best-corrected visual acuity (BCVA) improved from 0.16 ± 0.55 logarithm of the minimum angle of resolution (logMAR) at baseline to 0.05 ± 0.19 logMAR at 24 months ($p = 0.015$). The median dosage of systemic corticosteroids was reduced to 0 mg/day at 24 months of follow-up (versus 10 mg/day at baseline; $p < 0.001$). Adalimumab was discontinued in thirteen children due to ineffectiveness ($n = 8$), side effects ($n = 1$), long-term inactivity of uveitis ($n = 3$) or own initiative ($n = 1$). Relapse of uveitis occurred in 19 (49%) patients, 5 (26%) of them without an identifiable cause.

Conclusion: Adalimumab is effective in the treatment of non-JIA-uveitis in paediatric patients by achieving disease inactivity in the majority of the patients, improving BCVA and decreasing the dose of corticosteroids. Adverse events and side effects are limited. Pre-screening with MRI of the brain is recommended in paediatric patients with intermediate and panuveitis.

Key words: adalimumab – anti-TNF alpha – biologicals – treatment – magnetic resonance imaging – paediatric uveitis – visual acuity

Acta Ophthalmol. 2022; 100: e994–e1001

© 2021 The Authors. Acta Ophthalmologica published by John Wiley & Sons Ltd on behalf of Acta Ophthalmologica Scandinavica Foundation

This is an open access article under the terms of the Creative Commons Attribution-NonCommercial-NoDerivs License, which permits use and distribution in any medium, provided the original work is properly cited, the use is non-commercial and no modifications or adaptations are made.

doi: 10.1111/aos.15012

Introduction

Paediatric uveitis is a severe inflammatory eye disease, which can lead to visual loss in one-third of the patients, and eventually to permanent blindness (Cunningham 2000). The pathophysiology of non-infectious uveitis still

remains mostly unknown. Uveitis in childhood can be related to systemic conditions of which juvenile idiopathic arthritis (JIA) is by far the most common and well-studied (Angeles-Han et al. 2013; Moradi et al. 2014; Siiskonen et al. 2021). It is considered to be a multifactorial autoimmune

disorder with various (epi)genetic predisposing factors and involvement of pro-inflammatory cytokines such as tumour necrosis factor α (TNF α) (Lee & Dick 2012; Cordero-Coma & Sobrin 2015).

The goals of treatment in paediatric uveitis are to preserve vision and prevent ocular complications, by controlling the inflammation and achieving a stable remission as early as possible (Sood & Angeles-Han 2017). Corticosteroids are traditionally used as first-line treatment. However, they can lead to severe ocular side effects such as cataracts and glaucoma and have potential severe risks for the general child's health (Simonini et al. 2010; Sood & Angeles-Han 2017). Therefore, switching to systemic immunomodulatory therapy (IMT) in the early course of uveitis is the state of the art nowadays (Simonini et al. 2010; Sood & Angeles-Han 2017).

Adalimumab, a recombinant human anti-TNF α monoclonal antibody, has shown to be an effective and safe therapeutic in JIA-uveitis regarding the control of inflammation, improvement of visual acuity and reducing glucocorticoid use (Ramanan et al. 2017; Sood & Angeles-Han 2017; Horton et al. 2019). Despite the efficacy of adalimumab in treating uveitis, precautions are needed, since there is upcoming evidence suggesting an association between TNF α blocking agents and demyelination of the nervous system (Kemanetzoglou & Andreadou 2017; Olsen & Frederiksen 2017; Suhler et al. 2018; Cunha et al. 2020). Intermediate uveitis has been in 7–10% associated with multiple sclerosis but also patients with a history of optic neuritis or

papillitis could be at increased risk (Cunningham et al. 2017). Although less common than in intermediate uveitis, children with other types of uveitis may have pre-existent and asymptomatic white matter abnormalities and/or demyelination as well, which could potentially progress under anti-TNF α treatment (Olsen & Frederiksen 2017).

Studies involving clinical efficacy of adalimumab in non-JIA paediatric uveitis are scarce (Jaffe et al. 2016; Nguyen et al. 2016; Leal et al. 2019). Currently, adalimumab is used off-label in Europe in paediatric patients with intermediate, posterior and panuveitis. Therefore, the objective of this study is to investigate retrospectively the efficacy and potential risks of treatment with adalimumab in chronic paediatric non-JIA-uveitis.

Methods

Patient identification

The medical records from the department of ophthalmology, University Medical Centre Utrecht, the Netherlands, were reviewed to identify all patients with paediatric uveitis. Patients and/or their parents/caretakers were asked to give informed consent to review their medical records. The study adhered to the tenets of the Declaration of Helsinki and was conducted after ethical approval for data collection by the Medical Ethical Committee Utrecht (protocol number: 18-751/C).

Patients eligible for treatment with adalimumab were diagnosed with refractory non-JIA-uveitis and/or if the necessary dosage of IMT and/or oral corticosteroids was leading to complications. Uveitis was defined as refractory when patients did not achieve a 2-step decrease in the level of inflammation in the anterior chamber and/or vitreous humour, despite the use of systemic IMT and/or corticosteroids within at least six months. The reasons for starting adalimumab did not change significantly over the period of the study.

Before starting the additional treatment with adalimumab, to exclude associated systemic disease, children were screened with magnetic resonance imaging (MRI) of the brain or where indicated with visual evoked potential (VEP) to exclude the risk of

demyelinating disease (Kemanetzoğlu & Andreadou 2017). The children were also screened for tuberculosis and hepatitis.

Inclusion criteria were as follows: treatment with adalimumab (Humira®; AbbVie Inc., Ludwigshafen, Germany), diagnosis of non-JIA-uveitis, onset of uveitis before 16 years of age and a minimum follow-up of six months. The patients had been treated between January 2008 and March 2020. Diagnosis and treatment of uveitis were performed by an ophthalmologist specialized in paediatric uveitis and a paediatric immunologist according to the National Guidelines Uveitis. The diagnostic criteria for uveitis were defined according to the Standardization of Uveitis Nomenclature (SUN) criteria (Jabs et al. 2005).

Participants received adalimumab at a dose of 20 mg in patients weighing <30 kg, or 40 mg in patients weighing \geq 30 kg, administered as a subcutaneous injection every two weeks. The dose and the interval could in some cases be adjusted according to the level of disease activity.

Data collection

Data were retrieved retrospectively from visits at our outpatient ophthalmology clinic at standard time intervals before start of adalimumab (baseline), 3, 6, 9, 12 months, and then yearly after starting adalimumab.

Data extracted from the electronic patient files included as follows: demographics, uveitis characteristics, underlying systemic disease, date of adalimumab start, use of other medication, side effects and complications. The following side effects and complications were registered as follows: cataract requiring surgery, secondary glaucoma, cystoid macular oedema (CME), papillitis, strabismus, amblyopia and abnormal laboratory results (liver enzymes, kidney function, haemoglobin and leucocytes). Secondary glaucoma was defined as glaucomatous visual field defect in combination with intraocular pressure (IOP) higher than 21 mmHg, and glaucomatous cupping of the optic nerve or progressive thinning of the ganglion cell layer and retinal nerve fibre layer (RNFL) on optical coherence tomography (OCT) (Society EG 2014). CME was defined as the presence of macular thickening

with cyst formation observed by OCT or late phase leakage on fluorescein angiography (FA) scored according to the Angiography Scoring for Uveitis Working Group (ASUWOG) (Tugal-Tutkun et al. 2010). Papillitis was defined as blurring of the optic disc margins and/or as optic disc hyperfluorescence on FA scored according to the ASUWOG criteria. Anti-adalimumab antibodies were measured on indication, when patients did not achieve a 2-step decrease in the level of inflammation as according to the SUN criteria, or when the physician had doubts about the therapy compliance of the patient (Jabs et al. 2005). This policy did not change significantly over the period of the study.

Main outcome measures

The primary endpoint was the proportion of patients with disease inactivity or improvement from baseline for a minimum period of three months and with no development or worsening of any new ocular complications. Disease inactivity and improvement were defined according to the SUN criteria (Jabs et al. 2005). Disease inactivity was defined as anterior chamber cell count of <1+ cells in anterior uveitis and panuveitis, and <1+ cells in the vitreous humour in intermediate, posterior and panuveitis in absence of papillitis, CME and/or vasculitis. Disease improvement was defined as two grade decrease in the anterior chamber and/or vitreous cavity.

Secondary endpoints were as follows: time to inactivity of uveitis, improvement of visual acuity with two Snellen lines, taper of topical or systemic corticosteroids, time to first uveitis relapse on adalimumab therapy (excluding activity of uveitis up to three months after an eye surgery), improvement of CME on FA and/or OCT by 20% and total decrease of FA score with \geq 25% (Tugal-Tutkun et al. 2010).

Statistical analysis

Descriptive statistics were used to report demographic and clinical features of the patients. The McNemar test was used to analyse linked dichotomous variables. Wilcoxon's test for paired samples was used to analyse means of abnormally distributed linked samples. Cox proportional hazard

(PH) regression was used to identify factors associated with outcomes. The PH assumption was verified visually by examining the hazard plots and statistically by including the interaction between the logarithm of time and the covariate of interest in a univariate model. The PH assumption was considered suspect if the interaction between time and covariate of interest was significant at the 0.1 level. Variables that changed over time were evaluated as time-updated variables. Correction for analysis of paired eyes was performed using generalized estimating equations (GEE). The p-values of less than 0.05 were considered statistically significant. All significances are two-tailed. All statistical analyses were performed with SPSS 25 (SPSS Inc., Chicago, Illinois, USA).

Results

Fifty children with non-JIA-uveitis were eligible for treatment with adalimumab. Twenty-six children were screened before treatment with MRI of the brain, of whom seven (27%) children were diagnosed with anterior uveitis, seven (27%) with intermediate uveitis and twelve (46%) with panuveitis. Adalimumab was relatively contraindicated in six of them (23%) based on pre-existing white matter abnormalities of the brain, and in one patient based on an abnormal VEP (2%) (Fig. 1). Five patients with pre-existing white matter abnormalities of the brain had panuveitis and one patient had intermediate uveitis. Papillitis was seen in five of the six patients with abnormalities on MRI. For subsequent analyses, we included 43 children (81 affected eyes) with non-JIA-uveitis who started additional treatment with adalimumab and had a minimum follow-up of six months.

Characteristics of children before treatment of adalimumab

Table 1 summarizes the general patient characteristics before additional treatment with adalimumab (baseline). Fifteen (35%) of the patients treated with adalimumab were diagnosed with anterior uveitis and 28 children (65%) with non-anterior uveitis. Median age at baseline was eleven years (range 4-17 years). Median duration of uveitis at baseline was two years (range 0-9 years). Topical

corticosteroids were used in 91% of the children ($n = 70$ affected eyes of 39 children), of whom 44% ($n = 17$) used topical corticosteroids >3 drops daily. Thirty-one children (72%) were treated with systemic corticosteroids. Forty-one children had active uveitis at baseline. In the other two patients, adalimumab was initiated to reduce the high dosage of topical and systemic corticosteroids, which was needed to maintain disease inactivity.

Table 2 shows the clinical disease activity at baseline. Active inflammation in the anterior chamber was present in 27% ($n = 22$) of the affected eyes, in the vitreous humour in 19% ($n = 15$) of the affected eyes, and both in the anterior chamber and the vitreous humour in 26% ($n = 21$) of the affected eyes. Twenty-eight per cent of the affected eyes ($n = 23$) had no active inflammation in both the anterior chamber and the vitreous humour at baseline.

Ocular secondary complications of uveitis present before adalimumab treatment included cataract requiring surgery ($n = 17$ patients), papillitis ($n = 13$), ocular hypertension ($n = 13$), cystoid macular oedema ($n = 11$), glaucoma ($n = 4$) and amblyopia ($n = 1$).

Primary and secondary outcomes

Median duration of study follow-up was 2.5 years (range 0.5-11.3 years). Disease inactivity of uveitis was achieved in 91% of the patients after a median of three months (range 3-33)

of treatment, $p < 0.001$ (Fig. 2). The median dosage of systemic corticosteroids reduced from 10 mg/day at baseline (range 0-60 mg/day), to 5 mg/day at three months (range 0-20 mg/day) ($p < 0.001$), and to 0 mg/day at 24 months (range 0-15 mg/day) ($p < 0.001$) (Fig. 2). Best-corrected visual acuity (BCVA) improved from 0.16 ± 0.55 logarithm of the minimum angle of resolution (logMAR) at baseline to 0.08 ± 0.26 logMAR at 9 months ($p < 0.001$), and to 0.05 ± 0.019 logMAR at 24 months ($p < 0.05$) of follow-up (Table 2). Within the first year of adalimumab use, 35% of the patients ($n = 15$) had an improvement of visual acuity with two Snellen lines in at least one eye. An OCT scan was performed in 63 of the 81 affected eyes (78%) before the start of adalimumab. Fifteen of the scanned eyes had CME with an increased CMT on OCT. An improvement of $\geq 20\%$ CMT reduction on OCT occurred in 53% of the eyes with CME ($n = 8$). Six eyes showed this reduction in the first three months. Thirty-one patients (72%) had undergone a FA in the first year after the start of adalimumab therapy, of which eight children had undergone a FA in the second year. In seven of these patients (88%), an improvement of $\geq 25\%$ of the FA score in the second year of follow-up was achieved. After 24 months the median FA score was improved significantly to 2.0 compared to baseline of 13.5 ($p < 0.001$).

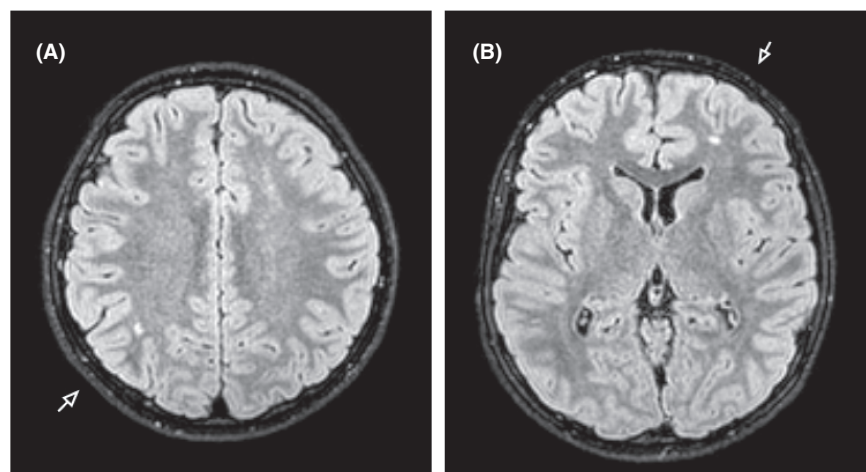


Fig. 1. The brain MRI of a 13-year-old boy with paediatric panuveitis is shown. A, Axial FLAIR MRI with the arrows showing white matter abnormalities localized right parietal, and B, left frontal. These focal white matter abnormalities could be based on small focal areas of demyelination. Based on these white matter abnormalities, the patients deemed ineligible for treatment with adalimumab.

Table 1. General baseline characteristics of children with idiopathic uveitis at the time adalimumab was started.

Pre-screening	Data, <i>n</i> = 50
White matter abnormalities on MRI of the brain, <i>n</i> (%)	6/26 (23.1)
Abnormal VEP, <i>n</i>	1
Tuberculosis, <i>n</i>	NA
Hepatitis, <i>n</i>	NA
Demographics	Data, <i>n</i> = 43
Bilateral disease, <i>n</i> (%)	38 (88.4)
Female gender, <i>n</i> (%)	29 (67.4)
Anatomic type of uveitis, <i>n</i> (%)	
Anterior uveitis	15 (34.9)
Intermediate uveitis	8 (18.6)
Posterior uveitis	NA
Panuveitis	20 (46.5)
Systemic diagnosis, <i>n</i> (%)	
Presumed TINU syndrome	4 (9.3)
Blau-syndrome	3 (6.7)
Other (Hashimoto, VKH disease)	2 (4.7)
Age in years	
At onset uveitis, median (range)	8.0 (3–15)
At start adalimumab, median (range)	11.0 (4–17)
Duration of uveitis at start of adalimumab, median (range)	2.0 (0–9)
Medication	
Topical steroids > 3 drops daily, <i>n</i> (%)	17 (39.5)
Systemic corticosteroids, <i>n</i> (%)	31 (72.1)
IMT, <i>n</i> (%)	
Non	1 (2.3)
MTX	21 (48.8)
MMF	17 (39.5)
Mycophenolic acid	2 (4.7)
MTX + MMF	2 (4.7)

IMT = Immunomodulatory therapy; MRI = magnetic resonance imaging; MTX = methotrexate; MMF = mycophenolate mofetil; NA = not applicable; TINU = Tubulointerstitial nephritis and uveitis; VEP = visual evoked potential; VKH = Vogt-Koyanagai-Harada.

Relapse of uveitis

Relapse of uveitis occurred in 19 (49%) of the 39 patients who achieved disease inactivity, after a median of 14 months (range 3–40 months). In 13 patients (68%), a relapse occurred within 12 months of disease remission, and in six patients (32%) after 12 months. Fourteen patients (74%) had an identifiable cause of relapse: dose reduction or discontinuation of medication (*n* = 7), lack of therapy compliance (*n* = 6) or anti-adalimumab antibodies (*n* = 1). In the group without an identifiable cause of relapse, the median duration of adalimumab controlled remission until the relapse was 5.5 months (range 3–16 months).

Comorbidities and complications

Comorbidities and complications whether or not related to treatment with adalimumab during follow-up were infections (*n* = 3): scarlet fever,

pharyngitis and influenza, causing a short interruption in the use of adalimumab for a maximum of two doses, not leading to hospitalization. During follow-up, no laboratory abnormalities that could be related to adalimumab were identified. Seven patients (16%) had elevated liver enzymes up to two times the normal value. In all six patients (14%) who underwent cataract surgery during adalimumab therapy, the cataract was already present before adalimumab treatment. Two patients were diagnosed with secondary glaucoma.

Adalimumab was discontinued in thirteen children (30%) due to ineffectiveness (*n* = 8, after 8–105 months, of whom one patient had positive anti-adalimumab antibodies), long-term disease inactivity (*n* = 3, after 31–44 months), side effects (urgency-incontinence) (*n* = 1, after 4 months) or own initiative (*n* = 1, after 75 months). The dose of adalimumab

was adjusted to weekly administration in eleven children (26%), of whom six discontinued adalimumab due to ineffectiveness (*n* = 5) or own initiative (*n* = 1). Relapse of uveitis occurred after a median of eight months (range 7–9 months) in all three patients who discontinued adalimumab due to long-term disease inactivity. Two of them used methotrexate, with one child also using topical corticosteroids. One child used no additional medication.

Regression analysis

Univariate analysis of predictive factors for inactivity of uveitis during adalimumab treatment showed that boys achieved disease inactivity faster with a hazard ratio (HR) of 3.34 (95% CI 1.54–7.27, *p* = 0.002). This was not the case for the anatomic classification of uveitis, age, and type of IMT used. Multivariate analysis confirms these results, with male gender being independently associated with a faster achievement of disease inactivity (HR 3.12, 95% CI 1.39–6.99, *p* = 0.006) (Fig. 3; Supplemental information).

Discussion

This retrospective cohort study focusses on the additional treatment with adalimumab used off-label in paediatric uveitis not associated with JIA. We demonstrate that treatment with adalimumab led to prompt inactivity of uveitis in the vast majority of the children (91%). Until now, the effectiveness of adalimumab was only shown for paediatric uveitis associated with JIA (SYCAMORE trial), adults with JIA-uveitis (ADJUVITE trial) or for non-infectious uveitis in adults (VISUAL III trial) (Ramanan et al. 2017; Quartier et al. 2018; Suhler et al. 2018). These trials showed a treatment response of 56–73% in the participants of the adalimumab group (Ramanan et al. 2017; Quartier et al. 2018; Suhler et al. 2018). Two systematic reviews reported a pooled response rate of 87% (95% CI 75–98%) in chronic paediatric uveitis with mostly JIA (Simonini et al. 2014; Ming et al. 2018). Although these studies include patients with different types of uveitis or adults, the results are in accordance with our findings. We also found that 20 patients achieved inactivity without the occurrence of a relapse during the variable follow-up.

Table 2. Ocular characteristics before treatment of adalimumab (baseline), after 6 and 24 months of follow-up, *n* = 81 eyes.

Ocular characteristics	Baseline	6 months	p-values	24 months	p-values
Best-corrected visual acuity (logMAR score)					
Mean (SD) ^a	0.16 (0.55)	0.08 (0.24)	0.092	0.05 (0.19)	0.015
Clinical disease activity, <i>n/N</i> (%)					
Anterior chamber cells $\geq 1+$ ^b	44/81 (54.3)	7/79 (8.9)	<0.001	10/58 (17.2)	<0.001
Flare score $\geq 1+$ ^b	14/22 (63.6)	9/30 (30.0)	1.000	5/29 (17.2)	0.250
Vitreous haze score $\geq 1+$ ^b	11/24 (45.8)	2/14 (14.3)	0.688	3/21 (14.3)	1.000
Vitreous humour cells $\geq 1+$ ^b	36/63 (57.1)	14/60 (23.3)	0.001	6/46 (13.0)	<0.001
Cystoid macular oedema (active inflammation) ^b	15/81 (18.5)	6/79 (7.6)	0.004	2/58 (3.4)	0.013
Papillitis ^b	24/81 (29.6)	12/79 (15.2)	0.001	2/58 (3.4)	0.001
Fluorescein angiography score, median (range) ^a	13.5 (1–23)	5.0 (0–15)	0.258	2.0 (0–19)	0.001
Newly diagnosed Comorbidities/Complications, <i>n/N</i> (%)					
Amblyopia	2/81 (2.5)	NA		NA	
Glaucoma	5/81 (6.2)	NA		1/53 (1.9)	
Ocular hypertension	19/81 (23.5)	NA		NA	
Cataract surgery	24/81 (29.6)	2/56 (3.6)		NA	
Topical steroid drops					
Eyes on > 3 drops topical steroids daily, <i>n/N</i> * (%) ^a	27/81 (33.3)	14/75 (18.7)	0.004	4/58 (6.9)	<0.001
Dosage of topical steroids daily, median drops (range) ^a	2 (0–6.5)	1 (0–4.5)	<0.001	0.6 (0–4.5)	<0.001

NA = not applicable; SD = standard deviation.

Boldface indicate that *p* < 0.05. All *p*-values are compared with the moment of start of adalimumab. Anterior chamber activity, flare score, vitreous cell activity, and vitreous haze is scored according to the recommendations of SUN working group (Jabs et al. 2005).

^a *p*-values computed with Wilcoxon's Signed-Ranks Test.

^b *p*-values computed with McNemar's Test.

This suggests that within 6 to 24 months of follow-up 50% of those achieving an early response will maintain a persistent state of inactivity. Long-term follow-up of these patients is rarely reported, but the rates of steroid reduction over two years in this study suggests that weaning of treatment in a significant number of patients is possible.

A growing number of studies describe central and peripheral nervous system demyelinating events during the use of TNF α inhibitors, suggesting a possible relation between the use of anti-TNF α agents and demyelination (Scheinfeld 2005; Zhu et al. 2016; Kemanetzoglou & Andreadou 2017; Suhler et al. 2018; Cunha et al. 2020). The literature regarding pre-screening with brain MRI is ambiguous as there are no clear guidelines (Ali & Laughlin 2017; Kemanetzoglou & Andreadou 2017). We performed our pre-screening with MRI of the brain in children without an underlying systemic disease and detected white matter abnormalities in twenty-three per cent of them. Although no diagnosis of MS

or other central nervous system condition could be made, we did not take the risk of treating these patients with adalimumab as nowadays other therapeutic options for refractory uveitis without this risk of demyelination emerge, like IL-6 inhibitors (i.e. tocilizumab) (Wennink et al. 2020). Interestingly, only one of our patients with abnormalities on MRI had intermediate uveitis, which is the most reported presentation of uveitis in relation to multiple sclerosis and white matter abnormalities on brain MRI (Cunningham et al. 2017; Olsen & Frederiksen 2017). The other five children were diagnosed with panuveitis, which emphasizes the need for the awareness of this potential risk by the treating physicians also in other forms of uveitis. Remarkable is that five of the six patients with abnormalities on MRI were diagnosed with papillitis. This possible association should be investigated in the future research. Initially, normal brain MRI was repeated in four patients during adalimumab treatment and showed no signs of demyelination. Also, no clinical signs of

demyelinating events were observed during treatment. Based on our results, we recommend screening with MRI of the brain before the start of adalimumab in case of intermediate or panuveitis.

To preserve vision in paediatric uveitis, it is crucial to achieve disease inactivity as fast as possible with limited use of topical and systemic corticosteroids and to prevent the development of secondary vision-threatening complications of uveitis. One of these complications is cataract, which is increasing more rapidly when topical corticosteroids are dosed at >3 drops daily (Thorne et al. 2010). In our study, we observed a relatively quick reduction in the use of topical corticosteroids during adalimumab treatment, reaching statistical significance after nine months of therapy. Equally important, we observed an impressive reduction of systemic corticosteroids during adalimumab treatment that reached statistical significance after six months. Chronic use of systemic corticosteroids involves serious health care risks in paediatric patients, such as ocular hypertension, Cushing's syndrome, hyperglycaemia, osteoporosis and growth retardation (Simonini et al. 2010; Sood & Angeles-Han 2017). Prior to the use of adalimumab, at least three children had clinical signs of Cushing's syndrome, and one child developed osteoporosis due to long-term use of systemic corticosteroids. Therefore, it is essential that the (long-term) use of systemic corticosteroids is minimized.

Although a good effectivity of adalimumab in reaching remission is being shown in our and other studies, a relapse of uveitis still occurs in a significant number of the patients (Jaffe et al. 2016; Ramanan et al. 2017; Suhler et al. 2018; Horton et al. 2019; Al-Janabi et al. 2020). In our study, uveitis flared up in five of the children (13%) without an identifiable cause during adalimumab treatment and in 14 (33%) with an identifiable cause. Drug immunogenicity is one of the few described risk factors linked to the failure of anti-TNF α treatment in non-infectious uveitis (Skrabl-Baumgartner et al. 2019). Hence, anti-adalimumab antibodies could play a role in the occurrence of uveitis relapse. In our study, three patients had developed anti-adalimumab antibodies resulting in discontinuation of the drug

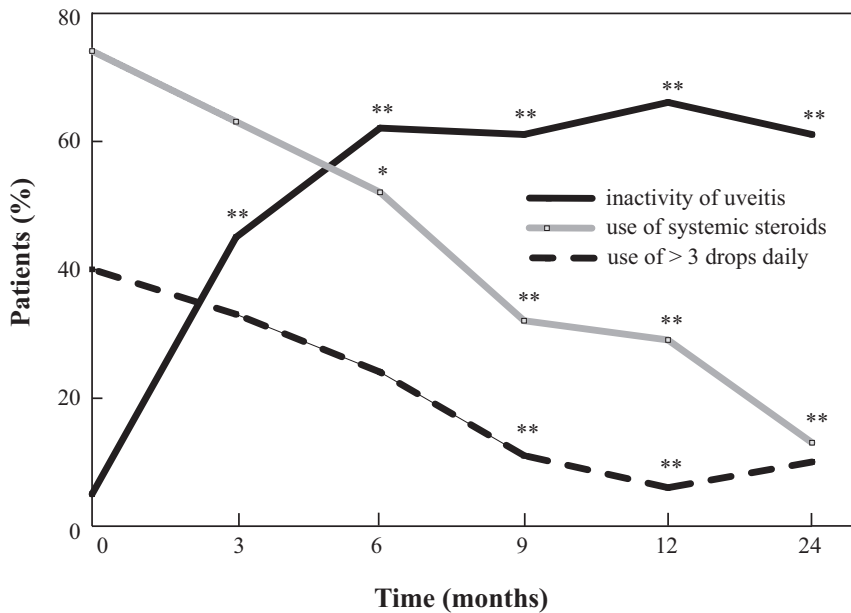


Fig. 2. Percentage of patients with inactivity of uveitis, the use of systemic corticosteroids and the use of topical corticosteroids dosed at more than three drops daily during the treatment with adalimumab. N = 43 children with idiopathic paediatric uveitis. P-values computed with McNemar Test. * p < 0.05, ** p < 0.01.

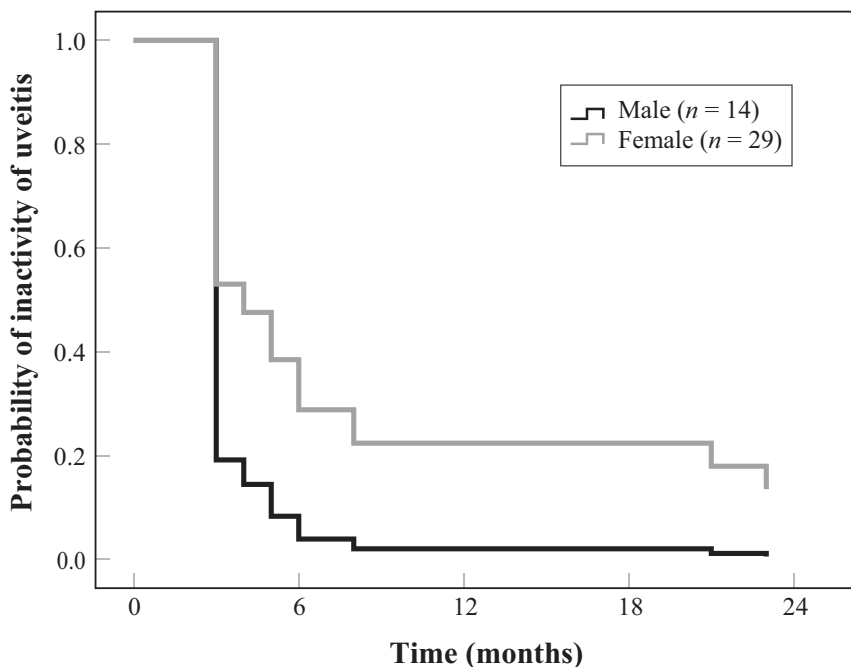


Fig. 3. Graph showing the probability of disease inactivity of uveitis as a function of gender after initiation of treatment with adalimumab. N = 43 children with idiopathic paediatric uveitis. P-value < 0.01.

in one patient. Two of these patients had chronic anterior uveitis (one had ANA positive serology), and one was diagnosed with panuveitis (ANA negative). Antibodies were found in 16-26% of the patients in studies with JIA patients. Results of a Finnish study shows that anti-adalimumab antibody

levels of ≥ 12 AU/ml were associated with a higher grade of activity of uveitis, a higher failure to reach disease remission and a lack of concomitant methotrexate therapy in JIA-associated patients (Wang et al. 2013; Skrabl-Baumgartner et al. 2015; Leinonen et al. 2017). Unfortunately, data

regarding non-JIA-uveitis are unknown. Our clinical experience is that after increasing the frequency from every other week to weekly, the antibodies can disappear and a control of inflammation can be attained. In some cases, it is possible to set the frequency later on back to every other week. In practice, when regarding treatment failure or its in-effectivity, serum anti-adalimumab antibodies can be analysed together with the serum blood level of adalimumab.

Our study found a positive association between male gender and time to achieve disease inactivity of uveitis. To our knowledge this positive finding is not described in literature before, whilst there is upcoming evidence that there are gender differences in uveitis in children for example in the risk of uveitis and in the severity of the inflammation (Ayuso et al. 2010; Kalinina Ayuso et al. 2010; Yeung, Popp & Chan 2015; Haasnoot et al. 2018).

Recent studies show that increasing adalimumab administration to weekly in patients with inadequate inflammatory control on every other week, is a reasonable treatment option (Correll et al. 2018; Lee et al. 2020; Liberman et al. 2020). We do suggest to consider weekly administration of adalimumab when there is no improvement in disease activity or in the case of the presence of anti-adalimumab antibodies. An increase to weekly administration took place in one-fourth of our patients. Disease inactivity was reached in fifty per cent of these children with weekly administration of adalimumab. Treatment of these anti-TNF α resistant patients can be challenging. Recent literature suggests switching to another type of anti-TNF α , tocilizumab, or other more experimental agents in paediatric uveitis such as abatacept, rituximab or a Janus kinase inhibitor (Maccora et al. 2020; Thau et al. 2018; Wennink et al. 2020).

Seven patients (16%) had elevated liver enzymes up to two times the normal value. In all of them, the elevated liver enzymes normalized after dose adjustment of the conventional IMT. After dose adjustment, only one patient had a relapse of uveitis. As a response, the dose of the conventional IMT was increased and the disease activity improved. The dose of adalimumab was not adjusted in these patients. Therefore, our opinion is that these elevated liver enzymes are due to the use of the conventional IMT. However, we cannot exclude the role of

adalimumab completely, but we do not think it was significant.

No major side effects or adverse events occurred in our study, resulting in the safe use of adalimumab in the home situation in contrast to other biological agents such as infliximab, which can only be administered intravenously in the hospital. The multidisciplinary team of ophthalmologists and paediatricians needs to make a trade-off between potential vision loss and potential risk of steroid-related complications on one hand and the risk of infection during adalimumab treatment on the other hand. This emphasizes the importance of a multidisciplinary approach in the treatment of paediatric uveitis by an ophthalmologist and a paediatric immunologist.

The study is limited by its retrospective design. Nonetheless, all data were structurally noted in the electronic patient files with a low inter-observer variability between two paediatric uveitis specialists, using the same protocolled treatment strategies and a uniform way of registration in the expert centre for paediatric uveitis in the Netherlands.

Conclusions

This study shows the effectiveness of anti-TNF α therapy with adalimumab treatment of chronic paediatric non-JIA-uveitis. Adalimumab therapy leads to improvement of disease inactivity, BCVA and decrease in the use of corticosteroids. We recommend MRI of the brain as a screening before starting adalimumab in intermediate and panuveitis.

Acknowledgement

This work was financially supported by AbbVie B.V., Hoofddorp, The Netherlands, (grant no.: SA-002407). The sponsor had no role in the design or conduct of this research.

References

Ali F & Laughlin RS (2017): Asymptomatic CNS demyelination related to TNF- α inhibitor therapy. *Neurol Neuroimmunol NeuroInflam* **4**: 1–2.

Al-Janabi A, El Nokrashy A, Sharief L, Nagendran V, Lightman S & Tomkins-Netzer O (2020): Long-term outcomes of treatment with biological agents in eyes with refractory, active, noninfectious intermediate uveitis,

posterior uveitis, or panuveitis. *Ophthalmology* **127**: 410–416.

Angeles-Han ST, Pelajo CF, Vogler LB et al. (2013): Risk markers of juvenile idiopathic arthritis-associated uveitis in the childhood arthritis and rheumatology research alliance (CARRA) registry. *J Rheumatol* **40**: 2088–2096.

Ayuso VK, ten Cate HAT, van der Does P, Rothova A & de Boer JH (2010): Male gender and poor visual outcome in uveitis associated with juvenile idiopathic arthritis. *Am J Ophthalmol* **149**: 987–993.

Cordero-Coma M & Sobrin L (2015): Anti-tumor necrosis factor- α therapy in uveitis. *Surv Ophthalmol*. Elsevier USA 575–589.

Correll CK, Bullock DR, Cafferty RM & Vehe RK (2018): Safety of weekly adalimumab in the treatment of juvenile idiopathic arthritis and pediatric chronic uveitis. *Clin Rheumatol* **37**: 549–553.

Cunha MI, Su M, Cantuti-Castelvetri L et al. (2020): Pro-inflammatory activation following demyelination is required for myelin clearance and oligodendrogenesis. *J Exp Med* **217**(5): <https://doi.org/10.1084/jem.20191390>.

Cunningham ET, Pavesio CE, Goldstein DA, Forooghian F & Zierhut M (2017): Multiple sclerosis-associated uveitis. *Ocul Immunol Inflamm* **25**: 299–301.

Cunningham ET (2000): Uveitis in children. *Ocul Immunol Inflamm* **8**: 251–261.

Haasnoot A-M, Schilham MW, Kamphuis S et al. (2018): Identification of an amino acid motif in HLA-DR β 1 that distinguishes uveitis in patients with juvenile idiopathic arthritis. *Arthritis Rheumatol* **70**: 1155–1165.

Horton S, Jones AP, Guly CM, Hardwick B, Beresford MW, Lee RW, Dick AD & Ramanan AV (2019): Adalimumab in juvenile idiopathic arthritis-associated uveitis: 5-year follow-up of the Bristol participants of the SYCAMORE trial. *Am J Ophthalmol* **207**: 170–174.

Jabs DA, Nussenblatt RB, Rosenbaum JT et al. (2005): Standardization of uveitis nomenclature for reporting clinical data. Results of the first international workshop. *Am J Ophthalmol* **140**: 509–516.

Jaffe GJ, Dick AD, Brézín AP et al. (2016): Adalimumab in patients with active noninfectious uveitis. *N Engl J Med* **375**: 932–943.

Kalinina Ayuso V, ten Cate HAT, van der Does P, Rothova A & de Boer JH (2010): Male gender as a risk factor for complications in uveitis associated with juvenile idiopathic arthritis. *Am J Ophthalmol* **149**: 994–999.e5.

Kemanetoglou E & Andreadou E (2017): CNS Demyelination with TNF- α Blockers. *Curr Neurol Neurosci Rep* **17**: <https://doi.org/10.1007/s11910-017-0742-1>.

Leal I, Rodrigues FB, Sousa DC, Duarte GS, Romão VC, Marques-Neves C, Costa J & Fonseca JE (2019): Anti-TNF drugs for chronic uveitis in adults—A systematic

review and meta-analysis of randomized controlled trials. *Front Med* **6**: <https://doi.org/10.3389/fmed.2019.00104>.

Lee J, Koreishi AF, Zumpf KB, Minkus CL & Goldstein DA (2020): Success of weekly adalimumab in refractory ocular inflammatory disease. *Ophthalmol* **127**: 1431–1433.

Lee RWJ & Dick AD (2012): Current concepts and future directions in the pathogenesis and treatment of non-infectious intraocular inflammation. *Eye* **26**(1): 17–28. Nature Publishing Group

Leinonen ST, Aalto K, Kotaniemi KM & Kivelä TT (2017): Anti-adalimumab antibodies in juvenile idiopathic arthritis-related uveitis. *Clin Exp Rheumatol* **35**: 1043–1046.

Liberman P, Berkenstock MK, Burkholder BM, Chaon BC & Thorne JE (2020): Escalation to weekly adalimumab for the treatment of ocular inflammation. *Ocul Immunol Inflamm* **00**: 1–5.

Maccora I, Sen ES & Ramanan AV. (2020): Update on noninfectious uveitis in children and its treatment. *Curr Opin Rheumatol* **32** (5): 395–402.

Ming S, Xie K, He H, Li Y & Lei B. (2018): Efficacy and safety of adalimumab in the treatment of non-infectious uveitis: A meta-analysis and systematic review. *Drug Des Devel Ther*. Dove Medical Press Ltd. 2005–2006.

Moradi A, Amin RM & Thorne JE. (2014): The role of gender in juvenile idiopathic arthritis-associated uveitis. *J Ophthalmol* **2014**: 1–7.

Nguyen QD, Merrill PT, Jaffe GJ et al. (2016): Adalimumab for prevention of uveitic flare in patients with inactive non-infectious uveitis controlled by corticosteroids (VISUAL II): a multicentre, double-masked, randomised, placebo-controlled phase 3 trial. *Lancet* **388**: 1183–1192.

Olsen TG & Frederiksen J (2017): The association between multiple sclerosis and uveitis. *Surv Ophthalmol* **62**: 89–95.

Quartier P, Baptiste A, Despert V et al. (2018): ADJUVITE: A double-blind, randomised, placebo-controlled trial of adalimumab in early onset, chronic, juvenile idiopathic arthritis-associated anterior uveitis. *Ann Rheum Dis* **77**: 1003–1011.

Ramanan AV, Dick AD, Jones AP et al. (2017): Adalimumab plus methotrexate for uveitis in juvenile idiopathic arthritis. *N Engl J Med* **376**: 1637–1646.

Scheinfeld N (2005): Adalimumab: A review of side effects. *Expert Opin Drug Saf* **4**: 637–641.

Siiskonen M, Hirn I, Pesälä R, Hautala T, Ohtonen P & Hautala N (2021): Prevalence, incidence and epidemiology of childhood uveitis. *Acta Ophthalmol* **99**(2): <http://dx.doi.org/10.1111/aos.14535>.

Simonini G, Cantarini L, Bresci C, Lorusso M, Galeazzi M & Cimaz R (2010): Current therapeutic approaches to autoimmune chronic uveitis in children. *Autoimmun Rev* **9**(10): 674–683.

Simonini G, Druce K, Cimaz R, Macfarlane GJ & Jones GT. (2014): Current evidence of anti-

- tumor necrosis factor α treatment efficacy in childhood chronic uveitis: A systematic review and meta-analysis approach of individual drugs. *Arthritis Care Res* **66**(7): 1073–1084.
- Skrabl-Baumgartner A, Erwa W, Muntean W & Jahnel J (2015): Anti-adalimumab antibodies in juvenile idiopathic arthritis: Frequent association with loss of response. *Scand J Rheumatol* **44**: 359–362.
- Skrabl-Baumgartner A, Seidel G, Langner-Wegscheider B, Schlagenhaut A & Jahnel J (2019): Drug monitoring in long-term treatment with adalimumab for juvenile idiopathic arthritis-associated uveitis. *Arch Dis Child* **104**: 246–250.
- Society EG (2014): The Guidelines project was entirely supported by the European Glaucoma Society Foundation.: Nebi 2
- Sood AB & Angeles-Han ST (2017): An Update on treatment of pediatric chronic non-infectious uveitis. *Curr Treat Options Rheumatol* **3**: 1–16.
- Suhler EB, Adán A, Brézin AP et al. (2018): Safety and efficacy of adalimumab in patients with noninfectious uveitis in an ongoing open-label study: VISUAL III. *Ophthalmol* **125**: 1075–1087.
- Thau A, Lloyd M, Freedman S, Beck A, Grajewski A & Levin AV. (2018): New classification system for pediatric glaucoma. *Curr Opin Ophthalmol* **29**: 385–394. Lippincott Williams and Wilkins.
- Thorne JE, Woreta FA, Dunn JP & Jabs DA (2010): Risk of cataract development among children with juvenile idiopathic arthritis-related uveitis treated with topical corticosteroids. *Ophthalmol* **117**: 1436–1441.
- Tugal-Tutkun I, Herbot CP, Khairallah M. (2010): Scoring of dual fluorescein and ICG inflammatory angiographic signs for the grading of posterior segment inflammation (dual fluorescein and ICG angiographic scoring system for uveitis). *Int Ophthalmol* **30**: 539–552.
- Wang S-L, Hauenstein S, Ohrmund L et al. (2013): Monitoring of adalimumab and antibodies-to-adalimumab levels in patient serum by the homogeneous mobility shift assay. *J Pharm Biomed Anal* **78–79**: 39–44.
- Wennink RAW, Ayuso VK, de Vries LA, Vastert SJ & de Boer JH (2020): Tocilizumab as an effective treatment option in children with refractory intermediate and panuveitis. *Ocul Immunol Inflamm* **00**: 1–5.
- Yeung IYL, Popp NA & Chan CC (2015): The role of sex in uveitis and ocular inflammation. *Int Ophthalmol Clin* **55**: 111–131.
- Zhu TH, Nakamura M, Abrouk M, Farahnik B, Koo J & Bhutani T (2016): Demyelinating disorders secondary to TNF-inhibitor therapy for the treatment of psoriasis: A review. *J Dermatolog Treat* **27**: 406–413.

Received on September 25th, 2020.
Accepted on August 31st, 2021.

**Correspondence*

Carlyn V. Kouwenberg, MD
Department of Ophthalmology
University Medical Centre Utrecht
Postal address: UMC Utrecht
Heidelberglaan 100, 3584 CX Utrecht
The Netherlands
Phone: +31 625777481
E-mail: C.V.Kouwenberg-3@umcutrecht.nl

Supporting Information

Additional Supporting Information may be found in the online version of this article:

Table S1-S2