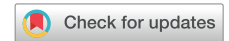

# Dose-dependent cardiac effects of collateral cardiac irradiation: Echocardiographic strain analysis in patients treated for extracardiac malignancies



Martijn H. van der Ree, MD,\* Rianne H.A. de Bruin-Bon,\* Brian V. Balgobind, MD, PhD,<sup>†</sup> Wiert F. Hoeksema, MD,\* Jorrit Visser, PhD,<sup>†</sup> Hanneke W.M. van Laarhoven, MD, PhD,<sup>‡</sup> Nadia Haj Mohammad, MD, PhD,<sup>§</sup> Edith M.T. Dieleman, MD,<sup>†</sup> Maarten C.C.M. Hulshof, MD, PhD,<sup>†</sup> S. Matthijs Boekholdt, MD, PhD,\* Pieter G. Postema, MD, PhD\*

From the \*Department of Clinical and Experimental Cardiology, University of Amsterdam, Amsterdam, the Netherlands, <sup>†</sup>Department of Radiation Oncology, University of Amsterdam, Amsterdam, the Netherlands, <sup>‡</sup>Department of Medical Oncology, University of Amsterdam, Amsterdam, the Netherlands, and <sup>§</sup>Department of Medical Oncology, University Medical Center Utrecht, Utrecht University, Utrecht, the Netherlands.

Cardiac radioablation is a new treatment modality for the treatment of patients with ventricular tachycardia.<sup>1</sup> The time course and magnitude of subsequent myocardial changes are unknown but seem to occur within weeks to months.<sup>2</sup> There is ongoing uncertainty about the relationship between radiotherapy dose and efficacy and safety of radioablation. Detailed cardiac investigations comparing pre- and post-thoracic radiotherapy may provide insights into functional effects. In this study, the effects of cardiac irradiation on the left ventricle were evaluated by correlating radiotherapy dose to echocardiographic changes.

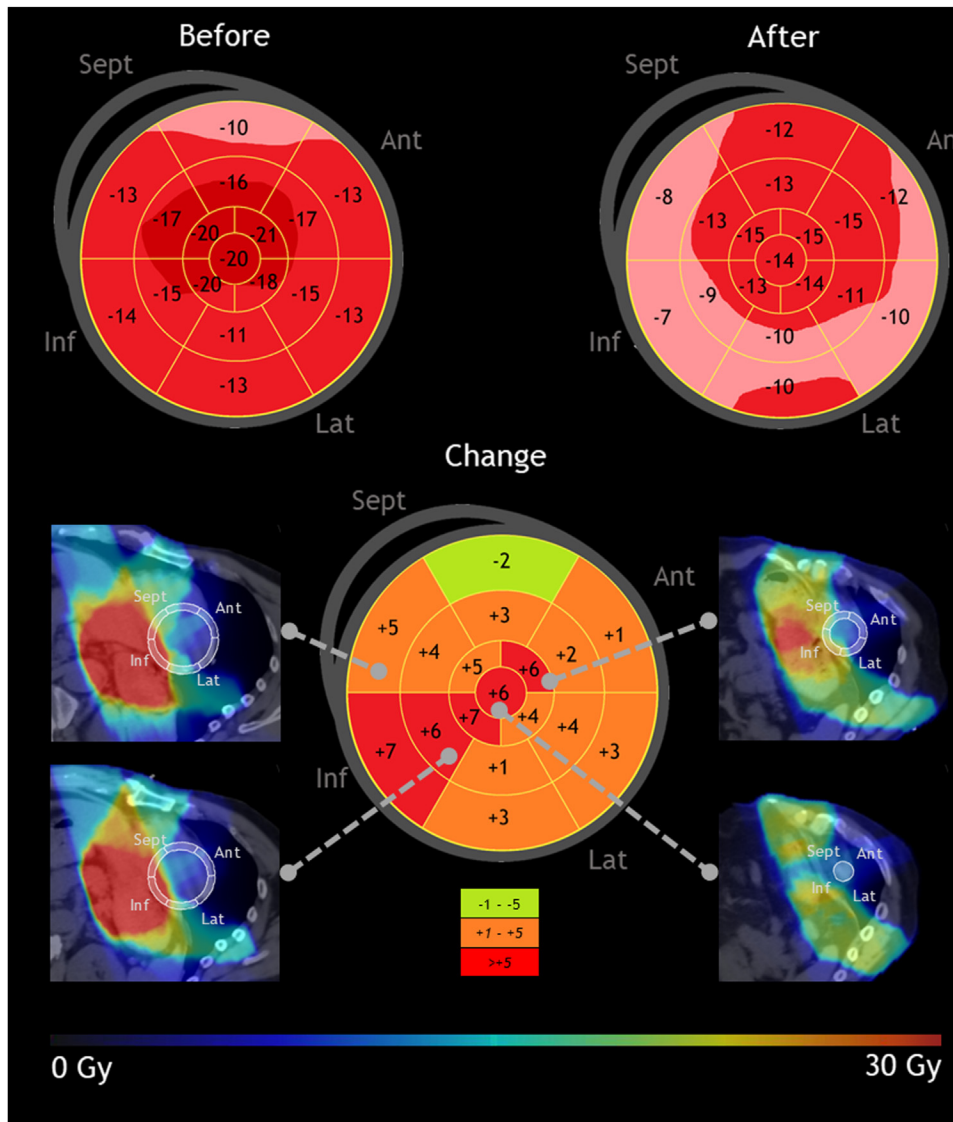
From a previously conducted prospective trial of patients with resectable esophageal cancer undergoing neoadjuvant chemoradiation with collateral left ventricular irradiation, we selected patients with echocardiograms of sufficient quality for deformation imaging before and after treatment.<sup>3</sup> Treatment consisted of fractionated radiotherapy (41.4 Gy in 23 fractions, 5 days per week) and low-dose/low-cardiotoxic carboplatin/paclitaxel chemotherapy.<sup>3</sup> Echocardiograms were analyzed with 2-dimensional speckle tracking (GE Healthcare, Oslo, Norway) by an experienced echocardiographer for research purposes and included assessment of longitudinal strain, globally and per cardiac segment.

**KEYWORDS** Cardiac radioablation; Deformation imaging; Echocardiography; Longitudinal strain; Ventricular tachycardia (Heart Rhythm 2023;20:149–151)

**Funding Sources:** The authors have no funding sources to disclose.  
**Disclosures:** The authors have no conflicts of interest to disclose.  
**Address reprint requests and correspondence:** Dr Pieter G. Postema, Department of Clinical and Experimental Cardiology, University of Amsterdam, Meibergdreef 9, Amsterdam 1105 AZ, the Netherlands. E-mail address: [p.g.postema@amsterdamumc.nl](mailto:p.g.postema@amsterdamumc.nl).

Mean radiotherapy dose per segment was calculated.<sup>4</sup> We compared laboratory results and echocardiograms before and after treatment (paired *t* test or Wilcoxon signed-rank test). Scatter plots and Pearson correlation coefficients (PCCs) were used to evaluate relationships between radiotherapy dose and echocardiographic changes, including subanalyses for segments receiving doses >20, >25, and >30 Gy.<sup>1,2,5</sup> The study was approved by the institutional review board of the Amsterdam UMC.

Twenty patients were included (mean age 64 ± 6 years; 16 men [80%]). Mean cumulative cardiac left ventricular dose was 18.7 ± 3.5 Gy, and mean dose per segment ranged between 3 and 40 Gy. Time between echocardiograms was 37 ± 6 days. Ejection fraction at baseline was 57% [interquartile range 54–61] and was unchanged after radiotherapy (55% [50–59]; *P* = .169). However, global longitudinal strain significantly worsened from -19% ± 3% to -17% ± 3% (-3% ± 2%; *P* = .001). This change did not correlate with mean cumulative radiotherapy dose as indicated by a small and nonsignificant PCC (0.062; *P* = .795). An illustrative case is shown in [Figure 1](#). For the 17 segments (*n* = 324 datapoints), no significant correlation with mean dose per segment was seen (PCC 0.064; *P* = .247). This also applied to segments that received >20 or >25 Gy (PCC 0.015, *P* = .875; and PCC 0.173, *P* = .151, respectively). However, if segments that received >30 Gy (*n* = 34 datapoints) were evaluated, a higher dose did correlate significantly with (mild) worsening in longitudinal strain (PCC 0.341; *P* = .048). Interestingly, troponin levels significantly increased from 0.007 µg/L [0.005–0.010] before to 0.013 µg/L after completion of treatment [0.001–0.017] (*P* < .0001), which did not correlate to radiotherapy dose, but N-terminal pro-brain natriuretic peptide level did not change. A modest



**Figure 1** Illustrative case showing echocardiographic longitudinal strain before (left) and after (right) irradiation. Improvement is indicated by a negative change (green) and worsening by positive values (orange/red). Ant = anterior; Inf = inferior; Lat = lateral; Sept = septal.

volume depletion with reduction in systolic blood pressure and increase in heart rate after treatment also was observed.<sup>3</sup>

In this study, we showed that chemoradiation results in early myocardial injury, as indicated by worsening of global longitudinal strain and increased troponin levels. If these alterations had been caused by cardiac irradiation alone, a dose-dependent effect would be expected.<sup>1</sup> Only in segments that received  $>30$  Gy did mild worsening of longitudinal strain correlate with radiotherapy dose. Thus, early functional alterations can be induced, which is consistent with clinical findings of early antiarrhythmic effects.<sup>1,2</sup> In preclinical *in vivo* experiments, both structural and functional myocardial alterations became apparent 8–12 weeks after irradiation, also only in tissue exposed to  $>30$  Gy,<sup>5</sup> which is mirrored in this study. In the preclinical work,

high single-fraction radiotherapy doses were given, in contrast to fractionation in this study. Currently, fractionation is not applied in the field of cardiac radioablation, and whether there is a future role for fractionation is unknown. In addition, patients eligible for cardiac radioablation generally have extensive structural heart disease in contrast to the patients included in this study, which might provide disparate results. The early timing of the echocardiograms in our study may explain why no correlation was found for all segments. Furthermore, we cannot ascertain from this study whether there may be inhomogeneous cardiac effects of (low-dose, low-cardiotoxic) chemotherapy, which coincidentally correlated with the segments that received the highest doses. Lastly, the observed volume depletion may affect global longitudinal strain.

In conclusion, fractionated collateral cardiac irradiation correlates with early functional myocardial changes detected by echocardiography. These findings support the need for further evaluation of the dose effects of (fractionated) radiotherapy in relation to cardiac function over time.

## References

1. van der Ree MH, Blanck O, Limpens J, et al. Cardiac radioablation—a systematic review. *Heart Rhythm* 2020;17:1381–1392.
2. Zhang DM, Navara R, Yin T, et al. Cardiac radiotherapy induces electrical conduction reprogramming in the absence of transmural fibrosis. *Nat Commun* 2021;12:5558.
3. Haj Mohammad N, Kamphuis M, Hulshof MC, et al. Reduction of heart volume during neoadjuvant chemoradiation in patients with resectable esophageal cancer. *Radiother Oncol* 2015;114:91–95.
4. van der Ree MH, Visser J, Planken RN, et al. Standardizing the cardiac radioablation targeting workflow: enabling semi-automated angulation and segmentation of the heart according to the American Heart Association segmented model. *Adv Radiat Oncol* 2022;7:100928.
5. Hohmann S, Deisher AJ, Suzuki A, et al. Left ventricular function after noninvasive cardiac ablation using proton beam therapy in a porcine model. *Heart Rhythm* 2019;16:1710–1719.