

Ocular surface disease is common in moderate-to-severe atopic dermatitis patients

To the Editor,

High rates of ocular surface disease (OSD) in atopic dermatitis (AD) patients have been reported during dupilumab treatment. One of the hypotheses about the pathomechanism to be responsible for its development is focal scarcity of intraepithelial goblet cells.¹ An association between moderate-to-severe AD patients and low goblet cell density (GCD) has also been reported previously.² Despite the association between AD and OSD reported in previous literature, moderate-to-severe AD patients do not commonly undergo ophthalmological evaluation.² To better understand the pathomechanism of dupilumab-associated OSD (DAO), more insight in the occurrence of OSD in moderate-to-severe AD population is needed. Therefore, we investigated the frequency, severity, and pathogenesis of OSD in moderate-to-severe AD patients before the start of dupilumab.

This prospective study included adult moderate-to-severe AD patients treated with topical corticosteroids on the skin, between February 2020 and September 2021 from the University Medical Centre Utrecht, the Netherlands. The patients provided written informed consent and were registered in the BioDay registry, which is co-funded by the manufacturer of dupilumab.³ Ethics approval was obtained by the local Medical Research Ethics Committee.

All patients were examined by a dermatologist and an ophthalmologist before starting dupilumab treatment. AD severity was assessed by the Eczema Area and Severity Index (EASI). Clinical ophthalmological characteristics and symptoms of OSD were reported.

The patients were divided into having no, mild, moderate or severe OSD based on the Utrecht Ophthalmic Inflammatory and Allergic disease (UTOPIA) score, and the severity classification of the most severely affected eye was used.³

Conjunctival impression cytology (CIC) by using the Eyeprim device was performed to investigate the number of conjunctival goblet cells (GCs) and its major secretory mucin, which is Mucin5AC (MUC5AC). The CIC from the left eye was stained with Periodic Acid-Schiff and haematoxylin following the Eyeprim protocol.⁴ Afterwards, the GCD per sample was calculated. Flow cytometry analyses of CIC of the right eye were performed in a representative subgroup of the included patients. CIC is further explained in the online access repository following <https://zenodo.org/record/6275350>

Differences between no or mild OSD and moderate-to-severe OSD were calculated with the chi-square test and with the Mann-Whitney U test. CIC results were reported per severity category

of OSD. Statistical analyses were conducted with SPSS Statistics version 25.0.0.2 (IBM Corp. Released 2017. IBM SPSS Statistics for Windows). Figures were created by using Prism (version 9 GraphPad Software).

A total of 70 moderate-to-severe AD patients (median EASI 15.0 (IQR 10.8–20.9)) were included (Table 1). Mild, moderate, and severe OSD were reported in 32/70 (45.7%), 24/70 (34.3%), and 7/70 (10.0%) patients respectively. Only 7/70 (10.0%) patients showed no signs of OSD. Significantly higher EASI scores were found in patients with moderate-to-severe OSD compared to patients with no or mild OSD (17.7 (IQR 13.7–24.9) vs. 11.8 (IQR 9.0–16.7), $p < .001$). Additionally, occurrence of both AD eyelid involvement and AD facial involvement in the past year was significantly higher in patients with moderate-to-severe OSD compared to patients with no or mild OSD ($n = 28$ (90.3%) vs. $n = 18$ (46.2%), $p < .001$ and $n = 31$ (100.0%) vs. $n = 33$ (84.6%), $p = .030$ respectively). Of all patients with moderate-to-severe OSD, 23/31 patients (74.2%) experienced OSD symptoms.

A lower conjunctival GCD median was found in patients with OSD compared to patients without OSD (Figure 1A). Flow cytometry analyses of CIC showed a trend of higher median fluorescence intensity (MFI) of MUC5AC within MUC5AC + GCs in patients with more severe OSD (Figure 1B). This indicates that patients with more severe OSD had more MUC5AC production by GCs.

This prospective study demonstrates that OSD is very frequent in adult patients with moderate-to-severe AD (90%) and is associated with lower conjunctival GCD compared with GCD of healthy controls reported in the literature.⁵ Moderate-to-severe OSD was found in 44.3% of the AD patients and was associated with more severe AD.

Our results show higher rates of OSD in AD patients (90%) than previous studies, reporting an incidence of 32.4%–55.8% of OSD in severe AD patients.¹ All of our patients were examined by an ophthalmologist following a standardized protocol, which is more reliable than patient-reported diagnosis and explain the higher rates of OSD. In our study, 25% of the patients with moderate-to-severe OSD did not report OSD symptoms. Bortoluzzi et al.⁶ reported low Ocular Surface Disease Index, which focusses partly on symptoms of OSD, in patients with severe ocular surface involvement. These findings are comparable to our results and explain the underreporting of ocular comorbidity in AD based on patient-reported

This is an open access article under the terms of the [Creative Commons Attribution-NonCommercial-NoDerivs](https://creativecommons.org/licenses/by-nc-nd/4.0/) License, which permits use and distribution in any medium, provided the original work is properly cited, the use is non-commercial and no modifications or adaptations are made.

© 2022 The Authors. *Clinical & Experimental Allergy* published by John Wiley & Sons Ltd.

diagnosis. Furthermore, significantly more of our included patients with moderate-to-severe OSD reported the presence of eyelid and facial eczema in the past year compared to patients with no or mild OSD. Dogru et al.² reported also that OSD in AD patients was associated with facial and eyelid eczema and that patients with facial atopy had higher grades of conjunctival squamous metaplasia. Additionally, patients from our study with moderate-to-severe OSD had more severe AD based on EASI and serum Thymus and Activation-Regulated Chemokine (TARC) levels, shown in Table 1, suggesting that more severe AD is associated with moderate-to-severe OSD. The abovementioned points underline the importance

Key Messages

- In a single-centre study, we assessed ocular surface disease prevalence in moderate-to-severe atopic dermatitis.
- Before starting dupilumab, 60/70 (90%) of patients already had ocular surface disease.
- Ocular surface disease was associated with lower conjunctival goblet cell density and more severe AD.

TABLE 1 Patient, dermatological and ophthalmological characteristics

	Total cohort (n = 70)	Severity of OSD		p-Value
		No or mild OSD (n = 39)	Moderate-to-severe OSD (n = 31)	
Age (years), median (IQR) ^a	38.5 (27.0–53.3)	41.0 (27.0–59.0)	32.0 (24.0–46.0)	.090
Men, n (%)	35 (50.0)	15 (38.5)	20 (64.5)	.030
Age of onset of AD, n (%)				.135
Childhood	62 (88.6)	32 (82.1)	30 (96.8)	n/a
Adolescence	5 (7.1)	4 (10.3)	1 (3.2)	n/a
Adult	3 (4.3)	3 (7.7)	0 (0.0)	n/a
History of self-reported episodic acute allergic conjunctivitis, n (%)	55 (78.6)	28 (71.8)	27 (87.1)	.121
Allergic asthma, n (%)	35 (50.0)	18 (46.2)	17 (54.8)	.470
Allergic rhinitis, n (%)	51 (72.9)	28 (71.8)	23 (74.2)	.823
Food allergy, n (%)	34 (48.6)	21 (53.8)	13 (41.9)	.322
History of rosacea, n (%)	2 (2.9)	1 (2.6)	1 (3.2)	1.000
EASI score, median (IQR) ^a	15.0 (10.8 – 20.9)	11.8 (9.0–16.7)	17.7 (13.7–24.9)	.001
IGA score, median (IQR) ^a	3 (3–3)	3 (2–3)	3 (3–4)	.002
AD eyelid involvement in the past year, n (%)	46 (65.7)	18 (46.2)	28 (90.3)	<.001
AD facial involvement in the past year, n (%)	64 (91.4)	33 (84.6)	31 (100.0)	.030
TARC (pg./ml), median (IQR) ^a	1564 (811–2716)	1411 (787–1975)	1919 (1348–3154)	.026
Missing, n (%)	1 (1.4)	0 (0)	1 (3.2)	n/a
Peripheral blood eosinophils (×10 ⁹ /L), median (IQR) ^a	0.29 (0.16–0.51)	0.29 (0.14–0.50)	0.31 (0.20–0.52)	.624
Eosinophilia (≥0.45 × 10 ⁹ /L), n (%)	21 (30.4)	12 (30.8)	9 (30.0)	.945
Missing, n (%)	1 (1.4)	0 (0)	1 (3.2)	n/a
Visited an ophthalmologist before, n (%)	36 (51.4)	19 (48.7)	17 (54.8)	.611
Previous use of ophthalmic medication, n (%)	45 (64.3)	24 (61.5)	21 (67.7)	.591
Lubricant eye drops	23 (32.9)	8 (20.5)	15 (48.4)	.014
Antihistamine eye drops	22 (31.4)	13 (33.3)	9 (29.0)	.700
Anti-inflammatory ointment for the external eyelids	5 (7.1)	2 (5.1)	3 (9.7)	.649
Anti-inflammatory therapy (eye drops or eye ointment)	14 (20.0)	4 (10.3)	10 (32.3)	.022
Other	15 (21.4)	6 (15.4)	9 (29.0)	.167
Wearing contact lenses, n (%)	6 (8.6)	4 (10.3)	2 (6.5)	.687

TABLE 1 (Continued)

	Total cohort (n = 70)	Severity of OSD		p-Value
		No or mild OSD (n = 39)	Moderate-to-severe OSD (n = 31)	
Current use of ophthalmic medication, n (%)				
Lubricant eye drops	3 (4.3)	0 (0.0)	3 (9.7)	.082
Antihistamine eye drops	6 (8.6)	4 (10.3)	2 (6.5)	.687
Anti-inflammatory ointment for the external eyelids	2 (2.9)	1 (2.6)	1 (3.2)	1.000
Anti-inflammatory therapy (eye drops or eye ointment)	2 (2.9)	1 (2.6)	1 (3.2)	1.000
Medical history of any eye disease, n (%)	22 (31.4)	9 (23.1)	13 (41.9)	.091
Medical history of allergic eye disease ^b , n (%)	3 (4.3)	1 (2.6)	2 (6.5)	.580
Medical history of non-allergic eye disease ^c , n (%)	12 (17.1)	5 (12.8)	7 (22.6)	.282
Medical history of other eye disease, n (%)	8 (11.4)	3 (7.7)	5 (16.1)	.452
Presence of symptoms of OSD, n (%)	40 (57.1)	17 (43.6)	23 (74.2)	.010
Redness	20 (28.6)	5 (12.8)	15 (48.4)	.001
Pruritus	35 (50.0)	14 (35.9)	21 (67.7)	.008
Watery eyes	20 (28.6)	10 (25.6)	10 (32.3)	.542
Burning sense	12 (17.1)	4 (10.3)	8 (25.8)	.086
Pain	6 (8.6)	1 (2.6)	5 (16.1)	.081
Photophobia	6 (8.6)	3 (7.7)	3 (9.7)	1.000
Presence of clinical characteristics of OSD, n (%)				
Blepharitis	50 (71.4)	19 (48.7)	31 (100.0)	<.001
Meibomian gland dysfunction	45 (64.3)	15 (38.5)	30 (96.8)	<.001
Tarsal conjunctivitis	57 (81.4)	26 (66.7)	31 (100.0)	<.001
Bulbar conjunctivitis	38 (54.3)	11 (28.2)	27 (87.1)	<.001
Limbitis	4 (5.7)	0 (0.0)	4 (12.9)	.034
Limbal vascularization	42 (60.0)	13 (33.3)	29 (93.5)	<.001
Punctate corneal lesions	20 (29.0)	6 (15.4)	14 (46.7)	.005
Hurricane fluorescein staining	0 (0.0)	0 (0.0)	0 (0.0)	n/a

Note: Severity of OSD is based on the eye with the highest severity within a patient. *p*-values were calculated with the chi-square test.

Abbreviations: AD, atopic dermatitis; EASI, eczema area and severity index; IGA scale, Investigator's Global Assessment Scale; IQR, interquartile range; OD, oculus dexter (right eye); OS, oculus sinister (left eye); OSD, ocular surface disease; SD, standard deviation; TARC, thymus and activation-regulated chemokine.

^aIndicates *p*-values were calculated with Mann-Whitney U tests.

^bAtopic keratoconjunctivitis; vernal keratoconjunctivitis; giant papillary conjunctivitis.

^cKeratoconus; pellucid marginal degeneration; keratitis; uveitis; herpetic keratitis; blepharitis; glaucoma; cataract; macular oedema; amblyopia; Meibomian gland dysfunction; retinal detachment.

of ophthalmological examination in patients with moderate-to-severe AD, especially in patients with the presence of eyelid eczema or severe AD including the face, in which low-threshold referral to an ophthalmologist is recommended. Diagnosing OSD is important since it may be associated with chronic limbitis, possibly leading to irreversible limbal stem cell deficiency and subsequently to irreversible long-term visual loss.³

In our study, lower conjunctival GCD was found in patients with OSD, compared to patients without OSD. Since there were only seven patients without OSD, having a large variation in GCD, no significant differences in GCD could be found between these groups. However, median GCD of patients with OSD was much lower compared with mean GCD from normally covered conjunctiva

sites (973 cells/mm²) described in the literature, assuming that lower GCD is associated with OSD.⁵ In contrast, GC hyperplasia and mucin hypersecretion are reported in allergic conjunctivitis.⁷ In our cohort, OSD was accompanied by low conjunctival GCD, which makes it different from (episodic) allergic conjunctivitis.

In addition to the lower GCD in patients with OSD, higher MFI of MUC5AC was found in patients with more severe OSD. MUC5AC is the major GC secretory mucin and protects and lubricates the ocular surface.² Dogru et al.² investigated OSD in atopic patients and suggested that the increased expression of MUC5AC might be a defence response of the ocular surface to compensate for the ailing ocular surface condition, with eventually decreased expression of MUC5AC as a result of the progression of atopic OSD. This higher

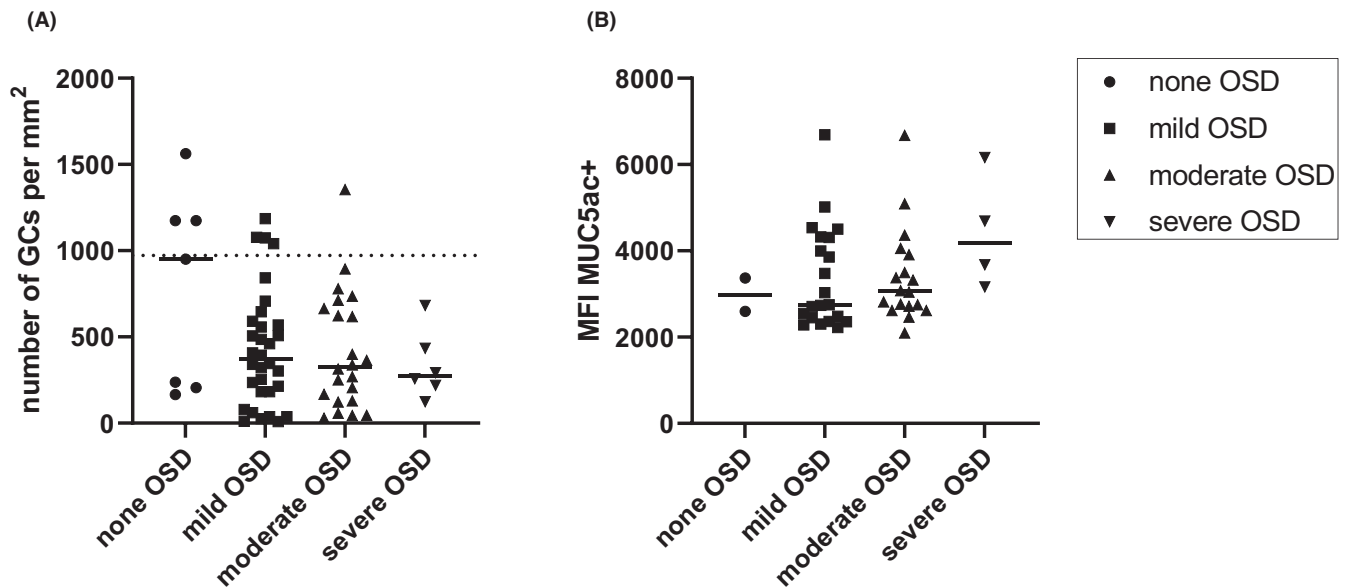


FIGURE 1 Results of conjunctival impression cytology of moderate-to-severe atopic dermatitis patients. Groups are based on the UTOPIA categories.³ The bold lines display the median. (A) Number of goblet cells (GCs) per mm² in 67 patients. The dotted line displays the mean GC density from normally covered conjunctiva sites (973 cells/mm²), based on Doughty et al.⁵ The median GC density of patients without ocular surface disease (OSD) was 950 cells/mm² (IQR 205–1174). The median GC density of patients with mild, moderate and severe OSD were 370 cells/mm² (IQR 182–580), 325 cells/mm² (IQR 129–664) and 276 cells/mm² (IQR 219–434) respectively. (B) Flow cytometry data displaying the median fluorescence intensity (MFI) of MUC5AC within MUC5AC + GCs in 45 patients

expression of MUC5AC protein as a defence response might explain the higher expression of MUC5AC protein found in our patients with more severe OSD.

The development of ocular side-effects during dupilumab treatment in AD patients emphasises the importance of gaining more insight into the ocular comorbidities in patients with moderate-to-severe AD.¹ This current study shows that 90% of the moderate-to-severe AD patients have OSD before the initiation of dupilumab, at least in our centre, which leads to the question of what effect dupilumab will have on pre-existing OSD. Previously, we have shown scarcity of conjunctival GCD with increased local Th1-related cytokine production in a case series of patients with DAOSD.⁸ Inhibition of interleukin (IL)-4/IL-13 signalling by dupilumab, combined with increased local Th1-related cytokine production may be the basis for the loss of GCs and their important immunomodulatory function in the conjunctiva. Additionally, a small observational study by Barnett et al.⁹ reported a relative deficiency of MUC5AC in tear levels in AD patients with DAOSD. The abovementioned hypothesis and conclusions will be studied in future research, in which we will evaluate the included patients of this current study longitudinally during dupilumab treatment.

This study has some limitations. First, severity of only one eye was included, which might have led to loss of information. However, a preliminary analysis showed a very strong association (Spearman correlation) of 0.953 between severity of both eyes, assuming that this has not influenced our results. Second, due to the small number of patients without OSD having a large variation in GCD, no significant differences were found in GCD between patients with and

without OSD. However, by comparing GCD of patients with OSD to GCD of healthy controls described in the literature, we can conclude that moderate-to-severe AD patients with OSD have lower GC counts. Third, since this is an explorative study in which two small subgroups were compared, we did not correct for multiple testing. Larger cohorts or other comparable studies are needed to support our results.

In conclusion, this prospective, single-centre cohort study shows that OSD is a common finding in adult patients with moderate-to-severe AD and is associated with low conjunctival GCD, more severe AD, and the presence of facial AD and/or eyelid eczema. As many patients with OSD did not report OSD symptoms, low-threshold referral to an ophthalmologist is recommended in patients with the mentioned risk factors. The results of this study provide an important basis for unravelling the pathomechanism of ocular side-effects associated with IL-4/IL-13 blocking treatment in future studies.

KEYWORDS

atopic dermatitis, goblet cell, ocular surface disease

ACKNOWLEDGEMENT

We would like to thank Andrew Walker for critically reading the manuscript.

CONFLICT OF INTEREST

Roselie E. Achten has nothing to disclose. Daphne S. Bakker is a speaker for Sanofi Genzyme and LEO Pharma. Chantal M. van Luijk

is a speaker for Sanofi Genzyme and Santen. Marlot van der Wal has nothing to disclose. Marlies de Graaf is a principal investigator and advisory board member and/or speaker for Sanofi Genzyme and Regeneron Pharmaceuticals and LEO Pharma. Femke van Wijk is a speaker and/or consultant for Janssen, Johnson & Johnson and Takeda. Nicolaas P.A. Zuithoff has nothing to disclose. Lisa P. van der Rijst has nothing to disclose. Celeste M. Boesjes has nothing to disclose. Judith L. Thijs is a speaker for Sanofi Genzyme and LEO Pharma. Joke H. de Boer received research funding from Abbvie; this is outside the submitted work. Marjolein S. de Bruin-Weller is a consultant, advisory board member and/or speaker for AbbVie, Almirall, Aslan, Arena, Eli Lilly, Galderma, Janssen, Leo Pharma, Pfizer, Regeneron and Sanofi-Genzyme.

AUTHOR CONTRIBUTIONS

The authors confirm contribution to the paper as follows: data were collected by Roselie E. Achten and Chantal M. van Luijk. Flow cytometry analyses were performed by Marlot van der Wal. PAS staining was performed by Roselie E. Achten. Statistical analyses were conducted by Roselie E. Achten and Nicolaas P.A. Zuithoff. Interpretation of data was performed by all authors. Roselie E. Achten and Daphne S. Bakker prepared the first draft manuscript. Critical comments on the draft and the manuscript and the final approval of the manuscript were given by all authors.

Roselie E. Achten¹ 

Daphne S. Bakker¹ 

Chantal M. van Luijk²


Marlot van der Wal³ 

Marlies de Graaf¹

Femke van Wijk³

Nicolaas P.A. Zuithoff⁴

Lisa P. van der Rijst¹

Celeste M. Boesjes¹ 

Judith L. Thijs¹ 

Joke H. de Boer² 

Marjolein S. de Bruin-Weller¹ 

¹Department of Dermatology and Allergology, National Expertise Center for Atopic Dermatitis, University Medical Center Utrecht, Utrecht, The Netherlands

²Department of Ophthalmology, University Medical Center Utrecht, Utrecht, The Netherlands

³Center for Translational Immunology, University Medical Center Utrecht, Utrecht University, Utrecht, The Netherlands

⁴Julius Center for Health Sciences and Primary Care, University Medical Center Utrecht, Utrecht, The Netherlands

Correspondence

Roselie E. Achten, Department of Dermatology and Allergology, University Medical Center Utrecht, Heidelberglaan 100, 3584 CX Utrecht, The Netherlands.
Email: R.E.Achten@umcutrecht.nl

ORCID

Roselie E. Achten  <https://orcid.org/0000-0001-5617-8615>


Daphne S. Bakker  <https://orcid.org/0000-0002-0193-5794>

Marlot van der Wal  <https://orcid.org/0000-0003-4554-9059>

Celeste M. Boesjes  <https://orcid.org/0000-0002-3371-6414>

Judith L. Thijs  <https://orcid.org/0000-0003-2753-5235>

Joke H. de Boer  <https://orcid.org/0000-0003-1712-3050>

Marjolein S. de Bruin-Weller  <https://orcid.org/0000-0002-1249-6993>

REFERENCES

1. Akinlade B, Guttman-Yassky E, de Bruin-Weller M, et al. Conjunctivitis in dupilumab clinical trials. *Br J Dermatol*. 2019;181(3):459-473.
2. Dogru M, Okada N, Asano-Kato N, et al. Atopic ocular surface disease: implications on tear function and ocular surface mucins. *Cornea*. 2005;24(8 Suppl):S18-S23.
3. Achten R, Bakker D, Ariens L, et al. Long-term follow-up and treatment outcomes of conjunctivitis during dupilumab treatment in patients with moderate-to-severe atopic dermatitis. *J Allergy Clin Immunol Pract*. 2021;9(3):1389-1392.e2.
4. Technologies O. *EYEPRIM Handbook: Guideline for Sample Processing and Analyses Applications*. Opia Technologies S.A.S; 2020. www.eyepri.com
5. Doughty MJ. Goblet cells of the normal human bulbar conjunctiva and their assessment by impression cytology sampling. *Ocul Surf*. 2012;10(3):149-169.
6. Bortoluzzi P, Ferrucci S, Galimberti D, et al. New insights on ocular surface disease in patients with atopic dermatitis treated with dupilumab. *Br J Dermatol*. 2022;186(1):186-187.
7. Swamynathan SK, Wells A. Conjunctival goblet cells: ocular surface functions, disorders that affect them, and the potential for their regeneration. *Ocul Surf*. 2020;18(1):19-26.
8. Bakker DS, Ter Linde JJM, Amini MM, et al. Conjunctival inflammation in dupilumab-treated atopic dermatitis comprises a multicellular infiltrate with elevated T1/T17 cytokines: a case series study. *Allergy*. 2021;76(12):3814-3817.
9. Barnett BP, Afshari NA. Dupilumab-Associated Mucin Deficiency (DAMD). *Transl vis Sci Technol*. 2020;9(3):29.

How to cite this article: Achten RE, Bakker DS, van Luijk CM, et al. Ocular surface disease is common in moderate-to-severe atopic dermatitis patients. *Clin Exp Allergy*. 2022;52:801-805. doi:[10.1111/cea.14127](https://doi.org/10.1111/cea.14127)