

# A Novel Method for Quantitative Three-Dimensional Analysis of Zygomatico-Maxillary Complex Symmetry

W.W.B. de Kort, MD, W.M.M.T. van Hout, MD, T.C. ten Harkel,  
E.M. van Cann, MD, DMD, and A.J.W.P. Rosenberg, MD, DMD

**Objective:** To develop a reliable and accurate method to quantify the symmetry of the zygomaticomaxillary complex (ZMC).

**Methods:** Virtual three-dimensional models were created from 53 computed-tomography scans: 15 healthy cases without maxillofacial disorders and 38 patients with ZMC fractures requiring surgical treatment.

Asymmetry of the ZMC was measured using a mirroring and surface-based matching technique that uses the anterior cranial fossa as reference to determine the symmetrical position of the ZMC. The measure for ZMC asymmetry was defined as mean surface distance (MSD) between the ZMC-surface and the symmetrical position.

Reliability of the method was tested in the 15 healthy cases. Inter- and intra-observer correlation coefficients (Ce) and variabilities were assessed. Accuracy was assessed by comparing ZMC asymmetry between healthy and ZMC fracture cases, and by assessing correlation of ZMC fracture severity with ZMC asymmetry.

**Results:** The average MSD of the 15 healthy cases was  $1.40 \pm 0.54$  mm and the average MSD of the 38 ZMC fracture cases was  $2.69 \pm 0.95$  mm ( $P < 0.01$ ). Zygomaticomaxillary complex asymmetry correlated with fracture severity ( $P = 0.01$ ). Intra-rater CC was 0.97 with an intra-rater variability of  $0.09 \pm 0.11$  mm. Inter-rater Ce was 0.95 with an inter-rater variability of  $0.12 \pm 0.13$  mm.

**Conclusions:** Our method is reliable and accurate for quantitative three-dimensional analysis of ZMC-symmetry. It takes into account asymmetry caused by the shape of the ZMC as well as asymmetry caused by the position of the ZMC.

**Clinical relevance:** This method is useful for the evaluation of ZMC asymmetry associated with congenital and acquired disorders of craniofacial skeleton, for surgical planning and for evaluation of postoperative results.

**Key Words:** 3D, asymmetry, symmetry, three-dimensional, zygoma, zygomaticomaxillary complex

(*J Craniofac Surg* 2022;33: 1474–1478)

The zygomaticomaxillary complex (ZMC) is a bilateral symmetrical eminence at the antero-lateral aspect of the face. Distortion of ZMC form and position is often encountered in ZMC fractures, which are common fractures in maxillofacial injuries.<sup>1-3</sup> Asymmetry of the ZMC may also be present in congenital syndromes such as craniofacial microsomia, Crouzon syndrome, and Treacher Collins syndrome.<sup>4,5</sup>

Visualization of the osseous ZMC is best attained with computed tomography (CT).<sup>6,7</sup> Zygomaticomaxillary complex fractures are examined on CT-images to determine the indication for surgical treatment and to evaluate treatment results postoperatively. In the clinical setting, the assessment of ZMC asymmetry on axial, coronal and sagittal CT slices and a three-dimensional (3D) reconstruction is usually qualitative.

Several methods have been developed for the quantitative assessment of the ZMC symmetry on CT.<sup>8-12</sup> These methods are either linear distance or angle measurements within CT-slices or coordinates-based methods in which a 3D reference frame is constructed of the CT-data. One disadvantage of these methods is that the asymmetry of a few landmarks is quantified, whereas the CT scan provides data of the entire ZMC, these methods do not use all available data. Another disadvantage is that imprecision is introduced by placement of landmarks.<sup>13</sup> Analysis of the entire ZMC surface is a superior method for measuring ZMC symmetry, as it uses all available data on the ZMC in the CT scan, which increases the accuracy of the method.

Three studies that describe methods to quantify the asymmetry of the entire ZMC surface have been published.<sup>14-16</sup> In these studies, the mirrored contralateral ZMC-surface is placed at the symmetrical position and used to determine the level of asymmetry of the non-mirrored ZMC. Zygomaticomaxillary complex asymmetry is quantified by measuring the shortest distance between the surface of the original and mirrored ZMC at a multitude of points throughout the surface of the ZMC. The measure for ZMC asymmetry was defined as the mean surface distance (MSD) of all these points. A disadvantage of the methods described in these studies, is that areas adjacent to the ZMC or the ZMC-surface

From the Department of Oral and Maxillofacial Surgery, University Medical Center Utrecht, Utrecht, The Netherlands.

Received November 18, 2020.

Accepted for publication October 31, 2021.

Address correspondence and reprint requests to W.W.B. de Kort, MD, Department of Oral and Maxillofacial Surgery, University Medical Center Utrecht, PO box 85500, 3508 GA Utrecht, The Netherlands; E-mail: W.W.B.deKort-3@umcutrecht.nl

WDK and WMMTVH contributed equally to this work.

Ethical approval: All procedures performed in studies involving human participants were in accordance with the ethical standards of the institutional and/or national research committee and with the 1964 Helsinki declaration and its later amendments or comparable ethical standards.

The authors report no conflicts of interest.

Supplemental digital contents are available for this article. Direct URL citations appear in the printed text and are provided in the HTML and PDF versions of this article on the journal's Web site ([www.jcraniofacialsurgery.com](http://www.jcraniofacialsurgery.com)).

This is an open access article distributed under the terms of the Creative Commons Attribution-Non Commercial-No Derivatives License 4.0 (CCBY-NC-ND), where it is permissible to download and share the work provided it is properly cited. The work cannot be changed in any way or used commercially without permission from the journal. Copyright © 2021 The Author(s). Published by Wolters Kluwer Health, Inc. on behalf of Mutaz B. Habal, MD

ISSN: 1049-2275

DOI: 10.1097/SCS.00000000000008382

itself are used as reference-area to determine the symmetrical position of the mirrored ZMC. In this way the asymmetry of the ZMC itself is quantified, without considering the position of the ZMC within the viscerocranium. Moreover, in ZMC fractures these reference areas are often fractured and displaced, making them unsuitable as reference areas.

The aim of this study is to develop a reliable and accurate method of quantifying ZMC symmetry, taking into account both the asymmetry of the shape of the ZMC and the asymmetry of the position of the ZMC within the viscerocranium.

## MATERIALS AND METHODS

A cross-sectional anthropometric study was performed. The local ethics committee exempted this study from formal ethical review (reference number: 19-259/C)

### Data Selection

This study contained 2 groups of patients, 15 subjects without craniofacial or maxillofacial disorders (hereafter called “healthy cases”), and 38 patients with a ZMC fracture requiring surgical treatment (hereafter called “ZMC fracture cases”).

For the healthy cases, CT scans of the facial bones of 15 adult trauma patients were randomly selected. Inclusion criteria were: absence of fractures to the head and neck area, age > 18 years, CT scan performed with a maximum slice thickness of 1.0 mm and slice increment of 1.0 mm. Exclusion criteria were: presence of maxillo-facial fractures, congenital or acquired craniofacial disorders causing asymmetry.

For the ZMC fracture cases, the preoperative CT scan of patients that were included in a prospective cohort study were used. Inclusion criteria for the fracture group were: age > 18 years, unilateral ZMC fracture that requires surgical treatment. Exclusion criteria were: bilateral ZMC fractures, Le Fort II or III midfacial fractures, and mentally incompetent patients.

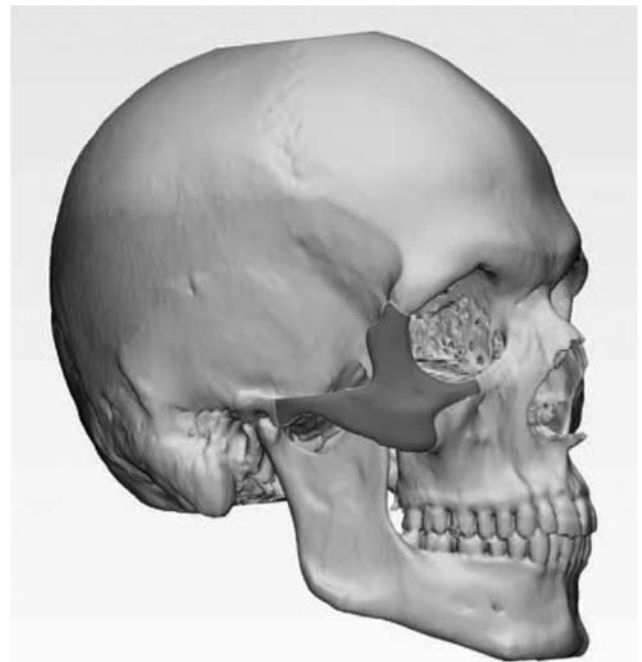### Analysis of Zygomaticomaxillary Complex Symmetry

The digital imaging and communications in medicine files of the CT scans were imported in Mimics Medical (version 20.0; Materialise, Leuven, Belgium). From each CT scan a virtual 3D model was created, which was exported in 3-Matic Medical (version 12.0, Materialise, Leuven, Belgium).

The outer surface of the left and right ZMC and the surface of the anterior cranial fossa (ACF) were selected in a standardized manner. The boundaries for defining the ZMC surface were the articular tubercle of the temporal bone dorsally, the orbital midline medially, the frontozygomatic suture cranially and the maxillozygomatic suture caudally (Fig. 1). The boundaries for defining the ACF surface were the dividing line between the ACF and the middle cranial fossa dorsally and a plane 1 cm above the superior orbital rim parallel to the Frankfurt Horizontal plane cranially (Fig. 2).

The created 3D model with the isolated ZMC-surfaces and ACF-surface is shown in Figure 3A. Subsequently, a mirrored duplicate of the entire 3D-model, including the ACF and ZMC surfaces was created (Fig. 3B).

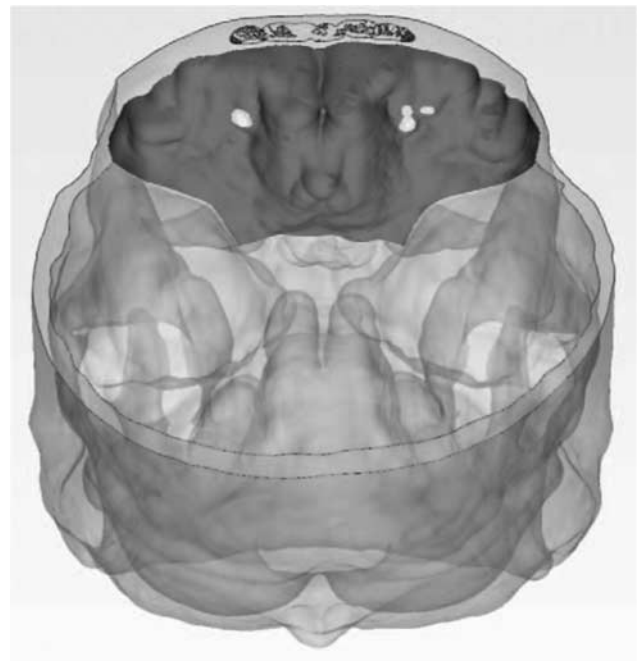
The mirrored 3D-model is then superimposed with the original 3D-model, using the ACF-surface as reference area (Fig. 3C). First, the mirrored ACF was matched roughly with the original ACF on 5 manually placed corresponding points on both objects. Then, the mirrored ACF-surface was matched to the best fit with the original ACF-surface by surface-based matching with an iterative closest point algorithm. A distance threshold of 5.0 mm and 100 iterations were used for the



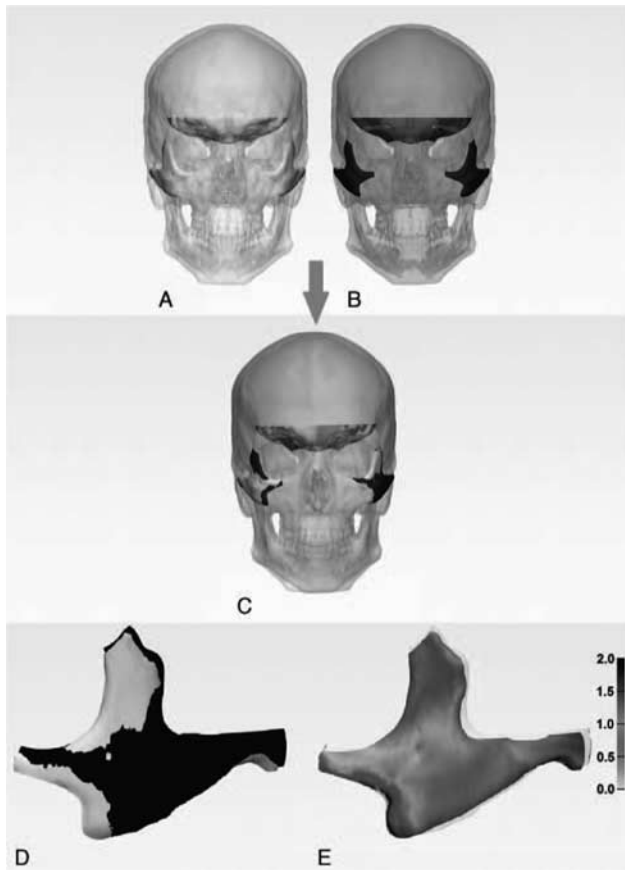
**FIGURE 1.** Boundaries used for isolating the ZMC surface. Dorsal boundary: articular tubercle of the temporal bone. Medial boundary: orbital midline. Cranial boundary: frontozygomatic suture. Medio-caudal boundary: zygomaticomaxillary suture. ZMC, zygomaticomaxillary complex.

surface-based matching; the matching process was repeated until a constant average surface distance was obtained.

During this alignment, the 3D spatial relation between the mirrored 3D-model (including the mirrored ZMC surfaces) and



**FIGURE 2.** Boundaries used for isolating the ACF surface. Cranial boundary: plane 1 cm above the superior orbital rim, parallel to the Frankfurt Horizontal plane. Dorsal boundary: dividing line between the ACF and the middle cranial fossa. ACF, anterior cranial fossa.



**FIGURE 3.** Overview of the method for measuring ZMC asymmetry. (A) Original 3D-model of the CT with the isolated ZMC and ACF surfaces. (B) Mirrored 3D-model of the CT with the isolated ZMC and ACF surfaces. (C) Mirrored 3D model (black) superimposed on original 3D model (grey) by surface-based matching of the mirrored ACF of the black model with the non-mirrored ACF-surface of the grey model. (D) Right-side mirrored ZMC-surface (black) projected over the left-side original ZMC-surface (grey) in the symmetrical position. (E) Surface distance analysis of the right-side mirrored ZMC-surface projected over the left-side original ZMC-surface, with distance map in millimeters. 3D, three-dimensional; ACF, anterior cranial fossa; CT, computed tomography; ZMC, zygomaticomaxillary complex.

the mirrored ACF was preserved. Consequently, the mirrored ZMC-surfaces made the same movement as the mirrored ACF and are thus projected over the non-mirrored ZMC-surfaces in the symmetrical position (Fig. 3D).

After alignment a surface distance analysis was carried out between the outer surfaces of the left-side ZMC and the mirrored right-side ZMC in the healthy cases (Fig. 3E). The surface distance analysis calculated the shortest distance from an average of 2.67 points per mm<sup>2</sup> on the left-side ZMC to the surface of the mirrored right-side ZMC. The outcome measures for ZMC symmetry were defined as the MSD in millimeters. In the ZMC-fracture cases a surface distance analysis was carried out between the outer surfaces of the fractured ZMC and the mirrored contralateral ZMC.

In the healthy cases, an additional surface distance analysis was performed to calculate the MSD between the ACF and the mirrored ACF, to evaluate the symmetry of the reference area.

In the healthy group, the 15 datasets were independently analyzed by 2 authors (WdK and WvH), 1 author (WdK) analyzed all datasets twice. In the ZMC fracture group, the 38

datasets were analyzed by 1 author (WdK). Both authors were trained to use Mimics and 3-Matic software

## Zygomaticomaxillary Complex Fracture Classification

The ZMC fracture classification that was used is based on the classification of Zingg et al,<sup>17</sup> it is described more extensively in a previous publication.<sup>18</sup> Incomplete ZMC fractures (A-type), complete ZMC fractures (B-type), and comminuted ZMC fractures (C-type) are distinguished. Fracture severity increases from A-type, to B-type, to C-type. The ZMC fractures were classified by the treating Oral and Maxillofacial Surgeon.

## Statistical Analysis

To assess reproducibility 2-way mixed intraclass correlation coefficients (CC) were calculated of the 15 healthy cases to quantify inter- and intra-observer agreement. A CC above 0.9 was considered excellent.<sup>19</sup>

The data on ZMC asymmetry in the healthy cases did not adhere to the normal distribution as it was skewed. After log-transformation the data was normally distributed. Consequently, several options exist for comparing ZMC asymmetry between the ZMC fracture cases and the healthy cases: a parametric test of the original data (independent samples T test), a nonparametric test of the original data (Mann-Whitney U-test), or a parametric test of the log-transformed data (independent samples T test). All these options gave the identical outcome.

Spearman rank correlation was used to determine the correlation between the ZMC fracture classification and ZMC asymmetry.

Statistical analysis was performed with SPSS Statistics (International Business Machines [IBM] Corporation. Released 2017.

IBM Statistical Package Social Sciences (SPSS) Statistics for Windows, Version 25.0. Armonk, NY: IBM Corp).

## RESULTS

In total 53 patients were included in this study; the patient characteristics are displayed in Supplementary Digital Content, Table 1, <http://links.lww.com/SCS/D578>.

## Zygomaticomaxillary Complex Symmetry

In the healthy cases, ZMC asymmetry expressed in MSD was 1.40 mm (standard deviation [SD] 0.54) on average.

In the ZMC fracture cases, MSD was 2.69 mm (SD 0.95) on average. In A-type fractures average MSD was 2.37 mm (SD 1.00), in B-type fractures average MSD was 2.69 mm (SD 0.88), and in C-type fractures average MSD was 3.33 mm (SD 0.79).

## Reliability

In healthy cases analysis of ZMC asymmetry was performed 3 times (Supplementary Digital Content, Table 2, <http://links.lww.com/SCS/D578>). The intra-rater CC was 0.97 with an intra-rater variability of  $0.09 \pm 0.11$  mm (95% confidence interval [CI] 0.03–0.15). The inter-rater CC was 0.95 with an inter-rater variability of  $0.12 \pm 0.13$  mm (95% CI 0.04–0.19).

## Accuracy

Zygomaticomaxillary complex asymmetry was higher in the ZMC fracture cases than in the healthy cases (MSD 1.40 versus 2.69 mm;  $P < 0.01$ ).

In the ZMC fracture cases, ZMC asymmetry correlated with the classification for ZMC fracture severity, increasing asymmetry was observed from A-type, to B-type, to C-type ZMC fractures ( $P = 0.01$ ).

## Symmetry of the Reference Area

The ACF asymmetry expressed in MSD was 0.70 mm (SD 0.12) on average.

## DISCUSSION

Analysis of ZMC symmetry on the 15 CT scans of the healthy cases showed a mean ZMC asymmetry of 1.40 mm MSD. The intra-rater CC was 0.97 with an intra-rater variability of 0.09 ± 0.11 mm (95% CI 0.03–0.15). The inter-rater CC was 0.95 with an inter-rater variability of 0.12 ± 0.13 mm (95% CI 0.04–0.19). The calculated inter- and intra-observer CC were >0.9, which indicates that the method is highly reproducible and thus reliable.

The accuracy of our method is more challenging to assess, as no gold standard exists for measuring ZMC symmetry. We confirmed that the outcome of the method correlated with the clinical perception of asymmetry, by comparing ZMC asymmetry in ZMC fracture cases that required surgical treatment (and thus deemed displaced by the clinician) with ZMC asymmetry in healthy cases. A statistically significant difference was observed (MSD 1.40 versus 2.69 mm;  $P < 0.01$ ). Additionally, we assessed whether the outcome of the method correlated with a classification for ZMC fracture severity. Increasing asymmetry was observed from A-type (2.37 mm), to B-type (2.69 mm), to C-type (3.33 mm) ZMC fractures ( $P = 0.01$ ). These findings indicate that the method is accurate.

There are 3 previous studies which assessed ZMC symmetry of the entire ZMC surface, in these studies an MSD ranging between 0.84 and 0.9 mm was found.<sup>14–16</sup> At 1.40 mm MSD our study measured a higher value for ZMC asymmetry. However, these 3 studies used methods in which the reference for placing the mirrored contralateral ZMC in the symmetrical position is the ZMC itself or a reference-area directly adjacent to the ZMC. Consequently, although these 3 studies are excellent in measuring the asymmetry of the ZMC itself, the asymmetry of the position of the ZMC within the viscerocranium is not taken into account. This might explain the lower MSD reported in these studies.<sup>14–16</sup>

In our study the ACF is used as reference-area for placing the mirrored contralateral ZMC in the symmetrical position. The ACF surface is selected so that a part of the object surface is perpendicular to all 3 axes. This helps in the reliable superimposing of the mirrored ACF on the original ACF with surface-based matching, as a deviation in any direction would cause an increase in surface distance. Additionally, Nada et al<sup>20</sup> reported that superimposing of 3D models derived from Cone Beam CT on the ACF is accurate and reproducible.

As previously addressed, by using the ACF as the reference area, the asymmetry of the position of the ZMC within the viscerocranium is reflected in the value for ZMC asymmetry. This is a key aspect to take into account, as the combination of the shape of the ZMC and the position of the ZMC defines cheek projection and is, therefore, an important factor for facial appearance.

In addition, in case of a ZMC fracture, the reference areas described in Ho et al 2016,<sup>14</sup> Ho et al 2017,<sup>15</sup> and Gibelli et al 2018<sup>16</sup> are distorted by the fracture, which is likely to influence the reliability of the method. This is less likely with the ACF as reference area as it is further away from the ZMC. In the 38 patients with a ZMC fracture used in this study, the ACF was intact in all cases. In addition, the ACF surface is larger and, therefore, the surface-based matching is likely to be less sensitive to minor distortions within the surface in case it has been affected by the trauma.

Asymmetry of the ACF was assessed in the 15 healthy cases to evaluate the symmetry of the reference area, the MSD between the original and mirrored ACF was 0.70 mm. This is less than 50% of the asymmetry of the ZMC.

Based on the arguments provided above and the excellent symmetry of the ACF we regard the ACF suitable to be used as reference area for measuring ZMC asymmetry.

The main limitation of our study is the way in which the surface distance is measured: from every point on the left-side ZMC the shortest distance to the surface of the mirrored right-side ZMC is calculated. In the ideal method, each point on the surface of the ZMC would be indexed with its corresponding point on the surface of the mirrored ZMC. The average distance between all corresponding points would better reflect the true ZMC asymmetry. The current method underestimates the ZMC asymmetry as the distance from a point on the ZMC to the corresponding point on the mirrored ZMC surface is often larger than the distance to the closest point on the mirrored ZMC surface.

To the best of our knowledge, all studies on this subject have been performed with this limitation as the described ideal method does not yet exist.

A second limitation of our method is that it is less suitable in cases with asymmetry at the level of the ACF. This might be the case in certain congenital craniofacial disorders.

## CONCLUSIONS

The proposed method is reliable and accurate for quantitative 3D-analysis of ZMC-symmetry. It takes into account both the asymmetry caused by the shape of the ZMC itself as well as asymmetry caused by the position of the ZMC within the viscerocranium.

## REFERENCES

- van Hout WMMT, van Cann EM, Abbink JH, et al. An epidemiological study of maxillofacial fractures requiring surgical treatment at a tertiary trauma centre between 2005 and 2010. *Br J Oral Maxillofac Surg* 2013;51:416–420
- Gupta AK, Garg R, Gupta A, et al. A retrospective analysis of 189 patients of maxillofacial injuries presenting to a tertiary care hospital in Punjab, India. *J Maxillofac Oral Surg* 2009;8:241–245
- Van Den Bergh B, Karagozoglu KH, Heymans MW, et al. Aetiology and incidence of maxillofacial trauma in Amsterdam: a retrospective analysis of 579 patients. *J Craniomaxillofac Surg* 2012;40:e165–e169
- Carinci F, Pezzetti F, Locci P, et al. Apert and Crouzon syndromes: Clinical findings, genes and extracellular matrix. *J Craniofac Surg* 2005;16:361–368
- Trainor PA, Dixon J, Dixon MJ. Treacher Collins syndrome: etiology, pathogenesis and prevention. *Eur J Hum Genet* 2009;17:275–283
- Kassel EE, Noyek AM, Cooper PW. CT in facial trauma. *J Otolaryngol* 1983;12:2–15
- Manson PN, Markowitz B, Mirvis S, et al. Toward CT-based facial fracture treatment. *Plast Reconstr Surg* 1990;85:202–212
- Furst IM, Austin P, Pharoah M, et al. The use of computed tomography to define zygomatic complex position. *J Oral Maxillofac Surg* 2001;59:647–654
- Khaqani MS, Tavosi F, Gholami M, et al. Analysis of facial symmetry after zygomatic bone fracture management. *J Oral Maxillofac Surg* 2018;76:595–604
- Belcastro A, Willing R, Jenkyn T, et al. A three-dimensional analysis of zygomatic symmetry in normal, uninjured faces. *J Craniofac Surg* 2016;27:504–508
- Park SH, Yu HS, Kim KD, et al. A proposal for a new analysis of craniofacial morphology by 3-dimensional computed tomography. *Am J Orthod Dentofacial Orthop* 2006;129:600.e23–600.e34

12. Ellis E, Kittidumkerng W. Analysis of treatment for isolated zygomaticomaxillary complex fractures. *J Oral Maxillofac Surg* 1996;54:386–400
13. Ludlow JB, Gubler M, Cevidanes L, et al. Precision of cephalometric landmark identification: cone-beam computed tomography vs conventional cephalometric views. *Am J Orthod Dentofacial Orthop* 2009;136:1–10
14. Ho JPTF, Schreurs R, Milstein DMJ, et al. Measuring zygomaticomaxillary complex symmetry three-dimensionally with the use of mirroring and surface based matching techniques. *J Craniomaxillofac Surg* 2016;44:1706–1712
15. Ho JPTFF, Schreurs R, Aydi S, et al. Natural variation of the zygomaticomaxillary complex symmetry in normal individuals. *J Craniomaxillofac Surg* 2017;45:1927–1933
16. Gibelli D, Cellina M, Gibelli S, et al. Assessing symmetry of zygomatic bone through three-dimensional segmentation on computed tomography scan and “mirroring” procedure: a contribution for reconstructive maxillofacial surgery. *J Craniomaxillofac Surg* 2018;46:600–604
17. Zingg M, Laedrach K, Chen J, et al. Classification and treatment of zygomatic fractures: a review of 1,025 cases. *J Oral Maxillofac Surg* 1992;50:778–790
18. van Hout WMMT, van Cann EM, Koole R, et al. Surgical treatment of unilateral zygomaticomaxillary complex fractures: a 7-year observational study assessing treatment outcome in 153 cases. *J Craniomaxillofac Surg* 2016;44:1859–1865
19. Koo TK, Li MY. A guideline of selecting and reporting intraclass correlation coefficients for reliability research. *J Chiropr Med* 2016;15:155–163
20. Nada RM, Maal TJJ, Breuning KH, et al. Accuracy and reproducibility of voxel based superimposition of cone beam computed tomography models on the anterior cranial base and the zygomatic arches. *PLoS One* 2011;6:e16520

