



# The effect of meatal correction on daytime urinary incontinence in girls with an anterior deflected urinary stream

<sup>a</sup>Department of Urology, UMC Utrecht, the Netherlands

<sup>b</sup>Department of Medical Psychology and Urology, Wilhelmina Children's Hospital, University Medical Center Utrecht, Utrecht, the Netherlands

<sup>c</sup>Department of Development and Education of Youth in Diverse Societies, Utrecht University, the Netherlands

<sup>d</sup>Department of Pediatric Urology, Wilhelmina Children's Hospital, University Medical Center Utrecht, the Netherlands

\* Correspondence to: Frank-Jan van Geen, Department of Urology, UMC Utrecht, the Netherlands  
[f.vangeen-2@umcutrecht.nl](mailto:f.vangeen-2@umcutrecht.nl)  
(F.-J. van Geen)

## Keywords

LUTS; Paediatric; Urinary incontinence; Meatal anomaly; Meatotomy

Received 3 February 2021

Revised 27 August 2021

Accepted 28 August 2021

Available online 3 September 2021

Frank-Jan van Geen <sup>a,\*</sup>, Anka J. Nieuwhof-Leppink <sup>b</sup>,  
Renske Schappin <sup>c</sup>, Aart J. Klijn <sup>d</sup>, Laetitia M.O. de Kort <sup>a</sup>

## Summary

### Introduction

Girls with an anterior deflected urinary stream (ADUS) are known to wet the toilet rim and their buttocks while voiding. This deviation may prevent adopting an ideal toileting position and can thus develop into a functional voiding disorder. Although surgical correction of the urinary stream by a meatotomy is part of standard care in girls with ADUS and lower urinary tract symptoms (LUTS) at our center, little is known about the effect of this procedure on daytime urinary incontinence (DUI).

### Objective

To assess the effect of meatal correction on incontinence in girls with ADUS and DUI, and to find predictors for therapy success.

### Study design

A retrospective chart study including all girls with ADUS and DUI who underwent a dorsally directed meatal correction at our tertiary referral center between 2005 and 2018 ( $n = 274$ ). The main outcome measurement was continence according to the International Children's Continence Society criteria, expressed as the percentage of children that were continent at post-surgical follow-up (complete response). Multivariate logistic regression was used to identify predictors of continence.

### Results

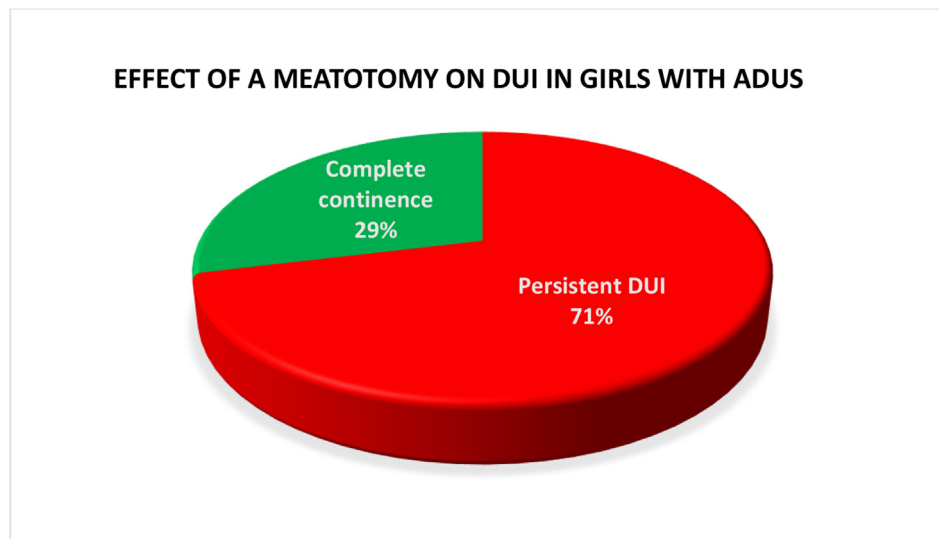
In 93% of girls, the direction of the urinary stream was no longer anterior deflected. 29% ( $n = 79$ ) of all girls were continent at post-surgical follow-up. We could not find a convincing predicting factor for achieving continence.

### Discussion

Although meatal correction is successful on normalizing the direction of the urinary stream, less than one-third of girls became continent. In addition, we were unable to indicate which girls will profit from this procedure in terms of continence. Since not every girl with ADUS develops incontinence complaints, it may also be questionable whether ADUS and incontinence are directly related. Since other, less invasive and more effective treatment options for DUI are available, meatal correction should therefore be considered a last-resort option in the treatment of pediatric DUI in girls with ADUS.

### Conclusion

Of the 274 girls with ADUS and DUI, 29% did benefit from a meatotomy. No convincing indicator for therapy success could however be found. Therefore, we discourage a meatotomy as standard treatment in girls with ADUS and DUI.



Summary Figure Treatment outcome.

## Introduction

Girls with an anterior deflected urinary stream (ADUS) are known to wet the toilet rim and their buttocks while voiding. This deflection of the urinary stream can be caused by a minimal meatal anomaly (ie. meatal web) [1]. Although no exact prevalence figures are known, several reports since 1999 have described the correlation of ADUS with lower urinary tract symptoms (LUTS) such as urinary tract infections (UTIs), urgency and daytime urinary incontinence (DUI) [1–3]. The proposed mechanism behind this relation is that girls with ADUS try to avoid voiding over the toilet rim. To achieve this, they tend to assume a hovering position while voiding, making proper relaxation of the pelvic floor muscles more difficult [2]. It is therefore thought that functional voiding disorders may be triggered by the experienced inability to void in the ideal toileting posture, causing a functional bladder outlet obstruction [2,3].

Although urotherapy is nowadays recognized to be the first-line treatment for all types of LUTS in children [4], surgical correction of the urinary stream had been previously suggested as treatment option in 1999 by Hoebeke et al. having established a correlation between ADUS and LUTS [1]. It is believed that this minimally invasive procedure could improve the direction of the urinary stream allowing girls to incorporate an adequate upright position and relax the pelvic floor musculature while voiding. Klijn et al. evaluated the effect of incising the meatal web on UTIs and voiding patterns in girls with ADUS and urodynamically confirmed dysfunctional voiding (DV; [2]). They found a significant relief on recurrent UTIs and normalized voiding patterns in 50% of girls ( $n=33$ ) at post-operative follow-up 5 months after the procedure, with no need for further treatment. The effect on DUI, a common problem that affects approximately 7–10% of children [5], was however less clear.

At our tertiary referral center surgical correction of the urinary stream has become part of standard care in girls

with ADUS and refractory LUTS in order to achieve continence, before they are enrolled into a specific urotherapy program [6]. We wanted to evaluate this practice, by investigating whether improving the urinary stream by meatotomy is an effective procedure for achieving continence in girls with ADUS and DUI, making further therapy in the majority of girls unnecessary. The aim of this study was therefore to assess the effects of meatal correction on DUI in girls with ADUS. In addition, we tried to find baseline indicators for therapy success.

## Material and methods

The present study was exempt from the Dutch Medical Research Involving Human Subjects Act by the Institutional Review Board of the University Medical Centre Utrecht.

In a retrospective study all girls with ADUS and DUI who underwent a dorsally directed meatal correction between 2005 and 2018 at our institution were considered for inclusion, resulting in  $N=274$  eligible patients. Excluded were children with urological anatomical abnormalities other than a minimal meatal anomaly causing ADUS or neurological causes of DUI. Analysis of a neurogenic bladder was based on history and physical examination (inspection of the lower lumbar region, testing of the reflexes of the lower limbs and assessment of the mobility and reflexes of the pelvic floor).

A medical chart study was conducted and data were retrieved from before treatment, during surgery and at post-operative outpatient discharge (3–6 months after the procedure). Data on medical history, LUTS questionnaires, physical examination, uroflowmetry and peroperative findings were collected. DUI was assessed according to de International Children's Continence Society (ICCS) [7]. Patient characteristics are presented in Table 1.

ADUS was defined as a clear history of wetting the toilet rim through an anterior deflection of the urinary stream and a meatal web at physical examination [1–3]. All girls

**Table 1** Patient characteristics N=274.

	N = 274
Age at surgery in years (st. dev.)	7.70 (2.04)
<i>Patient history:</i>	
Days with DUI/week	6.65
Urgency	162 (70%)
Recurrent UTIs	139 (51%)
Previous urotherapy	100 (37%)
<i>Physical examination &amp; uroflowmetry</i>	
Dysfunctional flow pattern	101 (53%)
Post micturition residue	104 (39%)
Generalised joint hypermobility	134 (56%)
<i>Perioperative findings:</i>	
Urethral diameter in French before calibration	18.00
Trabeculation of the bladder wall	214 (78%)

received instructions previously on the toileting position during voiding. A dysfunctional flow pattern was defined as a staccato or interrupted pattern at uroflowmetry. Since EMG activity of the pelvic floor during voiding was not routinely monitored, we could not meet all diagnostic criteria for DV as stated in the ICCS standardization paper [7]. Due to the overlap in symptomatology, we did not make a further differentiation based on diagnosis.

During surgery under general anesthesia and caudal block, as described by Klijn et al. [2], the meatus was inspected and the direction of the urinary stream was assessed by manually performing pressure on a full bladder. The diameter of the urethra was determined by calibration with bougies. In case of a visible web and anterior deflected stream, the meatus was incised 3–5 mm in the 6 o'clock position. Subsequently urethral calibration was done and

**Table 2** Responders vs non-responders.

	Complete response N = 79 (29%)	Persistent DUI N = 195 (71%)	P-value
Age at surgery (in years)	7.80	7.65	>0.05
<i>Patient history:</i>			
Days with DUI/week	6.40	6.75	>0.05
Urgency	34 (57%)	128 (74%)	>0.05
Recurrent UTIs	43 (54%)	96 (49%)	>0.05
Previous urotherapy	20 (25%)	80 (41%)	.018
<i>Physical examination &amp; uroflowmetry</i>			
Dysfunctional flow pattern	34 (62%)	67 (50%)	>0.05
Post micturition residue	25 (32%)	79 (41%)	>0.05
Generalised joint hypermobility	35 (76%)	99 (51%)	>0.05
<i>Perioperative findings:</i>			
Urethral diameter in French before calibration	17.50	18.00	>0.05
Trabeculation of the bladder wall	58 (73%)	156 (80%)	>0.05
<i>Operative findings:</i>			
ADUS after meatotomy	2 (2.5%)	15 (7.7%)	>0.05

**Table 3** Multiple logistic regression analyses predicting the change of being continent after meatotomy; Pooled data.

Covariable	Odds ratio (95% CI)	P ( $\chi^2$ )
Age at surgery (in years)	.99 (.98–1.00)	.123
Recurrent UTIs	.71 (.40–1.26)	.247
Previous urotherapy	2.00 (1.06–3.77)	.033*
Dysfunctional flow pattern	1.64 (.75–3.60)	.205
Post micturition residue	1.62 (.70–3.73)	.244
Generalised joint hypermobility	1.19 (.62–2.27)	.602
Urethral diameter in French before calibration	1.12 (1.00–1.25)	.060
Trabeculation of the bladder wall	1.69 (.79–3.64)	.178

the direction of the urinary stream was observed again. Three to six months after surgery DUI was assessed and uroflowmetry performed. In case of persistent incontinence specific urotherapy was offered [6,8].

### Outcome measures

Primary outcome was treatment response on DUI, expressed as the percentage of girls that were continent at post-surgical follow-up. Results were measured as an improvement from baseline and quantified in accordance with the ICCS standardization paper [7]. Responders are defined as having achieved complete continence.

### Statistical analysis

Univariate baseline differences between responders and non-responders were compared on treatment on DUI using the students T-test for normally distributed ordinal or continuous variables, the Mann–Whitney *U* test for not normally distributed continuous or ordinal variables, and the Fisher exact test for categorical variables. To explore predictors for treatment success, multivariate logistic regression analysis was used to evaluate if any of the related variables could predict treatment outcome on DUI. Missing data was before performing analyses replaced with substituted values (missing data imputation). In all tests, the level of statistical significance was predefined at  $p < 0.05$  (two-sided). Statistical analyses were performed using IBM Statistical Package for Social Sciences software (version 27, SPSS).

### Results

In 93% of girls, the direction of the urinary stream was no longer anteriorly deflected after meatal correction. Continence was achieved in 29% ( $n = 79$ ) of all cases.

Further patient characteristics per group (responders vs non-responders) at baseline, during surgery and post-surgical follow-up are presented in Table 2. Except for a medical history stating former urotherapy, no significant differences were found when comparing responders and non-responders.

In 123 of the 195 girls with persistent DUI after meatotomy, specific urotherapy was offered; 71 (58%) of these girls did the inpatient program, 52 followed an outpatient program. In 93 (76%) of all girls a good or improved result was achieved.

Multivariate logistic regression analysis was performed to assess whether it could be predicted that children became continent after meatotomy, see Table 3. Days with DUI/week was excluded as a predictor from these analyses as it had too little variance (90% of children had 7 days with DUI/week). The model fitted the data well (Hosmer Lemeshow goodness-of-fit = 0.39). Only a medical history stating former urotherapy showed to be a significant predictor for therapy success (odds ratio 2.00). The pseudo  $R^2$  (Nagelkerke) was 0.08, indicating that the model poorly predicted variability in continence. We were also unable to correctly classify individual cases based upon the model.

## Discussion

Our results show that a meatotomy is effective on correcting the direction of the urinary stream in girls with ADUS and DUI. However, less than one-third of girls became continent after meatotomy. Although several baseline characteristics (including flow pattern, UTIs and post-void residual) and per-operative findings were analyzed, no convincing indicator for therapy success could be found.

Comparison of our data with other studies is difficult. Although Klijn et al. reported normalized voiding patterns with no need for further treatment in 50% of girls, they did not focus on DUI, had a small sample size and only included girls with urodynamically proven DV [2]. In this study a dysfunctional voiding pattern appeared not to be predictive for postoperative success. Apoznanski et al. found no statistical difference when conservative treatment with oxybutynin in girls with ADUS and an overactive bladder (OAB) was compared to a meatal correction [3]. He did however not quantify DUI according to the ICCS standardization criteria.

A substantial group of the girls we evaluated remained dependent on urotherapy for DUI and achieved herein cure-rates that are comparable with an earlier report on incontinent girls without ADUS that did not undergo a meatal correction [6,9–11], lacking evidence for a clear added value of meatotomy to further urotherapeutic treatment. Based on the sparse available literature it has to be noted that not all children with ADUS experience DUI [2,12]. Considering normalization of the urinary stream in our study did also not lead to a complete response on DUI in the majority of girls, it has to be questioned whether a causal relationship between ADUS and incontinence exists at all.

Since only 29% achieved complete continence and we were not able to find predictors to improve our patient selection, we believe that meatal correction should not be part of standard care in girls with ADUS and DUI when continence is pursued. The invasive nature of the treatment, hospitalization and necessary anesthesia can no longer be justified from an ethical point of view when other, less invasive and more effective treatment options for DUI have not been explored. Our inpatient urotherapy program has for example shown to be effective on its own,

in standard therapy refractory children with LUTS [13]. Given that incontinence may severely reduce quality of life [5] and brings children at risk of social isolation [14,15], meatotomy may however still be considered as last-resort option in the treatment of DUI in girls with ADUS.

The main limitation of this study is the retrospective, non-randomized design. In our opinion this was the best possible study design we could practically carry out. A multi-centre comparison was not possible because of differences in applied standard care. Based on ethical grounds a prospective study would, given our results, not be approved by an institutional review board committee. Because of the limited follow-up period, we might have missed long-term effects of the meatotomy. As patients suffered for a long time of ADUS, it might take a longer period before secondary changes are restored. Furthermore, defining whether a girl had ADUS was a subjective consideration dependent on the judgment of the pediatric urologist, as was the decision to incise the meatal web. Because of the retrospective nature of our study, we could only define complete continence as therapy success. Another limitation could be that a dysfunctional flow pattern was assessed with a free uroflowmetry, without pressure flow study and pelvic floor electromyographic study, making it less accurate.

## Conclusion

Of the 274 girls with ADUS and DUI, only 29% achieved continence after meatotomy. No convincing indicator for therapy success could however be found. Therefore, we discourage a meatotomy as standard treatment in girls with ADUS and DUI, when continence is pursued. It should only be considered in therapy-resistant girls as last-resort option after conservative treatment has failed. A clear expectation of success should be discussed with the patient and parents leading to shared decision-making.

## Funding

None.

## Conflicts of interest

None.

## References

- [1] Hoebeke P, Van Laecke E, Raes A, Van Gool JD, Vande Walle J. Anomalies of the external urethral meatus in girls with non-neurogenic bladder sphincter dysfunction. *BJU Int* 1999;83.
- [2] Klijn AJ, Bochove-Overgaauw D, Winkler-Seinstra PL, Dik P, De Jong TPVM. Urethral meatus deformities in girls as a factor in dysfunctional voiding. *Neurourol Urodyn* [Internet] 2012;31: 1161–4 [cited 2020 Apr 29]. Available from: <http://wileyonlinelibrary.com/journal/nau>.
- [3] Apoznanski W, Polok M, Rysiakiewicz J. An evaluation of the effectiveness of external urethral meatus incision in girls with an anterior deflected urinary stream and symptoms of detrusor overactivity [Internet]. [cited 2020 Apr 29]. Available from: <http://www.advances.umed.wroc.pl/pdf/2014/23/2/283.pdf>.

- [4] Chang S-J, Van Laecke E, Bauer SB, von Gontard A, Bagli D, Bower WF, et al. Treatment of daytime urinary incontinence: a standardization document from the International Children's Continence Society. *Neurourol Urodyn* [Internet] 2017 Jan; 36(1):43–50. <https://doi.org/10.1002/nau.22911> [cited 2018 Jan 26]. Available from: .
- [5] Nieuwhof-Leppink AJ, Schroeder RPJ, van de Putte EM, de Jong TPVM, Schappin R. Daytime urinary incontinence in children and adolescents [Internet]. In: *The lancet child and adolescent health*, vol. 3. Elsevier B.V.; 2019. p. 492–501 [cited 2020 Aug 8]. Available from: <https://pubmed.ncbi.nlm.nih.gov/31060913/>.
- [6] Meijer EFJ, Nieuwhof-Leppink AJ, Dekker-Vasse E, de Joode-Smink GCJ, de Jong TPVM. Central inhibition of refractory overactive bladder complaints, results of an inpatient training program. *J Pediatr Urol* [Internet] 2015 Feb;11(1):21.e1–5 [cited 2018 Jan 26]. Available from: <http://linkinghub.elsevier.com/retrieve/pii/S1477513114002216>.
- [7] Austin PF, Bauer SB, Bower W, Chase J, Franco I, Hoebeke P, et al. The standardization of terminology of lower urinary tract function in children and adolescents: update report from the standardization committee of the International Children's Continence Society. *Neurourol Urodyn* [Internet] 2016 Apr; 35(4):471–81 [cited 2018 Apr 16]. Available from: <http://www.ncbi.nlm.nih.gov/pubmed/25772695>.
- [8] Vijverberg MA, Elzinga-Plomp A, Messer AP, van Gool JD, de Jong TP. Bladder rehabilitation, the effect of a cognitive training programme on urge incontinence. *Eur Urol* [Internet] 1997;31(1):68–72 [cited 2018 Apr 16]. Available from: <http://www.ncbi.nlm.nih.gov/pubmed/9032538>.
- [9] Oktar T, Dönmez Mİ, Özkuvancı Ü, Ander H, Ziyilan O. Animated versus non-animated biofeedback therapy for dysfunctional voiding treatment: does it change the outcome? *J Pediatr Surg* [Internet] 2018 Apr 1;53(4):825–7 [cited 2020 Aug 8]. Available from: <https://pubmed.ncbi.nlm.nih.gov/28648880/>.
- [10] Drzewiecki BA, Kelly PR, Marinaccio B, Borer JG, Estrada CR, Lee RS, et al. Biofeedback training for lower urinary tract symptoms: factors affecting efficacy. *J Urol* [Internet] 2009; 2050–5. Elsevier [cited 2020 Aug 8]. Available from: <https://pubmed.ncbi.nlm.nih.gov/19695584/>.
- [11] Schäfer SK, Niemczyk J, von Gontard A, Pospeschill M, Becker N, Equit M. Standard urotherapy as first-line intervention for daytime incontinence: a meta-analysis [Internet]. In: *European child and adolescent psychiatry*, vol. 27. Dr. Dietrich Steinkopff Verlag GmbH and Co. KG; 2018. p. 949–64 [cited 2020 Aug 8]. Available from: <https://pubmed.ncbi.nlm.nih.gov/28948380/>.
- [12] Abbas W, Woodward M, Shalaby MS. Anterior deflected urinary stream. 2017. <https://doi.org/10.1016/j.jpuro.2017.08.008> [cited 2020 Apr 29]; Available from: .
- [13] Nieuwhof-Leppink AJ, van Geen F-J, van de Putte EM, Schoenmakers MAGC, de Jong TPVM, Schappin R. Pelvic floor rehabilitation in children with functional LUTD: does it improve outcome? *J Pediatr Urol* 2019;15(5).
- [14] Thibodeau BA, Metcalfe P, Koop P, Moore K. Urinary incontinence and quality of life in children. *J Pediatr Urol* [Internet] 2013 Feb;9(1):78–83 [cited 2020 Aug 8]. Available from: <https://pubmed.ncbi.nlm.nih.gov/22236468/>.
- [15] Veloso LA, Mello MJG de, Ribeiro Neto JPM, Barbosa LNF, Silva EJ da CE. Quality of life, cognitive level and school performance in children with functional lower urinary tract dysfunction. *J Bras Nefrol* [Internet] 2016 Jun 1;38(2):234–44 [cited 2020 Aug 8]. Available from: <https://pubmed.ncbi.nlm.nih.gov/27438979/>.