European Journal of Paediatric Neurology 35 (2021) 82–92

Contents lists available at ScienceDirect

European Journal of Paediatric Neurology

Genetic causes underlying grey matter heterotopia

Ilona Vriend, Renske Oegema*

Department of Genetics, University Medical Center Utrecht, Utrecht University, Utrecht, the Netherlands

ARTICLE INFO

Article history:
Received 31 May 2021
Accepted 21 September 2021

Keywords:
Brain malformations
Malformations of cortical development
Periventricular nodular heterotopia
Subcortical band heterotopia
Genetics
FLNA

ABSTRACT

Grey matter heterotopia (GMH) can cause of seizures and are associated with a wide range of neurodevelopmental disorders and syndromes. They are caused by a failure of neuronal migration during fetal development, leading to clusters of neurons that have not reached their final destination in the cerebral cortex.

We have performed an extensive literature search in Pubmed, OMIM, and Google scholar and provide an overview of known genetic associations with periventricular nodular heterotopia (PNVH), subcortical band heterotopia (SBH) and other subcortical heterotopia (SUBH). We classified the heterotopias as PVNH, SBH, SUBH or other and collected the genetic information, frequency, imaging features and salient features in tables for every subtype of heterotopia. This resulted in 105 PVNH, 16 SBH and 25 SUBH gene/locus associations, making a total of 146 genes and chromosomal loci.

Our study emphasizes the extreme genetic heterogeneity underlying GMH. It will aid the clinician in establishing an differential diagnosis and eventually a molecular diagnosis in GMH patients. A diagnosis enables proper counseling of prognosis and recurrence risks, and enables individualized patient management.

Introduction

Grey matter heterotopia (GMH) also known as neuronal heterotopia can be detected on brain imaging of patients presenting with developmental delay, spasticity, seizures and/or other congenital abnormalities, or even as an incidental finding. As the presenting features are broad and non-specific, this finding can come as a surprise to both the patient and the physician and often raises questions of clinical significance and the underlying cause.

GMH are classified into the group of neuronal migration disorders in which the neuronal precursors do not migrate correctly from the origin alongside the ventricles deep inside the brain to their final destination in the developing brain cortex. Heterotopia are primarily classified according to their location, and secondarily on morphology and associated structural abnormalities ([1,2].

The most common type is periventricular nodular heterotopia (PVNH, formerly known as subependymal heterotopia) which consists of one or more grey matter nodules lining the ventricular wall [3]. Another type, subcortical band heterotopia (SBH), which has also been named double cortex, consists of a thick or thin smooth band-like heterotopia present within the white matter. It is separated from both the ventricle and the –usually normal appearing - cortex by a white matter layer [4,5]. SBH is considered part of the lissencephaly spectrum, and is distinct in morphology and etiology from other subcortical heterotopia e.g. subcortical curvilinear heterotopia and subcortical nodular heterotopia [2]. The curvilinear heterotopia with CFS-like spaces are usually large and asymmetric malformations, with un unstructured morphology with swirling, massive and/or a nodular appearance. They extend from the ventricular surface to the cortex, and with careful review, CSF-like inclusions can been identified [2]. Several other rare heterotopia subtypes exist, most of which have limited descriptions in the medical literature and are therefore poorly defined.

Over the years many different genes and syndromes have been associated with the different forms of heterotopia. The comprehensive MCD classification published by Barkovich et al., in 2012 lists 200 MCD subtypes, both with and without associated genetic etiology [1]. The MCD is listed according to its main abnormality, e.g. microcephaly, cobblestone malformation, etc. It includes 26 heterotopia subtypes, 9 of which had a known genetic cause. The Neuro-MIG group recently proposed a diagnostic workup for MCD

Abbreviations: GMH, Grey matter heterotopia; PVNH, periventricular nodular heterotopia; SBH, subcortical band heterotopia; SUBH, subcortical heterotopia; MCD, malformations of cortical development.

* Corresponding author. Department of Genetics, UMC Utrecht, Postbus 85060, 3508 AB, Utrecht, the Netherlands.
E-mail address: r.oegema@umcutrecht.nl (R. Oegema).

https://doi.org/10.1016/j.ejpn.2021.09.015

patients, including a gene list for a dedicated next-generation sequencing MCD gene panel of 212 genes. In this lists 16 genes were associated with PVNH, and two genes with other types of heterotopia [6]. Chromosomal loci were not systematically listed in this study. However, chromosomal abnormalities have been frequently associated with GMH, a recent study performing array-CGH found potential causal CNVs in 15 of 42 (35.7%) PVNH patients [7]. For both PVNH and subcortical curvilinear heterotopia, a non-genetic etiology has been proposed for some patients [2,8].

As far as we know there is no up-to-date overview for all CNVs and genes associated with various forms of GMH. Therefore the aim of this study was to perform an extensive literature review and provide a list of all genetically-associated GMH. We found a surprisingly large number of genetic associations. Together with the key imaging and clinical features associated with these disorders, this will aid the clinician in choosing a diagnostic strategy and reaching an etiological diagnosis which is important for estimating individual prognosis and recurrence risks.

2. Methods

We performed a NCBI PubMed search with the following search term: ((“Periventricular Nodular Heterotopia"[Mesh]) OR (“Classical Lissencephalies and Subcortical Band Heterotopias"[Mesh]) OR (Subcortical heterotopia)) AND ((gene-) OR (genetic*) OR (chromosome*)). This search has been restricted to publications written in English that were published before 22.01.21. We read the abstracts and discarded the irrelevant publications. The exclusion criteria were abstracts that solely focused on heterotopia found in animal models, abstracts that mentioned that no syndrome/genetic cause for heterotopia has been found and non-neuronal heterotopias. Thus only publications that mention cortical heterotopia in human subjects with a known syndrome or genetic cause were included and further examined.

Secondly we performed an OMIM search with the search term: “Heterotopia” and the sources that mentioned “heterotopia” on 25.01.21 were consulted in order to further expand the scope of this review. Every publication was assessed based on their abstract and discarded or included based on the same criteria as the PubMed articles.

Thirdly we further examined all the collected relevant publications, we also assessed their references based on the same exclusion criteria as noted above. Concurrently we performed a Google scholar search for every disorder using the search term: (disorder/syndromes/genes)+(heterotopia) in which the first 10 results were looked into. Next we reviewed the “cited by” section on PubMed for additional relevant articles. Both of these searches aimed to find additional cases for every disorder/gene that had been associated with heterotopia. Furthermore additional publications were included that were deemed relevant based on personal experience of the author (RO). We reviewed the published neuroimaging for a correct heterotopia classification. When neuroimaging was not available (e.g. the diagnosis was only mentioned in the text) this was indicated in the table with an *.

3. Results

The NCBI PubMed search resulted in 389 publications with 189 abstracts fulfilling our criteria. These papers led to a list of 70 unique syndrome/gene associations with heterotopia. The OMIM search resulted in 169 hits and led to 41 new relevant publications bringing the total to 97 unique syndrome/gene associations with heterotopia. All the relevant publications found so far (n = 230) their references on heterotopia were further assessed in the same way as the previously found publications. In addition all the unique “disease names/syndromes/genes” were searched in combination with “heterotopia” in google scholar and the first 10 results were examined in the same way as the other publications. Concurrently we checked the “cited by” section on PubMed for relevant articles in order to include more relevant case reports. Lastly publications and cases that were not found within the extensive search but were deemed relevant by the author based on personal experience were included. We classified the heterotopias as PVNH, SBH, SUBH or other and collected the genetic information, frequency, imaging features and salient features in tables for every subtype of heterotopia. This resulted in 105 PVNH, 16 SBH and 25 SUBH other gene/locus associations, making a total of 146 genes/loci. Several genes are listed multiple times, as they were associated with multiple heterotopia types. In Tables 1–3, associations reported in two or more patients are listed. In Supplementary Tables 1–3, associations reported in a single patient are listed.

4. Discussion

4.1. Periventricular nodular heterotopia

With 45 multiple and 60 single associations identified our study emphasizes the genetic heterogeneity underlying PVNH. Due to its relative frequency and the risk of systematic complications it is important to carefully look for signs of *FLNA*-related, X-linked periventricular heterotopia. Its imaging pattern is rather specific and characterized by bilateral multiple heterotopia lining the lateral ventricles, in combination with especially with mega cisterna magna/cerebellar hypoplasia and corpus callosum abnormalities (Fig. 1) [9,10]. Affected individuals are usually females with average cognitive abilities who present with seizures. They are at risk for cardiovascular disease including patent ductus arteriosus; dilatation and rupture of the thoracic aorta; atrial and ventricular septal defects; valvular dystrophy; and vasculopathy and/or coagulopathy leading to stroke [10]. Furthermore pulmonary disease leading to respiratory failure has been described in several individuals [9,10].

ARGEF2 mutations also cause extensive bilateral PVNH, but the clinical presentation is very distinct from FLNA-related PVNH. Patients have severe ID, spastic quadriplegia, progressive microcephaly, and several have been reported to develop cardiomyopathy [11–13]. It is rare disorder and the inheritance is autosomal recessive, males and females are therefore equally affected. On brain imaging PVNH, cerebral atrophy, abnormal intensity of the putamen, hippocampal atrophy, and thin corpus callosum can be noted (Fig. 1) [11–13]. Two other rare but high-penetrance PVNH genes are *NEDD4L* and *MAP1B*. Mutations in *NEDD4L* cause a syndrome with bilateral PVNH combined with polymicrogyria in several patients, and neurodevelopmental delay, syndactyly and cleft palate [14–17]. Heterozygous *MAP1B* mutations cause frontal predominant PVNH, with or without polymicrogyria and hypoplastic corpus callosum [18–20]. The clinical features have not been extensively reviewed, but appear to be ID and seizures, and possible microcephaly [18–20].

Ten chromosomal abnormalities have been described as a recurrent cause of PNVH, and in addition 22 chromosomal abnormalities have been associated with a single case (Table 1, Fig. 1, Table S1). For several loci a putative causal gene was identified, as single nucleotide variants in these genes cause a similar phenotype as large chromosomal deletions. Both deletions of 17p11.2 and SNVs of *RAI1*, the critical gene within this region, cause Smith Magenis syndrome, a syndrome characterized by intellectual disability, problems with sleep and behavior, and distinct facial features [21]. PVNH has been noted in several patients (Fig. 1), but does not seem in common feature in this syndrome [22,23]. A deletion involving

Table 1
Genes and loci associated with PVNH.

Disorder	Gene	Cytogenetic location	Inheritance	OMIM	Frequency	Imaging features	Clinical features	Refs
Agenesis of corpus callosum, cardiac, ocular, and genital syndrome	*CDH2*	18q12.1	AD	618929	5/13 cases	PVNH, ACC	global DD/ID, mirror movements, Duane anomaly, ocular, cardiac, and genital anomalies.	[40,41]
Aicardi syndrome	Etiology unknown	Possibly Xp22	XLD	304050	common (+3 cases of SUBH, +2 cases of SBH)	extensive abnormalities including uni/bilateral PVNH, SUBH, SBH, polymicrogyria, ACC, cysts	severe DD/ID, dysmorphism, seizures (incl. infantile spasms), chorioretinal lacunae	[42,43]
Au-Kline syndrome	*HNRNPK*	9q21.32	AD	616580	2/11 cases	PVNH, CC hypoplasia	congenital defects, severe ID, dysmorphism	[44,45]
Baraitser-Winter syndrome 1 **	*ACTB*	7p22.1	AD	243310	3 cases (+5 cases of SBH, +1 unspecified heterotopia)	Lissencephaly, PVNH	congenital defects, moderate to severe DD/ID, dysmorphism, seizures	[46,47]
Brain small vessel disease-1 with or without ocular anomalies (BSVD1)	*COL4A1*	13q34	AD	175780	rare	Small vessel disease, porencephaly, schizencephaly, subcortical nodular and small linear heterotopia	DD, seizures, hemiplegia, hematuria	[48,49]
Chromosome 15q11.2 deletion	–	one 15q11 del & one 15q11.2 del	AD	–	2 cases	various anomalies including uni/bilateral PVNH	congenital defects, dysmorphism, seizures, one passed away day 1	[50,51]
Chromosome 16q24.3 microdeletion syndrome	Incl *ANKRD11* and *ZNF778*	16q24.3	AD	148050	2 cases	PVNH	DD, ID, seizures, dysmorphism	[52]
Chromosome 22q11.2 deletion syndrome, distal	–	22q11.2 deletion	CHR	611867	7 cases	various anomalies including single and multiple PVNH	mild to severe ID, dysmorphism, seizures, schizophrenia and OCD	[53]
Chromosome 22q11.22q11.23 duplication	–	22q11.22q11.23 duplication	CHR	–	2 cases (mother and daughter)	various anomalies including bilateral PVNH	mild to moderate ID, seizures	[7]
Chromosome 5q14.3 deletion syndrome, distal	–	5q14.3-q15 deletion	CHR	612881	3 cases	bilateral PVNH, polymicrogyria [1]	congenital defects, severe DD (incl. ID), dysmorphism, seizures	[54]
Chromosome 6q27 terminal deletion syndrome	–	6q27 del (+2x ring chromosome 6)	CHR	–	Common	uni/bilateral PVNH, ventriculomegaly, abnormal CC, cerebellum, polymicrogyria	congenital defects, mild to moderate DD, dysmorphism, seizures	[24–28]
Chromosome Xp22.3 deletion	–	Xp22.3 deletion	CHR	–	2 cases	various anomalies including bilateral PVNH	one has severe ID, dysmorphism, both have seizures	[55,56]
Chromosome Xq28 duplication*	–	Xq28 duplication	CHR	–	2 cases	bilateral PVNH	congenital defects, severe ID, seizures	[57,58]
Chromosome 1p36 deletion syndrome	–	1p36 deletion	CHR	607872	6 cases (1 case with associated 19p13.3 dup)	various anormalities including uni/bilateral PVNH	congenital defects, severe DD (incl. ID), dysmorphism, seizures	[7]
Dravet syndrome	*SCN1A*	2q24.3	AD	607208	Rare, 3 cases	FCD/PVNH in minority	severe DD/ID, seizures, behavior problems	[59]
ECE2-related disorder	*ECE2*	3q27.1	AR	–	2 cases	bilateral PVNH	not reported	[60]
Fragile X syndrome	*FMR1*	Xq27.3	XLD	300624	Rare, 3 cases	uni/bilateral PVNH	ID, autism, dysmorphism, macrocephaly	[61,62]
Genitopatellar syndrome/ SBBYSS syndrome *	*KAT6B*	10q22.2	AD	606170	2 cases (+1 case of SUBH)	Various anomalies including PVNH	congenital defects, DD, dysmorphism, seizures	[63,64]
Hydrocephalus, congenital, 2, with or without brain or eye anomalies	*MPDZ*	9p23	AR	615219	common	Hydrocephalus, bilateral PVNH	DD, dysmorphism, colobomas, hypotonia	[65]
Joubert syndrome 30	*ARMC9*	2q37.1	AR	617622	rare (3/11 cases)	single PVNH, molar tooth sign	severe DD, seizures, polydactyly (infrequent)	[66]
Knobloch syndrome, type 1 *	*COL18A1*	21q22.3	AR	267750	unknown	Frontal pachygyria/ polymicrogyria, PVNH	high myopia, vitreoretinal degeneration occipital scalp defects	[67,68]
Koolen-De Vries syndrome	*KANSL1*	17q21.31 deletion	AD	610443	9 cases	various brain anomalies including PVNH	congenital defects, mild to severe DD (incl. ID), dysmorphism, seizures	[69–71]
Li-Ghorgani-Weisz-Hubshman syndrome	*KAT8*	16p11.2	AD	618974	2/9 cases	various brain anomalies including PVNH	congenital defects, severe DD (incl. ID), dysmorphism, seizures	[72]
Megalencephaly-polymicrogyria-polydactyly-hydrocephalus syndrome 2	*AKT3*	1q43-q44	AD	615937	4/20 cases, excluding mosaic	diffuse and bilateral PVNH, polymicrogyria	megalencephaly, seizures, ID	[73]
Microcephaly, short stature, and polymicrogyria with seizures	*RTTN*	18q22.2	AR	614833	7/28 cases	lissencephaly, polymicrogyria, PVNH	congenital defects, severe ID, dysmorphism, microcephaly, short stature	[74]
	ISPD	7p21.2	AR	614643	2 cases			[75]

Table 1 (*continued*)

Disorder	Gene	Cytogenetic location	Inheritance	OMIM	Frequency	Imaging features	Clinical features	Refs
Muscular dystrophy-dystroglycanopathy (congenital with brain and eye anomalies), type A, 7						PVNH, cobblestone complex, hydrocephalus, encephalocele, abnormal brain stem/cerebellum	Congenital muscular dystrophy, eye abnormalities, severe DD, early demise	
Neurodevelopmental disorder with cerebellar hypoplasia and spasticity	*INTS8*	8q22.1	AR	618572	3 sibs	PVNH and cerebellar hypoplasia	congenital defects, severe ID, dysmorphism, seizures, spastic paraplegia	[76]
Neurodevelopmental disorder with dysmorphic facies and distal skeletal anomalies*	*ZMIZ1*	10q22.3	AD	618659	rare (2/19 cases)	uni/bilateral PVNH	Severe ID/DD, congenital defects, growth failure, feeding difficulties, microcephaly, dysmorphism, seizures	[77]
Neurodevelopmental disorder with structural brain anomalies and dysmorphic facies	*RAC3*	17q25.3	AD	618577	2/6 cases, half-siblings	various anomalies including unilateral PVNH	congenital defects, severe DD/ID, dysmorphism, seizures	[78,79]
Orofaciodigital syndrome XIV	*C2CD3*	11q13.4	AR	615948	2 sibs	various anomalies including heterotopia, molar tooth sign, abnormal CC	Ciliopathy syndrome, ID, microcephaly, tongue hamartoma, cleft lip/palate, polydactyly, colobomas.	[80]
PERCHING syndrome*	*KLHL7*	7p15.3	AR	617055	3/7	PVNH, thin corpus callosum	congenital defects, severe learning difficulties, dysmorphism, microcephaly, seizures	[81,82]
Periventricular heterotopia with microcephaly	*ARFGEF2*	20q13.13	AR	608097	common	bilateral PVNH, small corpus callosum, cerebral and hippocampal atrophy and hyperintensity in the putamen	severe DD/ID, progressive microcephaly, seizures, movement disorder, cardiomyopathy	[12,13]
Periventricular nodular heterotopia-3	–	5p15 (5p15.1 duplication and 5p15.33 trisomy)	CHR	608098	2/2 cases (1/2 SUBH)	bilateral PVNH, with subcortical heterotopia or focal gliosis	congenital defects, mild dysmorphism, complex partial seizures	[83]
Periventricular nodular heterotopia-7	*NEDD4L*	18q21.31	AD	617201	common (11/11)	bilateral PVNH and polymicrogyria	Syndactyly, cleft palate, severe-mild DD/ID, seizures, arthrogryposis	[14–17]
Periventricular nodular heterotopia-8 *	*ARF1*	1q42.13	AD	618185	3/3 cases	PVNH, atrophy, delayed myelination	DD, seizures	[84]
Periventricular nodular heterotopia-9 **	*MAP1B*	5q13.2	AD	618918	common (15/17)	PVNH, thin corpus callosum	ID, usually mild, learning difficulties, dyslexia, ADHD, ASD, microcephaly, seizures	[18–20]
Phelan-McDermid syndrome	*SHANK3*	22q13 deletion	AD	606232	2 cases	various anomalies including uni/bilateral PVNH	DD (incl. Mild ID), dysmorphism, autism, congenital defects	[85,86]
Primary microcephaly-1	MCPH1	8p23.1	AR	251200	2 sibs	PVNH	ID, primary microcephaly, short stature	[87,88]
Smith-Magenis syndrome	*RAI1*	17p11.2 deletion	CHR	182290	3 cases	bilateral PVNH	congenital defects, DD (incl. ID), dysmorphism, seizures, behavior and sleep problems	[22,23]
TMTC3-related disorder	*TMTC3*	12q21.32	AR	617218	3/4 sibs	bilateral PVNH in the temporal lobes	ID, dysmorphism, nocturnal seizures	[89]
Van Maldergem syndrome 1	*DCHS1*	11p15.4	AR	601390	2/4 cases	Confluent nodular/laminar PH (+1 case of SBH)	congenital defects, DD (incl. ID), dysmorphism, microcephaly, hearing loss	[32,90]
Van Maldergem syndrome 2	*FAT4*	4q28.1	AR	615546	2/5 cases	Confluent nodular/laminar PH	congenital defects, DD (incl. ID), dysmorphism, microcephaly, hearing loss	[32,90]
Ventriculomegaly with cystic kidney disease	*CRB2*	9q33.3	AR	219730	3 cases	PVNH and ventriculomegaly	congenital defects, DD, macrocephaly, seizures, renal disease	[91,92]
Williams-Beuren syndrome	–	7q11.23 deletion	CHR	194050	3 cases	uni/bilateral PVNH	congenital defects, ID, dysmorphism, seizures	[93–96]
X-linked periventricular heterotopia	*FLNA*	Xq28	AD	300049	common	bilateral PVNH, mega cisterna magna, hypoplastic CC, deformed anterior horns	Cardiovascular, gastrointestinal, pulmonary disease, joint hypermobility, usually normal intelligence, seizures, more severe/lethal in males	[9,97]

* = no imaging available, ** = majority of cases has no imaging available, ACC = agenesis of corpus callosum, AD = autosomal dominant, AR = autosomal recessive, CC = corpus callosum DD = developmental delay, ID = intellectual disability, SBH = subcortical band heterotopia, UK = unknown, XL = X-linked, XLD = X-linked dominant, XLR = X-linked recessive, UK = unknown.

chromosome region 6q27 is associated with a pattern of structural brain malformations with abnormalities of the corpus callosum, cerebellum and hippocampus, predominantly posteriorly enlarged ventricles or hydrocephalus, and scattered PVNH (Fig. 2) [24–28]. Not all features are present in every patient and no recognizable facial gestalt is associated with this syndrome. Within the 6q27 region lie 2 genes in which a SNV have been identified, both in a single patient with PVNH, *ERMARD* and *DLL1* [25,29]. A similar pattern of malformations with posterior predominant periventricular nodular heterotopia and cerebellar heterotopia has a very

Table 2
Genes associated with subcortical band heterotopia.

Disorder	Gene/ Locus	Cytogenetic location	Inheritance	OMIM	Frequency	Imaging features	Salient features	Refs
Baraitser-Winter syndrome 1	*ACTB*	7p22.1	AD	243310	rare (5/25 cases), (+3 cases of PVNH, +1 unspecified heterotopia)	posterior SBH, pachygyria anterior > posterior gradient, enlarged perivascular spaces	ID, dysmorphism, seizures, colobomas, hearing loss	[98]
Baraitser-Winter syndrome 2	*ACTG1*	17q25.3	AD	614583	3/6 cases	pachygyria anterior > posterior gradient, posterior SBH, ACC, enlarged perivascular spaces	ID, mild dysmorphism, hearing loss	[99]
Borjeson-Forssman-Lehmann syndrome	*PHF6*	Xq26.2	XLR	301900	2 cases	simplified gyral pattern, bilateral SBH	ID, dysmorphism, seizures	[100]
Cortical dysplasia, complex, with other brain malformations 4	*TUBG1*	17q21.2	AD	615412	2 cases	Pachygyria, posterior SBH, dysmorphic CC	Mild- severe ID, microcephaly, seizures	[101,102]
Lissencephaly 1/subcortical band heterotopia	*PAFAH1B1* aka *LIS1*	17p13.3	AD	607432	UK, rare	Mainly agyria/pachygia with posterior > anterior gradient, rarely SBH in mosaicism	Severe ID/DD, seizures, hypotonia, spasticity	[103,104]
Lissencephaly 10	*CEP85L*	6q22.31	AD	618873	common (9/13 cases + 1 unclassified heterotopia)	SBH, posterior-predominant lissencephaly and pachygyria	DD/ID, seizures	[36]
Lissencephaly 3	*TUBA1A*	12q13.12	AD	611603	3 cases	Lissencephaly, dysgyria, abnormalities of midbrain/hindbrain/corpus callosum, basal ganglia, enlarged ventricles, SBH with pachygyria	DD/ID, seizures, spasticity	[105–107]
Lissencephaly, X-linked	*DCX*	Xq23	XL	300067	common	SBH in females and pachygyria and agyria in males, anterior > posterior gradient	DD/ID, seizures	[5]
Pachygyria, microcephaly, developmental delay, and dysmorphic facies, with or without seizures	*TUBGCP2*	10q26.3	AR	618737	2 cases (1/2 PVNH)	Pachygyria, thin CC and brain stem, subependymal cysts, SBH, PVNH	DD/ID, dysmorphism, microcephaly, seizures, eye abnormalities	[108]

* = no imaging available, ** = majority of cases has no imaging available, ACC = agenesis of corpus callosum, AD = autosomal dominant, AR = autosomal recessive, CC = corpus callosum DD = developmental delay, ID = intellectual disability, SBH = subcortical band heterotopia, UK = unknown, XL = X-linked, XLR = X-linked recessive.

low yield of *FLNA* mutations and has been suggested to be due to non-genetic factors [30,31].

In Van Maldergem syndrome periventricular heterotopia are observed which have an either nodular or a rather confluent, smooth appearance, referred to as laminar heterotopia (Fig. 2A). This syndrome is characterized by a distinctive facial appearance, ID, digital contractures and skeletal anomalies [32]. Its inheritance is autosomal recessive and it is caused by either mutations in *DCHS1* or *FAT4* [33].

In any individual with imaging and/or clinical features suggesting a specific diagnosis, targeted testing can be pursued. In any other case we suggest to follow a broad approach according to the flowchart in Oegema et al. with a [1] chromosomal copy number analysis [2] a targeted gene panel and [3] trio exome sequencing [6].

4.2. Subcortical band heterotopia

We identified 16 genes associated with SBH, for 9 genes there were multiple cases published (Table 2, Table S2). We did not find any association with chromosomal aberrations. SBH is usually discussed in the context of lissencephaly spectrum disorders where it marks the mild end of the spectrum, with agyria on the severe end. We decided to study it here to provide a comprehensive overview of all heterotopia and to separate it clearly from other types of subcortical heterotopia. SBH can be separated into thick or thin SBH, and further classified according to its location/gradient. Several genes show a clear predominance for either anterior or posterior occurrence. Rarely, agyria/pachygria and SBH can be identified in the same patient. In a large lissencephaly study genetic analysis revealed a causal mutation in 123/155 SBH cases, the majority of which were *DCX* mutations, and several *LIS1* mutations [34]. So in total, only 2 genes explained 80% of cases [34]. DCX mutations in females cause a thick or thin SBH, with either a diffuse localization or anterior to posterior gradient (Fig. 2B) [5].Recently, a novel lissencephaly gene, *CEP85L* has been discovered, mutations cause a posterior predominant agyria/pachygyria or SBH [35,36]. Except for females with diffuse SBH caused by DCX mutations, there is evidence supporting a role for mosaic mutations in other forms of SBH [34,37]. There is no compelling evidence to date of non-genetic causes of SBH [34]. Due to the limited amount of genes, and several key features in either imaging or dysmorphology, a differential diagnosis can be created for an individual patient, followed by targeted single gene/gene panel analysis. The yield of exome sequencing after ruling out mutations in the known genes is unknown, but can potentially lead to novel gene discovery. CNV analysis is not indicated per se, although can be considered when the etiology remains unclear.

4.3. Subcortical heterotopia

We identified 25 genes and loci associated with SUBH and other, less well specified GMH. On neuroimaging, this is a heterogenous group of malformations. For a more thorough review of the rare subcortical types we refer to our previous study on subcortical malformations [2]. One of the more frequent occurring types of

Table 3
Genes associated with other heterotopia including subcortical heterotopia.

Disorder	Gene	Cytogenetic location	Inheritance	OMIM	Frequency	Imaging features	Salient features	Refs
Aicardi syndrome	–	Xp22	XLD	304050	3 cases (+common PVNH, + 2 cases of SBH)	extensive abnormalities including uni/bilateral PVNH, SUBH, SBH, polymicrogyria, ACC, cysts	severe DD/ID, dysmorphism, seizures (incl. infantile spasms), chorioretinal lacunae	[42,43]
Brain small vessel disease 2	*COL4A2*	13q34	AD	614483	2 cases (mother and son), (+1 case of PVNH)	Small vessel disease, porencephaly, schizencephaly, subcortical nodular and small linear heterotopia	Seizures, hemiplegia, DD, hematuria	[109]
Breast-ovarian cancer, familial, 1	*BRCA1*	17q21.31	AD	604370	Very rare, 2 cases	extensive nodular/focal subcortical heterotopia	Seizures, breast/ovarian cancer	[110,111]
Chudley-McCullough syndrome	*GPSM2*	1p13.3	AR	604213	common (14/14)	symmetric parasagittal SUBH, polymicrogyria, cerebral cyst, cerebellar dysplasia	ID, early-onset sensorineural deafness, seizures	[2,38]
Cortical dysplasia, complex, with other brain malformations 10	*APC2*	19p13.3	AR	618677	5/12 cases from 3 families	posterior predominant lissencephaly, subcortical heterotopia adjacent to caudate nuclei and ribbon-like heterotopia (1 case)	ID, seizures	[112]
EML1-associated brain overgrowth syndrome with ribbon-like heterotopia	*EML1*	14q32.2	AR	600348	common	ACC, hydrocephalus, megalencephaly, cortical dysplasia, subcortical ribbon-like heterotopia	ID, seizures, macrocephaly, ophthalmological abnormalities	[39,113]
Lissencephaly 5	*LAMB1*	7q31.1	AR	615191	unknown	thin beaded subcortical laminar/band heterotopia, cobblestone cortex, hydrocephalus	severe DD, aqcuired macrocephaly, seizures	[114]
Lissencephaly 6, with microcephaly	*KATNB1*	16q21	AR	616212	2 sibs (+1 case of PVNH)	symmetric nodular grey matter heterotopia in the bilateral corona radiate, microlissencephaly, pachygyria	DD, dysmorphism, primary microcephaly	[115]
Mental retardation, autosomal dominant 13	*DYNC1H1*	14q32.31	AD	614563	2 cases	Cortical malformations, dysmorphic basal ganglia and hypoplasia of the corpus callosum, brainstem, and/or cerebellum, nodular heterotopia NOS	ID, seizures	[101]
Microcephaly 2, primary, autosomal recessive	*WDR62*	19q13.12	AR	604317	rare (3/17 cases)	Simplified gyral pattern, polymicrogyria, pachgyria SBH, hypoplastic CC	ID, primary microcephaly	[116,117]
Mitochondrial complex I deficiency, nuclear type 34	*NDUFAF8*	17q25.3	AR	618776	2 cases	Signal abnormalities, hypoplastic CC, heterotopia NOS	DD, Leigh syndrome, raised serum lactate	[118]
Muscular dystrophy-dystroglycanopathy, with brain and eye anomalies type 2A	*POMT2*	14q24.3	AR	613150	5 cases	Cobblestone complex, hydrocephalus, ACC, abnormal brain stem/cerebellum, subcortical/subependymal heterotopia	ID, muscular dystrophy, hypotonia, early demise	[119,120]
Orofaciodigital syndrome XVI	*TMEM107*	17p13.1	AR	617563	2 sibs (twin)	Molar tooth sign, vermian dysplasia, enlarged ventricles, subcortical heterotopia NOS	ID, congenital defects, hamartoma, retinopathy	[121]
Primary microcephaly-6	*CENPJ*	13q12.12-q12.13	AR	608393	1 case	nodular bilateral heterotopia in optic pathways	ID, microcephaly	[2]

* = no imaging available, ACC = agenesis of corpus callosum, AD = autosomal dominant, AR = autosomal recessive, CC = corpus callosum DD = developmental delay, ID = intellectual disability, NOS = not otherwise specified, SBH = subcortical band heterotopia, UK = unknown, XL = X-linked, XLD = X-linked dominant, XLR = X-linked recessive, UK = unknown.

SUBH is curvilinear heterotopia with CFS-like spaces (Fig. 2C and D) [2]. A genetic cause has not been identified and a non-genetic etiology has been suggested [2]. However, large genetic studies are lacking and genetic studies could be indicated, especially when the family is asking for recurrence risks. In this instance we would advise a careful review of the perinatal history, and examination of the patient for syndromal features or additional congenital anomalies and broad genetic testing (genome-wide CNV testing and trio exome studies) [6].

Other rare patterns of SUBH have a known genetic etiology (Table 3, Table S3). For example Chudley McCullough syndrome, caused by biallelic mutations in *GPSM2* [38]. This syndrome presents clinically with severe sensorineural hearing loss, seizures and mild ID in some affected individuals. On brain imaging the distinct mesial parasagittal heterotopia can be identified, which run parallel to the lateral ventricles and connect to the overlying polymicrogyric cortex (Fig. 2E). In addition, cerebellar dysplasia (Fig. 2F), corpus callosum abnormalities and interhemispheric cysts are often identified [38]. The heterotopia shows some resemblance to the *EML1*-related ribbon-like heterotopia, although the latter shows a more extensive, continuous heterotopia with an undulating morphology, in addition to megalencephaly, diffusively abnormal cortex, agenesis of the corpus callosum and hydrocephalus in several individuals (Fig. 2G and H). Clinically the syndrome is characterized by moderate-severe ID, seizures, and ophthalmological abnormalities [39].

5. Conclusion

An effort should be made to reach an etiological diagnosis in each individual with GMH. A diagnosis enables proper counseling of prognosis and recurrence risks, and enables individualized patient management [6]. Our study emphasizes the extreme genetic heterogeneity underlying GMH. To reach a diagnosis a careful

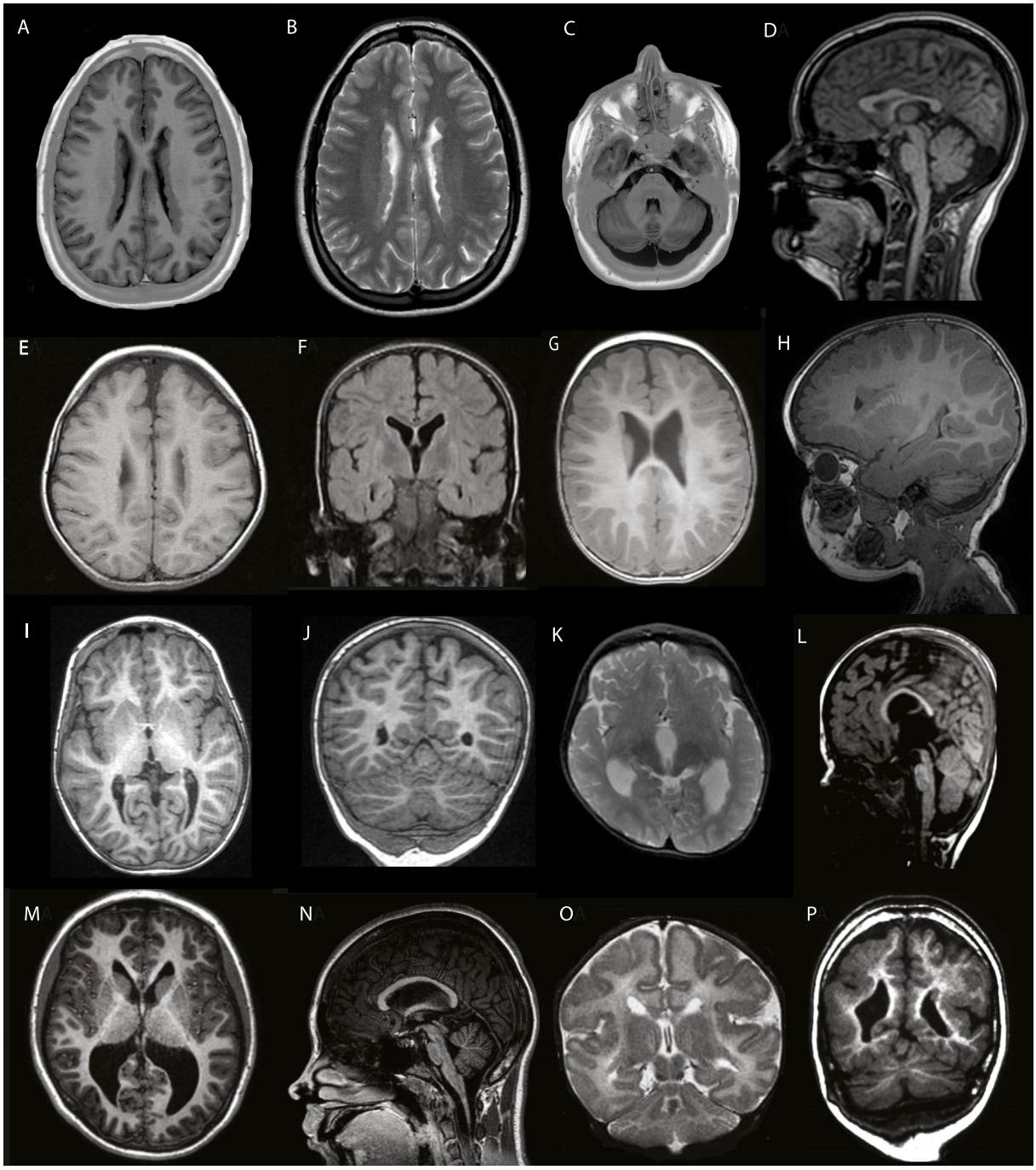

Fig. 1. MR imaging of PVNH. A,B: T1-and T2 weighted axial images showing bilateral continuous PNVH in female with *FLNA* mutation. C,D: mega cisterna magna on T2 axial and midline sagital in same FLNA patient, D also showing partial CC hypoplasia. E: T1-weighted axial image showing bilateral almost continuous PNVH in patient with *ARFGEF2* mutation. F: the same patient also showed hyperintensity of the putamen on FLAIR imaging. G: H: Single large heterotopia in left frontal horn anterior of the nucleus caudatus in patient with *SPTAN1* mutation on sagittal and axial T1 weighted images. I, J: axial and coronal T1 weighted images showing several small, scattered PVNH in patient with Smith-Magenis syndrome due to a *RAI1* mutation. K, L: axial T2 weighted and midline sagital T1 weighted image of patient with Smith-Magenis syndrome due to a 17p11.2 deletion showing small, scattered PVNH, brachycephaly, enlarged ventricles and thin CC. M, N: axial and coronal T1 weighted images showing enlarged ventricles, bilateral small PVNH, thin CC and small vermis and pons/mesencephalon in a patient with a microdeletion of 6q27 including both *DLL1* and *ERMARD*. O, P: coronal T1 and T2 weighted images of two patients with 1p36 deletion syndrome with several PVNH, and abnormal, likely polymicrogyric cortex in O.

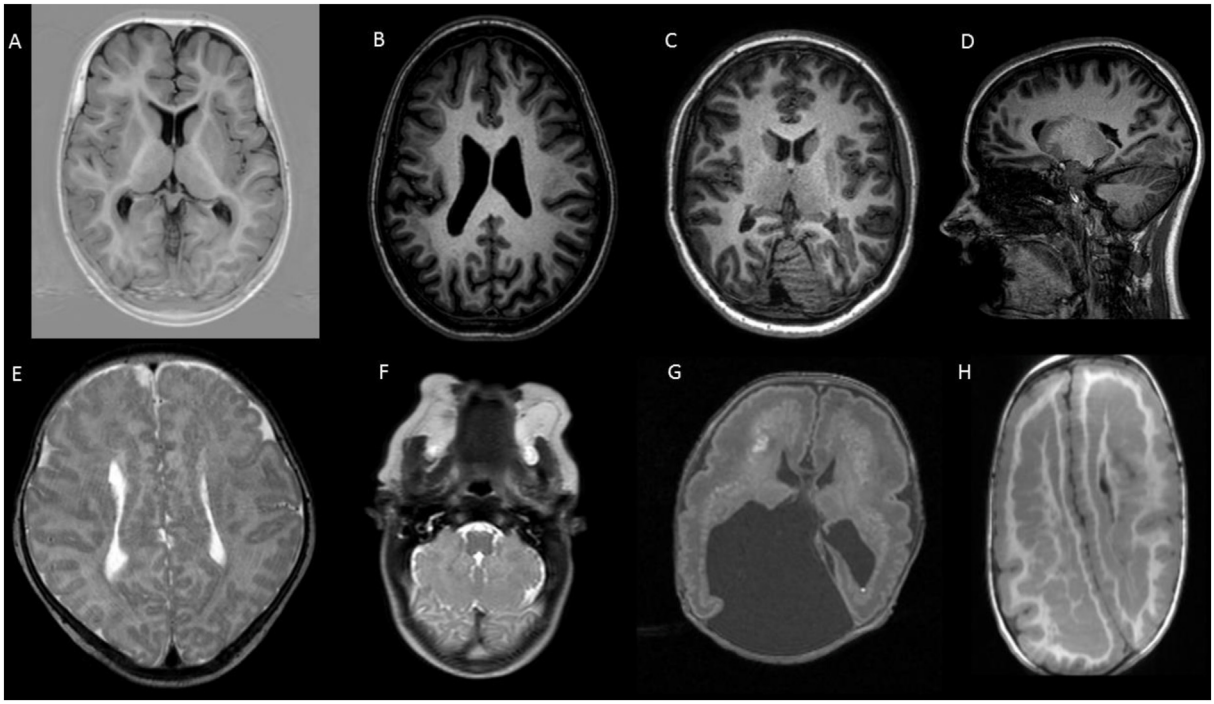

Fig. 2. MR imaging of other heterotopia. A: Axial T1-weighted image of periventricular laminar heterotopia in a patient with Van Maldergem syndrome due to a homozygous *DCHS1* mutation. B: Axial T1-weighted image of SBH in a female with a DCX mutation. C, D: axial and sagittal T1-weighted image of a subcortical curvilinear heterotopia with CFS-like spaces in the left occciptal lobe. E, F: patient with Chudley McCullough syndrome due to homozygous *GPSM2* mutation and mesial parasagittal heterotopia visible in E and typical "cauliflower-like" cerebellar dysplasia in F. G,H: *EML1*-related ribbon-like heterotopia in infancy (G) and 3 years of age (H). Also note the dysplastic cortex and hydrocephalus in G.

review of the patients history, clinical features and neuroimaging is extremely helpful. It will guide genetic testing, and help in the interpretation of variants of unknown significance [6]. Besides description of the GMH, other structures to be carefully assessed are the cortex, basal ganglia, corpus callosum, basal ganglia and thalami, brain stem and cerebellum. An approach to optimal imaging and classification of MCD is reviewed in Severino et al. [4]. The imaging pattern can be the clue to the underlying etiology, for example in *FLNA* or *DCX* associated disorders. For other patients, the clinical features in for example *NEDD4L- ARFGEF2* or chromosomal disorders will raise suspicion to a specific diagnosis. Always consider non-genetic factors (e.g. vascular disruption, congenital infections and other teratogens) in the differential diagnosis.

Declaration of competing interest

Regarding manuscript Genetic Causes underlying Grey Matter Heterotopia the authors declare no conflict of interest.

Acknowledgements

The authors would like to thank Bill Dobyns, Grazia Mancini and Nienke Verbeek for kindly sharing images.

Appendix A. Supplementary data

Supplementary data to this article can be found online at https://doi.org/10.1016/j.ejpn.2021.09.015.

Funding

This research did not receive any specific grant from funding agencies in the public, commercial, or not-for-profit sectors.

References

[1] A.J. Barkovich, R. Guerrini, R.I. Kuzniecky, G.D. Jackson, W.B. Dobyns, A developmental and genetic classification for malformations of cortical development: update 2012, Brain 135 (Pt 5) (2012) 1348–1369.
[2] R. Oegema, A.J. Barkovich, G.M.S. Mancini, R. Guerrini, W.B. Dobyns, Subcortical heterotopic gray matter brain malformations: classification study of 107 individuals, Neurology 93 (14) (2019) e1360–e1373.
[3] E. Parrini, A. Ramazzotti, W.B. Dobyns, D. Mei, F. Moro, P. Veggiotti, et al., Periventricular heterotopia: phenotypic heterogeneity and correlation with Filamin A mutations, Brain 129 (Pt 7) (2006) 1892–1906.
[4] M. Severino, A.F. Geraldo, N. Utz, D. Tortora, I. Pogledic, W. Klonowski, et al., Definitions and classification of malformations of cortical development: practical guidelines, Brain 143 (10) (2020) 2874–2894.
[5] N. Di Donato, S. Chiari, G.M. Mirzaa, K. Aldinger, E. Parrini, C. Olds, et al., Lissencephaly: expanded imaging and clinical classification, Am. J. Med. Genet. 173 (6) (2017) 1473–1488.
[6] R. Oegema, T.S. Barakat, M. Wilke, K. Stouffs, D. Amrom, E. Aronica, et al., International consensus recommendations on the diagnostic work-up for malformations of cortical development, Nat. Rev. Neurol. 16 (11) (2020) 618–635.
[7] E. Cellini, A. Vetro, V. Conti, C. Marini, V. Doccini, C. Clementella, et al., Multiple genomic copy number variants associated with periventricular nodular heterotopia indicate extreme genetic heterogeneity, Eur. J. Hum. Genet. 27 (6) (2019) 909–918.
[8] K.B. Park, T. Chapman, K.A. Aldinger, G.M. Mirzaa, J. Zeiger, A. Beck, et al., The spectrum of brain malformations and disruptions in twins, Am. J. Med. Genet. 185 (9) (2020) 2690–2718.
[9] M. Lange, B. Kasper, A. Bohring, F. Rutsch, G. Kluger, S. Hoffjan, et al., 47 patients with FLNA associated periventricular nodular heterotopia, Orphanet J. Rare Dis. 10 (2015) 134.
[10] M.H. Chen, C.A. Walsh, FLNA-related periventricular nodular heterotopia, in: M.P. Adam, H.H. Ardinger, R.A. Pagon, S.E. Wallace, L.J.H. Bean, G. Mirzaa, et al. (Eds.), GeneReviews((R)), 1993. Seattle (WA).
[11] M.C. de Wit, I.F. de Coo, D.J. Halley, M.H. Lequin, G.M. Mancini, Movement disorder and neuronal migration disorder due to ARFGEF2 mutation, Neurogenetics 10 (4) (2009) 333–336.
[12] V.L. Sheen, V.S. Ganesh, M. Topcu, G. Sebire, A. Bodell, R.S. Hill, et al., Mutations in ARFGEF2 implicate vesicle trafficking in neural progenitor proliferation and migration in the human cerebral cortex, Nat. Genet. 36 (1) (2004) 69–76.
[13] S. Yilmaz, S. Gokben, G. Serdaroglu, C. Eraslan, G.M. Mancini, H. Tekin, et al.,

The expanding phenotypic spectrum of ARFGEF2 gene mutation: cardiomyopathy and movement disorder, Brain Dev. 38 (1) (2016) 124–127.
[14] L. Broix, H. Jagline, E. Ivanova, S. Schmucker, N. Drouot, J. Clayton-Smith, et al., Mutations in the HECT domain of NEDD4L lead to AKT-mTOR pathway deregulation and cause periventricular nodular heterotopia, Nat. Genet. 48 (11) (2016) 1349–1358.
[15] M. Elbracht, F. Kraft, M. Begemann, P. Holschbach, M. Mull, I.M. Kabat, et al., Familial NEDD4L variant in periventricular nodular heterotopia and in a fetus with hypokinesia and flexion contractures, Mol Genet Genomic Med 6 (6) (2018) 1255–1260.
[16] K. Kato, F. Miya, I. Hori, D. Ieda, K. Ohashi, Y. Negishi, et al., A novel missense mutation in the HECT domain of NEDD4L identified in a girl with periventricular nodular heterotopia, polymicrogyria and cleft palate, J. Hum. Genet. 62 (9) (2017) 861–863.
[17] K. Stouffs, P. Verloo, S. Brock, L. Régal, D. Beysen, B. Ceulemans, et al., Recurrent NEDD4L variant in periventricular nodular heterotopia, polymicrogyria and syndactyly, Front. Genet. 11 (2020) 26.
[18] E.L. Heinzen, A.C. O'Neill, X. Zhu, A.S. Allen, M. Bahlo, J. Chelly, et al., De novo and inherited private variants in MAP1B in periventricular nodular heterotopia, PLoS Genet. 14 (5) (2018), e1007281.
[19] D.M. Julca, J. Diaz, S. Berger, E. Leon, MAP1B related syndrome: case presentation and review of literature, Am. J. Med. Genet. 179 (9) (2019) 1703–1708.
[20] G.B. Walters, O. Gustafsson, G. Sveinbjornsson, V.K. Eiriksdottir, A.B. Agustsdottir, G.A. Jonsdottir, et al., MAP1B mutations cause intellectual disability and extensive white matter deficit, Nat. Commun. 9 (1) (2018) 3456.
[21] A.C.M. Smith, K.E. Boyd, C. Brennan, J. Charles, S.H. Elsea, B.M. Finucane, et al., Smith-magenis syndrome, in: M.P. Adam, H.H. Ardinger, R.A. Pagon, S.E. Wallace, L.J.H. Bean, G. Mirzaa, et al. (Eds.), GeneReviews((R)), 1993. Seattle (WA).
[22] V. Capra, R. Biancheri, G. Morana, P. Striano, F. Novara, G.B. Ferrero, et al., Periventricular nodular heterotopia in Smith-Magenis syndrome, Am. J. Med. Genet. 164A (12) (2014) 3142–3147.
[23] I. Maya, C. Vinkler, O. Konen, L. Kornreich, T. Steinberg, J. Yeshaya, et al., Abnormal brain magnetic resonance imaging in two patients with Smith-Magenis syndrome, Am. J. Med. Genet. 164a (8) (2014) 1940–1946.
[24] S. Peddibhotla, S.C. Nagamani, A. Erez, J.V. Hunter, J.L. Holder Jr., M.E. Carlin, et al., Delineation of candidate genes responsible for structural brain abnormalities in patients with terminal deletions of chromosome 6q27, Eur. J. Hum. Genet. 23 (1) (2015) 54–60.
[25] V. Conti, A. Carabalona, E. Pallesi-Pocachard, E. Parrini, R.J. Leventer, E. Buhler, et al., Periventricular heterotopia in 6q terminal deletion syndrome: role of the C6orf70 gene, Brain 136 (Pt 11) (2013) 3378–3394.
[26] S. Nishigaki, T. Hamazaki, M. Saito, T. Yamamoto, T. Seto, H. Shintaku, Periventricular heterotopia and white matter abnormalities in a girl with mosaic ring chromosome 6, Mol. Cytogenet. 8 (2015) 54.
[27] S. Liu, Z. Wang, S. Wei, J. Liang, N. Chen, H. OuYang, et al., Gray matter heterotopia, mental retardation, developmental delay, microcephaly, and facial dysmorphisms in a boy with ring chromosome 6: a 10-year follow-up and literature review, Cytogenet. Genome Res. 154 (4) (2018) 201–208.
[28] M.D. Hanna, P.N. Moretti, PdO. C, A.R. Mt, R.V. B, S.F. de Oliveira, et al., Defining the critical region for intellectual disability and brain malformations in 6q27 microdeletions, Mol Syndromol 10 (4) (2019) 202–208.
[29] B. Fischer-Zirnsak, L. Segebrecht, M. Schubach, P. Charles, E. Alderman, K. Brown, et al., Haploinsufficiency of the notch ligand DLL1 causes variable neurodevelopmental disorders, Am. J. Hum. Genet. 105 (3) (2019) 631–639.
[30] K.A. Aldinger, A.E. Timms, Z. Thomson, G.M. Mirzaa, J.T. Bennett, A.B. Rosenberg, et al., Redefining the etiologic landscape of cerebellar malformations, Am. J. Hum. Genet. 105 (3) (2019) 606–615.
[31] T. Pisano, A.J. Barkovich, R.J. Leventer, W. Squier, I.E. Scheffer, E. Parrini, et al., Peritrigonal and temporo-occipital heterotopia with corpus callosum and cerebellar dysgenesis, Neurology 79 (12) (2012) 1244–1251.
[32] S. Mansour, M. Swinkels, P.A. Terhal, L.C. Wilson, P. Rich, L. Van Maldergem, et al., Van Maldergem syndrome: further characterisation and evidence for neuronal migration abnormalities and autosomal recessive inheritance, Eur. J. Hum. Genet. 20 (10) (2012) 1024–1031.
[33] S. Cappello, M.J. Gray, C. Badouel, S. Lange, M. Einsiedler, M. Srour, et al., Mutations in genes encoding the cadherin receptor-ligand pair DCHS1 and FAT4 disrupt cerebral cortical development, Nat. Genet. 45 (11) (2013) 1300–1308.
[34] N. Di Donato, A.E. Timms, K.A. Aldinger, G.M. Mirzaa, J.T. Bennett, S. Collins, et al., Analysis of 17 genes detects mutations in 81% of 811 patients with lissencephaly, Genet. Med. 20 (11) (2018) 1354–1364.
[35] A. Kodani, C. Kenny, A. Lai, D.M. Gonzalez, E. Stronge, G.M. Sejourne, et al., Posterior neocortex-specific regulation of neuronal migration by CEP85L identifies maternal centriole-dependent activation of CDK5, Neuron 106 (2) (2020) 246–255 e6.
[36] M.H. Tsai, A.M. Muir, W.J. Wang, Y.N. Kang, K.C. Yang, N.H. Chao, et al., Pathogenic variants in CEP85L cause sporadic and familial posterior predominant lissencephaly, Neuron 106 (2) (2020) 237–245, e8.
[37] S.S. Jamuar, A.T. Lam, M. Kircher, A.M. D'Gama, J. Wang, B.J. Barry, et al., Somatic mutations in cerebral cortical malformations, N. Engl. J. Med. 371 (8) (2014) 733–743.
[38] D. Doherty, A.E. Chudley, G. Coghlan, G.E. Ishak, A.M. Innes, E.G. Lemire, et al., GPSM2 mutations cause the brain malformations and hearing loss in Chudley-McCullough syndrome, Am. J. Hum. Genet. 90 (6) (2012) 1088–1093.
[39] R. Oegema, G. McGillivray, R. Leventer, A.G. Le Moing, N. Bahi-Buisson, A. Barnicoat, et al., EML1-associated brain overgrowth syndrome with ribbon-like heterotopia, Am J Med Genet C Semin Med Genet 181 (4) (2019) 627–637.
[40] A. Accogli, S. Calabretta, J. St-Onge, N. Boudrahem-Addour, A. Dionne-Laporte, P. Joset, et al., De novo pathogenic variants in N-cadherin cause a syndromic neurodevelopmental disorder with corpus collosum, axon, cardiac, ocular, and genital defects, Am. J. Hum. Genet. 105 (4) (2019) 854–868.
[41] L.M. Reis, N.S. Houssin, C. Zamora, O. Abdul-Rahman, J.M. Kalish, E.H. Zackai, et al., Novel variants in CDH2 are associated with a new syndrome including Peters anomaly, Clin. Genet. 97 (3) (2020) 502–508.
[42] S. Masnada, A. Pichiecchio, M. Formica, F. Arrigoni, P. Borrelli, P. Accorsi, et al., Basal ganglia dysmorphism in patients with Aicardi syndrome, Neurology 96 (9) (2020) e1319–e1333.
[43] B. Hopkins, V.R. Sutton, R.A. Lewis, I. Van den Veyver, G. Clark, Neuroimaging aspects of Aicardi syndrome, Am. J. Med. Genet. 146a (22) (2008) 2871–2878.
[44] L. Lange, A.T. Pagnamenta, S. Lise, S. Clasper, H. Stewart, E.S. Akha, et al., A de novo frameshift in HNRNPK causing a Kabuki-like syndrome with nodular heterotopia, Clin. Genet. 90 (3) (2016) 258–262.
[45] M.L. Dentici, S. Barresi, M. Niceta, F. Pantaleoni, S. Pizzi, B. Dallapiccola, et al., Clinical spectrum of Kabuki-like syndrome caused by HNRNPK haploinsufficiency, Clin. Genet. 93 (2) (2018) 401–407.
[46] N. Di Donato, A. Rump, R. Koenig, V.M. Der Kaloustian, F. Halal, K. Sonntag, et al., Severe forms of Baraitser-Winter syndrome are caused by ACTB mutations rather than ACTG1 mutations, Eur. J. Hum. Genet. 22 (2) (2014) 179–183.
[47] S. Cuvertino, H.M. Stuart, K.E. Chandler, N.A. Roberts, R. Armstrong, L. Bernardini, et al., ACTB loss-of-function mutations result in a pleiotropic developmental disorder, Am. J. Hum. Genet. 101 (6) (2017) 1021–1033.
[48] D. Tonduti, A. Pichiecchio, R. La Piana, J.H. Livingston, D.A. Doherty, A. Majumdar, et al., COL4A1-related disease: raised creatine kinase and cerebral calcification as useful pointers, Neuropediatrics 43 (5) (2012) 283–288.
[49] S. Zagaglia, C. Selch, J.R. Nisevic, D. Mei, Z. Michalak, L. Hernandez-Hernandez, et al., Neurologic phenotypes associated with COL4A1/2 mutations: expanding the spectrum of disease, Neurology 91 (22) (2018) e2078–e2088.
[50] M. Srour, M.F. Rioux, C. Varga, A. Lortie, P. Major, Y. Robitaille, et al., The clinical spectrum of nodular heterotopias in children: report of 31 patients, Epilepsia 52 (4) (2011) 728–737.
[51] J.A. Radley, P.C. Vasudevan, Is 15q11.2 microdeletion associated with periventricular nodular heterotopia? Clin. Dysmorphol. 24 (4) (2015) 156–158.
[52] M.H. Willemsen, B.A. Fernandez, C.A. Bacino, E. Gerkes, A.P. de Brouwer, R. Pfundt, et al., Identification of ANKRD11 and ZNF778 as candidate genes for autism and variable cognitive impairment in the novel 16q24.3 microdeletion syndrome, Eur. J. Hum. Genet. 18 (4) (2010) 429–435.
[53] A. Rezazadeh, E. Bercovici, T.R. Kiehl, E.W. Chow, T. Krings, A.S. Bassett, et al., Periventricular nodular heterotopia in 22q11.2 deletion and frontal lobe migration, Ann Clin Transl Neurol 5 (11) (2018) 1314–1322.
[54] C. Cardoso, A. Boys, E. Parrini, C. Mignon-Ravix, J.M. McMahon, S. Khantane, et al., Periventricular heterotopia, mental retardation, and epilepsy associated with 5q14.3-q15 deletion, Neurology 72 (9) (2009) 784–792.
[55] M.A. van Steensel, M. Vreeburg, J. Engelen, S. Ghesquiere, A.P. Stegmann, J. Herbergs, et al., Contiguous gene syndrome due to a maternally inherited 8.41 Mb distal deletion of chromosome band Xp22.3 in a boy with short stature, ichthyosis, epilepsy, mental retardation, cerebral cortical heterotopias and Dandy-Walker malformation, Am. J. Med. Genet. 146a (22) (2008) 2944–2949.
[56] H. Ozawa, M. Osawa, T. Nagai, N. Sakura, Steroid sulfatase deficiency with bilateral periventricular nodular heterotopia, Pediatr. Neurol. 34 (3) (2006) 239–241.
[57] J.M. Fink, W.B. Dobyns, R. Guerrini, B.A. Hirsch, Identification of a duplication of Xq28 associated with bilateral periventricular nodular heterotopia, Am. J. Hum. Genet. 61 (2) (1997) 379–387.
[58] S. El Chehadeh, L. Faivre, A.L. Mosca-Boidron, V. Malan, J. Amiel, M. Nizon, et al., Large national series of patients with Xq28 duplication involving MECP2: delineation of brain MRI abnormalities in 30 affected patients, Am. J. Med. Genet. 170a (1) (2016) 116–129.
[59] C. Barba, E. Parrini, R. Coras, A. Galuppi, D. Craiu, G. Kluger, et al., Co-occurring malformations of cortical development and SCN1A gene mutations, Epilepsia 55 (7) (2014) 1009–1019.
[60] I.Y. Buchsbaum, P. Kielkowski, G. Giorgio, A.C. O'Neill, R. Di Giaimo, C. Kyrousi, et al., ECE2 regulates neurogenesis and neuronal migration during human cortical development, EMBO Rep. 21 (5) (2020), e48204.
[61] F. Moro, T. Pisano, B.D. Bernardina, R. Polli, A. Murgia, L. Zoccante, et al., Periventricular heterotopia in fragile X syndrome, Neurology 67 (4) (2006) 713–715.
[62] J. Bidstrup, J. Kjeldbjerg Hansen, Fragile X syndrome and periventricular heterotopias: a rare association, J. Pediatr. Neurol. 19 (5) (2020) 348–351.
[63] L. Armstrong, J.T. Clarke, Report of a new case of "genitopatellar" syndrome which challenges the importance of absent patellae as a defining feature, J. Med. Genet. 39 (12) (2002) 933–934.

[64] L.X. Zhang, G. Lemire, C. Gonzaga-Jauregui, S. Molidperee, C. Galaz-Montoya, D.S. Liu, et al., Further delineation of the clinical spectrum of KAT6B disorders and allelic series of pathogenic variants, Genet. Med. 22 (8) (2020) 1338–1347.
[65] R. Shaheen, M.A. Sebai, N. Patel, N. Ewida, W. Kurdi, I. Altweijri, et al., The genetic landscape of familial congenital hydrocephalus, Ann. Neurol. 81 (6) (2017) 890–897.
[66] J.C. Van De Weghe, T.D.S. Rusterholz, B. Latour, M.E. Grout, K.A. Aldinger, R. Shaheen, et al., Mutations in ARMC9, which encodes a basal body protein, cause joubert syndrome in humans and ciliopathy phenotypes in zebrafish, Am. J. Hum. Genet. 101 (1) (2017) 23–36.
[67] M.R. Passos-Bueno, O.T. Suzuki, L.M. Armelin-Correa, A.L. Sertié, F.I. Errera, K. Bagatini, et al., Mutations in collagen 18A1 and their relevance to the human phenotype, An. Acad. Bras. Cienc. 78 (1) (2006) 123–131.
[68] A.O. Caglayan, J.F. Baranoski, F. Aktar, W. Han, B. Tuysuz, A. Guzel, et al., Brain malformations associated with Knobloch syndrome–review of literature, expanding clinical spectrum, and identification of novel mutations, Pediatr. Neurol. 51 (6) (2014) 806–813, e8.
[69] K.A. Myers, S.A. Mandelstam, G. Ramantani, E.J. Rushing, B.B. de Vries, D.A. Koolen, et al., The epileptology of Koolen-de Vries syndrome: electro-clinico-radiologic findings in 31 patients, Epilepsia 58 (6) (2017) 1085–1094.
[70] M. Zollino, G. Marangi, E. Ponzi, D. Orteschi, S. Ricciardi, S. Lattante, et al., Intragenic KANSL1 mutations and chromosome 17q21.31 deletions: broadening the clinical spectrum and genotype-phenotype correlations in a large cohort of patients, J. Med. Genet. 52 (12) (2015) 804–814.
[71] C. Dubourg, D. Sanlaville, M. Doco-Fenzy, C. Le Caignec, C. Missirian, S. Jaillard, et al., Clinical and molecular characterization of 17q21.31 microdeletion syndrome in 14 French patients with mental retardation, Eur. J. Med. Genet. 54 (2) (2011) 144–151.
[72] L. Li, M. Ghorbani, M. Weisz-Hubshman, J. Rousseau, I. Thiffault, R.E. Schnur, et al., Lysine acetyltransferase 8 is involved in cerebral development and syndromic intellectual disability, J. Clin. Invest. 130 (3) (2020) 1431–1445.
[73] D. Alcantara, A. Timms, K. Gripp, L. Baker, K. Park, S. Collins, et al., Mutations of AKT3 are associated with a wide spectrum of developmental disorders including extreme megalencephaly, Brain : J. Neurol. 140 (2017) 2610–2622.
[74] L.V. Vandervore, R. Schot, E. Kasteleijn, R. Oegema, K. Stouffs, A. Gheldof, et al., Heterogeneous clinical phenotypes and cerebral malformations reflected by rotatin cellular dynamics, Brain 142 (4) (2019) 867–884.
[75] S. Alharbi, A. Alhashem, F. Alkuraya, F. Kashlan, K. Tlili-Graiess, Neuroimaging manifestations and genetic heterogeneity of Walker-Warburg syndrome in Saudi patients, Brain Dev. 43 (3) (2021) 380–388.
[76] R. Oegema, D. Baillat, R. Schot, L.M. van Unen, A. Brooks, S.K. Kia, et al., Human mutations in integrator complex subunits link transcriptome integrity to brain development, PLoS Genet. 13 (5) (2017), e1006809.
[77] R. Carapito, E.L. Ivanova, A. Morlon, L. Meng, A. Molitor, E. Erdmann, et al., ZMIZ1 variants cause a syndromic neurodevelopmental disorder, Am. J. Hum. Genet. 104 (2) (2019) 319–330.
[78] G. Costain, B. Callewaert, H. Gabriel, T.Y. Tan, S. Walker, J. Christodoulou, et al., De novo missense variants in RAC3 cause a novel neurodevelopmental syndrome, Genet. Med. 21 (4) (2019) 1021–1026.
[79] J.J. White, J.F. Mazzeu, Z. Coban-Akdemir, Y. Bayram, V. Bahrambeigi, A. Hoischen, et al., WNT signaling perturbations underlie the genetic heterogeneity of robinow syndrome, Am. J. Hum. Genet. 102 (1) (2018) 27–43.
[80] N.J. Boczek, K. Hopp, L. Benoit, D. Kraft, M.A. Cousin, P.R. Blackburn, et al., Characterization of three ciliopathy pedigrees expands the phenotype associated with biallelic C2CD3 variants, Eur. J. Hum. Genet. 26 (12) (2018) 1797–1809.
[81] A.L. Bruel, S. Bigoni, J. Kennedy, M. Whiteford, C. Buxton, G. Parmeggiani, et al., Expanding the clinical spectrum of recessive truncating mutations of KLHL7 to a Bohring-Opitz-like phenotype, J. Med. Genet. 54 (12) (2017) 830–835.
[82] A. Kanthi, M. Hebbar, S.L. Bielas, K.M. Girisha, A. Shukla, Bi-allelic c.181_183delTGT in BTB domain of KLHL7 is associated with overlapping phenotypes of Crisponi/CISS1-like and Bohring-Opitz like syndrome, Eur. J. Med. Genet. 62 (6) (2019) 103528.
[83] V.L. Sheen, J.W. Wheless, A. Bodell, E. Braverman, P.D. Cotter, K.A. Rauen, et al., Periventricular heterotopia associated with chromosome 5p anomalies, Neurology 60 (6) (2003) 1033–1036.
[84] X. Ge, H. Gong, K. Dumas, J. Litwin, J.J. Phillips, Q. Waisfisz, et al., Missense-depleted regions in population exomes implicate ras superfamily nucleotide-binding protein alteration in patients with brain malformation, NPJ Genom Med 1 (2016) 16036.
[85] A.J. Barakat, P.L. Pearl, M.T. Acosta, B.P. Runkle, 22q13 deletion syndrome with central diabetes insipidus: a previously unreported association, Clin. Dysmorphol. 13 (3) (2004) 191–194.
[86] A. Philippe, N. Boddaert, L. Vaivre-Douret, L. Robel, L. Danon-Boileau, V. Malan, et al., Neurobehavioral profile and brain imaging study of the 22q13.3 deletion syndrome in childhood, Pediatrics 122 (2) (2008) e376–e382.
[87] H. Neitzel, L.M. Neumann, D. Schindler, A. Wirges, H. Tönnies, M. Trimborn, et al., Premature chromosome condensation in humans associated with microcephaly and mental retardation: a novel autosomal recessive condition, Am. J. Hum. Genet. 70 (4) (2002) 1015–1022.
[88] M. Trimborn, S.M. Bell, C. Felix, Y. Rashid, H. Jafri, P.D. Griffiths, et al., Mutations in microcephalin cause aberrant regulation of chromosome condensation, Am. J. Hum. Genet. 75 (2) (2004) 261–266.
[89] S.M.K. Farhan, K.C.J. Nixon, M. Everest, T.N. Edwards, S. Long, D. Segal, et al., Identification of a novel synaptic protein, TMTC3, involved in periventricular nodular heterotopia with intellectual disability and epilepsy, Hum. Mol. Genet. 26 (21) (2017) 4278–4289.
[90] I. Ivanovski, S. Akbaroghli, M. Pollazzon, C. Gelmini, S.G. Caraffi, M. Mansouri, et al., Van Maldergem syndrome and Hennekam syndrome: further delineation of allelic phenotypes, Am. J. Med. Genet. 176 (5) (2018) 1166–1174.
[91] R.E. Lamont, W.H. Tan, A.M. Innes, J.S. Parboosingh, D. Schneidman-Duhovny, A. Rajkovic, et al., Expansion of phenotype and genotypic data in CRB2-related syndrome, Eur. J. Hum. Genet. 24 (10) (2016) 1436–1444.
[92] A. Slavotinek, J. Kaylor, H. Pierce, M. Cahr, S.J. DeWard, D. Schneidman-Duhovny, et al., CRB2 mutations produce a phenotype resembling congenital nephrosis, Finnish type, with cerebral ventriculomegaly and raised alpha-fetoprotein, Am. J. Hum. Genet. 96 (1) (2015) 162–169.
[93] N. Bahi-Buisson, R. Guerrini, Diffuse malformations of cortical development, Handb. Clin. Neurol. 111 (2013) 653–665.
[94] R.J. Ferland, J.N. Gaitanis, K. Apse, U. Tantravahi, C.A. Walsh, V.L. Sheen, Periventricular nodular heterotopia and Williams syndrome, Am. J. Med. Genet. 140 (12) (2006) 1305–1311.
[95] M. van Kogelenberg, S. Ghedia, G. McGillivray, D. Bruno, R. Leventer, K. Macdermot, et al., Periventricular heterotopia in common microdeletion syndromes, Mol Syndromol 1 (1) (2010) 35–41.
[96] F. Nicita, G. Garone, A. Spalice, S. Savasta, P. Striano, C. Pantaleoni, et al., Epilepsy is a possible feature in Williams-Beuren syndrome patients harboring typical deletions of the 7q11.23 critical region, Am. J. Med. Genet. 170a (1) (2016) 148–155.
[97] J.W. Fox, E.D. Lamperti, Y.Z. Eksioglu, S.E. Hong, Y. Feng, D.A. Graham, et al., Mutations in filamin 1 prevent migration of cerebral cortical neurons in human periventricular heterotopia, Neuron 21 (6) (1998) 1315–1325.
[98] A. Verloes, N. Di Donato, J. Masliah-Planchon, M. Jongmans, O.A. Abdul-Raman, B. Albrecht, et al., Baraitser-Winter cerebrofrontofacial syndrome: delineation of the spectrum in 42 cases, Eur. J. Hum. Genet. 23 (3) (2015) 292–301.
[99] N. Di Donato, A. Kuechler, S. Vergano, W. Heinritz, J. Bodurtha, S.R. Merchant, et al., Update on the ACTG1-associated Baraitser-Winter cerebrofrontofacial syndrome, Am. J. Med. Genet. 170 (10) (2016) 2644–2651.
[100] B.S. Kasper, A. Dörfler, N. Di Donato, E.M. Kasper, D. Wieczorek, J. Hoyer, et al., Central nervous system anomalies in two females with Borjeson-Forssman-Lehmann syndrome, Epilepsy Behav. 69 (2017) 104–109.
[101] K. Poirier, N. Lebrun, L. Broix, G. Tian, Y. Saillour, C. Boscheron, et al., Mutations in TUBG1, DYNC1H1, KIF5C and KIF2A cause malformations of cortical development and microcephaly, Nat. Genet. 45 (6) (2013) 639–647.
[102] Y.T.K. Yuen, I. Guella, E. Roland, M. Sargent, C. Boelman, Case reports: novel TUBG1 mutations with milder neurodevelopmental presentations, BMC Med. Genet. 20 (1) (2019) 95.
[103] C. Cardoso, R.J. Leventer, J.J. Dowling, H.L. Ward, J. Chung, K.S. Petras, et al., Clinical and molecular basis of classical lissencephaly: mutations in the LIS1 gene (PAFAH1B1), Hum. Mutat. 19 (1) (2002) 4–15.
[104] F. Sicca, A. Kelemen, P. Genton, S. Das, D. Mei, F. Moro, et al., Mosaic mutations of the LIS1 gene cause subcortical band heterotopia, Neurology 61 (8) (2003) 1042–1046.
[105] D.J. Morris-Rosendahl, J. Najm, A.M. Lachmeijer, L. Sztriha, M. Martins, A. Kuechler, et al., Refining the phenotype of alpha-1a Tubulin (TUBA1A) mutation in patients with classical lissencephaly, Clin. Genet. 74 (5) (2008) 425–433.
[106] K. Poirier, D.A. Keays, F. Francis, Y. Saillour, N. Bahi, S. Manouvrier, et al., Large spectrum of lissencephaly and pachygyria phenotypes resulting from de novo missense mutations in tubulin alpha 1A (TUBA1A), Hum. Mutat. 28 (11) (2007) 1055–1064.
[107] N. Bahi-Buisson, K. Poirier, F. Fourniol, Y. Saillour, S. Valence, N. Lebrun, et al., The wide spectrum of tubulinopathies: what are the key features for the diagnosis? Brain 137 (Pt 6) (2014) 1676–1700.
[108] T. Mitani, J. Punetha, I. Akalin, D. Pehlivan, M. Dawidziuk, Z. Coban Akdemir, et al., Bi-allelic pathogenic variants in TUBGCP2 cause microcephaly and lissencephaly spectrum disorders, Am. J. Hum. Genet. 105 (5) (2019) 1005–1015.
[109] S. Neri, E. Ferlazzo, E. Africa, P. Versace, M. Ascoli, G. Mastroianni, et al., Novel COL4A2 mutation causing familial malformations of cortical development, Eur. Rev. Med. Pharmacol. Sci. 25 (2) (2021) 898–905.
[110] D. Eccles, D. Bunyan, S. Barker, B. Castle, BRCA1 mutation and neuronal migration defect: implications for chemoprevention, J. Med. Genet. 42 (7) (2005) e42.
[111] D.M. Eccles, S. Barker, D.T. Pilz, C. Kennedy, Neuronal migration defect in a BRCA1 gene carrier: possible focal nullisomy? J. Med. Genet. 40 (3) (2003) e24.
[112] S. Lee, D.Y. Chen, M.S. Zaki, R. Maroofian, H. Houlden, N. Di Donato, et al., Bi-allelic loss of human APC2, encoding adenomatous polyposis coli protein 2, leads to lissencephaly, subcortical heterotopia, and global developmental delay, Am. J. Hum. Genet. 105 (4) (2019) 844–853.
[113] M. Kielar, F.P. Tuy, S. Bizzotto, C. Lebrand, C. de Juan Romero, K. Poirier, et al., Mutations in Eml1 lead to ectopic progenitors and neuronal heterotopia in mouse and human, Nat. Neurosci. 17 (7) (2014) 923–933.
[114] F. Radmanesh, A.O. Caglayan, J.L. Silhavy, C. Yilmaz, V. Cantagrel, T. Omar, et al., Mutations in LAMB1 cause cobblestone brain malformation without

muscular or ocular abnormalities, Am. J. Hum. Genet. 92 (3) (2013) 468–474.
[115] K. Mishra-Gorur, A.O. Çağlayan, A.E. Schaffer, C. Chabu, O. Henegariu, F. Vonhoff, et al., Mutations in KATNB1 cause complex cerebral malformations by disrupting asymmetrically dividing neural progenitors, Neuron 84 (6) (2014) 1226–1239.
[116] V. Bhat, S.C. Girimaji, G. Mohan, H.R. Arvinda, P. Singhmar, M.R. Duvvari, et al., Mutations in WDR62, encoding a centrosomal and nuclear protein, in Indian primary microcephaly families with cortical malformations, Clin. Genet. 80 (6) (2011) 532–540.
[117] T.W. Yu, G.H. Mochida, D.J. Tischfield, S.K. Sgaier, L. Flores-Sarnat, C.M. Sergi, et al., Mutations in WDR62, encoding a centrosome-associated protein, cause microcephaly with simplified gyri and abnormal cortical architecture, Nat. Genet. 42 (11) (2010) 1015–1020.
[118] C.L. Alston, M.T. Veling, J. Heidler, L.S. Taylor, J.T. Alaimo, A.Y. Sung, et al., Pathogenic Bi-allelic mutations in NDUFAF8 cause leigh syndrome with an isolated complex I deficiency, Am. J. Hum. Genet. 106 (1) (2020) 92–101.
[119] A. Yanagisawa, C. Bouchet, S. Quijano-Roy, S. Vuillaumier-Barrot, N. Clarke, S. Odent, et al., POMT2 intragenic deletions and splicing abnormalities causing congenital muscular dystrophy with mental retardation, Eur. J. Med. Genet. 52 (4) (2009) 201–206.
[120] M.M. Nabhan, N. ElKhateeb, D.A. Braun, S. Eun, S.N. Saleem, H. YungGee, et al., Cystic kidneys in fetal Walker-Warburg syndrome with POMT2 mutation: intrafamilial phenotypic variability in four siblings and review of literature, Am. J. Med. Genet. 173 (10) (2017) 2697–2702.
[121] N.J. Lambacher, A.L. Bruel, T.J. van Dam, K. Szymańska, G.G. Slaats, S. Kuhns, et al., TMEM107 recruits ciliopathy proteins to subdomains of the ciliary transition zone and causes Joubert syndrome, Nat. Cell Biol. 18 (1) (2016) 122–131.