







openheart Update in imaging of cancer therapy-related cardiac toxicity in adults

Esmée C de Baat ¹, Willeke R Naaktgeboren ^{2,3}, Tim Leiner ⁴,
Arco J Teske ⁵, Jesse Habets ^{4,6}, Heynric B Grotenhuis ⁷

► Prepublication history and additional material is published online only. To view please visit the journal online (<http://dx.doi.org/10.1136/openhrt-2020-001506>).

To cite: de Baat EC, Naaktgeboren WR, Leiner T, *et al.* Update in imaging of cancer therapy-related cardiac toxicity in adults. *Open Heart* 2021;**8**:e001506. doi:10.1136/openhrt-2020-001506

JH and HBG contributed equally.

Received 5 November 2020
Revised 8 January 2021
Accepted 22 February 2021

ABSTRACT

Over the past decades, prognosis of patients with cancer has strongly improved and the number of cancer survivors is rapidly growing. Despite this success, cancer treatment is associated with development of serious cardiovascular diseases including left ventricular (LV) systolic dysfunction, heart failure, valvular disease, myocardial infarction, arrhythmias or pericardial diseases. Serial non-invasive cardiac imaging is an important tool to detect early signs of cardiotoxicity, to allow for timely intervention and provide optimal circumstances for long-term prognosis. Currently, echocardiographic imaging is the method of choice for the evaluation of myocardial function during and after cancer therapy. However, 2D echocardiography may fail to detect subtle changes in myocardial function, potentially resulting in a significant delay of therapeutic intervention to impede advanced cardiac disease states with more overt systolic dysfunction. Strain imaging is a promising method for early detection of myocardial dysfunction and may predict future changes in LV ejection fraction. The use of three-dimensional echocardiography may overcome the limitations of 2D echocardiography with more precise and reproducible measurements of LV performance. Cardiac MRI is the gold standard for volumetric assessment and can also be used to perform myocardial tissue characterisation. Visualisation of oedema and fibrosis may provide insights into the degree and disease course of cardiotoxicity and underlying pathophysiological mechanisms. There is growing body of literature regarding the promising role of these advanced imaging modalities in early detection of cardiotoxicity. With this overview paper, new insights and recent results in literature regarding echocardiographic and cardiac magnetic resonance imaging of cancer therapy-related cardiac dysfunction in post-cancer therapy adults will be highlighted.

INTRODUCTION

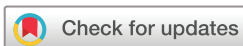Over the past decades, prognosis of patients with cancer has strongly improved and the number of cancer survivors is rapidly growing.¹ Despite this success, cancer treatment is associated with increased risk of morbidity and mortality during long-term follow-up.² Current anticancer protocols include anthracyclines, tyrosine kinase inhibitors and monoclonal antibody therapy, which can cause ventricular systolic

dysfunction (cancer treatment-related cardiac dysfunction (CTRCD)) later in life. CTRCD may progress to heart failure over time.² The incidence and degree of CTRCD depends on type of the used cancer drug, cumulative dose and (pre-)existing cardiovascular comorbidities.³

Currently, echocardiographic imaging is the method of choice for the evaluation of myocardial function during and after cancer therapy. Left ventricular (LV) ejection fraction (EF) is frequently used as predictor for cardiac outcomes, but is not the optimal parameter for detection of subtle alterations in systolic myocardial performance.⁴ Compensatory mechanisms may mask subtle LV dysfunction and clinical manifestations of myocardial injury can therefore occur years after cancer therapy.⁴ Asymptomatic patients with CTRCD may remain unrecognised by serial LVEF assessment, so early therapeutic intervention can be delayed until a later cardiac disease state. Early treatment with heart failure medication may improve recovery of myocardial dysfunction in a substantial part of patients.⁵

In recent years, the field of cardio-oncology has substantially evolved and the number of published studies is growing exponentially. Accordingly, the purpose of this overview paper is to provide a summary of the latest insights and recent results in literature about the current role of echocardiographic and cardiac magnetic resonance imaging (MRI) monitoring of CTRCD in adult patients with cancer and survivors.

Hence, a non-systematic literature search in PubMed and EMBASE was performed to extract original reports about imaging parameters for cardiac surveillance in patients with cancer treated with cardiotoxic treatment. A narrative synthesis of those reports with potential impact on clinical practice and future research is provided in the current manuscript. Imaging modalities as equilibrium radionuclide angiography (also known as multigated acquisition scan), cardiac CT



© Author(s) (or their employer(s)) 2021. Re-use permitted under CC BY-NC. No commercial re-use. See rights and permissions. Published by BMJ.

For numbered affiliations see end of article.

Correspondence to

Dr Heynric B Grotenhuis; H.B. Grotenhuis@umcutrecht.nl

and nuclear imaging are considered beyond the scope of this article.

ECHOCARDIOGRAPHY

LV systolic function

The most widely used method for the evaluation of LV function in patients with cancer at risk for CTRCD is assessment of LVEF by two-dimensional (2D) echocardiography.⁴ The European Society of Cardiology position paper from 2016 defined the lower limit of normal of LVEF as 50%, whereas the American Society of Echocardiography (ASE)/European Association of Cardiovascular Imaging (EACVI) expert consensus from 2014 defined CTRCD as a decrease in LVEF exceeding 10% points, to a value <53%.^{2,4} However, LVEF measured by 2D echocardiography is less suited to detect subtle changes in systolic function since the variability in LVEF measures can be approximately 10%.⁶ This may be caused by LV geometric assumptions and difficulties in visualising the apex. Abnormalities in regional wall displacement can also be difficult to detect with 2D echocardiography.⁴ In addition, LVEF is susceptible to volume loading conditions which may vary significantly during chemotherapy.

Changes in LVEF ultimately occur when compensatory mechanisms fail in the affected myocardium. Recent developments in echocardiographic techniques including myocardial strain by speckle tracking echocardiography (STE) and three-dimensional (3D) echocardiography offer possibilities for more accurate and subclinical detection of systolic dysfunction.^{6,7} Thavendirathan *et al* demonstrated that during treatment of patients with breast cancer with stable cardiac function, estimations of LVEF by 3D echocardiography had temporal variability of approximately 6%.⁶

Myocardial deformation

STE quantifies myocardial deformation by tracking speckle displacement during the cardiac cycle. Strain is expressed as percentage, which corresponds with the amount of deformation in a region of interest (ie, shortening or lengthening) in respect to the initial length, often measured at the end of diastole. The most evaluated STE parameter is 2D global longitudinal strain (GLS), which is the average of the strain values in the longitudinal direction of all 17 segments according to the ASE/EACVI LV segmentation model.⁸ Recently, 3D strain measurements are emerging, for which, similar to 3D LVEF assessment, no multiple apical images are required.

In the last decade, landmark reports demonstrated the additive value of strain assessment after cardiotoxic treatments.^{9–11} These results revealed that early decreases in deformation parameters during or after cancer therapy in adults allowed to predict subsequent LVEF deterioration. The ASE/EACVI Expert Consensus therefore strongly supports the use of GLS during follow-up, with a clinically significant deterioration of LV deformation supported by

a relative percentage decrease of >15% when compared with baseline. Changes of <8% are considered normal as this concerns inter-variability and intra-variability of measurements.⁴ A recent prospective study in adults with lymphoma or leukaemia who were treated with a cumulative anthracyclines dose up to 300 mg/m², demonstrated that (2D) GLS >−17.45% at a cumulative anthracycline dose of >150 mg/m² is an independent predictor of future CTRCD, defined as a decrease in the LVEF of >10% points to a value <53%.¹² Pretreatment measurements of GLS in this cohort were significantly lower in the CTRCD group than in the non-CTRCD group, which may suggest an increased baseline risk profile for cardiovascular disease. This finding is supported by the study of Ali *et al*; their results demonstrated that reduced baseline GLS was a strong predictor of cardiac events in patients with haematologic cancers. A GLS threshold of −17.5% before anthracycline therapy would have correctly identified 86% of the patients who develop a cardiac event after start of chemotherapy, defined as symptomatic heart failure or cardiac death.¹³

In addition, worse basal longitudinal strain after chemotherapy was—in contrast to worse GLS—associated with CTRCD in 61 anthracycline-treated patients. Since GLS is the average of all LV segments, it is possible to underestimate regional impairment, whereas basal longitudinal strain may be a more sensitive marker of CTRCD. However, further research is needed to assess its clinical relevance.¹⁴

Global circumferential strain (GCS) may also be predictive for the occurrence of CTRCD. In the study of Narayan *et al*, every 1% reduction in GCS compared with baseline circumferential strain was associated with an OR of 1.21 (95% CI 1.10 to 1.34) for developing CTRCD in women receiving breast cancer therapy (n=135), independent of relevant co-variables such as age, history of cardiovascular risk factors, treatment regimen and time since start of treatment.¹⁵

A novel deformation parameter—area strain (AS)—can be obtained with 3D STE. This parameter is calculated by combining the effects of GLS and GCS, so AS can be considered as parameter that integrates LV myocardial deformation.¹⁶ In 67 patients with breast cancer, the mean of global AS (%) deteriorated significantly between baseline and after anthracycline therapy (−30.2±4.5 and −27.5±5.4, respectively).¹⁷

Right ventricular (RV) function

Assessment of RV function is considered increasingly important. A recent report in patients with cancer treated with cardiotoxic treatment demonstrated concomitant abnormalities in longitudinal strain of the free RV wall in 75% of cases (n=20) with LVEF drop >10% to <53% (6 months after initiation of chemotherapy).¹⁸ Conventional RV functional parameters (ie, tricuspid annular plane systolic excursion) were within normal ranges, suggesting that this novel RV strain parameter could be useful as early marker for (sub)clinical RV toxicity. These

results should be affirmed in larger studies with a longer follow-up period.

LV mass and diastolic function

Lipshultz *et al* demonstrated that both LV thickness-dimension ratio and LV mass were significantly reduced in anthracycline-treated childhood cancer survivors.¹⁹ However, in adults, early evidence of remodelling may be reversible as Narayan *et al* demonstrated increased LV mass 1 year after anthracycline therapy which normalised in the years thereafter.²⁰

Reduced LV diastolic function may also occur as part of CTRCD, as reflected by abnormal mitral E velocity, E/A ratio, isovolumic relaxation time or tissue Doppler velocities.⁴ Anthracycline dose, age at treatment and BMI have been reported as risk factors of diastolic dysfunction.^{21 22} However, the prognostic value of LV diastolic impairment to predict CTRCD is doubtful because of inconsistent results regarding its ability to predict subsequent occurrence of systolic dysfunction.^{20 22 23}

CARDIAC MAGNETIC RESONANCE IMAGING

Cardiac MRI is a non-invasive imaging technique that allows for accurate and reproducible assessment of biventricular volumes, mass and function with negligible inter-observer and intra-observer variability.^{24 25} Besides anatomical and functional assessment, cardiac MRI allows for myocardial tissue characterisation by use of late gadolinium enhancement (LGE) and quantitative mapping techniques (T1 and T2 mapping).²⁶

LV function

For the surveillance of oncology patients, cardiac MRI-derived LVEF is considered as reference standard for LV systolic performance.²⁴ To detect small changes in LVEF, assessment with cardiac MRI is well-suited in patients with good health and non-cancer heart failure with a temporal variability of 2.4%–7.3%.²⁵

Recent reports have demonstrated that also cardiac MRI-derived LV strain allows detecting subclinical LV dysfunction, during and after potentially cardiotoxic cancer therapy.^{27 28} During follow-up of 41 trastuzumab-treated patients, significant reductions in GLS and GCS were observed at 6 and 12 months when compared with baseline. These alterations were related with concurrent decreases in LVEF.²⁹ To enhance the potential transition from echocardiographic LV-measurements to cardiac MRI, Jolly *et al* proposed an automated measurement of GCS from CMR cine images in patients treated with chemotherapy. They demonstrated that GCS can be obtained in ~7 min from routine cine LV short axis images in 98.6% of the patients (n=72) and the observed worsening in GCS correlated with LVEF decline on cardiac MRI.²⁸

LV volume

Alterations in LV dimensions should always be considered when evaluating changes in LVEF, since a decline in

LVEF can be the result of an increased left ventricular end systolic volume (LVESV) or reduction of left ventricular end diastolic volume (LVEDV). CTRCD is associated with an increased LVESV (with a preserved LVEDV)—as a reflection of reduced myocardial contractility—while reduced LVEDV can, for example, be observed in patients who are volume-depleted during chemotherapy.²⁶ Two recent studies demonstrated that CTRCD, based on drop in strain or LVEF measurements, was related to an isolated decline in LVEDV in 16%–19% of patients, indicating that in part of the patients with decreased systolic function, this may be the result of volume depletion.^{27 30}

Also important, an increased LVESV due to CTRCD can (partly) be compensated by increased LVEDV as part of cardiac remodelling, to preserve LVEF and cardiac output. Evaluation of LV dimensions by cardiac MRI should therefore be an integral part of cardiac evaluation, in addition to systolic function parameters.

LV mass can also be measured by cardiac MRI with higher accuracy and reproducibility compared with echocardiography.³¹ Neilan *et al* demonstrated an inverse correlation between decrease in LV mass after chemotherapy and anthracycline dose, and that LV mass index <57 g/m² was a predictor of adverse cardiac events.³² Also, Jordan *et al* showed a significant association between worsening of heart failure symptoms and declines in LV mass after accounting for both changes in LVEF and changes in body weight.³³ This may suggest that remodelling of the LV structure precedes myocardial function impairment. Evaluation and quantification of LV mass by cardiac MRI is therefore advised in (suspected) CTRCD.

RV function

In addition, cardiac MRI can be used to study RV performance. Several studies have demonstrated significant changes in RV systolic function, structure and dimensions during and after systemic cancer treatment.^{34–36} Recently, a prospective study of patients with breast cancer (n=41) demonstrated a significant decrease in RVEF from 58.3% (95% CI 57.1% to 59.5%) to 53.9% (95% CI 52.5% to 55.4%, p<0.001) and increases in right ventricular end diastolic volume (RVEDV) and right ventricular end systolic volume (RVESV) at 6 months after initiation of trastuzumab, however, these measurements reversed after completion of therapy. RVEF and LVEF changed in a similar pattern, but the relationship was non-significant.³⁶ Further studies are required to explore the prognostic value of RV evaluation in oncology patients.

Myocardial tissue characterisation

Imaging by cardiac MRI enables visualisation and characterisation of myocardial tissue.^{37 38} Formation of fibrosis due to collagen breakdown is one of the proposed molecular mechanisms of anthracycline-associated myocardial remodelling.³⁹ There are several cardiac MRI techniques to detect fibrosis, including LGE imaging and mapping parameters. Visualisation of fibrosis with LGE is generally a result of regional

differences in signal intensity.³⁷ Since interstitial fibrosis as late effect of cancer treatment is likely to be diffuse,²⁴ LGE seems less suitable for the surveillance of CTRCD,^{35–37 40–42} except for the detection of toxic myocarditis or previous cardiac events such as myocardial infarcts.⁴⁰ To detect diffuse myocardial diseases, specific mapping parameters (T1, T2, T2*) and extracellular volume (ECV) are important cardiac MRI techniques that depend on molecular environment in a myocardial voxel and quantify intracellular changes of the cardiomyocyte and extracellular changes in the myocardial interstitium.^{37 38}

Molecular environment changes may be caused by oedema, interstitial fibrosis or other more rare causes (ie, cardiac amyloidosis). Increases in T1 and T2 values reflect myocardial fibrosis and oedema, respectively. As a result of these processes, the extracellular matrix can expand, expressed by an increased ECV.³⁸ In a recent pig study, cardiac MRI evaluation over a period of 16 weeks after anthracycline administration showed that the acute phase of myocardial injury was characterised by prolongation of T2 relaxation time. Significant changes in LVEF, ECV and T1 mapping occurred only weeks later. T2 relaxation time prolongation in the acute phase was correlated with oedema within the cardiomyocyte. Withholding anthracycline administration at the time of occurrence of T2 abnormalities prevented development of subsequent LV systolic dysfunction.⁴³

Reports of myocardial mapping in oncology patients are generally mixed in results; myocardial oedema after receipt of anthracycline and/or trastuzumab was demonstrated in almost half of the patients at 1 or 4 months after initiation of therapy, but LV dysfunction could not be predicted.³⁴ In a 5-year follow-up study, both LV function and T1 mapping values were within the normal limits.⁴² Muehlberg *et al* described different findings with regard to cardiac MRI values in sarcoma patients shortly after anthracycline-based chemotherapy. Within 48 hours after chemotherapy initiation, native T1 decreased significantly in patients who developed CTRCD (LVEF drop >10% points) at the end of the chemotherapy. T1 values normalised in all CTRCD cases after treatment completion and myocardial T2 mapping values did not significantly change during chemotherapy.⁴¹ The authors suggest that development of CTRCD may consist of different phases and therefore the interpretation of cardiac MRI results after anthracycline therapy may be adapted to the timing of assessment.⁴¹

In addition, a recent study by Altaha *et al* demonstrated greater temporal differences in T1, T2 and ECV in patients with HER2-positive breast cancer with CTRCD (n=10), defined as >10% reduction in LVEF to <55% or >15% relative reduction in GLS, compared with patients without CTRCD and healthy participants. However, the results in patients with CTRCD overlap with variability in healthy participants, emphasising

the difficulty of interpreting mapping measurements in individual patients.⁴⁴

A landmark study of Jordan *et al* compared pretreatment (n=37) and post-treatment patients with cancer (n=37) with cancer-free controls (n=236), demonstrating elevated ECV 3 years after anthracycline treatment.⁴⁵ It is important to stress that cardiovascular risk factors, often present in patients with cancer,⁴⁶ are associated with elevations in ECV. Increase in ECV in this study was independent of cardiovascular risk factors, which corroborates the hypothesis that myocardial fibrosis develops after cancer treatment.⁴⁵ Accordingly, pretreatment cardiac MRI is crucial to interpret the myocardial tissue characteristics reflected by cardiac MRI. A more recent study indicated that interstitial myocardial fibrosis—reflected by elevated ECV—may arise within 3 months after initiation of cardiotoxic chemotherapy (71% received anthracyclines).⁴⁷ De Souza *et al* also suggested that decreased cardiomyocyte size may contribute to an increase in ECV.⁴⁸

The online supplemental contains E-figures that demonstrate the different cardiac MRI parameters in a case with CTRCD.

CLINICAL PRACTICE

Currently, cardiac follow-up of patients with increased risk for CTRCD is based on expert consensus. Teske *et al* provided an overview about the available evidence and clinical practice in our institution which will be referred to in the following section.⁴⁹ Typically, the surveillance of adult patients with cancer who will receive cardiotoxic agents starts before initiation of cancer therapy and ends up to 1 year after last chemotherapy dose. The frequency of follow-up is based on the individual risk profile for CTRCD, which incorporates parameters such as type and dosage of chemotherapy, age at time of chemotherapy and presence of cardiovascular risk factors.⁴⁹

The results of the recently published studies show that CTRCD can affect multiple parts of the myocardium and therefore reinforce the recommendation of a comprehensive and systematic echocardiographic assessment of at least LV systolic and diastolic function, LV strain and RV function.⁴ It is important to use the same imaging modality over time to enhance adequate interpretation of serial measurements and identification of individual CTRCD.⁴ Since the accuracy in LV measurements by 3D echocardiography has expanded in clinical care, this modality is recommended for serial LVEF measurements in patients with cancer.⁴ Regarding myocardial strain, a clear superiority of 3D STE over 2D STE has not been reported yet, although results of 3D-derived strain are promising.^{16 17}

The use of cardiac MRI is recommended as a complementary tool when echocardiography is inconclusive

and when evaluation of other underlying causes of LV dysfunction is indicated.²⁻⁴ Despite the superior qualities of cardiac MRI, this modality is (in the Netherlands) approximately three times more expensive and less available than echocardiography. In our own institution, CMR is routinely used in case of clinical CTRCD on transthoracic echocardiography and considered in case of subclinical CTRCD.⁴⁹ Furthermore, cardiac MRI provides additional diagnostic and prognostic information in patients with known cardiac disease, that is, previous myocardial infarction.

Heart failure medication is only initiated in adult patients with evidence of CTRCD, defined as LVEF >10% decline to LVEF <53% or GLS decline of 15% and NYHA ≥II/IV or LVEF <45% on echocardiography.⁴⁹

FUTURE PERSPECTIVES

In the future, strain measurements may replace LVEF for early detection of CTRCD and its incremental clinical value needs to be further explored. An important question remains what the consequences are for an asymptomatic patient with reduced strain and preserved LVEF. The SUCCOUR (Strain sURveillance of Chemotherapy for improving Cardiovascular Outcomes) trial is the first (ongoing) randomised controlled trial in anthracycline-treated patients with cancer at risk of heart failure which compares the effect of GLS-guided versus LVEF-guided management on 3D LVEF 3 years after diagnosis.⁵⁰

Parameters as RV function, LV dimensions and mass, regional function as expressed by basal longitudinal strain, circumferential strain, AS and diastolic measures have shown promising results to suggest that

subclinical myocardial changes may precede global LV dysfunction, but it is too early to incorporate these in decision making and warrant therapeutic intervention. Other novel technical parameters (eg, torsion, Tei index) are of potential interest, yet their incremental value for clinical purposes has to be explored.

In addition, more research is needed on diagnostic and risk prediction models that combine echocardiographic measures with other potential predictors such as genetics, cardiovascular risk factors and blood biomarkers to improve and individualise cardiac surveillance and treatment.

Myocardial tissue characterisation by cardiac MRI offers the opportunity to improve follow-up of the myocardium over time and, especially in light of the potential introduction of anti-fibrosis medication, may provide important clinical information. There are only few high-quality studies that evaluated early (within 3 months after treatment) effects of cancer treatment, so more evidence is needed to elucidate its prognostic value. In the future, diffusion-weighted cardiac MRI images will also be available for the evaluation of the myocardium, which enables evaluation of myocyte necrosis during the acute stage and has the potential to become a new biomarker.

CONCLUSION

Imaging techniques that allow for detection of early changes in myocardial function are crucial in the follow-up of cardiovascular diseases after cardiotoxic cancer treatment as exemplified in figure 1. Advanced imaging techniques may be of additive value due to better reproducibility and, even more important, the

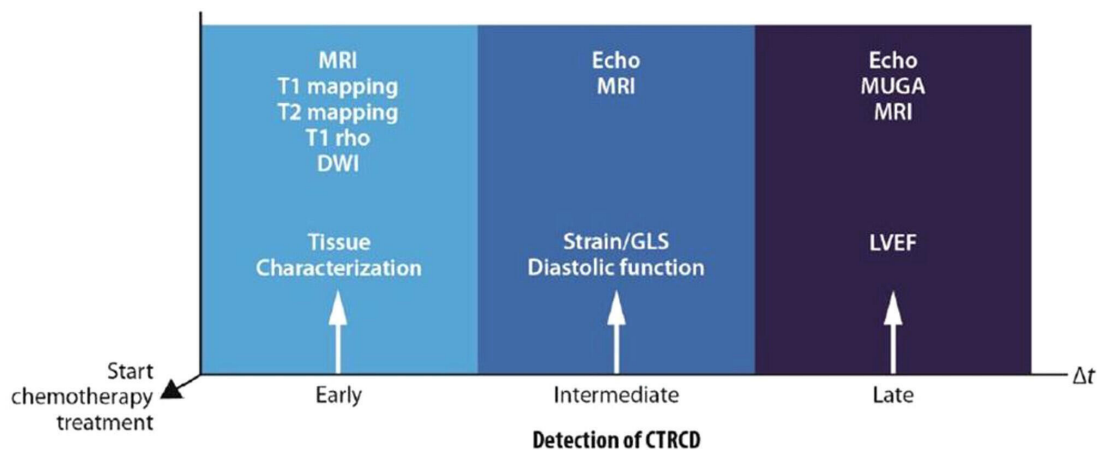


Figure 1 Detection of CTRCD using non-invasive imaging. The progress of CTRCD can be subdivided into different phases. Multiple non-invasive modalities play an important role in order to detect CTRCD as early as possible. Interstitial myocardial changes including oedema and fibrosis shortly after start of chemotherapy can be reflected by tissue characterisation with cardiac MRI. Thereafter, changes in myocardial function may occur. Myocardial strain is an important parameter of early to intermediate cardiac impairment which can be measured by echocardiography and MRI. On the long term, months to years after start of chemotherapy treatment, asymptomatic left ventricle systolic dysfunction may progress to heart failure so follow-up based on left ventricular ejection fraction is recommended. CTRCD, cancer treatment-related cardiac dysfunction; DWI, diffusion-weighted imaging; GLS, global longitudinal strain; LVEF, left ventricular ejection fraction; MRI, magnetic resonance imaging; MUGA, multigated acquisition scan.

introduction of novel parameters appears to improve our pathophysiological understanding of CTRCD and predict subsequent cardiac outcome. Tissue characterisation by cardiac MRI and early signs of myocardial dysfunction detected by STE may provide further information about the course of cardiotoxicity. The use of a homogeneous outcome definition (LVEF vs GLS) and clear cut-off points are warranted when confirming the promising results of advanced imaging techniques in larger study populations.

Author affiliations

- ¹Pediatric Oncology, Princess Maxima Center, Utrecht, The Netherlands
²Psychosocial Research and Epidemiology, Antoni van Leeuwenhoek Netherlands Cancer Institute, Amsterdam, The Netherlands
³Julius Center for Health Sciences and Primary Care, University Medical Center Utrecht, Utrecht University, Utrecht, The Netherlands
⁴Radiology, University Medical Center Utrecht Imaging Division, Utrecht, The Netherlands
⁵Cardiology, University Medical Centre Utrecht, Utrecht, The Netherlands
⁶Radiology, University Medical Center Nijmegen, Nijmegen, The Netherlands
⁷Pediatric Cardiology, Wilhelmina Children's Hospital University Medical Centre, Utrecht, The Netherlands

Contributors ECdB, WRN, JH and HBG wrote the manuscript. TL and AJT were co-authors who reviewed and revised the manuscript. All authors approved the final version. JH and HBG are shared last authors.

Funding The authors have not declared a specific grant for this research from any funding agency in the public, commercial or not-for-profit sectors.

Competing interests None declared.

Patient consent for publication Not required.

Provenance and peer review Not commissioned; externally peer reviewed.

Data availability statement There are no data in this work.

Open access This is an open access article distributed in accordance with the Creative Commons Attribution Non Commercial (CC BY-NC 4.0) license, which permits others to distribute, remix, adapt, build upon this work non-commercially, and license their derivative works on different terms, provided the original work is properly cited, appropriate credit is given, any changes made indicated, and the use is non-commercial. See: <http://creativecommons.org/licenses/by-nc/4.0/>.

ORCID iDs

- Esmée C de Baat <http://orcid.org/0000-0003-2694-8783>
 Willeke R Naaktgeboren <http://orcid.org/0000-0002-5767-7042>
 Tim Leiner <http://orcid.org/0000-0003-1885-5499>
 Arco J Teske <http://orcid.org/0000-0001-5305-1619>
 Jesse Habets <http://orcid.org/0000-0002-8997-2484>
 Heynric B Grotenhuis <http://orcid.org/0000-0002-9625-5969>

REFERENCES

- Heymach J, Krilov L, Alberg A, *et al*. Clinical cancer advances 2018: annual report on progress against cancer from the American Society of Clinical Oncology. *J Clin Oncol* 2018;36:1020–44.
- Zamorano JL, Lancellotti P, Rodriguez Muñoz D, *et al*. 2016 ESC Position Paper on cancer treatments and cardiovascular toxicity developed under the auspices of the ESC Committee for Practice Guidelines: The Task Force for cancer treatments and cardiovascular toxicity of the European Society of Cardiology (ESC). *Eur Heart J* 2016;37:2768–801.
- Chang H-M, Moudgil R, Scarabelli T, *et al*. Cardiovascular Complications of Cancer Therapy: Best Practices in Diagnosis, Prevention, and Management: Part 1. *J Am Coll Cardiol* 2017;70:2536–51.
- Plana JC, Galderisi M, Barac A, *et al*. Expert consensus for multimodality imaging evaluation of adult patients during and after cancer therapy: a report from the American Society of Echocardiography and the European Association of Cardiovascular Imaging. *Eur Heart J Cardiovasc Imaging* 2014;15:1063–93.
- Cardinale D, Colombo A, Bacchiani G, *et al*. Early detection of anthracycline cardiotoxicity and improvement with heart failure therapy. *Circulation* 2015;131:1981–8.
- Thavandiranathan P, Grant AD, Negishi T, *et al*. Reproducibility of echocardiographic techniques for sequential assessment of left ventricular ejection fraction and volumes: application to patients undergoing cancer chemotherapy. *J Am Coll Cardiol* 2013;61:77–84.
- Thavandiranathan P, Poulin F, Lim K-D, *et al*. Use of myocardial strain imaging by echocardiography for the early detection of cardiotoxicity in patients during and after cancer chemotherapy: a systematic review. *J Am Coll Cardiol* 2014;63:2751–68.
- Lang RM, Badano LP, Mor-Avi V, *et al*. Recommendations for cardiac chamber quantification by echocardiography in adults: an update from the American Society of Echocardiography and the European association of cardiovascular imaging. *Eur Heart J Cardiovasc Imaging* 2015;16:233–71.
- Hare JL, Brown JK, Leano R, *et al*. Use of myocardial deformation imaging to detect preclinical myocardial dysfunction before conventional measures in patients undergoing breast cancer treatment with trastuzumab. *Am Heart J* 2009;158:294–301.
- Negishi K, Negishi T, Hare JL, *et al*. Independent and incremental value of deformation indices for prediction of trastuzumab-induced cardiotoxicity. *J Am Soc Echocardiogr* 2013;26:493–8.
- Sawaya H, Sebag IA, Plana JC, *et al*. Assessment of echocardiography and biomarkers for the extended prediction of cardiotoxicity in patients treated with anthracyclines, taxanes, and trastuzumab. *Circ Cardiovasc Imaging* 2012;5:596–603.
- Charbonnel C, Convers-Domart R, Rigaudeau S, *et al*. Assessment of global longitudinal strain at low-dose anthracycline-based chemotherapy, for the prediction of subsequent cardiotoxicity. *Eur Heart J Cardiovasc Imaging* 2017;18:jew223–401.
- Ali MT, Yucel E, Bouras S, *et al*. Myocardial strain is associated with adverse clinical cardiac events in patients treated with anthracyclines. *J Am Soc Echocardiogr* 2016;29:522–7.
- Saijo Y, Kusunose K, Okushi Y, *et al*. Relationship between regional left ventricular dysfunction and cancer-therapy-related cardiac dysfunction. *Heart* 2020;106:1752–8.
- Narayan HK, French B, Khan AM, *et al*. Noninvasive measures of ventricular-arterial coupling and circumferential strain predict cancer Therapeutics-Related cardiac dysfunction. *JACC Cardiovasc Imaging* 2016;9:1131–41.
- Muraru D, Niero A, Rodriguez-Zanella H, *et al*. Three-dimensional speckle-tracking echocardiography: benefits and limitations of integrating myocardial mechanics with three-dimensional imaging. *Cardiovasc Diagn Ther* 2018;8:101–17.
- Santoro C, Arpino G, Esposito R, *et al*. 2D and 3D strain for detection of subclinical anthracycline cardiotoxicity in breast cancer patients: a balance with feasibility. *Eur Heart J Cardiovasc Imaging* 2017;18:930–6.
- Cherata DA, Donoiu I, Diaconu R, *et al*. Longitudinal strain analysis allows the identification of subclinical deterioration of right ventricular function in patients with cancer therapy-related left ventricular dysfunction. *Discoveries* 2019;7:e94.
- Lipshultz SE, Lipsitz SR, Sallan SE, *et al*. Chronic progressive cardiac dysfunction years after doxorubicin therapy for childhood acute lymphoblastic leukemia. *J Clin Oncol* 2005;23:2629–36.
- Narayan HK, Finkelstein B, French B, *et al*. Detailed echocardiographic phenotyping in breast cancer patients: associations with ejection fraction decline, recovery, and heart failure symptoms over 3 years of follow-up. *Circulation* 2017;135:1397–412.
- Serrano JM, González I, Del Castillo S, *et al*. Diastolic dysfunction following anthracycline-based chemotherapy in breast cancer patients: incidence and predictors. *Oncologist* 2015;20:864–72.
- Dorup I, Levitt G, Sullivan I, *et al*. Prospective longitudinal assessment of late anthracycline cardiotoxicity after childhood cancer: the role of diastolic function. *Heart* 2004;90:1214–6.
- Stoddard MF, Seeger J, Liddell NE, *et al*. Prolongation of isovolumetric relaxation time as assessed by Doppler echocardiography predicts doxorubicin-induced systolic dysfunction in humans. *J Am Coll Cardiol* 1992;20:62–9.
- Thavandiranathan P, Wintersperger BJ, Flamm SD, *et al*. Cardiac MRI in the assessment of cardiac injury and toxicity from cancer chemotherapy: a systematic review. *Circ Cardiovasc Imaging* 2013;6:1080–91.
- Grothues F, Smith GC, Moon JCC, *et al*. Comparison of interstudy reproducibility of cardiovascular magnetic resonance with two-dimensional echocardiography in normal subjects and in patients with heart failure or left ventricular hypertrophy. *Am J Cardiol* 2002;90:29–34.

- 26 Jordan JH, Todd RM, Vasu S, *et al.* Cardiovascular magnetic resonance in the oncology patient. *JACC Cardiovasc Imaging* 2018;11:1150–72.
- 27 Jordan JH, Sukpraphrute B, Meléndez GC, *et al.* Early myocardial strain changes during potentially cardiotoxic chemotherapy may occur as a result of reductions in left ventricular end-diastolic volume: the need to interpret left ventricular strain with volumes. *Circulation* 2017;135:2575–7.
- 28 Jolly M-P, Jordan JH, Meléndez GC, *et al.* Automated assessments of circumferential strain from cine CMR correlate with LVEF declines in cancer patients early after receipt of cardio-toxic chemotherapy. *J Cardiovasc Magn Reson* 2017;19:59.
- 29 Ong G, Brezden-Masley C, Dhir V, *et al.* Myocardial strain imaging by cardiac magnetic resonance for detection of subclinical myocardial dysfunction in breast cancer patients receiving trastuzumab and chemotherapy. *Int J Cardiol* 2018;261:228–33.
- 30 Meléndez GC, Sukpraphrute B, D'Agostino RB, *et al.* Frequency of left ventricular End-Diastolic Volume-Mediated declines in ejection fraction in patients receiving potentially cardiotoxic cancer treatment. *Am J Cardiol* 2017;119:1637–42.
- 31 Armstrong AC, Gidding S, Gjesdal O, *et al.* Lv mass assessed by echocardiography and CMR, cardiovascular outcomes, and medical practice. *JACC Cardiovasc Imaging* 2012;5:837–48.
- 32 Neilan TG, Coelho-Filho OR, Pena-Herrera D, *et al.* Left ventricular mass in patients with a cardiomyopathy after treatment with anthracyclines. *Am J Cardiol* 2012;110:1679–86.
- 33 Jordan JH, Castellino SM, Meléndez GC, *et al.* Left ventricular mass change after anthracycline chemotherapy. *Circ Heart Fail* 2018;11:e004560.
- 34 Grover S, Leong DP, Chakrabarty A, *et al.* Left and right ventricular effects of anthracycline and trastuzumab chemotherapy: a prospective study using novel cardiac imaging and biochemical markers. *Int J Cardiol* 2013;168:5465–7.
- 35 Ylänen K, Poutanen T, Savikurki-Heikkilä P, *et al.* Cardiac magnetic resonance imaging in the evaluation of the late effects of anthracyclines among long-term survivors of childhood cancer. *J Am Coll Cardiol* 2013;61:1539–47.
- 36 Barthur A, Brezden-Masley C, Connelly KA, *et al.* Longitudinal assessment of right ventricular structure and function by cardiovascular magnetic resonance in breast cancer patients treated with trastuzumab: a prospective observational study. *J Cardiovasc Magn Reson* 2017;19:44.
- 37 Mewton N, Liu CY, Croisille P, *et al.* Assessment of myocardial fibrosis with cardiovascular magnetic resonance. *J Am Coll Cardiol* 2011;57:891–903.
- 38 Messroghli DR, Moon JC, Ferreira VM, *et al.* Clinical recommendations for cardiovascular magnetic resonance mapping of T1, T2, T2* and extracellular volume: a consensus statement by the Society for cardiovascular magnetic resonance (SCMR) endorsed by the European association for cardiovascular imaging (EACVI). *J Cardiovasc Magn Reson* 2017;19:75.
- 39 Nguyen K-L, Hu P, Ennis DB, *et al.* Cardiac MRI: a translational imaging tool for characterizing anthracycline-induced myocardial remodeling. *Curr Oncol Rep* 2016;18:48.
- 40 Fallah-Rad N, Lytwyn M, Fang T, *et al.* Delayed contrast enhancement cardiac magnetic resonance imaging in trastuzumab induced cardiomyopathy. *J Cardiovasc Magn Reson* 2008;10:5.
- 41 Muehlberg F, Funk S, Zange L, *et al.* Native myocardial T1 time can predict development of subsequent anthracycline-induced cardiomyopathy. *ESC Heart Fail* 2018;5:620–9.
- 42 Kimball A, Patil S, Koczwara B, *et al.* Late characterisation of cardiac effects following anthracycline and trastuzumab treatment in breast cancer patients. *Int J Cardiol* 2018;261:159–61.
- 43 Galán-Arriola C, Lobo M, Vilchez-Tschischke JP, *et al.* Serial Magnetic Resonance Imaging to Identify Early Stages of Anthracycline-Induced Cardiotoxicity. *J Am Coll Cardiol* 2019;73:779–91.
- 44 Althaha MA, Nolan M, Marwick TH, *et al.* Can quantitative CMR tissue characterization adequately identify cardiotoxicity during chemotherapy?: impact of temporal and observer variability. *JACC Cardiovasc Imaging* 2020;13:951–62.
- 45 Jordan JH, Vasu S, Morgan TM, *et al.* Anthracycline-associated T1 mapping characteristics are elevated independent of the presence of cardiovascular comorbidities in cancer survivors. *Circ Cardiovasc Imaging* 2016;9.
- 46 Koene RJ, Prizment AE, Blaes A, *et al.* Shared risk factors in cardiovascular disease and cancer. *Circulation* 2016;133:1104–14.
- 47 Meléndez GC, Jordan JH, D'Agostino RB, *et al.* Progressive 3-Month Increase in LV Myocardial ECV After Anthracycline-Based Chemotherapy. *JACC Cardiovasc Imaging* 2017;10:708–9.
- 48 Ferreira de Souza T, Quinaglia A C Silva T, Osorio Costa F, *et al.* Anthracycline therapy is associated with cardiomyocyte atrophy and preclinical manifestations of heart disease. *JACC Cardiovasc Imaging* 2018;11:1045–55.
- 49 Teske AJ, Linschoten M, Kamphuis JAM, *et al.* Cardio-oncology: an overview on outpatient management and future developments. *Neth Heart J* 2018;26:521–32.
- 50 Negishi T, Thavendiranathan P, Negishi K, *et al.* Rationale and design of the strain surveillance of chemotherapy for improving cardiovascular outcomes: the SUCCOUR trial. *JACC Cardiovasc Imaging* 2018;11:1098–105.