










## ORIGINAL ARTICLE

# Dolichoarteriopathies of the extracranial internal carotid artery: The Plaque At RISK study

Kristine Dilba<sup>1,2</sup> | Dianne H. K. van Dam-Nolen<sup>2</sup>  | Geneviève A. J. C. Crombag<sup>3</sup>  |  
Anja G. van der Kolk<sup>4</sup>  | Peter J. Koudstaal<sup>5</sup>  | Paul J. Nederkoorn<sup>6</sup> |  
Jeroen Hendrikse<sup>4</sup> | Marianne Eline Kooi<sup>3</sup>  | Antonius F. W. van der Steen<sup>1</sup>  |  
Jolanda J. Wentzel<sup>1</sup>  | Aad van der Lugt<sup>2</sup>  | Daniel Bos<sup>2,7</sup> 

<sup>1</sup>Cardiology, Erasmus MC, University Medical Center Rotterdam, Rotterdam, The Netherlands

<sup>2</sup>Radiology and Nuclear Medicine, Erasmus MC, University Medical Center Rotterdam, Rotterdam, The Netherlands

<sup>3</sup>Radiology and Nuclear Medicine, CARIM School for Cardiovascular Diseases, Maastricht University Medical Center, Maastricht, The Netherlands

<sup>4</sup>Radiology, University Medical Center Utrecht, Utrecht, The Netherlands

<sup>5</sup>Neurology, Erasmus MC, University Medical Center Rotterdam, Rotterdam, The Netherlands

<sup>6</sup>Neurology, Amsterdam UMC, University of Amsterdam, Amsterdam, The Netherlands

<sup>7</sup>Epidemiology, Erasmus MC, University Medical Center Rotterdam, Rotterdam, The Netherlands

## Correspondence

Daniel Bos, Department of Radiology and Nuclear Medicine, Department of Epidemiology, Erasmus MC, 3000 CA, Rotterdam, The Netherlands  
Email: d.bos@erasmusmc.nl

## Funding information

This research was performed within the framework of the Center for Translational Molecular Medicine ([www.ctmm.nl](http://www.ctmm.nl)), project PARISK (Plaque At RISK; grant number 01C-202) and supported by the Dutch Heart Foundation (grant number DHF2008-T094). Kristina Dilba was supported by Toegepaste en Technische Wetenschappen project number 10813.

## Abstract

**Background and purpose:** Dolichoarteriopathies of the extracranial part of the internal carotid artery (ICA) are associated with cerebrovascular events, yet information on their prevalence and risk factors remains limited. The aim of the present study therefore was to study the prevalence and risk factors of dolichoarteriopathies in a sample of patients with cerebrovascular symptoms from the Plaque At RISK (PARISK) study.

**Methods:** In a random sample of 100 patients from the PARISK study, multidetector computed tomography angiography (MDCTA) was performed as part of clinical workup. On MDCTA, we evaluated the extracranial trajectory of the ICA by measuring the length (in millimeters), the tortuosity index (TI; defined as the ICA length divided by the shortest possible distance from bifurcation to skull base), and dolichoarteriopathy type (tortuosity, coiling or kinking). Next, we investigated the association between cardiovascular risk factors and these measurements using linear and logistic regression analyses.

**Results:** The mean (standard deviation) length of the ICA was 93 ( $\pm$  14) mm, with a median (interquartile range) TI of 1.2 (1.1–1.3). The overall prevalence of dolichoarteriopathies was 69%, with tortuosity being the most common (72%), followed by coiling (20%), and kinking (8%). We found that age and obesity were associated with a higher TI: difference per 10-year increase in age: 0.05 (95% confidence interval [CI] 0.02–0.08) and 0.16 (95% CI 0.07–0.25) for obesity. Obesity and hypercholesterolemia were associated with a more severe type of dolichoarteriopathy (odds ratio [OR] 2.07 [95% CI 1.04–4.12] and OR 2.17 [95% CI 1.02–4.63], respectively).

**Conclusion:** Dolichoarteriopathies in the extracranial ICA are common in patients with cerebrovascular symptoms, and age, obesity and hypercholesterolemia may play an important role in the pathophysiology of these abnormalities.

## KEYWORDS

atherosclerosis, carotid disease, computed tomography angiography, stroke

This is an open access article under the terms of the Creative Commons Attribution-NonCommercial-NoDerivs License, which permits use and distribution in any medium, provided the original work is properly cited, the use is non-commercial and no modifications or adaptations are made.

© 2021 The Authors. *European Journal of Neurology* published by John Wiley & Sons Ltd on behalf of European Academy of Neurology

## INTRODUCTION

Dolichoarteriopathies are abnormal configurations in the geometry and course of the extracranial part of the internal carotid artery (ICA). These abnormalities have been linked to a wide range of cerebrovascular symptoms, such as transient ischemic attacks (TIAs) and even potentially life-threatening ischemic strokes requiring prompt interventions [1–6]. Despite the potential harm of carotid dolichoarteriopathies, information on their prevalence and etiology remains limited.

The prevalence of dolichoarteriopathies in the ICA may range from 4% to 66% in symptomatic patients [7,8]. An important explanation for this wide range of prevalence estimates is the heterogeneity in the assessment of dolichoarteriopathies across studies. First, the main noninvasive imaging modality that has been used to assess carotid dolichoarteriopathies is ultrasonography. Important shortcomings of ultrasonography for assessing dolichoarteriopathies are its restricted coverage of the trajectory of the ICA and a high observer dependency. Second, the classification of dolichoarteriopathies currently relies on subjective, visual assessments, which are particularly troublesome when differentiating between straight and slightly tortuous arteries, leading to substantial misclassification of dolichoarteriopathies.

In addition to information on the prevalence of carotid dolichoarteriopathies, the evidence on risk factors for dolichoarteriopathies remains equally inconsistent. In some studies among patients with a wide range of pathologies including stroke, dementia or other neurological conditions, hypertension, body mass index (BMI), hypercholesterolemia, diabetes mellitus and cigarette smoking were linked to dolichoarteriopathies [4,5,7–9], while other studies did not find any association of these factors with dolichoarteriopathies [10–13]. Yet, given the potential harm of these aberrations, detailed insight into the contributing risk factors is paramount.

We therefore investigated the prevalence of ICA dolichoarteriopathies using quantitative measurements and traditional visual rating in a random sample of symptomatic stroke and TIA patients who underwent multidetector computed tomography angiography (MDCTA). Furthermore, we investigated the association between common cardiovascular risk factors and these dolichoarteriopathies.

## METHODS

### Study population

We randomly selected 100 patients from the Plaque At RISK (PARISK) cohort (clinicaltrials.gov: NCT01208025) who underwent MDCTA between September 2010 and December 2014. The PARISK study is a Dutch prospective multicenter cohort study that uses noninvasive plaque imaging to identify patients with mild to moderate carotid artery stenosis (<70%) and an increased risk of recurrent stroke [14].

### Statement of ethics

The PARISK study was approved by the institutional Medical Ethical Committees. Written informed consent was obtained from each participant in each center before enrollment.

### MDCTA image acquisition

Image acquisition was performed using a 16-, 64- or 128-slice MDCTA system using a standardized optimized contrast-enhanced MDCTA protocol (120 kVp, 150–180 mAs, collimation  $16 \times 0.75$  mm or  $64 \times 2 \times 0.6$  mm, pitch <1), ranging from the ascending aorta to the intracranial circulation (3 cm above the sella turcica) [14]. Image reconstructions are made with a field of view of 120–160 mm, matrix size  $512 \times 512$ , slice thickness 1.0 mm, increment 0.6–0.7 mm and with intermediate reconstruction algorithms.

### Assessment of ICA dolichoarteriopathies

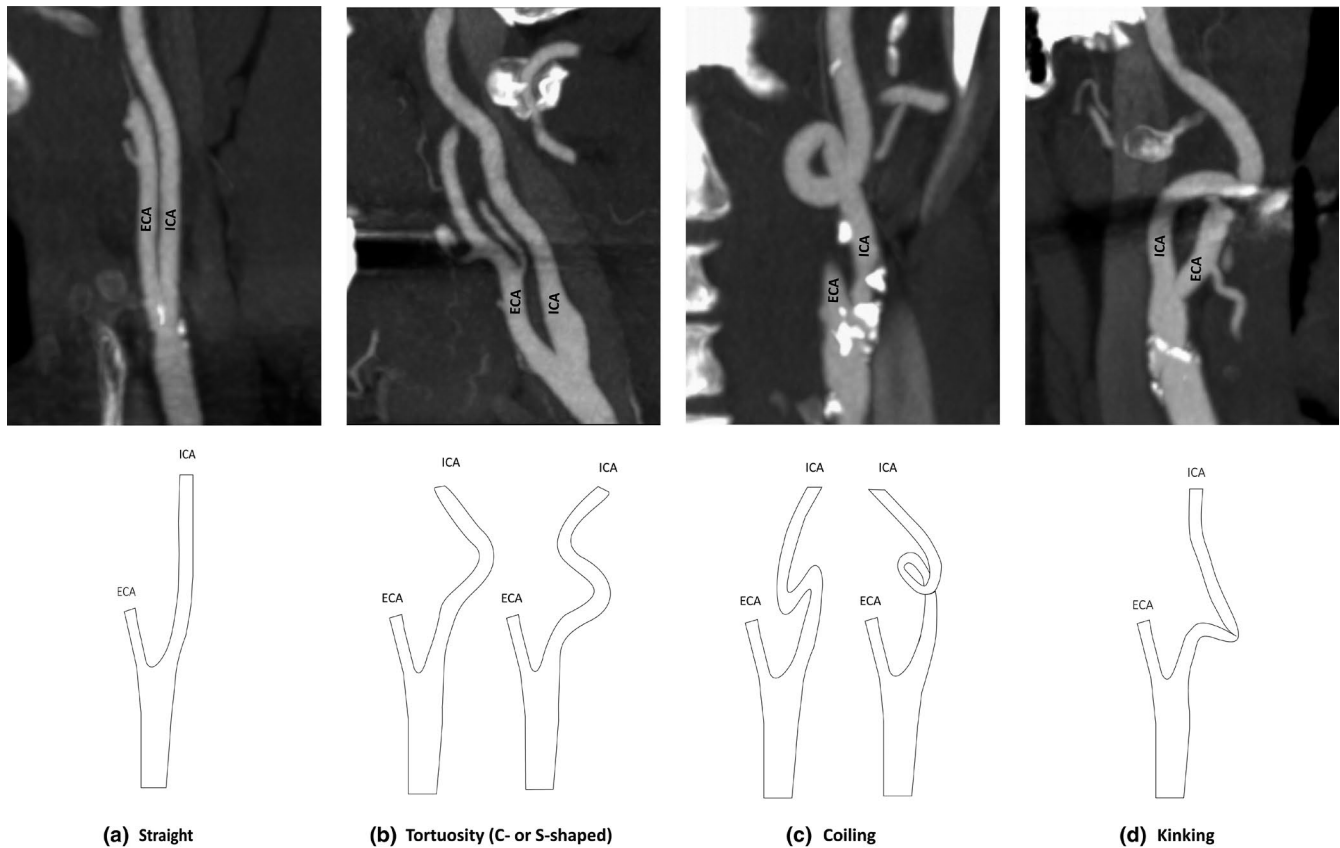
For the evaluation of dolichoarteriopathies, all MDCTA images were transferred to a workstation equipped with dedicated three-dimensional analysis software (Syngo.via; Siemens, Erlangen, Germany). For all 100 patients, we evaluated the course of both carotid arteries using the following strategy.

### Quantitative measurements of dolichoarteriopathies

First, we calculated the length of the ICA in mm by quantifying the length of the centerline from the carotid bifurcation to the point of entering the skull. Second, we calculated the shortest distance from the carotid bifurcation to the skull base (in a three-dimensional multiplane view) in millimeters to subsequently calculate the tortuosity index (TI) by dividing the real length of the ICA by the shortest distance from bifurcation to skull. Thus, a higher TI represents a more tortuous vessel.

### Qualitative assessment of dolichoarteriopathies

Two trained readers in carotid computed tomography (K.D./D.v.D.N.) performed the ICA morphological classification under the supervision of an expert in vascular imaging (D.B.) and neuroradiologist (A.v.d.L.) according to a classification system as described by Weibel and Fields [15] (Figure 1). All were blinded to the clinical data of the patients. We classified arteries as follows: tortuosity: S- or C-shaped course of the ICA; coiling: an exaggerated S-shaped curve or a circular configuration of the course of the ICA; kinking: angulation of one or more segments of the ICA associated with a visible impression of the lumen. The extracranial ICA was classified as straight if none of the abovementioned abnormalities were seen. In case of two or



**FIGURE 1** Multidetector computed tomography angiography examples (maximum intensity projection views) and schematic illustrations of different types of dolichoarteriopathy of the extracranial internal carotid artery. ECA, external carotid artery; ICA, internal carotid artery

more abnormalities in the same artery, we classified the artery according to the most severe abnormality (from mild to severe: tortuosity; coiling; kinking).

### Assessment of cardiovascular risk factors

We assessed the following cardiovascular risk factors: BMI, hypertension, hypercholesterolemia, diabetes mellitus, and smoking status (ever- versus never-smoker) [14,16].

### Statistical analysis

To compare the frequency of the type of dolichoarteriopathy between left and right, and between symptomatic and asymptomatic side, we used McNemar's tests. Potential differences in the length of the ICA between left and right, and between symptomatic and asymptomatic were investigated using paired *t*-tests. Given the skewed distribution of the TI, Wilcoxon signed rank tests were used to evaluate differences between left and right, and between symptomatic and asymptomatic carotid arteries.

Next, we assessed the association between cardiovascular risk factors and dolichoarteriopathies. In order to take into account the fact that one patient has two arteries, which are inherently subject

to the presence or absence of the same cardiovascular risk factors of that patient (in-patient correlation), we used a generalized estimation equation approach. Using linear (ICA length, TI) and ordinal logistic models (classification of dolichoarteriopathies [straight/tortuous/coiling/kinking]), we assessed the association of sex, age, obesity, hypertension, hypercholesterolemia, diabetes mellitus, and smoking with the outcomes. In Model 1, the risk factors were entered individually. In Model 2, all factors were entered simultaneously to investigate whether specific risk factors were linked to the outcomes independent of other risk factors. Given that both coiling and kinking are regarded as potential cerebrovascular event risk-increasing dolichoarteriopathies, we combined these into one category in our ordinal logistic models. Multiple imputation algorithms (with five imputations) were used to deal with missing values in the cardiovascular risk factors (missing: obesity  $n = 3$ ; hypertension  $n = 9$ ; hypercholesterolemia  $n = 4$ ; diabetes mellitus  $n = 13$ ). All analyses were performed using IBM SPSS Statistics version 21.

### RESULTS

The mean (standard deviation [SD]) age of the patients was 66 (8) years, and 76% were male. Obesity was present in 18% of the population, hypertension in 69%, hypercholesterolemia in 79%, diabetes mellitus in 23%, and 81% had ever smoked.

## Prevalence and distribution of dolichoarteriopathies in the ICA

From the 200 arteries in 100 patients, we had to exclude two arteries from the analyses because of the presence of a stent and an occlusion. We found a mean (SD) length of the ICA of 93 (14) mm with a median (interquartile range [IQR]) TI of 1.2 (1.1–1.3). Dolichoarteriopathies were present in 136 arteries (69%). The most common type of dolichoarteriopathy was tortuosity (98/136 = 72%), followed by coiling (27/136 = 20%), and kinking (11/136 = 8%). Tortuosity occurred bilaterally in 69% of the cases, coiling in 59%, but kinking only occurred unilaterally. We found no statistically significant differences between the length of the ICA, TI or presence of dolichoarteriopathies when comparing the ICA on the right and left side or when comparing the symptomatic and asymptomatic side (Tables 1 and 2).

## Cardiovascular risk factors and dolichoarteriopathies

Male sex was independently associated with a longer ICA: difference between male and female sex: 9.28 mm (95% confidence interval [CI] 4.62; 13.93). Older age and obesity were associated with a higher TI: difference per 10-year increase in age: 0.05 (95% CI 0.02–0.08), and 0.16 (95% CI 0.07–0.25) for obesity (Table 3). Obesity and hypercholesterolemia were independently associated with the severity of dolichoarteriopathy (odds ratio [OR] 2.07 [95% CI 1.04–4.12] and OR 2.17 [95% CI 1.02–4.63]; Table 4).

## DISCUSSION

We found that dolichoarteriopathies are very common in patients with recent cerebrovascular symptoms. The length and TI of the ICA, and the presence of dolichoarteriopathies were similar between the

**TABLE 1** Comparison of dolichoarteriopathies prevalence, extracranial internal carotid artery length and tortuosity index between the right and left extracranial internal carotid artery

	Right (n = 99)	Left (n = 99)	p value
Mean ± SD length ICA, mm	94 ± 15	93 ± 14	0.11
TI ICA median (IQR)	1.14 (1.07–1.28)	1.17 (1.09–1.29)	0.06
Straight, n (%)	34 (34)	28 (29)	0.29
Tortuous, n (%)	45 (45)	53 (53)	0.19
Coiling, n (%)	13 (13)	14 (14)	1.00
Kinking, n (%)	7 (7)	4 (4)	N.A. <sup>a</sup>

Abbreviations: ICA, internal carotid artery; IQR, interquartile range; n, number; SD, standard deviation; TI, tortuosity index.

<sup>a</sup>Due to the low numbers, no statistical comparison was made.

right and left carotid artery. Male sex, age, obesity and hypercholesterolemia were linked to dolichoarteriopathies.

The prevalence of dolichoarteriopathies of 69% that we found is in agreement with previous studies reporting a high prevalence of these abnormalities, especially in patients with cardiovascular risk factors [7,8,17]. When examining types of dolichoarteriopathies, we found that kinking occurred less frequently than tortuosity and coiling. An important remark with regard to this finding is that we defined kinking as a configuration with an impression of the lumen in the inner curvature of the kink. As this is only possible to assess on computed tomography angiography (CTA), and not on ultrasonography, which was used in most previous studies, we likely have recorded a lower, but more accurate prevalence of kinking than previous studies [18,19]. Additionally, the head position might influence carotid artery geometry; the supine position with the head tilted back during CTA ensures a similar position of all patients, whereas during ultrasonography the head position could vary [18,19].

Tortuosity is postulated to be a generally benign abnormality, whereas kinking and coiling are potentially harmful in light of cerebrovascular disease [1,18,20]. Carotid artery kinking and coiling are thought to alter the blood flow to the brain and may, in case of coexistence of atherosclerosis or disturbances in self-regulatory blood flow mechanisms, lead to cerebral ischemia [18,21–23]. Additionally, kinks and coilings might induce turbulences in the blood flow that can lead to thrombus formation with subsequent embolization [1,20,24]. However, in the present cross-sectional analysis we did not find differences in the prevalence of dolichoarteriopathies according to the symptomatic and asymptomatic arteries. Hence, future longitudinal studies are warranted to further investigate the link between dolichoarteriopathies and the risk of stroke.

In terms of risk factors for dolichoarteriopathies, we found that male sex was independently associated with the length of the ICA. However, this is likely completely driven by the fact that men are generally taller than women, which was further confirmed by the lack of a finding for TI. When investigating the other cardiovascular risk factors, we found that age, obesity and hypercholesterolemia

**TABLE 2** Comparison of dolichoarteriopathies prevalence, extracranial internal carotid artery length and tortuosity index between the symptomatic and asymptomatic extracranial internal carotid artery

	Symptomatic (n = 99)	Asymptomatic (n = 99)	p value
Mean ± SD ICA length, mm	95 ± 15	92 ± 13	0.07
TI ICA median (IQR)	1.15 (1.07–1.30)	1.16 (1.09–1.28)	0.06
Straight, n (%)	32 (32)	30 (30)	0.83
Tortuous, n (%)	50 (50)	48 (48)	1.00
Coiling, n (%)	11 (11)	16 (16)	0.23
Kinking, n (%)	7 (7)	4 (4)	N.A. <sup>a</sup>

Abbreviations: ICA, internal carotid artery; IQR, interquartile range; n, number; SD, standard deviation; TI, tortuosity index.

<sup>a</sup>Due to the low numbers, no statistical comparison was made.

**TABLE 3** Associations of cardiovascular risk factors with length and tortuosity index of the extracranial internal carotid artery

	ICA length (mm)		TI	
	Regression coefficient [95% CI]		Regression coefficient [95% CI]	
	Model 1	Model 2	Model 1	Model 2
Sex (male)	8.85 [4.61;13.09]	9.28 [4.62;13.93]	-0.02 [-0.09;0.06]	-0.02 [-0.09;0.04]
Age (10 years increase)	2.48 [0.58;4.38]	1.00 [-0.90;2.89]	0.04 [0.01;0.07]	0.05 [0.02;0.08]
Obesity	3.04 [-2.84;8.92]	4.03 [-2.21;10.26]	3.04 [-2.84;8.92]	0.16 [0.07;0.25]
Hypertension	2.57 [-1.88;7.02]	1.50 [-3.01;6.01]	0.04[-0.01;0.10]	0.01 [-0.05;0.07]
Hypercholesterolemia	1.62 [-4.44;7.68]	4.15 [-0.69;9.00]	0.05 [-0.01;0.11]	-0.01 [-0.06;0.06]
Diabetes mellitus	-0.69 [-5.21;3.84]	-1.47 [-5.75;2.81]	0.06 [-0.01;0.13]	0.05 [-0.01;0.12]
Ever smoker	-1.20 [-6.05;3.66]	-1.04 [-5.79;3.71]	0.03 [-0.03;0.09]	0.05 [-0.01;0.11]

Note: Model 1: Univariable model.

Model 2: Multivariable model with all variables entered simultaneously.

Abbreviations: CI, confidence interval; ICA, internal carotid artery; TI, tortuosity index.

**TABLE 4** Associations of cardiovascular risk factors with classification of dolichoarteriopathies.

	Classification: straight vs. tortuous vs. coiling and kinking	
	Odds ratio [95% CI]	
	Model 1	Model 2
Sex (male)	0.95 [0.51;1.75]	0.96 [0.53;1.73]
Age (10-year increase)	10.33 [10.01;10.67]	10.30 [9.96;10.65]
Obesity	2.37 [1.20;4.69]	2.07 [1.04;4.12]
Hypertension	1.48 [0.82;2.67]	1.29 [0.70;2.40]
Hypercholesterolemia	2.67 [1.29;5.56]	2.17 [1.02;4.63]
Diabetes mellitus	1.19 [0.64;2.19]	1.13 [0.60;2.12]
Ever smoker	0.86 [0.45;1.63]	1.06 [0.56;1.99]

Note: Model 1: Univariable model.

Model 2: Multivariable model with all variables entered simultaneously.

Abbreviation: CI, confidence interval.

were most prominently associated with higher TI and more severe types of dolichoarteriopathies. For obesity, it has been proposed that larger amounts of abdominal visceral fat increase the intra-abdominal static pressure which may result in an upward shift of the diaphragm and a rise of the mediastinum. Consequently, the distance from the aortic arch to the skull base may change and result in carotid dolichoarteriopathy [1,7]. Future studies should be focused on further elucidating this potential explanation. The observed association between old age and TI supports the theory that dolichoarteriopathies partly develop as a result of ageing, due to a substantial loss of arterial elasticity [25]. Overall, the development of dolichoarteriopathies seems to be the result of a complex interaction of multiple factors, which merits further investigation.

Strengths of the present study were the use of MDCTA and of quantitative measures to evaluate dolichoarteriopathies. The study

also has some limitations. First, the results can only be generalized to persons with recent cerebrovascular symptoms; data on the prevalence of dolichoarteriopathies in the general population and according to different age categories would be of great value, in particular, as these may represent an important but underestimated risk factor for stroke. Second, given the cross-sectional analyses, we were unable to investigate the link between dolichoarteriopathies and symptomatology.

In conclusion, dolichoarteriopathies in the extracranial ICA are common findings in patients with recent cerebrovascular symptoms. Age, obesity and hypercholesterolemia may play an important role in the pathophysiology of dolichoarteriopathies at this location.

#### ACKNOWLEDGMENTS

The authors thank Marcel Dijkshoorn for his technical support with Syngo.via software.

#### CONFLICT OF INTEREST

None.

#### AUTHOR CONTRIBUTIONS


**Kristina Dilba:** Data curation (lead); Formal analysis (lead); Methodology (equal); Writing – original draft (lead). **Dianne H.K. van Dam-Nolen:** Data curation (equal); Formal analysis (equal); Methodology (equal); Visualization (equal); Writing – original draft (equal); Writing – review and editing (equal). **Geneviève A.J.C. Crombag:** Writing – review and editing (supporting). **Anja G. van der Kolk:** Writing – review and editing (supporting). **Peter J. Koudstaal:** Funding acquisition (equal); Resources (equal); Supervision (equal); Writing – review and editing (equal). **Paul J. Nederkoorn:** Funding acquisition (equal); Resources (equal); Writing – review and editing (equal). **Jeroen Hendrikse:** Funding acquisition (equal); Resources (equal); Writing – review and editing (equal). **Marianne Eline Kooi:** Funding acquisition (equal); Resources (equal); Supervision (equal);

Writing – review and editing (equal). **Antonius F.W. van der Steen:** Funding acquisition (equal); Resources (equal); Writing – review and editing (equal). **Jolanda J. Wentzel:** Conceptualization (supporting); Methodology (equal); Resources (equal); Writing – review and editing (equal). **Aad van der Lugt:** Conceptualization (equal); Funding acquisition (equal); Resources (equal); Supervision (supporting); Writing – review and editing (equal). **Daniel Bos:** Conceptualization (lead); Data curation (supporting); Formal analysis (supporting); Funding acquisition (supporting); Methodology (equal); Supervision (lead); Writing – review and editing (lead).

#### DATA AVAILABILITY STATEMENT

The data used in this research were collected subject to the informed consent of the participants. Access to the data will only be granted in line with that consent, subject to approval by the project ethics board and under a formal Data Sharing Agreement.

#### ORCID

Dianne H. K. van Dam-Nolen  <https://orcid.org/0000-0002-4527-3876>

Geneviève A. J. C. Crombag  <https://orcid.org/0000-0002-6233-3391>

Anja G. van der Kolk  <https://orcid.org/0000-0002-8267-8848>

Peter J. Koudstaal  <https://orcid.org/0000-0003-4998-9609>

Marianne Eline Kooi  <https://orcid.org/0000-0001-7562-5724>

Antonius F. W. van der Steen  <https://orcid.org/0000-0002-8045-7363>

Jolanda J. Wentzel  <https://orcid.org/0000-0001-9893-3404>

Aad van der Lugt  <https://orcid.org/0000-0002-6159-2228>

Daniel Bos  <https://orcid.org/0000-0001-8979-2603>

#### REFERENCES

- Leipzig TJ, Dohrmann GJ. The tortuous or kinked carotid artery: pathogenesis and clinical considerations. A historical review. *Surg Neurol.* 1986;25:478-486.
- Koskas F, Bahnini A, Walden R, Kieffer E. Stenotic coiling and kinking of the internal carotid artery. *Ann Vasc Surg.* 1993;7:530-540.
- Ballotta E, Abbruzzese E, Thiene G, et al. The elongation of the internal carotid artery: early and long-term results of patients having surgery compared with unoperated controls. *Ann Vasc Surg.* 1997;11:120-128.
- Martins HFG, Mayer A, Batista P, et al. Morphological changes of the internal carotid artery: prevalence and characteristics. A clinical and ultrasonographic study in a series of 19 804 patients over 25 years old. *Eur J Neurol.* 2018;25:171-177.
- Pancera P, Ribul M, Presciuttini B, Lechi A. Prevalence of carotid artery kinking in 590 consecutive subjects evaluated by Echocolor Doppler. Is there a correlation with arterial hypertension? *J Intern Med.* 2000;248:7-12.
- Yu J, Qu L, Xu B, et al. Current understanding of dolichoarteriopathies of the internal carotid artery: a review. *Int J Med Sci.* 2017;14:772-784.
- Wang HF, Wang DM, Wang JJ, et al. Extracranial internal carotid artery tortuosity and body mass index. *Front Neurol.* 2017;8:508.
- Del Corso L, Moruzzo D, Conte B, et al. Tortuosity, kinking, and coiling of the carotid artery: expression of atherosclerosis or aging? *Angiology.* 1998;49:361-371.
- Ghilardi G, Longhi F, De Monti M, Bortolani E. [Carotid kinking and arterial hypertension. Preliminary results of the OPI program] Kinking carotideo ed ipertensione arteriosa. Risultati preliminari del programma OPI. *Minerva Cardioangiol.* 1993;41:287-291.
- Prencipe G, Pellegrino L, Vairo F, Tomaiuolo M, Furio OA. [Dolichoarteriopathy (kinking, coiling, tortuosity) of the carotid arteries and cardiovascular risk factors] Dolicoarteriopatie (kinking, coiling, tortuosita) delle arterie carotidi e fattori di rischio cardiovascolare. *Minerva Cardioangiol.* 1998;46:1-7.
- Pellegrino L, Prencipe G. [Dolichoarteriopathies (kinking, coiling, tortuosity) of carotid arteries and atherosclerotic disease: an ultrasonographic study] Dolicoarteriopatie (kinking, coiling, tortuosita) delle arterie carotidi e malattia aterosclerotica: studio ultrasonografico. *Cardiologia.* 1998;43:959-966.
- Togay-Isikay C, Kim J, Betterman K, et al. Carotid artery tortuosity, kinking, coiling: stroke risk factor, marker, or curiosity? *Acta Neurol Belg.* 2005;105:68-72.
- Beigelman R, Izaguirre AM, Robles M, Grana DR, Ambrosio G, Milei J. Are kinking and coiling of carotid artery congenital or acquired? *Angiology.* 2010;61:107-112.
- Truijman MTB, Kooi ME, van Dijk AC, et al. Plaque At RISK (PARISK): prospective multicenter study to improve diagnosis of high-risk carotid plaques. *Int J Stroke.* 2014;9:747-754.
- Weibel J, Fields WS. Tortuosity, coiling, and kinking of the internal carotid artery: II. Relationship of morphological variation to cerebrovascular insufficiency. *Neurology.* 1965;15:462-468.
- van Dijk AC, Truijman MTB, Hussain B, et al. Intraplaque hemorrhage and the plaque surface in carotid atherosclerosis: the Plaque At RISK Study (PARISK). *AJNR Am J Neuroradiol.* 2015;36:2127-2133.
- Sacco S, Totaro R, Baldassarre M, Carolei A. Morphological variations of the internal carotid artery: prevalence, characteristics and association with cerebrovascular disease. *Int J Angiol.* 2007;16:59-61.
- Saba L, Mallarini G. Correlation between kinking and coiling of the carotid arteries as assessed using MDCTA with symptoms and degree of stenosis. *Clin Radiol.* 2010;65:729-734.
- Quattlebaum JK Jr, Wade JS, Whiddon CM. Stroke associated with elongation and kinking of the carotid artery: long-term follow-up. *Ann Surg.* 1973;177:572-579.
- Milic DJ, Jovanovic MM, Zivic SS, Jankovic RJ. Coiling of the left common carotid artery as a cause of transient ischemic attacks. *J Vasc Surg.* 2007;45:411-413.
- Kaplan ML, Bontsevich DN. Effect of the form of pathological tortuosity of the internal carotid artery on cerebral haemodynamics. *Angiol Sosud Khir.* 2013;19:102-106.
- Derrick JR, Estess M, Williams D. Circulatory dynamics in kinking of the carotid artery. *Surgery.* 1965;58:381-383.
- Wang L, Zhao F, Wang D, et al. Pressure drop in tortuosity/kinking of the internal carotid artery: simulation and clinical investigation. *Biomed Res Int.* 2016;2016:2428970.
- Mukherjee D, Inahara T. Management of the tortuous internal carotid artery. *Am J Surg.* 1985;149:651-655.
- Kamenskiy AV, Pipinos II, Dzenis YA, et al. Effects of age on the physiological and mechanical characteristics of human femoropopliteal arteries. *Acta Biomater.* 2015;11:304-313.

**How to cite this article:** Dilba K, van Dam-Nolen DHK, Crombag GAJC, et al. Dolichoarteriopathies of the extracranial internal carotid artery: The Plaque At RISK study. *Eur J Neurol.* 2021;28:3133–3138. <https://doi.org/10.1111/ene.14982>



# Rare Disease Connect in Neurology

**10–12 November 2021**

Three half-days of virtual collaboration

04:00–08:00 PST (Los Angeles) | 07:00–11:00 EST (New York)  
12:00–16:00 GMT (London) | 13:00–17:00 CET (Paris)  
19:00–23:00 JST (Tokyo)

Join us for **Rare Disease Connect in Neurology 2021**, the inaugural meeting of a long-term learning journey, connecting neuromuscular experts committed to delivering excellence for patients living with myasthenia gravis (MG).

Imagine what we could do for patients, together.

## Why take part in Rare Disease Connect in Neurology 2021?

With a world-class programme spanning three half-days, developed in collaboration with a steering committee of renowned MG experts, **Rare Disease Connect in Neurology 2021** will feature:



Live and  
on-demand  
content



Group  
discussions



Networking  
opportunities  
with your  
global peers

To join us virtually on 10–12 November 2021

Register your interest now



Inspired by patients.  
Driven by science.

This educational meeting has been organised and sponsored by UCB Biopharma SRL, and is intended for practicing healthcare professionals interested in the area of myasthenia gravis and managing patients in this space. Terms and conditions apply.

© UCB Biopharma SRL 2021. All rights reserved. GL-N-DA-MG-2100042  
Date of preparation: October 2021