

Children with multiple endocrine neoplasia type 2B: Not tall and marfanoid, but short with normal body proportions

Medard F. M. van den Broek¹  | Hanneke M. van Santen^{2,3} | Gerlof D. Valk¹ | Annemarie A. Verrijn Stuart²

¹Department of Endocrine Oncology, University Medical Center Utrecht, Utrecht, The Netherlands

²Department of Pediatric Endocrinology, Wilhelmina Children's Hospital, University Medical Center Utrecht, Utrecht, The Netherlands

³Princess Maxima Center for Pediatric Oncology, Utrecht, The Netherlands

Correspondence

Annemarie A. Verrijn Stuart, Department of Pediatric Endocrinology, Wilhelmina Children's Hospital, University Medical Center Utrecht, Huispostnummer KE 04.133.1, Postbus 85090, 3508 AB Utrecht, The Netherlands.
Email: a.a.verrijnstuart@umcutrecht.nl

Abstract

Objective: Multiple endocrine neoplasia 2B (MEN2B) is characterised by early-onset medullary thyroid carcinoma (MTC), pheochromocytoma and several non-endocrine manifestations. Unfortunately, MEN2B is often diagnosed late, after the development of clinically significant MTC. Marfanoid habitus is considered an important related feature, which may lead to the assumption that patients with MEN2B have tall stature. Here, we describe the longitudinal growth and body proportions of eight MEN2B patients during childhood.

Design: It is a retrospective case series.

Methods: Patients were under the care of a Dutch MEN expertise centre. Growth patterns were assessed and interpreted in relation to body mass index (BMI), age at diagnosis and at thyroidectomy, extensiveness of disease manifestations and parental height.

Results: Seven patients were short during childhood, of whom four showed growth below target height range (THR) and three at the lowest margin of THR. Only one patient grew well within THR. All patients who attained final height ($n = 4$) ended within THR, despite short stature during childhood. Arm span/height ratio was not increased and upper segment/lower segment ratio was not reduced in any patient. Short stature in childhood in this study did not seem to be associated with age at diagnosis, age at thyroidectomy, extensiveness of MTC, endocrine deficiencies or BMI.

Conclusions: This study shows that children with MEN2B may well present with short rather than tall stature. Thereafter, final height within THR was attained in those who already reached adulthood, but none had tall stature. Finally, body proportions were normal in all children and adults in this case series, not underlining a 'marfanoid' body habitus.

KEYWORDS

final height, growth, marfanoid body habitus, multiple endocrine neoplasia type 2B, short stature

This is an open access article under the terms of the Creative Commons Attribution NonCommercial License, which permits use, distribution and reproduction in any medium, provided the original work is properly cited and is not used for commercial purposes.

© 2021 The Authors. *Clinical Endocrinology* published by John Wiley & Sons Ltd.

1 | INTRODUCTION

Multiple endocrine neoplasia type 2B (MEN2B) is an autosomal dominant inherited cancer syndrome. In the majority of patients, it is caused by a de novo germline mutation in the *REarranged Translocation* proto-oncogene (*RET* gene) (c.2753T>C (p.Met918Thr)).^{1–3} It is an extremely rare entity (estimated prevalence 0.9–1.7 per million) characterized by the combination of very early-onset medullary thyroid carcinoma (MTC) in nearly all patients, a 50% lifetime risk of pheochromocytoma as well as several nonendocrine manifestations.^{4–7} Some of the latter can occur during the first years of life, thereby creating a window of opportunity for timely recognition and diagnosis of MEN2B, before the development of MTC.^{8,9} More specifically, reported signs that should call for alert are intestinal ganglioneuromatosis, mucosal neuromas/neurofibromas, alacrima and a 'marfanoid' body habitus.^{8–10}

The frequently reported but rarely specified MEN2B-related 'marfanoid' habitus refers to signs that resemble the characteristics of patients with the Marfan syndrome, such as tall stature, long limbs and hyperlaxity.¹¹ In the largest MEN2B cohort to date ($n = 345$), a 'marfanoid' habitus was reported in 73% of patients.⁷ Somewhat paradoxically, a recent German study suggested that short stature might be associated with the MEN2B syndrome.⁹ However, data on parental height was missing and data on follow-up of patients were limited.

In this report, we aimed to describe growth patterns, body proportions and final height (FH) in children and adolescents with MEN2B syndrome in a Dutch MEN expertise centre. Furthermore, we intended to relate growth patterns to age at MEN2B diagnosis and thyroidectomy, the extensiveness of MTC as well as other possible growth influencing parameters, such as body mass index (BMI), gastrointestinal manifestations and endocrine status.

2 | MATERIALS AND METHODS

A retrospective medical record review was performed of all patients diagnosed with MEN2B syndrome during the period 1976–2020 under care at the Wilhelmina Children's Hospital/University Medical Center Utrecht (UMCU), a tertiary referral and European Reference Network expertise centre for MEN patients in the Netherlands. The primary outcomes of interest were patients' growth pattern, body proportions and FH—reported as age- and sex-related standard deviation (SD) scores (SDS)¹²—in relation to target height (TH). Secondary, we described the association between growth and possible influencing factors. The upper segment (US)/lower segment (LS) ratio and arm span/height ratio were used to quantify anthropometric signs which have been associated with 'marfanoid' habitus.¹³ Written informed consent for publication was obtained from parents (for patients aged less than 12 years), patients (aged ≥ 16 years) or both (patients aged 12–16 years). The study was approved by the institutional review board of the UMCU. Detailed methods are presented in the [Supporting Information Material](#).

3 | RESULTS

3.1 | Patients; growth patterns and body proportions

A total of eight MEN2B patients were identified; the diagnosis of MEN2B had been confirmed by a de novo c.2753T>C (p.Met918Thr) *RET* mutation in all cases. Patient characteristics are shown in Table 1. Three patients showed growth below their target height range (THR) (Figure 1, Patients 2–4). Three more patients (Figure 1, Patients 1, 5 and 7) showed prepubertal growth in the lowest margin of their THR. In addition, Patient 8 had been under follow-up for (unexplained) short stature from age 4–14 for which he had been treated with testosterone preparations. Only Patient 6 grew well within his THR.

During their last outpatient clinic visit, two children (Patients 3 and 4) were prepubertal, whereas two others (Patients 1 and 2) showed the first signs of puberty (see Table 2). Bone age was determined in six patients: all showed delayed bone maturation (calendar age minus bone age: range 0.9–4.7 years) (Figure 1, Patients 1–5 and 8). Data on parental pubertal development were available in four cases: menarche was reported at a normal age for Dutch females by three mothers, whereas a fourth reported delayed menarche. None of the fathers reported an early or delayed puberty. No data were available on the longitudinal growth patterns of the parents.

Four MEN2B patients reached FH (Patients 5–8), all within THR, whereas all had short stature during childhood (see Table 2).

Body proportions (US/LS ratio and arm span/height ratio) were within the normal range in all cases studied ($n = 7$). Nevertheless, four patients (Patients 5–8) had been labelled 'marfanoid' by the treating physician at some point during follow-up. In addition, hyperlaxity was reported in six patients (75%) (Table 2).

3.2 | Possible determinants of growth

Impaired (prepubertal) growth was seen in patients diagnosed during late childhood and adolescence as well as in patients who had been diagnosed and successfully treated by thyroidectomy early in life. Details on MTC status as well as thyroid disease after surgery are reported in Table 1.

As illustrated in Figure 1, neither growth during childhood nor FH appeared to be influenced by age at MEN2B diagnosis, age at thyroidectomy or extensiveness of MTC. Late MEN2B diagnosis with progressive loco-regional or metastasised MTC did not seem to be associated with reduced FH (Patients 5 and 6). It is worth noting that we could not relate calcitonin levels to biochemical parameters of bone mineralisation (calcium, phosphate and/or PTH levels) (data not shown).

Thyroid replacement therapy after thyroidectomy, initiated to maintain TSH and FT4 levels within age-specific reference range levels, had been adequate in all patients. Insulin-like growth factor-1

TABLE 1 Patient characteristics

Patient	Sex	Age at Dx (year)	Age at thyroidectomy (year)	Follow-up time (year)	Thyroid disease at Dx ^a	Thyroid disease at last FU ^d
1	F	0.1	0.6	13.3	CCH	Cured
2	F	6.5	6.5	4.0	MTC, T3N1bMx (IVa)	Persistent
3	F	0.3	0.6	8.4	CCH	Cured
4	M	0.1	0.5	7.3	MTC, T1aNxMx (I)	Cured
5	F	15.8	15.9	7.0	MTC, T4aN1bM1 (IVc)	Progressive
6	M	11.7	11.7	14.6	MTC, T1aNxMx (I)	Progressive
7	F	6.0	6.1	30.3	CCH ^b	Recurrence
8	M	16.0	16.0	38.0 ^c	MTC, T1aNxMx (I)	Persistent

Abbreviations: CCH, C-cell hyperplasia; Dx, diagnosis; F, female; FU, follow-up; M, male; MTC, medullary thyroid carcinoma; ND, not determined; SD, standard deviation.

^aHistological diagnosis and tumour node metastasis—classification, based upon the *American Joint Committee on Cancer (AJCC) Cancer Staging Manual*, eighth edition.¹⁴

^bPossible MTC.

^cPatient died at age 54.0 years due to a metastasised pancreatic adenocarcinoma.

^dThyroid disease has been defined as 'cured' if calcitonin levels remained undetectable after the surgery. Thyroid disease was labelled as 'recurrence' if calcitonin levels were initially undetectable after surgery, but became detectable afterwards. Thyroid disease was defined as 'persistent' if calcitonin levels were elevated before surgery and remained elevated afterwards. Thyroid disease was labelled as 'progressive' in case of increasing calcitonin concentrations and/or evidence of metastatic disease on imaging.

(IGF-1) level was less than 2 SD below the age- and sex-related mean in three patients (Patients 2–4). Growth hormone (GH) stimulation testing in Patients 3 and 4 ruled out GH deficiency as well as GH resistance (data shown in the [Supporting Information Material](#)). In Patient 2, GH testing had not been performed as GH therapy was not considered advisable with the simultaneous presence of persistent MTC.

In five patients, BMI SDS was within the reference range (± 2) during their entire childhood (Figure 1, Patients 1 and 3–6). A decline in BMI in the three other patients (Patients 2, 7 and 8) did not co-occur with a decrease in height growth velocity (Figure 1). Patient 3 underwent a partial small bowel removal after a neonatal volvulus and thereafter, at age three, a rectosigmoid resection. She suffered from ongoing mild malabsorption (iron- and fat-soluble vitamin deficiencies) thereafter, and the rectosigmoid resection coincided with a temporary reduced growth velocity (Figure 1).

4 | DISCUSSION

In contrast to the expected 'marfanoid' tall stature, 50% of the patients with MEN2B described in our report had been diagnosed with short stature. Another three patients (38%) showed growth around the lower limit of their THR—at least until puberty. Until now, growth restriction and short stature during childhood have not been fully acknowledged as associated features of MEN2B. Results from this detailed case series confirm a previous report; short stature in childhood may be considered as an associated feature of MEN2B. This is an important finding because it illustrates that short stature

during childhood does not decrease the chance of a diagnosis of MEN2B when other MEN2B symptoms are present.

Interestingly, none of the four patients who thus far have reached adulthood remained short. Thus, short stature in childhood in MEN2B patients is not necessarily associated with FH below predicted TH.

As the results on growth patterns were contradictory of what is generally assumed, factors that could have influenced growth were investigated. Although the small number of patients prevented us to draw firm conclusions about the effect of several clinical aspects on growth patterns, some important observations could be made: first, in our patients, age at MEN2B diagnosis or age at thyroidectomy did not seem to influence growth velocity. Second, there appeared to be no relationship between MTC status and either patients' growth or FH (both related to TH).

With regard to endocrine status: although levels of IGF-1 were low in three patients with growth restriction, GH stimulation testing ruled out GH deficiency in two cases. Delayed bone maturation may partly explain the low IGF-1 concentrations, as IGF-1 levels should be interpreted considering both bone and calendar age in children. Furthermore, as the GH-IGF-1 axis is influenced by malnutrition, low levels of IGF-1 might be partially explained by the low BMI in Patient 2 and malabsorption in Patient 3.^{15,16} Growth charts did not show a clear co-occurrence of reduced BMI and impaired growth, while intestinal surgery was accompanied by a temporary reduced height velocity in one patient.

Whether the abovementioned factors—and gastrointestinal manifestations in particular—may have impacted growth velocity in these case series cannot be clearly determined. Malabsorption

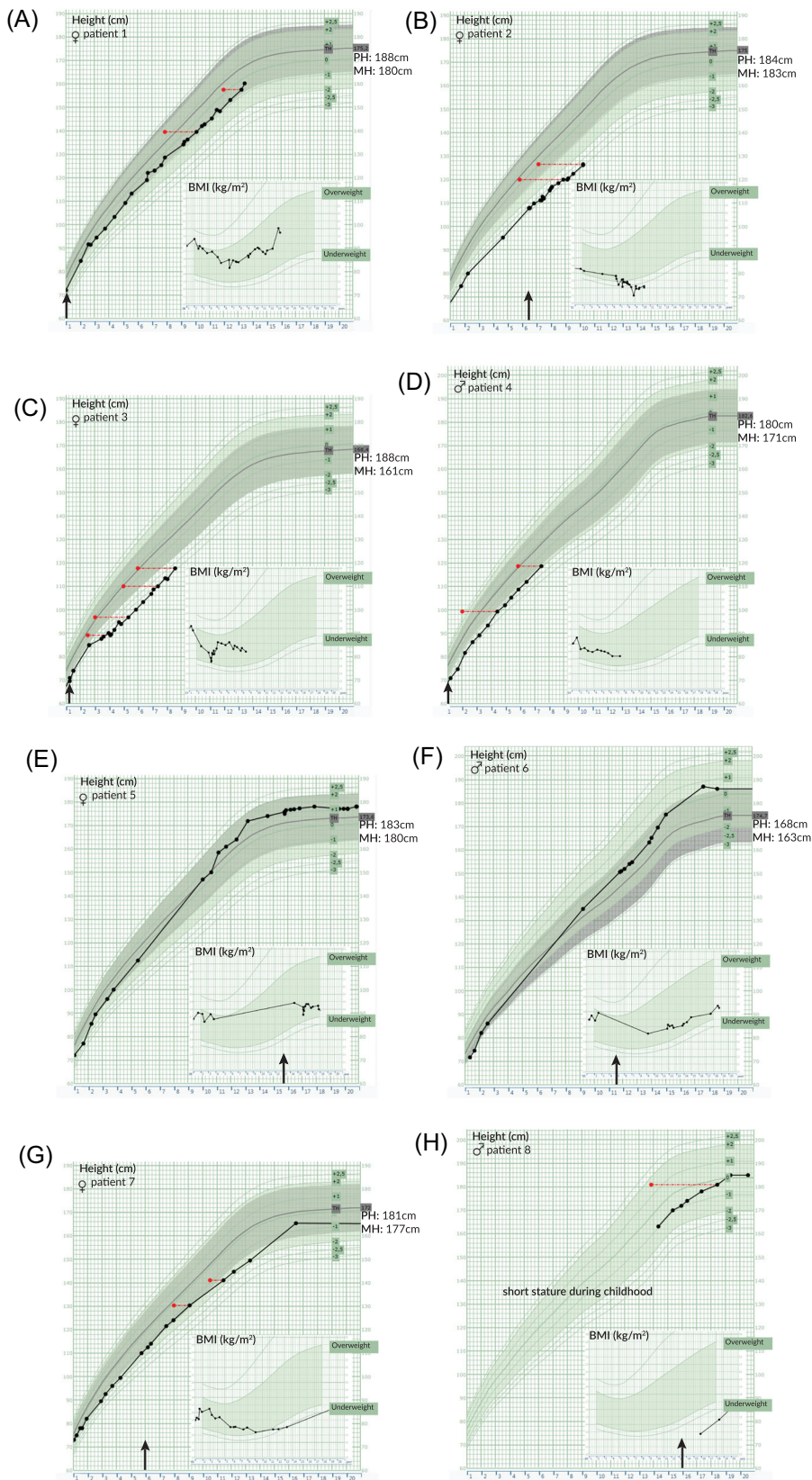


FIGURE 1 Growth charts. Height (cm) for age (years) charts and BMI (kg/m²) for sex and age (years) charts of all included patients. Age at MEN2B diagnosis is indicated by an arrow just above the X-axis. Target height and parental height are reported (in cm) along the right Y-axis (parental data missing for Patient 8). Green colour background (online version) indicates age- and sex-specific Dutch population mean \pm 2 standard deviations for height and BMI.¹² Grey colour background (online version) marks the target height range (data missing for Patient 8). Bone age is marked by a red dot (online version). BMI, body mass index; MEN2B, multiple endocrine neoplasia type 2; MH, maternal height; PH, paternal height

TABLE 2 Anthropometric data and musculoskeletal features related to 'marfanoid' habitus

Patient (age at last FU)	Target height ^a	Height at last FU ^b	BMI at last FU ^c	Pubertal development ^d	US/LS ratio ^e	Arm span ratio ^f	Musculoskeletal features ^g	Labelled as 'marfanoid' by physician ^g
1 (13.3 year)	175 cm +0.71 SD	-0.61 SD	+0.74 SD	Tanner stage at last FU: P2 M2	0.98	0.96	Hyperlaxity Scoliosis Pes cavus	-
2 (10.5 year)	175 cm +0.68 SD	-2.86 SD	-3.49 SD	Tanner stage at last FU: P1 M2	1.05	0.96	Hyperlaxity Hip dysplasia Muscle weakness Hypotonia	-
3 (8.7 year)	168 cm -0.38 SD	-2.87 SD	-0.52 SD	Tanner stage at last FU: P1 M1	1.13	0.96	-	-
4 (7.5 year)	183 cm -0.17 SD	-1.87 SD	-0.82 SD	Tanner stage at last FU: P1 G1	1.19	0.96	Hypotonia	-
5 (22.8 year)	174 cm +0.45 SD	178 cm ^h +1.16 SD	-1.91 SD	Normal (age at menarche: 13 year)	1.13	0.94	Hyperlaxity	+
6 (26.3 year)	175 cm -1.29 SD	186 cm ^h +0.39 SD	-0.87 SD	Normal	0.96	0.99	Hyperlaxity Muscle weakness Hypotonia DMD	+
7 (36.3 year)	172 cm +0.2 SD	165 cm ^h -0.52SD	+0.15 SD	Somewhat delayed (age at menarche: 15 year)	1.14	1.00	Hyperlaxity DMD	+
8 (54.0 year)	ND	186 cm ^h +0.17 SD	-2.35 SD	Delayed ⁱ	ND	ND	Hyperlaxity Scoliosis Pectus carinatum Pes cavus Muscle weakness Hypotonia	+

Abbreviations: +, yes; -, no; DMD, delayed motor development; FU, follow-up; LS, lower segment; ND, not determined; SD, age-related sex-specific standard deviation; US, upper segment.

^aIn cm and in standard deviations above or below the sex-specific population mean.

^bStandard deviations above or below the age-related sex-specific population mean. Absolute height in cm is also reported for patients who have reached their final height.

^cStandard deviations above or below the age-related sex-specific population mean.

^dPubertal development is described by Tanner stadium at last follow-up in the case of paediatric patients. In adult patients, the pubertal development was classified as 'normal', 'somewhat delayed' or 'delayed', and in female patients, age at menarche has also been reported.

^eUpper segment/lower segment ratio. A reduced ratio, defined as <1 for age 0–5 years, <0.95 for age 6–7, <0.9 for age 8–9 and <0.85 for age ≥10, is associated with Marfan syndrome.¹³

^fArm span-to-height ratio. An increased arm span-to-height ratio, defined as >1.05, is associated with Marfan syndrome.

^gBased on medical record notes by treating physicians.

^hFinal height.

ⁱAccording to medical correspondence, Patient 8 had been treated with testosterone preparations due to (unexplained) short stature at pubertal age. Remarkably, at age 20, his height was 186 cm with a 4.7-year delay in bone maturation. Further details on his pubertal development could not be retrieved.

has not been assessed at regular intervals, and investigations were based on the clinical judgement of the treating physicians.

Given the delayed bone development, we considered the possibility of familial constitutional delay in growth and puberty; however, the available data overall do not suggest a familial constitutional delay in growth and puberty to play a significant role in the aetiology of short stature in childhood in this series.

Literature on growth patterns in MEN2B is limited to a few case reports and cohort studies.^{9,17–22} In the report of Redlich et al.⁹ on physical stigmata in patients with MEN2B, short stature was reported in 12 out of 24 (50%) patients. Although data on parental height was missing and a limited number of measurements per patient were available, these findings also suggested an association between growth restriction and MEN2B.⁹ Results described in our

case series clearly show that short stature and growth beneath THR are prevalent in MEN2B children. However, as the number of patients included in our case series is small, we cannot rule out that tall stature may occur in children with MEN2B as well.

Patients with MEN2B are often mentioned to have a 'marfanoid' body habitus, though this is a nonspecific term without standardised criteria. On the contrary, criteria for diagnosing Marfan syndrome have been meticulously defined and include a reduced US/LS ratio and increased arm span/height ratio.¹³ To the best of our knowledge, no studies have been published actually describing body proportions in MEN2B children. Somewhat surprisingly, none of the hereby reported MEN2B patients showed abnormal body proportions, whereas 50% of the patients had been labelled 'marfanoid' by their treating physician. Given the lack of standardised criteria for 'marfanoid' habitus, it is difficult to compare our findings with other reports.⁷ We, as well as previous authors, did not use specific scoring systems for hyperlaxity, which makes it more challenging to define this symptom in patients with MEN2B. Future studies may address musculoskeletal features including hyperlaxity and bone health to understand how they develop in patients with MEN2B.

To conclude, this case series shows that short stature and height below THR are frequently present in prepubertal children with MEN2B. Next, normal body proportions as measured by arm span/height and US/LS ratios do not support a marfanoid body habitus during childhood in this cohort. These findings suggest that short stature should by no means rule out a possible diagnosis of MEN2B when this diagnosis is suspected due to the presence of other MEN2B-related symptoms. Short stature during childhood may even be considered one of the independent characteristics of the MEN2B syndrome. Furthermore, normal adult height within THR—but not tall stature—may be reached despite the reported short stature during childhood. Larger prospective cohort studies are needed to validate these findings on growth and body proportions.

CONFLICT OF INTERESTS

The authors declare that there are no conflict of interests.

DATA AVAILABILITY STATEMENT

The data that support the findings of this study are available from the corresponding author upon reasonable request. The data are not publicly available due to privacy or ethical restrictions.

ORCID

Medard F. M. van den Broek  <https://orcid.org/0000-0002-4656-2960>

REFERENCES

- Carlson KM, Dou S, Chi D, et al. Single missense mutation in the tyrosine kinase catalytic domain of the RET protooncogene is associated with multiple endocrine neoplasia type 2B. *Proc Natl Acad Sci U S A*. 1994;91(4):1579-1583. <https://doi.org/10.1073/pnas.91.4.1579>
- Hofstra RM, Landsvater RM, Ceccherini I, et al. A mutation in the RET proto-oncogene associated with multiple endocrine neoplasia type 2B and sporadic medullary thyroid carcinoma. *Nature*. 1994;367(6461):375-376.
- Eng C, Smith DP, Mulligan LM, et al. Point mutation within the tyrosine kinase domain of the RET proto-oncogene in multiple endocrine neoplasia type 2B and related sporadic tumours. *Hum Mol Genet*. 1994;3(2):237-241.
- Morrison PJ, Nevin NC. Multiple endocrine neoplasia type 2B (mucosal neuroma syndrome, Wagenmann-Froboese syndrome). *J Med Genet*. 1996;33(9):779-782. <https://doi.org/10.1136/jmg.33.9.779>
- Znaczko A, Donnelly DE, Morrison PJ. Epidemiology, clinical features, and genetics of multiple endocrine neoplasia type 2b in a complete population. *Oncologist*. 2014;19(12):1284-1286. <https://doi.org/10.1634/theoncologist.2014-0277>
- Mathiesen JS, Kroustrup JP, Vestergaard P, et al. Incidence and prevalence of multiple endocrine neoplasia 2B in Denmark: a nationwide study. *Endocr Relat Cancer*. 2017;24(7):L39-L42. <https://doi.org/10.1530/ERC-17-0122>
- Castinetti F, Waguespack SG, Machens A, et al. Natural history, treatment, and long-term follow up of patients with multiple endocrine neoplasia type 2B: an international, multicentre, retrospective study. *Lancet Diabetes Endocrinol*. 2019;7(3):213-220. [https://doi.org/10.1016/S2213-8587\(18\)30336-X](https://doi.org/10.1016/S2213-8587(18)30336-X)
- Brauckhoff M, Machens A, Hess S, et al. Premonitory symptoms preceding metastatic medullary thyroid cancer in MEN 2B: an exploratory analysis. *Surgery*. 2008;144(6):1044-1051. <https://doi.org/10.1016/j.surg.2008.08.028>
- Redlich A, Lessel L, Petrou A, Mier P, Vorwerk P. Multiple endocrine neoplasia type 2B: frequency of physical stigmata—Results of the GPOH-MET registry. *Pediatr Blood Cancer*. 2020;67(2):e28056. <https://doi.org/10.1002/pbc.28056>
- van den Broek MFM, Rijks EBG, Nikkels PGJ, et al. Timely diagnosis of multiple endocrine neoplasia 2B by identification of intestinal ganglioneuromatosis; a case-series. *Endocrine*. 2021;72:905-914.
- Vasen HF, van der Feltz M, Raue F, et al. The natural course of multiple endocrine neoplasia type IIb. A study of 18 cases. *Arch Intern Med*. 1992;152(6):1250-1252.
- Schönbeck Y, Talma H, Van Dommelen P, et al. The world's tallest nation has stopped growing taller: the height of Dutch children from 1955 to 2009. *Pediatr Res*. 2013;73(3):371-377. <https://doi.org/10.1038/pr.2012.189>
- Loeys BL, Dietz HC, Braverman AC, et al. The revised Ghent nosology for the Marfan syndrome. *J Med Genet*. 2010;47(7):476-485. <https://doi.org/10.1136/jmg.2009.072785>
- Rosen JE, Lloyd RV, Brierly JD, et al. Thyroid-Medullary. In: Amid AB, ed. *AJCC Cancer Staging Manual*. 8th ed. New York, NY: Springer; 2017:891.
- Juul A. Serum levels of insulin-like growth factor I and its binding proteins in health and disease. *Growth Horm IGF Res*. 2003;13(4):113-170. [https://doi.org/10.1016/S1096-6374\(03\)00038-8](https://doi.org/10.1016/S1096-6374(03)00038-8)
- Haspolat K, Ece A, Gürkan F, Atamer Y, Tutanç M, Yolbaş I. Relationships between leptin, insulin, IGF-1 and IGFBP-3 in children with energy malnutrition. *Clin Biochem*. 2007;40(3-4):201-205. <https://doi.org/10.1016/j.clinbiochem.2006.11.008>
- Nelson G, Aceto T, Keppen M, Wagner L. Multiple endocrine neoplasia, type 2B, with medullary thyroid carcinoma: a diagnostic potential for dentistry. *Pediatr Dent*. 1979;1(2):125-128.
- Carney J, Bianco A, Sizemore G, Hayles A. Multiple endocrine neoplasia with skeletal manifestations. *J Bone Jt Surg*. 1981;63(3):405-410.
- Jones BA, Sisson JC. Early diagnosis and thyroidectomy in multiple endocrine neoplasia, type 2b. *J Pediatr*. 1983;102(2):219-223. [https://doi.org/10.1016/S0022-3476\(83\)80524-1](https://doi.org/10.1016/S0022-3476(83)80524-1)

20. Smith VV, Eng E, Milla PJ. Intestinal ganglioneuromatosis and multiple endocrine neoplasia type 2B: implications for treatment. *Gut*. 1999;45(1):143-146. <https://doi.org/10.1136/gut.45.1.143>
21. Singer K, Heiniger N, Thomas I, Worden FP, Menon RK, Chen M. Ectopic Cushing syndrome secondary to metastatic medullary thyroid cancer in a child with multiple endocrine neoplasia syndrome type 2B: clues to early diagnosis of the paraneoplastic syndromes. *J Pediatr Endocrinol Metab*. 2014;27(9-10):993-996. <https://doi.org/10.1515/jpem-2013-0456>
22. Subtirelu R. Short stature in a child with multiple endocrine neoplasia Type 2B. 10th International Meeting of Pediatric Endocrinology. *Horm Res Paediatr*. 2017;88(suppl 1):1-628. <https://doi.org/10.1159/000481424>

SUPPORTING INFORMATION

Additional Supporting Information may be found online in the supporting information tab for this article.

How to cite this article: van den Broek MFM, van Santen HM, Valk GD, Verrijn Stuart AA. Children with multiple endocrine neoplasia type 2B: Not tall and marfanoid, but short with normal body proportions. *Clin Endocrinol*. 2021;95: 453-459. <https://doi.org/10.1111/cen.14536>