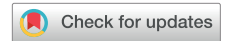

The Presence of Metastatic Thoracic Duct Lymph Nodes in Western Esophageal Cancer Patients: A Multinational Observational Study



Ingmar L. Defize, MD, Stijn M. C. Gorgels, BSc, Elena Mazza, MD, Bernadette Schurink, MD, PhD, Paolo Strignano, MD, PhD, Giorgia Catalano, MD, PhD, Lodewijk A. A. Brosens, MD, PhD, Luigi Chiusa, MD, Ronald L. A. W. Bleys, MD, PhD, Stella Mook, MD, PhD, Gert J. Meijer, PhD, Renato Romagnoli, MD, PhD, Jelle P. Rurda, MD, PhD, and Richard van Hillegersberg, MD, PhD

Department of Surgery, University Medical Center Utrecht, Utrecht, the Netherlands; Department of Radiation Oncology, University Medical Center Utrecht, Utrecht, the Netherlands; General Surgery 2U – Liver Transplant Unit, A.O.U. Città della Salute e della Scienza di Torino, University of Turin, Turin, Italy; Department of Anatomy, University Medical Center Utrecht, Utrecht, the Netherlands; Department of Pathology, University Medical Center Utrecht, Utrecht, the Netherlands; and Department of Pathology, A.O.U. Città della Salute e della Scienza di Torino, University of Turin, Turin, Italy

ABSTRACT

BACKGROUND The thoracic lymphadenectomy during an esophagectomy for esophageal cancer includes resection of the thoracic duct (TD) compartment containing the TD lymph nodes (TDLNs). The role of TD compartment resection is still a topic of debate since metastatic TDLNs have only been demonstrated in squamous cell carcinomas in Eastern esophageal cancer patients. Therefore, the aim of this study was to assess the presence and metastatic involvement of TDLNs in a Western population, in which adenocarcinoma is the predominant type of esophageal cancer.

METHODS From July 2017 to May 2020, all consecutive patients undergoing an open or robot-assisted transthoracic esophagectomy with concurrent lymphadenectomy and resection of the TD compartment in the University Medical Center Utrecht in Utrecht, the Netherlands, and the Città della Salute e della Scienza University Hospital in Turin, Italy, were included. The TD compartment was resected en bloc and was separated in the operation room by the operating surgeon after which it was macroscopically and microscopically assessed for (metastatic) TDLNs by the pathologist.

RESULTS A total of 117 patients with an adenocarcinoma (73%) or squamous cell carcinoma (27%) of the esophagus were included. In 61 (52%) patients, TDLNs were found, containing metastasis in 9 (15%) patients. No major complications related to TD compartment resection were observed.

CONCLUSIONS This study demonstrates the presence of metastatic TDLNs in adenocarcinomas of the esophagus. This result provides a valid argument to routinely extend the thoracic lymphadenectomy with resection of the TD compartment during an esophagectomy for esophageal cancer.

(Ann Thorac Surg 2022;113:429-35)

© 2022 by The Society of Thoracic Surgeons. Published by Elsevier Inc. This is an open access article under the CC BY-NC-ND license (<http://creativecommons.org/licenses/by-nc-nd/4.0/>).

Multimodality treatment, consisting of neoadjuvant chemo(radio)therapy and esophagectomy, is the standard of care for patients with locally advanced esophageal cancer treated with curative intent. The esophagectomy is performed with an en bloc thoracic and abdominal lymphadenectomy.¹⁻³ The thoracic lymphadenectomy consists of a complete resection of the lymph node (LN) stations surrounding the esophagus and includes resection of the thoracic

duct (TD) compartment.⁴ This compartment contains the TD and its surrounding TDLNs. Resection of the TD compartment is a feasible procedure that may increase the (metastatic) LN yield.⁵⁻⁷

The anatomy of the esophageal lymphatics facilitates spread to the TDLNs, as it consists of an extensive network of vessels located in all layers of esophagus that drain directly into the TD.⁸⁻¹⁰ The presence of metastatic TDLNs has been demonstrated in 6% to 11% of patients

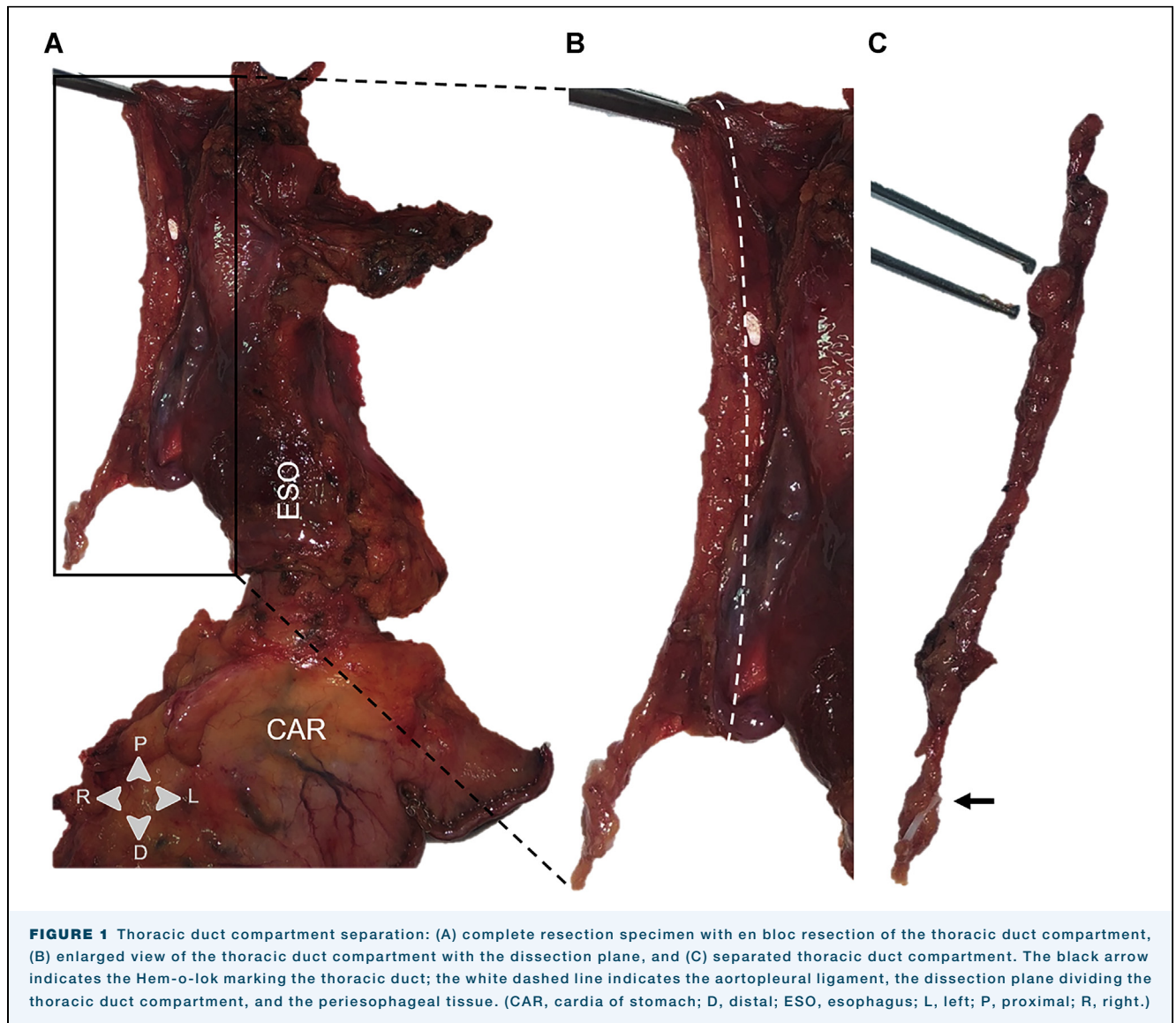


FIGURE 1 Thoracic duct compartment separation: (A) complete resection specimen with en bloc resection of the thoracic duct compartment, (B) enlarged view of the thoracic duct compartment with the dissection plane, and (C) separated thoracic duct compartment. The black arrow indicates the Hem-o-lok marking the thoracic duct; the white dashed line indicates the aortopleural ligament, the dissection plane dividing the thoracic duct compartment, and the periesophageal tissue. (CAR, cardia of stomach; D, distal; ESO, esophagus; L, left; P, proximal; R, right.)

with advanced squamous cell carcinoma (SCC).^{7,11} Therefore, extension of the thoracic lymphadenectomy with resection of the TD compartment has been advocated and a standardized approach has been developed.⁵

However, resection of the TD compartment is not routinely performed in all centers in the Western world, as metastatic involvement of TDLNs has not been demonstrated in adenocarcinomas, which is the most common histological subtype of esophageal cancer in the Western population.¹² Additionally, TD resection is associated with an increase in postoperative complications such as chyle leakage and recurrent nerve injury.^{13,14} However, this has been contradicted in literature and a general consensus is lacking, resulting in different surgical strategies across centers.¹⁵⁻¹⁷

Therefore, the aim of this study was to assess the presence of TDLNs and the metastatic involvement of

these nodes in patients with SCCs or adenocarcinomas of the esophagus. To assess the safety of TD compartment resection, associated complications were reported.

PATIENTS AND METHODS

STUDY POPULATION. Between July 2017 and May 2020, all consecutive patients with a histologically proven adenocarcinoma or SCC of the esophagus who underwent a transthoracic esophagectomy with a 2-field or 3-field lymphadenectomy and resection of the TD compartment in the University Medical Center Utrecht in Utrecht, the Netherlands, and the A.O.U. Città della Salute e della Scienza in Turin, Italy, were included. Patient, tumor, and clinical characteristics were extracted from a prospectively maintained database.

TABLE 1 Patient Demographics and Tumor Characteristics

Characteristic	n = 117
Age, y	67 ± 10
Sex	
Male	83 (71)
Female	34 (29)
BMI, kg/m ²	25 ± 4
Histopathology ^a	
Adenocarcinoma	85 (73)
Squamous cell carcinoma	32 (27)
Tumor location	
Proximal	4 (3)
Middle	22 (19)
Distal	91 (78)
Clinical T stage ^b	
T1	9 (8)
T2	13 (11)
T3	91 (78)
T4	4 (3)
Clinical N stage ^b	
N0	35 (30)
N1	52 (44)
N2	22 (19)
N3	8 (7)
Neoadjuvant treatment	
Chemotherapy	12 (10)
Chemoradiotherapy	82 (70)
None	23 (20)
Type of surgery	
McKeown	31 (27)
Ivor Lewis	86 (73)
Surgical approach	
Open	55 (47)
RAMIE	62 (53)

^aDetermined in pretreatment biopsy; ^bBased on the 7th edition of the American Joint Committee on Cancer Cancer Staging Manual. Values are mean ± SD or n (%). BMI, body mass index; RAMIE, robot-assisted minimally invasive esophagectomy.

Institutional review board approval was obtained and the need for informed consent was waived.

CLINICAL STAGING. The standard diagnostic workup for clinical staging consisted of an endoscopy with biopsies, an endoscopic ultrasound, and a contrast computed tomography scan of the neck, thorax, and abdomen. A 18F-fluorodeoxyglucose positron emission tomography-computed tomography (PET-CT) was routinely performed in the Netherlands and in selected cases in Italy. Staging was done according to the 7th edition of the American Joint Committee on Cancer Cancer Staging Manual.¹⁸

SURGICAL PROCEDURE. An open or robot-assisted transthoracic esophagectomy was performed by dedicated upper gastrointestinal surgeons (the Netherlands: R.v.H., J.P.R.; Italy: R.R., P.S.). During the

thoracic part of the procedure, mobilization of the esophagus was combined with the thoracic lymphadenectomy, which included the right and left paratracheal (station 2R, L), tracheobronchial (station 4R, L), aortopulmonary window (station 5), subcarinal (station 7), periesophageal (station 8M, L), and pulmonary ligament (station 9) LNs and en bloc resection of the TD compartment.¹⁸ As previously described, the TD compartment is anatomically defined by the aortoesophageal and aortopleural ligament anteriorly, by the spine posteriorly, and by the azygos vein and aorta laterally.^{5,10} The TD was ligated 5 cm above the diaphragm which is the surgical caudal border of the TD compartment. At this location most of the abdominal tributaries have merged with the TD.¹⁹ The surgical cranial border of the TD compartment is located in the left thoracic inlet. At this location, the TD is transected with a bipolar vessel sealer. The operating surgeon separated the TD compartment from the resection specimen by following the dissection plane provided by the aortopleural ligament, after which it was sent to the Pathology Department (Figure 1).¹⁰ If there was suspicion of tumor invasion in the TD compartment, the compartment was marked and separated by the pathologist to ensure a reliable assessment of the circumferential resection margin.

PATHOLOGICAL ASSESSMENT OF THE TD COMPARTMENT.

A standard protocol was used for evaluation of the resection specimen. The entire TD compartment was inspected macroscopically, and visible LNs were separated and embedded in paraffin, as was the remaining part of the TD. For the microscopic assessment of TDLNs, 4-µm sections were made and stained with hematoxylin and eosin. The number of TDLNs, metastatic involvement, and response to neoadjuvant treatment were assessed. Tumor-positive LNs were defined as LNs containing metastatic disease regardless of the size of the metastasis. Pathological assessment was done according to the College of American Pathologists.

TD RESECTION-ASSOCIATED POSTOPERATIVE COMPLICATIONS.

Chyle leakage and recurrent nerve injury were assessed during hospital admission and registered in a weekly consensus meeting. Complications were defined according to the Esophagectomy Complications Consensus Group (ECCG) and severity was registered according to the Clavien-Dindo classification.^{20,21}

DATA ANALYSIS. Patient and tumor characteristics were described as count and percentage, mean ± SD, or median (range) where appropriate. Data analysis was performed using SPSS version 26 (IBM Corporation, Armonk, NY).

TABLE 2 Pathology Results	
Characteristic	n = 117
Pathologic T stage	
T0	30 (26)
T1	28 (24)
T2	14 (12)
T3	45 (38)
Pathologic N stage	
N0	69 (59)
N1	25 (21)
N2	12 (10)
N3	11 (9)
Mandard	
1	29 (25)
2	22 (19)
3	18 (15)
4	24 (21)
5	1 (1)
No neoadjuvant treatment	23 (20)
LN yield	37 (10-96)
Positive LNs ^a	2 (1-20)
TDLN present	
Yes	61 (52)
No	56 (48)

^aNumber of positive nodes if LN metastasis was present. Values are n (%) or median (range). LN, lymph node; TDLN, thoracic duct lymph node.

RESULTS

STUDY POPULATION. A total of 117 patients were included, with a mean age of 67 ± 10 years, and 83 (71%) were men. Most patients had a histologically proven adenocarcinoma (73%) of the distal esophagus (78%). A clinical T3 stage (78%) was most frequent with clinically suspected LN metastasis in 82 (70%) patients. A majority of patients (80%) received neoadjuvant treatment, consisting of chemoradiotherapy in 70% of the cases. A complete overview of patient and tumor characteristics is presented in Table 1.

HISTOPATHOLOGICAL RESULTS. A pathological T3 stage was observed in the majority of patients (38%). Among patients who received neoadjuvant treatment, a pathological complete response (Mandard 1) was observed in 25%. The median number of resected LNs was 37 (range,

TABLE 3 Presence of (Metastatic) TDLNs	
Variable	n = 117
TDLN present	61 (52)
Number of TDLNs	2 (1-11)
Patients with metastatic TDLNs	9 (8)
Number of metastatic TDLNs	1 (1-2)

Values are n (%) or median (range). TDLN, thoracic duct lymph node.

10-96) with LN metastasis in 40% of the patients. In the patients with LN metastasis, a median of 2 (range, 1-20) tumor-positive LNs were found (Table 2).

THORACIC DUCT LNS. TDLNs were present in 61 (52%) patients, with a median number of 2 (range, 1-11) nodes per patient. Of these patients, 9 (15%) had metastatic TDLNs, with a median of 1 (range, 1-2) metastatic node (Table 3). In 1 patient, the metastatic TDLN was the only tumor-positive LN in the resection specimen. Metastatic TDLNs were observed in both SCCs (3%, n = 1 of 31) and adenocarcinomas (10%, n = 8 of 85) with a pathologic T3 stage, all located at the distal esophagus. None of the metastatic TDLNs were visible during diagnostic imaging. A total of 8 of 9 patients with metastatic TDLNs received neoadjuvant treatment. Regressive changes in the TDLNs were observed in 2 of the patients that received neoadjuvant treatment. A complete overview of the patients with metastatic TDLNs is provided in Table 4.

TD RESECTION-ASSOCIATED POSTOPERATIVE COMPLICATIONS. An uncomplicated postoperative course was observed in 30 (26%) patients. Chyle leakage was observed in 5 (4%) patients and recurrent nerve injury in 14 (12%) patients, of which 12 cases were left-sided. Surgical treatment of chyle leakage was required in 2 patients and was graded as type III according to the ECCG classification. In these patients, video-assisted thoracoscopic surgery was performed to locate and repair the leak. In both cases, the leakage was of the TD distal from the initial ligation and was stopped through mass ligation of the area caudal to the leak. All patients with recurrent nerve injury had transient complaints that were conservatively treated and were graded as type I according to the ECCG classification (Table 5).²⁰

COMMENT

This study demonstrates the presence of TDLNs in 52% of patients, of which 15% contained metastasis, even after neoadjuvant therapy. Metastatic TDLNs were observed in both adenocarcinomas and SCCs. Postoperative complications associated with TD resection such as chyle leakage and recurrent nerve injury were observed in 4% and 12%, respectively, and were of limited severity in most cases.

This report demonstrates the presence of metastatic TDLNs in adenocarcinomas of the esophagus and substantiates previous research on the existence of metastatic TDLNs in SCCs.^{5,7} The presence of metastatic TDLNs in both adenocarcinomas and SCCs, even after neoadjuvant treatment, provides a valid argument to extend the thoracic lymphadenectomy with resection of the TD compartment. Standard resection of the TD

TABLE 4 Characteristics of Metastatic Thoracic Duct Lymph Nodes

Characteristic	n = 9
Histopathology	
Adenocarcinoma	8 (89)
Squamous cell carcinoma	1 (11)
Tumor location	
Distal	9 (100)
Clinical T stage^a	
T2	1 (11)
T3	8 (89)
Clinical N stage^a	
N0	2 (22)
N1	3 (33)
N2	3 (33)
N3	1 (11)
Neoadjuvant treatment	
Chemotherapy	4 (44)
Chemoradiotherapy	4 (44)
None	1 (11)
Pathologic T stage^a	
T1	1 (11)
T3	8 (89)
Pathologic N stage^a	
N1	2 (22)
N2	2 (22)
N3	5 (56)
Mandard	
2	1 (11)
3	1 (11)
4	6 (67)
No neoadjuvant treatment	1 (11)

^aBased on the 7th edition of the American Joint Committee on Cancer Cancer Staging Manual. Values are n (%).

compartment leads to an increase in LN yield, which is associated with an improved prognosis.²² Additionally, resection of metastatic TDLNs will increase the oncologic radicality of this procedure.

Assessment of the presence of (metastatic) TDLNs on diagnostic imaging might aid in the decision to remove the TD compartment. However, the assessment of LNs on conventional imaging remains challenging even in the case of LN metastasis. In 24% of the included patients with a clinical N0 stage, tumor-positive nodes were found upon pathological assessment. This indicates the inability of current diagnostic imaging techniques to accurately identify nodal metastasis preoperatively. Therefore, resection of the TD compartment should not be based on imaging, but rather on the considerable possibility of LN metastasis in this compartment.

It should be noted that TDLNs were absent in 48% of the included patients and that in these patients routine resection other TD compartment does not contribute to an increased (metastatic) LN yield. The absence of

TDLNs in some patients is in line with previous reports in which TDLNs were found in 67% of the patients. The varying presence of LNs in well-defined thoracic LN stations such as stations 2, 4, 8, and 9 has been previously reported in cadaver studies.²³ It might well be hypothesized that these variations also apply to the TDLNs.

The most common complications that have been associated with resection of the TD compartment are chyle leakage and recurrent nerve injury.^{13,14} To provide insight in the safety of TD compartment resection, these complications were assessed in the current report. Of these complications, chyle leakage is associated with the highest morbidity and mortality. Chyle leakage occurred in 4%, which is comparable to the incidence observed in previous reports assessing complications associated with esophagectomy.²⁰ The observed recurrent nerve injury rate of 12% is significant, but within the range of 4% to 30% that has been reported in literature.^{14,20,24-27} With that, all complaints were of transient nature and were graded as type I according to the ECCG classification, indicating that no therapy was needed.²⁰ The incidence of these complications suggests that resection of the TD compartment can be performed safely. In addition, both chyle leakage and recurrent nerve injury have a multifactorial etiology, and the increased risk of these complications that is attributable to TD compartment resection remains unclear. This particularly accounts for recurrent nerve injury. Regarding the anatomy of the recurrent nerve region, it is improbable that TD resection causes recurrent nerve injury. The TD compartment and the recurrent nerve region are 2 distinct compartments that can be dissected independently.²⁸ Therefore, recurrent nerve injury is presumably caused by either resection of the paratracheal and aortopulmonary window LNs (ie, stations 4 and 5) or the left cervical dissection in case of a McKeown approach.²⁹

TABLE 5 Postoperative Complications Associated With Thoracic Duct Resection

Complication ^a	n (%)
Uncomplicated procedures	30 (26)
Recurrent nerve injury	14 (12)
Type I	14
Unilateral left	12
Unilateral right	1
Bilateral	1
Chyle leakage	5 (4)
Type I	1
Type II	2
Type III	2

^aComplications defined according to Esophageal Complications Consensus Group.

Some limitations apply to the current report. Due to the routine resection of the TD compartment in the participating centers, we were not able to directly compare a TD-resected group and a TD-preserved group in terms of perioperative, oncological outcomes as well as in terms of survival. However, a recently published report demonstrated that besides a statistically significant longer operating time, there were no differences in terms of blood loss and postoperative complications between TD-resected and TD-preserved groups.¹⁵ Our report provides convincing evidence of the presence of metastatic TDLNs in both SCCs and adenocarcinomas of the esophagus. Routine resection of these nodes might have a considerable impact on the oncological completeness of an esophagectomy for esophageal cancer. These oncological benefits and the comparable perioperative results in the previous literature substantiate the added value of extending the thoracic lymphadenectomy with resection of the TD compartment. Nevertheless, our report does not demonstrate a survival benefit related to the resection of the TD compartment, which would be a more conclusive argument to routinely resect the TDLNs. To demonstrate a survival benefit, a randomized controlled trial with an intervention arm (ie, resection of TD compartment) and a control arm (ie, preservation of the TD compartment) would be the preferred method. However, because this report evidently demonstrates the presence of metastatic TDLNs, it would be in conflict with the surgical oncological principles to design a randomized controlled trial

in which these metastatic LNs might not be resected (ie, the control arm). Therefore, this report together with previous literature regarding this subject might be the highest level of evidence that can be provided.

The current report demonstrates that extending the standard thoracic lymphadenectomy with resection of the TD compartment is feasible in open as well as robot-assisted minimally invasive esophageal surgery. Standardized steps for TD compartment resection have been described, and the anatomical borders of the TD compartment allow for a clear identification and meticulous dissection.⁵ Therefore, adding the resection of TD compartment to an existing procedure is relatively straightforward. However, it should be taken into account that the alteration of an existing procedure might be subject to a learning curve.

In conclusion, this study confirms the presence of metastatic TDLNs in patients with esophageal SCC and demonstrates the presence of metastatic TDLNs in patients with adenocarcinoma of the esophagus. These results provide a valid argument to routinely resect the TD compartment. Related postoperative complication rates were relatively mild and, in our opinion, acceptable with regard to the increased oncological completeness that is achieved with resection of the TDLNs. Therefore, this report should act as an incentive to consider the extension of the thoracic lymphadenectomy with resection of the TD compartment in patients undergoing an esophagectomy for esophageal cancer.

REFERENCES

1. Japan Esophageal Society. Japanese Classification of Esophageal Cancer, 11th Edition: part I. *Esophagus*. 2017;14:1-36.
2. Shapiro J, van Lanschoot JJB, Hulshof MCCM, et al. Neoadjuvant chemoradiotherapy plus surgery versus surgery alone for oesophageal or junctional cancer (CROSS): Long-term results of a randomised controlled trial. *Lancet Oncol*. 2015;16:1090-1098.
3. Hulscher JBF, van Sandick JW, de Boer AGEM, et al. Extended trans-thoracic resection compared with limited transhiatal resection for adenocarcinoma of the esophagus. *N Engl J Med*. 2002;347:1662-1669.
4. Siewert JR, Hölscher AH, Roder J, Bartels H. En-bloc Resektion der Speiseröhre beim Oesophaguscarcinom. *Langenbecks Arch Chir*. 1988;373:367-376.
5. Schurink B, Defize IL, Mazza E, et al. Two-field lymphadenectomy during esophagectomy: the presence of thoracic duct lymph nodes. *Ann Thorac Surg*. 2018;106:435-439.
6. Matsuda S, Takeuchi H, Kawakubo H, et al. Clinical outcome of trans-thoracic esophagectomy with thoracic duct resection. *Medicine (Baltimore)*. 2016;95:e3839.
7. Udagawa H, Ueno M, Shinohara H, et al. Should lymph nodes along the thoracic duct be dissected routinely in radical esophagectomy? *Esophagus*. 2014;11:204-210.
8. Saito H, Sato T, Miyazaki M. Extramural lymphatic drainage from the thoracic esophagus based on minute cadaveric dissections: fundamentals for the sentinel node navigation surgery for the thoracic esophageal cancers. *Surg Radiol Anat*. 2007;29:531-542.
9. Murakami G, Sato I, Shimada K, Dong C, Kato Y, Imazeki T. Direct lymphatic drainage from the esophagus into the thoracic duct. *Surg Radiol Anat*. 1994;16:399-407.
10. Weijs TJ, Goense L, van Rossum PSN, et al. The peri-esophageal connective tissue layers and related compartments: visualization by histology and magnetic resonance imaging. *J Anat*. 2017;230:262-271.
11. Matsuda S, Takeuchi H, Kawakubo H, et al. Clinical outcome of transthoracic esophagectomy with thoracic duct resection: number of dissected lymph node and distribution of lymph node metastasis around the thoracic duct. *Medicine (Baltimore)*. 2016;95:e3839.
12. Coleman HG, Xie SH, Lagergren J. The epidemiology of esophageal adenocarcinoma. *Gastroenterology*. 2018;154:390-405.
13. Yoshida N, Nagai Y, Baba Y, et al. Effect of resection of the thoracic duct and surrounding lymph nodes on short- and long-term and nutritional outcomes after esophagectomy for esophageal cancer. *Ann Surg Oncol*. 2019;26:1893-1900.
14. Oshikiri T, Takiguchi G, Miura S, et al. Thoracic duct resection during esophagectomy does not contribute to improved prognosis in esophageal squamous cell carcinoma: a propensity score matched-cohort study. *Ann Surg Oncol*. 2019;26:4053-4061.
15. Matsuda S, Kawakubo H, Takeuchi H, et al. Minimally invasive oesophagectomy with extended lymph node dissection and thoracic duct resection for early-stage oesophageal squamous cell carcinoma. *Br J Surg*. 2020;107:705-711.

- 16.** Choh CTP, Khan OA, Rychlik IJ, McManus K. Does ligation of the thoracic duct during oesophagectomy reduce the incidence of post-operative chylothorax? *Int J Surg.* 2012;10:203-205.
- 17.** Crucitti P, Mangiameli G, Petitti T, et al. Does prophylactic ligation of the thoracic duct reduce chylothorax rates in patients undergoing oesophagectomy? A systematic review and meta-Analysis. *Eur J Cardiothoracic Surg.* 2016;50:1019-1024.
- 18.** Amin MB, Edge SB, Greene F, et al. *AJCC Cancer Staging Manual.* New York, NY: Springer; 2017.
- 19.** Defize IL, Schurink B, Weijts TJ, et al. The anatomy of the thoracic duct at the level of the diaphragm: a cadaver study. *Ann Anat.* 2018;217:47-53.
- 20.** Low DE, Kuppusamy MK, Alderson D, et al. Benchmarking complications associated with esophagectomy. *Ann Surg.* 2019;269:291-298.
- 21.** Dindo D, Demartines N, Clavien PA. Classification of surgical complications: A new proposal with evaluation in a cohort of 6336 patients and results of a survey. *Ann Surg.* 2004;240:205-213.
- 22.** Visser E, van Rossum PSN, Ruurda JP, van Hillegersberg R. Impact of lymph node yield on overall survival in patients treated with neoadjuvant chemoradiotherapy followed by esophagectomy for cancer. *Ann Surg.* 2017;266:863-869.
- 23.** Ziyade S, Pinarbasili NB, Ziyade N, et al. Determination of standard number, size and weight of mediastinal lymph nodes in postmortem examinations: reflection on lung cancer surgery. *J Cardiothorac Surg.* 2013;8:771-776.
- 24.** Zhong D, Zhou Y, Li Y, et al. Intraoperative recurrent laryngeal nerve monitoring: a useful method for patients with esophageal cancer. *Dis Esophagus.* 2014;27:444-451.
- 25.** Koyanagi K, Igaki H, Iwabu J, Ochiai H, Tachimori Y. Recurrent laryngeal nerve paralysis after esophagectomy: respiratory complications and role of nerve reconstruction. *Tohoku J Exp Med.* 2015;237:1-8.
- 26.** Swanson SJ, Batirel HF, Bueno R, et al. Transthoracic esophagectomy with radical mediastinal and abdominal lymph node dissection and cervical esophagogastrotomy for esophageal carcinoma. *Ann Thorac Surg.* 2001;72:1918-1925.
- 27.** Van Sandick JW, Van Lanschot JJB, Ten Kate FJW, Tijssen JGP, Obertop H. Indicators of prognosis after transhiatal esophageal resection without thoracotomy for cancer. *J Am Coll Surg.* 2002;194:28-36.
- 28.** Fujiwara H, Kanamori J, Nakajima Y, et al. An anatomical hypothesis: a "concentric-structured model" for the theoretical understanding of the surgical anatomy in the upper mediastinum required for esophagectomy with radical mediastinal lymph node dissection. *Dis Esophagus.* 2019;32:doy119.
- 29.** Kingma BF, Grimminger PP, van der Sluis PC, et al. Worldwide techniques and outcomes in robot-assisted minimally invasive esophagectomy (RAMIE) [e-pub ahead of print]. *Ann Surg.* <https://doi.org/10.1097/SLA.0000000000004550>, accessed December 5, 2020.