

## MINI-FOCUS ISSUE: CARDIOMYOPATHIES

## BEGINNER

## CASE REPORT: CLINICAL CASE

# Arrhythmogenic Right Ventricular Cardiomyopathy in a Pediatric Patient



Rob W. Roudijk, MD,<sup>a</sup> Reinder Evertz, MD,<sup>b</sup> Arco J. Teske, MD, PhD,<sup>a</sup> Carlo Marcelis, MD,<sup>c</sup> Dennis Bosboom, MD,<sup>d</sup> Birgitta K. Velthuis, MD, PhD,<sup>e</sup> Floris E.A. Udink ten Cate, MD, PhD,<sup>f,g</sup> Anneline S.J.M. te Riele, MD, PhD<sup>a</sup>

## ABSTRACT

Arrhythmogenic right ventricular cardiomyopathy (ARVC) is rarely diagnosed in childhood. We describe the case of a 9-year-old girl with genetically confirmed ARVC who presented with syncope, ventricular arrhythmia, and biventricular myocardial dysfunction. This case highlights the need for development of pediatric ARVC diagnosis criteria specific for pediatric patients and discusses potential diagnostic improvement using echocardiographic deformation imaging.

(**Level of Difficulty: Beginner.**) (J Am Coll Cardiol Case Rep 2020;2:919–24) © 2020 The Authors. Published by Elsevier on behalf of the American College of Cardiology Foundation. This is an open access article under the CC BY-NC-ND license (<http://creativecommons.org/licenses/by-nc-nd/4.0/>).

## PRESENTATION

A 9-year-old girl was admitted to the authors' hospital for evaluation of recurrent syncope. She was not taking any medication. Physical examination was unremarkable.

## MEDICAL HISTORY

Prior to presentation, she experienced daily episodes of palpitations with nearly syncope and 2 episodes of syncope during exercise (i.e., gymnastics class at school). She did not have chest pain or dyspnea. Her family history was negative for sudden cardiac death or cardiomyopathy. She did not participate in

## LEARNING OBJECTIVES

- Since the diagnostic Task Force Criteria were derived in a predominantly adult cohort, their use in children should be considered experimental, and physicians should be aware of their limitations in the pediatric population.
- Echocardiographic deformation imaging is useful for diagnostic evaluation of arrhythmogenic right ventricular cardiomyopathy.
- Given the incomplete penetrance of disease, genetic testing should be integrated in the evaluation of young patients with unexplained cardiomyopathy, even without a family history of heart disease.

From the <sup>a</sup>Department of Cardiology, Division of Heart and Lungs, University Medical Center Utrecht, Utrecht, the Netherlands;

<sup>b</sup>Department of Cardiology, Radboud University Medical Center, Nijmegen, the Netherlands; <sup>c</sup>Department of Clinical Genetics, Radboud University Medical Center, Nijmegen, the Netherlands; <sup>d</sup>Department of Radiology, Radboud University Medical Center, Nijmegen, the Netherlands; <sup>e</sup>Department of Radiology, University Medical Center Utrecht, Utrecht, the Netherlands; <sup>f</sup>Department of Pediatric Cardiology, Academic Center for Congenital Heart Disease, Amalia Children's Hospital, Radboud University Medical Center, Nijmegen, the Netherlands; and the <sup>g</sup>Division of Pediatric Cardiology, Department of Pediatrics, Sophia Children's Hospital, Erasmus Medical Center, Rotterdam, the Netherlands. Supported by Dutch Heart Foundation grants 2015T058 to Dr. te Riele; and CVON2015-12 eDETECT, 2012-10 PREDICT, and CVON PREDICT Young Talent Program to Dr. te Riele; and the University Medical Center Utrecht Fellowship Clinical Research Talent grant to Dr. te Riele. All other authors have reported that they have no relationships relevant to the contents of this paper to disclose.

The authors attest they are in compliance with human studies committees and animal welfare regulations of the authors' institutions and Food and Drug Administration guidelines, including patient consent where appropriate. For more information, visit the *JACC: Case Reports* [author instructions page](#).

Manuscript received August 13, 2019; revised manuscript received November 29, 2019, accepted January 6, 2020.

**ABBREVIATIONS  
AND ACRONYMS**

**ARVC** = arrhythmogenic right ventricular cardiomyopathy

**CMR** = cardiac magnetic resonance

**DCM** = dilated cardiomyopathy

**ECG** = electrocardiogram

competitive sports. Her medical history included only urticaria.

**DIFFERENTIAL DIAGNOSIS**

Syncope in children has a broad differential (Table 1). Exercise-induced syncope associated with palpitations is highly suspicious of a cardiac cause, especially ventricular arrhythmia.

**INVESTIGATIONS**

**ELECTROCARDIOGRAPHY.** The 12-lead electrocardiography (ECG) showed sinus rhythm, right heart axis,

normal conduction intervals, high R-wave amplitude, T-wave inversions in leads V<sub>1</sub> to V<sub>4</sub> and flattened T waves in the inferior leads (Figure 1). Twenty-four-hour Holter monitor revealed 1,689 premature ventricular complexes and 4 episodes of nonsustained ventricular tachycardia with unknown morphology at 250 to 270 beats/min.

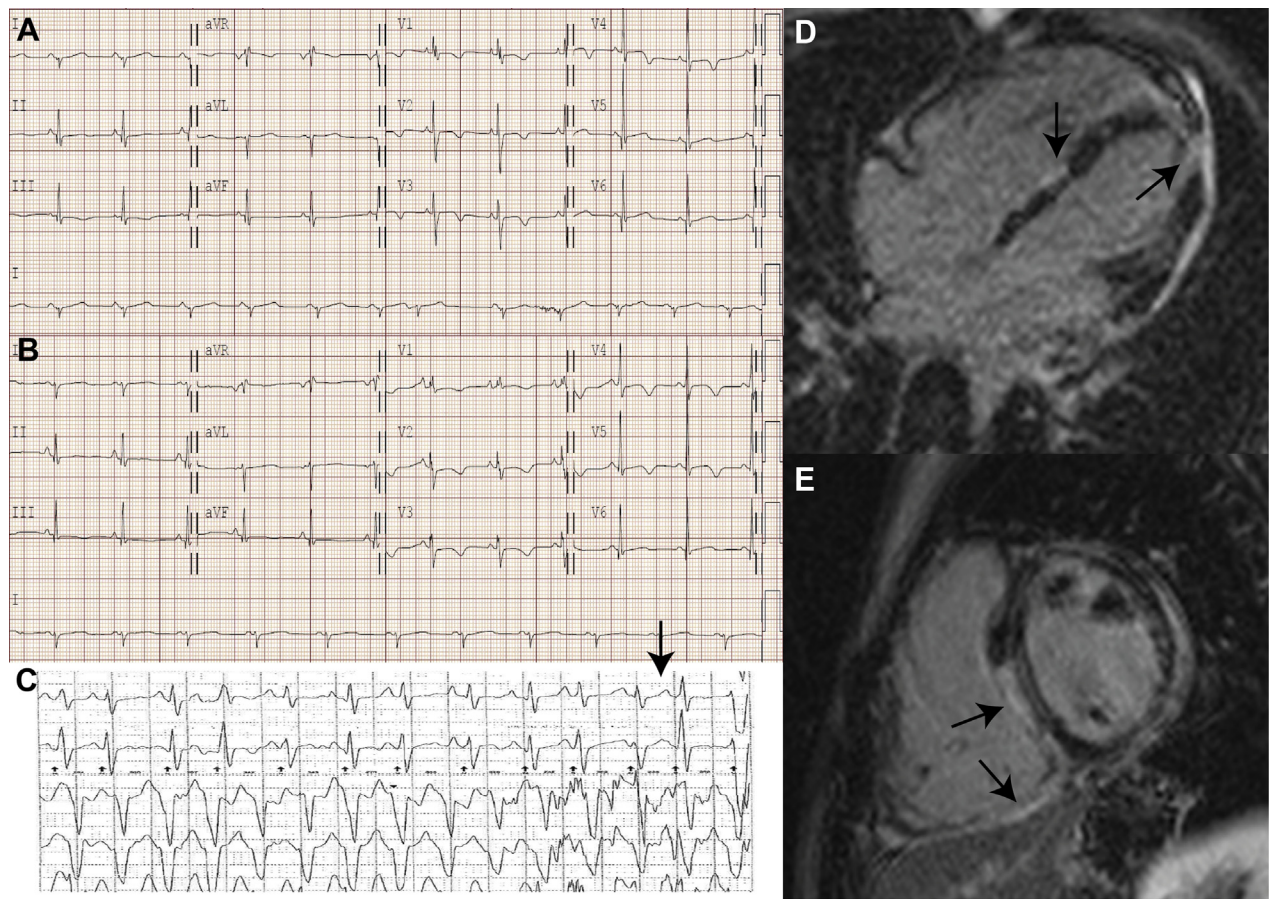
**ECHOCARDIOGRAPHY.** Two-dimensional trans-thoracic echocardiography showed a morphologically normal heart and left ventricular (LV) wall thickness (Video 1). Mild biventricular dilation and systolic dysfunction were present (LV ejection fraction [EF] of 50% and tricuspid annular plane systolic excursion of 17 mm). Task Force Criteria (TFC) for ARVC were not

**TABLE 1 Differential Diagnosis of Syncope**

Differential Diagnosis	Arguments Pro and Con Diagnosis
<b>Cardiac causes</b>	
Primary electrical disease	
Long QT syndrome	Normal QT interval and presence of significant structural heart disease makes diagnosis unlikely.
RVOT/LVOT tachycardia	Presence of significant structural heart disease makes diagnosis unlikely.
Catecholaminergic polymorphic ventricular tachycardia	Patients with CPVT present with exercise-induced ventricular arrhythmias in absence of structural heart disease. In this case, presence of significant structural heart disease in this case makes CPVT diagnosis unlikely. NB patients in the "concealed" phase of ARVC can present with exercise-induced ventricular arrhythmias in absence of structural disease, a presentation that mimics CPVT. However, CPVT does not progress into structural heart disease, has a different genetic etiology and ventricular arrhythmias have a polymorphic character compared to monomorphic left bundle branch block morphology in cases of classical ARVC.
<b>Cardiomyopathy</b>	
Dilated cardiomyopathy	Mild LV dilation (104 ml/m <sup>2</sup> ) and LV dysfunction (49%) are suggestive of diagnosis. The incidence of DCM in children is far higher compared to ARVC which is more commonly seen during young adulthood. However, DCM was not the most likely diagnosis because the evident RV involvement and the occurrence of ventricular arrhythmias in the early stages of disease are more suggestive of ARVC with LV involvement. Patients with ARVC and LV involvement can mimic patients with DCM, however the arrhythmic risk and genetic etiology are different (4).
Hypertrophic (obstructive) cardiomyopathy	Not likely, LV myocardial segment diameters are within two standard deviations when corrected for age.
Arrhythmogenic right ventricular cardiomyopathy	Most likely diagnosis, due to presentation with ventricular tachycardia, significant PVC burden, focal akinesia of the RV with epicardial LGE with RV dilation and dysfunction. Diagnosis confirmed by pathogenic desmosomal variants.
<b>Myocardial Inflammation</b>	
Sarcoidosis	No evidence of systemic or cardiac sarcoidosis (Table 2).
Myocarditis	No evidence of active myocarditis on T2 imaging of CMR and normal troponin levels. Normal inflammatory markers, virus serology, and bacterial cultures (Table 2)
<b>Other cardiac causes</b>	
Valvular disease	Echocardiography showed no severe valvular disease.
Acute myocardial infarction or ischemia	No acute coronary syndrome and no signs of an aberrant coronary artery on imaging.
Acute aortic dissection	No evidence of aortic dissection on echocardiography or CMR.
Cardiac masses	No myxoma or cardiac tumor on echocardiography or CMR.
Cardiac tamponade	No pericardial effusion on echocardiography or CMR or signs.
Pulmonary hypertension	Other than RV dilation, no other signs of pulmonary hypertension on echocardiography or CMR.
Pulmonary embolism	Besides RV dilation, no other signs of pulmonary embolism echocardiography or CMR.
<b>Neurally mediated (reflex) syncope</b>	
Situational	Clear cardiac pathology and relation with exercise make cardiac cause more likely.
Vasovagal	Clear cardiac pathology and relation with exercise make cardiac cause more likely.
Micturition	Syncope episodes had no relation with micturition.
Carotid sinus syndrome/hypersensitivity	Clear cardiac pathology makes cardiac cause more likely.
<b>Orthostatic hypotension syncope</b>	
Postural tachycardia syndrome	No relation of syncope with posture.
Drug-induced hypotension	No drug or substance usage in history.
Autonomic failure	No signs of orthostatic hypotension.
Volume depletion	No history of fluid loss or dehydration.

ARVC = arrhythmogenic right ventricular cardiomyopathy; CMR = cardiac magnetic resonance imaging; CPVT = catecholaminergic polymorphic ventricular tachycardia; DCM = dilated cardiomyopathy; HCM = hypertrophic (obstructive) cardiomyopathy; LGE = late gadolinium enhancement; LV = left ventricle; LVOT = left ventricular outflow tract; NB = nota bene; PVC = premature ventricular complex; RV = right ventricle; RVOT = right ventricular outflow tract; VT = ventricular tachycardia.

**FIGURE 1** Electrocardiographic and CMR Evaluation



**(A)** ECG at presentation shows a right heart axis (+128°), T-wave inversions in leads V<sub>1</sub> to V<sub>4</sub> and flattened T waves in the inferior leads. **(B)** ECG during follow-up shows an incomplete right bundle branch block, fragmented QRS in V<sub>1</sub> to V<sub>3</sub> and T-wave inversions in leads V<sub>1</sub> to V<sub>5</sub>. **(C)** Holter registration of NSVT (arrow). **(D)** CMR 4-chamber image with multifocal LGE in the septum and lateral LV wall. **(E)** CMR short-axis image with multifocal LGE in the septum and inferior RV wall. CMR = cardiac magnetic resonance; ECG = electrocardiography; LGE = late gadolinium enhancement; LV = left ventricle; NSVT = nonsustained ventricular tachycardia; RV = right ventricle.

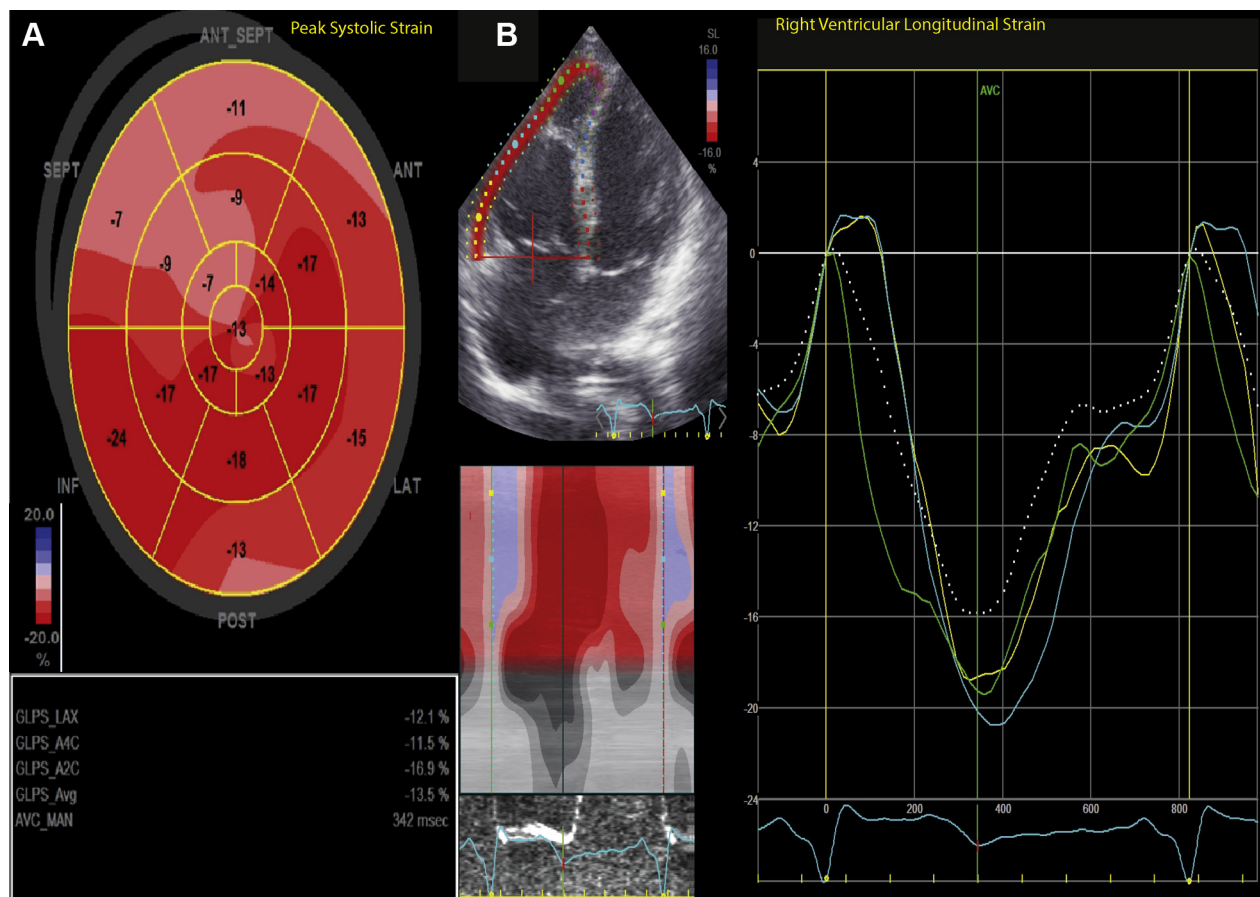
fulfilled as no right ventricular (RV) wall motion abnormalities were present. However, deformation imaging using speckle tracking indicated biventricular dysfunction (Figures 2 and 3). RV subtricuspid strain showed systolic pre-stretch, as may be observed in adult ARVC (1). Global longitudinal strain was significantly reduced in both the LV (−13.5%; normal: >−18.5%) and RV (−20.0%; normal: >−26.5%).

**CARDIAC MAGNETIC RESONANCE IMAGING.** Cardiac magnetic resonance (CMR) confirmed biventricular dilation and dysfunction (LV indexed end-diastolic volume [EDV]: 104 ml/m<sup>2</sup> and LVEF of 49%; RV EDV: 117 ml/m<sup>2</sup>; and RVEF: 36%) (Figure 1, Video 2). Akinesia was observed in the inferior RV and RV outflow tract which resulted in a major criterion for ARVC. T2-weighted images showed no myocardial

edema suggestive of myocarditis. Epicardial patchy late gadolinium enhancement was present in the LV, midwall septum, extending to the inferior RV.

**MISCELLANEOUS.** Laboratory examinations, chest radiography, and ophthalmological examination (Tables 1 and 2) did not yield a specific diagnosis.

**DIAGNOSTIC CONFIRMATION BY GENETIC TESTING.** ARVC with LV involvement was thought to be more likely than dilated cardiomyopathy (DCM) due to the evident RV involvement and occurrence of episodes of ventricular arrhythmia in the early stages of the disease (Table 1). However, ARVC could not be definitively diagnosed during clinical evaluation because the 2010 TFC for ARVC were not fulfilled (Table 3) (2).

**FIGURE 2** Echocardiographic Deformation Imaging of RV and LV

**(A)** Bull's-eye plot with regional myocardial dysfunction (basal, midventricular septal, and anteroseptal segments). LV GLS was moderately affected (LV-GLS:  $-13.5\%$ ; normal: 5% to 95% range:  $-18.4\%$  to  $-23.6\%$ ) (9). **(B)** RV strain imaging demonstrated significant impairment of the RV free wall (global:  $-19.5\%$ ) with abnormal presystolic stretch of the basal and midventricular segments (white curve). Mean normal RV GLS is  $-29.0\%$  (5% to 95% range:  $-26.5\%$  to  $-31.5\%$ ) (10). The subtricuspid segment showed the lowest segmental longitudinal RV strain value (yellow curve:  $-18.9\%$ ). GLS = global longitudinal strain; other abbreviations as in Figure 1.

Genetic testing confirmed the diagnosis of ARVC. The patient was heterozygous for 2 plakophilin (*PKP2*) variants, c.397C>T, p.(Gln133\*), classified as pathogenic, and c.2615C>T, p.(Thr872Ile), classified as variants of unknown significance; and 1 pathogenic desmoglein (*DSG2*) variant (c.1003A>G, p.(Thr335Ala)). Cascade screening confirmed ARVC diagnosis in her asymptomatic mother (age 44 years) who carried both *PKP2* variants and had T-wave inversions in V<sub>1</sub> to V<sub>3</sub>, and a major CMR criterion. The mother of the patient was treated with sotalol and received a primary prophylactic implantable cardioverter-defibrillator (ICD). The girl's asymptomatic father (age 50 years) carried the *DSG2*

variant and had normal cardiac evaluation (including an ECG, an echocardiogram, and CMR).

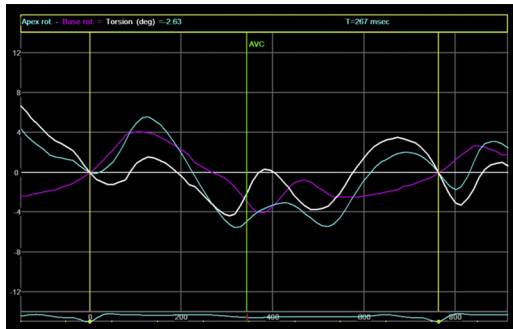
### MANAGEMENT

The patient was started on sotalol therapy to suppress her symptomatic ventricular arrhythmia episodes and spironolactone to prevent further adverse ventricular remodeling. She was advised to avoid competitive sports. A subcutaneous ICD was implanted before she was discharged (3).

### DISCUSSION

ARVC is rarely diagnosed before adolescence, and the diagnostic TFC are not validated for use in pediatric

**FIGURE 3** LV Rotational Mechanics Using Echocardiographic Deformation Imaging



Reversed apical rotation (clockwise rotation, turquoise curve) with subsequent loss of normal LV twist (white curve). The pattern of rotation was identical for both base and apex (rigid body rotation).

**TABLE 2** Laboratory Test Results

Hemoglobin	7.9 mmol/l
Leucocytes	$6.7 \times 10^9/l$
Angiotensin-converting enzyme	17.3 U/l
Erythrocyte sedimentation rate	4 mm/h
Serum amyloid A	2.9 mg/l
Troponin T	11 ng/l
NT-proBNP	670 pg/ml
Interleukin-2 receptor	409 U/ml
Thyroid-stimulating hormone	2.32 mE/l
Free T4	13.8 pmol/l
Cytomegalovirus	Negative IgG and IgM
Adenovirus	Negative IgG
Enterovirus	Negative serology
Influenza A and B	Negative IgG
Mycoplasma pneumoniae	Negative IgG and IgM
Parvovirus	IgG positive and IgM negative
Coxiella burnetii	Negative IgG
Borrelia burgdorferi	Negative IgG and IgM

IgG = immunoglobulin G; IgM = immunoglobulin M; NT-proBNP = N-terminal pro-B-type natriuretic peptide.

cohorts (4,5). The case presented here emphasizes the limitations of the TFC in children and highlights opportunities for improvement.

#### LOW SENSITIVITY OF THE TFC IN PEDIATRIC PATIENTS.

The diagnostic TFC were developed in a predominantly adult cohort (2). To deal with this limitation, repolarization abnormalities were excluded from the TFC in children <14 years of age. Of note, CMR cutoff values were based on a comparison between adult ARVC probands and controls, the implications of which for pediatric ARVC evaluation remains unknown (2,6). The present case illustrates the fact that the TFC are relatively insensitive for pediatric diagnosis, and future studies should focus on validation in pediatric cohorts and development of imaging criteria specific for children (3).

#### LOW SENSITIVITY OF IMAGING CRITERIA IN EARLY ARVC.

In this patient, both echocardiography and CMR were suggestive of ARVC, but only CMR provided a major criterion for ARVC diagnosis. This is not unexpected, as echocardiography is less sensitive for ARVC evaluation than CMR (7). However, this case illustrates the fact that echocardiographic deformation imaging may unmask the abnormal structural substrate, suggesting a possible role in screening for ARVC.

**BIVENTRICULAR INVOLVEMENT IN ARVC.** Left ventricular involvement is well recognized in ARVC and leads to diagnostic overlap with DCM. Indeed, this

patient clearly had biventricular involvement and, hence, should be regarded as spanning the spectrum between ARVC and DCM. Given the overlapping phenotypes, it seems important to be vigilant for arrhythmic risk and genetic causes in apparent DCM cases.

**GENOTYPE-PHENOTYPE CORRELATION.** Early development of ARVC in this pediatric case might have been influenced by variants in both the *PKP2* and the *DSG2* genes. Indeed, multiple pathogenic variants are associated with worse prognosis (8). In contrast, although exercise is a known environmental modifier of the ARVC phenotype, this patient did not participate in vigorous physical exercise.

**FOLLOW-UP.** During 2.5 years of follow-up, the patient did not experience syncope or ICD interventions, and the LVEF and RVEF were stable. Device interrogation revealed frequent episodes of nonsustained ventricular tachycardia (maximum: 160 beats/min) without requiring device therapy and a stable premature ventricular complex burden of 5% of QRS complexes.

#### CONCLUSIONS

This report provides detailed phenotypic information for a young girl carrying 2 pathogenic desmosomal variants. Albeit a diagnosis of ARVC is highly

TABLE 3 Task Force Criteria		
	Feature	Criterion and Points
Imaging criteria		
Echocardiography	No wall motion abnormalities RVOT PLAX 28.1 mm (indexed to BSA 24.0) and PSAX 23.7 mm (indexed to BSA 20.3), FAC 30.3%	No criterion, 0 points
Cardiac magnetic resonance	Regional wall motion abnormalities inferior and RVOT RV ejection fraction 36%, RV EDV 117 mL/m <sup>2</sup>	Major criterion, 2 points
Tissue characterization		
Endomyocardial biopsy	Not performed	-
Repolarization abnormalities		
ECG	T-wave inversions in V <sub>1</sub> to V <sub>4</sub>	Not appropriate, because <14 yrs of age
Depolarization abnormalities		
ECG	Normal TAD, no epsilon wave	-
SAECG	Not performed	-
Arrhythmia		
24-h Holter monitoring	>500 PVC/24 h and polymorphic non-sustained ventricular tachycardia	Minor criterion, 1 point
Exercise test	PVC with LBBB morphology, no ventricular tachycardia	-
Family history		
Genetic analysis	Identification of a pathogenic ARVC related variant	Major criterion, 2 points
Family history of sudden death or ARVC	No 1st- or 2nd-degree family members with cardiomyopathy or sudden cardiac death	-
Total Task Force Points		5 points
BSA = body surface area; ECG = electrocardiogram; EDV = end diastolic volume; FAC = fractional area change; LBBB = left bundle branch block; PLAX = parasternal long axis; PSAX = parasternal short axis; SAECG = signal averaged electrocardiogram; TAD = terminal activation duration; other abbreviations as in Table 1.		

likely to explain her symptoms, the data highlight the fact that the diagnostic TFC have low sensitivity for disease among children. Echocardiographic deformation imaging may have added value for ARVC screening.

**ADDRESS FOR CORRESPONDENCE:** Dr. Anneline S.J.M. te Riele, University Medical Center Utrecht, Heidelberglaan 100, 3508 GA, Utrecht, the Netherlands. E-mail: [ariele3@umcutrecht.nl](mailto:ariele3@umcutrecht.nl).

## REFERENCES

- Mast TP, Teske AJ, Walmsley J, et al. Right ventricular imaging and computer simulation for electromechanical substrate characterization in arrhythmogenic right ventricular cardiomyopathy. *J Am Coll Cardiol* 2016;68:2185-97.
- Marcus FI, McKenna WJ, Sherrill D, et al. Diagnosis of arrhythmogenic right ventricular cardiomyopathy/dysplasia: proposed modification of the task force criteria. *Circulation* 2010;121:1533-41.
- Towbin JA, McKenna WJ, Abrams DJ, et al. 2019 HRS expert consensus statement on evaluation, risk stratification, and management of arrhythmogenic cardiomyopathy. *Heart Rhythm* 2019;16:e373-407.
- DeWitt ES, Chandler SF, Hylind RJ, et al. Phenotypic manifestations of arrhythmogenic cardiomyopathy in children and adolescents. *J Am Coll Cardiol* 2019;74:346-58.
- Te Riele A, James CA, Sawant AC, et al. Arrhythmogenic right ventricular dysplasia/cardiomyopathy in the pediatric population: clinical characterization and comparison with adult-onset disease. *J Am Coll Cardiol EP* 2015;1:551-60.
- Maceira AM, Prasad SK, Khan M, Pennell DJ. Reference right ventricular systolic and diastolic function normalized to age, gender and body surface area from steady-state free precession cardiovascular magnetic resonance. *Eur Heart J* 2006;27:2879-88.
- Borgquist R, Haugaa KH, Gilljam T, et al. The diagnostic performance of imaging methods in ARVC using the 2010 Task Force criteria. *Eur Heart J Cardiovasc Imaging* 2014;15:1219-25.
- Bhonsale A, Groeneweg JA, James CA, et al. Impact of genotype on clinical course in arrhythmogenic right ventricular dysplasia/cardiomyopathy-associated mutation carriers. *Eur Heart J* 2015;36:847-55.
- Marcus KA, Mavinkurve-Groothuis AM, Barends M, et al. Reference values for myocardial two-dimensional strain echocardiography in a healthy pediatric and young adult cohort. *J Am Soc Echocardiogr* 2011;24:625-36.
- Levy PT, Sanchez Mejia AA, Machevsky A, Fowler S, Holland MR, Singh GK. Normal ranges of right ventricular systolic and diastolic strain measures in children: a systematic review and meta-analysis. *J Am Soc Echocardiogr* 2014;27:549-60.

**KEY WORDS** arrhythmogenic cardiomyopathy, arrhythmogenic right ventricular cardiomyopathy, deformation imaging, desmosomal mutations, genetic screening, pediatrics, ventricular tachycardia

**APPENDIX** For supplemental videos, please see the online version of this paper.