

Renal transplant patient survives a donor-derived abdominal invasive mucormycosis (*Lichtheimia ramosa*)

E.M. Spithoven^{a,*}, A.H.W. Bruns^b, B.J. Petri^c, P.J. Haas^d, T.Q. Nguyen^e, F. Hagen^{d,f}, A. D. van Zuilen^a

^a Department of Nephrology, Internal Medicine, University Medical Center Utrecht, Utrecht, the Netherlands

^b Department of Infectious Diseases, Internal Medicine, University Medical Center Utrecht, Utrecht, the Netherlands

^c Department of Vascular Surgery, Surgery Department, University Medical Center Utrecht, Utrecht, the Netherlands

^d Department of Medical Microbiology, University Medical Center Utrecht, Utrecht, the Netherlands

^e Department of Pathology, University Medical Center Utrecht, Utrecht, the Netherlands

^f Department of Medical Mycology, Westerdijk Fungal Biodiversity Institute, Utrecht, the Netherlands

ARTICLE INFO

Keywords:

mucormycosis
Renal transplant
Interferon gamma
Survival

ABSTRACT

Mucormycosis is a life-threatening invasive fungal infection, most commonly described in severely immunocompromised patients. It is characterized by rapid invasive growth of the fungus and often with fatal outcome. We report a case of a renal transplant recipient diagnosed with a donor-derived invasive mucormycosis. In this patient, we used a step-wise approach of withdrawal of immunosuppressants, antifungal induction therapy, extensive surgical debridement of all (potentially) infected tissue, abdominal irrigation of liposomal amphotericin B and interferon gamma. Due to rapid diagnosis and intensive therapy the patient survived.

1. Introduction

Mucormycosis is a rare but severe invasive fungal infection with mortality rates up to 96–100% in disseminated disease. Mucormycosis is mainly seen in severely immunocompromised patients and characterized by rapid invasive growth of the fungus. Here, we report a donor-derived invasive mucormycosis infection in a renal transplant patient.

1.1. Case report

A 38-year old male patient on peritoneal dialysis with a medical history of end-stage renal disease due to bilateral kidney hypoplasia and two failed kidney transplants (2000 implanted on the right and 2006 implanted on the left side and removed in 2015) was admitted to receive a renal transplant in the left iliac fossa of a brain death donor. His immunosuppressive regimen consisted of basiliximab, tacrolimus, mycophenolate mofetil and glucocorticoids. Thirteen days after transplantation he was readmitted due to acute kidney failure. Methylprednisolone was administered based on a provisional diagnosis of rejection. Subsequently a kidney biopsy was performed. The biopsy showed thick hyphae without segmentation suspected for Mucorales in blanchophor

staining (17 days after transplantation) (Fig. 1). Positron-Emission-Tomography showed no evidence of hematological spread of the suspected mucormycosis. Combination antifungal therapy with liposomal Amphotericin B (L-AmB) (intravenous 5mg/kg) and posaconazole (oral 400mg b.i.d. TDM guided with 3mg/L) was started and all immunosuppressive agents were discontinued (cumulative prednisone 3 g). The next day (day 18), nephrectomy of the graft was performed. Pathology of the explanted kidney showed acute purulent, necrotizing inflammation with extended hyphae throughout the kidney (Fig. 2). The biopsy was subjected to a pan-Mucorales qPCR [1] that became positive, subsequent pan-fungal PCR targeting the ITS region resulted in the identification of the Mucorales as *Lichtheimia ramosa* (Genbank accession number MW012945). His postoperative recovery was complicated by progressive growth of the mucormycosis into the abdominal cavity, bladder and the old kidney graft in the right iliac fossa. A second surgical debridement with nephrectomy of the old graft was performed.

Postoperatively, intravenous L-AmB and posaconazole were continued. Additionally intraperitoneal irrigation of L-AmB through abdominal catheters was applied daily and left for 4 h in the peritoneal cavity. To stimulate the host immune response interferon gamma 100mcg (cumulative dose 600 mcg) was administered subcutaneously

* Corresponding author. Department of Nephrology, Internal Medicine, University Medical Center Utrecht Heidelberglaan 100, 3584 CX Utrecht, the Netherlands.
E-mail address: e.m.spithoven-2@umcutrecht.nl (E.M. Spithoven).

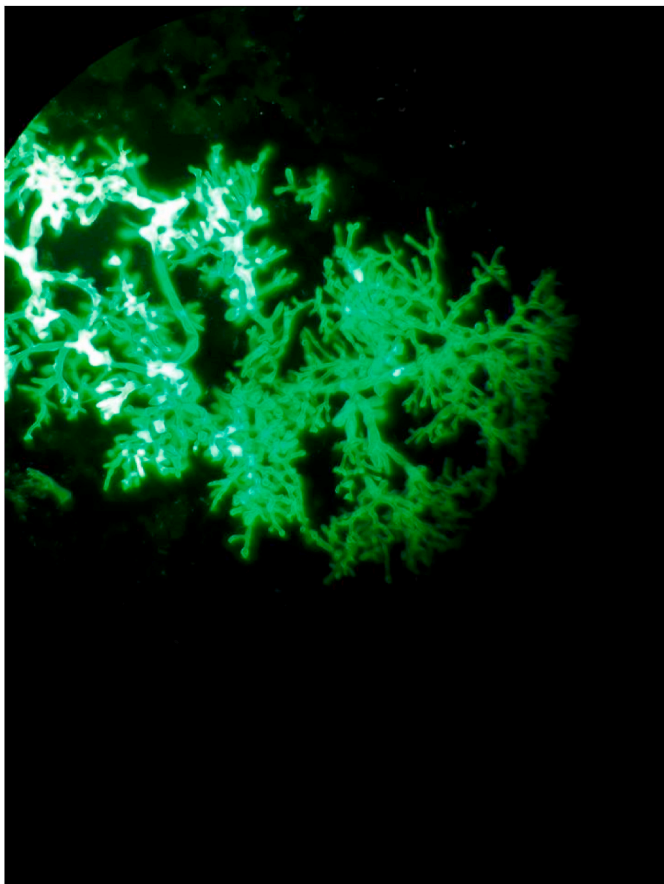


Fig. 1. The hyphae are broad, irregularly branched, and are sparsely septated, typically for mucormycosis.

six times during 14 days.

At day 57, the patient suffered from increased pain in the right psoas area. Computer-tomography showed an abscess. Cultures yielded a carbapenem resistant *Enterobacter cloacae* additionally fungal growth

was observed. Meropenem and amikacine were added to the antimicrobial regimen.

At day 98 post-transplant the patient underwent a final major surgical procedure. In this procedure, all potentially infected tissue, the subsplenic pus collection together with the complete peritoneum and his bladder were removed. Tissue surrounding the former graft location including segments of the iliac artery and vein appeared dusky and were stripped. A venous bleeding occurred and hemostasis was obtained by placement of a venous patch. Mucorales DNA was repetitively detected in the abdominal cavity intraoperatively. We therefore instituted a continuous dwell of the abdominal cavity (5L L-AmB 200mg/L) with L-AmB for 3 days postoperatively. Dwelling the complete abdominal cavity with L-AmB was only possible when patient had complete muscle relaxation on ventilator support. After 110 days, L-AmB (cumulative dosage 58,5 g) and posaconazole were switched to isavuconazole (200mg q.d.). During this period he suffered from several episodes of abdominal abscesses, due to a persistent *Enterobacter cloacae* superinfection. Treatment with meropenem-amikacin i.v. and later on ceftazidime-avibactam i.v. was initiated. At day 155, both infections were controlled and patient was discharged to a rehabilitation centre.

At day 625 the computer tomography showed no inflammation around the infected patch and ceftazidime-avibactam (cumulative dosage 480gr/120gr) prophylaxis was stopped. At day 797 positron emission tomography showed no inflammation and isavuconazole was stopped (cumulative dosage 143 gr). Despite all complications, currently 29 months after transplantation and intensive revalidation the patient is alive, at home and on hemodialysis again.

The donor was a young man admitted to the ICU after a fall in a slurry pit. He donated his liver, pancreas and two kidneys. His colleague fell in the same slurry pit and survived. A culture from the bronchoalveolar lavage taken from his colleague identified the presence of *Lichtheimia ramosa*. Because the short interval between the occurrence of the mucormycosis in renal transplant, the primary localization of the mucormycosis therein, and the same species identified in BAL samples of the colleague, we concluded a very high likelihood of donor-derived mucormycosis. The other organ recipients had no signs or diagnosis of a mucormycosis.

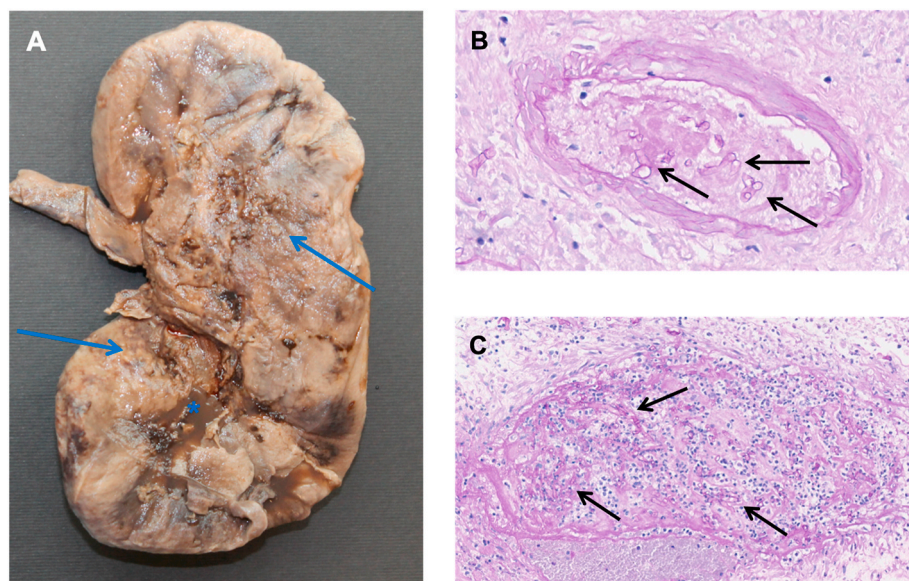


Fig. 2. A resection specimen of the infected kidney transplant. Gross inspection of the specimen showed extensive areas with necrosis (arrows) and purulent fluid (asterisk) (A). Histological examination (PAS stain) showed acute purulent, necrotizing extended inflammation with localization of thick hyphae, consistent with mucormycosis, in arteries (B) and veins (C).

2. Discussion

We report a donor-derived abdominal mucormycosis in a renal transplant patient successfully treated with vigorous antifungal therapy and surgical debridement. In addition to pathology, per-operative pan-Mucorales qPCR was performed on abdominal tissue indicating abdominal spread of the *Lichtheimia ramosa* infection. We applied a step-wise approach with antifungal induction therapy, extensive surgical debridement of all (potentially) infected tissue, abdominal irrigation of L-AmB and interferon gamma to treat this patient.

Mucormycosis is a severe and rapidly progressive fungal infection caused by members of the genera *Mucor*, *Rhizopus*, *Rhizomucor*, and *Lichtheimia* in the order Mucorales. Recently, Pan et al. reviewed all published cases on infections caused by *Lichtheimia* in humans [2]. Mucormycosis is a rare complication of solid organ transplantation associated with use of immunosuppression. The incidence of mucormycosis in renal transplant recipients was 0.4–0.5 per 1000 patients [3]. The median time to diagnosis was 2.5 months (range 2 days–20 years) post renal transplantation. Donor-derived mucormycosis has rarely been reported, with 8 cases known so far [4–9]. The mucormycosis manifested early with massive involvement of the transplanted kidney, without evidence of the portal entry. Only two patients survived. Alexander and colleagues reported two patients who developed renal mucormycosis following kidney transplantation originating from the same donor who deceased after a near-drowning in a motor vehicle crash [9].

In our case the donor died due to a fall into a slurry pit. Our recipient was the only one of four recipients receiving an organ from this donor to contract mucormycosis. Currently there is insufficient information to adequately estimate the changes of contracting such an infection after ingesting water possibly contaminated with a high dose of fungi. It is therefore not possible to decide upfront whether anyone experiencing this would be a suitable donor. Given the shortage of donors and the still occurring waitlist mortality on the one hand and the seriousness of the consequences of a fungal infection on the other hand careful weighing of these risks and benefits should be performed for every single possible recipient. It seems prudent to regard organs from donors who have been exposed to contaminated water as high risk for donor derived infectious complications. In case of complications after transplantation, the transplant physician should consider infectious complication including fungal infections like mucormycosis. Of note, it is unknown how many organs are transplanted from donors, who were extensively exposed to contaminated water.

There are several methods to diagnose Mucorales infections. First, periodic-acid-schiff staining shows hyphae by light microscopy. In our case, initial histopathological evaluation missed the hyphae. The hyphae have distinct features that differentiate them from other clinically relevant fungi. As Mucorales hyphae are broad (5–15 µm in diameter), irregular branched, and sparsely septated. Histopathology specimens show acute suppurative inflammation with focal areas of granuloma formation. In our case, this was observed. Due to the infrequent occurrence of mucormycosis and similar histopathology findings that can be seen in an ascending bacterial urinary tract infection, a fungal infection of the transplant did not immediately cross the mind. Mucormycosis characteristically invades the walls of adjacent blood vessels, causing thrombosis and consequently infarction. It rarely disseminates through the vessels, but easily invades the surrounding tissue. Mucormycosis is difficult to culture due to the lack of regular septation, causing fragile hyphae, which easily leak. Molecular diagnostics using qPCR with additionally pan-fungal PCR and sequencing is essential for identifying causative species when histopathology is positive and cultures remain negative.

One should immediately reduce the immunosuppressive regimen to the absolute possible minimum. Of note, immune suppressive effects of corticosteroids may last up to 3 months [10].

L-AmB (5mg/kg) is considered the primary drug of choice [11].

Conflicting data are available regarding posaconazole. Posaconazole has no in vitro activity against all Mucorales species, resistance is more likely to occur as compared to L-AmB [12,13]. Two trials reported that posaconazole was successfully as salvage therapy in patients refractory to L-AmB [14,15]. Rodriguez et al. showed in a murine model of disseminated mucormycosis that low dose of amphotericin B combined with posaconazole was as effective as high dose amphotericin B [16]. In contrast, in mice the combination posaconazole with L-AmB therapy showed no survival benefit compared to monotherapy L-AmB [17]. Furthermore, Kyvernitis et al. showed that initial use of combination treatment does not impact survival in hematological malignancies or mucormycosis [18]. In addition, combination therapy may lead to additional toxicity, drugs interactions and costs. In the recent guideline [11], surgical debridement with immediate additional treatment with L-AmB is recommended. When progressive disease is noticed after response assessment, an increased dosage of L-AmB or combination with posaconazole is advised.

Rapid progression, the extend of the infection into abdominal wall, urinary structures, and non-functional transplant together with variable tissue kinetics raises concerns on the tissue penetration of intravenous L-AmB [19]. We therefore added posaconazole. Marty et al. showed that isavuconazole has similar efficacy as L-AmB against mucormycosis [20].

Lichtheimia ramosa is generally susceptible for L-AmB and isavuconazole with wildtype MIC ranges of <0.03 for L-AmB and 0.125–0.5 for isavuconazole [21]. Although no clinical susceptibility breakpoints are defined for mucormycosis these susceptibility ranges are below the achievable serum concentrations. Also intravenously administrated L-AmB moderately penetrates in the peritoneal fluid with a peritoneal cavity to serum ratio of 0.4–0.52 [22]. To improve drug penetration in the peritoneal cavity, we additionally instilled the abdominal cavity with L-AmB (200 mg/L in glucose 5%). A total of 5Litre L-AmB was instilled three times daily for three days. We instilled the L-AmB 4 h in order to achieve the highest concentrations in the surrounding tissue. L-AmB has rapid, concentration dependent fungicidal activity [23].

Immunity against fungi is depended on both innate and adaptive immunity. The patient was at the moment of diagnosis on mycophenolate mofetil, tacrolimus and high dose of glucocorticoids because of the initial diagnosis of rejection. The immunosuppressive effect of glucocorticoids is determined by several mechanisms; the reduction of phagocytic function of macrophages and neutrophils, suppression of pro-inflammatory cytokines (TNF and IL-1), impairment of neutrophil migration and decrease of T lymphocytes [10]. The antiproliferative agent mycophenolate mofetil and the calcineurin inhibitor tacrolimus also target T lymphocytes. Present immunosuppressive regimen impairs the interferon gamma driven response to fungal pathogens. Interferon gamma is normally produced by NK-cells and T-cells and stimulate macrophages [24]. Interferon gamma stimulates the antifungal activities of effector cells. Several case-series suggested beneficial effects of exogenous interferon gamma for fungal infections [25,26]. We therefore added interferon gamma therapy (100mcg trice a week during 14 days subcutaneous) subcutaneously to the antifungal therapy.

Immediate surgical response is necessary as soon as the diagnosis of mucormycosis is suspected. The infected organ and infected surrounding soft tissue should be removed. In our case, within 24 hours after diagnosis, the infected kidney transplant was removed. Perioperatively, no surrounding soft tissue appeared to be infected. Perioperatively, one might consider to dwell the area with L-AmB as “prophylaxis”. After nephrectomy, our patient underwent two additional surgical procedures to remove infected tissue including the bladder, the dysfunctional graft in the right fossa and all peritoneum.

No antigen tests are available for detecting Mucorales. Duration of treatment was eventually determined by repetitive radiological evaluation using PET-CT scan [11]. The Mucorales qPCR on blood is not considered a good marker for follow-up of disease activity.

3. Conclusion

Here we report a case of a donor-derived invasive *Lichtheimia ramosa* infection in a renal transplant recipient with a successful outcome. A fast diagnosis, withdrawal of immunosuppressants, antifungal combination therapy, immunotherapy with interferon gamma, extensive surgical debridement and management of bacterial superinfections have all been part of the therapeutic approach and contributed to the successful outcome.

References

- [1] L. Irinyi, C. Serena, D. Garcia-Hermoso, M. Arabatzis, M. Desnos-Ollivier, D. Vu, et al., International Society of Human and Animal Mycology (ISHAM)-ITS reference DNA barcoding database—the quality controlled standard tool for routine identification of human and animal pathogenic fungi, *Med. Mycol.* 53 (4) (2015 May) 313–337.
- [2] J. Pan, C. Tsui, M. Li, K. Xiao, G.S. de Hoog, P.E. Verweij, et al., First case of rhinocerebral mucormycosis caused by *Lichtheimia ornata*, with a review of *Lichtheimia* infections, *Mycopathologia* 185 (3) (2020 Jun) 555–567.
- [3] N.G. Almyroudis, D.A. Sutton, P. Linden, M.G. Rinaldi, J. Fung, S. Kusne, Zygomycosis in solid organ transplant recipients in a tertiary transplant center and review of the literature, *Am. J. Transplant.* 6 (10) (2006 Oct) 2365–2374.
- [4] Z. Armaly, E. Khankin, R. Ramadan, O. Ben-Itzhak, L. Guralnik, J. Green, et al., Two Cases of Renal Mucormycosis in Renal Transplanted Patients, vol. 58, *Clinical nephrology*. Germany, 2002, pp. 247–249.
- [5] A. Chkhotua, A. Yussim, A. Tovar, M. Weinberger, V. Sobolev, N. Bar-Nathan, et al., Mucormycosis of the renal allograft: case report and review of the literature, *Transpl. Int.* 14 (6) (2001 Dec) 438–441.
- [6] A. Mitwalli, G.H. Malik, J. al-Wakeel, H. Abu Aisha, S. al-Mohaya, A. al-Jaser, et al., Mucormycosis of the graft in a renal transplant recipient, *Nephrol. Dial. Transplant.* 9 (6) (1994) 718–720.
- [7] M.R. Nampoory, Z.U. Khan, K.V. Johnny, J.N. Constandi, R.K. Gupta, I. Al-Muzairi, et al., Invasive fungal infections in renal transplant recipients, *J. Infect.* 33 (2) (1996 Sep) 95–101.
- [8] K.J. Stas, P.G. Louwagie, B.J. Van Damme, W. Coosemans, M. Waer, Y. F. Vanrenterghem, Isolated zygomycosis in a bought living unrelated kidney transplant, *Transpl. Int.* 9 (6) (1996) 600–602.
- [9] B.D. Alexander, W.A. Schell, A.M. Siston, C.Y. Rao, W.A. Bower, S.A. Balajee, et al., Fatal *Apophysomyces elegans* infection transmitted by deceased donor renal allografts, *Am. J. Transplant.* 10 (9) (2010 Sep) 2161–2167.
- [10] W.W. Chatham, R.P. Kimberly, Treatment of lupus with corticosteroids, *Lupus* 10 (3) (2001) 140–147.
- [11] O.A. Cornely, A. Alastruey-Izquierdo, D. Arenz, S.C.A. Chen, E. Dannaoui, B. Hochegger, et al., Global guideline for the diagnosis and management of mucormycosis: an initiative of the European confederation of medical mycology in cooperation with the mycoses study group education and research consortium, *Lancet Infect. Dis.* 19 (12) (2019 Dec) e405–e421.
- [12] R.E. Lewis, N.D. Albert, D.P. Kontoyiannis, Comparative pharmacodynamics of posaconazole in neutropenic murine models of invasive pulmonary aspergillosis and mucormycosis, *Antimicrob. Agents Chemother.* 58 (11) (2014 Nov) 6767–6772.
- [13] G. Luo, T. Gebremariam, H. Lee, S.W. French, N.P. Wiederhold, T.F. Patterson, et al., Efficacy of liposomal amphotericin B and posaconazole in intratracheal models of murine mucormycosis, *Antimicrob. Agents Chemother.* 57 (7) (2013 Jul) 3340–3347.
- [14] J.-A.H. van Burik, R.S. Hare, H.F. Solomon, M.L. Corrado, D.P. Kontoyiannis, R.N. Greenberg, K. Mullane, J.-A.H. van Burik, I. Raad, M.J. Abzug, G. Anstead, et al., Posaconazole as salvage therapy for zygomycosis, *Antimicrob. Agents Chemother.* 50 (1) (2006 Jan) 126–133.
- [15] J.-A.H. van Burik, R.S. Hare, H.F. Solomon, M.L. Corrado, D.P. Kontoyiannis, Posaconazole is effective as salvage therapy in zygomycosis: a retrospective summary of 91 cases, *Clin. Infect. Dis.* 42 (7) (2006 Apr) e61–e65.
- [16] M.M. Rodríguez, C. Serena, M. Mariné, F.J. Pastor, J. Guarro, Posaconazole combined with amphotericin B, an effective therapy for a murine disseminated infection caused by *Rhizopus oryzae*, *Antimicrob. Agents Chemother.* 52 (10) (2008 Oct) 3786–3788.
- [17] A.S. Ibrahim, T. Gebremariam, J.A. Schwartz, J.E.J. Edwards, B. Spellberg, Posaconazole mono- or combination therapy for treatment of murine zygomycosis, *Antimicrob. Agents Chemother.* 53 (2) (2009 Feb) 772–775.
- [18] A. Kyvernitakis, H.A. Torres, Y. Jiang, G. Chamilos, R.E. Lewis, D.P. Kontoyiannis, Initial use of combination treatment does not impact survival of 106 patients with hematologic malignancies and mucormycosis: a propensity score analysis, *Clin Microbiol Infect Off Publ Eur Soc Clin Microbiol Infect Dis* 22 (9) (2016 Sep) 811.e1–811.e8.
- [19] I. Bekersky, R.M. Fielding, D.E. Dressler, J.W. Lee, D.N. Buell, T.J. Walsh, Pharmacokinetics, excretion, and mass balance of liposomal amphotericin B (AmBisome) and amphotericin B deoxycholate in humans, *Antimicrob. Agents Chemother.* 46 (3) (2002 Mar) 828–833.
- [20] F.M. Marty, L. Ostrosky-Zeichner, O.A. Cornely, K.M. Mullane, J.R. Perfect, G. R. Thompson 3rd, et al., Isavuconazole treatment for mucormycosis: a single-arm open-label trial and case-control analysis, *Lancet Infect. Dis.* 16 (7) (2016 Jul) 828–837.
- [21] M.C. Arendrup, R.H. Jensen, J. Meletiadis, Vitro activity of isavuconazole and comparators against clinical isolates of the Mucorales order, *Antimicrob Agents Chemother [Internet]* 59 (12) (2015/10/05. 2015 Dec) 7735. –42. Available from, <https://www.ncbi.nlm.nih.gov/pubmed/26438494>.
- [22] P.H.J. van der Voort, E.C. Boerma, J.P. Yska, Serum and intraperitoneal levels of amphotericin B and flucytosine during intravenous treatment of critically ill patients with *Candida peritonitis*, *J. Antimicrob. Chemother.* 59 (5) (2007 May) 952–956.
- [23] J. Adler-Moore, R.E. Lewis, R.J.M. Brüggemann, B.J.A. Rijnders, A.H. Groll, T. J. Walsh, Preclinical safety, tolerability, pharmacokinetics, pharmacodynamics, and antifungal activity of liposomal amphotericin B, *Clin Infect Dis [Internet]* 68 (2019), <https://doi.org/10.1093/cid/ciz064>. Supplement_4):S244–59. Available from.
- [24] K. Schroder, P.J. Hertzog, T. Ravasi, D.A. Hume, Interferon-gamma: an overview of signals, mechanisms and functions, *J. Leukoc. Biol.* 75 (2) (2004 Feb) 163–189.
- [25] D. Armstrong-James, I.A. Teo, S. Shrivastava, M.A. Petrou, D. Taube, A. Dorling, et al., Exogenous interferon-gamma immunotherapy for invasive fungal infections in kidney transplant patients, *Am. J. Transplant.* 10 (8) (2010 Aug) 1796–1803.
- [26] C.E. Delsing, M.S. Gresnigt, J. Leentjens, F. Preijers, F.A. Frager, M. Kox, et al., Interferon-gamma as adjunctive immunotherapy for invasive fungal infections: a case series, *BMC Infect. Dis.* 14 (2014) 166.