


The efficacy of corticosteroid-sparing immunomodulatory therapy in treating patients with central multifocal choroiditis

Evianne L.de Groot,  Ninette H. ten Dam-van Loon, Joke H.de Boer and Jeannette Ossewaarde-van Norel

Department of Ophthalmology, University Medical Center Utrecht, University of Utrecht, Utrecht, The Netherlands

ABSTRACT.

Purpose: To evaluate the efficacy of corticosteroid-sparing immunomodulatory therapy (IMT) in patients with recurrent and/or sight-threatening central multifocal choroiditis (MFC).

Methods: This was a retrospective cohort study in a tertiary uveitis centre including all patients with MFC who have been treated with IMT for at least 12 months. Clinical data and imaging results were collected regarding the period prior to the start of IMT and at 3, 6, 12 and – where available – 24 months after the start of IMT. Main outcome measure was the number of annual recurrences of choroiditis with or without active choroidal neovascularization before and after the start of IMT. Secondary outcomes were the percentage of patients with (steroid-free) remission and the median time between the start of IMT and (steroid-free) remission.

Results: Thirty-two patients (39 eyes) were included. At the start of IMT, none of the patients were in (steroid-free) remission. At 24 months, the probability of achieving remission and steroid-free remission was 88,5% and 50%, respectively. The median time to achieve remission and steroid-free remission was 21 and 83 weeks, respectively. In 17 patients (20 eyes) with available clinical data and imaging results for ≥ 12 months prior to the start of IMT, the mean number of recurrences/year decreased significantly from 1.40 ± 0.81 at baseline to 0.49 ± 0.47 ($p = 0.001$) after the start of IMT.

Conclusions: Preventive therapy with IMT should be considered in patients with recurrent and/or sight-threatening MFC to decrease the number of recurrences/year and to increase the prospects of achieving either remission or steroid-free remission.

Key words: corticosteroid-sparing therapy – DMARD – Immunomodulatory therapy – Immunosuppressive therapy – MFC – multifocal choroiditis – Multifocal choroiditis without panuveitis – PIC

Acta Ophthalmol. 2020; 98: 816–821

© 2020 The Authors. Acta Ophthalmologica published by John Wiley & Sons Ltd on behalf of Acta Ophthalmologica Scandinavica Foundation

This is an open access article under the terms of the Creative Commons Attribution-NonCommercial-NoDerivs License, which permits use and distribution in any medium, provided the original work is properly cited, the use is non-commercial and no modifications or adaptations are made.

doi: 10.1111/aos.14473

Introduction

Central multifocal choroiditis (MFC) is a rare form of noninfectious posterior uveitis most commonly seen in the second to fourth decade of life in Caucasian women with myopia. (Ahnood et al. 2017) Several subtypes of MFC have been described based on the phenotypic presentation, including punctate inner choroidopathy (PIC) and multifocal choroiditis without panuveitis, though they are considered to be slightly different clinical presentations of the same disease entity. The aetiology of these subtypes remains unclear, and no association with a systemic disease has been identified. (Ahnood et al. 2017) Symptoms of MFC can include metamorphopsia, floaters, decreased vision and scotoma. (Tavallali & Yannuzzi 2016) Moreover, patients typically develop numerous central choroidal spots that usually form atrophic scars, without signs of ocular inflammation. A common complication is the development of choroidal neovascularization (CNV) in – or adjacent to – one or more of these choroidal spots. (Kedhar et al. 2007; Baxter et al. 2013; Leung et al. 2014; Fung et al 2014) Fluorescein angiography (FA), indocyanine green angiography (ICG), optical coherence tomography (OCT) and optical coherence tomography angiography (OCTA) can be used in order to diagnose and monitor the disease (Figure 1). (Ahnood et al. 2017) The current treatment for MFC consists of systemic corticosteroids in the early

stage of the disease in order to control the inflammatory component; in the case of active CNV, this treatment can be combined with intravitreal injections of anti-vascular endothelial growth factor (anti-VEGF). (Barth et al., 2008; Parodi et al. 2013; Niederer et al. 2018; Chen et al. 2019) Corticosteroid-sparing immunomodulatory therapy (IMT) is widely used for treating noninfectious uveitis to achieve disease control and minimize corticosteroid-related side-effects. (Jabs et al. 2000; Galor et al. 2008; Niederer et al. 2018; Dick et al. 2018; Jabs 2018) Recently, the inflammatory component was proposed to trigger the onset and growth of CNV in MFC, suggesting that IMT such as methotrexate and mycophenolate mofetil may be used as a preventive treatment for MFC. (Ahnood et al. 2017) To date, however, the potential value of using IMT in central MFC has been investigated in retrospective case studies involving only small cohort sizes. (Turkcuoglu et al. 2011; Goldberg et al. 2014) Therefore, the aim of this study was

to retrospectively evaluate the effect of IMT in a relatively large group of patients with central MFC.

Patients and Methods

This study was performed in accordance with the tenets of the Declaration of Helsinki regarding research involving human subjects and approved by the University Medical Center Utrecht institutional review board.

Study population

This retrospective cohort study was performed at the University Medical Center (UMC) Utrecht in Utrecht, the Netherlands. We included patients presenting with idiopathic central choroiditis who were treated for at least 12 months with IMT. Central multifocal choroiditis was diagnosed in case of the presence of idiopathic punctate choroidal or chorioretinal spots or punched-out lesions within the temporal vascular arcades without

signs of intraocular inflammation. In addition, patients who were treated consecutively with more than one immunosuppressive drug were included only if at least one agent was administered for at least three consecutive months. We excluded patients who were diagnosed with an infectious cause of uveitis (f.e. toxoplasmosis), birdshot chorioretinopathy, or had suspected systemic and/or ocular sarcoidosis; patients with anterior uveitis (based on the SUN criteria with a score > 0) (Jabs et al. 2005), ≥ 1 + vitreous cells (based on the National Health Institute grading system for vitreous cells) (Nussenblatt et al. 1985), retinal vasculitis, and/or papillitis; and eyes with a best-corrected visual acuity (BCVA) (LogMAR) of 20/1200 (1.79) or worse. Secondly, we excluded patients who were treated with IMT for less than 12 months.

Data collection

Clinical data and imaging results were collected regarding the period from 1988 through 20 July 2018. Imaging modalities included FA-ICGA and SD-OCT (Spectralis HRA + OCT; Heidelberg Engineering, Heidelberg, Germany). Data were collected for the period prior to the start with IMT and at 3, 6, 12 and – where available – 24 months of follow-up after the start of IMT. Data regarding the patient's ophthalmic history prior to presentation at the UMC Utrecht were reviewed in selected cases in which recurrences were documented and all relevant imaging results were available. If this data were incomplete or inconclusive, this time period was not included in this study. In cases involving more than one immunosuppressive agent, all agents were included in the analysis. When a biological agent was added to the treatment regime, only the data regarding the period without treatment with the biological agent were used.

Outcome measures

Patients who were treated with IMT and ≤ 10 mg prednisolone and developed no new choroidal lesions, no growth of existing lesions, no new CNV site, or reactivation of an existing CNV site based on FA-ICG or SD-OCT imaging for at least 3 months

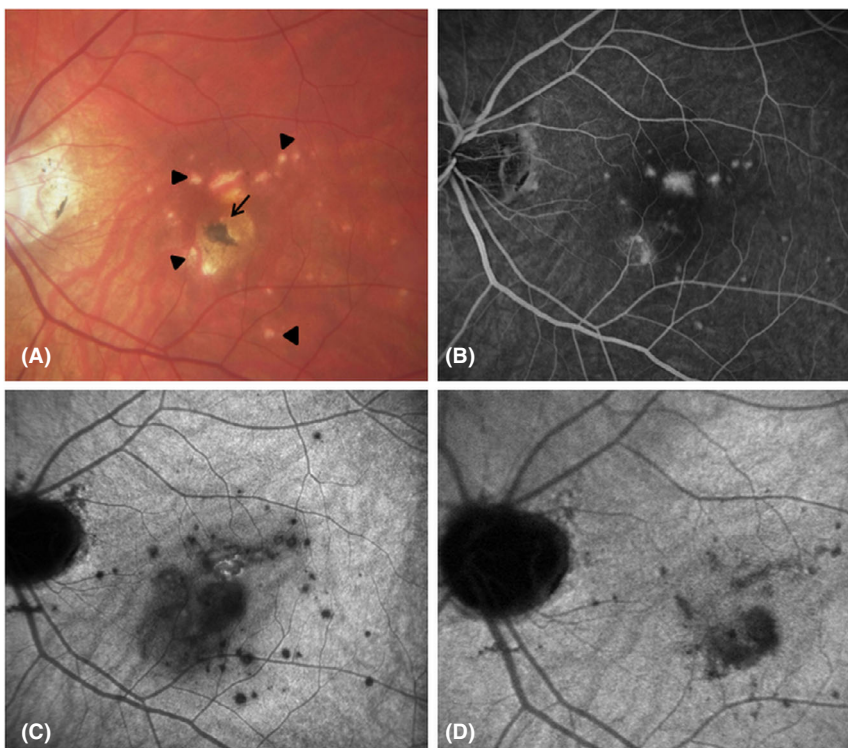


Fig. 1. Central multifocal choroiditis in the left eye. (A) Colour fundus photograph taken during an active stage of the disease, showing multiple spots in the posterior pole (arrowheads) and a hyperpigmented spot in the centre (arrow). (B) Fluorescein angiography image at 4 min during an active stage of the disease, showing leakage of multiple active CNV sites. (C) Indocyanine green angiography (ICGA) image at 31 min during an active stage of the disease, showing a hypodense area with vague boundaries corresponding with choroidal inflammation. (D) ICGA image at 31 min during an inactive stage of the disease, showing a reduction in the hypodense area with sharp boundaries.

were defined as being in remission. Steroid-free remission was defined as remission without treatment with steroids for at least 3 months. A recurrence of choroiditis was defined as the presence of new choroidal lesions or the growth of any existing choroidal lesions visible on OCT or FA-ICG after previous by imaging confirmed remission. A recurrence of CNV was defined as follows: (1a) dye leakage from an existing subretinal neovascular lesion visible on FA-ICG; or (1b) subretinal and/or intraretinal fluid visible on OCT; or (1c) evidence of a growing subretinal neovascular complex on OCT; and 2) CNV that had been documented previously as inactive based on imaging. Intraretinal fluid in the context of atrophic cysts due to scarring was left out of account.

The primary outcome was the difference between the number of recurrences/year measured before the start of IMT and the number of recurrences/year measured after the start of IMT. The number of recurrences was further classified as whether or not an active site of CNV was present. Because no statistical correction could be performed in patients with bilateral disease, the analysis was repeated by analysing only the first affected eye in the patients with bilateral disease. In addition, the following secondary outcomes were recorded: BCVA; the percentage of patients who achieved remission and the median time to achieve remission; the percentage of patients who achieved steroid-free remission and the median time to achieve steroid-free remission; the number of anti-VEGF injections/year before and after the start of IMT; the number of patients with treatment escalation to a combination of IMT and biologicals within 12 months of follow-up; the percentage of patients who received high-dose IMT at 24 months of follow-up; the percentage of patients who were treated with two immunomodulatory agents at 24 months of follow-up; and the percentage of patients who switched their type of immunomodulatory agent during follow-up. BCVA was converted to LogMAR (logarithm of the minimum angle of resolution) values for analysis, and is presented as both Snellen and LogMAR values.

The IMT was prescribed at standard doses (methotrexate: 15–20 mg/week,

mycophenolate mofetil: 2000 mg/day, mycophenolate sodium: 1440 mg/day and azathioprine: 1–3 mg/kg/day). A trough serum level of ≥ 0.10 mg/L was used for cyclosporine treatment. High-dose IMT was defined as follows: methotrexate > 20 mg/week, mycophenolate mofetil > 2000 mg/day, mycophenolate sodium > 1440 mg/day and azathioprine > 3 mg/kg/day.

Statistical analysis

All statistical analyses were performed using SPSS for Windows version 25.0 (IBM Corp., Armonk, NY, USA). The number of recurrences/year before and after the start of IMT was calculated by dividing the total number of recurrences in the given period by the total number of years in the given period and was compared using the Wilcoxon signed-rank test. Differences with a p -value ≤ 0.05 were considered significant. The probability to achieve (steroid-free) remission and the time to (steroid-free) remission was estimated using the Kaplan–Meier method.

Results

Baseline characteristics

A total of 34 patients with 48 affected eyes were identified. Two patients were excluded because IMT was discontinued within 12 months (in one patient due to side-effects and in one patient due to inefficacy). Of the remaining 32 patients and 44 eyes, five eyes of five patients with bilateral disease were excluded because the BCVA (LogMAR) was $\leq 20/1200$ (1.79) prior to the first presentation in the UMC Utrecht. Thus, a total of 39 eyes in 32 patients were included in the final analysis (Table 1). Of the 32 patients, 12 patients (36%) presented with bilateral disease. Thirty of the 32 patients (94%) were female. Seventeen of the 39 eyes (44%) had high myopia with a spherical equivalent (SE) over -6.0 dioptres (D), and 20 eyes (51%) had mild to moderate myopia with a SE up to -6.0 D. The mean (\pm SD) age at presentation was 33.4 ± 9.3 years (range: 21–56 years) (Table 1).

Annual recurrences

A total of 20 eyes (in 17 patients) had a follow-up period of at least 12 months

both before and after the start of IMT, and we determined the change in the mean number of recurrences/year of disease activity for these cases. In this group, the median follow-up period before IMT and after the start of IMT was 23 months (range: 14–256 months) and 59 months (range: 15–109 months), respectively. Data regarding recurrences prior to the first presentation in the UMC Utrecht were judged eligible for 3 patients; thus, these recurrences were included in the final analysis. When analysing 1 eye per patient, the mean (\pm SD) number of recurrences/year before the start of IMT was 1.40 ± 0.81 . After the start of IMT, this number was significantly lower (0.49 ± 0.47 ; $p = 0.002$). Our analysis of the number of recurrences/year is summarized in Table 2.

We also analysed the number of recurrences/year separately for choroiditis with active CNV and choroiditis without active CNV, revealing that the number of recurrences/year for choroiditis with active CNV decreased significantly after the start of IMT, from 0.73 ± 0.76 to 0.17 ± 0.25 ($p = 0.008$). In contrast, although the mean number of recurrences/year for choroiditis without active CNV decreased from 0.67 ± 0.68 to 0.32 ± 0.30 , this difference was not significant ($p = 0.234$). Similar results were obtained when all affected eyes were analysed (Table 2). The number of anti-VEGF injections decreased significantly when analysing one eye per patient, but this decrease lost its significance when analysing all affected eyes (Table 2).

Remission and steroid-free remission

Next, we measured the time between the start of IMT and (steroid-free) remission. The median time after the start of IMT to achieve remission and steroid-free remission was 21 and 83 weeks, respectively. At 2 years of follow-up, the probability of achieving remission and steroid-free remission was 88.5% and 50%, respectively (Figure 2). Mean Snellen BCVA (LogMAR) improved from 20/31 (0.19) at the start of IMT to 20/28 (0.15) at 3 months of follow-up and remained stable with a mean Snellen (LogMAR) BCVA of 20/27 (0.13) at 24 months of follow-up. In one patient, treatment was escalated to the combination of

Table 1. Patient characteristics (*n* = 32 patients)

Eyes, <i>n</i> *	39
Age at presentation in years, mean (range)	33.4 (18–56)
Female patients, <i>n</i> (%)	30 (94%)
CNV present prior to first consult†, <i>n</i> (%)	22 (56%)
BCVA at presentation, mean (range)	20/38 (20/400 – 20/9.4)
Bilateral disease, <i>n</i> (%)	12 (36%)
High myopia‡, <i>n</i> (%)	17 (44%)
BCVA ≤ 20/1200 (0.02) in one eye, <i>n</i> (%)	5 (16%)

BCVA = best-corrected visual acuity; CNV = choroidal neovascularization.

* Does not include the five eyes with a BCVA (LogMAR) ≤ 20/1200 (1.79).

† First consult refers to the first consult at UMC Utrecht.

‡ High myopia is defined as a spherical equivalent over –6 dioptres.

IMT and biological treatment within the first 12 months of follow-up. Twenty-three of the 32 patients had 24 months of follow-up. At 24 months of follow-up, 4/23 patients (17%) required two immunomodulatory agents in order to achieve remission, and an additional four patients (17%) required high-dose IMT. Moreover, in 15/32 patients (47%) the type of agent of IMT was switched within the first 24 months either because of treatment failure (i.e. no remission was achieved) or because the patient developed intolerable objective and/or subjective side-effects. In some cases, the dose of IMT could not be increased due to side-effects.

Discussion

In our opinion, treatment with IMT is recommended in patients with recurrent and/or sight-threatening central MFC in order to prevent cumulative damage from recurrent disease and to avoid corticosteroid-related side-effects. In this study, we accepted 10 mg/day of prednisolone as the

maximum maintenance dose, as suggested by guidelines. (Jabs et al. 2000; Dick et al. 2018).

Our retrospective analysis revealed a significant decrease in both the total number of recurrences/year and the number of recurrences/year of choroiditis with active CNV following the start of IMT. This finding is consistent with a previous report of 8 patients with recurrent PIC, which also found a significant reduction in the frequency of recurrences after starting mycophenolate mofetil therapy. (Turkcuoglu et al. 2011) A recent study documented a significant reduction of the risk of the development of a choroidal neovascular membrane in the subgroup of 14 patients treated with IMT before the development of CNV. (Niederer et al. 2018) Another study (Goldberg et al. 2014) evaluated the success of mycophenolate mofetil monotherapy in a cohort of 27 patients with various multifocal choroidopathies, including birdshot chorioretinitis, multifocal choroiditis with panuveitis and – relevant to our study – six patients with PIC; the authors

reported a 95% success rate after 2 years of follow-up. Success was defined as no disease activity while treated with ≤ 10 mg/day prednisolone. The 95% success rate is similar to our finding that the probability of achieving remission is 88.5% at 24 months of follow-up. Moreover, 21% of the patients required a second immunosuppressive agent in order to achieve remission, which is similar to our results in which 17% of patients required a second immunosuppressive agent. Twenty-four months after the start of IMT, mean BCVA (LogMAR) in our cohort was 20/27 (0.13), which is relatively high compared to other studies. (Kedhar et al. 2007; Turkcuoglu et al. 2011; Leung et al. 2014; Goldberg et al. 2014) This difference may be due to the relatively early detection and more timely treatment of the disease which is a result of increased awareness among ophthalmologists and/or improvements in retinal imaging over the past decade. In particular, the eye-tracking function on the Heidelberg SD-OCT and improved quality of the ICGA on the Heidelberg scanning laser ophthalmoscope (with reduced stray light compared to conventional ICG) provide a more accurate means of monitoring disease activity and recognizing a recurrence early, possibly resulting in better long-term visual acuity. In half of the patients, at least one year with multiple recurrences passed by before IMT was initiated. One could argue that this period is relatively long and earlier intervention should be considered in the future. This observance can be explained by the fact that for this retrospective study, a large

Table 2. Summary of the number of recurrences/year and the number of anti-VEGF injections/year in the subgroup of patients with ≥ 12 months of follow-up data before and after the start of IMT

	17 eyes of 17 patients			20 eyes of 17 patients		
	Before IMT	After IMT	<i>P</i> -value*	Before IMT	After IMT	<i>P</i> -value*
Total recurrences†/year	1.40 ± 0.81	0.49 ± 0.47	0.002	1.25 ± 0.83	0.45 ± 0.45	0.001
Number of recurrences	49	34		59	38	
Recurrences with active CNV/year	0.73 ± 0.76	0.17 ± 0.25	0.008	0.63 ± 0.73	0.16 ± 0.24	0.011
Number of recurrences	21	10		25	12	
Recurrences without active CNV/year	0.67 ± 0.68	0.32 ± 0.30	0.234	0.62 ± 0.65	0.29 ± 0.30	0.136
Number of recurrences	28	24		34	26	
Anti-VEGF injections‡/year	3.34 ± 3.46	1.98 ± 2.92	0.041	2.87 ± 3.40	1.75 ± 2.76	0.071
Number of injections	81	155		81	161	

CNV = choroidal neovascularization; IMT = corticosteroid-sparing immunomodulatory therapy; VEGF = vascular endothelial growth factor.

Bold *P*-values are significant at *P* < 0.05.

* Wilcoxon signed-rank test.

† Total, number of recurrences/year of choroiditis with CNV + number of recurrences/year of choroiditis without CNV.

‡ Anti-VEGF injections included bevacizumab, ranibizumab and aflibercept.

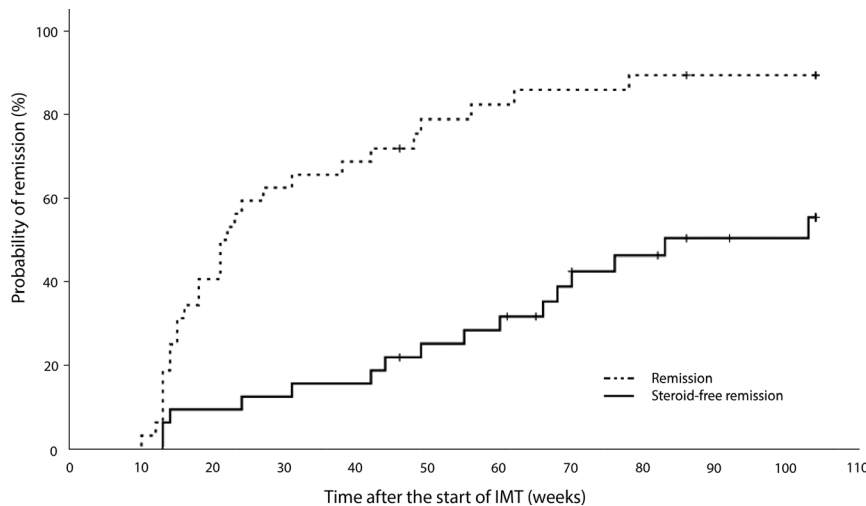


Fig. 2. Time to remission and steroid-free remission. A Kaplan–Meier graph illustrates the time between the start of IMT and the probability of achieving remission (interrupted line) and steroid-free remission (continuing line). Censoring is indicated by small vertical lines.

timeframe was assessed with a change of clinical practice over time.

A strength of this study is the relatively large, homogeneous study cohort including 32 patients with central MFC for whom clinical data were available after the start of IMT. To the best of our knowledge, this is the first study of this size to evaluate the efficacy of IMT on the long term exclusively in patients with central MFC. Moreover, data were available for at least 12 months – and in some cases, 24 months – after the start of IMT, thus providing important insight into the long-term course of the disease after the start of IMT.

Despite these strengths, our study has several possible limitations that warrant discussion, and as with any retrospective cohort study, the results should be interpreted in the context of these limitations. First, although the sample size is relatively large compared to previously published studies regarding central MFC (Turkcuoglu et al. 2011; Goldberg et al. 2014), the sample size is still a limitation of the study.

Second, we chose for a longitudinal (within-subject) study design instead of cross-sectional study design. Therefore, a control group is not applicable and thus the natural course of disease is not taken into account. Though, in our opinion within-subject study design is the best method considering the available data. Only a selective group of MFC patients have an indication for preventive treatment with IMT. When comparing these results to a control

group (patients without treatment with IMT and often without indication for preventive treatment), it will inevitably causes distortion of the results. This study focused exclusively on patients with sight-threatening and/or recurrent central MFC, and thus, the results are most applicable to this specific subgroup of patients with central MFC.

Third, the observed decrease in the number of annual recurrences in the choroiditis cases both with and without active CNV after the start of IMT is likely an underestimation. Since 2011, most patients treated with IMT are closely monitored using the eye-tracker system on the OCT machine, thereby allowing for the early identification and treatment of subclinical recurrences of choroiditis, rather than treating only clinically identifiable recurrences (which present mostly with active CNV). Thus, it is reasonable to assume that the number of recurrences before 2011 (and often prior to the start of IMT) is likely an underestimation due to unreported subclinical recurrences.

Fourth, choroidal neovascularization (CNV) develops in a relatively large percentage of patients, ranging from 45.2% (Leung et al. 2014) to 76.9% (Kedhar et al. 2007; Fung et al. 2014), and CNV can result in permanent vision loss. Distinguishing between an active CNV site and an inflammatory lesion is often difficult; literature suggests OCTA can be used to distinguish an inflammatory lesion and CNV though unfortunately this imaging modality was not yet available

during the timeframe of this study. For this reason, at least one preventive injection of anti-VEGF often was given in cases with an active inflammatory lesion. Moreover, in the case of active CNV, neither the number nor the frequency of injections is standardized and varied both between patients and over time; thus, our results regarding anti-VEGF injections should be interpreted with caution.

Finally, patient-centred outcomes should also be considered. For example, it is unclear to what extent preserving vision in a patient with central MFC improves quality of life, as well as whether this is sufficient to offset the extent to which preventive treatment with IMT can potentially decrease the patient’s quality of life. Moreover, no data are currently available regarding the impact of IMT on quality of life in patients with central MFC, and additional research is needed in order to evaluate the overall effects of IMT in these patients.

Conclusions

In summary, we report that after the start of preventive treatment with IMT, the number of recurrences/year significantly decreased, BCVA stabilized, and the number of patients who achieved (steroid-free) remission increased. We therefore conclude that preventive treatment with IMT should be considered as a treatment option in patients with recurrent and/or sight-threatening central MFC.

References

Ahnood D, Madhusudan S, Tsaloumas MD, Waheed NK, Keane PA & Denniston AK (2017): Punctate inner choroidopathy: a review. *Surv Ophthalmol* **62**: 113–126.

Barth T, Zeman F, Helbig H & Gamulescu MA (2008): Intravitreal anti-VEGF treatment for choroidal neovascularization secondary to punctate inner choroidopathy. *Int Ophthalmol* **38**: 923–931.

Baxter SL, Pistilli M, Pujari SS et al. (2013): Risk of choroidal neovascularization among the uveitides. *Am J Ophthalmol* **156**: 468–477.

Chen SN, Chen YL & Yang BC (2019): Long-term outcome of punctate inner choroidopathy or multifocal choroiditis with active choroidal neovascularization managed with intravitreal bevacizumab. *Ocul Immunol Inflamm* **28**: 33–38.

Dick AD, Rosenbaum JT, Al-Dhibi HA et al. (2018): Guidance on noncorticosteroid

- systemic immunomodulatory therapy in noninfectious uveitis: Fundamentals of Care for Uveitis (FOCUS) initiative. *Ophthalmology* **125**: 757–773.
- Fung AT, Pal S & Yannuzzi NA (2014): Multifocal choroiditis without panuveitis: clinical characteristics and progression. *Retina* **34**: 98–107.
- Galor A, Jabs DA, Leder HA, Kedhar SR, Dunn JP, Peters GB & Thorne JE (2008): Comparison of antimetabolite drugs as corticosteroid-sparing therapy for noninfectious ocular inflammation. *Ophthalmology* **115**: 1826–1832.
- Goldberg NR, Lyu T, Moshier E, Godbold J & Jabs DA (2014): Success with single-agent immunosuppression for multifocal choroidopathies. *Am J Ophthalmol* **158**: 1310–1317.
- Jabs DA (2018): Immunosuppression for the Uveitides. *Ophthalmology* **125**: 193–202.
- Jabs DA, Rosenbaum JT, Foster C et al. (2000): Guidelines for the use of immunosuppressive drugs in patients with ocular inflammatory disorders: recommendations of an expert panel. *Am J Ophthalmol* **130**: 492–513.
- Jabs DA, Nussenblatt RB & Rosenbaum JT (2005): Standardization of Uveitis Nomenclature (SUN) Working Group. Standardization of uveitis nomenclature for reporting clinical data. Results of the First International Workshop. *Am J Ophthalmol* **140**: 509–16.
- Kedhar SR, Thorne JE, Wittenberg S, Dunn JP & Jabs DA (2007): Multifocal choroiditis with panuveitis and punctate inner choroidopathy: comparison of clinical characteristics at presentation. *Retina* **27**: 1174–1179.
- Leung TG, Moradi A, Liu D et al. (2014): Clinical features and incidence rate of ocular complications in punctate inner choroidopathy. *Retina* **34**: 1666–1674.
- Niederer RL, Gilbert R, Lightman SL & Tomkins-Netzer O (2018): Risk factors for developing choroidal neovascular membrane and visual loss in punctate inner choroidopathy. *Ophthalmology* **125**: 288–294.
- Nussenblatt RB, Palestine AG, Chan CC & Roberge F (1985): Standardization of vitreal inflammatory activity in intermediate and posterior uveitis. *Ophthalmology* **92**: 467–471.
- Parodi MB, Iacono P, Mansour A et al. (2013): Intravitreal bevacizumab for juxtafoveal choroidal neovascularization secondary to multifocal choroiditis. *Retina* **33**: 953–956.
- Tavallali A & Yannuzzi L (2016): Idiopathic multifocal choroiditis. *J Ophthalmic Vis Res* **11**: 429–432.
- Turkcuoglu P, Chang PY, Rentiya ZS et al. (2011): Mycophenolate mofetil and fundus autofluorescence in the management of recurrent punctate inner choroidopathy. *Ocul Immunol Inflamm* **19**: 286–292.

Received on January 3rd, 2020.
Accepted on April 21st, 2020.

Correspondence:

Evianne L. de Groot
Department of Ophthalmology
University Medical Center Utrecht
PO Box 85500
Room E 03.136
3508 GA Utrecht
The Netherlands
Tel: +31 88-5560980
Fax: +31 887555405
Email: e.l.degroot-24@umcutrecht.nl

Funding/Support: Fisher Foundation, Keizersgracht 444-A, 1016 GD Amsterdam, the Netherlands; Foundation Beheer Het Schild, Wolfhezerweg 101, 6874 AD Wolfheze, the Netherlands; Landelijke Stichting voor Blinden en Slechtzienden (LSBS), Galvanistraat 1, 6716 AE Ede, the Netherlands