

# Cervical articular process joint osteochondrosis in Warmblood foals

Wilhelmina Bergmann<sup>1</sup>  | Marjolijn de Mik-van Mourik<sup>1,2</sup> | Stefanie Veraa<sup>3</sup>  |  
Jan van den Broek<sup>4</sup> | Inge D. Wijnberg<sup>2</sup> | Willem Back<sup>2,5</sup> | Andrea Gröne<sup>1</sup>

<sup>1</sup>Division of Pathology, Faculty of Veterinary Medicine, Utrecht University, Utrecht, the Netherlands

<sup>2</sup>Division of Equine Sciences, Faculty of Veterinary Medicine, Utrecht University, Utrecht, the Netherlands

<sup>3</sup>Division of Integrating Disciplines, Faculty of Veterinary Medicine, Utrecht University, Utrecht, the Netherlands

<sup>4</sup>Division of Farm Animal Health, Faculty of Veterinary Medicine, Utrecht University, Utrecht, the Netherlands

<sup>5</sup>Department of Surgery and Anaesthesia of Domestic Animals, Faculty of Veterinary Medicine, Ghent University, Merelbeke, Belgium

## Correspondence

Wilhelmina Bergmann, Division of Pathology, Faculty of Veterinary Medicine, Utrecht University, Yalelaan 1, NL-3584 CL, Utrecht, The Netherlands.  
Email: w.bergmann@uu.nl

## Present address

Marjolijn de Mik-van Mourik, Central Laboratory Animal Facility, Leiden University Medical Center, Leiden, the Netherlands.

## Abstract

**Background:** In Warmblood horses, degenerative joint disease is involved in cervical malformation and malarticulation (CVM). The degree of contribution of articular process joint (APJ) osteochondrosis (OC) is not clear.

**Objectives:** (a) To explore the presence of predilection sites for APJ OC in cervical and cranial thoracic vertebral columns of Warmblood foals and (b) to examine the correlation of such a site with the predilection site of CVM.

**Study design:** Case series.

**Methods:** Seven hundred APJ facets of C2 to T2 of 29 foals (11 months gestation to 12 months [median age 7 days; range 365 days; 95% confidence interval [95% CI] 2-47 days]) were examined for OC and prevalence between joints, and the predilection site for CVM and the cranial cervical vertebral column were evaluated.

**Results:** About 20.6% of facets revealed OC. There was no predilection site. Prevalence decreased with age up to 1 year (odds ratio [OR] 0.997; (95% CI 0.975-0.998)) but not up to 5 months. Severity increased with age in all age ranges (up to 1 year OR 1.023; 95% CI 1.005-1.049; >1-5 months, OR 1.203; 95% CI 1.014e+00-1.921; up to 1 month, OR 1.114; 95% CI 1.041-1.228). Highest prevalence was in cranial facets of the cervical and cervical-thoracic joints and in caudal facets of the thoracic joint up to 1 year and up to 1 month (OR 0.364; 95% CI 0.170-0.745, OR 0.434; 95% CI: 0.235-0.782, OR 7.665; 95% CI: 1.615-66.553 and OR 0.400; 95% CI 0.170-0.880, OR 0.351; 95% CI 0.172-0.700, OR 5.317; 95% CI 1.098-44.344 respectively).

**Main limitations:** Two-thirds of the foals were less than 1 month of age.

**Conclusions:** Articular process joint OC in Warmblood foals is common and is not more prevalent at CVM predilection sites, suggesting that abnormalities of enchondral ossification may not be major contributors to CVM.

## KEYWORDS

horse, cervical vertebral malformation and malarticulation, predilection site

This is an open access article under the terms of the Creative Commons Attribution-NonCommercial License, which permits use, distribution and reproduction in any medium, provided the original work is properly cited and is not used for commercial purposes.

© 2020 The Authors. *Equine Veterinary Journal* published by John Wiley & Sons Ltd on behalf of EVJ Ltd

## 1 | INTRODUCTION

Cervical malformation and malarticulation (CVM) is a common cause for neck pain, pelvic and/or thoracic limb paresis and ataxia and is caused by compression of the spinal cord and/or nerve roots.<sup>1-7</sup> The pathogenesis for this condition is presumed to be multifactorial.<sup>1,3,7</sup> Compression of the spinal cord or nerves may be present in a static or dynamic form although there is overlap. The caudal part of the cervical vertebral column from cervical vertebra (C)5 to thoracic vertebra (T)1 is most frequently involved in the static form of spinal cord compression and is most commonly seen in older horses, especially Warmblood horses of 4 years and older.<sup>2,4-6</sup> This form is most often caused by osteoarthritic change in the articular process joints (APJs), with resulting enlargement of the joints, hypertrophy of the ligamentum flavum and the joint capsule and formation of synovial cysts.<sup>3,5,7</sup> The presence of APJ osteochondrosis (OC) has been described in cases of CVM<sup>2-4,8</sup> and it has been suggested that degenerative changes of the APJs in horses with CVM are secondary to primary OC.<sup>4,8</sup>

This study has two aims. First to investigate whether the different cervical and cranial thoracic vertebral APJs or certain regions within this part of the vertebral column of Warmblood foals have predilection sites for OC. Second, to determine the extent of agreement between predilection sites of OC and the predilection site for CVM as seen in adult Warmblood horses. It is hypothesised that APJ OC is more common with more severe lesions in the caudal cervical region, the predilection site for CVM in Warmblood horses.

## 2 | MATERIALS AND METHODS

### 2.1 | Horses

A total of 31 Warmblood foals that were privately owned by 25 different owners were examined. The foals either died unexpectedly or were humanly subjected to euthanasia for reasons unrelated to the current study between July 2012 to August 2013 and April 2017 to July 2018 and subsequently referred for necropsy to the Division of Pathology of Utrecht University (Table S1). One of the foals (at term, foal 1; Table S1) was removed from the uterus of its dam during the necropsy of this mare. Foals were excluded from this study if disorders were present that could affect the morphology of the APJs (eg fractures, osteomyelitis and arthritis).

Two foals (foal 7 and foal 10; Table S1) had a septicaemia with resultant microscopically visible vascular changes in the facet cartilage. As these changes can lead to OC-like lesions, these foals were removed from further investigation.<sup>9</sup> The remaining 29 foals were of different ages, varying from 11 months gestation to 12 months post-partum (median age 7 days; range 365 days; 95% confidence interval [95% CI] 2-47 days), breed (28 Royal Dutch Sport horses, one Zangersheide horse) and sex (11 females, 18 males; Table S1). For the flowchart concerning the eligibility of the available foals see Figure S1.

### 2.2 | Data collection

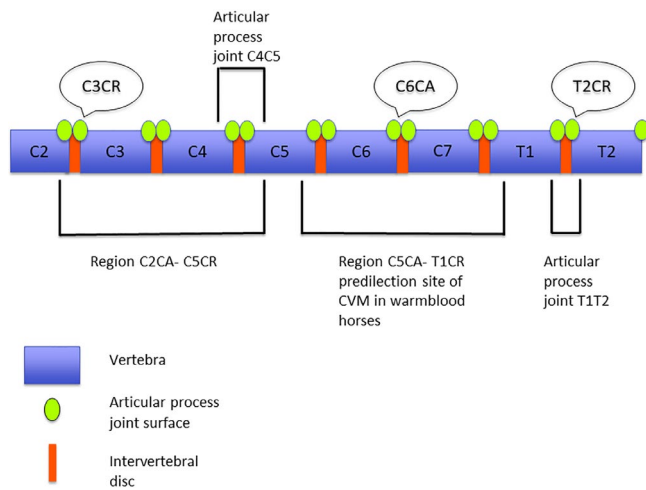
Necropsy was performed on all foals with the owner's informed consent to investigate the cause of death or the cause for the clinical signs (Table S1).

After necropsy, the cervical and cranial parts of the thoracic vertebral column were removed and the neck was dissected with subsequent gross evaluation of the APJs. For histological evaluation, slices of approximately 3 mm thickness were cut perpendicular to the facet. The area was selected based on possible OC-related gross changes. A slice was taken from the middle of the facet when no gross changes were visible. In 17 foals (foals 1, 2, 5, 13, 14, 15, 17, 18, 19, 20, 21, 22, 23, 27, 29, 30 and 31), the facets of the cervical vertebrae C3, C5, C6, C7, the thoracic vertebra T1 and the cranial facet of T2 were examined (22 facets each). In 11 foals (foals 3, 4, 6, 8, 9, 12, 16, 24, 25, 26 and 28), the caudal facets of C2 and the facets of C4 were additionally assessed (28 facets each). In foal 11, the facets of C2, C3 and C4 were not collected, whereas those of C5, C6, C7, T1 and the cranial facets of T2 were collected (a total of 18 facets). The bone slices were fixed in 4% buffered formaldehyde and decalcified in 10% ethylenediaminetetraacetic acid (EDTA) before routine processing and staining with haematoxylin and eosin and subsequent light microscopic evaluation for osteochondral lesions. Although lesions suggestive for OC (focal thickening of cartilage, soft and red cartilage)<sup>10</sup> can be identified during gross evaluation, histology was considered the 'gold standard' for confirmation and for diagnosing initial lesions (OC latens), which cannot be diagnosed grossly.<sup>10,11</sup>

Each affected facet was designated to one of the subtypes of OC (latens, manifesta or dissecans) to classify the severity of the lesions. OC latens is characterised by focal epiphyseal cartilage necrosis, OC manifesta is accompanied by the involvement of enchondral ossification and OC dissecans is accompanied by fissure formation through articular cartilage.<sup>10</sup> The presence of only OC latens was classified as mild, presence of at least one area with OC manifesta was classified as being moderate and presence of at least one area with OC dissecans was classified as severe OC. Other joints were not evaluated for the presence of OC.

### 2.3 | Sites of interest

The focus of this study was on the APJs of the caudal cervical vertebral columns from the caudal APJs of cervical vertebra 5 up to the cranial APJs on the first thoracic vertebra (region C5CA-T1CR) with a total of 236 facets. The facets of caudal APJs on the second cervical vertebra up to the facets of the cranial APJs on the fifth cervical vertebra (region C2CA-C5CR) with a total of 348 facets were added as control (Figure 1). Furthermore, a possible predilection site was investigated for the different individual joints C2C3, C3C4, C4C5, C5C6, C6C7, C7T1 and T1T2. In total, 700 facets were assessed. Facet locations are abbreviated by vertebra (C2, C3, C4, C5, C6, C7, T1, T2), left or right side (L or R) and cranial or caudal position on the vertebra (CR or CA).



**FIGURE 1** Overview of the facets examined. C, cervical vertebra; T, thoracic vertebra; CR, cranial; CA, caudal; CVM, cervical malformation and malarticulation

## 2.4 | Data analysis

Facets without histological signs of OC were given a score 0, while facets with lesions consistent with OC were given a 1, thus producing binary data. The outcomes were analysed using a logistic regression model with foal as a random effect and the fixed effects of age, sex, joint, region of the vertebral column, position (cranial/caudal) of the facet on the vertebra and site (left/right) of the facet on the vertebra (Figure 1). Model selection was done by stepwise backward elimination and the Akaike information criterion (AIC) was used to select the best model. Furthermore, 95% log profile likelihood confidence intervals were used as effect size estimates.<sup>12</sup> To see if the likelihood of the occurrence of OC increased if a neighbouring joint had OC could not be determined by this model due to identifiability problems that were likely due to intertwinement of the fixed effects. Instead, the proportions of OC per joint were determined and subsequently the Pearson's correlation coefficient between the proportion of OC in a joint with the one before or after was determined.

The same logistic regression model was also used for the outcome severity of OC, with OC latens given a score 0, and OC manifesta a score 1. For this model, the 144 OC-positive facets were used. No OC dissecans was encountered and therefore not scored. All calculations were performed with R (R Development Core Team, version 3.4.3, package lme4, R: A language and environment for statistical computing. R Foundation for Statistical Computing, <https://www.R-project.org>) and analysed using R studio (RStudio Team [2015], version 1.2.1335, RStudio: Integrated Development for R. RStudio, Inc., <http://www.rstudio.com/>).

Age turned out to have an effect on the likelihood to develop OC and therefore these calculations were repeated with one subset of foals within the age range of >1 month up to 5 months of age ( $n = 7$ ) and one subset of foals within the age range of 0 days up to 1 month of age ( $n = 20$ ). Hereby, the fixed effect age was kept as a continuous variable. In the subset of foals within the age range of >1 month up to 5 months of age, only one female foal was present, and therefore

the independent variable sex for this subset of foals was not taken into account. For the outcome severity of OC 25 respectively 114 OC-positive facets were used for these subsets of foals.

## 3 | RESULTS

Both foal 7 and foal 10 (Table S1) showed OC-like changes in many of the APJs due to a severe bacterial osteomyelitis affecting the osteochondral junction, and a vasculitis of bacterial origin respectively. Therefore, these two foals were omitted from further investigation.<sup>9</sup>

Osteochondrosis latens was characterised by necrotic epiphyseal cartilage. This cartilage contained hypereosinophilic, shrunken chondrocytes with pyknotic nuclei and was occasionally also hypocellular. The matrix showed loss of differential staining. Often nodular clusters of chondrocytes (chondrones) were visible surrounding areas of necrotic cartilage. Cartilage canal blood vessels in affected areas had lost their endothelium and very rarely swollen endothelial cells or endothelial cells with pyknotic nuclei were present. Occasionally, the vessel lumen was filled with hypereosinophilic, fibrillar material, interpreted as fibrin (Figure S2).

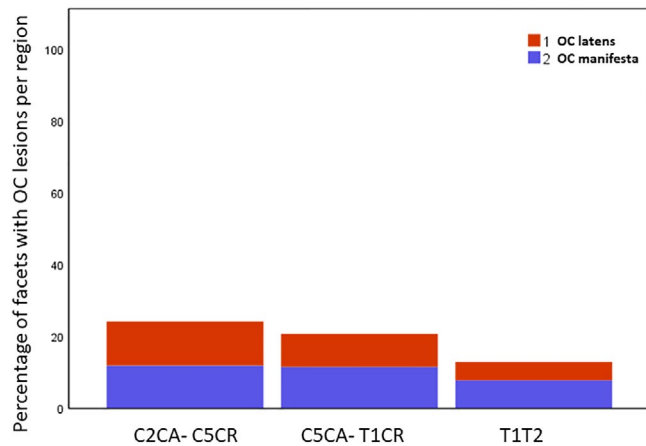
In OC manifesta, the ossification front was (also) affected and persistent necrotic cartilage could be seen (Figure S3). Occasionally, fissure formation was present in the necrotic cartilage, which often extended into the subchondral bone where bone lysis and fibrosis could be appreciated.

Commonly, multiple, up to 4, separate affected areas were visible and both OC latens and manifesta could be seen within the same facet. All foals but one had OC lesions in one to 24 facets examined (mean number of lesions per foal  $4.24 \pm 4.50$  lesions). The foal removed from the uterus (foal 1; Table S1) during the necropsy of its dam had two facets with OC lesions (one latens, one manifesta).

Osteochondrosis was identified in 144/700 facets (20.6%), of which 66 (45.8%) had OC latens and 78 (54.2%) OC manifesta. OC dissecans was not encountered (Table S1, Figure 2). Only five of the 144 facets with histologically confirmed OC lesions (3.5% of all facets with OC) had gross changes visible on the facet's surfaces, characterised by round to longitudinal indentation of the cartilage. All grossly visible affected facets had OC manifesta. There was no association between the frequency of OC lesions and sex, the different joints, regions within the vertebral column, nor the site (right/left) of the affected facet.

Taking all foals into account (age range of 0 up to 1 year), the likelihood of having OC decreased with age (Table 1).

The odds of having OC lesions within the cranial facets of the cranial cervical region (C2CA-C5CR) and the CVM predilection site (C5CA-T1CR) were higher than odds of the caudal facets being affected (Figure 3, Table 1). Odds of finding OC lesions within the caudal facets of the first thoracic APJ (T1T2) were higher than in the cranial facets (Figure 3, Table 1). There was no correlation between the proportion of OC in a joint and the proportion of OC in the joints cranial or caudal (lag-1 correlation  $-0.425$ ; 95% CI  $-0.791$  to  $0.165$ ) to it. The likelihood of either



**FIGURE 2** Percentage of OC lesions found in each examined region in a group of Warmblood foals. OC, osteochondrosis; C2CA-C5CR, region from the caudal articular process joints of the second cervical vertebra up to the cranial articular process joints of the fifth cervical vertebra; C5CA-T1CR, region from the caudal articular process joints of the fifth cervical vertebra up to the cranial articular process joint of the first thoracic vertebra; T1T2, articular process joints between the first and second thoracic joints

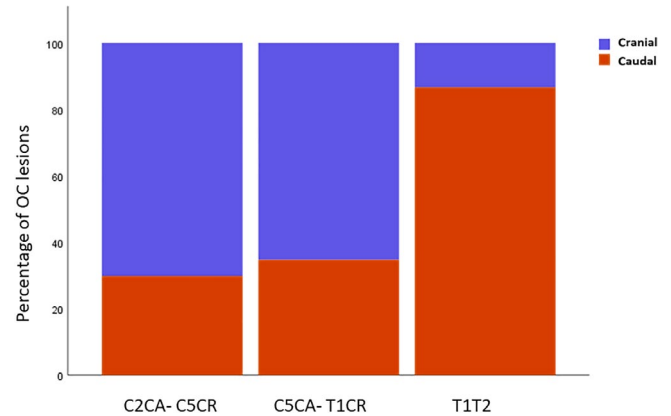
**TABLE 1** Effective independent variables on the occurrence of osteochondrosis lesions in a group of Warmbloods aged 0 d to 1 y

Age range	Independent variable	Odds ratio	95% profile likelihood confidence interval
0 d up to 1 y of age (N = 29)	Age	0.997	0.975-0.998
	Position (cranial vs. caudal)		
	Craniocervical (C2CA-C5CR)	0.364	0.170-0.745
	Caudocervical (C5CA-T1CR)	0.434	0.235-0.782
0 d up to 1 mo of age (N = 20)	First thoracic joint (T1T2)	7.665	1.615-66.553
	Position (cranial vs. caudal)		
	Craniocervical (C2CA-C5CR)	0.400	0.170-0.880
	Caudocervical (C5CA-T1CR)	0.351	0.172-0.700
	First thoracic joint (T1T2)	5.317	1.098-44.344

Abbreviations: C2CA-C5CR, region from the caudal articular process joints of the second cervical vertebra up to the cranial articular process joints of the fifth cervical vertebra; C5CA-T1CR, region from the caudal articular process joints of the fifth cervical vertebra up to the cranial articular process joint of the first thoracic vertebra; T1T2, articular process joints between the first and second thoracic joints; N, amount of foals examined.

mild or moderate OC did not differ between sex, different joints, region, site (left/right) or position (cranial/caudal). However, the likelihood of moderate OC did increase with age (Table 2).

In the subset of foals aged >1-5 months none of the independent variables, including age, had an effect on the likelihood of OC



**FIGURE 3** Distribution of OC lesions along the cranial and caudal position of the facets in each region examined in a group of Warmblood foals aged 0 d to 1 y. C2CA-C5CR, from the caudal articular process joints of the second cervical vertebra to the cranial articular process joints of the fifth cervical vertebra; C5CA-T1CR, from the caudal articular process joints of the fifth cervical vertebra to the cranial articular process joint of the first thoracic vertebra; T1T2, articular process joints between the first and second thoracic joints

**TABLE 2** Effective independent variables on the severity of osteochondrosis lesions in a group of Warmblood foals aged 0 d to 1 y

Age range	Independent variable	Odds ratio	95% profile likelihood confidence interval
0 d up to 1 y of age (N = 29)	Age	1.023	1.005-1.049
>1 mo up to 5 mo of age (N = 7)	Age	1.203	1.014e+00-1.921
0 d up to 1 mo of age (N = 20)	Age	1.114	1.041-1.228

Abbreviation: N, amount of foals examined.

lesions. Similar to the entire population of foals aged 0 days up to 1 year, in the subset of foals aged 0 days to 1 month, the likelihood of OC lesions was higher for the cranial facets than the caudal facets in the cranial cervical region and the predilection site for CVM (Table 1). Also, the likelihood to develop OC was higher in the caudal facets than in the cranial facets of the first thoracic APJ in this age range (Table 1). As seen across the entire population, the likelihood of developing moderate OC increased with age in the subsets of foals with the younger age ranges (Table 2). The other independent variables had no effect on the likelihood to develop moderate OC.

## 4 | DISCUSSION

In this case series, predilection for OC was not identified in either the predilection site of CVM in Warmblood horses or within the

different examined joints and the cranial cervical region. This suggests that OC may not be a major contributor to CVM.

This finding is supported by previous studies in which not only OC but also synovial cysts, degenerate joint disease and osteomyelitis have been described as a cause for spinal cord compression in horses with CVM,<sup>3,8</sup> with the severity of both OC lesions and non-OC lesions being greater at sites of compression than at sites without compression.<sup>8</sup> Compression has also been seen at sites with no lesions of the APJs.<sup>8</sup> Furthermore, no difference in frequency of OC lesions has been found between horses with and without CVM.<sup>8</sup>

However, the significant increase in frequency and severity of lesions of the APJs at both compression and noncompression sites and the increase in severity of OC lesions in horses with CVM compared to control horses suggest a common developmental pathogenesis of OC and CVM.<sup>8,13</sup> The more frequent progression of OC lesions in horses with CVM may be the result of secondary biomechanical influences. In pigs, the progression of the severity of OC has been suggested to be a consequence of local mechanical overload due to differences in joint and leg shape.<sup>14,15</sup> Also, in humans, increased biochemical stress seems to increase the prevalence and severity of gross OC lesions.<sup>16</sup> Therefore, it is likely that minimal trauma, caused by normal movements, can lead to the progression of subclinical OC to clinical OC dissecans in horses with malformations of the vertebral column while these forces would have no effect in horses without CVM.

Osteochondrosis is a dynamic condition in which the time course of lesion development varies between joints.<sup>17,18</sup> Depending on the joint, there is a time window in which OC can develop and regress again.<sup>17,18</sup> Regression is common and just a few lesions will develop into clinical OC.<sup>17,18</sup> Although no susceptible period in particular has been described for APJ OC, it has been suggested that the majority of OC lesions will develop before the age of 5 months and that regression after the age of 11 months is no longer likely.<sup>18</sup> The vast majority of foals examined here were less than 1 month of age and this age range showed the bulk of OC lesions. Only two foals were 5 months and older. Therefore, this case series consists of predominantly early onset OC. A relatively high prevalence of OC lesions in the cervical APJs of Warmblood foals reported earlier was considered to be due to the fact that these foals were specifically selected for being offspring of a sire affected by OC, and as such genetically predisposed to OC.<sup>18</sup> On the other hand, the foals used in the current study were assumed to be a representative sample of the general Dutch Warmblood population and especially of the Royal Dutch Sport horse population, as almost all foals belonged to this breed. However, we used a convenience sample and therefore bias cannot be excluded and no details about the sire or dam were available to confirm this. Of the joints examined, 20.6% showed OC making APJ OC common in the general population of Warmblood foals. This is in line with OC development in other joints in which the prevalence of OC in domesticated horse breeds is much higher than those of feral horses, suggesting that OC could have unintentionally been introduced by selective breeding.<sup>19-21</sup>

It is also possible that had these foals lived longer, more lesions on other facets could have developed while others could have regressed. A larger group of foals between 5 and 12 months of age needs to be studied to determine whether certain joints or regions might be a predilection site for lesions in this age range.

Within the foals we examined, the presence of OC manifested increased with age; however, OC dissecans was not encountered. Biomechanical stress and trauma play a role in the progression of severity of OC.<sup>10</sup> The level of biomechanical stress most of these foals had experienced is likely to be low as many were very young and this is a possible explanation for the lack of OC dissecans in the facets studied.

The odds of having OC lesions in the cranial facets of the cervical APJs and the cervical-thoracic APJs (C7T1) and the caudal facets of the first thoracic APJs (T1T2) were higher than having OC lesions in their opposite facets in the population of foals aged 0 days up to 1 year and the subset of foals aged 0 days up to 1 month of age. This difference between the cervical facets has been described before in foals of 5 and 11 months of age.<sup>18</sup> Although in the subset of foals aged >1 month up to 5 months, 15 OC-positive cranial facets were present in the cervical spinal column in contrast to only seven OC-positive caudal facets, position was not an effective independent variable for the occurrence of OC in this age range. Possibly this was due to the small number of foals and of OC-positive facets in this subset of foals with subsequent limited statistical power. Microtrauma is thought to be the initiating event for the development of OC<sup>10</sup> and site-specific traits, as a cause for microtrauma, are likely due to the focal nature of OC.<sup>10</sup> This suggests a different biomechanical environment between these two positions and these regions. In humans, APJ orientation is correlated with the development of APJ arthrosis due to changes in biomechanical forces.<sup>22</sup> This difference in biomechanics could also be an explanation for the difference of the most likely affected facets between these regions in the horse as in the horse the orientation of the cervical and cervical/thoracic APJs is different than that of the first thoracic APJ with subsequent different biomechanics.

Less than one-fifth of the affected joint pairs examined here were affected bilaterally confirming that OC of the APJs is not a bilateral symmetrical process<sup>3,18</sup> in contrast to most other joints.<sup>10,18</sup>

In conclusion, early onset OC is common in the cervical and cranial thoracic vertebral column of Warmblood foals, without the presence of a predilection site, suggesting that OC is not the only contributor to CVM.

#### ETHICAL ANIMAL RESEARCH

Research ethics committee oversight not currently required by this journal: the study was performed on material collected during post-mortem examination.

#### OWNER INFORMED CONSENT

Owners gave consent for their animals' inclusion in the study.



## AUTHOR CONTRIBUTIONS

W. Bergmann, M. de Mik-van-Mourik, S. Veraa, I.D. Wijnberg, W. Back and A. Gröne contributed to study conception and design, and data acquisition. W. Bergmann, J. van den Broek and A. Gröne contributed to analysis and interpretation of data. All authors contributed to drafting the article or revising it critically for important intellectual content and gave their approval of the final version of the manuscript.

## CONFLICT OF INTEREST

No competing interests have been declared.

## ORCID

Wilhelmina Bergmann  <https://orcid.org/0000-0002-8667-5070>

Stefanie Veraa  <https://orcid.org/0000-0002-1067-3976>

## REFERENCES

- Levine JM, Scrivani PV, Divers TJ, Furr M, Mayhew IJ, Reed S *et al*. Multicenter case-control study of signalment, diagnostic features, and outcome associated with cervical vertebral malformation-malarticulation in horses. *J Am Vet Med Assoc*. 2010;237:812–22.
- van Biervliet J, Mayhew J, de Lahunta A. Cervical vertebral compressive myelopathy: diagnosis. *Clin Tech Equine Pract*. 2006;5:54–9.
- Trostle SS, Dubielzig RR, Beck KA. Examination of frozen cross sections of cervical spinal intersegments in nine horses with cervical vertebral malformation: lesions associated with spinal cord compression. *J Vet Diagn Invest*. 1993;5:423–31.
- Powers BE, Stashak TS, Nixon AJ, Yovich JV, Norrdin RW. Pathology of the vertebral column of horses with cervical static stenosis. *Vet Pathol*. 1986;23:392–9.
- Levine JM, Adam E, MacKay RJ, Walker MA, Frederick JD, Cohen ND. Confirmed and presumptive cervical vertebral compressive myelopathy in older horses: a retrospective study (1992–2004). *J Vet Intern Med*. 2007;21:812–9.
- Van Biervliet J. An evidence-based approach to clinical questions in the practice of equine neurology. *Vet Clin North Am Equine Pract*. 2007;23:317–28.
- Nout YS, Reed SM. Cervical vertebral stenotic myelopathy. *Equine Vet Educ*. 2003;15:212–23.
- Stewart RH, Reed SM, Weisbrode SE. Frequency and severity of osteochondrosis in horses with cervical stenotic myelopathy. *Am J Vet Res*. 1991;52:873–9.
- Wormstrand B, Østevik L, Ekman S, Olstad K. Septic arthritis/osteomyelitis may lead to osteochondrosis-like lesions in foals. *Vet Pathol*. 2018;55:693–702.
- Ytrehus B, Carlson CS, Ekman S. Etiology and pathogenesis of osteochondrosis. *Vet Pathol*. 2007;44:429–48.
- Olstad K, Ekman S, Carlson CS. An update on the pathogenesis of osteochondrosis. *Vet Pathol*. 2015;52:785–802.
- Burnham KP, Anderson DR. Model selection and multimodel inference: a practical information-theoretic approach. 2nd ed. New York: Springer-Verlag, 2002.
- Janes JG, Garrett KS, McQuerry KJ, Waddell S, Voor MJ, Reed SM *et al*. Cervical vertebral lesions in equine stenotic myelopathy. *Vet Pathol*. 2015;52:919–27.
- Grøndalen T. Osteochondrosis and arthrosis in pigs. VII. Relationship to joint shape and exterior conformation. *Acta Vet Scand Suppl*. 1974;46:1–32.
- de Koning DB, van Grevenhof EM, Laurensen BF, Hazeleger W, Kemp B. Associations of conformation and locomotive characteristics in growing gilts with osteochondrosis at slaughter. *J Anim Sci*. 2015;93:93–106.
- Bohndorf K. Osteochondritis (osteochondrosis) dissecans: a review and new MRI classification. *Eur Radiol*. 1998;8:103–12.
- Barneveld A, van Weeren PR. Conclusions regarding the influence of exercise on the development of the equine musculoskeletal system with special reference to osteochondrosis. *Equine Vet J*. 1999;31 (Suppl 31):112–9.
- van Weeren PR, Barneveld A. The effect of exercise on the distribution and manifestation of osteochondrotic lesions in the Warmblood foal. *Equine Vet J*. 1999;31 (Suppl 31):16–25.
- Valentino LW, Lillich JD, Gaughan EM, Biller DR, Raub RH. Radiographic prevalence of osteochondrosis in yearling feral horses. *Vet Comp Orthop Traumatol*. 1999;12:151–5.
- van Weeren PR. Osteochondritis dissecans. In: McIlwraith CW, Frisbie DD, Kawcak CE, van Weeren PR, editors. *Joint disease in the horse*. 2nd ed. Elsevier, St. Louis, Missouri. 2015; p. 57–84.
- van Weeren R. Fifty years of osteochondrosis. *Equine Vet J*. 2018;50:554–5.
- Kalichman L, Suri P, Guermazi A, Li L, Hunter DJ. Facet orientation and tropism: associations with facet joint osteoarthritis and degeneratives. *Spine (Phila Pa 1976)* 2009;34:E579–585.

## SUPPORTING INFORMATION

Additional supporting information may be found online in the Supporting Information section.

**How to cite this article:** Bergmann W, de Mik-van Mourik M, Veraa S, *et al*. Cervical articular process joint osteochondrosis in Warmblood foals. *Equine Vet J*. 2020;52:664–669. <https://doi.org/10.1111/evj.13245>