Columnar cell lesions of the breast:

morphologic features and role of 16q losses

Mirthe de Boer

Columnar cell lesions of the breast: morphologic features and role of 16q losses

Mirthe de Boer

Layout and printing: proefschrift-aio.nl
Cover design: Mirthe de Boer

ISBN: 978-94-93315-65-5

DOI:https://doi.org/10.33540/1608

Columnar cell lesions of the breast: morphologic features and role of 16q losses

Cilindercellaesies van de mamma: morfologische kenmerken en de rol van 16q verlies
(met een samenvatting in het Nederlands)

PROEFSCHRIFT

ter verkrijging van de graad van doctor aan de
Universiteit Utrecht
op gezag van de rector magnificus
prof.dr. H.R.B.M. Kummeling,
ingevolge het besluit van het college voor promoties
in het openbaar te verdedigen
op donderdag 6 juli 2023 des middags te 2.15 uur

door

Mirthe de Boer

geboren op 7 april 1986
te Alkmaar

Promotor:
Prof. dr P.J. van Diest

Copromotor:
Dr. C.B. Moelans

Beoordelingscommissie:
Prof.dr P.W.B. Derksen
Prof.dr C. H. van Gils
Prof.dr R.M. Pijnappel
Prof.dr. V.T.H.B.M Smit
Prof.dr E. van der Wall

Table of contents

Chapter 1

General introduction: The spectrum of columnar cell lesions of the breast: terminology, definition of atypia, carcinogenesis and differential diagnosis with other benign and (pre)malignant lesions

Columnar cell lesions

Definition and terminology

Over the last decades, lesions characterized by the presence of clonal columnar epithelial cells lining the terminal duct lobular units (TDLU) of the breast have been described under a variety of names, but one of the most widely used term is columnar cell lesion (CCL).(1) CCLs with atypia have also frequently been denoted Flat Epithelial Atypia (FEA).(1, 2) The reproducibility of this diagnosis is weak to moderate (3-5), while others describe excellent agreement (6). The combination of varying reproducibility and of different terminologies makes it difficult to interpret and compare published papers.

Low nuclear grade breast neoplasia family

CCLs have been proposed as early precursor lesions in the low nuclear grade breast neoplasia family, that consists of atypical ductal hyperplasia (ADH), low grade ductal carcinoma *in situ* (DCIS), low-grade invasive ductal carcinomas such as tubular and cribriform carcinoma and carcinomas of no special type (NST), lobular neoplasia (LN) and invasive lobular carcinoma.(7-10) Figure 1 provides a proposal of the putative progression routes of CCLs into other more advanced lesions.

Morphology

CCLs of the breast are cystically dilated TDLU lined by clonal columnar cells with uniform, ovoid to elongated nuclei and often with apical cytoplasmic blebs or snouts present at the luminal surface. The lining consists of one or two cell layers (columnar cell change) or more cell layers (columnar cell hyperplasia). Intraluminal secretions and microcalcifications are frequently seen.(11, 12) See also figure 2.

Stromal changes around CCLs are sometimes seen such as myxoid and fibroid stromal changes, and inflammation around CCLs (13), as well as pseudoangiomatous stromal hyperplasia-like changes(14). Not much is yet known about the clinical importance of these stromal changes. CCL in a complex fibroadenoma was described only once.(15) In this case, the CCL was associated with a carcinoma. Besides this case report, CCLs in fibroadenoma have never been described, and in our practice, we have also never seen CCLs in fibroadenomas. Nevertheless, apical snouts are very common in the epithelium of fibroadenoma, but this does not warrant a diagnosis of CCL in fibroadenoma.

In CCLs with atypia, the columnar cells show cytonuclear atypia, consisting of relatively round (16, 17) to ovoid, sometimes irregular nuclei with inconspicuous but sometimes also more prominent nucleoli (12). The nuclear orientation along

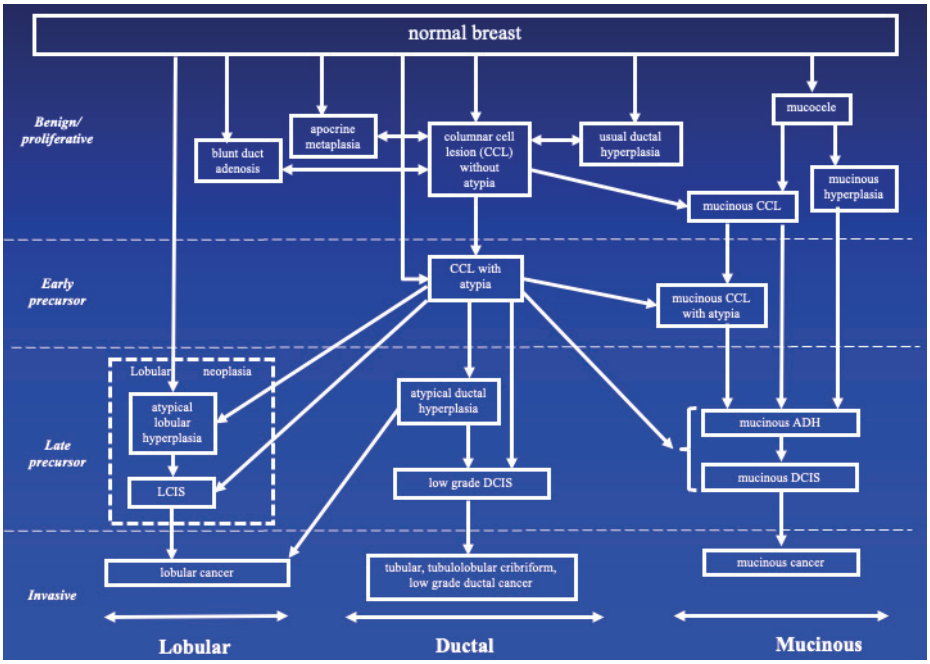

Figure 1. Proposal for relations of columnar cell lesions (CCLs) with other (premalignant) lesions in the low-grade breast carcinogenesis progression spectrum (LCIS=lobular carcinoma *in situ*, ADH=atypical ductal hyperplasia, DCIS= ductal carcinoma *in situ*).

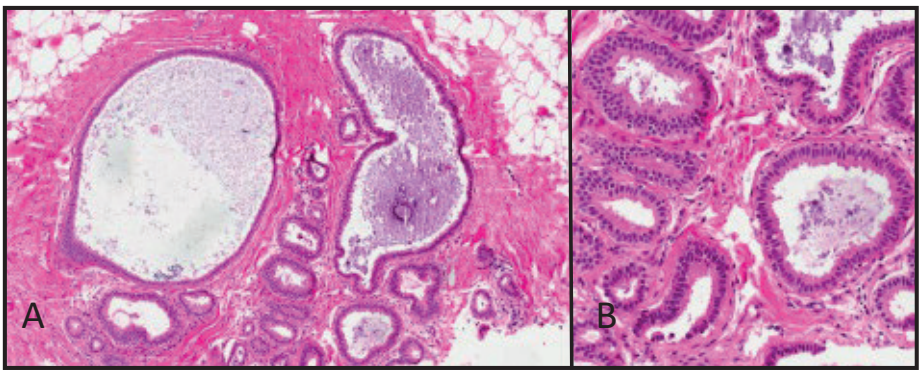

Figure 2. Columnar cell lesion without atypia. A. An enlarged terminal duct lobular unit (TDLU) with cystically dilated acini B. Detail of A, the acini are lined by cuboid to columnar cells with uniform nuclei and apical cytoplasmic blebs at the luminal surface. There are intraluminal secretions and microcalcifications.

the basement membrane can be disturbed [figure 3]. The designation atypia is however not unambiguous, since these criteria are not objective and prone to observer variation.(3-6, 18) A phenomenon that recently attracted our attention in this framework is the presence of rounded cells with clear cytoplasm just below the luminal columnar cells [figure 4], which we have become to call the "pale cells". Dimorphic ("pale") cell populations have been described in DCIS(19), and our impression in clinical practice was that we regularly encounter pale cells in low-grade precursor lesions, but dimorphic differentiation has to the best of our knowledge not been described in CCLs and atypical ductal hyperplasia (ADH) before. In **Chapter 3**, we systematically retrospectively evaluate the presence of pale cells in a group of ADH and CCL lesions to cover the earliest spectrum of the low nuclear grade precursor lesions, in search of further morphological features of CCLs related to the designation cellular "atypia".

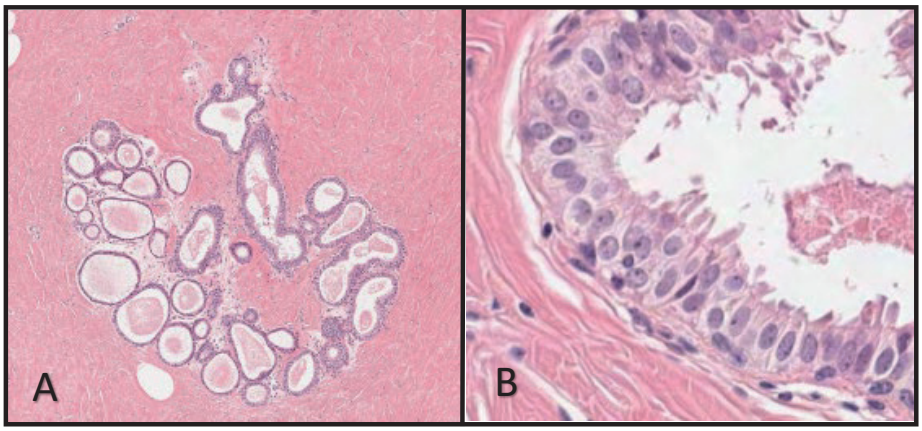

Figure 3. Columnar cell lesion with atypia. A. Enlarged TDLU with cystically dilated acini with intraluminal secretions. B. Detail of A, the acini are lined by columnar cells with round to ovoid nuclei with prominent nucleoli and an increased nuclear/cytoplasmic ratio. Also the nuclear orientation along the basement membrane is disturbed.

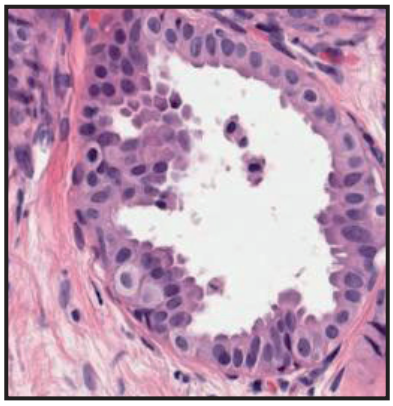

Figure 4. "Pale cells", rounded cells with a central nucleus and remarkable light eosinophylic cytoplasm, below the luminal epithelium in a CCLs with beginning complex architecture.

Sometimes, early CCL like changes can be seen in TDLUs, in the sense that one or two acini of a TDLU are slightly dilated and the lining columnar-like cells may show some apical snouts. Usually, such changes would be subclinical and it is not clear whether a diagnosis of CCL should be given. Arbitrarily, CCL could be diagnosed when they explain the presence of microcalcifications seen at mammography (to safeguard radiologic-pathologic correlation), when part of the CCL shows atypia or when at least half of the acini of a TDLU show the typical changes of CCL.

Complex architectural patterns (micropapillae, Roman arches, cribriformity) upgrade a CCL to atypical ductal hyperplasia (ADH) or low grade ductal carcinoma *in situ* (DCIS) and therefore preclude a diagnosis of CCL.(1)

Protein expression

Regarding hormone receptors, CCLs show high expression of the Estrogen Receptor-α (ER-α) (20-24) and the Progesterone Receptor (PR) (21-23) throughout the lesion. There is also higher expression in Androgen Receptor (AR) (21) although usually focally, and decreased expression in ER-β1.(20) These changes in hormone receptors indicate that hormones play an important role in the development of CCLs. In this respect it is remarkable that McLaren et al. found that patients with CCLs with a lower ER-α expression have a higher risk of developing invasive breast cancer.(25)

Cell cycle control proteins like p16, p27, p21, Rb1, Bcl-2 and Cyclin D1 are significantly increased in CCLs compared to normal breast tissue.(20-23, 26) This suggests a changed and/or disordered cell cycle control in CCLs. Still, the proliferative fraction (as reflected by MIB-1/Ki-67 expression) in CCLs (with and without atypia) is low (up to a mean proliferation fraction of 8% for CCLs with atypia), and CCLs without atypia even seem to have a significantly lower proliferation index than normal TDLU.(2, 27, 28)

It is believed that c-kit is one of the factors playing a role in differentiation of normal breast epithelium and c-kit loss may play a role in carcinogenesis.(29) Indeed, c-kit expression seems to be significantly reduced in CCLs (with and without atypia) compared to normal breast parenchyma.(14, 28, 29)

Some CCLs show focal areas of reduced or absent E-cadherin expression, typically affecting small isolated pockets of cells in areas of epithelial tufting and crowding.(21) However, a reduced E-cadherin expression in CCLs could not be confirmed by Abdel-Farah et al.(20) E-cadherin expression in CCL could play a role in the carcinogenesis of lobular lesions, as will be discussed later.

Molecular changes

In microsatellite analysis, CCLs showed a significantly higher average level of allelic imbalance (AI) than normal tissue although AI frequencies of the different genes did not differ.(30) On the other hand, "normal appearing" epithelium in patients with CCLs with atypia show LOH with similar frequencies of CCLs with atypia.(31) This "normal appearing" epithelium looked indeed normal under low magnification (40x) but seemed to present mild atypical nuclear features at 400x magnification. "Truly" normal epithelium (i.e. normal at 400x magnification) shows rarely LOH.(31) This points out the importance of cytologic evaluation of epithelial cells at high magnification and suggests that the first changes of CCLs are cytological rather than architectural changes.

A gene expression study suggested that genes associated with embryonic development, terminal differentiation, suppression of inflammation and immunity may play a role in the development of CCLs.(8)

Upregulation of miR-2(32), promoter methylation(33, 34) and several genetic changes demonstrated by LOH and CGH analysis(31, 35-38) have been demonstrated in CCLs. The most frequent genetic alterations are listed in table 1. Loss of 16q is one of the most interesting genetic aberrations, because it has been established as the molecular hallmark of the low nuclear grade breast neoplasia family as described in **Chapter 2** of this thesis. As shown in Table 1, also the frequency of 16q loss varies. Ellsworth et al. found a low frequency of 16q loss in pure CCLs (not associated with pre-cancerous lesions), leading the authors to suggest there is a difference between pure CCLs and CCLs associated with pre-cancerous lesions.(30) However, Moinfar et al. did not find different rates of LOH in pure CCLs and CCLs associated with DCIS.(31) An explanation for this could be could be the small numbers of CCLs in the different studies, different definitions of CCLs and different genes tested. Also different molecular techniques were used. In **Chapter 4**, we therefore analyze copy number changes of 6 genes on 16p and 20 genes on 16q by multiplex ligation-dependent probe amplification (MLPA) in 165 lesions of 103 patients. Twenty-three columnar cell lesions and 19 atypical ducal hyperplasia lesions arising in columnar cell lesions were included, as well as cases of UDH, Blunt duct adenosis (BDA), DCIS, lobular neoplasia (LN) and invasive carcinoma.

Table 1. Overview of gains and losses identified in different molecular studies on columnar cell lesions of the breast.

chromosomal arm	Author	LOH/CHG/ FISH	DNA marker	Location	Type of CCL	Gains (G) / Loss (L)	Frequency	Absolute numbers
1q	Simpson(9)	CGH			CCL -	L	4%	1/25
	Simpson(9)	CGH			CCL +	G	10%	1/10
3p	Dabbs(36)	LOH	D3S1539	3p26.3	Hyperplastic CCL -	-	0%	0/3
	Dabbs(36)	LOH	D32303	3p25.3	Hyperplastic CCL -	-	0%	0/3
	Simpson(9)	CGH			CCL -	L	4%	1/25
	Ellsworth(30)	LOH	D3S1566	3p14.1	CCL -/+	-	12%	5/42
	Moinfar(31)	LOH	D3S1300	3p14.2	CCL +	-	50%	5/10
	Simpson(9)	CGH			CCL +	-	0%	0/10
	Dabbs(36)	LOH	D3S1539	3p26.3	CCL + and ADH	-	7%	1/15
	Dabbs(36)	LOH	D32303	3p25.3	CCL + and ADH	-	0%	0/15
8p	Aulmann(35)	LOH	D8S264	8p21	CCL +	-	75%	15/20
	Simpson(9)	CGH			CCL +	G	10%	1/10
9q	Dabbs(36)	LOH	D9S252	9q22.1	Hyperplastic CCL -	-	33%	1/3
	Dabbs(36)	LOH	D9S252	9q22.1	CCL + and ADH	-	27%	4/15
	Simpson(9)	CGH			CCL +	G	10%	1/10
11q	Simpson(9)	CGH			CCL -	L	12%	3/25
	Simpson(9)	CGH			CCL -	G	8%	2/25
	Moinfar(31)	LOH	D11S1818	11q22-23	CCL +	-	33%	1/3
	Moinfar(31)	LOH	D11S1311	11q21-23.2	CCL +	-	50%	3/6
	Simpson(9)	CGH			CCL +	-	0%	0/10
	Aulmann(35)	LOH	D11S1311	11q14	CCL +	-	35%	6/17

Table 1. Continued

chromosomal arm	Author	LOH/CHG/ FISH	DNA marker	Location	Type of CCL	Gains (G) / Loss (L)	Frequency	Absolute numbers
16p	Simpson(9)	CGH			CCL -	G	16%	4/25
	Simpson(9)	CGH			CCL +	G	20%	2/10
16q	Simpson(9)	CGH			CCL -	L	32%	8/25
	Go(39)	FISH		16q12.3-13; 16q22.1; 16q23.2	CCL -	L	0%	0/19
	Ellsworth(30)	LOH	-	16q11.2 – 22.1	CCL -/+	-	7%	3/42
	Ellsworth(30)	LOH	-	16q22.3 – 24.3	CCL -/+	-	5%	2/42
	Moinfar(31)	LOH	D16S518	16q23.1-24.2	CCL +	-	33%	2/6
	Moinfar(31)	LOH	D16S402	16q24.2	CCL +	-	27%	3/11
	Aulmann(35)	LOH	D16S539	16q24	CCL +	-	27%	3/11
	Aulmann(35)	LOH	D16S2624	16q22.3	CCL +	-	46%	11/24
	Simpson(9)	CGH			CCL +	L	40%	4/10
	Stacher(38)	Array CGH			CCL +	L	70%	7/10
	Go(39)	FISH		16q12.3-13	CCL +	L	20%	2/10
	Go(39)	FISH		16q22.1	CCL +	L	10%	1/10
	Go(39)	FISH		16q23.2	CCL +	L	10%	1/10
17p	Dabbs(36)	LOH	D17S974+D17S1289	17p13.1	Hyperplastic CCL -	-	0%	0/3
	Simpson(9)	CGH			CCL -	L	4%	1/25
	Ellsworth(30)	LOH	-	17p13.3	CCL -/+	-	10%	4/42
	Ellsworth(30)	LOH	-	17p13.1	CCL -/+	-	0%	0/42
	Simpson(9)	CGH			CCL +	L	30%	3/10
	Stacher(38)	Array CGH			CCL +	L	20%	2/10
	Dabbs(36)	LOH	D17S974+D17S1289	17p13.1	CCL + and ADH	-	13%	2/15

Table 1. Continued

chromosomal arm	Author	LOH/CHG/ FISH	DNA marker	Location	Type of CCL	Gains (G) / Loss (L)	Frequency	Absolute numbers
	Dabbs(36)	LOH	D17S907	17q12	Hyperplastic CCL -	-	0%	0/3
	Simpson(9)	CGH			CCL -	G	12%	3/25
	Ellsworth(30)	LOH	-	17q12-21	CCL -/+	-	15%	6/42
17q	Moinfar(31)	LOH	D17S791	17q21.3	CCL +	-	14%	1/7
	Moinfar(31)	LOH	D17S785	17q24	CCL +	-	30%	3/10
	Simpson(9)	CGH			CCL +	L/G	0%	0/10
	Dabbs(36)	LOH	D17S907	17q12	CCL + and ADH	-	27%	4/15

Columnar cell lesions and relations with other lesions in the (intra)ductal neoplasia spectrum

Morphology

The difference between CCL and ADH is essentially only architectural atypia (complexity) such as well-developed arcades, bridges and micropapillary formations.(12) The spectrum of CCL and ADH has often been described.(2, 40-45) An extensive ADH lesion (>2 mm) can be classified as low-grade DCIS (12). ADH and DCIS are frequently found in close proximity or in direct continuity with CCLs and the lesions have similar cytonuclear features (especially those with atypia).(11, 22, 31, 39, 41-44, 46, 47) The calcifications of CCLs show similarities with calcifications in DCIS(22). Tubular carcinoma as well is often associated with CCLs with atypia and coexisting DCIS, shows similar cytonuclear features.(7, 21, 22, 31, 46, 48-50) The triad comprising tubular carcinoma, LCIS and CCL in breast tissue is usually called the "Rosen Triad". (51) Next to the association of CCLs with pure tubular carcinoma, CCLs are also associated with other low grade ductal type carcinomas.(13, 20, 48, 52) Moreover, CCLs with atypia are only infrequently associated with high grade DCIS, DCIS with necrosis or high grade invasive ductal carcinomas(20, 42, 44, 53) , in these cases they might not be related.

Protein expression

Protein expression (hormone receptors, cell cycle proteins and keratins) of CCLs, ADH, low grade DCIS and low grade invasive ductal carcinomas largely correspond.(2, 22, 27, 54) Individual correlation of marker expression of coexisting lesions is also frequently seen(20, 21, 29). CyclinD1 and ER-α/ER-β showed progression in the sequence from CCL to ADH, DCIS and invasive carcinoma, suggesting that CCLs are the first step in this sequence.(20, 55)

Molecular changes

Several times a clonal relationship between CCLs and coexisting lesions (DCIS and invasive ductal carcinoma) has been demonstrated.(7, 31, 35, 37) Also multiple genetic and epigenetic changes found in ADH, DCIS invasive ductal carcinomas, interpreted as oncogenic, are found in CCLs, supporting the idea of CCL as a precursor lesion. At the molecular level, CCL and ADH seem to be most related. Similar changes by microarray in several HER family genes(8) and methylation levels of 15 selected CpG island loci (breast cancer specific)(33) have been found in CCLs and ADH. On the other hand, CGH detected more genomic gains in ADH compared to CCLs with atypia(9) and also $p16^{INK4a}$ was significantly more methylated in ADH compared to CCLs with atypia.(55) As expected, the genetic and epigenetic changes in DCIS and invasive ductal carcinoma usually show progression compared to CCLs.(9, 31, 34, 36, 39)

Columnar cell lesions and relations with other lesions in the lobular neoplasia spectrum

Morphology

A number of authors have noted an association between CCLs and LN, consisting of lobular carcinoma *in situ* and atypical lobular neoplasia.(13, 21, 40, 42, 43, 45, 48, 50-53, 56-59) The combination CCLS and LN is also part of the "Rosen Triad".(51) CCLs show multifocality and bilaterality, similar to LN(56, 59, 60) and both lesions are often located in close proximity. CCLs are sometimes even seen in the same TDLU as the LN (57) [figure 5]. Although other authors propose that there is no topographic relation between LN and CCL(56). Unlike the morphological spectrum of CCLs with ADH and DCIS, CCL and LN do not represent a morphologic continuum. Usually the transition between both lesions is clear [figure 5]. However, cytonuclear similarities with the cells in LN are also seen. Part of CCLs contain cytoplasmic vacuoles, as seen in LN [figure 5C].(61-63)

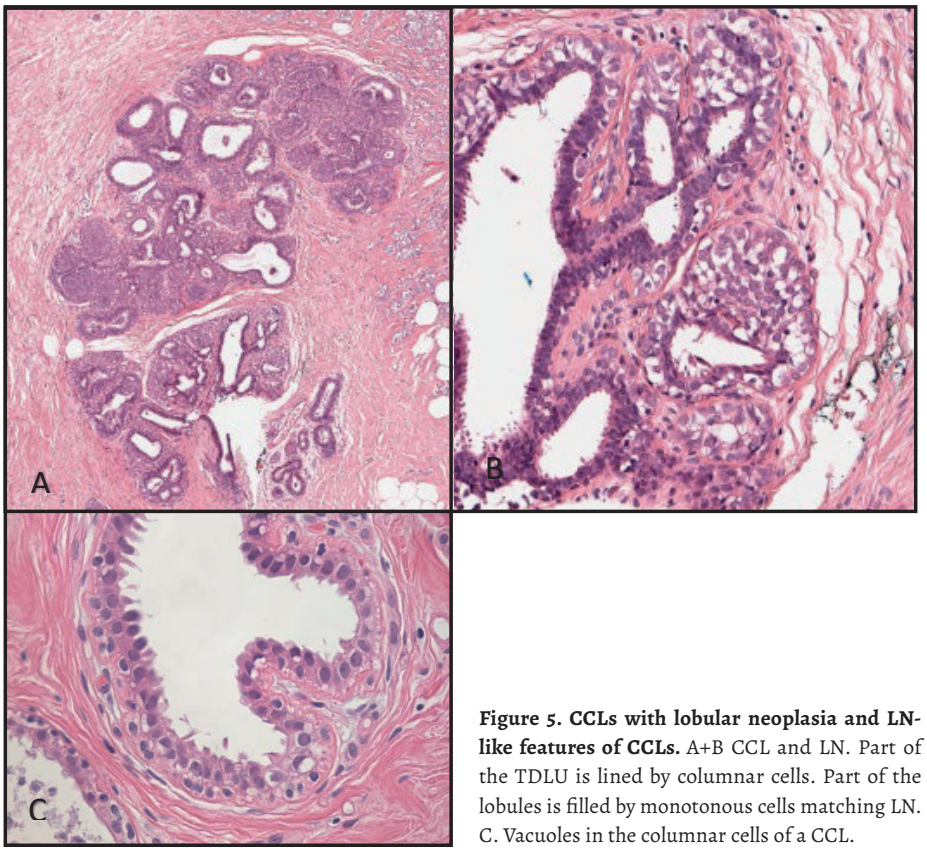

Figure 5. CCLs with lobular neoplasia and LN-like features of CCLs. A+B CCL and LN. Part of the TDLU is lined by columnar cells. Part of the lobules is filled by monotonous cells matching LN. C. Vacuoles in the columnar cells of a CCL.

In invasive lobular carcinoma (ILC) cases, co-occurrence of CCL in 60% has also regularly been described(20, 48). The co-existence between CCLs and ILC is less often described than the co-existence of CCLs and LN and probably the relation between CCLs and ILC is due to the relation between CCLs and LN.

Protein expression

The hallmark of LN, loss of E-cadherin expression, is inconclusive in CCLs. Dessauvagie et al. describe a significantly reduced E-cadherin IHC staining in CCLs, compared to normal breast epithelium, but surprisingly, there was a weak negative correlation between E-cadherin loss and co-existence with LN.(21) The reduced E-cadherin staining was not confirmed by Abdel-Farah et al. (20)

Molecular changes

Molecular similarities of LN and CCLs have been found by array CGH in which LN and simultaneous CCLs had frequent 16q losses and 1q gains.(9, 38) In some single cases also clonality between LN and CCL in the same patient was confirmed.(7, 31) The morphological and molecular evidence supports the idea that LN can evolve from CCLs and that thereby CCLs play a role in lobular carcinogenesis.

Columnar cell lesions and the relation with mucocele like lesion

Mucocele like lesions (MLLs) are mucin-containing cystically dilated acini, lined by flat or low cuboidal epithelium with or without extravasated mucin ("mucinous dissection"). MLLs are associated with atypical lesions (ADH and LN) (64) and MLLs in morphological continuum with CCLs or accompanying CCLs have been described. (65-67) Biopsies with mucinous dissection often contain CCLs.(65, 68) Our group first described the mucinous variant of CCL as presence of mucin in the lumina of the acini of CCL, often combined with mucinous dissection in the surrounding stroma [figure 6].(69) The frequency of mucinous CCLs was relatively rare, being 0.5% in all CNBs and 5.8% of the studied CCLs. Mucinous CCLs seem to be significantly more often associated with invasive mucinous carcinomas compared to invasive ductal carcinomas, implying that they may be precursors of mucinous carcinoma.(69)

Protein expression

Few data are present on protein expression of MLL and the mucinous variant of CCLs. The latter expresses MUC2 in 33% of cases, which is typically also expressed in the cytoplasm of tumor cells in mucinous carcinoma.(69-75)

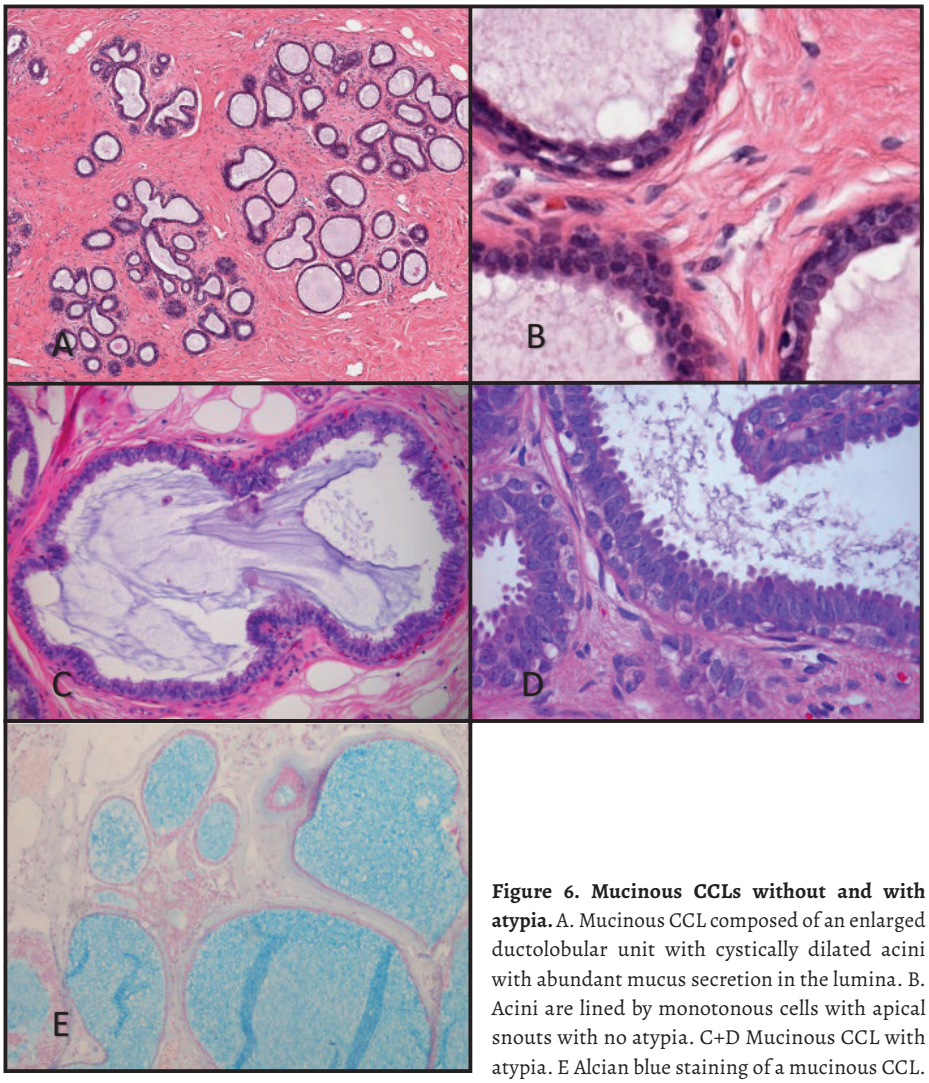

Figure 6. Mucinous CCLs without and with atypia. A. Mucinous CCL composed of an enlarged ductolobular unit with cystically dilated acini with abundant mucus secretion in the lumina. B. Acini are lined by monotonous cells with apical snouts with no atypia. C+D Mucinous CCL with atypia. E Alcian blue staining of a mucinous CCL.

Molecular changes

Molecular studies on MLL and mucinous CCL versus mucinous carcinomas are rare. Given the potential precursor role of (mucinous) CCLs in the carcinogenesis of mucinous carcinoma, it would be interesting to know if there are similarities in molecular alterations between CCLs, MLL and mucinous carcinoma. However, mucinous carcinoma of the breast is genomically distinct from invasive ductal carcinomas of no special type by showing fewer genetic changes.(76, 77) Different chromosomal loci (3p, 6p, 9p, 16q, 17p and 17q) showed significantly lower LOH in mucinous cancers compared to invasive ductal cancers.(76) Mucinous carcinoma also

less often displayed whole arm gains of 1q and 16p and whole arm losses of 16q and 22q by high-resolution microarray-based comparative genomic hybridization, although partial loss of chromosome 16q was frequently seen in mucinous carcinomas.(77) This gives rise to the idea that mucinous CCLs probably have a different genetic profile than non-mucinous CCLs, although to our knowledge, this has never been tested. Only one study evaluated chromosomal alterations in CCLs associated with mucinous carcinoma, however it is not clear if these CCLs were mucinous CCLs. In this study, a panel of point mutations tested by multiplex polymerase chain reaction showed a PIK3CA mutation in one of five CCLs, while the associated mucinous carcinoma did not harbour this mutation.(78) Given the small numbers of CCLs studied and uncertainty regarding the mucinous nature of the CCLs, the latter article in our opinion does not disprove the precursor role of (mucinous) CCLs.

Clinical implications of columnar cell lesions

The use of (digital) mammography as screening tool has resulted in an increased number of breast biopsies diagnosed with CCLs.(79, 80) On mammography, CCLs characteristically presents as small, often clustered, amorphous or fine pleomorphic calcifications.(81) The lesions are mostly classified as BIRADS III or IV and often a biopsy is taken to exclude atypical ductal hyperplasia (ADH), ductal carcinoma *in situ* (DCIS), or invasive carcinoma.(81)

In patients with microcalcifications on mammography that undergo CNBs, 8% show CCLs without atypia and roughly 2% atypical CCL.(79) Columnar cell lesions without atypia are associated with only a slightly increased risk for subsequent development of breast cancer (RR: ~1.5) (40, 82) and an 8-years progression risk of 2% (83). There is also an association with (*in situ*) carcinoma in the subsequent excision in 1.5% of cases, also referred to as “upgrade rate”. (84) The American Society of Breast Surgeons guideline states that surgical excision is unnecessary for pure columnar cell hyperplasia, identified on CNB (85)

According to several systematic reviews and meta-analyses CCLs with atypia in CNB have a pooled upgrade rate of 5-11%.(84, 86-88) These (in situ) carcinomas usually concern lesions from the low nuclear grade breast neoplasia family such as invasive tubular cancer and lobular carcinoma in situ, low grade ductal carcinoma in situ and other low grade invasive cancers such as cribriform, mucinous and no special type (NST) cancers. When more than 90% of the calcifications were removed at CNB, the pooled upgrade rate was 0%.(86) Although the meta-analysis with a pooled upgrade

rate of 5-11% may support advising surgical excision, the need for routine surgical excision after a diagnosis of CCL with atypia on core needle biopsy is a matter of debate. Surgical excision may not be necessary if a post-biopsy mammogram shows that all of the radiographical microcalcifications have been removed.(86, 89) Removal of all micro-calcifications by vacuum-assisted biopsy or Breast Lesion Excision System may be considered. (84) The American Society of Breast Surgeons guideline recommends observation with imaging and clinical follow-up for pure CCLs with atypia/FEA (85) and excision if there is concurrent ADH.

Columnar cell lesions in the male breast

Whether CCLs occur in male breast is still a matter of debate. A paper described "CCL-like changes"(i.e. apical snouts) in 39 out of 71 consecutive surgical resections from men, most for gynecomastia.(90) However, intraluminal secretions or calcifications, features typical of CCL, were not detected. Immunohistochemically, these "columnar" epithelial cells were negative for CK5/6 in 38/39 cases as expected. At difference with CCLs described in the female breast, ER expression was heterogeneous. In our own study, 89 surgical resections from 88 male patients with breast cancer, 20 gynaecomastia and 5 normal breast specimens from autopsies were reviewed for the presence of CCLs, supplemented by IHC for CK5/6, CK14 and ER. In all types of specimens, we found no lesions with convincing CCL morphology, although occasional apical snouts were seen in the luminal layer. However, we found some ducts with clonally negative CK5/6 luminal cells, which we interpreted as putative male breast cancer precursors lesions, but we do not believe these to be the male counterparts of female CCLs.(91)

Differential diagnosis

Like any morphologically defined precursor lesion, characteristics of CCL are not unambiguously defined, since it is part of a morphological spectrum of benign or premalignant breast lesions with partly overlapping features [figure 7]. The diagnosis of CCLs can be challenging and reproducibility is not optimal.(3-5)

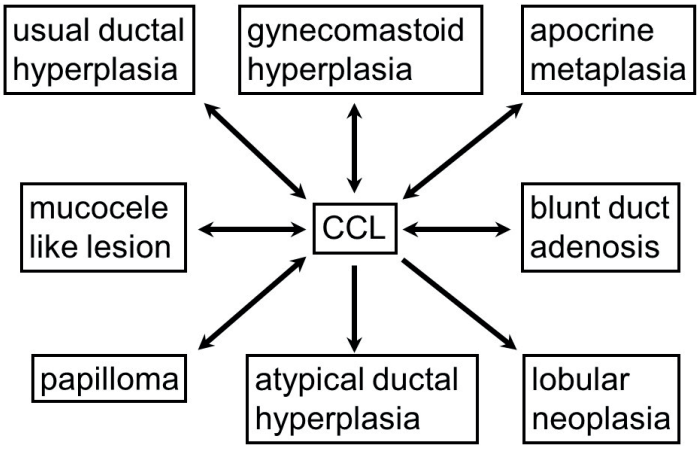

Figure 7. The morphological spectrum of columnar cell lesions of the breast

Columnar cell lesions versus blunt duct adenosis

Terminology and morphology

The earliest description of BDA was by Foote and Stewart in 1945.(92) In 1976, Azzopardi more extensively described BDA as a proliferative benign lesion of the enlarged terminal duct lobular unit (TDLU) not indicating increased risk of malignancy.(93) Throughout recent decades, further literature descriptions of blunt duct adenosis have been confusing leading to widespread discussions among breast pathologists wot regard to this diagnosis. In the literature concerning CCLs, BDA was in the past often considered as a synonym or a growth pattern of CCL(2, 94), independent of atypia. The World Health Organization (WHO) Classication of tumours of the breast, 2012 Edition, considers BDA as a synonym of columnar cell change (CCC)/hyperplasia (CCH), a category for which cytological atypia is not a feature(95). Thereby, BDA is distinguished from FEA, for which cytonuclear atypia is the hallmark feature. This is also adopted in most recent textbooks about breast pathology, usually without further morphological descriptions. The 2019 WHO edition, however, clearly states that BDA is “not recommended terminology” for CCL.(12) Nevertheless, in some textbooks we found a more detailed description of BDA, and also different types or different stages of BDA were distinguished. Whether BDA and CCL need to be viewed as separate entities, and if so based on which morphological and molecular critaria, needs to further clarified. Therefore, in **Chapter 5**, we propose strict morphologic criteria for BDA [figure 8].

Protein expression

Proposals for differentiating between BDA and FEA with immunohistochemical stainings have been put forward in several papers. BDA luminal cells express glandular keratins such as CK7, CK8, or CK18. CK5 and CK14 should display a mosaic pattern especially by small knots of hyperplastic cells protruding into the lumen while CCLs are clonally negative(96, 97). Erα is often expressed in a high percentage of the luminal cells of BDA, so this does not help much to discriminate BDA Erα patterns from the (clonally) positive Erα expression in CCL.(96) There seems to be less Cyclin D1 expression in BDA compared to CCL with atypia/FEA, although not all CCLs are cyclin D1 positive(22). In our own practice, we usually see a quite low number of CK5 and CK14 positive cells in flat parts of BDA, while Erα is expressed in the majority of cells, meaning that there is no striking mosaic pattern and the lesion can be misinterpreted as clonal. In BDA with areas of UDH with more luminal proliferating cells the immunohistochemical profile more clearly points toward a polyclonal proliferation. Altogether, immunohistochemical stainings do therefore not seem to play a major role in differentiating CCLs and BDA.

Molecular changes

An overview of the molecular characteristics of BDA is obscured by the confusing terminology in various studies seemingly addressing BDA but in fact probably concerning CCLs. Therefore, we studied 16q losses in a group of morphologically well-defined BDA lesions in **Chapter 4**.

Columnar cell lesions versus usual ductal hyperplasia

Morphology

Usual ductal hyperplasia (UDH) is associated with a moderately elevated breast cancer risk and the role of UDH in evolution of breast cancer has been debated in recent decades. (98-102) These days it is generally accepted that the vast majority of UDH lesions are benign, polyclonal lesion and risk indicators for malignancy rather than precursor lesions of breast cancer.(103) Morphologically, UDH differs from CCL by a disorderly and streaming proliferation of epithelial cells with formation of irregular, peripheral secondary lumina in ducts or acini with irregular spacing, size and shape, with no polarization of nuclei around the lumina. The cell proliferation may consist of different cell types. These cells have inconspicuous cell borders and overlapping nuclei (thereby not having their own cytoplasmic “domain”). The nuclei vary in size and shape with only small nucleoli. The cells rarely become truly atypical and microcalcifications are rarely seen.(12, 104, 105) The periphery of a UDH lesion

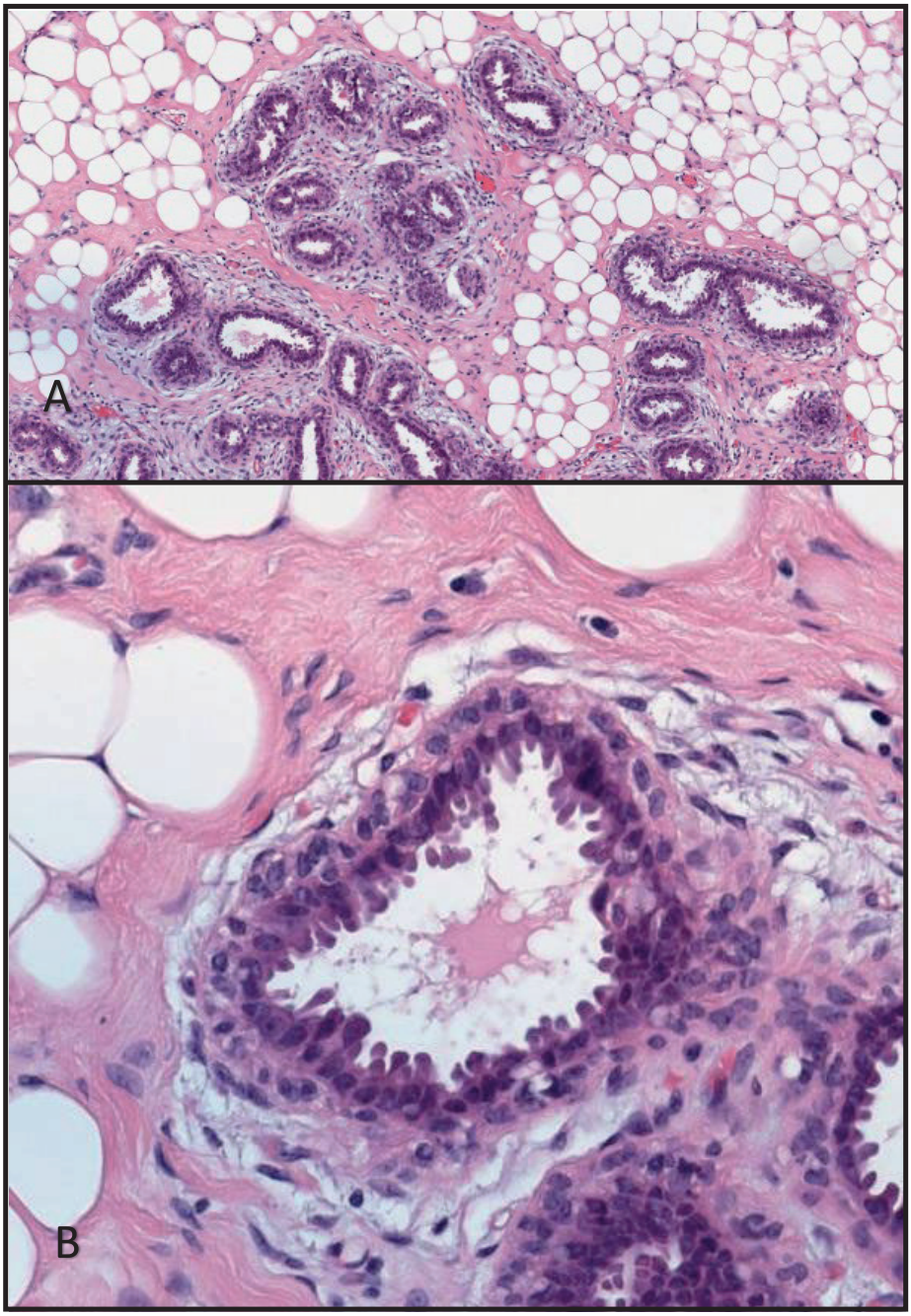

Figure 8. Blunt duct adenosis. A. Enlarged ductolobular unit with irregular, branching, acinic structures. B. The acinic structures are lined by columnar-like cells with luminal snouts and slightly enlarged ovoid nuclei with scattered nucleoli. Myoepithelial cells are prominent and the intralobular stroma shows increase in cellularity.

can contain cells with apical snouts, [Figure 9].(106) Difficulties with differentiating CCLs and UDH may arise in smaller lesions with a few layers of disorderly epithelium with enlarged nuclei with nucleoli and apical snouts, which may simulate atypical CCLs. Once the architecture becomes complex with cribriform patterns, UDH needs to be distinguished from ADH or DCIS.

The combination of CCL and UDH is however often seen in the same patients, sometimes in remarkable proximity.(35, 107) Goldstein et al. describe cytologically identical cells in UDH and associated CCLs and the authors therefore suggest that CCLs may originate from UDH.(107) The authors do not describe the presence of atypia in the CCLs associated with UDH. In our practice we have not seen "true" atypia in CCLs merging into UDH and in our opinion these pseudocolumnar cell like changes are to be considered as an occasional feature of UDH.

Protein expression

The columnar cells at the periphery of UDH lesions can have some CCL-like protein expression features meaning that they are uniformly strongly positive for ER and Bcl-2 and negative for CK5/6.(12, 23, 24, 106) However, the center of the UDH lesion then still has a characteristic and distinctive IHC profile with heterogeneity in ER expression, a mosaic staining pattern of basal keratins (CK5/6 and CK14) and Bcl-2, matching the polyclonal nature of the lesion.(23, 24, 108) CCLs are clonally negative for CK5/6 and CK14, although in 25% sporadic elongated basal keratin positive (CK5/6 and CK14) and hormone negative (ER and PR) luminal cells have been described in CCLs, which are in the third dimension often attached to the basal layer and in some cases enter the lumen of the duct.(9, 109) These cells, in our view, are not part of the clonal CCL but "residual" luminal cells that are also often seen in DCIS and BDA.

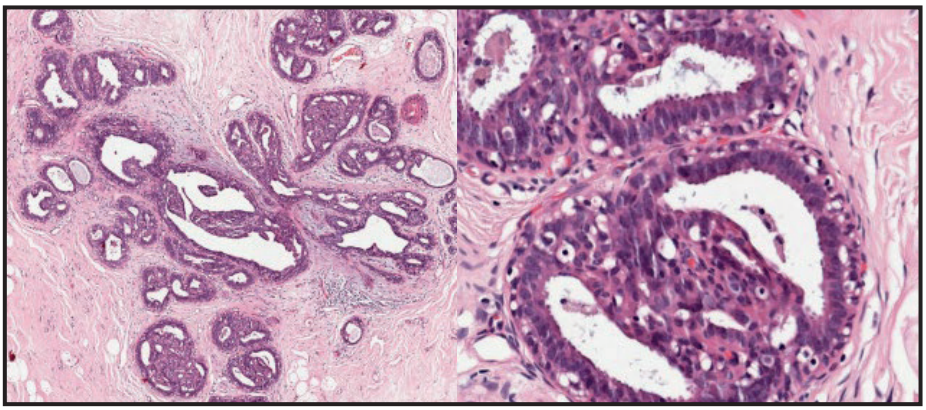

Figure 9. Usual ductal hyperplasia with some peripheral columnar cell-like snouting

Molecular changes

In UDH conflicting results on the presence of genetic/chromosomal alterations have been published.(100, 101, 110-115) The polyclonal aspect of the lesion and the lack of uniform chromosomal aberrations contribute the idea that the majority of UDH lesions are risk indicators and no true precursor lesions.

CCL versus apocrine metaplasia

Morphology

Apocrine metaplastic (AM) lesions need to be distinguished from CCLs. Both CCLs and AM have columnar cells and apical cytoplasmic snouts/blebs, although apocrine cells possess more abundant, granular and more strongly eosinophilic/pink cytoplasm. In addition, the nuclei of CCLs tend to be ovoid whereas those of apocrine lesions are round, usually with a prominent nucleolus. No secretion is seen in apocrine lesions, and calcium phosphate microcalcifications are rare.

Little is known about the relation and possible interaction between AM and CCLs, whereas they may be in close proximity and a transition between CCL and AM may be seen.(116, 117) In addition, CCLs with apocrine features have also been described.(2) Only one article describes the relation between apocrine lesions and CCLs with atypia. In this article, the coexistence of papillary AM and CCLs is described in 19.5% of cases, often in continuity or adjacent to each other, having "transitional cells" with characteristics of both AM and CCL.(117) A striking conclusion was the association of the close relationship of AM and CCLs with atypia and the simultaneous presence of low grade, ER and PR receptor positive neoplasia.(117) This association has never been confirmed by other authors and implications are not clear.

Protein expression

Immunohistochemistry clearly differentiates between CCLs and AM, with ER, PR and Bcl-2 positivity in CCLs, while those are negative in AM.(11, 116) Androgen receptor (AR) expression in CCLs is focal while in AM there is a strong nuclear overexpression.(21, 118) AM usually shows strong positive BRST-2 (GCDFP15/PIP) expression throughout, but this strong expression can also be seen in CCLs, especially in CCLs arising in continuity with AM.(116, 119) Finally, AM is known to have strong and diffuse Cyclin D1 expression. (116), although CCLs can also have an increased Cyclin D1.(20, 55)

Molecular changes

At the molecular level, several chromosomal changes found in a subset of lesions with apocrine morphology show similarities with changes found in CCLs. This concerns chromosomes 11q, 16q, 17q and 22q.(31, 35-38, 115, 120, 121) This implies that some apocrine lesions may have the same progenitor role as CCLs, or possibly CCLs and a subset of apocrine lesions can evolve from each other.

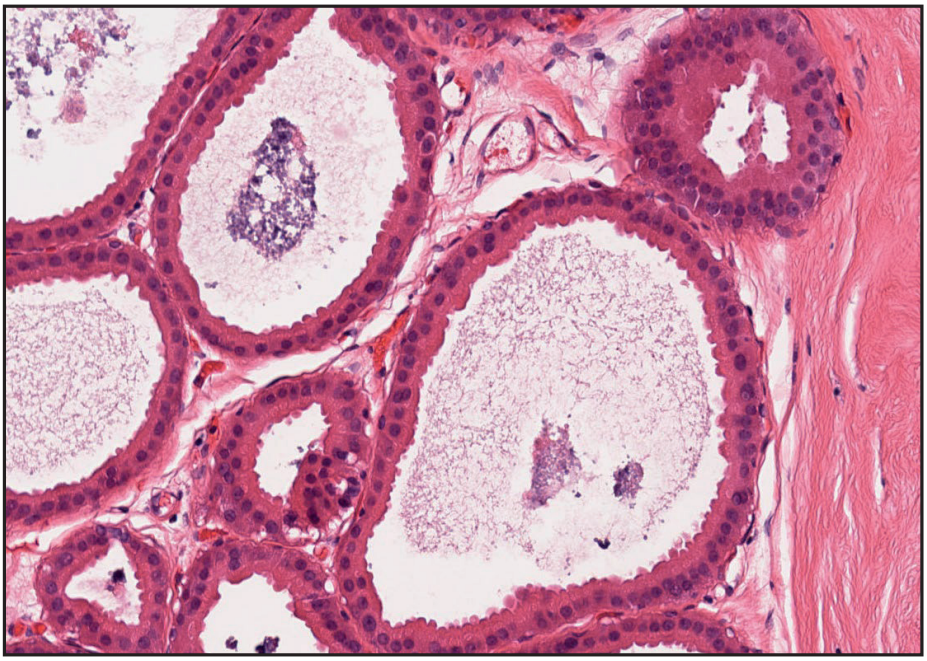

Figure 10. Apocrine metaplasia typical example of apocrine metaplasia at high magnification.

Columnar cell lesions versus intraductal papilloma

According to the 2019 World Health Organization (WHO) Classification of Tumours, intraductal papillomas are characterized by a cohesive but arborescent structure composed of fibrovascular cores covered by a layer of myoepithelial cells with overlying luminal epithelial cells.(12) The epithelial component may consist of one layer of cuboidal to cells or may show foci of UDH. Apocrine changes are frequently found. Also papillomas with areas of ADH and DCIS have been described. In papillomas with ADH and DCIS, there is a focal luminal cell population with cytological and architectural features of (usually) low-grade ductal neoplasia. These atypical epithelial cells usually show lack of staining for high-molecular weight keratins with uniform positivity for the estrogen receptor. (122, 123) While CCLs are regarded as precursors

of ADH and DCIS, CCLs have to our knowledge not been described in papillomas, also not in those with ADH or DCIS. In view of the role of CCLs in the intraductal neoplasia progression spectrum, it would however make sense that CCL-like changes would occur in papillomas, especially in those with ADH or DCIS.

In **Chapter 6**, we indeed describe two papillary breast lesions with fibrovascular cores lined by a single layer of monotonous luminal cells throughout the lesions, morphologically resembling the monoclonal cells of atypical CCL/flat epithelial atypia (FEA). We compared these two lesions with 13 morphologically benign intraductal papillomas with limited UDH and two papillomas with areas with ADH/DCIS grade 1 features. All lesions were immunohistochemically stained for the ER, PR, CK5 and Cyclin D1.

Conclusion

Because of confusing terminology and different classifications, reliable comparative research of CCLs and other lesions has been obscured. The importance of a solid classification system with objective and reproducible characteristics is not only of research interest but also of clinical significance, especially because of the precursor role of CCLs. Unfortunately, so far there are no IHC or molecular markers which can distinguish between CCLs without atypia and CCLs with atypia, and this will for now have to rely on imperfect and subjective morphologic criteria.

Table 2. Differential diagnosis of CCL vs. other benign and premalignant lesions of the breast by histological criteria

	CCL without atypia	**CCL with atypia**	**BDA**	**MLL**	**UDH**	**AM**
Shape of acini/ducts	Round to oval	Round to oval	Irregular, tubular	Round to oval	Irregular	Round to oval
Architecture	Flat, tufts or mounds	Flat, tufts or mounds; No well-formed bridges and papillary structures	Flat, tufts or mounds	Flat	Lumina filled with a streaming proliferation of epithelial cells, usually with formation of secondary peripheral lumina	Flat or micropapillary
Stratification	Present in CCL with hyperplasia	May be present	Mild stratification may be present	-	+	-
Conspicuous cell borders	+	+	-	-	-	-
Luminal snouting	+	+	+	-	Occasional in peripheral cells	+
Intracytoplasmic vacuoles	Rare	Rare	-	-	-	-
Dimorphic cell population "Pale cells"	-	More frequent	-	-	-	-
Myoepithelium	Inconspicuous	Inconspicuous	Conspicuous	Inconspicuous	Conspicuous	Inconspicuous
Overlapping nuclei	-	-	Slightly	-	+ (especially central cells)	-
Nuclear arrangement	Regular	Regular or disorderly	Disorderly	Regular	Disorderly	Regular
Nuclear size	Monotonous, small	Monotonous or variable; enlarged	Slightly variable, slightly enlarged	Monotonous	Highly variable; slightly enlarged	Monotonous
Nuclear shape	Elongated/oval	Oval to round	Round to oval, slightly irregular	Round to oval	Round to oval, irregular	Round

Table 2. Continued

	CCL without atypia	CCL with atypia	BDA	MLL	UDH	AM
Nucleoli	Inconspicuous; Small	May be conspicuous	Small to prominent	Small	Small	Prominent
Position of nuclei	Basal	Usually central	Basal	Central	Peripheral cells: basal	Central
Microcalcifications	+	+	+	Frequent	Rare	Calcium oxalate
Luminal secretion	+	+	+	+	Rare	Rare
Luminal mucin	Rare	Rare	-	Always	-	-
Intralobular stroma	normal	normal	Expanded and mildly cellular, often myxoid	Normal; sometimes mucinous dissection	normal	normal

+ = usually present; +/- = may be present; - = not present

Table 3. Differential diagnosis of CCL versus other benign and premalignant lesions of the breast by immunohistochemistry

	CCL (with and without atypia)	BDA	UDH	AM
ER and PR	+ (uniformly)	+ (uniformly)	Mosaic pattern	-
CKHMW, CK5/6, CK14	- (uniformly)	Conspicuous residual cells and mosaic in hyperplastic areas	Mosaic pattern	-
Cyclin D1	+/-	-	-	+

Subt. + = (over)expression; +/- = may be (over)expressed; - = negative

Summary of research questions for this thesis

As outlined above in the overview of the literature on CCL and related lesions, several questions remain that we will answer in the remainder of this thesis.

In **Chapter 2**, we review genetic events in the low nuclear grade breast neoplasia family. Loss of 16q is turns out to be the hallmark molecular aberration.

In **Chapter 3**, we systematically retrospectively evaluate the presence of pale cells in a group of ADH and CCL lesions to cover the earliest spectrum of the low nuclear grade precursor lesions, in search of further morphological features of CCLs related to the designation cellular "atypia".

In **Chapter 4**, we analyze copy number changes on chromosome 16q by multiplex ligation-dependent probe amplification (MLPA) in CCLs and ADH lesions arising in CCLs, in comparison with cases of UDH, BDA, DCIS, LN and invasive carcinoma.

In **Chapter 5**, we propose strict morphologic criteria for BDA that, when uptaken by the international breast pathology community, may contribute to a better definition of BDA and form a better foundation for molecular studies.

In **Chapter 6**, we describe for the first time two papillary breast lesions with fibrovascular cores lined by a single layer of monotonous luminal cells throughout the lesions, morphologically resembling the monoclonal cells of atypical CCL/flat epithelial atypia (FEA). For these lesions, we propose the term papillary FEA.

References

1. Schnitt SJ. The diagnosis and management of pre-invasive breast disease: flat epithelial atypia--classification, pathologic features and clinical significance. Breast Cancer Res. 2003;5(5):263-8.
2. Kunju LP, Kleer CG. Significance of flat epithelial atypia on mammotome core needle biopsy: Should it be excised? Hum Pathol. 2007;38(1):35-41.
3. Gomes DS, Porto SS, Balabram D, Gobbi H. Inter-observer variability between general pathologists and a specialist in breast pathology in the diagnosis of lobular neoplasia, columnar cell lesions, atypical ductal hyperplasia and ductal carcinoma in situ of the breast. Diagn Pathol. 2014;9:121.
4. Haupt B, Schwartz MR, Xu Q, Ro JY. Columnar cell lesions: a consensus study among pathology trainees. Hum Pathol. 2010;41(6):895-901.
5. Tan PH, Ho BC, Selvarajan S, Yap WM, Hanby A. Pathological diagnosis of columnar cell lesions of the breast: are there issues of reproducibility? J Clin Pathol. 2005;58(7):705-9.
6. O'Malley FP, Mohsin SK, Badve S, Bose S, Collins LC, Ennis M, et al. Interobserver reproducibility in the diagnosis of flat epithelial atypia of the breast. Mod Pathol. 2006;19(2):172-9.
7. Aulmann S, Elsawaf Z, Penzel R, Schirmacher P, Sinn HP. Invasive tubular carcinoma of the breast frequently is clonally related to flat epithelial atypia and low-grade ductal carcinoma in situ. Am J Surg Pathol. 2009;33(11):1646-53.
8. Lee S, Medina D, Tsimelzon A, Mohsin SK, Mao S, Wu Y, et al. Alterations of gene expression in the development of early hyperplastic precursors of breast cancer. Am J Pathol. 2007;171(1):252-62.
9. Simpson PT, Gale T, Reis-Filho JS, Jones C, Parry S, Sloane JP, et al. Columnar cell lesions of the breast: the missing link in breast cancer progression? A morphological and molecular analysis. Am J Surg Pathol. 2005;29(6):734-46.
10. Sinn HP, Elsawaf Z, Helmchen B, Aulmann S. Early Breast Cancer Precursor Lesions: Lessons Learned from Molecular and Clinical Studies. Breast Care (Basel). 2010;5(4):218-26.
11. Fraser JL, Raza S, Chorny K, Connolly JL, Schnitt SJ. Columnar alteration with prominent apical snouts and secretions: a spectrum of changes frequently present in breast biopsies performed for microcalcifications. Am J Surg Pathol. 1998;22(12):1521-7.
12. World Health O, International Agency for Research on C. Breast tumours. Lyon: International Agency for Research on Cancer; 2019.
13. Kunju LP, Ding Y, Kleer CG. Tubular carcinoma and grade 1 (well-differentiated) invasive ductal carcinoma: comparison of flat epithelial atypia and other intra-epithelial lesions. Pathol Int. 2008;58(10):620-5.
14. Recavarren RA, Chivukula M, Carter G, Dabbs DJ. Columnar cell lesions and pseudoangiomatous hyperplasia like stroma: is there an epithelial-stromal interaction? Int J Clin Exp Pathol. 2009;3(1):87-97.
15. Petersson F, Tan PH, Putti TC. Low-grade ductal carcinoma in situ and invasive mammary carcinoma with columnar cell morphology arising in a complex fibroadenoma in continuity with columnar cell change and flat epithelial atypia. Int J Surg Pathol. 2010;18(5):352-7.

16. Yamashita Y, Ichihara S, Moritani S, Yoon HS, Yamaguchi M. Does flat epithelial atypia have rounder nuclei than columnar cell change/hyperplasia? A morphometric approach to columnar cell lesions of the breast. Virchows Arch. 2016;468(6):663-73.
17. Katayama A, Toss MS, Parkin M, Sano T, Oyama T, Quinn CM, et al. Nuclear morphology in breast lesions: refining its assessment to improve diagnostic concordance. Histopathology. 2022;80(3):515-28.
18. Samples LS, Rendi MH, Frederick PD, Allison KH, Nelson HD, Morgan TR, et al. Surgical implications and variability in the use of the flat epithelial atypia diagnosis on breast biopsy specimens. Breast. 2017;34:34-43.
19. Ueno N, Kuroda H, Kurosumi M, Kozuka Y, Ito J, Kato H, et al. Clinicopathological study of a dimorphic variant of breast carcinoma. Breast Cancer. 2018;25(2):151-8.
20. Abdel-Fatah TM, Powe DG, Hodi Z, Reis-Filho JS, Lee AH, Ellis IO. Morphologic and molecular evolutionary pathways of low nuclear grade invasive breast cancers and their putative precursor lesions: further evidence to support the concept of low nuclear grade breast neoplasia family. Am J Surg Pathol. 2008;32(4):513-23.
21. Dessauvagie BF, Zhao W, Heel-Miller KA, Harvey J, Bentel JM. Characterization of columnar cell lesions of the breast: immunophenotypic analysis of columnar alteration of lobules with prominent apical snouts and secretions. Hum Pathol. 2007;38(2):284-92.
22. Oyama T, Iijima K, Takei H, Horiguchi J, Iino Y, Nakajima T, et al. Atypical cystic lobule of the breast: an early stage of low-grade ductal carcinoma in-situ. Breast Cancer. 2000;7(4):326-31.
23. Luna-More S, Weil B, Bautista D, Garrido E, Florez P, Martinez C. Bcl-2 protein in normal, hyperplastic and neoplastic breast tissues. A metabolite of the putative stem-cell subpopulation of the mammary gland. Histol Histopathol. 2004;19(2):457-63.
24. Tremblay G, Deschenes J, Alpert L, Quenneville LA. Overexpression of estrogen receptors in columnar cell change and in unfolding breast lobules. Breast J. 2005;11(5):326-32.
25. McLaren BK, Gobbi H, Schuyler PA, Olson SJ, Parl FF, Dupont WD, et al. Immunohistochemical expression of estrogen receptor in enlarged lobular units with columnar alteration in benign breast biopsies: a nested case-control study. Am J Surg Pathol. 2005;29(1):105-8.
26. Feriancova M, Walter I, Singer CF, Gazdarica J, Pohlodek K. Expression of COX-2, p16, and Ki67 in the range from normal breast tissue to breast cancer. Neoplasma. 2021;68(2):342-51.
27. Noel JC, Fayt I, Fernandez-Aguilar S, Buxant F, Boutemy R. Proliferating activity in columnar cell lesions of the breast. Virchows Arch. 2006;449(6):617-21.
28. Tomasino RM, Morello V, Gullo A, Pompei G, Agnese V, Russo A, et al. Assessment of "grading" with Ki-67 and c-kit immunohistochemical expressions may be a helpful tool in management of patients with flat epithelial atypia (FEA) and columnar cell lesions (CCLs) on core breast biopsy. J Cell Physiol. 2009;221(2):343-9.
29. Polat A. c-KIT expression in columnar cell lesions of the breast accompanied by benign and malignant breast diseases. Pathol Res Pract. 2007;203(11):765-9.

30. Ellsworth RE, Ellsworth DL, Weyandt JD, Fantacone-Campbell JL, Deyarmin B, Hooke JA, et al. Chromosomal alterations in pure nonneoplastic breast lesions: implications for breast cancer progression. Ann Surg Oncol. 2010;17(6):1688-94.
31. Moinfar F, Man YG, Bratthauer GL, Ratschek M, Tavassoli FA. Genetic abnormalities in mammary ductal intraepithelial neoplasia-flat type ("clinging ductal carcinoma in situ"): a simulator of normal mammary epithelium. Cancer. 2000;88(9):2072-81.
32. Qi L, Bart J, Tan LP, Platteel I, Sluis T, Huitema S, et al. Expression of miR-21 and its targets (PTEN, PDCD4, TM1) in flat epithelial atypia of the breast in relation to ductal carcinoma in situ and invasive carcinoma. BMC Cancer. 2009;9:163.
33. Park SY, Kwon HJ, Lee HE, Ryu HS, Kim SW, Kim JH, et al. Promoter CpG island hypermethylation during breast cancer progression. Virchows Arch. 2011;458(1):73-84.
34. Verschuur-Maes AH, de Bruin PC, van Diest PJ. Epigenetic progression of columnar cell lesions of the breast to invasive breast cancer. Breast Cancer Res Treat. 2012;136(3):705-15.
35. Aulmann S, Braun L, Mietzsch F, Longerich T, Penzel R, Schirmacher P, et al. Transitions between flat epithelial atypia and low-grade ductal carcinoma in situ of the breast. Am J Surg Pathol. 2012;36(8):1247-52.
36. Dabbs DJ, Carter G, Fudge M, Peng Y, Swalsky P, Finkelstein S. Molecular alterations in columnar cell lesions of the breast. Mod Pathol. 2006;19(3):344-9.
37. Simpson PT, Reis-Filho JS, Gale T, Lakhani SR. Molecular evolution of breast cancer. J Pathol. 2005;205(2):248-54.
38. Stacher E, Boldt V, Leibl S, Halbwedl I, Popper HH, Ullmann R, et al. Chromosomal aberrations as detected by array comparative genomic hybridization in early low-grade intraepithelial neoplasias of the breast. Histopathology. 2011;59(3):549-55.
39. Go EM, Tsang JY, Ni YB, Yu AM, Mendoza P, Chan SK, et al. Relationship between columnar cell changes and low-grade carcinoma in situ of the breast--a cytogenetic study. Hum Pathol. 2012;43(11):1924-31.
40. Boulos FI, Dupont WD, Simpson JF, Schuyler PA, Sanders ME, Freudenthal ME, et al. Histologic associations and long-term cancer risk in columnar cell lesions of the breast: a retrospective cohort and a nested case-control study. Cancer. 2008;113(9):2415-21.
41. Chivukula M, Bhargava R, Tseng G, Dabbs DJ. Clinicopathologic implications of "flat epithelial atypia" in core needle biopsy specimens of the breast. Am J Clin Pathol. 2009;131(6):802-8.
42. Collins LC, Achacoso NA, Nekhlyudov L, Fletcher SW, Haque R, Quesenberry CP, Jr., et al. Clinical and pathologic features of ductal carcinoma in situ associated with the presence of flat epithelial atypia: an analysis of 543 patients. Mod Pathol. 2007;20(11):1149-55.
43. Lavoue V, Roger CM, Poilblanc M, Proust N, Monghal-Verge C, Sagan C, et al. Pure flat epithelial atypia (DIN 1a) on core needle biopsy: study of 60 biopsies with follow-up surgical excision. Breast Cancer Res Treat. 2011;125(1):121-6.
44. Lee TY, Macintosh RF, Rayson D, Barnes PJ. Flat epithelial atypia on breast needle core biopsy: a retrospective study with clinical-pathological correlation. Breast J. 2010;16(4):377-83.

45. Senetta R, Campanino PP, Mariscotti G, Garberoglio S, Daniele L, Pennecchi F, et al. Columnar cell lesions associated with breast calcifications on vacuum-assisted core biopsies: clinical, radiographic, and histological correlations. Mod Pathol. 2009;22(6):762-9.
46. Goldstein NS, O'Malley BA. Cancerization of small ectatic ducts of the breast by ductal carcinoma in situ cells with apocrine snouts: a lesion associated with tubular carcinoma. Am J Clin Pathol. 1997;107(5):561-6.
47. Peres A, Barranger E, Becette V, Boudinet A, Guinebretiere JM, Cherel P. Rates of upgrade to malignancy for 271 cases of flat epithelial atypia (FEA) diagnosed by breast core biopsy. Breast Cancer Res Treat. 2012;133(2):659-66.
48. Abdel-Fatah TM, Powe DG, Hodi Z, Lee AH, Reis-Filho JS, Ellis IO. High frequency of coexistence of columnar cell lesions, lobular neoplasia, and low grade ductal carcinoma in situ with invasive tubular carcinoma and invasive lobular carcinoma. Am J Surg Pathol. 2007;31(3):417-26.
49. Rosen PP. Columnar cell hyperplasia is associated with lobular carcinoma in situ and tubular carcinoma. Am J Surg Pathol. 1999;23(12):1561.
50. Sahoo S, Recant WM. Triad of columnar cell alteration, lobular carcinoma in situ, and tubular carcinoma of the breast. Breast J. 2005;11(2):140-2.
51. Brandt SM, Young GQ, Hoda SA. The "Rosen Triad": tubular carcinoma, lobular carcinoma in situ, and columnar cell lesions. Adv Anat Pathol. 2008;15(3):140-6.
52. Fernandez-Aguilar S, Simon P, Buxant F, Simonart T, Noel JC. Tubular carcinoma of the breast and associated intra-epithelial lesions: a comparative study with invasive low-grade ductal carcinomas. Virchows Arch. 2005;447(4):683-7.
53. Bratthauer GL, Tavassoli FA. Assessment of lesions coexisting with various grades of ductal intraepithelial neoplasia of the breast. Virchows Arch. 2004;444(4):340-4.
54. Simooka H, Oyama T, Sano T, Horiguchi J, Nakajima T. Immunohistochemical analysis of 14-3-3 sigma and related proteins in hyperplastic and neoplastic breast lesions, with particular reference to early carcinogenesis. Pathol Int. 2004;54(8):595-602.
55. Liu T, Niu Y, Feng Y, Niu R, Yu Y, Lv A, et al. Methylation of CpG islands of p16(INK4a) and cyclinD1 overexpression associated with progression of intraductal proliferative lesions of the breast. Hum Pathol. 2008;39(11):1637-46.
56. Brogi E, Oyama T, Koerner FC. Atypical cystic lobules in patients with lobular neoplasia. Int J Surg Pathol. 2001;9(3):201-6.
57. Carley AM, Chivukula M, Carter GJ, Karabakhtsian RG, Dabbs DJ. Frequency and clinical significance of simultaneous association of lobular neoplasia and columnar cell alterations in breast tissue specimens. Am J Clin Pathol. 2008;130(2):254-8.
58. Gomes DS, Balabram D, Porto SS, Gobbi H. Lobular neoplasia: frequency and association with other breast lesions. Diagn Pathol. 2011;6:74.
59. Leibl S, Regitnig P, Moinfar F. Flat epithelial atypia (DIN 1a, atypical columnar change): an underdiagnosed entity very frequently coexisting with lobular neoplasia. Histopathology. 2007;50(7):859-65.

60. Martel M, Barron-Rodriguez P, Tolgay Ocal I, Dotto J, Tavassoli FA. Flat DIN 1 (flat epithelial atypia) on core needle biopsy: 63 cases identified retrospectively among 1,751 core biopsies performed over an 8-year period (1992-1999). Virchows Arch. 2007;451(5):883-91.
61. Andersen JA, Vendelboe ML. Cytoplasmic mucous globules in lobular carcinoma in situ. Diagnosis and prognosis. Am J Surg Pathol. 1981;5(3):251-5.
62. Breslow A, Brancaccio ME. Intracellular mucin production by lobular breast carcinoma cells. Arch Pathol Lab Med. 1976;100(11):620-1.
63. Gad A, Azzopardi JG. Lobular carcinoma of the breast: a special variant of mucin-secreting carcinoma. J Clin Pathol. 1975;28(9):711-6.
64. Towne WS, Michaels AY, Ginter PS. Mucocele-like Lesion of the Breast Diagnosed on Core Biopsy. Arch Pathol Lab Med. 2022;146(2):213-9.
65. Begum SM, Jara-Lazaro AR, Thike AA, Tse GM, Wong JS, Ho JT, et al. Mucin extravasation in breast core biopsies--clinical significance and outcome correlation. Histopathology. 2009;55(5):609-17.
66. Fadare O, Mariappan MR. Mucocele-like tumor and columnar cell hyperplasia of the breast occurring in a morphologic continuum. J Med Case Rep. 2008;2:138.
67. Ohi Y, Umekita Y, Rai Y, Sagara Y, Baba S, Tamada S, et al. Mucocele-like lesions of the breast: a long-term follow-up study. Diagn Pathol. 2011;6:29.
68. Ha D, Dialani V, Mehta TS, Keefe W, Iuanow E, Slanetz PJ. Mucocele-like lesions in the breast diagnosed with percutaneous biopsy: is surgical excision necessary? AJR Am J Roentgenol. 2015;204(1):204-10.
69. Verschuur-Maes AH, Van Diest PJ. The mucinous variant of columnar cell lesions. Histopathology. 2011;58(6):847-53.
70. Adsay NV, Merati K, Nassar H, Shia J, Sarkar F, Pierson CR, et al. Pathogenesis of colloid (pure mucinous) carcinoma of exocrine organs: Coupling of gel-forming mucin (MUC2) production with altered cell polarity and abnormal cell-stroma interaction may be the key factor in the morphogenesis and indolent behavior of colloid carcinoma in the breast and pancreas. Am J Surg Pathol. 2003;27(5):571-8.
71. Chu JS, Chang KJ. Mucin expression in mucinous carcinoma and other invasive carcinomas of the breast. Cancer Lett. 1999;142(1):121-7.
72. Matsukita S, Nomoto M, Kitajima S, Tanaka S, Goto M, Irimura T, et al. Expression of mucins (MUC1, MUC2, MUC5AC and MUC6) in mucinous carcinoma of the breast: comparison with invasive ductal carcinoma. Histopathology. 2003;42(1):26-36.
73. O'Connell JT, Shao ZM, Drori E, Basbaum CB, Barsky SH. Altered mucin expression is a field change that accompanies mucinous (colloid) breast carcinoma histogenesis. Hum Pathol. 1998;29(12):1517-23.
74. Rakha EA, Boyce RW, Abd El-Rehim D, Kurien T, Green AR, Paish EC, et al. Expression of mucins (MUC1, MUC2, MUC3, MUC4, MUC5AC and MUC6) and their prognostic significance in human breast cancer. Mod Pathol. 2005;18(10):1295-304.
75. Yonezawa S, Sato E. Expression of mucin antigens in human cancers and its relationship with malignancy potential. Pathol Int. 1997;47(12):813-30.

76. Fujii H, Anbazhagan R, Bornman DM, Garrett ES, Perlman E, Gabrielson E. Mucinous cancers have fewer genomic alterations than more common classes of breast cancer. Breast Cancer Res Treat. 2002;76(3):255-60.
77. Lacroix-Triki M, Suarez PH, MacKay A, Lambros MB, Natrajan R, Savage K, et al. Mucinous carcinoma of the breast is genomically distinct from invasive ductal carcinomas of no special type. J Pathol. 2010;222(3):282-98.
78. Kehr EL, Jorns JM, Ang D, Warrick A, Neff T, Degnin M, et al. Mucinous breast carcinomas lack PIK3CA and AKT1 mutations. Hum Pathol. 2012;43(12):2207-12.
79. Verschuur-Maes AH, van Gils CH, van den Bosch MA, De Bruin PC, van Diest PJ. Digital mammography: more microcalcifications, more columnar cell lesions without atypia. Mod Pathol. 2011;24(9):1191-7.
80. Luiten JD, Korte B, Voogd AC, Vreuls W, Luiten EJT, Strobbe LJ, et al. Trends in frequency and outcome of high-risk breast lesions at core needle biopsy in women recalled at biennial screening mammography, a multiinstitutional study. Int J Cancer. 2019;145(10):2720-7.
81. Kim MJ, Kim EK, Oh KK, Park BW, Kim H. Columnar cell lesions of the breast: mammographic and US features. Eur J Radiol. 2006;60(2):264-9.
82. Aroner SA, Collins LC, Schnitt SJ, Connolly JL, Colditz GA, Tamimi RM. Columnar cell lesions and subsequent breast cancer risk: a nested case-control study. Breast Cancer Res. 2010;12(4):R61.
83. Verschuur-Maes AH, Witkamp AJ, de Bruin PC, van der Wall E, van Diest PJ. Progression risk of columnar cell lesions of the breast diagnosed in core needle biopsies. Int J Cancer. 2011;129(11):2674-80.
84. Verschuur-Maes AH, van Deurzen CH, Monninkhof EM, van Diest PJ. Columnar cell lesions on breast needle biopsies: is surgical excision necessary? A systematic review. Ann Surg. 2012;255(2):259-65.
85. Consensus Guideline on Concordance Assessment of Image-Guided Breast Biopsies and Management of Borderline or High-Risk Lesions2017.
86. Wahab RA, Lee SJ, Mulligan ME, Zhang B, Mahoney MC. Upgrade Rate of Pure Flat Epithelial Atypia Diagnosed at Core Needle Biopsy: A Systematic Review and Meta-Analysis. Radiol Imaging Cancer. 2021;3(1):e200116.
87. Ferre R, Kuzmiak CM. Upgrade rate of percutaneously diagnosed pure flat epithelial atypia: systematic review and meta-analysis of 1,924 lesions. J Osteopath Med. 2022;122(5):253-62.
88. Rudin AV, Hoskin TL, Fahy A, Farrell AM, Nassar A, Ghosh K, et al. Flat Epithelial Atypia on Core Biopsy and Upgrade to Cancer: a Systematic Review and Meta-Analysis. Ann Surg Oncol. 2017;24(12):3549-58.
89. Dialani V, Venkataraman S, Frieling G, Schnitt SJ, Mehta TS. Does isolated flat epithelial atypia on vacuum-assisted breast core biopsy require surgical excision? Breast J. 2014;20(6):606-14.
90. Ni YB, Mujtaba S, Shao MM, Lacambra M, Tsang JY, Chan SK, et al. Columnar cell-like changes in the male breast. J Clin Pathol. 2014;67(1):45-8.
91. Verschuur-Maes AH, Kornegoor R, de Bruin PC, Oudejans JJ, van Diest PJ. Do columnar cell lesions exist in the male breast? Histopathology. 2014;64(6):818-25.

92. Foote FW, Stewart FW. Comparative Studies of Cancerous Versus Noncancerous Breasts. Ann Surg. 1945;121(1):6-53.
93. JG A. Problems in breast pathology. London: WB Saunders; 1979.
94. Shaaban AM, Sloane JP, West CR, Moore FR, Jarvis C, Williams EM, et al. Histopathologic types of benign breast lesions and the risk of breast cancer: case-control study. Am J Surg Pathol. 2002;26(4):421-30.
95. Lakhani SR, International Agency for Research on C, World Health O. WHO classification of tumours of the breast. Lyon: International Agency for Research on Cancer; 2012.
96. Palazzo JP. Difficult diagnoses in breast pathology. New York: Demos Medical Pub.; 2011.
97. Dabbs DJ. Breast pathology. Philadelphia, PA: Elsevier; 2017.
98. Dupont WD, Page DL. Risk factors for breast cancer in women with proliferative breast disease. N Engl J Med. 1985;312(3):146-51.
99. Fitzgibbons PL, Henson DE, Hutter RV. Benign breast changes and the risk for subsequent breast cancer: an update of the 1985 consensus statement. Cancer Committee of the College of American Pathologists. Arch Pathol Lab Med. 1998;122(12):1053-5.
100. Lakhani SR, Slack DN, Hamoudi RA, Collins N, Stratton MR, Sloane JP. Detection of allelic imbalance indicates that a proportion of mammary hyperplasia of usual type are clonal, neoplastic proliferations. Lab Invest. 1996;74(1):129-35.
101. O'Connell P, Pekkel V, Fuqua SA, Osborne CK, Clark GM, Allred DC. Analysis of loss of heterozygosity in 399 premalignant breast lesions at 15 genetic loci. J Natl Cancer Inst. 1998;90(9):697-703.
102. Reis-Filho JS, Lakhani SR. The diagnosis and management of pre-invasive breast disease: genetic alterations in pre-invasive lesions. Breast Cancer Res. 2003;5(6):313-9.
103. Lopez-Garcia MA, Geyer FC, Lacroix-Triki M, Marchio C, Reis-Filho JS. Breast cancer precursors revisited: molecular features and progression pathways. Histopathology. 2010;57(2):171-92.
104. Mommers EC, Poulin N, Meijer CJ, Baak JP, van Diest PJ. Malignancy-associated changes in breast tissue detected by image cytometry. Anal Cell Pathol. 2000;20(4):187-95.
105. Mommers EC, Poulin N, Sangulin J, Meijer CJ, Baak JP, van Diest PJ. Nuclear cytometric changes in breast carcinogenesis. J Pathol. 2001;193(1):33-9.
106. Lerwill MF. Flat epithelial atypia of the breast. Arch Pathol Lab Med. 2008;132(4):615-21.
107. Goldstein NS, Kestin LJ, Vicini FA. Monomorphic epithelial proliferations: characterization and evidence suggesting they are the pool of partially transformed lesions from which some invasive carcinomas arise. Am J Clin Pathol. 2007;128(6):1023-34.
108. Lerwill MF. Current practical applications of diagnostic immunohistochemistry in breast pathology. Am J Surg Pathol. 2004;28(8):1076-91.
109. Moreira JM, Cabezon T, Gromova I, Gromov P, Timmermans-Wielenga V, Machado I, et al. Tissue proteomics of the human mammary gland: towards an abridged definition of the molecular phenotypes underlying epithelial normalcy. Mol Oncol. 2010;4(6):539-61.
110. Aubele MM, Cummings MC, Mattis AE, Zitzelsberger HF, Walch AK, Kremer M, et al. Accumulation of chromosomal imbalances from intraductal proliferative lesions to adjacent in situ and invasive ductal breast cancer. Diagn Mol Pathol. 2000;9(1):14-9.

111. Boecker W, Buerger H, Schmitz K, Ellis IA, van Diest PJ, Sinn HP, et al. Ductal epithelial proliferations of the breast: a biological continuum? Comparative genomic hybridization and high-molecular-weight cytokeratin expression patterns. J Pathol. 2001;195(4):415-21.
112. Boecker W, Moll R, Dervan P, Buerger H, Poremba C, Diallo RI, et al. Usual ductal hyperplasia of the breast is a committed stem (progenitor) cell lesion distinct from atypical ductal hyperplasia and ductal carcinoma in situ. J Pathol. 2002;198(4):458-67.
113. Gong G, DeVries S, Chew KL, Cha I, Ljung BM, Waldman FM. Genetic changes in paired atypical and usual ductal hyperplasia of the breast by comparative genomic hybridization. Clin Cancer Res. 2001;7(8):2410-4.
114. Jones C, Merrett S, Thomas VA, Barker TH, Lakhani SR. Comparative genomic hybridization analysis of bilateral hyperplasia of usual type of the breast. J Pathol. 2003;199(2):152-6.
115. Washington C, Dalbegue F, Abreo F, Taubenberger JK, Lichy JH. Loss of heterozygosity in fibrocystic change of the breast: genetic relationship between benign proliferative lesions and associated carcinomas. Am J Pathol. 2000;157(1):323-9.
116. Sciarra A, Lopez G, Corti C, Runza L, Ercoli G, Bonometti A, et al. Columnar Cell Lesion and Apocrine Hyperplasia of the Breast: Is There a Common Origin? The Role of Prolactin-induced Protein. Appl Immunohistochem Mol Morphol. 2019;27(7):508-14.
117. Kosemehmetoglu K, Guler G. Papillary apocrine metaplasia and columnar cell lesion with atypia: is there a shared common pathway? Ann Diagn Pathol. 2010;14(6):425-31.
118. Gatalica Z. Immunohistochemical analysis of apocrine breast lesions. Consistent over-expression of androgen receptor accompanied by the loss of estrogen and progesterone receptors in apocrine metaplasia and apocrine carcinoma in situ. Pathol Res Pract. 1997;193(11-12):753-8.
119. Hoda SA, Rosen PP. Rosen's breast pathology Syed A. Hoda. Philadelphia: Lippincott Williams & Wilkins; 2021.
120. Jones C, Damiani S, Wells D, Chaggar R, Lakhani SR, Eusebi V. Molecular cytogenetic comparison of apocrine hyperplasia and apocrine carcinoma of the breast. Am J Pathol. 2001;158(1):207-14.
121. Selim AG, Ryan A, El-Ayat GA, Wells CA. Loss of heterozygosity and allelic imbalance in apocrine adenosis of the breast. Cancer Detect Prev. 2001;25(3):262-7.
122. Ichihara S, Fujimoto T, Hashimoto K, Moritani S, Hasegawa M, Yokoi T. Double immunostaining with p63 and high-molecular-weight cytokeratins distinguishes borderline papillary lesions of the breast. Pathol Int. 2007;57(3):126-32.
123. Mulligan AM, O'Malley FP. Papillary lesions of the breast: a review. Adv Anat Pathol. 2007;14(2):108-19.

Chapter 2

Chromosome 16q loss– a genetic key to the understanding of breast carcinogenesis

Horst Bürger, Mirthe de Boer, Paul J. van Diest and Eberhard Korsching

Histol Histopathol (2013) 28: 311-320

Summary

In the last decade the concepts of breast cancer dedifferentiation and progression have undergone a significant and substantial change. In the past it was widely believed that the detailed associations between genetic and morphological changes defined in the Vogelstein model of colorectal cancer pathogenesis could be transferred to breast carcinogenesis. A multitude of studies seemed to verify this a priori hypothesis. However, with the introduction of global screening techniques, predominantly at the DNA level, it became obvious that this linear model might be oversimplified for breast cancer. It is now widely accepted that losses of chromosomal 16q characterize in-situ and invasive breast cancer tumours with predominantly low tumour grade and estrogen receptor (ER) positivity (luminal breast cancers). In contrast, high grade breast cancers of the HER2, the basal or the non expressor phenotype with 16q-losses are rarely seen and in consequence a concept of multiple, parallel pathways with defined precursor lesions emerged. As a consequence, it became obvious that the hunt for oncogenes/tumour suppressor genes in invasive breast cancer is pathway specific. Whereas high grade breast cancers have been relatively well characterized by several recurrent changes in oncogenes/tumour suppressor genes located on various chromosomal regions (e.g. *egfr*, p53, HER2), the characterization of a 16q-specific tumour suppressor gene in ER-positive breast cancer is still a tremendous challenge. This review will focus on the role of 16q in breast cancer and aims to give insights into actual research efforts, e.g. alternative explanations in order to unravel the central role of 16q in breast cancer.

Chromosome 16 in breast cancer

Chromosome 16 belongs to the small group of metacentric chromosomes. It is characterized by large centromeric heterochromatin. Alterations of chromosome 16 belong to the most frequent and most extensively characterized genetic alterations in invasive breast cancer. Two major genetic changes involving chromosome 16 have been described. The loss of the long arm, or at least large parts of 16q, was first demonstrated by classical cytogenetics, and later confirmed by microsatellite analysis and comparative genomic hybridization, but more recently also amplifications of 16p have been described. The repeated detection of 16q-losses initiated intense research on putative tumour suppressor genes residing on 16q, but so far no convincing single candidate gene or group of candidate genes have been described which would convincingly fulfil the requirements in the sense of the Knudson postulate. Interestingly, the described clinical significance of 16q-losses varied over time. At first glance this might question the general importance of 16q-losses, but when looking deeper into these contradictory results, the interpretation of 16q-losses seems to be heavily influenced by the varying methods over time (Buerger and Boecker, 2006).

Chromosome 16q losses in invasive breast cancer

The earliest descriptions of 16q losses were based on G-banding of metaphase chromosomes. The loss of 16q was often, but not exclusively, due to an unbalanced chromosomal translocation t(1;16) (Pandis et al., 1994, 1995; Tsuda et al., 1997; Adeyinka et al., 2003) and was associated with a decreased rate of lymph node metastases, increased expression of estrogen (ER) and progesterone receptor (PR), low tumour proliferation rate and improved overall survival (Adeyinka et al., 1999, 2003; Tsuda et al., 1999a; Hislop et al., 2002). In a few cases t(1;16) was the sole cytogenetic abnormality (Pandis et al., 1992), underlining the importance of 16qlosses. Since the breakpoint of the recurrent t(1;16) was located in the centromeric heterochromatin of chromosome 16, no specific genetic gene fusion transcript resulted from this chromosomal alteration. It was speculated by Tsuda et al, that hypomethylation of specific chromosomal regions in the pericentromeric regions on 16q could be associated with the pathogenesis of an unbalanced chromosomal translocation t(1;16) (Tsuda et al., 2002). Further studies using fluorescence *in situ* hybridization (FISH) also demonstrated the presence of this chromosomal alteration predominantly in Grade 1 (G1) and Grade 2 (G2) invasive breast cancer cases (Tsuda et al., 1999b). In parallel, loss of heterozygosity analysis (LOH) with microsatellite markers covering the whole 16q-arm narrowed 16q losses down to 3 different shortest regions (SOR) of overlap.

Interestingly, different studies revealed partially different, partially overlapping results (Whitmore et al., 1998; Cleton-Jansen et al., 2001; Callen et al., 2002). Part of these discrepant results might be explained by the limited number of cases that could be analysed by classical cytogenetics, and the limited statements about the overall chromosome 16q-status that can be made by LOH analysis as discussed more extensively below. In line with this, correlations between cytogenetic findings on the one hand and histopathological features and prognosis on the other have varied as well (Tsuda et al., 1994a; Caligo et al., 1998; Hansen et al., 1998). With the introduction of conventional (chromosome) Comparative Genomic Hybridization (CGH) and array CGH that yield a global overview of unbalanced chromosomal alterations in paraffin-embedded tissue, these limitations could be overcome (Ried et al., 1995; Pinkel et al., 1998). endent distribution of 16q-losses was maintained in different invasive carcinomas. Especially tubular, tubulo-lobular, lobular, papillary and ductal invasive grade 1 breast cancers were characterized by 16q-losses, whereas ductal invasive grade 3 carcinomas usually lack this alteration (Buerger et al., 1999a; Roylance et al., 1999; Waldman et al., 2001; Reis-Filho et al., 2005). More detailed studies in ductal invasive grade 3 carcinomas could further show that 16q loss is also very uncommon in HER2-overexpressing/amplified carcinomas (Isola et al., 1999) and in basal, triplenegative breast carcinomas of various subtypes (Korsching et al., 2002, 2005; Reis-Filho et al., 2006; Vincent-Salomon et al., 2007; Lae et al., 2009). In general, 16q loss was associated with prognostically favourable features such as a low proliferation rate, ER/PR expression and axillary lymph node negativity (Zudaire et al., 2002; Farabegoli et al., 2004; Loo et al., 2004; Fang et al., 2011). Noteworthy, even though the background and the biological rationale of these findings are unclear, synchronous multifocal unilateral and bilateral breast cancers also displayed 16q-losses in a significant percentage (Agelopoulos et al., 2003; Ghazani et al., 2007). The explanation for 16q-losses in grade 3 breast cancers could be twofold. On one hand it might be that this subgroup has evolved from grade 1 through grade 2 carcinomas (Roylance et al., 2006), but could on the other hand reflect cytogenetic instability in different subclones within a tumour. The latter hypothesis is further substantiated by the finding of 16q-losses in poorly-differentiated DCIS and the lack of an identical alteration in the synchronous ipsilateral invasive breast cancer within the same patient (Buerger et al., 2000b). Noteworthy, the underlying mechanisms of 16q-losses in grade 1 and grade 3 ductal invasive breast cancer cases seem to differ significantly. Several studies showed no differences in the frequency of LOH at 16q between invasive tumours of different histological grade. Combining data from LOH, FISH with chromosome 16–specific probes and CGH, it could be demonstrated that physical losses of chromosome 16q could be preferentially demonstrated in well-differentiated grade I carcinomas, whereas in poorly differentiated grade III

tumours, LOH was accompanied by mitotic recombination. These results clarified the discrepancies between CGH and LOH for 16q in breast cancer (Cleton-Jansen et al., 2004) and further point towards the existence of different, independent pathways. More recent studies also revealed that in low-grade carcinomas the whole arm of 16q was usually lost, whereas in less differentiated carcinomas only small parts/regions of the respective arm seem to be lost (Natrajan et al., 2009b).

Chromosome 16q losses in ductal *in situ* carcinomas of the breast

An important finding was the demonstration of 16q losses as rather early events in breast carcinogenesis in ductal (DCIS) and lobular carcinoma *in situ* (LCIS) (Tsuda et al., 1994b, 1995; Lakhni et al., 1995a; Stratton et al., 1995). The first studies dealing with genetic changes in DCIS using conventional CGH demonstrated that 16q losses are, besides gains of 1q, the most frequent changes in DCIS. This established the presence of 16q loss in the precursor stage of breast cancer. Loss of 16q was predominantly detected in G1 and G2 DCIS, whereas other cytogenetic alterations were more frequent in G3 DCIS (Buerger et al., 1999b; Vos et al., 2000; Waldman et al., 2000). Articles also demonstrated that 16q-loss is associated with absence of intraductal necrosis, low proliferation rate (Buerger et al., 2000a) and the lack of identical alterations in poorly differentiated DCIS and synchronous ipsilateral invasive breast cancer (Buerger et al., 2000b).

Chromosome 16q losses in lobular neoplasia of the breast

In lobular neoplasia (atypical lobular hyperplasia and LCIS) 16q loss was frequently seen using conventional CGH (Lu et al., 1998b; Etzell et al., 2001) and array CGH (Mastracci et al., 2006a; Green et al., 2009). Usually there was loss of the complete arm of 16q (Etzell et al., 2001). There was no difference in frequency between 16q loss between atypical lobular hyperplasia and LCIS (Lu et al., 1998a,b; Mastracci et al., 2006a,b). Also, a similar frequency of 16q loss in lobular neoplasia was found compared with invasive lobular carcinoma (Etzell et al., 2001; Hwang et al., 2004). There were some indications that 16q loss in LCIS is associated with t(1;16) (Flagiello et al., 1998a,b; Buerger et al., 2000b; Chen et al., 2009a,b). On the other hand, some articles reported a significantly higher frequency of 1q gain in invasive lobular carcinomas, compared with lobular neoplasia (Lu et al., 1998b; Etzell et al., 2001).

With regard to the relation between lobular neoplasia and DCIS, similar chromosomal changes were found between lobular neoplasia compared to DCIS and invasive ductal carcinoma, which suggests a common genetic pathway (Lu et al., 1998b). In search of tumour suppressor genes, several gene targets located on chromosome 16q were tested with real-time PCR in LCIS and normal lobular epithelium (Green et al., 2009).

LCIS had a significantly lower gene expression of DPEP1 (dipeptidase 1), CDH1 and CTCF (CCCTC-binding factor). Also, CTCF immunohistochemistry expression was significantly lower in LCIS. This low expression indicates these genes are potential tumour suppressor genes in breast cancer.

Chromosome 16q losses in atypical ductal hyperplasia

LOH analysis and CGH of 16q in atypical ductal hyperplasia (ADH) demonstrated variability ranging from 10 to 58% (Lakhani et al., 1995b). Some articles revealed that the loss of 16q was similar in ADH to DCIS and invasive ductal carcinoma (Gao et al., 2009; Larson et al., 2006). Because of frequent concordant LOH patterns between ADH and coexisting invasive cancer, the precursor role of ADH was corroborated (Larson et al., 2006). Not all studies could confirm this (Tsuda et al., 2001a), probably explained by the high tumour grade (G2-3) of the (metachronous) invasive carcinomas. O'Connell et al. tested 16q loss in several lesions (UDH, ADH and DCIS) in cancerous and noncancerous breasts (O'Connell et al., 1998). There was no significant difference between the frequency of 16q loss between the cancerous group and the non-cancerous group. This was in contrast with the findings of Ellsworth et al., who described a low frequency of 16q loss of pure ADH (not accompanied by more advanced lesions). Pure ADH only had significantly more frequent allelic imbalance at chromosome 8q24 compared with normal breast, while the frequency of 16q loss was similar to normal epithelium (Ellsworth et al., 2010). To conclude, 16q loss is often present in ADH which underlines its role in breast carcinogenesis, with progression potential to both low nuclear grade ductal and lobular (pre)invasive lesions.

Chromosome 16q losses in columnar cell lesions

Recently, atypical columnar cell lesions (CCL, characterized by the presence of columnar epithelial cells lining the terminal duct lobular units of the breast, either with atypical nuclei or early ("clinging") architectural atypia, also known as flat epithelial atypia or DIN1a), have been proposed as the earliest possible neoplastic alterations of the breast. LOH and CGH analysis demonstrated relatively frequent 16q loss in atypical CCL (Moinfar et al., 2000; Simpson et al., 2005), which suggests a precursor role in low grade early breast carcinogenesis. Other frequent chromosomal changes were LOH of chromosome 11q and 3p (Moinfar et al., 2000). A gain of 1q was variably observed in CCL. A high frequency of 1q gain was found in CCLs associated with lobular neoplasia (Simpson et al., 2005; Stacher et al., 2011). Schmidt et al. showed a high concordance between 16q loss in atypical CCL and the adjacent invasive carcinoma or *in situ* carcinoma (Schmidt et al., 2008). Moinfair et al. found that pure atypical CCL (not associated with invasive ductal carcinoma) showed the same frequency of 16q loss as in cancerous breasts (Moinfar et al., 2000).

This is in contrast with the findings of Ellsworth et al., who tested pure CCL by LOH and revealed a significantly lower frequency of 16q loss compared with CCL of cancerous breasts. They also demonstrated that pure CCL did not show a However, no distinction between non-atypical and atypical CCL was made. Ellsworth et al. suggested that pure CCLs have different molecular changes from CCL with more advanced synchronous lesions (Ellsworth et al., 2010). Different types of CCL (metaplasia, hyperplasia, hyperplasia with architectural atypia, hyperplasia with cytologic atypia, hyperplasia with architectural and cytologic atypia and metaplasia with cytologic atypia) were compared by Simpson et al. (2005). A remarkable finding of the CGH analysis was the relatively high 16q loss in columnar cell metaplasia and hyperplasia, respectively 29% and 36%. CCL with atypia (architectural or cytologic) showed 16q loss in 47%. They concluded that all these CCL categories exhibit loss of 16q, and that the morphologic classification of CCL closely mirrors the level of genetic instability (Simpson et al., 2005). To conclude, it appears that 16q loss is common in CCL, possibly most common in atypical CCL. Studying the progression risk of 16q loss would be interesting.

Chromosome 16q losses in usual ductal hyperplasia and normal epithelium

Although usual ductal hyperplasia (UDH) is generally regarded as a polyclonal carcinogenetic dead end, Gong et al. suggested a precursor role of UDH, based on a high frequency of 16q loss (56%) in UDH adjacent to ADH (Gong et al., 2001). However, pure UDH (not related to ADH) demonstrated lower frequency of 16q loss (11%). Other studies revealed low frequencies of 16q loss in UDH (O'Connell et al., 1998; Tsuda et al., 2001b; Larson et al., 2006; Gao et al., 2009). This may imply that a subset of lesions morphologically appear as UDH yet harbour clonal cell populations with progression potential. Also, morphologically normal epithelium from cancerous breasts was analysed for 16q losses, and normal epithelium with mildly atypical nuclear features at high magnification demonstrated loss of 16q with a frequency of 44%, equal to the rate in atypical CCLs (Moinfar et al., 2000). In contrast, normal epithelium from women without breast disease did not show any LOH at the tested loci (Moinfar et al., 2000). Normal epithelium in cancerous breasts tested by Larson et al. revealed that 16q loss was one of the most frequent LOH, although significantly less frequent compared to carcinoma *in situ* and invasive carcinoma (Larson et al., 2002). This suggests that even morphologically normal breast epithelium may harbour aberrant clones that may progress and contribute to tumorgenesis.

Correlation between chromosomal 16q-status and gene expression patterns

As nicely reviewed by Rakha et al., the classical hunt for "the" 16q-specific tumour suppressor gene seemed to fail in the past, since somatic mutations (in view of the Knudson hypothesis) of the respective genes could not be observed (van Wezel et al., 2005; Rakha et al., 2006). Consequently, other mechanisms seem to contribute to the 16q-specific effect in breast carcinogenesis. One mechanism, even though hard to prove for a long time, was haploinsufficiency as a result of a loss of chromosomal material in the sense of a gene dosage effect. Consequently, the loss of chromosomal material at a distinct genetic region would be associated with a decreased expression of the affected genes. Global gene expression has been proven to be of high value in the gene based subclassification of invasive breast cancer. According to Perou et al. invasive breast cancer can be divided into luminal, basal and HER2 driven cancers (Perou et al., 2000). The luminal group is composed of luminal A and luminal B breast cancers, both characterized by the expression of ER and/or PR, but differing in the expression of HER2 and/or the rate of tumour proliferation (Kornegoor et al., 2012). The studies of Wennmalm et al. and Nordgard et al. demonstrated a clear correlation between 16q-specific gene expression and intrinsic breast cancer subgroup as previously described (Sorlie et al., 2001), as well as the overall survival in breast cancer patients (Nordgard et al., 2008). A decreased expression of genes located on 16q was associated with an improved prognosis (Wennmalm et al., 2007). Interestingly, the expression based classification of Sorlie et al. (2001) agreed better with 16q expression than stratification according to grade. Similar findings were observed by Wang et al. using combined genome-wide single nucleotide polymorphism analysis and expression analysis. 16q-losses have not been detected in basal breast cancers, but in ER-positive luminal breast cancers (Wang et al., 2004), as already seen in a series of breast cancers characterized by immunohistochemistry (Korsching et al., 2002). DCIS studies with global screening techniques demonstrated that DCIS can be classified into different intrinsic subtypes like invasive breast cancer (Tamimi et al., 2008). On the genomic and the transcriptomic level invasive carcinomas and DCIS revealed similar phenoand genotypic relationships, demonstrating that the molecular heterogeneity of breast cancers is already detectable at the *in situ* level. Furthermore, a gene dosage effect could be shown for 16q in DCIS (Vincent- Salomon et al., 2008).

Against this background it has been speculated that 16q-losses will mediate their effect by a simple gene dosage effect, mainly in luminal, ER-positive breast cancer. In a recently published study of Hungermann et al. this hypothesis was further substantiated. Whole-arm chromosome 16q losses were associated with decreased

expression of a number of candidate genes located on 16q in breast carcinomas with a low degree of genetic instability. The differential expression of the candidate genes according to the chromosomal 16q-status vanished in genetically advanced breast cancer cases and negative ER status. These results corroborate previous reports about the importance of whole-arm loss of chromosome 16q in breast carcinogenesis and give evidence that haploinsufficiency, in the sense of a gene dosage effect, might be an important contributing factor in the early steps of breast carcinogenesis (Hungermann et al., 2011). Haploinsufficiency is associated with the loss of one allele of a specific gene in a tumour cell, whereas the other allele maintains gene expression, leading to a decreased overall expression (gene dosage) in the tumour cell. Dosage sensitivity has been implicated in tumourigenesis especially for cell-cycle regulatory genes, such as p53 and p27, but also for other genes (Santarosa and Ashworth, 2004). However, a recurrent feature of haploinsufficient genes is that tumours generated via this mechanism are of later onset and lower aggressiveness. In addition, haploinsufficiency has been associated with an early stage of disease. For some genes also a pathway specific haploinsufficiency effect has been described. The parallels between these observations and the findings in breast cancer are compelling. 16q-losses belong to the earliest events in breast cancer and are generally associated with favourable prognostic features in breast cancer.

The relationship between 16q-losses and the expression of ER will focus further research on the interaction between ER and 16q-losses in ER-positive carcinomas (Habashy et al., 2012).

Consequences for progression and classification schemes of breast cancer and its precursor lesions

Integrating all these data into a unifying model of breast carcinogenesis it becomes evident that a simple linear model like the one proposed for colorectal carcinogenesis does not apply to breast cancer. Rather, the istribution of 16q-loss in preinvasive or invasive breast lesions clearly points towards the existence of different pathways, associated with different malignancy grades. One could therefore propose a low-grade and a high-grade pathway in breast carcinogenesis (van-Diest, 1999). The latter is characterized by a multitude of different genetic alterations and protein expression patterns (p53, HER2, Ck5) in invasive breast cancer and its associated DCIS. In contrast, hallmarks of the lowgrade pathway are the loss of 16q, the expression of ER and a likewise lower degree of genetic instability (Korsching et al., 2008). Lobular and ductal breast lesions might therefore be regarded as two different morphological patterns with a unique underlying genetic alteration pattern as shown in figure 1. These observations are therefore not only of tumourbiological interest,

but also significantly influence our understanding of the classification of early breast lesions and invasive breast cancer. The modified DIN (ductal intraepithelial neoplasia) concept, highly analogous to a multitude of other "intraepithelial neoplasia" classification systems, such as in the cervix or squamous epithelium, suggest a linear progression of grade 1 to grade 3 and finally to invasive carcinoma. However, as discussed above, this simple concept transferred from other tumour entities does not to seem hold for breast cancer and the DIN classification scheme therefore insufficiently reflects the underlying biology. Since the distribution of 16q-losses changes significantly with grade, it is unlikely that well-differentiated DCIS progresses towards poorly-differentiated DCIS in high frequency. The morphological association of G1 DCIS with tubular, tubulo-lobular, lobular and ductal invasive grade 1 carcinomas, in contrast to the poorlydifferentiated DCIS/ ductal invasive grade 3 carcinoma pathway, is also a plea against this hypothesis. Consequently, our current understanding of breast cancer has to incorporate the presence of multiple genetic pathways in the progression of *in situ* and invasive breast cancer as recently reviewed.

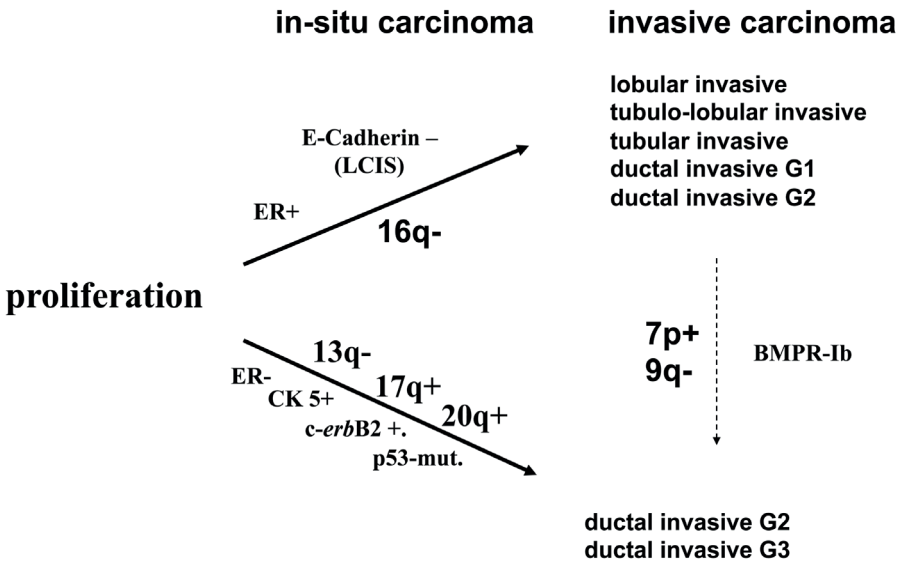

Fig. 1. Morphological and cytogenetic progression model of invasive breast cancer and associated *in situ* carcinoma. The presence of multiple, at least two different progression pathways in invasive breast cancer is nowadays undoubted and substantiated by RNA expression profiling (Sorlie et al., 2001). From a genetic point of view the loss of chromosome 16q-material is the most significant distinguisher between these different pathways and is associated with the expression of ER. It seems unlikely that poorly-diffferentiated DCIS/poorly differentiated grade 3 breast cancers generally evolve out of this low-grade pathway due to the distribution of 16q. These are characterized by a multitude of different genetic alterations and protein expression patterns, including c-erbB2 overexpressing breast cancers, as well as the "basal" carcinoma subgroup. For a subgroup of luminal breast cancers a "progression through grade" has been postulated, even though the exact mechanisms remain unclear (Korsching et al., 2004; Helms et al., 2005; Natrajan et al., 2009a).

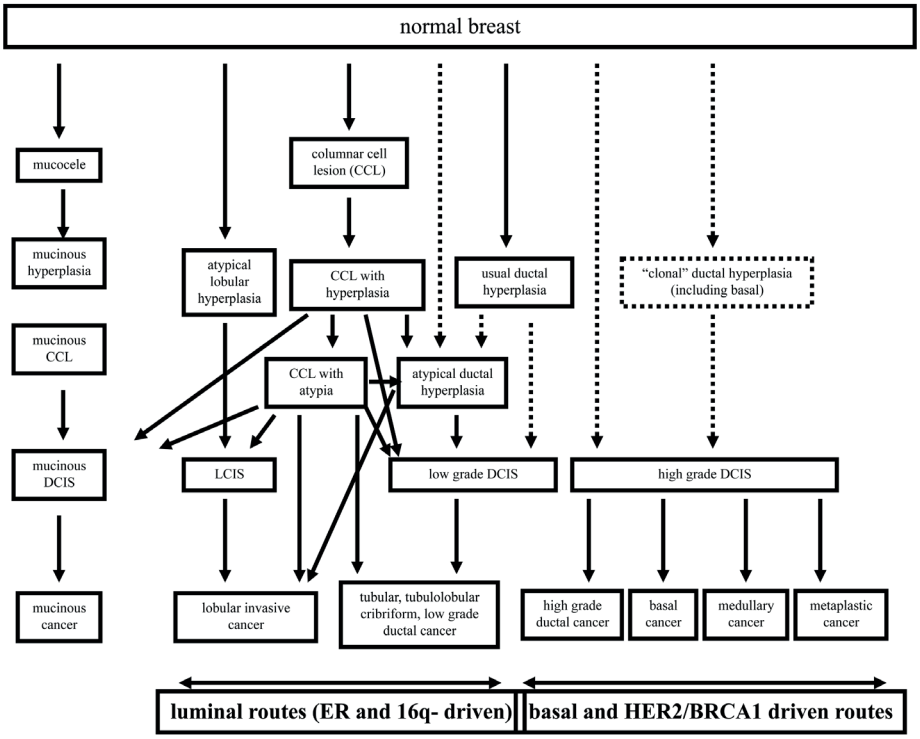

Fig. 2. The detection of 16qlosses in breast lesions discussed as precursor lesions of in-situ carcinomas and invasive breast cancer further support the presence of a low and a high grade pathway in breast carcinogenesis. Even though the number of genetic investigations is rather low, the available genetic and morphological observations support a direct relationship between cylinder cell lesions (columnar cell change and columnar cell hyperplasia), flat epithelial atypia, atypical ductal hyperplasia and well-differentiated DCIS. More recent studies showed that mucinous carcinomas represent their own subgroup of cancers within the spectrum of the lowgrade breast cancers.

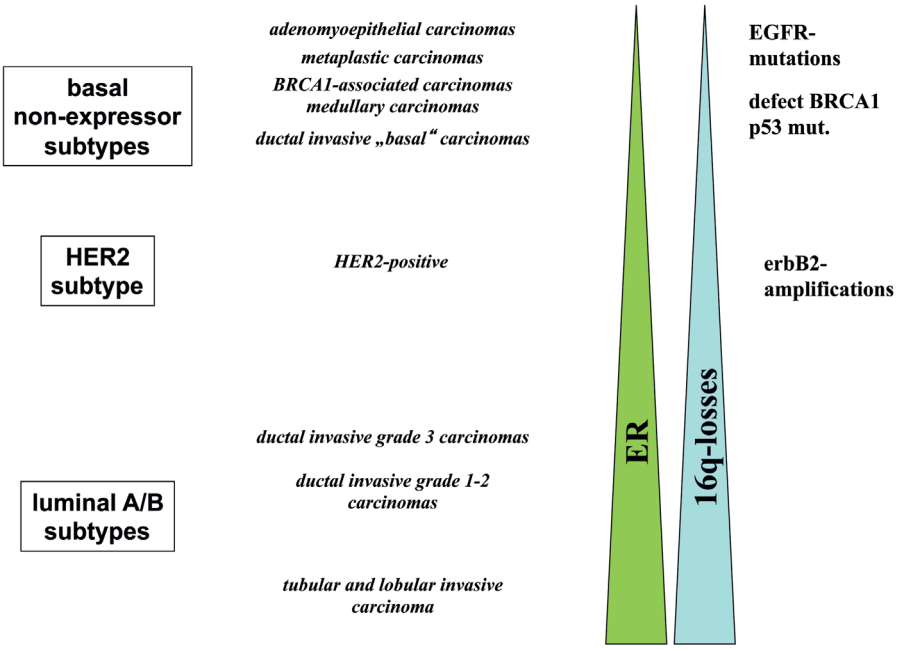

Fig. 3. Relationship between morphological, immunohistochemical and genetic findings in breast cancer. Invasive breast cancer can be characterized by the definition of molecular subtypes as well as the traditional histological typing. The distribution of 16qlosses, the expression of estrogen receptor (ER) and the frequency of other genetic alterations points towards the obvious existence of a breast cancer spectrum. As shown in the text, the distribution of 16q losses points towards the existence of multiple independent pathways, rather than a stepwise tumour progression.

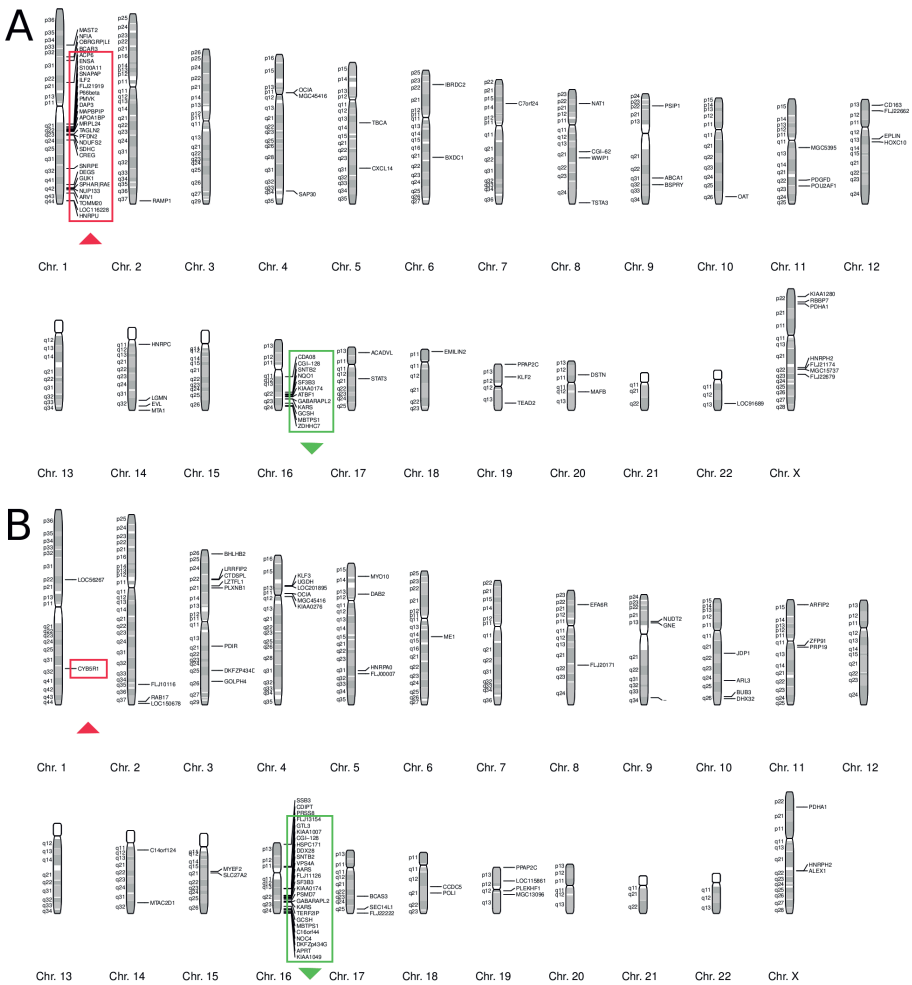

Fig. 4. Overview of all differentially expressed genes in regard to their chromosomal location. The genome is displayed as a panel of ordered metaphase ideograms of the human chromosomes 1 to 22 and X. The differentially expressed genes are mapped to their genomic location. On 16q and 1q a significant accumulation of differentially expressed genes can be seen. All the 16q genes revealed a decreased expression, while 1q genes showed an increased expression.

References

Adeyinka A., Mertens F., Idvall I., Bondeson L., Ingvar C., Mitelman F. and Pandis N. (1999). Different patterns of chromosomal imbalances in metastasising and non-metastasising primary breast carcinomas. Int. J. Cancer 84, 370-375.

Adeyinka A., Baldetorp B., Mertens F., Olsson H., Johannsson O., Heim S. and Pandis N. (2003). Comparative cytogenetic and DNA flow cytometric analysis of 242 primary breast carcinomas. Cancer. Genet. Cytogenet. 147, 62-67.

Agelopoulos K., Tidow N., Korsching E., Voss R., Hinrichs B., Brandt B., Boecker W. and Buerger H. (2003). Molecular cytogenetic investigations of synchronous bilateral breast cancer. J. Clin. Pathol. 56, 660-665.

Buerger H. and Boecker W. (2006). Cytogenetic concepts of intraductal proliferative breast disease and invasive breast cancer. In: Preneoplasias of the breast. Boecker W.Saunders. Munich. pp 545- 554.

Buerger H., Otterbach F., Simon R., Poremba C., Diallo R., Brinkschmidt C., Dockhorn-Dworniczak B. and Boecker W. (1999a). Different genetic pathways in the evolution of invasive breast cancer are associated with distinct morphological subtypes. J. Pathol. 189, 521-526.

Buerger H., Otterbach F., Simon R., Poremba C., Diallo R., Decker T., Riethdorf L., Brinkschmidt C., Dockhorn-Dworniczak B. and Boecker W. (1999b). Comparative genomic hybridization of ductal carcinoma *in situ* of the breast- evidence of multiple genetic pathways. J. Pathol. 187, 396-402.

Buerger H., Mommers E., Littmann R., Diallo R., Poremba C., Brinkschmidt C., Dockhorn D.B., van Diest P.J. and Boecker W. (2000a). Correlation of morphologic and cytogenetic parameters of genetic instability with chromosomal alterations in *in situ* carcinomas of the breast. Am. J. Clin.Pathol. 114, 854-859.

Buerger H., Simon R., Schaefer K.L., Diallo R., Littmann R., Poremba C., van Diest P.J., Dockhorn-Dworniczak B. and Boecker W. (2000b). Genetic relationship of lobular carcinoma *in situ*, ductal carcinoma *in situ* and associated invasive carcinoma of the breast. Mol. Pathol. 53, 118-121.

Caligo M.A., Polidoro L., Ghimenti C., Campani D., Cecchetti D. and Bevilacqua G. (1998). A region on the long arm of chromosome 16 is frequently deleted in metastatic node-negative breast cancer. Int. J. Oncol. 13, 177-182. Callen D.F., Crawford J., Derwas C., Cleton-Jansen A.M., Cornelisse C.J. and Baker E. (2002). Defining regions of loss of heterozygosity of 16q in breast cancer cell lines. Cancer Genet. Cytogenet. 133, 76-82.

Chen Y.Y., Hwang E.S., Roy R., DeVries S., Anderson J., Wa C., Fitzgibbons P.L., Jacobs T.W., MacGrogan G., Peterse H., Vincent- Salomon A., Tokuyasu T., Schnitt S.J. and Waldman F.M. (2009a). Genetic and phenotypic characteristics of pleomorphic lobular carcinoma *in situ* of the breast. Am. J. Surg. Pathol. 33, 1683-1694.

Chen Y.Y., Hwang E.S., Roy R., DeVries S., Anderson J., Wa C., Fitzgibbons P.L., Jacobs T.W., MacGrogan G., Peterse H., Vincent- Salomon A., Tokuyasu T., Schnitt S.J. and Waldman F.M. (2009b). Genetic and phenotypic characteristics of pleomorphic lobular carcinoma *in situ* of the breast. Am. J. Surg. Pathol. 33, 1683-1694.

Cleton-Jansen A.M., Callen D.F., Seshadri R., Goldup S., Mccallum B., Crawford J., Powell J.A., Settasatian C., van Beerendonk H., Moerland E.W., Smit V.T., Harris W.H., Millis R., Morgan N.V., Barnes D., Mathew C.G. and Cornelisse C.J. (2001). Loss of heterozygosity mapping at chromosome arm 16q in 712 breast tumors reveals factors that influence delineation of candidate regions. Cancer Res. 61, 1171-1177.

Cleton-Jansen A.M., Buerger H., Haar N.N., Philippo K., van de Vijver M.J., Boecker W., Smit V.T. and Cornelisse C.J. (2004). Different mechanisms of chromosome 16 loss of heterozygosity in wellversus poorly differentiated ductal breast cancer. Genes Chromosomes Cancer 41, 109-116.

Ellsworth R.E., Ellsworth D.L., Weyandt J.D., Fantacone-Campbell J.L., Deyarmin B., Hooke J.A. and Shriver C.D. (2010). Chromosomal alterations in pure nonneoplastic breast lesions: implications for breast cancer progression. Ann. Surg. Oncol. 17, 1688-1694.

Etzell J.E., DeVries S., Chew K., Florendo C., Molinaro A., Ljung B.M. and Waldman F.M. (2001). Loss of chromosome 16q in lobular carcinoma *in situ*. Hum. Pathol. 32, 292-296.

Fang M., Toher J., Morgan M., Davison J., Tannenbaum S. and Claffey K. (2011). Genomic differences between estrogen receptor (ER)- positive and ER-negative human breast carcinoma identified by single nucleotide polymorphism array comparative genome hybridization analysis. Cancer 117, 2024-2034.

Farabegoli F., Hermsen M.A., Ceccarelli C., Santini D., Weiss M.M., Meijer G.A. and van Diest P.J. (2004). Simultaneous chromosome 1q gain and 16q loss is associated with steroid receptor presence and low proliferation in breast carcinoma. Mod. Pathol. 17, 449-455.

Flagiello D., Gerbault S.M., Sastre G.X., Padoy E., Vielh P. and Dutrillaux B. (1998a). Highly recurrent der (1;16)(q10;p10) and other 16q arm alterations in lobular breast cancer. Genes Chromosomes Cancer 23, 300-306.

Flagiello D., Gerbault-Seureau M.l., Sastre-Garau X., Padoy E., Vielh P. and Dutrillaux B. (1998b). Highly recurrent der(1;16)(q10;p10) and other 16q arm alterations in lobular breast cancer. Genes Chromosomes Cancer 23, 300-306.

Gao Y., Niu Y., Wang X., Wei L. and Lu S. (2009). Genetic changes at specific stages of breast cancer progression detected by comparative genomic hybridization. J. Mol. Med. (Berl) 87, 145-152.

Ghazani A.A., Ameson N., Warren K., Pintilie M., Bayani J., Squire J.A. and Done S.J. (2007). Genomic alterations in sporadic synchronous primary breast cancer using array and metaphase comparative genomic hybridization. Neoplasia 9, 511-520.

Gong G., DeVries S., Chew K.L., Cha I., Ljung B.M. and Waldman F.M. (2001). Genetic changes in paired atypical and usual ductal hyperplasia of the breast by comparative genomic hybridization. Clin. Cancer Res. 7, 2410-2414.

Green A.R., Krivinskas S., Young P., Rakha E.A., Paish E.C., Powe D.G. and Ellis I.O. (2009). Loss of expression of chromosome 16q genes DPEP1 and CTCF in lobular carcinoma *in situ* of the breast. Breast Cancer Res. Treat. 113, 59-66.

Habashy H.O., Powe D.G., Abdel-Fatah T.M., Gee J.M., Nicholson R.I., Green A.R., Rakha E.A. and Ellis I.O. (2012). A review of the biological and clinical characteristics of luminal-like oestrogen receptor positive breast cancer. Histopathology 60, 854-863.

Hansen L.L., Yilmaz M., Overgaard J., Andersen J. and Kruse T.A. (1998). Allelic loss of 16q23.2-24.2 is an independent marker of good prognosis in primary breast cancer. Cancer Res. 58, 2166-2169.

Helms M.W., Packeisen J., August C., Schittek B., Boecker W., Brandt B.H. and Buerger H. (2005). First evidence supporting a potential role for the BMP/SMAD pathway in the progression of oestrogen receptor-positive breast cancer. J. Pathol. 206, 366-376.

Hislop R.G., Pratt N., Stocks S.C., Steel C.M., Sales M., Goudie D., Robertson A. and Thompson A.M. (2002). Karyotypic aberrations of chromosomes 16 and 17 are related to survival in patients with breast cancer. Br. J. Surg. 89, 1581-1586.

Hungermann D., Schmidt H., Natrajan R., Tidow N., Poos K., Reis-Filho J.S., Brandt B., Buerger H. and Korsching E. (2011). Influence of whole arm loss of chromosome 16q on gene expression patterns in oestrogen receptor-positive, invasive breast cancer. J. Pathol. 224, 517-528.

Hwang E.S., Nyante S.J., Yi C.Y., Moore D., DeVries S., Korkola J.E., Esserman L.J. and Waldman F.M. (2004). Clonality of lobular carcinoma *in situ* and synchronous invasive lobular carcinoma. Cancer 100, 2562-2572.

Isola J., Chu L., DeVries S., Matsumura K., Chew K., Ljung B.M. and Waldman F.M. (1999). Genetic alterations in ERBB2-amplified breast carcinomas. Clin. Cancer Res. 5, 4140-4145.

Kornegoor R., Verschuur-Maes A.H., Buerger H., Hogenes M.C., De Bruin P.C., Oudejans J.J., van der G.P., Hinrichs B. and van Diest P.J. (2012). Molecular subtyping of male breast cancer by immunohistochemistry. Mod. Pathol. 25, 398-404.

Korsching E., Packeisen J., Agelopoulos K., Eisenacher M., Voss R., Isola J., van Diest P.J., Brandt B., Boecker W. and Buerger H. (2002). Cytogenetic alterations and cytokeratin expression patterns in breast cancer: integrating a new model of breast differentiation into cytogenetic pathways of breast carcinogenesis. Lab. Invest. 82, 1525-1533.

Korsching E., Packeisen J., Helms M.W., Kersting C., Voss R., van Diest P.J., Brandt B., Van Der W.E., Boecker W. and Burger H. (2004). Deciphering a subgroup of breast carcinomas with putative progression of grade during carcinogenesis revealed by comparative genomic hybridisation (CGH) and immunohistochemistry. Br. J. Cancer 90, 1422-1428.

Korsching E., Packeisen J., Liedtke C., Hungermann D., Wulfing P., van Diest P.J., Brandt B., Boecker W. and Buerger H. (2005). The origin of vimentin expression in invasive breast cancer: epithelialmesenchymal transition, myoepithelial histogenesis or histogenesis from progenitor cells with bilinear differentiation potential? J. Pathol. 206, 451-457.

Korsching E., Jeffrey S.S., Meinerz W., Decker T., Boecker W. and Buerger H. (2008). Basal carcinoma of the breast revisited: an old entity with new interpretations. J. Clin. Pathol. 61, 553-560. Lae M., Freneaux P., Sastre-Garau X., Chouchane O., Sigal-Zafrani B. and Vincent-Salomon A. (2009). Secretory breast carcinomas with ETV6-NTRK3 fusion gene belong to the basal-like carcinoma spectrum. Mod. Pathol. 22, 291-298.

Lakhani S.R., Collins N., Sloane J. and Stratton M.R. (1995a). Loss of heterozygosity in lobular carcinoma *in situ* of the breast. J Clin. Pathol. Mol. Pathol. 48, 74-78.

Lakhani S.R., Collins N., Stratton M.R. and Sloane J.P. (1995b). Atypical ductal hyperplasia of the breast: clonal proliferation with loss of heterozygosity on chromosomes 16q and 17p. J. Clin. Pathol. 48, 611-615.

Larson P.S., de las M.A., Bennett S.R., Cupples L.A. and Rosenberg C.L. (2002). Loss of heterozygosity or allele imbalance in histologically normal breast epithelium is distinct from loss of heterozygosity or allele imbalance in co-existing carcinomas. Am. J. Pathol. 161, 283-290.

Larson P.S., de las Morenas A., Cerda S.R., Bennett S.R., Cupples L.A. and Rosenberg C.L. (2006). Quantitative analysis of allele imbalance supports atypical ductal hyperplasia lesions as direct breast cancer precursors. J. Pathol. 209, 307-316.

Loo L.W., Grove D.I., Williams E.M., Neal C.L., Cousens L.A., Schubert E.L., Holcomb I.N., Massa H.F., Glogovac J., Li C.I., Malone K.E., Daling J.R., Delrow J.J., Trask B.J., Hsu L. and Porter P.L. (2004). Array comparative genomic hybridization analysis of genomic alterations in breast cancer subtypes. Cancer Res. 64, 8541-8549.

Lu Y.J., Osin P., Lakhani S.R., Di P.S., Gusterson B.A. and Shipley J.M. (1998a). Comparative genomic hybridization analysis of lobular carcinoma *in situ* and atypical lobular hyperplasia and potential roles for gains and losses of genetic material in breast neoplasia. Cancer Res. 58, 4721-4727.

Lu Y.J., Osin P., Lakhani S.R., Di-Palma S., Gusterson B.A. and Shipley J.M. (1998b). Comparative genomic hybridization analysis of lobular carcinoma *in situ* and atypical lobular hyperplasia and potential roles for gains and losses of genetic material in breast neoplasia. Cancer Res. 58, 4721-4727.

Mastracci T.L., Shadeo A., Colby S.M., Tuck A.B., O'Malley F.P., Bull S.B., Lam W.L. and Andrulis I.L. (2006a). Genomic alterations in lobular neoplasia: a microarray comparative genomic hybridization signature for early neoplastic proliferationin the breast. Genes Chromosomes Cancer 45, 1007-1017.

Mastracci T.L., Shadeo A., Colby S.M., Tuck A.B., O'Malley F.P., Bull S.B., Lam W.L. and Andrulis I.L. (2006b). Genomic alterations in lobular neoplasia: a microarray comparative genomic hybridization signature for early neoplastic proliferationin the breast. Genes Chromosomes Cancer 45, 1007-1017.

Moinfar F., Man Y.G., Bratthauer G.L., Ratschek M. and Tavassoli F.A. (2000). Genetic abnormalities in mammary ductal intraepithelial neoplasia-flat type ("clinging ductal carcinoma *in situ*"): a simulator of normal mammary epithelium. Cancer 88, 2072-2081.

Natrajan R., Lambros M.B., Geyer F.C., Marchio C., Tan D.S., Vatcheva R., Shiu K.K., Hungermann D., Rodriguez-Pinilla S.M., Palacios J., Ashworth A., Buerger H. and Reis-Filho J.S. (2009a). Loss of 16q in high grade breast cancer is associated with estrogen receptor status: Evidence for progression in tumors with a luminal phenotype? Genes Chromosomes Cancer 48, 351-365.

Natrajan R., Lambros M.B., Rodriguez-Pinilla S.M., Moreno-Bueno G., Tan D.S., Marchio C., Vatcheva R., Rayter S., Mahler-Araujo B., Fulford L.G., Hungermann D., Mackay A., Grigoriadis A., Fenwick K., Tamber N., Hardisson D., Tutt A., Palacios J., Lord C.J., Buerger H., Ashworth A. and Reis-Filho J.S. (2009b). Tiling path genomic profiling of grade 3 invasive ductal breast cancers. Clin.Cancer Res. 15, 2711-2722.

Nordgard S.H., Johansen F.E., Alnaes G.I., Bucher E., Syvanen A.C., Naume B., Borresen-Dale A.L. and Kristensen V.N. (2008). Genome-wide analysis identifies 16q deletion associated with survival, molecular subtypes, mRNA expression, and germline haplotypes in breast cancer patients. Genes Chromosomes Cancer 47, 680-696.

O'Connell P., Pekkel V., Fuqua S.A., Osborne C.K., Clark G.M. and Allred D.C. (1998). Analysis of loss of heterozygosity in 399 premalignant breast lesions at 15 genetic loci. J. Natl. Cancer. Inst. 90, 697-703.

Pandis N., Heim S., Bardi G., Idvall I., Mandahl N. and Mitelman F. (1992). Whole-arm t(1;16) and i(1q) as sole anomalies identify gain of 1q as a primary chromosomal abnormality in breast cancer [see comments]. Genes Chromosomes Cancer 5, 235-238.

Pandis N., Bardi G., Jin Y., Dietrich C., Johansson B., Andersen J., Mandahl N., Mitelman F. and Heim S. (1994). Unbalanced t(1;16) as the sole karyotypic abnormality in a breast carcinoma and its lymph node metastasis [letter]. Cancer Genet. Cytogenet. 75, 158-159.

Pandis N., Jin Y., Gorunova L., Petersson C., Bardi G., Idvall I.,'Johansson B., Ingvar C., Mandahl N., Mitelman F. and Heim S. (1995). Chromosome analysis of 97 primary breast carcinomas: identification of eight karyotypic subgroups. Genes Chromosomes Cancer 12, 173-185.

Perou C., Sorlie T., Eisen M., van de Rijn M., Jeffrey S.S., Rees C.A., Pollack J.R., Ross D.T., Johnsen H., Akslen L.A., Fluge O., Pergamenschikov A., Williams C., Zhu S., Lonning P.E., Borresen D.A., Brown P.O. and Botstein D. (2000). Molecular portraits of human breast tumours. Nature 406, 747-752.

Pinkel D., Segraves R., Sudar D., Clark S., Poole I., Kowbel D., Collins C., Kuo W.L., Chen C., Zhai Y., Dairkee S.H., Ljung B.M., Gray J.W. and Albertson D.G. (1998). High resolution analysis of DNA copy number variation using comparative genomic hybridization to microarrays. Nat. Genet. 20, 207-211.

Rakha E.A., Green A.R., Powe D.G., Roylance R. and Ellis I.O. (2006). Chromosome 16 tumor-suppressor genes in breast cancer. Genes Chromosomes Cancer 45, 527-535.

Reis-Filho J.S., Simpson P.T., Jones C., Steele D., Mackay A., Iravani M., Fenwick K., Valgeirsson H., Lambros M., Ashworth A., Palacios J., Schmitt F. and Lakhani S.R. (2005). Pleomorphic lobular carcinoma of the breast: role of comprehensive molecular pathology in characterization of an entity. J. Pathol. 207, 1-13.

Reis-Filho J.S., Milanezi F., Steele D., Savage K., Simpson P.T., Nesland J.M., Pereira E.M., Lakhani S.R. and Schmitt F.C. (2006). Metaplastic breast carcinomas are basal-like tumours. Histopathology 49, 10-21.

Ried T., Just K.E., Holtgreve-Grez H., du Manoir S., Speicher M.R., Schrock E., Latham C., Blegen H., Zetterberg A., Cremer T. and Auert G. (1995). Comparative genomic hybridization of formalinfixed, paraffin-embedded breast tumors reveals different patterns of chromosomal gains and losses in fibroadenomas and diploid and aneuploid carcinomas. Cancer Res. 55, 5415-5423.

Roylance R., Gorman P., Harris W., Barnes D., Hanby A. and Sheer D. (1999). Comparative genomic hybridization of breast tumours stratified by histological grade reveals new insights into the biological progression of breast cancer. Cancer Res. 59, 1433-1436.

Roylance R., Gorman P., Papior T., Wan Y.L., Ives M., Watson J.E., Collins C., Wortham N., Langford C., Fiegler H., Carter N., Gillett C., Sasieni P., Pinder S., Hanby A. and Tomlinson I. (2006). A comprehensive study of chromosome 16q in invasive ductal and lobular breast carcinoma using array CGH. Oncogene 25, 6544-6553.

Santarosa M. and Ashworth A. (2004). Haploinsufficiency for tumour suppressor genes: when you don't need to go all the way. Biochim. Biophys. Acta 1654, 105-122.

Schmidt H., Dahrenmöller C., Agelepoulos K., Hungermann D. and Böcker W. (2008). Früher Verlust der Heterozygotie auf Chromosomenarm 16q in flachen epithelialen Atypien der Brust. Pathologe 29, 328-332.

Simpson P.T., Gale T., Reis-Filho J.S., Jones C., Parry S., Sloane J.P., Hanby A., Pinder S.E., Lee A.H., Humphreys S., Ellis I.O. and Lakhani S.R. (2005). Columnar cell lesions of the breast: the missing link in breast cancer progression? A morphological and molecular analysis. Am. J. Surg. Pathol. 29, 734-746.

Sorlie T., Perou C., Tibshirani R., Aas T., Geisler S., Johnsen H., Hastie T., Eisen M., van de Rijn M., Jeffrey S.S., Thorsen T., Quist H., Matese J.C., Brown P.O., Botstein D., Lonning P.E. and Borresen D.A. (2001). Gene expression patterns of breast carcinomas distinguish tumor subclasses with clinical implications. Proc. Natl. Acad. Sci. USA 98, 10869-10874.

Stacher E., Boldt V., Leibl S., Halbwedl I., Popper H.H., Ullmann R., Tavassoli F.A. and Moinfar F. (2011). Chromosomal aberrations as detected by array comparative genomic hybridization in early lowgrade intraepithelial neoplasias of the breast. Histopathology 59, 549-555.

Stratton M.R., Collins N., Lakhani S.R. and Sloane J.P. (1995). Loss of heterozygosity in ductal carcinoma *in situ* of the breast. J. Pathol. 175, 195-201.

Tamimi R.M., Baer H.J., Marotti J., Galan M., Galaburda L., Fu Y., Deitz A.C., Connolly J.L., Schnitt S.J., Colditz G.A. and Collins L.C. (2008). Comparison of molecular phenotypes of ductal carcinoma *in situ* and invasive breast cancer. Breast Cancer Res. 10, R67.

Tsuda H., Callen D.F., Fukutomi T., Nakamura Y. and Hirohashi S. (1994a). Allele loss on chromosome 16q24.2-qter occurs frequently in breast cancers irrespectively of differences in phenotype and extent of spread. Cancer Res. 54, 513-517.

Tsuda H., Uei Y., Fukutomi T. and Hirohashi S. (1994b). Different incidence of loss of heterozygosity on chromosome 16q between intraductal papilloma and intracystic papillary carcinoma of the breast. Jpn. J. Cancer Res. 85, 992-996.

Tsuda H., Fukutomi T. and Hirohashi S. (1995). Pattern of gene alterations in intraductal breast neoplasms associated with histological type and grade. Clin. Cancer Res. 1, 261-267.

Tsuda H., Takarabe T., Susumu N., Inazawa J., Okada S. and Hirohashi S. (1997). Detection of numerical and structural alterations and fusion of chromosomes 16 and 1 in low-grade papillary breast carcinoma by fluorescence *in situ* hybridization. Am. J. Pathol 151, 1027-1034.

Tsuda H., Takarabe T., Fukutomi T. and Hirohashi S. (1999a). der(16)t(1;16)/der(1;16) in breast cancer detected by fluorescence *in situ* hybridizytion is an indicator of better patient prognosis. Genes Chromosomes Cancer 24, 72-77.

Tsuda H., Takarabe T. and Hirohashi S. (1999b). Correlation of numerical and structural status of chromosome 16 with histological type and grade of non-invasive and invasive breast carcinomas. Int. J. Cancer 84, 381-387.

Tsuda H., Takarabe T., Akashi-Tanaka S., Fukutomi T. and Hirohashi S. (2001a). Pattern of chromosome 16q loss differs between an atypical proliferative lesion and an intraductal or invasive ductal carcinoma occurring subsequently in the same area of the breast. Mod. Pathol. 14, 382-388.

Tsuda H., Takarabe T., Kashi-Tanaka S., Fukutomi T. and Hirohashi S. (2001b). Pattern of chromosome 16q loss differs between an atypical proliferative lesion and an intraductal or invasive ductal carcinoma occurring subsequently in the same area of the breast. Mod. Pathol. 14, 382-388.

Tsuda H., Takarabe T., Kanai Y., Fukutomi T. and Hirohashi S. (2002). Correlation of DNA hypomethylation at pericentromeric heterochromatin regions of chromosomes 16 and 1 with histological features and chromosomal abnormalities of human breast carcinomas. Am. J. Pathol. 161, 859-866.

van Wezel T., Lombaerts M., van Roon E.H., Philippo K., Baelde H.J., Szuhai K., Cornelisse C.J. and Cleton-Jansen A.M. (2005). Expression analysis of candidate breast tumour suppressor genes on chromosome 16q. Breast Cancer Res. 7, R998-1004.

van-Diest P.J. (1999). Ductal carcinoma *in situ* in breast carcinogenesis. J. Pathol. 187, 383-384.

Vincent-Salomon A., Gruel N., Lucchesi C., Macgrogan G., Dendale R., Sigal-Zafrani B., Longy M., Raynal V., Pierron G., de Mascarel I, Taris C., Stoppa-Lyonnet D., Pierga J.Y., Salmon R., Sastre-Garau X., Fourquet A., Delattre O., de Cremoux P. and Aurias A. (2007). Identification of typical medullary breast carcinoma as a genomic sub-group of basal-like carcinomas, a heterogeneous new molecular entity. Breast Cancer Res. 9, R24-

Vincent-Salomon A., Lucchesi C., Gruel N., Raynal V., Pierron G., Goudefroye R., Reyal F., Radvanyi F., Salmon R., Thiery J.P., Sastre-Garau X., Sigal-Zafrani B., Fourquet A. and Delattre O. (2008). Integrated genomic and transcriptomic analysis of ductal carcinoma *in situ* of the breast. Clin. Cancer Res. 14, 1956-1965.

Vos C.B., ter Haar N.T., Rosenberg C., Peterse J.L., Cleton J.A., Cornelisse C.J. and van-de Vijver M.J. (2000). Genetic alterations on chromosome 16 and 17 are important features of ductal carcinoma *in situ* of the breast and are associated with histologic type. Br. J. Cancer 81, 1410-1418.

Waldman F., DeVries S., Chew K., Moore D.H., Kerlikowske K. and Ljung B.M. (2000). Chromosomal alterations in ductal carcinomas *insitu* and their *in situ* recurrences. J. Natl. Cancer Inst. 92, 323-320.

Waldman F.M., Hwang E.S., Etzell J., Eng C., DeVries S., Bennington J. and Thor A. (2001). Genomic alterations in tubular breast carcinomas. Hum. Pathol. 32, 222-226.

Wang Z.C., Lin M., Wei L.J., Li C., Miron A., Lodeiro G., Harris L., Ramaswamy S., Tanenbaum D.M., Meyerson M., Iglehart J.D. and Richardson A. (2004). Loss of heterozygosity and Its correlation with expression profiles in subclasses of invasive breast cancers. Cancer Res. 64, 64-71.

Wennmalm K., Calza S., Ploner A., Hall P., Bjohle J., Klaar S., Smeds J., Pawitan Y. and Bergh J. (2007). Gene expression in 16q is associated with survival and differs between Sorlie breast cancer subtypes. Genes Chromosomes Cancer 46, 87-97.

Whitmore S.A., Crawford J., Apostolou S., Eyre H., Baker E., Lower K.M., Settasatian C., Goldup S., Seshadri R., Gibson R.A., Mathew C.G., Cleton-Jansen A.M., Savoia A., Pronk J.C., Auerbach A.D., Doggett N.A., Sutherland G.R. and Callen D.F. (1998). Construction of a high-resolution physical and transcription map of chromosome 16q24.3: a region of frequent loss of heterozygosity in sporadic breast cancer. Genomics 50, 1-8.

Zudaire I., Odero M.D., Caballero C., Valenti C., Martinez-Penuela J.M., Isola J. and Calasanz M.J. (2002). Genomic imbalances detected by comparative genomic hybridization are prognostic markers in invasive ductal breast carcinomas. Histopathology 40, 547-555.

Chapter 3

Dimorphic cells: a common feature throughout the low nuclear grade breast neoplasia spectrum

Mirthe de Boer, Paul J. van Diest

Virchows Archiv (2023) 482:369–375

Abstract

Columnar cell lesions (CCLs) are recognized precursor lesions of the low nuclear grade breast neoplasia family. CCLs are cystic enlarged terminal duct lobular units with monotonous (monoclonal) columnar-type luminal cells. CCLs without atypia are regarded as benign and CCLs with atypia as true precursor lesions with clonal molecular changes, a certain progression risk, and an association with more advanced lesions. However, reproducibility of designating atypia in CCL is not optimal, and no objective markers of atypia have been identified, although 16q loss seems to be associated with atypical CCLs. Dimorphic ("pale") cell populations have been described in low nuclear grade ductal carcinoma in situ (DCIS) but not in CCLs and atypical ductal hyperplasia (ADH). Therefore, we searched for pale cells in CCL (N = 60), ADH (N = 41), and DCIS grade 1 (N = 84). Diagnostic criteria were derived from the WHO, and atypia was designated according to the Schnitt criteria. Pale cells occurred in 0% (0/30), 73% (22/30), 56% (23/41), and 76% (64/84) of CCLs without atypia, CCLs with atypia, ADH, and DCIS grade 1, respectively. Pale cells expressed ERα, E-cadherin and p120 and variably cyclin D1, and lacked expression of CK5 and p63. In conclusion, dimorphic "pale" cells occur throughout the low nuclear grade progression spectrum, increasing in frequency with progression. Interestingly, CCL lesions without atypia do not seem to bear pale cells, indicating that the presence of pale cells may serve as a diagnostic morphological feature of atypia in CCLs.

Introduction

Columnar cell lesions (CCLs) of the breast are cystically dilated enlarged terminal duct lobular units lined by columnar luminal cells with uniform, ovoid nuclei and often with apical cytoplasmic blebs or snouts presenting at the luminal surface. The lining is usually one or two cell layers (columnar cell change) although multiple cell layers may be present, usually denoted columnar cell hyperplasia. Intraluminal secretions and microcalcifications are commonly seen [1]. In columnar cell change with atypia, also denoted flat epithelial atypia (FEA), the columnar cells show nuclear atypia of relatively round to ovoid nuclei with or without prominent nucleoli and an increased nuclear/cytoplasmic ratio and/or disturbed nuclear orientation along the basement membrane. A complex architectural pattern (micropapillae, rigid cellular bridges, bars and arcades, or cribriform architecture) necessitates upgrading a CCL to atypical ductal hyperplasia (ADH) or low-grade ductal carcinoma in situ (DCIS) [2, 3].

The diagnosis of atypia in a CCL is of clinical importance. They are both recognized as low-grade preneoplasms of the breast with clonal molecular alterations [4, 5]. Nevertheless, the diagnosis CCL without atypia does not have consequences for treatment because of a low upgrade risk. In contrast, CCLs with atypia are considered true precursor lesions of the low nuclear grade breast cancer family [4–7], with upgrade rates of 5–9% [8, 9] and an association with more advanced lesions (ADH [10–16], DCIS grade 1 [1, 11, 14, 17, 18], lobular neoplasia [10, 12, 14, 16, 19–22], and tubular cancer [7, 17, 19, 20, 23, 24]) in about 20% of patients [25]. This necessitates a discussion about further follow-up and/or treatment in individual patients with atypical CCLs.

However, reproducibility of designating atypia in CCL is generally low. Although O'Malley achieved excellent agreement (multi-rater kappa value 0.83) in diagnosing atypical CCLs after a tutorial in a selected case set [26], other groups found substantially lower kappa values (0.27 and 0.41) [27–29]. Two recent meta-analyses described pooled upgrade rate of pure FEA diagnosed by CNB of 5% and 9% [8, 9]. The difference between these studies is that Wahab et al. also included imaging follow-up, whereas Ferre et al. analyzed only the results of surgical excision. In contrast to the results of these studies based on standardized second opinion, publications without this standard show upgrade rates at the surgical specimen between 0 and 30% for CNB-based diagnosed pure FEAs [30]. This also indicates that the reproducibility of diagnosis of atypia in CCL is not optimal in routine practice. So far, no phenotypical markers of atypia have unfortunately been identified.

Dimorphic cells have been described in the literature in three original publications so far [31–33]. Altogether, they have been described in 70 cases (Lefkowitz (1994), 20 cases; Ueno (2018), 50 cases; Koerner (2010), not specified), predominantly in papillary carcinomas [31, 33] and besides in 40 invasive NST carcinomas but also in 10 DCIS cases [32]. The frequency of dimorphic cells in DCIS is however not well-established. Koerner described that careful scrutiny reveals frequent cellular dimorphism in DCIS [33]. Others describe a dimorphic type DCIS as an unusual variant [34, 35]. The cells are characterized by clear cytoplasm-simulating myoepithelial cells but with nuclei similar to those in the adjacent malignant cells, rounded cell borders, and clear cytoplasm in the H&E stain. Several of these articles indicate that dimorphic cell populations are especially seen in low nuclear grade DCIS, which makes it plausible that these "pale cells" would also occur in earlier precursor lesions of the low nuclear grade family. Indeed, our impression was that we regularly encounter pale cells in our practice in lowgrade precursor lesions, but dimorphic differentiation has to the best of our knowledge not been described in CCLs and ADH before. This prompted us to systematically retrospectively evaluate the presence of pale cells in a group of ADH and CCL lesions to cover the earliest spectrum of the low nuclear grade precursor lesions, in search of further morphological features of CCLs, especially with regard to the designation "atypia."

Material and Methods

Slides from 185 formalin-fixed, paraffin-embedded breast tissue samples (biopsies or resections) with CCLs ($N = 60$), ADH ($N = 41$), and DCIS grade 1 ($N = 84$) were collected from the Department of Pathology of the University Medical Center Utrecht between July 2017 and July 2018. CCLs were graded according to the classification described by Schnitt and Vincent-Salomon [3] as CCLs without atypia ($N = 30$) and CCLs with atypia ($N = 30$). Designation of DCIS grade 1 and atypical ductal hyperplasia was assessed by two experienced observers, according to the World Health Organization classification [36, 37]. The presence of co-existing lobular neoplasia (LN) was noted, confirmed by E-cadherin immunohistochemistry when deemed necessary.

A dimorphic cell population was defined as epithelial cells with clear cytoplasm with nuclei similar to those in the adjacent clonal cells, rounded cell borders, and clear cytoplasm in the H&E stain, often located between the luminal and myoepithelial layers, simulating pagetoid spread of LN. The CCLs, ADH, and DCIS lesions were screened for the presence of these pale cells. This was not done in pure LN since pale cells resemble the cells of LN. Routinely performed immunohistochemical stains

were screened to identify the expression patterns of pale cells. Since pale cells are often scattered as single cells throughout lesions, E-cadherin stains were especially scrutinized for adjacent pale cells and pale cell groups to pinpoint membrane expression or lack thereof.

Results

Table 1 shows the frequency of pale cells in the various low nuclear grade breast precursor lesions studied. Pale cells occurred in 0% (0/30), 73% (22/30), 56% (23/41), and 76% (64/84) of CCLs without atypia, CCLs with atypia, ADH, and DCIS grade 1, respectively. Figure 1 shows examples of pale cells in CCLs with atypia, ADH, and DCIS grade 1. In some ADH and DCIS lesions, clusters of pale cells were observed ("clonal expansion") that rarely formed tubular structures (Fig. 1). Pale cells turned out to be expressing ERα, PR, E-cadherin, AR and p120 and variably cyclin D1, and lacked expression of CK5 and p40 (Fig. 2 and Fig. 3). Figure 2 also shows a comparison of the immunophenotype of pale cells and its mimics. Pagetoid spread of LN below the pre-existent luminal epithelium clonally expressed ERα while lacking CK5, p40 expression, and E-cadherin. Prominent myoepithelium in blunt duct adenosis expressed CK5 and p40 while lacking ERα expression, and clusters of ductal hyperplastic cells below the pre-existent luminal epithelium expressed CK5 and ERα while lacking p40.

Diagnosis	#	# patients	mean age (range)	#biopsy	#resection	#with pale cells (%)
CCL without atypia	30	29	49.7 (37-70)	25	5	0 (0%)
CCL with atypia	30	27	51.3 (39-71)	21	9	22 (73%)
ADH	41	41	44.5 (40-76)	32	9	23 (56%)
DCIS grade 1	84	67	61.6 (35-84)	35	49	64 (76%)

Table 1. Frequency of dimorphic ("pale") cells in different lesions throughout the spectrum of the low nuclear grade breast neoplasia family (CCL= columnar cell lesion, ADH=atypical ductal hyperplasia, DCIS= ductal carcinoma *in situ*).

Discussion

Dimorphic "pale" cell populations were first described in papillary DCIS as epithelial cells with clear cytoplasmsimulating myoepithelial cells, but with nuclei similar to those in the adjacent malignant cells, rounded cell borders, and clear cytoplasm in the H&E stain [29], later designated as a feature of low nuclear grade DCIS. We here show that pale cells frequently occur in true low-grade nuclear breast precursor lesions, in 109 of 155 precursor lesions (CCL with atypia 22/30, ADH 23/41, DCIS grade 1 64/84) while being absent in 30 CCL lesions without atypia. This indicates that the presence of pale cells may serve as a diagnostic feature of atypia in CCLs. Pale cells expressed ERα, E-cadherin and p120 and variably cyclin D1, and lacked expression of CK5 and p40.

The biological background of these pale cells is not clear. Theoretically, they could be luminal epithelial cells with a slightly different morphology, scattered apocrine cells, scattered LN cells, neuroendocrine cells, or myoepithelial cells. Since pale cells express ERα and PR, an apocrine origin is unlikely, and the expression of E-cadherin largely rules out LN. The expression of ERα and the lack of CK5 and p40 expression rule out myoepithelial origin [38]. We therefore hypothesize that these pale cells are neoplastic luminal epithelial cells, compatible with the observed expression of ERα and the lack of CK5 expression. We have however no explanation why they morphologically stand out. This requires further molecular studies, e.g., applying single-cell sequencing on microdissected pale cells, but this is yet technically challenging on paraffin-embedded tissue. Perhaps, they are a subclone, as we sometimes see clonal expansion of pale cell-forming groups that start to take over precursor lesions (Fig. 1). This may also explain the previously described dimorphic lesions [31–35]. Further, when lesions are fully comprised of pale cells, they may be hard to designate as "pale," indicating that the frequency of pale cell lesions reported here may be underestimated. Pale cells have also been described to express AR and BRST2 [32], compatible with their luminal breast origin.

In conclusion, we here describe that dimorphic "pale" cells frequently occur throughout the low nuclear grade breast progression spectrum (CCL with atypia, ADH, DCIS grade 1). Interestingly, CCLs without atypia did not show pale cells, indicating that the presence of pale cells may serve as a diagnostic morphological feature of atypia in CCLs.

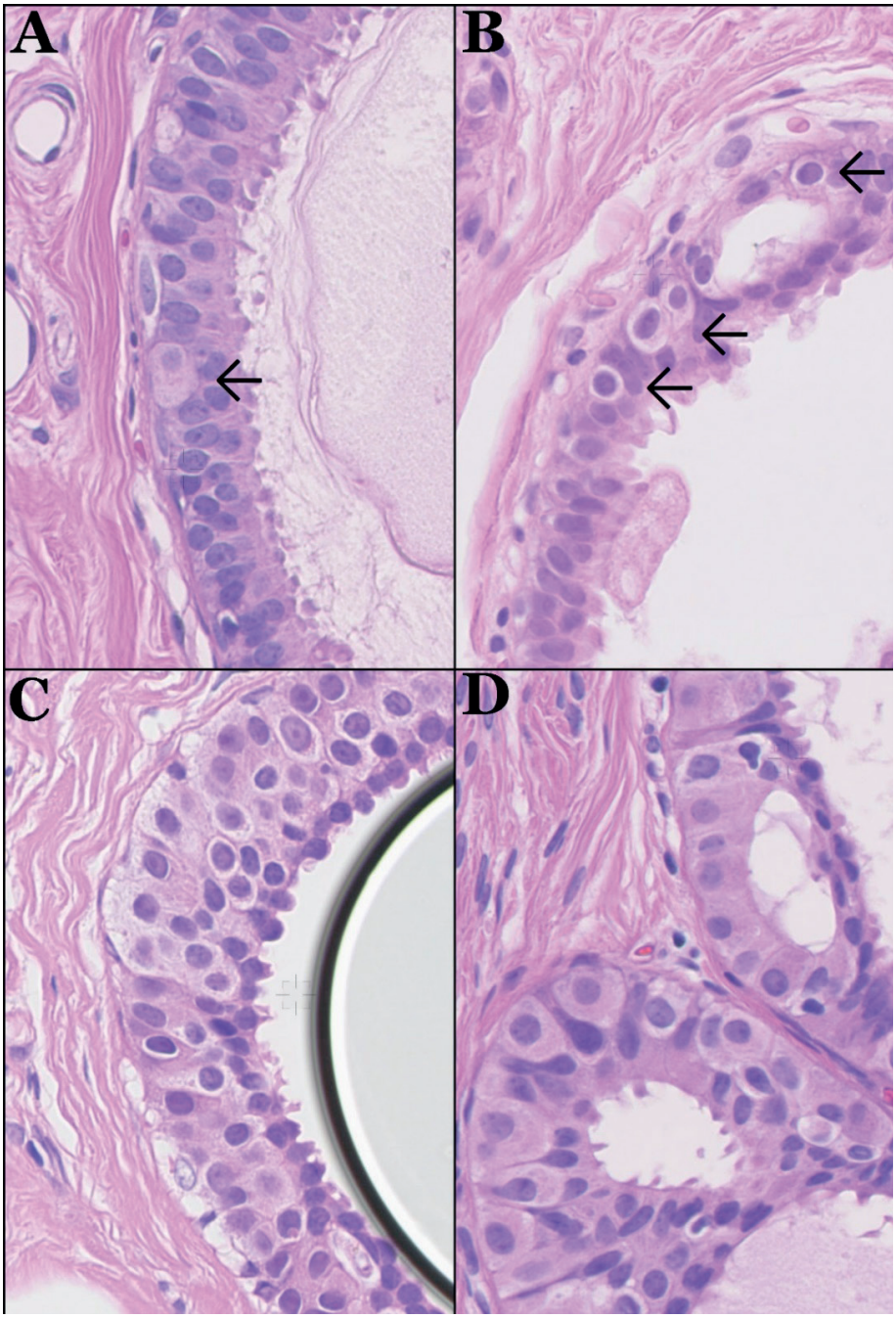

Fig. 1 Representative examples of A. Single pale cells in CCL with atypia (**B**). Single pale cell in ADH, as well as examples of clonal expansion of pale cells, linear in CCL with atypia (**C**), and forming tubular structures (**D**) in DCIS grade 1

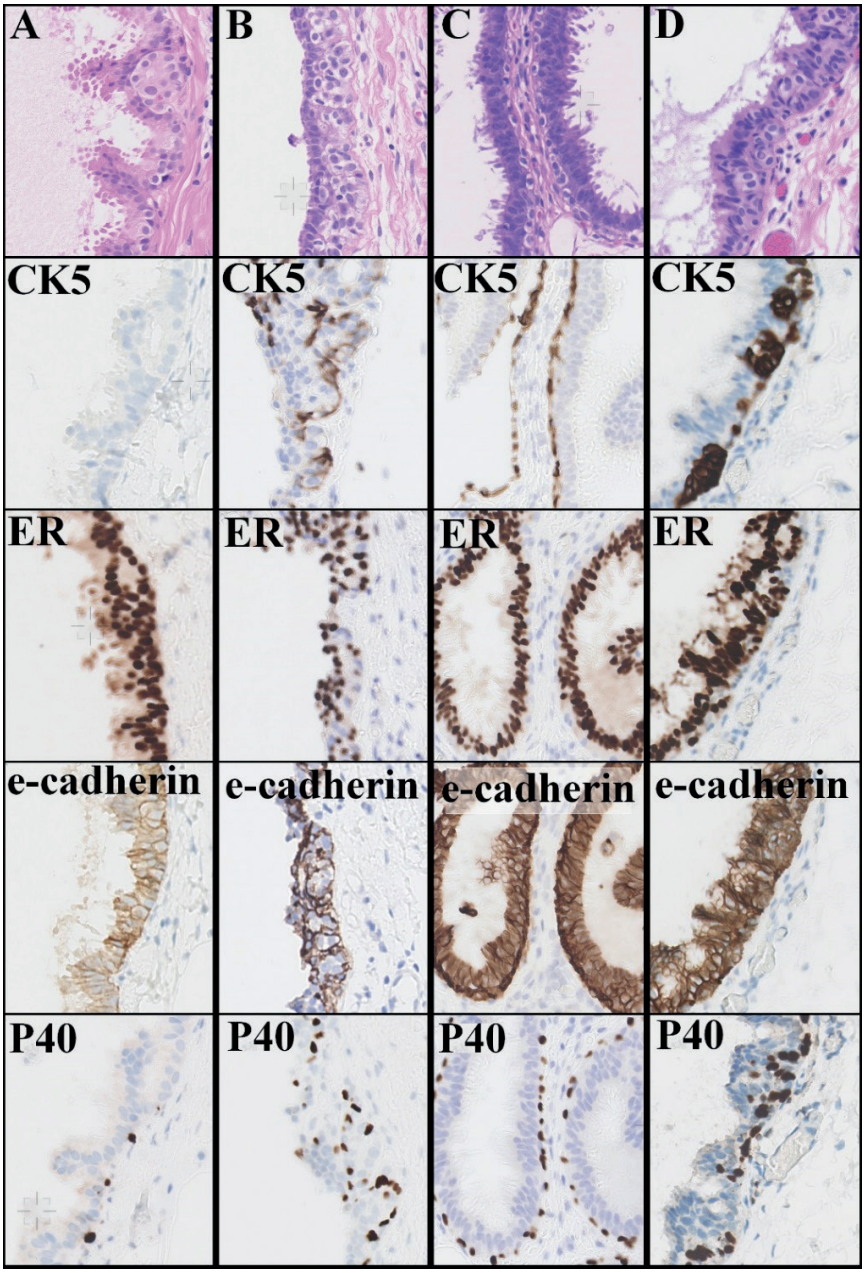

Fig. 2 Immunophenotype of pale cells versus its mimics. Column **A**, pale cells in micropapillary ductal carcinoma in situ (column **A**) clonally expressing ERα while lacking CK5 and p40 expression, with normal membrane expression of E-cadherin. Column **B**, pagetoid spread below the pre-existent luminal epithelium of lobular neoplasia cells clonally expressing ERα while lacking CK5 and p40 expression as well as lacking membrane expression of E-cadherin. Column **C**, blunt duct adenosis with prominent myoepithelium that expresses CK5 and p40 while lacking Erα expression. Column **D**, clusters of ductal hyperplastic cells below the pre-existent luminal epithelium expressing CK5 and ERα while lacking p40

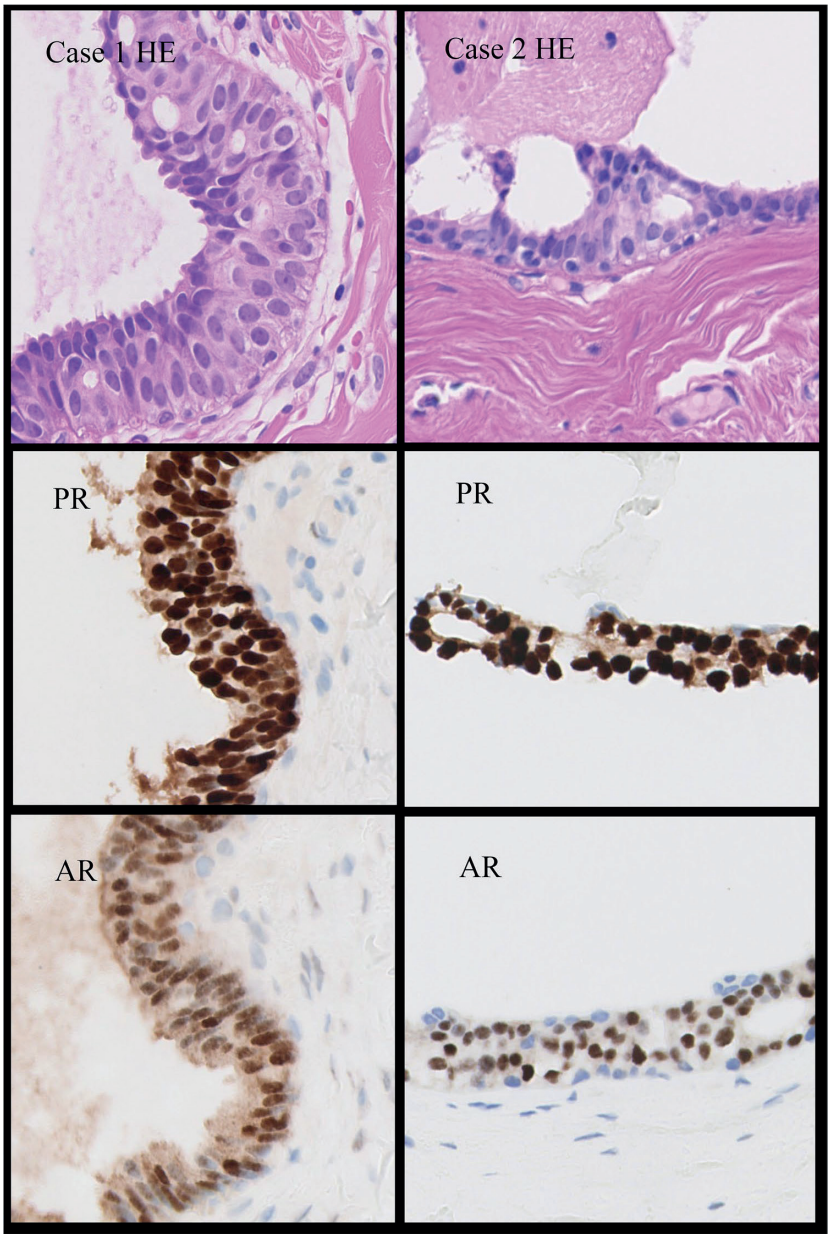

Fig. 3 Immunophenotype of pale cells. Case 1, extensive pale cells in atypical ductal hyperplasia clonally expressing PR and AR. Case 2, pagetoid pale cells in micropapillary ductal carcinoma in situ, forming small cribriform structures, clonally expressing PR and AR

References

1. Fraser JL, Raza S, Chorny K, Connolly JL, Schnitt SJ (1998) Columnar alteration with prominent apical snouts and secretions: a spectrum of changes frequently present in breast biopsies performed for microcalcifications. Am J Surg Pathol 22(12):1521– 1527. https:// doi. org/ 10. 1097/ 00000 478- 19981 2000- 00009
2. Schnitt S (2003) The diagnosis and management of pre-invasive breast disease: flat epithelial atypia—classification, pathologic features and clinical significance. Breast Cancer Res 5(5):263– 268. https:// doi. org/ 10. 1186/ bcr625
3. Schnitt S, Vincent Salomon A (2003) Columnar cell lesions of the breast. Adv Anat Pathol 10(3):113–124. https:// doi. org/ 10. 1097/ 00125 480- 20030 5000- 00001
4. Simpson P, Gale T, Reis Filho J, Jones C, Parry S, Sloane J, Hanby A, Pinder S, Lee AHS, Humphreys S, Ellis I, Lakhani S (2005) Columnar cell lesions of the breast: the missing link in breast cancer progression? A morphological and molecular analysis. Am J Surg Pathol 29(6):734–746. https:// doi. org/ 10. 1097/ 01. pas. 00001 57295. 93914. 3b
5. de Boer M, Verschuur-Maes AHJ, Buerger H, Moelans CB, Steenkamer M, Savola S, van Diest PJ (2018) Role of columnar cell lesions in breast carcinogenesis: analysis of chromosome 16 copy number changes by multiplex ligation-dependent probe amplification. Mod Pathol 31:1816–1833. https:// doi. org/ 10. 1038/ s41379- 018- 0099-2
6. Abdel-Fatah TMA, Powe D, Hodi Z, Reis Filho J, Lee AHS, Ellis I (2008) Morphologic and molecular evolutionary pathways of low nuclear grade invasive breast cancers and their putative precursor lesions: further evidence to support the concept of low nuclear grade breast neoplasia family. Am J Surg Pathol 32(4):513–523. https:// doi. org/ 10. 1097/ PAS. 0b013 e3181 61d1a5
7. Moinfar F, Man YG, Bratthauer GL, Ratschek M, Tavassoli FA (2000) Genetic abnormalities in mammary ductal intraepithelial neoplasia-flat type ("clinging ductal carcinoma in situ"): a simulator of normal mammary epithelium. Cancer 88(9):2072–2081
8. Ferre R, Kuzmiak CM (2022) Upgrade rate of percutaneously diagnosed pure flat epithelial atypia: systematic review and metaanalysis of 1,924 lesions J Osteopathic Med 122:253–262. https:// doi. org/ 10. 1515/ jom- 2021- 0206
9. Wahab RA, Lee S-J, Mulligan ME, Zhang B, Mahoney MC (2021) Upgrade rate of pure flat epithelial atypia diagnosed at core needle biopsy: a systematic review and meta-analysis radiology. Imaging Cancer 3:e200116–e200116. https:// doi. org/ 10. 1148/ rycan. 20212 00116
10. Boulos F, Dupont W, Simpson J, Schuyler P, Sanders M, Freudenthal M, Page D (2008) Histologic associations and longterm cancer risk in columnar cell lesions of the breast: a retrospective cohort and a nested case-control study. Cancer 113(9):2415–2421. https:// doi. org/ 10. 1002/ cncr. 23873
11. Chivukula M, Bhargava R, Tseng G, Dabbs D (2009) Clinicopathologic implications of "flat epithelial atypia" in core needle biopsy specimens of the breast. Am J Clin Pathol 131(6):802–808. https:// doi. org/ 10. 1309/ AJCPL DG6TT 7VAHPH

12. Collins L, Achacoso N, Nekhlyudov L, Fletcher S, Haque R, Quesenberry C, Alshak N, Puligandla B, Brodsky G, Schnitt S, Habel L (2007) Clinical and pathologic features of ductal carcinoma in situ associated with the presence of flat epithelial atypia: an analysis of 543 patients. Mod Pathol 20(11):1149–1155. https:// doi. org/ 10. 1038/ modpa thol. 38009 49
13. Kunju L, Kleer C (2007) Significance of flat epithelial atypia on mammotome core needle biopsy: should it be excised? Hum Pathol 38(1):35–41. https:// doi. org/ 10. 1016/j. humpa th. 2006. 08. 008
14. Lavoue V, Roger C, Poilblanc M, Proust N, Monghal Verge C, Sagan C, Tas P, Mesbah H, Poree P, Gay C, Body G, Leveque J (2011) Pure flat epithelial atypia (DIN 1a) on core needle biopsy: study of 60 biopsies with follow-up surgical excision. Breast Cancer Res Treat 125(1):121–126. https:// doi. org/ 10. 1007/ s10549- 010- 1208-1
15. Lee T, Macintosh R, Rayson D, Barnes P (2010) Flat epithelial atypia on breast needle core biopsy: a retrospective study with clinical-pathological correlation. Breast J 16(4):377–383. https:// doi. org/ 10. 1111/j. 1524- 4741. 2010. 00934.x
16. Senetta R, Campanino P, Mariscotti G, Garberoglio S, Daniele L, Pennecchi F, Macri L, Bosco M, Gandini G, Sapino A (2009) Columnar cell lesions associated with breast calcifications on vacuum-assisted core biopsies: clinical, radiographic, and histological correlations. Mod Pathol 22(6):762–769. https:// doi. org/ 10. 1038/ modpa thol. 2009. 21
17. Goldstein NS, O'Malley BA (1997) Cancerization of small ectatic ducts of the breast by ductal carcinoma in situ cells with apocrine snouts: a lesion associated with tubular carcinoma. Am J Clin Pathol 107(5):561–566. https:// doi. org/ 10. 1093/ ajcp/ 107.5. 561
18. Oyama T, Iijima K, Takei H, Horiguchi J, Iino Y, Nakajima T, Koerner F (2000) Atypical cystic lobule of the breast: an early stage of low-grade ductal carcinoma in-situ. Breast Cancer 7(4):326–331. https:// doi. org/ 10. 1007/ BF029 66399
19. Abdel-Fatah TMA, Powe D, Hodi Z, Lee AHS, Reis Filho J, Ellis I (2007) High frequency of coexistence of columnar cell lesions, lobular neoplasia, and low grade ductal carcinoma in situ with invasive tubular carcinoma and invasive lobular carcinoma. Am JSurg Pathol 31(3):417–426. https:// doi. org/ 10. 1097/ 01. pas. 00002 13368. 41251. b9
20. Sahoo S, Recant W (2005) Triad of columnar cell alteration, lobular carcinoma in situ, and tubular carcinoma of the breast. Breast J 11(2):140–142. https:// doi. org/ 10. 1111/j. 1075- 122X. 2005. 21616.x
21. Dessauvagie B, Zhao W, Heel Miller K, Harvey J, Bentel J (2007) Characterization of columnar cell lesions of the breast: immunophenotypic analysis of columnar alteration of lobules with prominent apical snouts and secretions. Hum Pathol 38(2):284– 292. https:// doi. org/ 10. 1016/j. humpa th. 2006. 08. 003
22. Kunju L, Ding Y, Kleer C (2008) Tubular carcinoma and grade 1 (well-differentiated) invasive ductal carcinoma: comparison of flat epithelial atypia and other intra-epithelial lesions. Pathol Int 58(10):620–625. https:// doi. org/ 10. 1111/j. 1440- 1827. 2008. 02280.x
23. Aulmann S, Elsawaf Z, Penzel R, Schirmacher P, Sinn H (2009) Invasive tubular carcinoma of the breast frequently is clonally related to flat epithelial atypia and low-grade ductal carcinoma in situ. Am J Surg Pathol 33(11):1646–1653. https:// doi. org/ 10. 1097/ PAS. 0b013 e3181 adfdcf

24. Rosen PP (1999) Columnar cell hyperplasia is associated with lobular carcinoma in situ and tubular carcinoma. Am J Surg Pathol 12:1561. https:// doi. org/ 10. 1097/ 00000 478- 19991 2000- 00017
25. Verschuur-Maes AH, van Deurzen CH, Monninkhof EM, van Diest PJ (2012) Columnar cell lesions on breast needle biopsies: is surgical excision necessary? A systematic review. Ann Surg 255:259–265. https:// doi. org/ 10. 1097/ SLA. 0b013 e3182 33523f
26. O'Malley FP, Mohsin SK, Badve S, Bose S, Collins LC, Ennis M, Kleer CG, Pinder SE, Schnitt SJ (2006) Interobserver reproducibility in the diagnosis of flat epithelial atypia of the breast. Mod Pathol 19:172–179. https:// doi. org/ 10. 1038/ modpa thol. 38005 14
27. Gomes DS, Porto SS, Balabram D, Gobbi H (2014) Inter-observer variability between general pathologists and a specialist in breast pathology in the diagnosis of lobular neoplasia, columnar cell lesions, atypical ductal hyperplasia and ductal carcinoma in situ of the breast. Diagn Pathol 9:121. https:// doi. org/ 10. 1186/ 1746- 1596-9- 121
28. Tan PH, Ho BC, Selvarajan S, Yap WM, Hanby A (2005) Pathological diagnosis of columnar cell lesions of the breast: are there issues of reproducibility? J Clin Pathol 58(7):705–709. https:// doi. org/ 10. 1136/ jcp. 2004. 025239
29. Haupt B, Schwartz MR, Xu Q, Ro JY (2010) Columnar cell lesions: a consensus study among pathology trainees. Hum Pathol 41(6):895–901. https:// doi. org/ 10. 1016/j. humpa th. 2009. 12. 003
30. DiPasquale A, Silverman S, Farag E, Peiris L (2020) Flat epithelial atypia: are we being too aggressive? Breast Cancer Res Treat 179:511–517. https:// doi. org/ 10. 1007/ s10549- 019- 05481-9
31. Lefkowitz M, Lefkowitz W, Wargotz ES (1994) Intraductal (intracystic) papillary carcinoma of the breast and its variants: a clinicopathological study of 77 cases. Hum Pathol 25:802–809. https:// doi. org/ 10. 1016/ 0046- 8177(94) 90250-X
32. Ueno N, Kuroda H, Kurosumi M, Kozuka Y, Ito J, Kato H, Kubota K (2018) Imai Y (2010) Clinicopathological study of a dimorphic variant of breast carcinoma. Breast Cancer 25:151–158. https:// doi. org/ 10. 1007/ s12282- 017- 0804-x
33. Koerner F (2010) Papilloma and papillary carcinoma. Semin Diagn Pathol 27:13–30. https:// doi. org/ 10. 1053/j. semdp. 2009.12. 004
34. Rakha E, Ellis I.(2016) Ductal carcinoma in situ. In: Dabbs DJ. Breast Pathology 2nd Edition. Elsevier, pp 471–488.
35. Hoda SA. (2020) Ductal carcinoma in situ. In: Hoda SA, Brogi E, Koerner FC, Rosen PP. Rosen's breast pathology. Fifth edition, Wolters-Kluwer pp363–451.
36. Tse GMK, Tan P, Lui PCW, Gilks CB, Poon CSP, Ma TKF, Lam Law BKB, WWM, (2007) The role of immunohistochemistry for smooth-muscle actin, p63, CD10 and cytokeratin 14 in the differential diagnosis of papillary lesions of the breast. J Clin Pathol 60(3):315–20. https:// doi. org/ 10. 1136/ jcp. 2006. 036830
37. Cardenosa G, Eklund GW (1991) Benign papillary neoplasms of the breast: mammographic findings. Radiology 181(3):751–755. https:// doi. org/ 10. 1148/ radio logy. 181.3. 19470 92
38. Sailer V, Luders C, Kuhn W, Pelzer V, Kristiansen G (2015) Immunostaining of ΔNp63 (using the p40 antibody) is equal to that of p63 and CK5/6 in high-grade ductal carcinoma in situ of the breast. Virchows Arch 467(1):67–70. https:// doi. org/ 10. 1007/ s00428- 015- 1766-z

Chapter 4

Role of columnar cell lesions in breast carcinogenesis: analysis of chromosome 16 copy number changes by multiplex ligation-dependent probe amplification

Mirthe de Boer, Anoek H. J. Verschuur-Maes, Horst Buerger, Cathy B Moelans, Maryvonne Steenkamer, Suvi Savola, Paul J. van Diest

Modern Pathology (2018) 31:1816–1833

Abstract

Columnar cell lesions have been proposed as precursor lesions of low-grade breast cancer. The molecular characteristic of low-grade breast neoplasia is whole-arm loss of chromosome 16q. Copy number changes of 6 genes on 16p and 20 genes on 16q were analysed by multiplex ligation-dependent probe amplification in 165 lesions of 103 patients. Twenty-three columnar cell lesions and 19 atypical ducal hyperplasia lesions arising in columnar cell lesions were included, as well as cases of usual ductal hyperplasia, blunt duct adenosis, ductal carcinoma in situ, lobular neoplasia and invasive carcinoma. Usual ductal hyperplasia and blunt duct adenosis lacked whole-arm losses of 16q. In contrast, columnar cell lesions without atypia, columnar cell lesions with atypia, atypical ductal hyperplasia, low-grade ductal carcinoma in situ and low-grade invasive carcinomas increasingly harboured whole-arm losses of 16q (17%, 27%, 47% and 57%, respectively). However, no recurrent losses in specific genes could be identified. In several patients, columnar cell lesions and atypical ductal hyperplasia harboured similar losses as related ductal carcinoma in situ or invasive carcinomas within the same breast. There were indications for 16q breakpoints near the centromere. Whole-arm gains on 16p were relatively scarce and there was no relation between whole-arm gains of 16p and progression of lesions of the low-grade breast neoplasia family. In conclusion, columnar cell lesions (with and without atypia) often harbour whole-arm losses of 16q, which underlines their role as precursors in low-grade breast carcinogenesis, in contrast with usual ductal hyperplasia and blunt duct adenosis. However, no recurrent losses in specific genes could be identified, pointing to minor events in multiple tumour suppressor genes rather than major events in a single 16q gene contributing to low-grade breast carcinogenesis.

Introduction

Columnar cell lesions of the breast are cystically dilated enlarged terminal duct lobular units lined by columnar cells often with apical cytoplasmic blebs or snouts present at the luminal surface. The lining consists of one or two (columnar cell change), or more (columnar cell hyperplasia) cell layers. Intraluminal secretions and microcalcifications are frequently seen [1]. In columnar cell lesions with atypia, the columnar cells show nuclear atypia of relatively round to ovoid, sometimes irregular nuclei with prominent nucleoli and an increased nuclear/cytoplasmic ratio. In addition, the nuclear orientation along the basement membrane can be disturbed. Complex architectural patterns upgrade a columnar cell lesion to atypical ductal hyperplasia or low-grade ductal carcinoma in situ [2, 3]. Columnar cell lesions with atypia have also been denoted flat epithelial atypia [2]. In recent years it has been recognized that columnar cell lesions have a possible role as precursor of low nuclear grade breast cancer [4–6].

Multiple studies on chromosome 16 aberrations in breast cancer have shown an association between loss of the long arm of chromosome 16 [16q] and low-grade breast cancer [7–13]. These losses of chromosome 16q have also been reported in premalignant lesions, such as atypical ductal hyperplasia, low-grade ductal carcinoma in situ and lobular neoplasia [14–22]. Thereby, this chromosomal aberration is probably one of the first steps in low-grade carcinogenesis.

Several authors have investigated aberrations on chromosome 16 in columnar cell lesions by loss of heterozygosity analysis, (array) comparative genomic hybridization or fluorescent in situ hybridization [5, 6, 23–26]. The results of these studies vary strongly (see Table 1), most likely due to the small number of tested lesions, different types of columnar cell lesions studied and use of different DNA probes, varying definitions of columnar cell lesions and inter-observer variability in diagnosing columnar cell lesions [27, 28]. In addition, the presence of whole-arm loss in columnar cell lesions was never reported, suggesting that these results might be incomplete.

Therefore, in this study we investigated in depth copy number changes of 21 genes on 16q and 6 genes on 16p in columnar cell lesions, and other lesions of the low-nuclear-grade breast neoplasia family (atypical ductal hyperplasia, ductal carcinoma in situ, invasive ductal carcinoma, lobular neoplasia and invasive lobular carcinoma). In addition, high-nuclear-grade (pre)malignant lesions (ductal carcinoma in situ and invasive ductal carcinoma) and benign, columnar cell-like lesions (usual ductal hyperplasia and blunt duct adenosis) were analysed. To our knowledge, this is the

Table 1 Overview of studies on chromosome 16 changes in columnar cell lesions of the breast

chromosomal arm	Author	Method	DNA marker	Location	Type of CCL	Gains (G) / Losses (L)	Frequency (%)	absolute numbers
16p	Simpson[6]	CGH			CCL without atypia	G	16%	4/25
	Simpson[6]	CGH			CCL with atypia	G	20%	2/10
	Simpson[6]	CGH			CCL without atypia	L	32%	8/25
16q	Go[25]	FISH		16q12.3-13; 16q22.1; 16q23.2	CCL without atypia	Heteroz del	0%	0/19
	Ellsworth[24]	LOH		16q11.2 – 22.1	CCL with/without atypia		7%	3/42
	Ellsworth[24]	LOH		16q22.3 – 24.3	CCL with/without atypia		5%	2/42
	Moinfar[5]	LOH	D16S518	16q23.1-24.2	CCL with atypia		33%	2/6
	Moinfar[5]	LOH	D16S402	16q24.2	CCL with atypia		27%	3/11
	Aulmann[48]	LOH	D16S539	16q24	CCL with atypia		27%	3/11
	Aulmann[48]	LOH	D16S2624	16q22.3	CCL with atypia		46%	11/24
	Simpson[6]	CGH			CCL with atypia	L	40%	4/10
	Stacher[26]	aCGH			CCL with atypia	L	70%	7/10
	Go[25]	FISH		16q12.3-13	CCL with atypia	Heteroz del	20%	2/10
	Go[25]	FISH		16q22.1	CCL with atypia	Heteroz del	10%	1/10
	Go[25]	FISH		16q23.2	CCL with atypia	Heteroz del	10%	1/10

(a)CGH, (array) comparative genomic hybridization; CCL, columnar cell lesion; FISH, fluorescent in situ hybridization; LOH, loss of heterozygosity

first study investigating copy number changes of multiple genes on chromosome 16q (and 16p) in a relatively large group of columnar cell lesions with and without atypia, as well as related lesions. In addition, this is the first study describing the presence of whole-arm losses of 16q in columnar cell lesions.

Methods

Patient material

From formalin-fixed, paraffin-embedded breast resection specimens, tissue samples with columnar cell-like lesions (usual ductal hyperplasia and blunt duct adenosis), columnar cell lesions (with or without atypia) and atypical ductal hyperplasia (consisting of columnar cells with apical snouts and complex architecture, so probably originating form a columnar cell lesion) were collected between 1996 and 2013 at the Departments of Pathology of the University Medical Center, Utrecht, and St. Antonius Hospital Nieuwegein, The Netherlands. Vacuum biopsies and core needle biopsies were excluded. If present and available for DNA analysis, co-existing lesions such as lobular neoplasia, ductal carcinoma in situ and invasive carcinoma were also included. All ductal carcinoma in situ and invasive carcinoma subgroups (ductal carcinoma in situ/invasive ductal carcinoma grades 1, 2 and 3, tubular carcinomas and invasive lobular carcinoma non-pleomorphic type) were supplemented to groups of at least 10 cases each.

The columnar cell lesions were graded according to the classification described by Schnitt and Vincent-Salomon [3] as columnar cell lesions without atypia and columnar cell lesions with atypia. Classification and grading of the invasive carcinoma [29, 30], ductal carcinoma in situ [31], atypical ductal hyperplasia [32], usual ductal hyperplasia [33] and lobular neoplasia [34] was assessed by two experienced observers (PvD and MdB), according to the World Health Organization classification. For differentiation between lobular neoplasia and atypical ductal hyperplasia, e-cadherin immunohistochemical staining was used. Blunt duct adenosis was classified according to descriptions of Lerwill [35] and Brogi [36], and our own experience.

A total of 165 lesions from 103 patients were included (Table 2). Pure lesions were defined as either columnar cell lesions, columnar cell-like lesions (usual ductal hyperplasia and blunt duct adenosis) or atypical ductal hyperplasia, not associated with ductal carcinoma in situ or invasive carcinoma in the same resection specimen or in the prior biopsy. Furthermore, 28 independent cases of normal breast formalin-

fixed, paraffin-embedded tissue obtained from breast reductions specimen or autopsies were taken along as control and were tested to set reference values for copy number gains and losses.

Anonymous use of leftover tissue for research purposes is part of the standard treatment agreement with patients in our hospitals [37]. Pathological reports were used to retrieve information on age and coexistence of malignancy.

DNA extraction and multiplex ligation-dependent probe amplification analysis

For detailed technical description of DNA extraction, PCR analysis and multiplex ligation-dependent probe amplification (MLPA) analysis, see supplementary methods. The P451-A1 probemix (MRC-Holland) was designed to contain 6 probes on the 16p arm and 28 probes on the 16q arm. The target genes for the MLPA probes were chosen using the information provided in the Atlas of Genetics and Cytogenetics in Oncology and Haematology (http://atlasgeneticsoncology.org/). Only genes on chromosome 16 associated with cancer or possibly implicated in cancer were chosen to be included. Probe coverage on chromosome 16 was designed to have an even distribution of probes along the chromosomal arm with an average of 7.2 MB for the p-arm and 1.6 MB for the q-arm (highest distance 7.4 MB for the p-arm and 7.3 MB for the q-arm).

Also, 16 reference probes were included. See Fig. 1 and Supplementary Table 1 for detailed description of the probe locations.

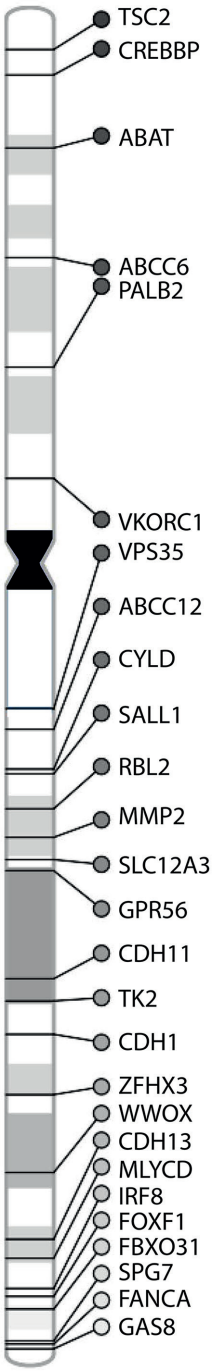

Fig. 1 Distribution of multiplex ligation-dependent probe amplification probes across chromosome 16. Legend: this figure was generated with the help of http://visualization.ritchielab.psu.edu/phenograms/plot#

Table 2. Overview of breast lesions studied for chromosome 16 changes

Samples	Type of lesion	Lesions (number)	Mean Age (year) [range]
All Lesions	BDA	10	57.5 [45-75]
	UDH	13	56.3 [34-76]
	CCL without atypia	12	57.8 [48-72]
	CCL with atypia	11	50.3 [41-67]
	ADH	19	52.8 [37-84]
	DCIS grade 1	14	51.9 [37-82]
	DCIS grade 2	11	54.0 [32-68]
	DCIS grade 3	10	58.0 [34-80]
	LN	11	56.1 [43-71]
	IDC grade 1	12	58.8 [45-73]
	Tubular carcinoma	11	54.2 [36-71]
	IDC grade 2	11	54.6 [34-74]
	IDC grade 3	10	51.4 [32-65]
	ILC	10	59.5 [60-72]
Pure lesions	BDA	2	48.0 [47-49]
	UDH	5	53.6 [34-76]
	CCL without atypia	4	54.3 [48-69]
	CCL with atypia	5	48.6 [44-51]
	ADH	11	53.3 [39-84]

ADH, atypical ductal hyperplasia; BDA, blunt duct adenosis; CCL, columnar cell lesion; DCIS, ductal carcinoma in situ; IDC, invasive ductal carcinoma; ILC, invasive lobular carcinoma; LN, lobular neoplasia; UDH, usual ductal hyperplasia; Pure lesions, lesions not associated with ductal carcinoma in situ or invasive carcinoma in the same breast.

All samples were tested in duplicate, except for three samples, because of a shortage of DNA. Cutoff values for gains and losses per probe were defined by the mean copy number ratios of 58 MLPA tests of 28 independent cases of normal breast tissue ± 2 SD. All values below the lowest cut-off value were defined as losses, and those above the highest cut-off value were defined as gains. The stated cut-off values are listed in Supplementary Table 2. Three probes (CDH1 Exon 1, FOXF1 Exon 2, SPG7 Exon 3) were excluded from further analysis due to high SDs (> 0.13) in normal breast tissue.

Whole-arm loss was defined, as described before, as copy number loss of > 75% of all tested genes of one chromosomal arm [38, 39]. Whole-arm gain was defined as gain of > 75% of all tested genes of one chromosomal arm.

Statistical analysis

Statistical calculations were performed using IBM SPSS for Windows version 20.0. Mann–Whitney test was used to compare copy number ratios of each individual gene between different lesions. Unsupervised hierarchical clustering was performed using the statistical programme R (http://www.r-project.org), version 3.0.1, packages: gplots, pvclust and snow. We used Euclidean distance and Spearman's correlation together with Ward's clustering method.

Results

Overall results

The overall results are summarized in Table 3. The most commonly lost probes differed per lesion and no smallest region of overlap was found for the low-nuclear-grade breast neoplasia family.

Usual ductal hyperplasia

In usual ductal hyperplasia lesions, the average percentage of copy number changes was 18%. Losses on 16q were found in 11/13 lesions (85%), with a maximum of 6 probes (Fig. 2). Nine lesions showed both gains and losses. Losses were only found in small clusters (with a maximum of three uninterrupted MLPA probe lost), separated by probes without copy number changes or single probes with gains. Gains on 16p were found in 7/13 lesions (54%). There were no whole-arm changes.

Blunt duct adenosis

In blunt duct adenosis lesions, the average percentage of copy number changes was 19%. Losses on 16q were found in 10/10 lesions (100%), with a maximum of 8 probes per lesion (Fig. 2). Six lesions showed both gains and losses. The losses were only found in small clusters (with a maximum of three probes), separated by probes without copy number changes or single probes with gains. Gains on 16p were found in 6/10 lesions (60%). There were no whole-arm changes.

Columnar cell lesions without atypia

In columnar cell lesions without atypia the average per-centage of copy number changes was 27%. Losses on 16q were found in 12/12 lesions (100%) (Fig. 3). CDH1 exon 11 was most commonly lost (7/12 = 58%). Two out of 12 lesions (17%) fulfilled the criteria for whole-arm loss of 16q. Six lesions showed both gains and losses. Gains on 16p were found in 8 out of 12 lesions (67%) but none of these lesions fulfilled the criteria for whole-arm gain of 16p.

Table 3. Overview results

Lesion (n)		average copy number changes chromosome 16	16q losses (n)		Combination of gains and losses on 16q (n)		whole arm 16q loss (n)		gains on 16p (n)		whole arm 16p gain (n)		Probe(s) most commonly lost	frequency (n)	
UDH	(13)	18%	85%	(11)	69%	(9)	0%	(0)	54%	(7)	0%	(0)	MLYCD exon 2	38%	(5)
BDA	(10)	19%	100%	(10)	60%	(6)	0%	(0)	80%	(8)	0%	(0)	SPG7	50%	(5)
CCL-	(12)	27%	100%	(12)	50%	(6)	17%	(2)	67%	(8)	0%	(0)	CDH1 exon 11	58%	(7)
CCL+	(11)	40%	100%	(11)	36%	(4)	27%	(3)	55%	(6)	9%	(1)	SLC12A3	91%	(10)
ADH	(19)	44%	95%	(18)	26%	(5)	47%	(9)	58%	(11)	0%	(0)	CDH11 exon 3 CDH1 exon 11	74%	(14)
DCIS1	(14)	56%	86%	(12)	7%	(1)	57%	(8)	64%	(9)	7%	(1)	CDH1 exon 11 MLYCD exon 2 FBXO31	79%	(11)
DCIS2	(11)	47%	73%	(8)	27%	(3)	27%	(3)	82%	(9)	9%	(1)	CDH1 exon 11	73%	(8)
DCIS3	(10)	49%	90%	(9)	60%	(6)	10%	(1)	80%	(8)	0%	(0)	FANCA exon 20	80%	(8)
TubCa	(11)	64%	91%	(10)	9%	(1)	55%	(6)	73%	(8)	27%	(3)	CYLD MMP2 CDH11 exon 3 FANCA exon 20	91%	(10)
IDC1	(12)	65%	92%	(11)	17%	(2)	42%	(5)	92%	(11)	25%	(3)	CYLD	83%	(10)
IDC2	(11)	58%	91%	(10)	27%	(3)	36%	(4)	82%	(9)	27%	(3)	CYLD WWOX exon 10 FANCA exon 20	73%	(8)
IDC3	(10)	63%	80%	(8)	50%	(5)	30%	(3)	90%	(9)	20%	(2)	CDH11 exon 8&3 ZFHX3 MLYCD exon 3	70%	(7)
LN	(11)	53%	91%	(10)	9%	(1)	45%	(5)	55%	(6)	0%	(0)	SLC12A3	82%	(9)

Table 3. Continued

Lesion (n)	average copy number changes chromosome 16	16q losses (n)	Combination of gains and losses on 16q (n)	whole arm 16q loss (n)	gains on 16p (n)	whole arm 16p gain (n)	Probe(s) most commonly lost	frequency (n)
ILC (10)	73%	100% (10)	0% (0)	80% (8)	60% (6)	10% (1)	MMP2 SLC12A3 CDH1 exons 11& 14 WWOX exon 10 MLYCD exon 2 FANCA exon 20	90% (9)

ADH, atypical ductal hyperplasia; BDA, blunt duct adenosis; CCL–, columnar cell lesion without atypia; CCL+, columnar cell lesion with atypia; DCIS, ductal carcinoma in situ; IDC, invasive ductal carcinoma; ILC, invasive lobular carcinoma; LN, lobular neoplasia; TubCa, tubular carcinoma; UDH, usual ductal hyperplasia.



Fig. 2 Gains and losses by multiplex ligation-dependent probe amplification in genes on chromosome 16 in usual ductal hyperplasia and blunt duct adenosis lesions. BDA, blunt duct adenosis; N, no; UDH, usual ductal hyperplasia; Y, yes



Fig. 3 Gains and losses by multiplex ligation-dependent probe amplification in genes on chromosome 16 in columnar cell lesions without atypia, columnar cell lesions with atypia and atypical ductal hyperplasia. ADH, atypical ductal hyperplasia; CCL, columnar cell lesion; N, no; Y, yes

Columnar cell lesions with atypia

In columnar cell lesions with atypia, the average percentage of copy number changes was 40%. Losses on 16q were found in 11/11 lesions (100%) (Fig. 3). SLC12A3 was most commonly lost (10/11 = 91%).Three out of 11 lesions (27%) fulfilled the criteria for whole-arm loss of 16q. In four lesions there were both gains and losses. Gains on

16p were found in 6/11 lesions (55%) and one of these lesions fulfilled the criteria for whole-arm gain of 16p.

Atypical ductal hyperplasia

In atypical ductal hyperplasia lesions, the average percentage of copy number changes was 44%. Losses on 16q were found in 18/19 lesions (95%) (Fig. 3). CDH11 exon 3 and CDH1 exon 11 were most commonly lost (14/19 = 74%). Nine out of 19 lesions (47%) fulfilled the criteria for whole-arm loss of 16q. In five lesions, there were both gains and losses. In one case, gain of the first two tested genes on 16q adjacent to the centromere Gains on 16p were found in 6/11 lesions (55%) and one of these lesions fulfilled the criteria for whole-arm gain of 16p.

Atypical ductal hyperplasia

In atypical ductal hyperplasia lesions, the average percentage of copy number changes was 44%. Losses on 16q were found in 18/19 lesions (95%) (Fig. 3). CDH11 exon 3 and CDH1 exon 11 were most commonly lost (14/19 = 74%). Nine out of 19 lesions (47%) fulfilled the criteria for whole-arm loss of 16q. In five lesions, there were both gains and losses. In one case, gain of the first two tested genes on 16q adjacent to the centromere

Ductal carcinoma in situ grade 1

In ductal carcinoma in situ grade 1, the average percentage of copy number changes was 56%. Losses on 16q were found in 12/14 lesions (86%) (Fig. 4). CDH1 exon 11, MLYCD exon 2 and FBXO31 were most commonly lost losses. Gains on 16p were found in 9/14 lesions (64%) and 1 of these lesions fulfilled the criteria for whole-arm gain of 16p.

Ductal carcinoma in situ grade 2

In ductal carcinoma in situ grade 2, the average percentage of copy number changes was 47%. Losses on 16q were found in 8/11 lesions (73%) (Fig. 4). CDH1 exon 11 was most commonly lost (8/11 = 73%). Three out of 11 lesions (27%) fulfilled the criteria for whole-arm loss of 16q. In three lesions there were both gains and losses. Gains on 16p were found in 9/11 lesions (82%) and 1 of these lesions fulfilled the criteria for whole-arm gain of 16p.

Ductal carcinoma in situ grade 3

In ductal carcinoma in situ grade 3, the average percentage of copy number changes was 49%. Losses on 16q were found in 9/10 lesions (90%) (Fig. 4). FANCA exon 20 was most commonly lost (8/10 = 80%). One out of 10 lesions (10%) fulfilled the criteria for whole-arm loss of 16q. In six lesions there were both gains and losses. In one case

gain of the first two tested genes on 16q adjacent to the centromere was associated with losses of other investigated genes on 16q. Gains on 16p were found in 8/10 lesions (80%) but none of these lesions fulfilled the criteria for whole-arm gain of 16p.

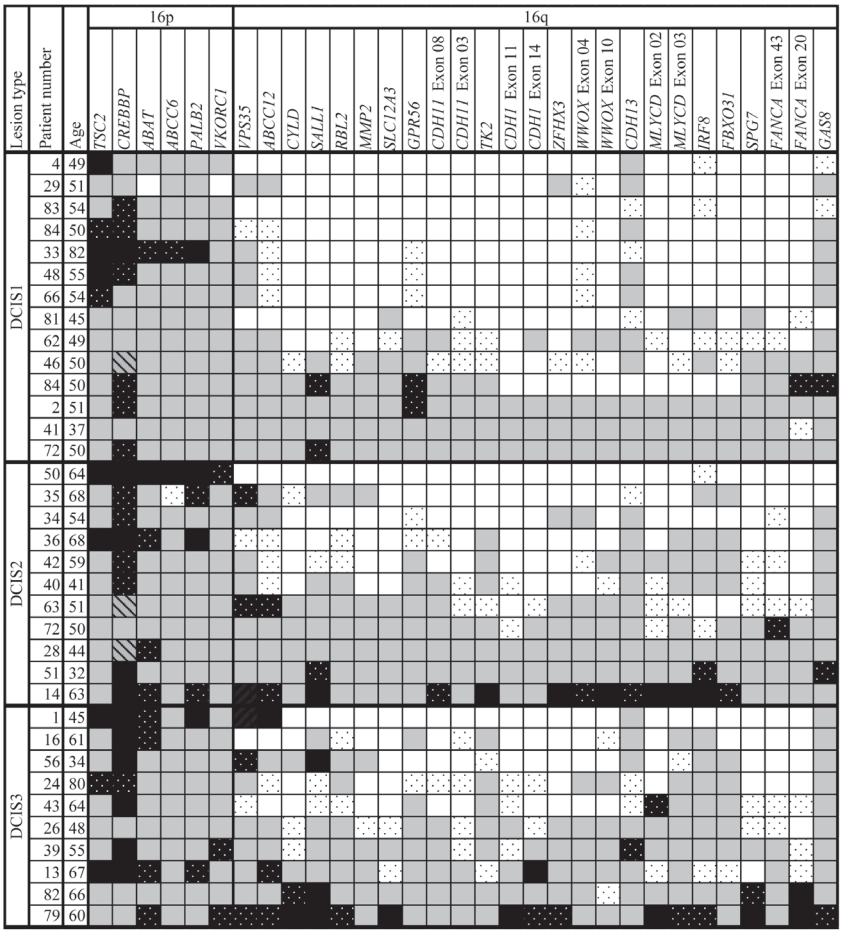

Fig. 4 Gains and losses by multiplex ligation-dependent probe amplification in genes on chromosome 16 in ductal carcinoma in situ lesions. DCIS, ductal carcinoma in situ

Invasive ductal carcinoma grade 1 and tubular carcinoma

Two types of low-grade invasive ductal carcinomas were included: tubular carcinomas and invasive ductal carcinoma grade 1. In invasive ductal carcinoma grade 1, the average percentage of copy number changes was 65% (Fig. 5). Losses on 16q were found in 11/12 lesions (92%). CYLD was most commonly lost (10/12 = 83 %). Five out of 12 lesions (42%) fulfilled the criteria for whole-arm loss of 16q. In two lesions there were both gains and losses. In one case gain of the first two tested genes on 16q adjacent to the centromere was associated with losses of other investigated genes on 16q. Gains on 16p were found in 11/12 lesions (92%) and three of these lesions fulfilled the criteria for whole-arm gain of 16p.



Fig. 5 Gains and losses by multiplex ligation-dependent probe amplification in genes on chromosome 16 in tubular carcinomas and grade 1 invasive ductal carcinomas. IDC, invasive ductal carcinoma; TubCa, tubular carcinoma

In tubular carcinomas, the average percentage of copy number changes was 64% (Fig. 5). Losses on 16q were found in 10 lesions (10/11 = 91%). CYLD, MMP2, CDH11 exon 3 and FANCA exon 20 were most commonly lost (10/ 11 = 91 %). Six out of 11

lesions (55%) fulfilled the criteria for whole-arm loss of 16q. In one lesion there were both gains and losses. Gains on 16p were found in 8/11 lesions (73%) and 3 of these lesions fulfilled the criteria for whole-arm gain of 16p.

Invasive ductal carcinoma grade 2

In invasive ductal carcinoma grade 2, the average percentage of copy number changes was 58% (Fig. 6). Losses on 16q were found in 10/11 lesions (91%). CYLD, WWOX exon 10 and FANCA exon 20 were most commonly lost (8/ 11 = 73%). Four out of 11 lesions (36%) fulfilled the criteria for whole-arm loss of 16q. In three lesions there were both gains and losses. Gains on 16p were found in 9/11 lesions (82%) and 3 of these lesions fulfilled the criteria for whole-arm gain of 16p.



Fig. 6 Gains and losses by multiplex ligation-dependent probe amplification in genes on chromosome 16 in invasive ductal carcinomas grade 2 or 3. IDC, invasive ductal carcinoma

Invasive ductal carcinoma grade 3

In invasive ductal carcinoma grade 3, the average percentage of copy number changes was 63% (Fig. 6). Losses on 16q were found in 8/10 lesions (80%). CDH11 exon 8 and 3, ZFHX3 and MLYCD exon 3 were most commonly lost. Three out of 10 lesions (30%) fulfilled the criteria for whole-arm loss of 16q. In five lesions there were both gains and losses. In one lesion there was polysomy of whole chromosome 16. Gains on 16p were found in 9/10 lesions (90 %) and 2 of these lesions fulfilled the criteria for whole-arm gain of 16p.

Lobular neoplasia and invasive lobular carcinoma

In lobular neoplasia, the average percentage of copy number changes was 53% (Fig. 7). Losses on 16q were found in 10/ 11 lesions (91%). SLC12A3 was most commonly lost (9/11 = 82 %), closely followed by MMP2, CDH11 exon 3, CDH1 exon 11, MYCD exon 2, SPG7 and FANCA exons 43 and 20 (8/11 = 73%). Five out of 11 lesions (45%) fulfilled the criteria for whole-arm loss of 16q. In one lesion there were both gains and losses. Gains on 16p were found in 6/11 lesions (55%) but none of these lesions fulfilled the criteria for whole-arm gain of 16p.



Fig. 7 Gains and losses by multiplex ligation-dependent probe amplification in genes on chromosome 16 in invasive lobular carcinomas and lobular neoplasia. ILC, invasive lobular carcinoma; LN, lobular neoplasia

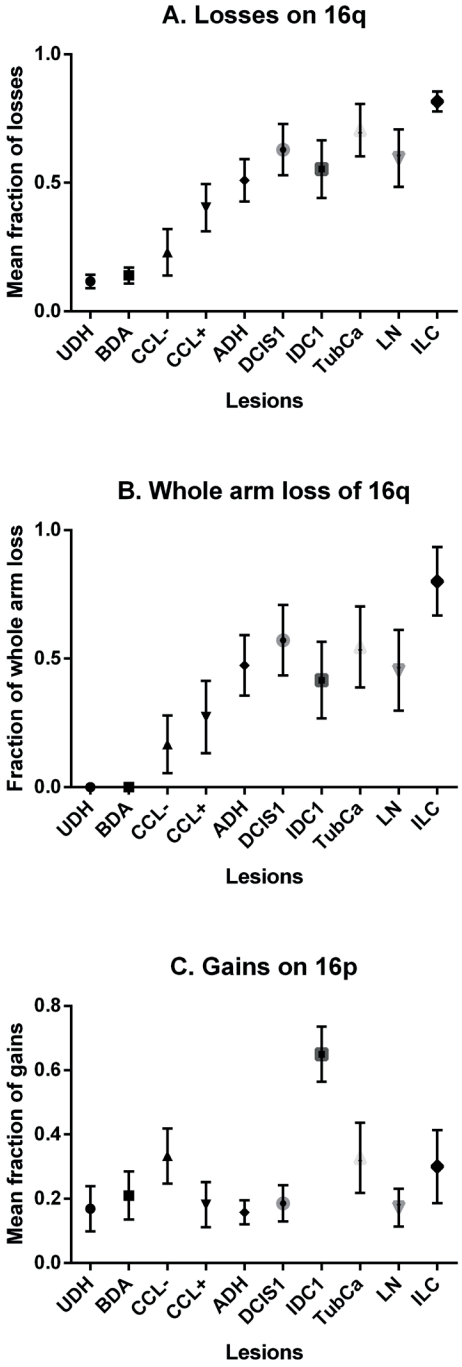

In invasive lobular carcinoma, the average percentage of copy number changes was 73% (Fig. 7). Losses on 16q were found in 10/10 lesions (100%). MMP2, SLC12A3, CDH1 exons 11 and 14, WWOX exon 10, MLYCD exon 2 and FANCA exon 20 were most commonly lost. Eight out of 10 lesions (80%) fulfilled the criteria for whole-arm loss of 16q. There were no lesions with both gains and losses on 16q. Gains on 16p were found in 6/10 lesions (60%) and 1 of these lesions fulfilled the criteria for whole-arm gain of 16p.

Comparison of 16q losses between lesion categories

The percentages of 16q losses over the spectrum usual ductal hyperplasia, blunt duct adenosis, columnar cell lesion without atypia, columnar cell lesion with atypia, atypical ductal hyperplasia and ductal carcinoma in situ grade 1 gradually increased as shown in Fig. 8a. In ductal carcinoma in situ grade 1, invasive ductal carcinoma grade 1, tubular carcinoma and lobular neoplasia the percentages of losses were similar. Invasive lobular carcinoma had the highest percentage of loss on 16q.

Fig. 8 Trends in copy number changes in low-grade breast carcino-genetic spectrum. a Increasing frequency of 16q losses over the low-grade breast carcinogenetic spectrum. b Increasing frequency of 16q whole-arm loss over the low-grade breast carcinogenetic spectrum. c No trend of increasing 16p gains over the low-grade breast carcinogenetic spectrum. ADH, atypical ductal hyperplasia; BDA, blunt duct adenosis; CCL–, columnar cell lesion without atypia; CCL+, columnar cell lesion with atypia; DCIS, ductal carcinoma in situ; IDC, invasive ductal carcinoma; ILC, invasive lobular carcinoma; LN, lobular neoplasia; TubCa, tubular carcinoma; UDH, usual ductal hyperplasia

Although whole-arm losses were not found in usual ductal hyperplasia and blunt duct adenosis lesions, there was an increase in whole-arm losses of 16q from columnar cell lesion without atypia, to columnar cell lesion with atypia and atypical ductal hyperplasia (Fig. 8b). In atypical ductal hyperplasia, ductal carcinoma in situ grade 1, invasive ductal carcinoma grade 1 and tubular carcinoma the percentages of 16q whole-arm losses were similar, ranging from 42% to 57%. The highest percentage of whole-arm losses was found in invasive lobular carcinoma (80%).

Lesions not fulfilling whole-arm loss

In benign lesions (usual ductal hyperplasia and blunt duct adenosis), losses were only found in small clusters (with a maximum of three uninterrupted MLPA probe lost), separated by probes without copy number changes or single probes with gains. A maximum losses of eight probes per lesion (in blunt duct adenosis) was found. In 34 other lesions, the number of losses was between 9 and 18, thereby having more losses compared with the benign lesions, but not fulfilling the criteria for whole-arm loss. These cases included three columnar cell lesions with atypia, three atypical ductal hyperplasia lesions, three ductal carcinoma in situ grade 1 lesions, four tubular carcinomas, two invasive ductal carcinomas grade 1, three lobular neoplasias and two invasive lobular carcinomas. In almost all of these cases, losses were spread across the whole-arm, interspersed with small areas without copy number changes. In one ductal carcinoma in situ grade 1, there was loss of a contiguous region between CDH1 exon 11 and FBXO31, suggestive for partial arm loss.

Breakpoints on 16q

In 65% of cases with whole-arm losses, the breakpoint seemed to be around the centromere (between VKORC1 and VPS35), and in 18% between ABCC12 and CYLD. In three cases (atypical ductal hyperplasia, invasive ductal carcinoma grade 1 and ductal carcinoma in situ grade 3) with this breakpoint, there was gain of VPS35 and ABCC12.

Comparison of 16p gains between lesion categories

In contrast to 16q losses, there was no increase in percentage of 16p gains or 16p whole-arm gains in the low-grade carcinogenesis sequence from columnar cell lesions to atypical ductal hyperplasia, low-grade ductal carcinoma in situ and low-grade invasive carcinoma (Fig. 8c). In total, there were 16 cases with whole-arm gain of 16p, of which 11 were associated with whole-arm loss of 16q (69%).

Pure lesions and lesions associated with neoplasia

There was a nonsignificant difference between the mean copy number ratios of all pure and neoplasia associated lesions (measured in the whole group of usual ductal

hyperplasia, blunt duct adenosis, columnar cell lesion without atypia, columnar cell lesion with atypia and atypical ductal hyperplasia). Also, the mean copy number ratios of columnar cell lesions with atypia and atypical ductal hyperplasia lesions were similar between the pure group and the neoplasia associated group. Clustering with Euclidian distance and Spearman's correlation did not yield clusters of pure and malignancy-associated lesions.

Comparison of different lesions within the same patient

We tested eight columnar cell lesions without atypia, associated with (pre)malignant lesions in the same breast (Fig. 9). In two cases (patient 27 and patient 87), the columnar cell lesion without atypia revealed whole-arm loss. In these cases the copy number pattern was similar in the (pre)malignant lesions from the same breast (tubular carcinoma and lobular neoplasia, respectively), although both just did not fulfil the criteria for whole-arm loss. In two other cases (patients 34 and 44) there were fewer losses in the columnar cell lesion, but the losses in the columnar cell lesion were also found in the related (pre)malignant lesions (ductal carcinoma in situ grade 2, invasive ductal carcinoma grade 2 and invasive lobular carcinoma, respectively). In three cases (patients 39, 63 and 54) the columnar cell lesion had a very low rate of copy number changes with no striking similarities between these changes and the copy number changes of the associated (pre)malignant lesions.

Further, copy number changes were compared between eight cases of columnar cell lesion with atypia associated with other (pre)malignant lesions in the same breast (Fig. 10). In all three atypical columnar cell lesion cases with whole-arm loss (patients 4, 32 and 76), there was also whole-arm loss in the associated (pre)malignant lesion (ductal carcinoma in situ grade 1, atypical ductal hyperplasia and tubular carcinoma, respectively). On the other hand, in patient 4 the tubular carcinoma did not show whole-arm loss and was probably not related to the associated columnar cell lesion and ductal carcinoma in situ grade 1. In one other case (patient 77) there were fewer losses in the columnar cell lesion, but the losses corresponded to the associated atypical ductal hyperplasia. Patient 79 had a columnar cell lesion with a few gains on 16q. The associated ductal carcinoma in situ grade 3 had corresponding and additional gains. Patient 45 had a columnar cell lesion and invasive ductal carcinoma grade 2, both with whole-arm 16p gain. In two cases (patients 13 and 84), only some of the copy number changes present in the columnar cell lesion were also found back in concomitant (pre)malignant lesions.

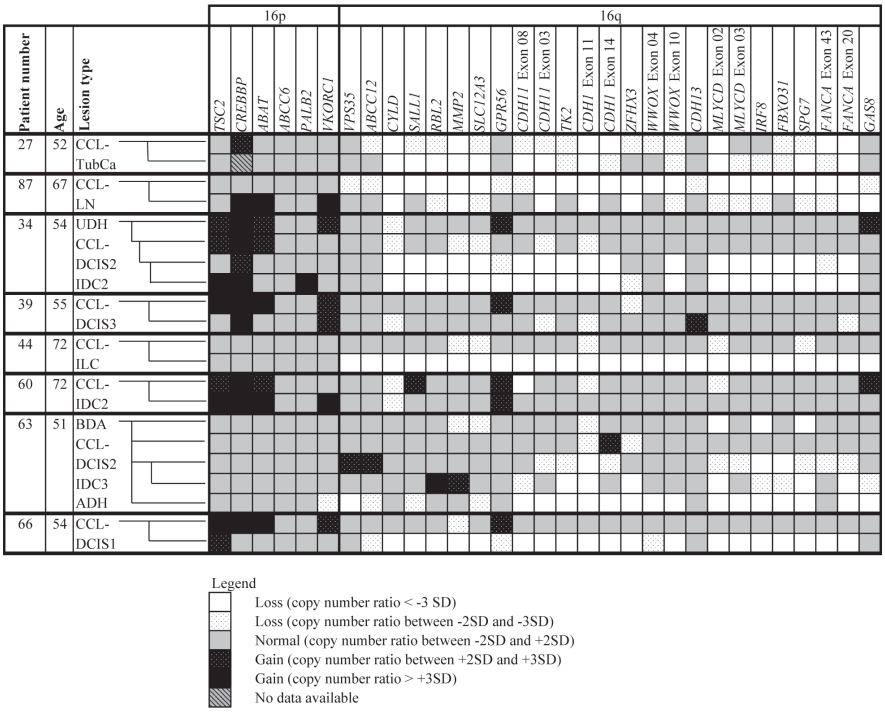

Fig. 9 Comparison of columnar cell lesions without atypia and concomitant (pre)neoplastic lesions within the same breast. Comparison of 16p and 16q copy number changes by multiplex ligation-dependent probe amplification in columnar cell lesions without atypia and concomitant (pre)neoplastic lesions within the same breast, showing many similarities. ADH, atypical ductal hyperplasia; BDA, blunt duct adenosis; CCL–, columnar cell lesion without atypia; DCIS, ductal carcinoma in situ; IDC, invasive ductal carcinoma; ILC, invasive lobular carcinoma; LN, lobular neoplasia; TubCa, tubular carcinoma; UDH, usual ductal hyperplasia

Next, seven cases of atypical ductal hyperplasia with concomitant other (pre) malignant lesions in the same breast were analysed (Fig. 11). One out of three atypical ductal hyperplasia lesions with 16q whole-arm loss (patient 57) was associated with invasive ductal carcinoma grade 3 with 16q whole-arm loss. Patient 9 had atypical ductal hyperplasia with 16q whole-arm loss and invasive lobular carcinoma with extensive 16q loss but not fulfilling the criteria for whole-arm loss. Patient 63 had atypical ductal hyperplasia with whole-arm loss, but ductal carcinoma in situ grade 2 and invasive ductal carcinoma grade 3 with losses only at the distal part of 16q. Patient 62 had both atypical ductal hyperplasia and ductal carcinoma in situ grade 1. The atypical ductal hyperplasia revealed fewer losses on 16q but all losses were also found in the ductal carcinoma in situ lesion. In patient 67 the copy number changes (both gains and losses) of atypical ductal hyperplasia only partly corresponded to the copy number changes of the concomitant invasive lobular carcinoma. Lastly, there

were no similarities between atypical ductal hyperplasia and ductal carcinoma in situ lesions (grade 1 and grade 3) in two patients (patients 41 and 82).



Fig. 10 Comparison of columnar cell lesions with atypia and concomitant (pre)neoplastic lesions within the same breast. Comparison of 16p and 16q copy number changes by multiplex ligation-dependent probe amplification in columnar cell lesions with atypia and concomitant (pre)neoplastic lesions within the same breast, showing many similarities. ADH, atypical ductal hyperplasia; BDA, blunt duct adenosis; CCL+, columnar cell lesion with atypia; DCIS, ductal carcinoma in situ; IDC, invasive ductal carcinoma; LN, lobular neoplasia; TubCa, tubular carcinoma; UDH, usual ductal hyperplasia

Discussion

It is now widely accepted that invasive breast cancer progresses from early, non-cancerous breast lesions in multiple, parallel pathways [4, 40], and columnar cell lesions seem to represent the earliest morphologically recognizable precursor lesion of the low nuclear grade breast neoplasia family.

This study investigated chromosome 16 copy number alterations in columnar cell lesions, atypical ductal hyperplasia and associated lesions of the breast by MLPA, circumventing whole-genome-amplification protocols, in order to minimize

technical artefacts. The underlying aim was to support the precursor role of columnar cell lesions in low-nuclear-grade breast carcinogenesis, and to clarify the role of columnar cell lesions without atypia, blunt duct adenosis and usual ductal hyperplasia in breast carcinogenesis.

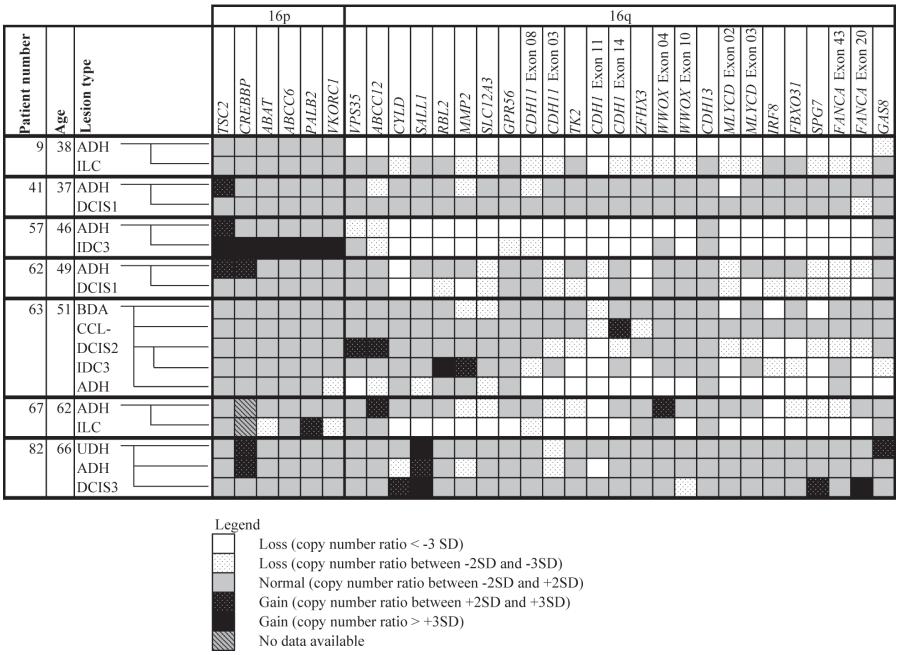

Fig. 11 Comparison of atypical ductal hyperplasia and concomitant (pre)neoplastic lesions within the same breast. Comparison of 16p and 16q copy number changes by multiplex ligation-dependent probe amplification in atypical ductal hyperplasia and concomitant (pre) neoplastic lesions within the same breast, showing many similarities. ADH, atypical ductal hyperplasia; BDA, blunt duct adenosis; CCL–, columnar cell lesion without atypia; DCIS, ductal carcinoma in situ; IDC, invasive ductal carcinoma; ILC, invasive lobular carcinoma; UDH, usual ductal hyperplasia

MLPA is an easy and fast method to identify copy number changes of multiple genes, even in fragmented DNA, by a single PCR-based reaction [41]. The concordance between MLPA and other molecular techniques such as array-comparative genomic hybridization and fluorescent in situ hybridization has been confirmed in the past [42, 43]. Nevertheless, this study has its limitations and assumptions. One of the issues we faced during this study was the relatively low DNA content of the smaller lesions and lesions with prominent stroma, such as columnar cell lesion, lobular neoplasia and blunt duct adenosis. In these cases we could have missed gains and losses because of the admixture of normal DNA.

We defined whole-arm loss as > 75% loss of the residing genes/probes. This is a generally accepted cut-off value, which has been used previously in array-comparative genomic hybridization [39] and MLPA [38] experiments. The retained presence of some probes (< 25%) could be explained by the normalization process. Normalization was done in a probe-specific manner and the cut-off values for loss and gain were determined per probe, based on the MLPA ratio variation in normal breast tissue (see Supplementary Table 2). Together with the varying relative DNA content, this could also explain the subtle differences between related lesions.

The frequencies of 16q whole-arm losses detected with MLPA in invasive lobular carcinoma and invasive ductal carcinoma grade 1 were similar to previous array-comparative genomic hybridization results [12, 44], corroborating our MLPA approach. None of our tested usual ductal hyperplasia and blunt duct adenosis lesions showed whole-arm losses of 16q. This confirms that, although some authors considered blunt duct adenosis to be a synonym of columnar cell lesion (without atypia) [45–47] or a growth pattern of columnar cell lesions [48], this lesion seems to be a separate entity and no precursor lesions of low-grade breast neoplasia. And this underlines the importance of morphologically discriminating blunt duct adenosis from columnar cell lesion.

Seventeen percent of the columnar cell lesions without atypia and 27% of columnar cell lesions with atypia showed whole-arm loss of chromosome 16q. In addition, three more columnar cell lesions with atypia had more losses compared with the benign columnar cell lesion-like lesions, but just did not fulfil the criteria for whole-arm losses. It is possible, given the small lesion size and abundance of surrounding stroma, that we missed whole-arm loss in these cases, caused by intermixture of normal DNA. Taking these lesions into account, it leads to a total of 54% of columnar cell lesions with atypia with significant losses on 16q. This result is in line with previously obtained results (40–70%loss) by (array) comparative genomic hybridization (see Table 1)[6, 26].

These frequent whole-arm losses in columnar cell lesions with and without atypia, and the coexistence of columnar cell lesion with more advanced (pre)malignant lesions with similar losses, support a precursor role of columnar cell lesions in low-grade breast neoplasia. There were only sporadic cases in which the number of lost probes was lower in the more advanced lesion compared to the columnar cell lesion. For example, in case 87, the lower number of losses in the lobular neoplasia could be explained by the small size of the lesion and admixture of normal DNA. Although whole-arm loss could not be demonstrated in this lobular neoplasia, given the distribution of the lost probes, it is plausible we missed whole-arm loss in this case.

Further, there was no influence of concomitant neoplasia on the presence of copy number changes on chromosome 16q, implying that these losses are true carcinogenetic events and not just the result of field effects.

As expected and known from the literature our study did not find a smallest region of overlap or a hint towards the existence of specific tumour suppressor genes on 16q. Although, we found evidence for a breakpoint near the centromere, not previously described. In 65% of cases with whole-arm losses, the breakpoint was between VKORC1 and VPS35, and in 18% between ABCC12 and CYLD. In three cases (atypical ductal hyperplasia, invasive ductal carcinoma grade 1 and ductal carcinoma in situ grade 3) with this breakpoint, there was gain of VPS35 and ABCC12, making it unlikely that losses of ABCC12 and VPS35 have a major role in low-grade breast carcinogenesis.

Gains of single probes on chromosome 16p were frequently seen but whole-arm gains were relatively rare. In addition, there was no relation between whole-arm gains on 16p and progression in the low-grade breast neoplasia family. Previously, higher frequencies of 16p gains were described in tubular carcinoma and invasive lobular carcinoma (39% and 42–54%, respectively) [13, 44, 49, 50]. These differences can be explained by the fact we only included whole-arm gains and no partial arm gains and by the use of different (less specific) techniques before. Overall, our results implicate that 16p does not have a major role in early low-grade breast carcinogenesis.

In cases with significant losses, not fulfilling the definition of whole-arm loss, the losses appeared to be spread fairly randomly across the whole 16q arm. Clear segmental loss in low-grade breast neoplasia was only found once in a ductal carcinoma in situ grade 1. Thereby, no smallest regions of overlap were found, and no driver genes could be identified. This is in line with previous studies [8, 51, 52]. Therefore, the carcinogenetic effect of 16q might be due to a multitude of mechanisms. Haploinsufficiency of genes residing on chromosome 16q has been shown to be of interest in the early steps of breast carcinogenesis [39]. However, the interpretation of these results is complicated by the finding that the copy number status of genes on 16q is not necessarily reflected on the protein expression level [53]. This is further sustained by findings of Rakha et al. [54] and Cleton-Jansen et al. [55] focussing on CTCF and NQO1. Noteworthy and in line with these findings, our study supports this missing effect. Of the atypical ductal hyperplasia cases with whole-arm 16q losses, including the E-Cadherin locus, a normal membranous E-Cadherin expression could be observed in all investigated cases.

Also in invasive breast cancer, the loss of 16q has repeatedly been shown to be associated with the gain of 1q [56] with a clear impact on the mRNA expression levels of the respective genes [39]. The interplay of these genes is completely unknown. A new perspective, complicating the present knowledge, has been added by the association of non-16q-located single-nucleotide polymorphisms associated with chromosomal 16q losses [57]. It therefore seems likely that a multitude of genes located on chromosome 16q, 1q or single-nucleotide polymorphisms associated with these alterations, with unknown interplay, contribute to the evolution of low-grade breast cancer, rather than major events in a few key genes.

In conclusion, columnar cell lesions (with and without atypia) often harbour whole-arm losses of 16q, which emphasizes their role as precursors in low-grade breast carcinogenesis, in contrast with usual ductal hyperplasia and blunt duct adenosis. However, no recurrent losses in specific genes could be identified, pointing to minor events in multiple tumour suppressor genes rather than major events in a single 16q gene contributing to low-grade breast carcinogenesis.

Compliance with ethical standards

Conflict of interest M Steenkamer and S Savola are employed by MRC-Holland, manufacturer of commercially available multiplex ligation-dependent probe amplification probe mixes. All other authors declare that they have no conflict of interest.

References

1. Fraser JL, Raza S, Chorny K, et al. Columnar alteration with prominent apical snouts and secretions: a spectrum of changes frequently present in breast biopsies performed for microcalcifications. Am J Surg Pathol. 1998;22:1521–7.
2. Schnitt SJ. The diagnosis and management of pre-invasive breast disease: flat epithelial atypia--classification, pathologic features and clinical significance. Breast Cancer Res. 2003;5:263–8.
3. Schnitt SJ, Vincent-Salomon A. Columnar cell lesions of the breast. Adv Anat Pathol. 2003;10:113–24.
4. Abdel-Fatah TM, Powe DG, Hodi Z, et al. Morphologic and molecular evolutionary pathways of low nuclear grade invasive breast cancers and their putative precursor lesions: further evidence to support the concept of low nuclear grade breast neoplasia family. Am J Surg Pathol. 2008;32:513–23.
5. Moinfar F, Man YG, Bratthauer GL, et al. Genetic abnormalities in mammary ductal intraepithelial neoplasia-flat type ("clinging ductal carcinoma in situ"): a simulator of normal mammary epithelium. Cancer. 2000;88:2072–81.
6. Simpson PT, Gale T, Reis-Filho JS, et al. Columnar cell lesions of the breast: the missing link in breast cancer progression? A morphological and molecular analysis. Am J Surg Pathol. 2005;29:734–46.
7. Buerger H, Otterbach F, Simon R, et al. Different genetic path-ways in the evolution of invasive breast cancer are associated with distinct morphological subtypes. J Pathol. 1999;189:521–6.
8. Burger H, de Boer M, van Diest PJ, et al. Chromosome 16q loss--a genetic key to the understanding of breast carcinogenesis. Histol Histopathol. 2013;28:311–20.
9. Loo LW, Ton C, Wang YW, et al. Differential patterns of allelic loss in estrogen receptor-positive infiltrating lobular and ductal breast cancer. Genes Chromosomes Cancer. 2008;47:1049–66.
10. Riener MO, Nikolopoulos E, Herr A, et al. Microarray comparative genomic hybridization analysis of tubular breast carcinoma shows recurrent loss of the CDH13 locus on 16q. Hum Pathol. 2008;39:1621–9.
11. Roylance R, Gorman P, Hanby A, et al. Allelic imbalance analysis of chromosome 16q shows that grade I and grade III invasive ductal breast cancers follow different genetic pathways. J Pathol. 2002;196:32–36.
12. Roylance R, Gorman P, Papior T, et al. A comprehensive study of chromosome 16q in invasive ductal and lobular breast carcinoma using array CGH. Oncogene. 2006;25:6544–53.
13. Waldman FM, Hwang ES, Etzell J, et al. Genomic alterations in tubular breast carcinomas. Hum Pathol. 2001;32:222–6.
14. Buerger H, Otterbach F, Simon R, et al. Comparative genomic hybridization of ductal carcinoma in situ of the breast-evidence of multiple genetic pathways. J Pathol. 1999;187:396–402.
15. Etzell JE, Devries S, Chew K, et al. Loss of chromosome 16q in lobular carcinoma in situ. Hum Pathol. 2001;32:292–6.
16. Gao Y, Niu Y, Wang X, et al. Genetic changes at specific stages of breast cancer progression detected by comparative genomic hybridization. J Mol Med (Berl). 2009;87:145–52.
17. Green AR, Krivinskas S, Young P, et al. Loss of expression of chromosome 16q genes DPEP1 and CTCF in lobular carcinoma in situ of the breast. Breast Cancer Res Treat. 2009;113:59–66.

18. Lakhani SR, Collins N, Stratton MR, et al. Atypical ductal hyperplasia of the breast: clonal proliferation with loss of heterozygosity on chromosomes 16q and 17p. J Clin Pathol. 1995; 48:611–5.
19. Larson PS, de las Morenas A, Cerda SR, et al. Quantitative analysis of allele imbalance supports atypical ductal hyperplasia lesions as direct breast cancer precursors. J Pathol. 2006;209: 307–16.
20. Lu YJ, Osin P, Lakhani SR, et al. Comparative genomic hybridization analysis of lobular carcinoma in situ and atypical lobular hyperplasia and potential roles for gains and losses of genetic material in breast neoplasia. Cancer Res. 1998;58:4721–7.
21. Mastracci TL, Shadeo A, Colby SM, et al. Genomic alterations in lobular neoplasia: a microarray comparative genomic hybridization signature for early neoplastic proliferation in the breast. Genes Chromosomes Cancer. 2006;45:1007–17.
22. Vos CB, ter Haar NT, Rosenberg C, et al. Genetic alterations on chromosome 16 and 17 are important features of ductal carcinoma in situ of the breast and are associated with histologic type. Br J Cancer. 1999;81:1410–8.
23. Aulmann S, Elsawaf Z, Penzel R, et al. Invasive tubular carcinoma of the breast frequently is clonally related to flat epithelial atypia and low-grade ductal carcinoma in situ. Am J Surg Pathol. 2009;33:1646–53.
24. Ellsworth RE, Ellsworth DL, Weyandt JD, et al. Chromosomal alterations in pure nonneoplastic breast lesions: implications for breast cancer progression. Ann Surg Oncol. 2010;17:1688–94.
25. Go EM, Tsang JY, Ni YB, et al. Relationship between columnar cell changes and low-grade carcinoma in situ of the breast--a cytogenetic study. Hum Pathol. 2012;43:1924–31.
26. Stacher E, Boldt V, Leibl S, et al. Chromosomal aberrations as detected by array-comparative genomic hybridization in early low-grade intraepithelial neoplasias of the breast. Histopathology. 2011;59:549–55.
27. Gomes DS, Porto SS, Balabram D, et al. Inter-observer variability between general pathologists and a specialist in breast pathology in the diagnosis of lobular neoplasia, columnar cell lesions, atypical ductal hyperplasia and ductal carcinoma in situ of the breast. Diagn Pathol. 2014;9:121.
28. Tan PH, Ho BC, Selvarajan S, et al. Pathological diagnosis of columnar cell lesions of the breast: are there issues of reproducibility? J Clin Pathol. 2005;58:705–9.
29. Ellis IO, Collins C, Ichihara S, et al. Invasive carcinoma of no special type. In: lakhani SR, Ellis IO, Schnitt SJ, et al., editors. WHO Classification of Tumours of the Breast. 4th ed. Lyon: International Agency for Research on Cancer (IARC); 2012. p. 34–38.
30. Lakhani SR, Rakha EA, Simpson PT. Invasive lobulair carcinoma. In: lakhani SR, Ellis IO, Schnitt SJ, et al., editors. WHO Classification of Tumours of the Breast. 4th ed. Lyon: International Agency for Research on Cancer (IARC); 2012. p. 40–42.
31. Schnitt SJ, Allred C, Britton P, et al. Ductal carcinoma in situ. In: lakhani SR, Ellis IO, Schnitt SJ, et al., editors. WHO Classification of Tumours of the Breast. 4th ed. Lyon: International Agency for Research on Cancer (IARC); 2012. p. 90–94.
32. Simpson JF, Schnitt SJ, Visscher D, et al. Atypcial ductal hyperplasia. In: lakhani SR, Ellis IO, Schnitt SJ, et al., editors. WHO Classification of Tumours of the Breast. 4th ed. Lyon: International Agency for Research on Cancer (IARC); 2012. p. 88–89.

33. Collins L, Visscher D, Simpson J, et al. Usual ductal hyperplasia. In: lakhani SR, Ellis IO, Schnitt SJ, et al., editors. WHO Classification of Tumours of the Breast. 4th ed. Lyon: International Agency for Research on Cancer (IARC); 2012. p. 84–85.
34. Lakhani SR, Schnitt SJ, O'Malley FP, et al. Lobular neoplasia. In: lakhani SR, Ellis IO, Schnitt SJ, et al., editors. WHO Classification of Tumours of the Breast. 4th ed. Lyon: International Agency for Research on Cancer (IARC); 2012. p. 78–80.
35. Lerwill MF. Flat epithelial atypia of the breast. Arch Pathol Lab Med. 2008;132:615–21.
36. Brogi E. Adenosis and Microglandular Adenosis. In: Hoda SA, Brogi E, Koerner F, et al., editors. Rosen's Breast Pathology. 4th ed. Philadelphia, PA: Lippincott Williams and Wilkins; 2014. p. 183–212.
37. van Diest PJ. No consent should be needed for using leftover body material for scientific purposes. For. BMJ. 2002;325:648–51.
38. Lacle MM, Kornegoor R, Moelans CB, et al. Analysis of copy number changes on chromosome 16q in male breast cancer by multiplex ligation-dependent probe amplification. Mod Pathol. 2013;26:1461–7.
39. Hungermann D, Schmidt H, Natrajan R, et al. Influence of whole arm loss of chromosome 16q on gene expression patterns in oestrogen receptor-positive, invasive breast cancer. J Pathol. 2011;224:517–28.
40. Rakha EA. The low nuclear grade breast neoplasia family. Diagn Histopathol. 2012;18:124–32.
41. Schouten JP, McElgunn CJ, Waaijer R, et al. Relative quantification of 40 nucleic acid sequences by multiplex ligation-dependent probe amplification. Nucleic Acids Res. 2002; 30:e57.
42. Nowee ME, Snijders AM, Rockx DA, et al. DNA profiling of primary serous ovarian and fallopian tube carcinomas with array comparative genomic hybridization and multiplex ligation-dependent probe amplification. J Pathol. 2007;213:46–55.
43. Moelans CB, de Weger RA, van Blokland MT, et al. HER-2/neu amplification testing in breast cancer by multiplex ligation-dependent probe amplification in comparison with immunohistochemistry and in situ hybridization. Cell Oncol. 2009;31: 1–10.
44. Lacroix-Triki M, Suarez PH, MacKay A, et al. Mucinous carcinoma of the breast is genomically distinct from invasive ductal carcinomas of no special type. J Pathol. 2010;222:282–98.
45. Turashvili G, Hayes M, Gilks B, et al. Are columnar cell lesions the earliest histologically detectable non-obligate precursor of breast cancer? Virchows Arch. 2008;452:589–98.
46. Shaaban AM, Sloane JP, West CR, et al. Histopathologic types of benign breast lesions and the risk of breast cancer: case-control study. Am J Surg Pathol. 2002;26:421–30.
47. Hanby AM, Ellis IO, Schnitt SJ. Columnar cell lesions. In: lakhani SR, Ellis IO, Schnitt SJ, et al., editors. WHO Classification of Tumours of the Breast. 4th ed. Lyon: International Agency for Research on Cancer (IARC); 2012. p. 86.
48. Kunju LP, Kleer CG. Significance of flat epithelial atypia on mammotome core needle biopsy: should it be excised? Hum Pathol. 2007;38:35–41.
49. Stange DE, Radlwimmer B, Schubert F, et al. High-resolution genomic profiling reveals association of chromosomal aberrations on 1q and 16p with histologic and genetic subgroups of invasive breast cancer. Clin Cancer Res. 2006;12:345–52.

50. Hwang ES, Nyante SJ, Yi Chen Y, et al. Clonality of lobular carcinoma in situ and synchronous invasive lobular carcinoma. Cancer. 2004;100:2562–72.
51. van Wezel T, Lombaerts M, van Roon EH, et al. Expression analysis of candidate breast tumour suppressor genes on chromosome 16q. Breast Cancer Res. 2005;7:R998–1004.
52. Rakha EA, Green AR, Powe DG, et al. Chromosome 16 tumor-suppressor genes in breast cancer. Genes Chromosomes Cancer. 2006;45:527–35.
53. Myhre S, Lingjaerde OC, Hennessy BT, et al. Influence of DNA copy number and mRNA levels on the expression of breast cancer related proteins. Mol Oncol. 2013;7:704–18.
54. Rakha EA, Pinder SE, Paish CE, et al. Expression of the transcription factor CTCF in invasive breast cancer: a candidate gene located at 16q22.1. Br J Cancer. 2004;91:1591–6.
55. Cleton-Jansen AM, van Eijk R, Lombaerts M, et al. ATBF1 and NQO1 as candidate targets for allelic loss at chromosome arm 16q in breast cancer: absence of somatic ATBF1 mutations and no role for the C609T NQO1 polymorphism. BMC Cancer. 2008;8:105.
56. Farabegoli F, Hermsen MA, Ceccarelli C, et al. Simultaneous chromosome 1q gain and 16q loss is associated with steroid receptor presence and low proliferation in breast carcinoma. Mod Pathol. 2004;17:449–55.
57. Nordgard SH, Johansen FE, Alnaes GI, et al. Genome-wide analysis identifies 16q deletion associated with survival, molecular subtypes, mRNA expression, and germline haplotypes in breast cancer patients. Genes Chromosomes Cancer. 2008;47:680–96.

Supplementary methods:

Guided by marked H&E stained slides, insulated lesions were macrodissected with a scalpel from serial of 8 to 10 μm of thick paraffin slides (deparaffinized for 10 minutes). In non-insulated cases laser microdissection (PALM Microlaser Technologies AG, Bernied, Germany) was performed on 8 to 10 μm thick paraffin slides, from which the areas of interest were catapulted by laser pressure into a cap moistened with a drop of mineral oil. DNA was extracted by adding 20 to 100 μl of lysis buffer (10 mM TRIS-Hcl pH 8,3, 0.5% Tween 0.20, 1 mM EDTA) and 5 to 20 μl proteinase K (10 mg/ml; Roche, Almere, The Netherlands), depending on the amount of starting material. The DNA was heated in a 56°C water bath overnight and if necessary, after 14-16 hours, additional 5 μl of proteinase K was added. Thereafter the sample was heat inactivated for 10 min and centrifuged. Five microliters of the supernatant, containing the DNA, was used for multiplex ligation-dependent probe amplification analysis. Multiplex ligation-dependent probe amplification was performed according to the manufacturers' instructions (MRC-Holland, Amsterdam, The Netherlands), using a Veriti 96-well thermal cycler (Applied Biosystems, Foster City, CA, USA). Reference samples (normal breast) were included in each multiplex ligation-dependent probe amplification experiment.

The PCR products were separated by electrophoresis on an ABI 3730 capillary sequencer (Applied Biosystems). Mean probe peaks were used for final gene copy number analysis with Genescan v4.1 (Applied Biosystems) and Coffalyser v9.4 (MRC-Holland) software. Per run, standard deviations of MLPA probes in the reference samples were calculated. Probes with standard deviations above 0.15 were excluded from further analysis.

Supplementary table 1. Genes and probes included in multiplex ligation-dependent probe amplification P451-A1 probemix

Gene	*Location*	Probe (length - nt)	Target exon(s)	Mittelman Database
ZNF638	2p13.2	00965-L00552 (355)	reference probe	
IL1RN	2q13	00517-L00097 (238)	reference probe	
GHRL	3p25.3	02266-L01752 (301)	reference probe	
MCCC1	3q27.1	06517-L20092 (479)	reference probe	
KLKB1	4q35.2	01217-L00694 (184)	reference probe	
IL4	5q31.1	00797-L13645 (130)	reference probe	
LAMA2	6q22.33	14955-L16688 (463)	reference probe	
COL1A2	7q21.3	13154-L14442 (454)	reference probe	
VCL	10q22.2	01119-L19685 (227)	reference probe	
ALX4	11p11.2	14431-L20042 (487)	reference probe	
KIF21A	12q12	05762-L05200 (360)	reference probe	
APEX1	14q11.2	05731-L05170 (208)	reference probe	
MESDC1	15q25.1	00977-L13327 (400)	reference probe	
TSC2	16p13.3	*11931-L20180* (321)	2	Associated with cancer
CREBBP	16p13.3	*09891-L10304* (190)	12	Associated with cancer
ABAT	16p13.2	*13864-L20685* (149)	4	Possibly associated with cancer
ABCC6	16p13.11	*07415-L07063* (178)	13	Possibly associated with cancer
PALB2	16p12.1	*07497-L19690* (375)	6	Possibly associated with cancer
VKORC1	16p11.2	*10491-L19684* (160)	1	Possibly associated with cancer
VPS35	16q11.2	*05770-L05208* (369)	13	Possibly associated with cancer
ABCC12	16q12.1	*08086-L19691* (409)	28	Possibly associated with cancer
CYLD	16q12.1	*16225-L20089* (265)	19	Associated with cancer
SALL1	16q12.1	*05679-L05121* (220)	3	Possibly associated with cancer
RBL2	16q12.2	*01193-L20088* (173)	2	Associated with cancer
MMP2	16q12.2	*04766-L04114* (337)	14	Associated with cancer
SLC12A3	16q13	*15520-L17375* (202)	12	Possibly associated with cancer
GPR56	16q13	*10195-L10655* (154)	10	Possibly associated with cancer
CDH11	16q22.1	*04229-L03565* (328) *04228-L20351* (144)	3 and 8	Possibly associated with cancer
TK2	16q22.1	*11589-L15222* (307)	6	Possibly associated with cancer
CDH1	16q22.1	*02412-L19686* (472) *02412-L19686* (232) *02414-L17063* (286)	1, 11 and 14	Associated with cancer
ZFHX3	16q22.3	*04738-L20091* (445)	3	Associated with cancer
WWOX	16q23.1	*03346-L01793* (416) *11970-L19689* (314)	4 and 10	Associated with cancer
CDH13	16q23.3	*07946-L20181* (436)	1	Associated with cancer

Supplementary table 1. Continued

Gene	*Location*	Probe (length - nt)	Target exon(s)	Mittelman Database
MLYCD	16q23.3	*06326-L05901* (214) *06327-L05902* (196)	2 and 3	Possibly associated with cancer
IRF8	16q24.1	*10286-L10798* (292)	9	Possibly associated with cancer
FOXF1	16q24.1	*S0590-L18601* (136)	2	Associated with cancer
FBXO31	16q24.2	*10265-L10777* (274)	4	Associated with cancer
SPG7	16q24.3	*07260-L06831* (391) *07261-L08406* (245)	3 and 4	Possibly associated with cancer
FANCA	16q24.3	*01707-L01275* (382) *01491-L01099* (256)	20 and 43	Associated with cancer
GAS8	16q24.3	*03201-L02669* (426)	6	Possibly associated with cancer
NPC1	18q11.2	10155-L18616 (166)	reference probe	
PRPF31	19q13.42	06015-L07508 (346)	reference probe	
NF2	22q12.2	02485-L19688 (279)	reference probe	

Supplementary table 2. Multiplex ligation-dependent probe amplification cut-off values for copy number ratios to define gains and losses.

Gene	Cutoff value loss mean -2 SD	Cutoff value gain Mean +2SD
TSC2 Exon 2	0.81783	1.22044
CREBBP Exon 12	0.74433	1.13463
ABAT Exon 4	0.86478	1.09419
ABCC6 Exon 13	0.76722	1.14727
PALB2 Exon 6	0.83131	1.23386
VKORC1 Exon 1	0.81327	1.12363
VPS35 Exon 13	0.85304	1.16558
ABCC12 Exon 28	0.86644	1.19356
CYLD Exon 19	0.91143	1.09616
SALL1 Exon 3	0.86341	1.05004
RBL2 Exon 2	0.87654	1.21381
MMP2 Exon 14	0.87639	1.15602
SLC12A3 Exon 12	0.87141	1.17135
GPR56 Exon 10	0.77839	1.11644
CDH11 Exon 8	0.87385	1.19097
CDH11 Exon 3	0.86495	1.25643
TK2 Exon 6	0.89106	1.17894
CDH1 Exon 11	0.89497	1.17434
CDH1 Exon 14	0.89474	1.09939
ZFHX3 Exon 3	0.89861	1.08760
WWOX Exon 4	0.90563	1.14886
WWOX Exon 10	0.90605	1.14326
CDH13 Exon 1	0.78608	1.09254
MLYCD Exon 2	0.89858	1.14521
MLYCD Exon 3	0.86470	1.16461
IRF8 Exon 9	0.83140	1.20170
FBXO31 Exon 4	0.86355	1.22059
SPG7 Exon 4	0.83136	1.14451
FANCA Exon 43	0.87220	1.15573
FANCA Exon 20	0.87132	1.07489
GAS8 Exon 6	0.81305	1.08798

These cutoff values are based on 58 multiplex ligation-dependent probe amplification runs with normal breast tissue, by calculating the mean value of these 58 runs ± 2 standard deviations for each probe.

SD = standard deviation

Chapter 5

Blunt duct adenosis: a separate entity from columnar cell lesions?

Mirthe de Boer, Paul J van Diest

*J Clin Pathol 2022;**75**:5–9.*

ABSTRACT

Blunt duct adenosis (BDA) is a breast lesion first described by Foote and Stewart in 1945 as a proliferative benign lesion of the terminal duct lobular unit. Throughout recent decades, further literature descriptions of BDA have been confusing. Some consider BDA to be a separate entity, some a growth pattern of columnar cell changes. The WHO 2012 considered BDA and columnar cell changes to be synonyms, while columnar cell lesions, especially those with atypia, are part of a spectrum of early precursors of the low nuclear grade breast neoplasia family. In the updated WHO 2019 version, BDA is mentioned as 'not recommended' terminology for columnar cell lesions without further discussing it, leaving the question open if BDA should be considered a separate entity.

Good diagnostic criteria for BDA have however largely been lacking, and its biological background has not yet been unravelled. In this paper, we point out that BDA is mainly associated with benign breast lesions and not with other recognised precursor lesions. Further, 16q loss, which is the hallmark molecular event in the low nuclear grade breast neoplasia family, is lacking in BDA. We therefore hypothesise that BDA may not be a true precursor lesion but a benign polyclonal lesion, and propose morphological diagnostic criteria to better differentiate it from columnar cell lesions.

INTRODUCTION

The human breast displays a broad spectrum of benign proliferative lesions. They are seen frequently and do not indicate an increased risk of breast cancer and therefore need to be discriminated from proliferative clonal breast lesions that are early precursors of invasive breast cancer. For many benign proliferative lesions, such as adenosis, apocrine metaplasia, usual ductal hyperplasia, sclerosing lobular hyperplasia and ductectasias, diagnostic criteria have been well defined these lesions do not often pose diagnostic dilemmas on the practising pathologist. An exception is blunt duct adenosis (BDA) that has caused confusion because of the varying terminology used in literature and the lack of a clear definition based on well- defined diagnostic criteria. Also, the relation with early precursors of the low nuclear grade breast neoplasia family like columnar cell lesions (CCLs) is unclear.

Here, we review the criteria for the diagnosis of BDA put forward by different authors, evaluate its biological background. This leads to the hypotesis that BDA may not be a true precursor lesion but a benign polyclonal lesion that needs to be discriminated from CCLs, for which we propose morphological diagnostic criteria.

MORPHOLOGICAL DESCRIPTIONS AND INTERPRETATION OF BDA IN THE LITERATURE

The earliest description of BDA was by Foote and Stewart in 1945[1] as a lesion affecting small or large areas of the breast tissue with formation of cysts in some cases. They postulated that BDA originated from terminal ducts with obliteration of the lobules as the process expands to dilated lobules.

In 1976, Azzopardi more extensively described BDA as a proliferative benign lesion of the enlarged terminal duct lobular unit (TDLU) not indicating increased risk of malignancy.[2] The lesion was conceptually viewed as 'organoid hypertrophy', with acini that are not increased in number but in size, with hyperplasia of the epithelium and increased intralobular stroma, and a prominent myoepithelial layer was illustrated in pictures. He also described non- organoid and microcystic forms of BDA.

In the scientific literature concerning CCLs, BDA was in the past often considered as a synonym or a growth pattern of CCL,[3,4] independent of atypia. Shaaban et al described different subtypes of BDA (BDA not otherwise specified, BDA with

calcifications, BDA with columnar cell metaplasia, BDA with atypical columnar cell metaplasia, BDA with usual ductal hyperplasia (UDH) and BDA with atypical ductal hyperplasia (ADH)).[3] In line with this, Kunju et al described that the most common morphological pattern (52%) of flat epithelial atypia (FEA) was that of BDA.[4] This is a good illustration of the overlap in terminology between BDA and CCL.

The WHO Classification of tumours of the breast, 2012 Edition, considers BDA as a synonym of columnar cell change (CCC)/hyperplasia (CCH), a category for which cytological atypia is not a feature.[5] Thereby, BDA was distinguished from FEA, for which cytonuclear atypia is the hallmark feature. This is also adopted in most recent textbooks about breast pathology, usually without further morphological descriptions. The 2019 WHO edition, however, clearly states in a chapter 'Columnar cell lesions including flat epithelial atypia' that BDA is 'not recommended terminology' for CCL[6] without further discussing BDA, leaving the question open whether it should be considered a separate entity. The histopathology description of columnar cell change by the WHO mentions "The involved acini usually have irregular contours", while we consider irregular contours to be rather a feature of BDA (see below), while the acini involved by FEA are described by the WHO to 'usually have smooth contours'. Nevertheless, in some textbooks, we found a more detailed description of BDA, and also different types or different stages of BDA were distinguished.

Brogi described BDA in Rosen's breast pathology[7] as a form of terminal duct hyperplasia characterised by abortive lobule formation, referring to the first description of Foote et al. Also some typical characteristics were mentioned, containing conspicuous myoepithelial cells with often abundant clear cytoplasm and slightly expanded, fibrotic and cellular intralobular stroma. Only the cystically dilated variant was described to simulate FEA.

Koerner[8] included two different lesions in the term BDA, the first one described by Foote and Steward, which in his opinion could not be confused with FEA. The second lesion included lobular hypertrophy with dilated glands, which can mimic FEA, probably similar to the microcystic form described by Azzo-pardi.[2] Koerner pointed out some differences between BDA and FEA like the flattened branching configurations in BDA in contrast to the round globular shapes in FEA, the prominent continuous myoepithelial layer in BDA which is incomplete and not conspicuous in FEA, and the cellular myxoid stroma of early BDA, while FEA stroma lacks these reactive features. At the same time, it was mentioned that in the early proliferative phase of BDA, the luminal cells have columnar features, abundant apical cytoplasm and slightly enlarged round nucleoli, and calcium deposits may be present, resembling FEA.

The book of Palazzo provided a chapter written by Lerwill with a comprehensive text on FEA including the differential diagnosis with BDA.[9] In the early proliferative phase of BDA, cells are described to be columnar with mildly enlarged and atypical nuclei comparable to the nuclei of UDH, dilated acini of branching shape and expanded intralobular stroma. Also an inactive phase of BDA was described, with more rounded acini in which the luminal cells have a stubby columnar or cuboidal shape, minimal cytoplasm and the nuclei are hyperchromatic with inconspicuous nucleoli, and more fibrotic stroma. Very illustrative pictures and a rather complete table with criteria to discriminate BDA from FEA were provided.

Also in the book of Dabbs, several subtypes of BDA were described, like a BDA with CCC/CCH lining, apocrine BDA and BDA of no special type.[10]

BDA AND ASSOCIATIONS WITH OTHER BREAST LESIONS

BDA has been described to be often associated with other benign proliferative lesions. BDA lesions have been described to regularly show apocrine changes.[7,10] Morphological overlap with UDH or foci of UDH in BDA have also been reported.[9,10] Only Foote and Stewart in 19451 support the association of BDA and benign cystic and proliferative lesions with data. It has been described that FEA may arise in a BDA background[11] but detailed morphological observations suggest that FEA more likely arises in structurally normal TDLU,[12] independent of BDA, which is also our experience.

Although the association of CCL without atypia and other family members of the low nuclear grade breast neoplasia family, like lobular neoplasia (LN) and tubular carcinoma, has been described,[13,14] we rarely observe such association for BDA.

IMMUNOHISTOCHEMICAL PROFILE OF BDA

Proposals for differentiating between BDA and FEA with immunohistochemical stainings have been put forward in several papers. BDA luminal cells express glandular keratins such as CK7, CK8 or CK18. CK5 and CK14 should display a mosaic pattern especially by small knots of hyperplastic cells protruding into the lumen, while CCLs are clonally negative.[9,10] Oestrogen receptor-α (ERα) is often expressed in a high percentage of the luminal cells of BDA, so this does not help much to discriminate BDA ERα patterns from the (clonally) positive ERα expression in CCL.[9]

There seems to be less cyclin D1 expression in BDA compared with CCL with atypia/FEA, although not all CCLs are cyclin D1 positive.[15] In our own practice, we usually see a quite low number of CK5 and CK14 positive cells in flat parts of BDA, while ERα is expressed in the majority of cells, meaning that there is no striking mosaic pattern and the lesion can be misinterpreted as clonal. In BDA with areas of UDH with more luminal proliferating cells, the immunohistochemical profile more clearly points towards a polyclonal proliferation. Altogether, immunohistochemical stainings do therefore not seem to play a major role in differentiating CCLs and BDA.

MOLECULAR STUDIES ON BDA

Molecular studies on BDA are difficult to identify because of the varying terminology used. It is especially difficult to find out if there are differences in molecular background between CCLs (without atypia) and BDA because likely, in some molecular studies on CCLs, cases of BDA as we define them have been included as CCL without atypia. Regarding to CCLs without atypia, Simpson et al studied 14 cases of CCL without hyperplasia and atypia that unlikely included BDA lesions (which are usually small) since enough DNA could be isolated for comparative genomic hybridisation (CGH) analysis. Four of these 14 CCLs showed loss of 16q by CGH,[16] suggesting the studied CCLs are low nuclear grade breast neoplasia family precursors despite absence of atypia. On the other hand, Go et al did not find deletions of 16q in CCLs without atypia.[17]

Our own study with well- defined BDA cases applying copy number multiplex ligation- dependent probe amplification for chromosome 16 showed no whole arm losses of 16q in 10 well- defined BDA cases, while 16q losses were common in CCLs with and without atypia.[18]

Altogether, these scarce data do not seem to point to clonal (premalignant) changes in BDA, in contrast to the CCLs with and without atypia.

BDA: A SEPARATE ENTITY?

Most authors of the described studies use BDA as a synonym of, or entity within the group of, CCL without atypia, and thereby discriminate BDA from CCL with atypia/FEA. This was endorsed by the WHO Classification of tumours of the breast up to the 2012 Edition. The 2019 WHO edition, however, clearly states that BDA is 'not recommended

terminology' for CCL.[6] We have provided several arguments that BDA may differ from CCL without atypia in the above. Using morphological characteristics (see next paragraph), BDA can, in our opinion, also well be separated from other lesions in this group. The role of CCL without atypia in breast carcinogenesis may have been questioned, but the 2019 WHO[6] states that "given that they (ie, CCL with- and without atypia) share immunophenotypic and molecular alterations with other lesions in the low- grade breast neoplasia pathway, it is reasonable to speculate that their etiology is similar". Not only the associations between CCL and lesions from the low- grade nuclear breast neoplasia family have been described,[13,14] also similar molecular alterations were found in CCL with and without atypia.[16,18] Especially chromosome 16q loss was found repeatedly, pointing towards a precursor role of both lesions in low nuclear grade breast carcinogenesis.[19]

Because of the morphological differences and our own molecular findings in BDA showing no 16q loss,[18] we propose that BDA is not part of this low nuclear grade breast neoplasia family but rather a benign polyclonal lesion. Potentially, the inclusion of BDA in the group of CCL without atypia has obscured the molecular and follow-up data in previous studies concerning CCLs without atypia. In fact, some lesions designated CCL in our own studies[20] later had to be reclassified as BDA. The final problem with the current diagnostic criteria is the low reproducibility of diagnosing CCL with and without atypia. Although O'Malley achieved excellent agreement (kappa index 0.83 and higher) in diagnosing CCLs after a tutorial and in a selected case set,[21] other groups found substantially lower kappa values (0.27 and 0.41).[22–24] This indicates that differentiating between CCLs with and without atypia can be difficult. Because of the definable morphological characteristics of BDA, we propose to recognise BDA as a separate entity that can be differentiated from true CCL.

PROPOSAL FOR MORPHOLOGICAL CRITERIA FOR BDA

Based on the common denominator of the above studies and books, and integrating morphological and molecular features, we propose to define BDAs an enlarged terminal duct lobular unit with the following specific characteristics (see also table 1 and figure 1):

1. Tubular and often irregular acinic contours.

The acinic structures in BDA are distended, tubular and usually have irregular contours. This is immediately visible on overview. This is in contrast to CCLs, in which the contours of the acinic structures are usually round to oval.

2. Specialised intralobular stroma.

The intralobular stromal component in BDA is expanded and in the early phase more cellular and myxoid compared with the surrounding stroma of the breast. Also, this feature is easily visible on overview. In CCLs, the stroma is usually not expanded, the cellularity is similar to the surrounding stroma, and myxoid change is usually lacking.

3. Prominent myoepithelium.

In BDA, the myoepithelium is prominent, often with clear cytoplasm. The myoepithelial cells are cuboidal. This in contrast to CCLs in which the myoepithelium is flattened and often not even well visible.

4. Usual ductal hyperplasia-like luminal epithelium.

The luminal epithelium of BDA consists of columnar cells, usually with apical snouts. Especially in early proliferative lesions, the cells are slightly disorderly lined. There are no clear visible borders between the cells and slight nuclear overlap is often seen. The nuclei can be slightly to moderately enlarged with sometimes prominent nucleoli. All these changes are similar to what is seen in usual type hyperplasia. The

Figure 1 (right page). Morphological and immunohistochemical characteristics of blunt duct adenosis (BDA). Case 1: Classic BDA. 1A: Expanded terminal duct lobular unit (TDLU) with characteristic enlarged and irregular and tubular acini (^) and expanded and cellular intralobular stroma (<). 1B: Prominent myoepithelium (↑), cellular intralobular stroma (<), cytoplasmic tufting of luminal epithelial cells (↓). 1C: Small area of usual type ductal hyperplasia (←). Case 2: BDA with usual type hyperplasia. 2A: Very expanded TDLU with characteristic enlarged and irregular acini (^) in the upper left and lower right corner, but more rounded acini in the centre. 2B: Usual type ductal hyperplasia- like luminal epithelium with slight disordered cell orientation, nuclear overlap (*) and inconspicuous cell borders. 2C: Clear focus of usual type ductal hyperplasia (←) in the centre. Case 3: BDA with apocrine metaplasia. 3A: Expanded TDLUs with enlarged and mostly irregular acini (^). 3B: Some rounded acini with apocrine metaplastic changes (*). 3C: Close op of the luminal cells of BDA with classic luminal snouting (↓), inconspicuous cell borders, nuclear overlap (>) and prominent nucleoli (→), in this context not to be interpreted as atypia. Case 4: Late phase BDA. 4A: TDLU with enlarged, largely rounded acini with in the lower left corner some irregular acinic contours (^). 4B: Intralobular stroma (<) is still expanded but less cellular. 4C: The myoepithelium is not prominent in all acinic structures. Case 5: Classic BDA. 5A: Expanded TDLU with characteristic enlarged and irregular and tubular acini and expanded and cellular intralobular stroma. 5B: Prominent myoepithelium highlighted by CK5 staining, some solitary cytokeratin (CK) positive luminal cells. 5C: Oestrogen receptor (ER) staining showing 100% positivity in this non- clonal proliferation. Case 6: Columnar cell lesion with atypia. 6A: Expanded TDLU with expanded regular rounded acini. 6B: Monotonous largely one- layered luminal epithelial proliferation that is partly flat, partly tufting. Several luminal calcifications. 6C: Conspicuous cell borders, monotonous round nuclei with nucleoli, cytoplasmic tufting. Inconspicuous myoepithelium. Fat cells between the acini, no intralobular fibrosis.

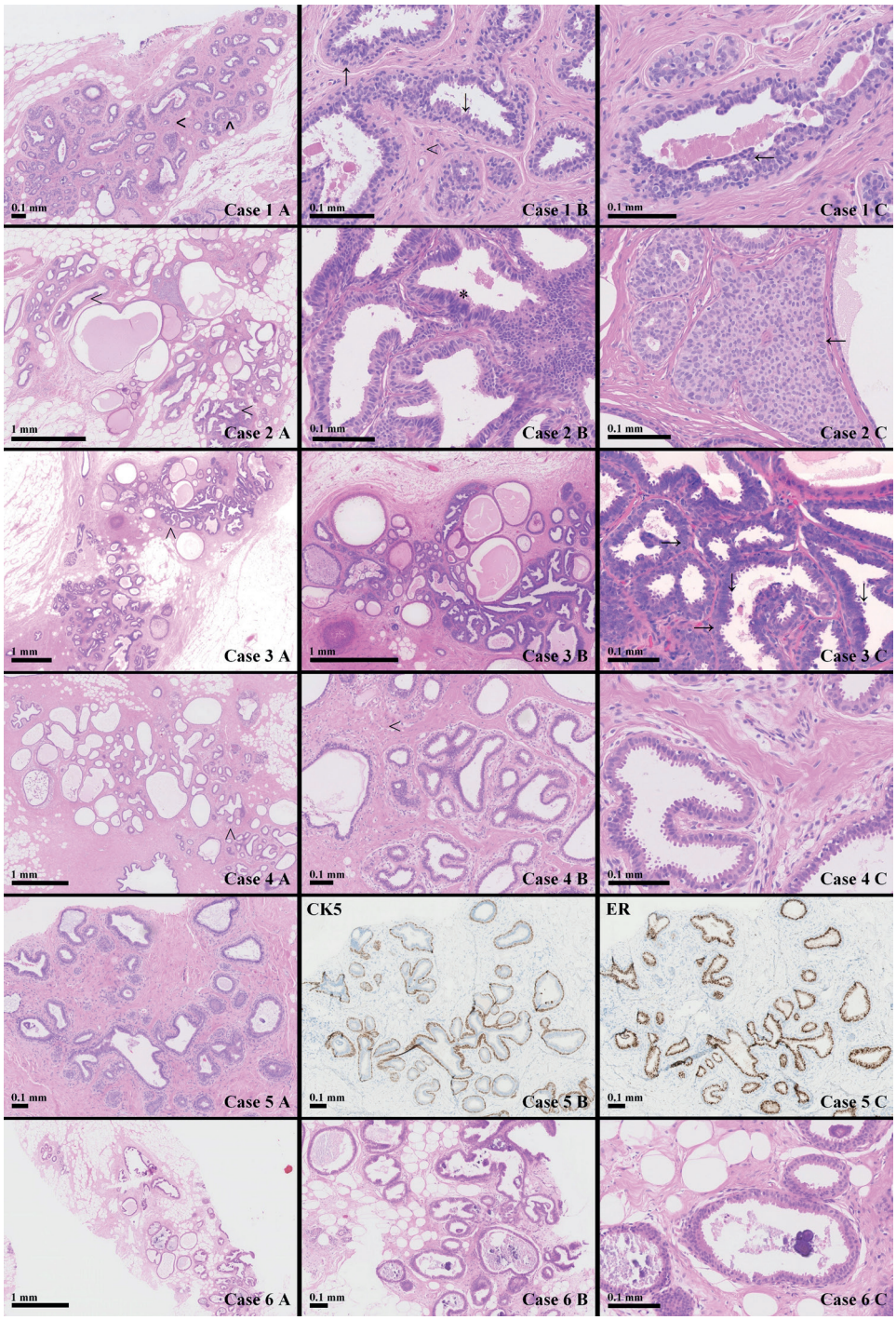
0.1 mm
Case 1 A
0.1 mm
Case 1 B
0.1 mm
Case 1 C
1 mm
Case 2 A
0.1 mm
Case 2 B
0.1 mm
Case 2 C
1 mm
Case 3 A
1 mm
Case 3 B
0.1 mm
Case 3 C
1 mm
Case 4 A
0.1 mm
Case 4 B
0.1 mm
Case 4 C
0.1 mm
Case 5 A
CK5
0.1 mm
Case 5 B
ER
0.1 mm
Case 5 C
1 mm
Case 6 A
0.1 mm
Case 6 B
0.1 mm
Case 6 C

5

larger and disorganised nuclei, with prominent nucleoli, can be confused with atypia as seen in CCLs with atypia. However, in contrast to BDA, the atypia in CCLs is apparent by a monotonous luminal cell population with conspicuous cell borders and lack of nuclear overlap. In the inactive (late stage) BDA, the nuclei are more orderly and hyperchromatic, usually without nucleoli.

Table 1. Differential diagnosis of blunt duct adenosis (BDA) vs columnar cell lesion (CCL) with and without atypia

	CCL without atypia	CCL with atypia	BDA
Shape of acini/ducts	**Round to oval**	**Round to oval**	**Distended, irregular, tubular**
Architecture	flat, tufts or mounds	flat, tufts or mounds; No well-formed bridges and papillary structures	flat, tufts or mounds
Stratification	present in CCL with hyperplasia	may be present	mild stratification may be present, sometimes (minimal) hyperplasia
Conspicuous cell borders	**+**	**+**	-
Luminal snouting	+	+	+
Intracytoplasmic vacuoles	rare	rare	-
Dimorphic cell population (“pale cells”)	rare	more frequent	-
Myoepithelium	**inconspicuous**	**inconspicuous**	**conspicuous**
Overlapping nuclei	**-**	**-**	**slightly**
Nuclear arrangement	regular	regular or disorderly	disorderly
Nuclear size	monotonous, small	monotonous or variable; enlarged	slightly variable, slightly to moderately enlarged
Nuclear shape	elongated/oval	oval to round	round to oval, slightly irregular
Nucleoli	inconspicuous; small	may be conspicuous	small to prominent
Position of nuclei	basal	usually central	basal
Microcalcifications	+	+	+
Luminal secretion	+	+	+
Luminal mucin	rare	rare	-
Intralobular stroma	**normal**	**normal**	**expanded and mildly cellular, often myxoid**
Immunohistochemistry	**CK5 negative**	**CK5 negative**	**CK5 mosaic in hyperplastic areas**
Molecular pathology	16q loss	16q loss	no 16q loss

+/−, may be present; +, usually present; −, not present; CK, cytokeratin.

As indicated, these features may slightly vary over the lifespan of a BDA. In the early (proliferative) phase, irregular acini dominate the lobular architecture, the intralobular stroma is more myxoid and less cellular, and the nuclei show more overlap and prominent nucleoli. In the late (inactive) phase, acini tend to adopt more rounded profiles and are lined by a simple, single layer of luminal cells without stratification. The cells have columnar or cuboidal shapes and minimal cytoplasm, apical or flattened. The nuclei are ovoid and the nucleoli are inconspicuous. The myoepithelium remains prominent, and the cellular intralobular stroma is still expanded but fibrotic rather than myxoid. The inactive phase of BDA is thereby more difficult to discriminate from columnar cell changes.

CONCLUSION

BDA has been a controversial entity, since uniform diagnostic criteria for the diagnosis BDA were lacking, and not much was known about its molecular background. In this paper, we point out that BDA is mainly associated with benign breast lesions and rarely with other recognised precursor lesions. Further, 16q loss, which is the hallmark molecular event in the low nuclear grade breast neoplasia family, is lacking in well-defined BDA. We therefore propose that BDA is not a true precursor lesion in the low nuclear grade breast neoplasia family but rather a benign polyclonal lesion that may be diagnosed based on four well-recognisable architectural and cytonuclear criteria. This may contribute to a better diagnosis of this common breast lesion in the differential diagnosis from CCL without atypia. Immunohistochemistry is of limited value, but molecular testing for 16q loss may help to make the distinction between BDA and CCL-type lesions in difficult cases. Follow-up data will have to show that the risk of subsequent progression to invasive cancer is indeed in the order of other benign lesions.[25–27] Also, the reproducibility of diagnosis of BDA versus CCL based on these criteria will have to be studied.

REFERENCES

1 Foote FW, Stewart FW. Comparative studies of cancerous versus noncancerous breasts. *Ann Surg* 1945;121:6–53.

2 Azzopardi JG. *Problems in breast pathology*. 1st edn. London: WB Saunders, 1979.

3 Shaaban AM, Sloane JP, West CR, *et al*. Histopathologic types of benign breast lesions and the risk of breast cancer: case-control study. *Am J Surg Pathol* 2002;26:421–30.

4 Kunju LP, Kleer CG. Significance of flat epithelial atypia on mammotome core needle biopsy: should it be excised? *Hum Pathol* 2007;38:35–41.

5 Hanbly AM, Ellis IO, Schnitt SJ. *Who classification of tumours of the breast*. 4th edn. Lyon: IARC Press, 2012: 86–7.

6 Schnitt SJ, Morris EA, Vincent-Salamon A. including flat epithelial atypia. In: *Breast tumours*. 5th edn. Lyon: IARC Press, 2019: 15–17.

7 Brogi E. Adenosis and microglandular adenosis. In: Hoda SA, Brogi E, Koerner FC, *et al*, eds. *Rosen's breast pathology*. 4th ed. Philadelphia, PA: Lippincott Williams & Wilkins, 2014: 183–212.

8 Koerner F. Conventional Ductal Proliferations. In: *Diagnostic problems in breast pathology*. Philadelphia, PA, 2009: 15–83.

9 Lerwill MF. Flat Epithelial Atypia. In: Palazzo JP, ed. *Difficult diagnosis in breast pathology*. New York: Demos Medical Pub, 201188-113.

10 Dabbs DJ. Fibrocystic changes and Usual Epithelial Hyerplasia of Ductal Type. In: *Breast pathology*. 2nd ed. Philadelphia, PA: Elsevier, 2017: 373–95.

11 Böcker W, Hungermann D, Tio J, *et al*. [Flat epithelial atypia]. *Pathologe* 2009;30:36–41.

12 Koerner FC, Oyama T, Maluf H. Morphological observations regarding the origins of atypical cystic lobules (low-grade clinging carcinoma of flat type). *Virchows Arch* 2001;439:523–30.

13 Carley AM, Chivukula M, Carter GJ, *et al*. Frequency and clinical significance of simultaneous association of lobular neoplasia and columnar cell alterations in breast tissue specimens. *Am J Clin Pathol* 2008;130:254–8.

14 Brandt SM, Young GQ, Hoda SA. The "Rosen Triad": tubular carcinoma, lobular carcinoma in situ, and columnar cell lesions. *Adv Anat Pathol* 2008;15:140–6.

15 Oyama T, Iijima K, Takei H, *et al*. Atypical cystic lobule of the breast: an early stage of low-grade ductal carcinoma in-situ. *Breast Cancer* 2000;7:326–31.

16 Simpson PT, Gale T, Reis-Filho JS, *et al*. Columnar cell lesions of the breast: the missing link in breast cancer progression? A morphological and molecular analysis. *Am J Surg Pathol* 2005;29:734–46.

17 Go EML, Tsang JYS, Ni Y-B, *et al*. Relationship between columnar cell changes and low-grade carcinoma in situ of the breast--a cytogenetic study. *Hum Pathol* 2012;43:1924–31.

18 de Boer M, Verschuur-Maes AHJ, Buerger H, *et al*. Role of columnar cell lesions in breast carcinogenesis: analysis of chromosome 16 copy number changes by multiplex ligation-dependent probe amplification. *Mod Pathol* 2018;31:1816–33.

19 Bürger H, de Boer M, van Diest PJ, *et al*. Chromosome 16q loss--a genetic key to the understanding of breast carcinogenesis. *Histol Histopathol* 2013;28:311–20.

20 Verschuur-Maes AHJ, Witkamp AJ, de Bruin PC, *et al*. Progression risk of columnar cell lesions of the breast diagnosed in core needle biopsies. *Int J Cancer* 2011;129:2674–80.

21 O'Malley FP, Mohsin SK, Badve S, *et al*. Interobserver reproducibility in the diagnosis of flat epithelial atypia of the breast. *Mod Pathol* 2006;19:172–9.

22 Gomes DS, Porto SS, Balabram D, *et al*. Inter-observer variability between general pathologists and a specialist in breast pathology in the diagnosis of lobular neoplasia, columnar cell lesions, atypical ductal hyperplasia and ductal carcinoma in situ of the breast. *Diagn Pathol* 2014;9:121.

23 Haupt B, Schwartz MR, Xu Q, *et al*. Columnar cell lesions: a consensus study among pathology trainees. *Hum Pathol* 2010;41:895–901.

24 Tan PH, Ho BC-S, Selvarajan S, *et al*. Pathological diagnosis of columnar cell lesions of the breast: are there issues of reproducibility? *J Clin Pathol* 2005;58:705–9.

25 Boulos FI, Dupont WD, Simpson JF, *et al*. Histologic associations and long-term cancer risk in columnar cell lesions of the breast: a retrospective cohort and a nested case-control study. *Cancer* 2008;113:2415–21.

26 Boulos FI, Dupont WD, Schuyler PA, *et al*. Clinicopathologic characteristics of carcinomas that develop after a biopsy containing columnar cell lesions: evidence against a precursor role. *Cancer* 2012;118:2372–7.

27 Aroner SA, Collins LC, Schnitt SJ, *et al*. Columnar cell lesions and subsequent breast cancer risk: a nested case-control study. *Breast Cancer Res* 2010;12:R61.

Chapter 6

Papillomatous breast lesions with atypical columnar cell features

Mirthe de Boer, Anoek H J Verschuur-Maes, Cathy Moelans, Paul J van Diest

J Clin Pathol 2023;76:228–233.

ABSTRACT

Columnar cell lesions (CCLs) are recognised breast cancer precursor lesions. Intraductal papillomas are usually lined by benign (polyclonal) cells. Although papillomas with monoclonal lesions (atypical ductal hyperplasia (ADH)/ductal carcinoma in situ (DCIS)) have been described, CCLs have not been described in papillomas.

We present two papillary breast lesions lined by a single layer of luminal cells resembling atypical CCL/flat epithelial atypia (FEA). We compared these two lesions with 13 benign intraductal papillomas, and 2 papillomas with ADH/DCIS grade 1 features as controls were immunohistochemically stained for the oestrogen receptor alpha (oestrogen receptor) and progesterone receptors (PR), cytokeratin 5 (CK5) and cyclin D1.

Oestrogen receptor/PR expression was variable, with areas with ≥85% hormone receptor positivity in both morphologically normal papillomas and papillomas with ADH. In ADH areas, CK5 expression was seen in ≤5% of cells while cyclin D1 expression was high (>60%). The two papillary lesions with FEA were 100% oestrogen receptor and 90% cyclin D1 positive, and low on PR/CK5. There was only one morphologically normal papilloma with similar areas of low CK5 (5%) and high cyclin D1 expression; in all other morphologically benign papillomas CK5 expression varied between 10% and 50% and cyclin D1 expression was ≤50%. The papillary lesion with FEA that could be tested showed 16q losses, the hallmark genetic change in low nuclear grade breast neoplasias, in contrast to nine morphologically benign papillomas that could be tested.

We present two papillomatous breast lesions with atypical CCL morphology and 16q loss, for which we propose the term papillary FEA.

INTRODUCTION

Columnar cell lesions (CCLs) of the breast are cystically dilated enlarged terminal duct lobular units lined by columnar luminal cells with uniform ovoid to elongated nuclei. The cytoplasm often shows apical blebs or snouts at the luminal surface. The luminal lining consists of one or two cell layers (columnar cell change) or multiple cell layers (columnar cell hyperplasia). Intraluminal secretions and microcalcifications are frequently seen.[1] In columnar cell change with atypia, also denoted as flat epithelial atypia (FEA), the columnar cells show nuclear atypia of relatively round to ovoid, sometimes irregular nuclei with nucleoli and an increased nuclear/cytoplasmic ratio. Also the nuclear orientation along the basement membrane can be disturbed. A complex architectural pattern upgrades a CCL to atypical ductal hyperplasia (ADH) or low grade ductal carcinoma in situ (DCIS).[2,3] These complex architectural patterns include well-developed micropapillae, rigid cellular bridges, bars and arcades, or sieve-like fenestrations ('cribriform architecture'), with evidence of cellular polarisation within the micropapillae and bars or around the fenestrations.[2] In recent years it has been recognised that CCLs play a role as a potential precursor of the low nuclear grade breast cancer family[4-6] with loss of 16q.[7,8]

According to the 2019 WHO Classification of Tumours, intraductal papillomas are characterised by a cohesive but arborescent structure composed of fibrovascular cores covered by a layer of myoepithelial cells with overlying luminal epithelial cells.[9] Foci of usual ductal hyperplasia (UDH) may be present. Apocrine changes are frequently found. Also papillomas with areas of ADH and DCIS have been described. In papillomas with ADH and DCIS, there is a focal luminal cell population with cytological and architectural features of (usually) low-grade ductal neoplasia. These atypical epithelial cells usually show lack of staining for high molecular weight keratins with uniform positivity for the oestrogen receptor.[10,11] While FEA lesions are regarded as precursors of ADH and DCIS, FEA is to our knowledge not been described in papillomas, also not in those with ADH or DCIS.

In this paper, we describe two papillomatous lesions with atypical CCL/FEA features throughout and compare these immunohistochemically and molecularly with a selected group of 13 morphologically benign intraductal papillomas without ductal hyperplasia and two papillomas with areas of ADH/DCIS grade 1.

MATERIAL AND METHODS

Patient material

From our routine practice at the University Medical Center Utrecht, the Netherlands, we derived two index patients. Both index patients demonstrating morphologically similar papillary lesions with throughout FEA-like features in their breast biopsies. To compare these lesions with (non-hyperplastic and non-apocrine areas of) benign intraductal papillomas, we additionally reviewed all intraductal papillomas diagnosed at our department from 01 January 2017 till 30 April 2017 for morphological, immunohistochemical and molecular evaluation. In this period, 30 intraductal papillomas were diagnosed. All were reviewed and classified by two experienced breast pathologists (MdB and PvD) according to the WHO classification.[9] Of these 30 intraductal papillomas, 15 were excluded, 9 because of insufficient material for additional immunohistochemistry, 3 because of extensive apocrine metaplasia and benign hyperplasia, resulting in lack of areas of flat luminal epithelium (as in CCL) and 3 because of multiple specimens of the same papillary lesion. In these last three cases the one specimen with most lesional material was chosen. Of the remaining 15 papillomas, there were 2 papillomas with areas of ADH/DCIS grade 1 and 13 morphologically benign papillomas. In one of the specimens with a morphologically benign papilloma, there was also ADH adjacent to the papilloma. Table 1 shows the patient characteristics.

Immunohistochemistry

Immunohistochemical stainings were performed according to the usual diagnostic procedure protocols on Ventana autostainers (Roche) used at the pathology department of the University Medical Center in Utrecht, The Netherlands, including appropriate positive and negative controls. The stainings were evaluated by two breast pathologists (MdB and PvD) by consensus. This left-over material was anonymously used in compliance with Dutch legislation.

The following stainings were used: cytokeratin 5 (CK5, Nova-castra, XM26, 1:200), oestrogen receptor alpha (Roche, SP1, ready-to-use), progesterone receptor (PR, Roche, 1E2, ready-to-use), cyclin D1 (Cellmarque, SP4, 1:100). In all morphologically normal papillomas, areas without UDH and apocrine metaplasia were selected to score the percentage of positive luminal cells regardless of staining intensity.

Analysis of 16q loss

Loss at 16q, the hallmark cytogenetic event in the low nuclear grade breast neoplasia family,[7] was analysed as before[8] by multiplex ligation-dependent probe amplification (MLPA). In short, after standard DNA extraction[8] from macrodissected paraffin sections, the P451-B1 probemix (MRC- Holland, Amsterdam, The Netherlands) was used containing 7 probes on the 16p arm and 29 probes on the 16q arm for target genes associated with cancer or possibly implicated in cancer (http://atlasgeneticsoncology.org/). Fourteen reference probes were included, which target relatively copy number stable regions in various cancer types, including breast cancer. All samples were tested in duplicate. Using Coffalyser.Net, all ratio values below 0.7 were defined as losses, and those above 1.3 were defined as gains.[8]

RESULTS

Index case 1

Patient 1 was a woman in her 50s with high breast density at screening mammography who was enrolled in the DENSE Study (NCT01315015) to undergo breast MRI, at which two lesions were found, one in each breast.[12] At biopsy, no abnormalities were found in the right breast. In the left breast, one small fragment contained fibrous tissue with parts of a papillary lesion with fibrovascular cores covered by a layer of inconspicuous myoepithelial cells and a single layer of monotonous columnar cells throughout the lesion. At the edge of the papillary projections, a more classical presentation of FEA seemed to be present. In this component, dilated, rounded, ductal structures, also lined by similar monotonous columnar cells with apical snouts were seen. Luminal calcifications were observed. The columnar cells had round to oval nuclei with inconspicuous nucleoli. The nuclei were arranged in a slightly irregular fashion. No architectural complexities like bridges, micropapillae or cribriformity were seen.

Figure 1 shows the H&E, CK5, oestrogen receptor and cyclin D1 slide of patient 1. In the subsequent lumpectomy on the left side, no further papillary structures were found, although there was a small focus of FEA. No DCIS or invasive carcinoma was seen. The patient died 17 months after the initial breast biopsy due to a metastatic lung carcinoma.

Index case 2

Patient 2 was a woman in her 50s presenting with calcifications on breast screening mammography classified as suspicious, according to the Breast Imaging- eporting

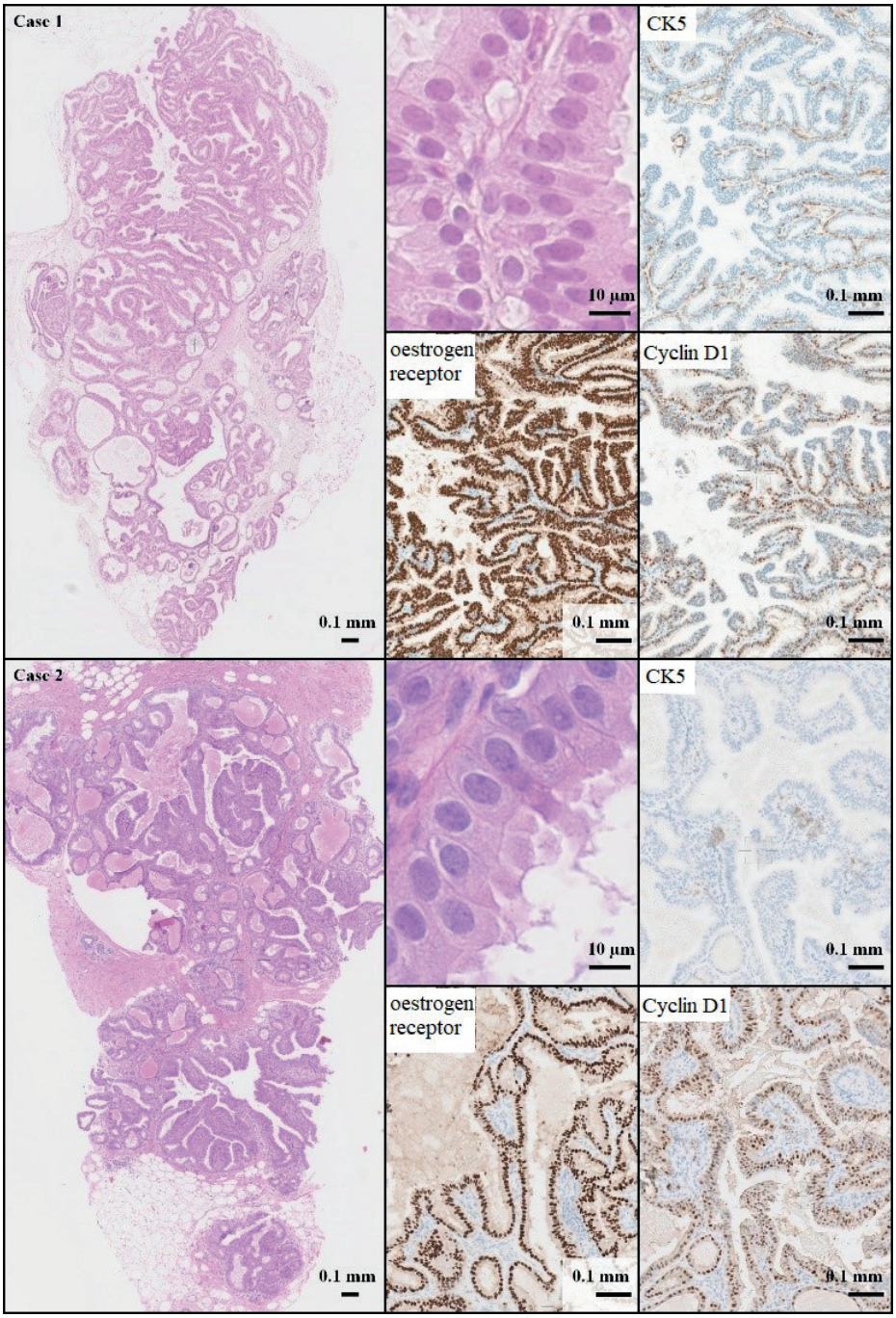
Case 1
10 µm
CK5
0.1 mm
oestrogen receptor
0.1 mm
Cyclin D1
0.1 mm
0.1 mm
Case 2
10 µm
CK5
0.1 mm
oestrogen receptor
0.1 mm
Cyclin D1
0.1 mm
0.1 mm

Figure 1 (left page). Morphology and immunohistochemistry of two index papillary flat epithelial atypia. CK5, cytokeratin.

Index case 1: Biopsy with a partially papillary lesion with fibrovascular cores covered with monotonous columnar cells with apical cytoplasmic snouts and rounded nuclei with inconspicuous nucleoli (FEA). The myoepithelium is discrete and flattened. The lining epithelium is completely negative for CK5, but strongly and diffusely oestrogen receptor positive. The cyclin D1 shows approximately 90% positivity of the lining cells.
Index case 2: Biopsy with a partially papillary lesion also covered with FEA-like columnar cells, similar to case 1. Also the immunohistochemical profile is consistent with case 1, with an epithelial layer that is CK5 negative and oestrogen receptor strongly and diffusely positive and increased cyclin D1 positivity.

and Data System (BI-BADS 4) . Vacuum-assisted core biopsies contained fibrous tissue with a partially papillary and partially ductal lesion (figure 1). The papillary projections contained fibrovascular cores and both the papillary structures and ductal structures were covered by myoepithelium and a monotonous layer of columnar cells (FEA) throughout the lesion. These columnar cells contained round to oval, basally orientated nuclei and between the cells there were sharp cell boarders. No architectural complexities were seen, excluding ADH or low-grade DCIS. According to the patient's preference, she was offered a wait-and-see policy with yearly mammography control for the next 10 years. Follow-up remained uneventful for 5 years.

Immunohistochemistry

As shown in table 1, oestrogen receptor expression in both papillary FEA lesions was 100% while PR expression was low, <1% in case 1 and 10%–20% in case 2, and both lesions showed very low CK5 expression (<2%). Cyclin D1 expression was high in both papillary FEA lesions (90%).

In the benign intraductal papillomas, oestrogen receptor expression varied between 30% and 90%, PR expression varied between 5% and 85%, cyclin D1 expression varied between 5% and 80%, and CK5 expression varied between 5% and 50%. In the two papillomas with ADH/DCIS grade 1 areas, the morphologically clonal areas showed high oestrogen receptor (80–100%) and PR (80%–90%) expression, while there was low CK5 expression (<2%). Cyclin D1 expression in these clonal areas was high too (80%). Figure 2 shows representative examples of a benign intraductal papilloma and a papilloma with ADH/DCIS.

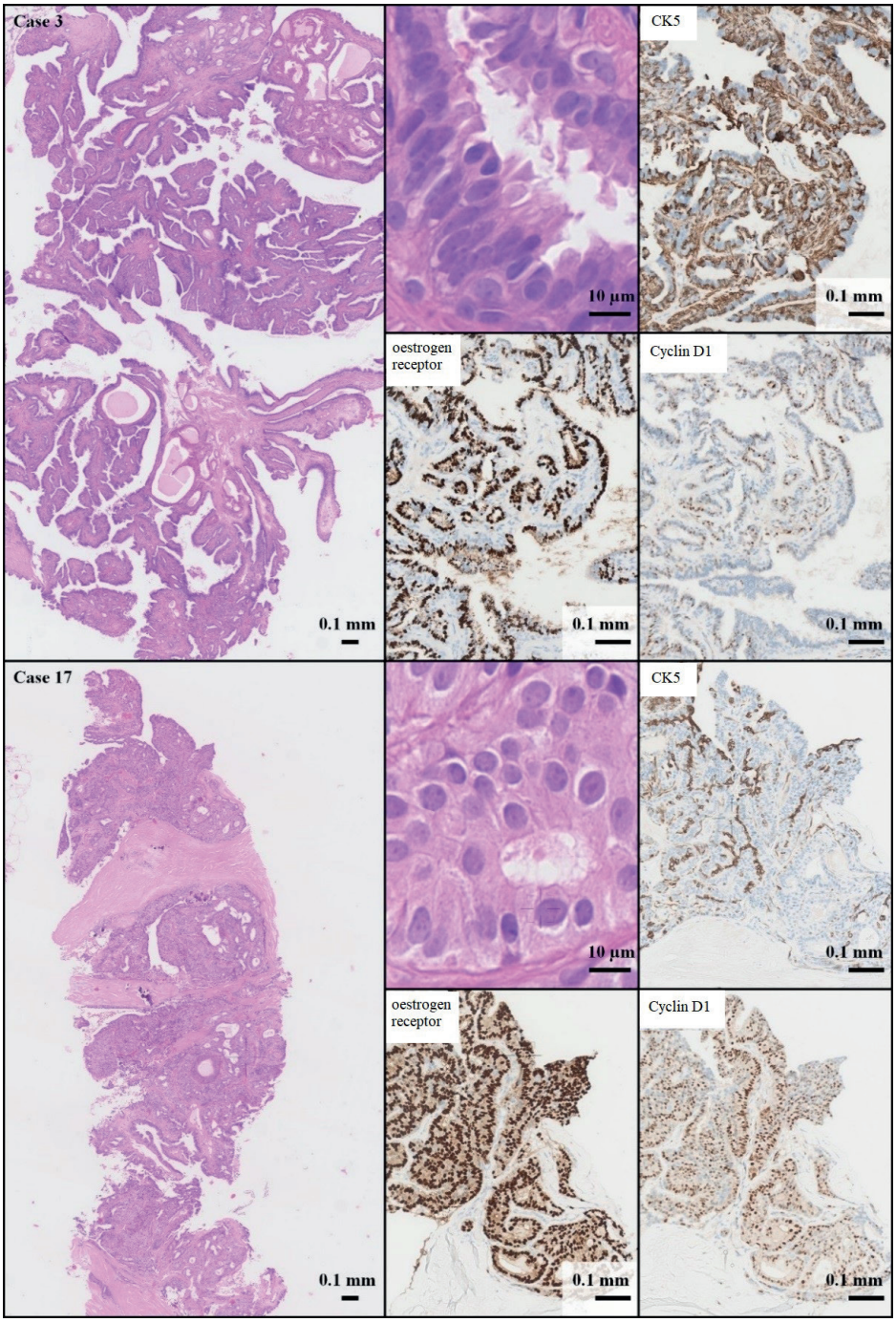
Case 3
10 µm
CK5
0.1 mm
oestrogen receptor
0.1 mm
Cyclin D1
0.1 mm
0.1 mm
Case 17
10 µm
CK5
0.1 mm
oestrogen receptor
0.1 mm
Cyclin D1
0.1 mm
0.1 mm

Figure 2. Representative examples of a benign intraductal papilloma and a papilloma with atypical ductal hyperplasia (ADH)/ductal carcinoma in situ (DCIS). CK5, cytokeratin.

Case 3: Vacuum biopsy with a papillary lesion with focal apocrine changes at the top right. The fibrovascular cores are lined with columnar cells with oval nuclei with small nucleoli. Compared with cases 1 and 2, the cell membranes of the lining cells are less visible and there is more nuclear overlap, and the nuclei are also more oval. Also compared with cases 1 and 2, there is clearly more positivity in the CK5 staining, with both prominent myoepithelium and mosaic (polyclonal) staining pattern in the lining epithelium. The oestrogen receptor shows slightly varying positivity and the cyclin D1 shows about 30% positivity in the lining cells.

Case 17: Core biopsy with a partially papillary lesion, in which the lining cells form compact and cribriform areas. The cribriform areas are formed by monomorphic cells with clear cell borders, lightly eosinophilic cytoplasm and rounded nuclei with fairly prominent nucleoli. No nuclear overlap is seen. In the CK5, a clonally negative region is seen on the right side, while a partial polyclonal population is still visible on the left side. The oestrogen receptor is strongly positive, whereby the more solid component is very noticeable. Cyclin D1 shows 80% positivity of the lining cells.

Chromosome 16 losses by MLPA

Table 2 shows the MLPA results of the lesions tested. In five cases (index case 2 and four benign intraductal papillomas (cases 8, 10, 11 and 14)) the analysis failed due to low input DNA. Case 1 showed loss for 11/29 probes on chromosome 16q. None of the nine tested morphologically benign papillomas that could be analysed showed probe losses on chromosome 16q. One of the two papillomas with ADH/DCIS grade 1 features showed loss of one probe on chromosome 16q, the other papilloma with ADH/DCIS grade 1 did not reveal any losses.

DISCUSSION

FEA, as a recognised precursor lesion of the low nuclear grade breast neoplasia family, has, to the best of our knowledge, not been described in intraductal papillomas. Two index cases of papillomas that we considered to show atypical columnar cell changes/FEA in regular diagnostics, 13 morphologically benign intraductal papillomas and 2 papillomas with ADH/DCIS grade 1 areas for clonality were analysed by immunohistochemistry and MLPA. We hereby carefully excluded areas of apocrine metaplasia, since these are usually oestrogen receptor/PR/CK5 negative, mimicking clonality. The index papillary FEA lesions and the ADH/DCIS cell populations in otherwise benign papillomas invariably showed low CK5 positivity and high cyclin D1 expression, although focal areas of low CK5 and high cyclin D1 expression were also seen in morphologically benign papillomas, whereas oestrogen receptor and PR were more variable. CK5 thereby seemed to be a suitable surrogate marker for clonality in papillomatous lesions, even in non-hyperplastic areas. This seems to be in accordance with the literature as far as hyperplastic areas are concerned,

Table 1 Clinicopathological data of 17 papillomatous breast lesions studied for clonality

Patient	Age	Biopsy/ resection	Diagnosis	CK5 % positive luminal cells	ER % positive luminal cells	PR % positive luminal cells	Cyclin D1 % positive luminal cells
1	50-55	CNB	papillary FEA	1-2%	100%	<1%	90%
2	50-55	VAB	papillary FEA	<1%	100%	10-20%	90%
3	50-55	VAB	Intraductal papilloma	50%	50%	50%	30%
4	56-60	Resection	Intraductal papilloma	30%	70%	60%	5%
5	25-30	VAB	Intraductal papilloma	20%	30%	50%	20%
6	20-25	VAB	Intraductal papilloma	30%	50%	10%-20%	20%
7	50-55	CNB	Intraductal papilloma	5%	90%	85%	80%
8	60-65	CNB	Intraductal papilloma	10%	90%	75%	30%
9	46-50	Conus excision	Intraductal papilloma	50%	50%	40%	10%
10	50-55	CNB	Intraductal papilloma	30%	70%	50%	20-40% weak
11	76-80	CNB	Intraductal papilloma	30%	90%	5%	30%
12	25-30	Resection	Intraductal papilloma	20%	70%	50%	5%
13	40-45	CNB	Intraductal papilloma	20%	80%	60%	40%
14	50-55	CNB	Intraductal papilloma	30%	80%	70%	20%
15	66-70	VAB	Intraductal papilloma with adjacent ADH	30%	90%	30%	50%
16	60-65	CNB	Papilloma with ADH/DCIS grade 1 areas	1-2%*	80%*	80%*	80%*
17	70-75	VAB	Papilloma with ADH/DCIS grade 1 areas	<1%*	100%*	90%*	80%*

*Scored in clonal areas.

ADH, atypical ductal hyperplasia; CK5, cytokeratin 5; CNB, core needle biopsy; DCIS, ductal carcinoma in situ; FEA, flat epithelial atypia; PR, progesterone receptor; VAB, vacuum assisted biopsy.

but previous studies have provided little detail on expression in non-hyperplastic areas.[13–18] In the present study CK5 expression in these non-hyperplastic papilloma areas was 5% or higher, with a mean expression of 27%, higher than the expression rate of morpho-logically clonal ADH/DCIS grade areas (<1%–2% CK5 expression).

Increased cyclin D1 expression is a well-known phenomenon in CCLs and low-grade DCIS.[4,19,20] In literature, cyclin D1 expression in benign intraductal papillomas ranged from 0% to 37%.[21,22] In our series of morphologically benign papillomas, expression of cyclin D1 ranged from 5% to 80%, with a mean of 29%. In contrast, the papillary FEA lesions and morphologically clonal areas in papillomas with ADH/DCIS grade 1 all had 80% or more cyclin D1 expressing cells.

As to oestrogen receptor, only 4% of all intraductal papillomas were described to show more than 70% oestrogen receptor expression,[13,23] in contrast to the present series with more than 70% oestrogen receptor expression in 6 out of 13 benign papillomas. This may be explained by the fact that we especially selected papillomas with minimal hyperplasia and without apocrine metaplasia. PR expression was even more variable in both morphologically benign papillomas and papillomas with ADH/DCIS. Therefore, hormone receptors do not seem to differentiate well between clonal and non-clonal epithelium in non-hyperplastic areas in papillomas.

Our two index cases were lesions with a papillomatous architecture but with morphologically atypical CCL/FEA features and clonal status by immunohistochemistry, corroborated by (non-contiguous) losses on chromosome 16q in the single case that could be analysed. This points towards a clonal precursor status comparable to FEA/atypical CCL or ADH, but morphologically these lesions seem to fall outside the spectrum of these diagnostic categories. We therefore propose the term 'papillary FEA' for these lesions, to be preferred over 'papilloma with FEA' since the index lesions were purely clonal and FEA-like did not concern FEA-like areas within a background of otherwise benign papillomas.

Confirmation by analysis of other molecular changes could be helpful, but besides 16q loss there are no other highly prevalent molecular changes in CCL. PIK3CA mutations occur in ~50%[24] so lack of this change does not preclude clonal cell change, and PIK3CA mutations are not specific for clonal cell change since they also occur in other proliferative lesions such as UDH.[25]

In conclusion, we present two papillomatous breast lesions with fibrovascular cores lined by a single layer of monotonous luminal cells with atypical CCL/FEA morphology,

Table 2 Overview of gains (green) and losses (red) on various gene loci on chromosome 16 by multiplex ligation-dependent probe amplification in different papillomatous lesions. Grey: not enough input DNA for analysis.

		Chromosome 16p							Chromosome 16q																							
		TSC2	CREBBP	ABAT	ABCC1	UQCRC2	PALB2	VKORC1	VPS35	ABCC12	CYLD	SALL1	RBL2	MMP2	SLC12A3	ADGRG1	CDH8	CDH11	TK2-6	CMTM3	CDH1 exon 4	CDH1 exon 14	TXNL4B	DHX38	ZFHX3	BCAR1	CNTNAP4	ADAMTS18	WWOX	CDH13	MLYCD	IRF8	FOXF1	FBXO31	SPG7	FANCA	GAS8
Patient	Diagnosis																																				
1	papillary FEA																																				
2	papillary FEA																																				
3	intraductal papilloma																																				
4	intraductal papilloma																																				
5	intraductal papilloma																																				
6	intraductal papilloma																																				
7	intraductal papilloma																																				
8	intraductal papilloma																																				
9	intraductal papilloma																																				
10	intraductal papilloma																																				
11	intraductal papilloma																																				
12	intraductal papilloma																																				
13	intraductal papilloma																																				
14	intraductal papilloma																																				
15	intraductal papilloma with adjacent ADH																																				
16	papilloma with ADH																																				
17	papilloma with ADH																																				

ADH, atypical ductal hyperplasia; FEA, flat epithelial atypia.

for which we propose the term papillary FEA. The clonal morphology was corroborated by low CK5 and high cyclin D1 expression and losses on chromosome 16q in the one lesion that could be tested.

REFERENCES

1 Fraser JL, Raza S, Chorny K, et al. Columnar alteration with prominent apical snouts and secretions: a spectrum of changes frequently present in breast biopsies performed for microcalcifications. Am J Surg Pathol 1998;22:1521–7.

2 Schnitt SJ. The diagnosis and management of pre-invasive breast disease: flat epithelial atypia--classification, pathologic features and clinical significance. Breast Cancer Res 2003;5:263–8.

3 Schnitt SJ, Vincent-Salomon A. Columnar cell lesions of the breast. Adv Anat Pathol 2003;10:113–24.

4 Abdel-Fatah TMA, Powe DG, Hodi Z, et al. Morphologic and molecular evolutionary pathways of low nuclear grade invasive breast cancers and their putative precursor lesions: further evidence to support the concept of low nuclear grade breast neoplasia family. Am J Surg Pathol 2008;32:513–23.

5 Simpson PT, Gale T, Reis-Filho JS, et al. Columnar cell lesions of the breast: the missing link in breast cancer progression? A morphological and molecular analysis. Am J Surg Pathol 2005;29:734–46.

6 Moinfar F, Man YG, Bratthauer GL, et al. Genetic abnormalities in mammary ductal intraepithelial neoplasia-flat type ("clinging ductal carcinoma in situ"): a simulator of normal mammary epithelium. Cancer 2000;88:2072–81.

7 Burger H, de Boer M, van Diest PJ, et al. Chromosome 16q loss--a genetic key to the understanding of breast carcinogenesis. Histol Histopathol 2013;28:311–20.

8 de Boer M, Verschuur-Maes AHJ, Buerger H, et al. Role of columnar cell lesions in breast carcinogenesis: analysis of chromosome 16 copy number changes by multiplex ligation-dependent probe amplification. Mod Pathol 2018;31:1816–33.

9 WHO Classification of Tumours of the Breast. Lyon: international agency for research on cancer, 2019: 52–6.

10 Ichihara S, Fujimoto T, Hashimoto K, et al. Double immunostaining with p63 and high-molecular-weight cytokeratins distinguishes borderline papillary lesions of the breast. Pathol Int 2007;57:126–32.

11 Mulligan AM, O'Malley FP. Papillary lesions of the breast: a review. Adv Anat Pathol 2007;14:108–19.

12 Bakker MF, de Lange SV, Pijnappel RM, et al. Supplemental MRI screening for women with extremely dense breast tissue. N Engl J Med 2019;381:2091–102.

13 Furuya C, Kawano H, Yamanouchi T, et al. Combined evaluation of CK5/6, ER, p63, and MUC3 for distinguishing breast intraductal papilloma from ductal carcinoma in situ. Pathol Int 2012;62:381–90.

14 Pathmanathan N, Albertini A-F, Provan PJ, et al. Diagnostic evaluation of papillary lesions of the breast on core biopsy. Mod Pathol 2010;23:1021–8.

15 Reisenbichler ES, Balmer NN, Adams AL, et al. Luminal cytokeratin expression profiles of breast papillomas and papillary carcinomas and the utility of a cytokeratin 5/p63/cytokeratin 8/18 antibody cocktail in their distinction. Mod Pathol 2011;24:185–93.

16 Tse GMK, Tan P-H, Lui PCW, et al. The role of immunohistochemistry for smooth-muscle actin, p63, CD10 and cytokeratin 14 in the differential diagnosis of papillary lesions of the breast. J Clin Pathol 2007;60:315–20.

17 Otterbach F, Bankfalvi A, Bergner S, et al. Cytokeratin 5/6 immunohistochemistry assists the differential diagnosis of atypical proliferations of the breast. Histopathology 2000;37:232–40.

18 Tse GM, Ni Y-B, Tsang JYS, et al. Immunohistochemistry in the diagnosis of papillary lesions of the breast. Histopathology 2014;65:839–53.

19 Dessauvagie BF, Zhao W, Heel-Miller KA, et al. Characterization of columnar cell lesions of the breast: immunophenotypic analysis of columnar alteration of lobules with prominent apical snouts and secretions. Hum Pathol 2007;38:284–92.

20 Luna-More S, Weil B, Bautista D, et al. Bcl-2 protein in normal, hyperplastic and neoplastic breast tissues. A metabolite of the putative stem-cell subpopulation of the mammary gland. Histol Histopathol 2004;19:457–63.

21 Wang Y, Zhu J-fu, Liu Y-ying, et al. An analysis of cyclin D1, cytokeratin 5/6 and cytokeratin 8/18 expression in breast papillomas and papillary carcinomas. Diagn Pathol 2013;8:8.

22 Saddik M, Lai R, Medeiros LJ, et al. Differential expression of cyclin D1 in breast papillary carcinomas and benign papillomas: an immunohistochemical study. Arch Pathol Lab Med 1999;123:152–6.

23 Grin A, O'Malley FP, Mulligan AM. Cytokeratin 5 and estrogen receptor immunohistochemistry as a useful adjunct in identifying atypical papillary lesions on breast needle core biopsy. Am J Surg Pathol 2009;33:1615–23.

24 Troxell ML, Brunner AL, Neff T, et al. Phosphatidylinositol-3- Kinase pathway mutations are common in breast columnar cell lesions. Mod Pathol 2012;25:930–7.

25 Ang DC, Warrick AL, Shilling A, et al. Frequent phosphatidylinositol-3- kinase mutations in proliferative breast lesions. Mod Pathol 2014;27:740–50.

Chapter 7

General discussion

In the General Introduction, we describe morphological immunohistochemical and molecular features of CCL and review the similarities and differences of CCLs and other benign and premalignant look-alikes to better define their place in breast carcinogenesis and improve reproducibility of their classification. Based on an analysis of the literature, we identify a number of gaps that we have tried to fill in in the subsequent Chapters of this thesis.

In **Chapter 2**, we review the role of chromosome 16q loss in breast carcinogenesis. Chromosome 16q loss is a key genetic event in the low nuclear grade breast neoplasia family. These low grade and estrogen receptor alpha (ERα) positive (pre) invasive lesions follow a different genetic progression pathway than high grade (pre)invasive breast lesions. CCLs have been proposed as earliest morphologically recognizable precursor lesions in the low nuclear grade breast neoplasia family. The knowledge gap on 16q losses in CCLs with- and without atypia and their lookalikes form an important base for the remaining chapters in this thesis. Still, no specific chromosome 16q-specific tumor suppressor gene is identified that could explain the carcinogenetic effect other than CDH1 that is (functionally) lost in carcinogenesis of ILC. Possible, this points to a multifactorial effect of different genes on 16q.

A morphological phenomenon that recently attracted our attention in this framework is the presence of rounded cells with clear cytoplasm just below the luminal columnar cells in CCLs, which we have become to call "pale cells". Dimorphic ("pale") cell populations have been described in low nuclear grade DCIS and our impression in clinical practice was that we regularly encounter pale cells in low-grade precursor lesions, but dimorphic differentiation had, to the best of our knowledge, not been described in CCLs and atypical ductal hyperplasia (ADH) before. In **Chapter 3**, we systematically retrospectively evaluate the presence of pale cells in a group of ADH and CCL lesions to cover the earliest spectrum of the low nuclear grade precursor lesions, in search of further morphological features of CCLs related to the designation cellular "atypia". Slides from 185 formalin fixed, paraffin-embedded breast tissue samples (biopsies or resections) with CCLs (N=60), ADH (N=41) and DCIS grade 1 (N=84) were collected and screened for presence of pale cells. Diagnostic criteria were derived from the WHO, and atypia was designated according to the Schnitt criteria. Pale cells occurred in 0% (0/30), 73% (22/30), 56% (23/41), and 76% (64/84) of CCLs without atypia, CCLs with atypia, ADH and DCIS grade 1, respectively. So, pale cells seem to occur throughout the low nuclear grade progression spectrum. Since CCLs without atypia did not contain pale cells, the presence of pale cells may serve as a diagnostic morphological feature of atypia in CCLs. The biological background of these pale cells is not clear. Pale cells turned out to be expressing ERα, E-cadherin

and p120 and variably cyclin D1, and lacked expression of cytokeratin 5 (CK5) and p63. We therefore hypothesize that these pale cells are neoplastic luminal epithelial cells. We have however no explanation why the morphology of these cells stands out. Further, when lesions are fully comprised of pale cells, they may be hard to designate as "pale" since contrast with non-pale cells is absent, indicating that the frequency of pale cell lesions reported here may be underestimated. For future research, it would be interesting to validate these findings in another diagnostic center, to identify kappa values and support the diagnostic value in differentiating between CCls with- and without atypia. Also it would be interesting to apply single cell RNA and DNA sequencing on microdissected pale cells and compare the genetic makeup of these pale cells with the surrounding clonal but non-pale cells and normal epithelium. Perhaps the pale cells are a subclone, as we sometimes see clonal expansion of pale cells forming groups that start to take over precursor lesions.

To further investigate the frequency of chromosome 16q loss in CCls with and without atypia, CCL look-alikes and other members of the low nuclear grade breast neoplasia family, we studied chromosome 16q losses in 23 CCLs and 19 ADH lesions arising in CCLs, as well as cases of UDH, blunt duct adenosis (BDA), DCIS, lobular neoplasia (LN) and invasive carcinoma in **Chapter 4**. Copy number changes of 6 genes on 16p and 20 genes on 16q were analyzed by multiplex ligation-dependent probe amplification (MLPA) in 165 lesions of 103 patients. UDH and BDA lacked whole arm losses of 16q. In contrast, CCLs without atypia, CCLs with atypia, ADH, low grade DCIS and low grade invasive carcinomas increasingly harbored whole arm losses of 16q (17%, 27%, 47% and 57%, respectively). This underlines the role of CCLs (with- and without atypia) as precursors in low nuclear grade breast carcinogenesis. In several patients, CCLs and ADH harbored similar losses as DCIS or invasive carcinomas within the same breast, supporting sequential progression. There were indications for 16q breakpoints near the centromere, although no recurrent losses in specific genes could be identified, making it unlikely the carcinogenic effect lies in major events in a single 16q gene. Haploinsufficiency could play a role here. To gain more insight into this process, it would be interesting to know more about protein expression of genes on chromosome 16q. Also in the literature there is a suggestion of intratumoral heterogeneity of chromosome 16q loss (1), so it would be interesting to investigate whether this finding can be confirmed and whether this phenomenon also plays a role in earlier precursor lesions. Chromosome 1q status in early precursor lesions would also be an interesting focus of research. In literature, chromosome 16q loss is often associated with chromosome 1q gains (2). It has even been suggested that overexpression of genes on chromosome 1q cooperate with gene losses on chromosome 16q (1, 2). Also there is an association between non-16q-located

single-nucleotide polymorphisms and chromosomal 16q losses (3). It therefore seems likely that a multitude of genes located on chromosome 16q, possible in combination with 1q or single-nucleotide polymorphisms with yet unknown interplay, contribute to the evolution of low-grade breast cancer, rather than major events in a few key genes. In our data, whole arm gains on 16p were relatively scarce, and there was no relation between whole arm gains of 16p and progression of lesions of the low grade breast neoplasia family. Therefore we concluded that chromosome 16p does not seem to play a significant role in progression of CCLs. The lack of chromosome 16q losses in BDA is interesting, because in the past BDA was often seen as a synonym of CCL without atypia or a growth pattern of CCLs. Our findings suggest BDA is a separate entity and not a precursor lesion of the low nuclear grade breast neoplasia family. This underlines the importance of morphologically discriminating BDA from CCL. This has led us to propose diagnostic criteria for BDA in **Chapter 5.** Based on the common denominator of our own experience and literature, and supported by the molecular features of **Chapter 4**, we propose to define BDAs an enlarged terminal duct lobular unit with the following specific characteristics as depicted in Table 1.

These features may slightly vary over the lifespan of a BDA. In the early (proliferative) phase, irregular acini dominate the lobular architecture, the intralobular stroma is more myxoid and less cellular, and the nuclei show more overlap and prominent nucleoli. In the late (inactive) phase, acini tend to adopt more rounded profiles, and are lined by a simple, single layer of luminal cells without stratification. The cells have columnar or cuboidal shapes and minimal cytoplasm, apical or flattened. The nuclei are ovoid and nucleoli are inconspicuous. The myoepithelium remains prominent, and the cellular intralobular stroma is still expanded but fibrotic rather than myxoid. The inactive phase of BDA is thereby more difficult to discriminate from columnar cell changes. In daily practice, immunohistochemistry is of limited value, but molecular testing for 16q loss may help to make the distinction between BDA and CCL type lesions. We think it is important to consider BDA as a separate entity because we believe it is not a precursor lesion. For future studies, reproducibility of diagnosis of BDA vs. CCL based on these criteria will have to be studied. Also follow up data will have to show that the risk of subsequent progression of BDA to invasive cancer does not exceed that of other benign lesions. The role of CCLs without atypia in breast carcinogenesis was difficult to demonstrate in previous literature. Potentially, the inclusion of BDA in the group of CCL without atypia has obscured the molecular and follow-up data in previous studies. Discrimination between BDA and CCls without atypia could provide more insight and could even improve follow-up protocols when CCLs without atypia are biopsied. With this knowledge, research into upgrade risk of CCLs and BDA in biopsies should be repeated.

Table 1. Differential diagnosis of blunt duct adenosis (BDA) versus columnar cell lesion (CCL) with- and without atypia (key features in bold)

	CCL without atypia	CCL with atypia	BDA
Shape of acini/ducts	**round to oval**	**round to oval**	**distended, irregular, tubular**
Architecture	flat, tufts or mounds	flat, tufts or mounds; No well-formed bridges and papillary structures	flat, tufts or mounds
Stratification	+ in CCL with hyperplasia	+/-	mild stratification may be present, sometimes (minimal) hyperplasia
Conspicuous cell borders	**+**	**+**	**-**
Luminal snouting	+	+	+
Intracytoplasmic vacuoles	rare	rare	-
Dimorphic cell population ("pale cells")	-	more frequent	-
Myoepithelium	**inconspicuous**	**inconspicuous**	**conspicuous**
Overlapping nuclei	**-**	**-**	**slightly**
Nuclear arrangement	regular	regular or disorderly	disorderly
Nuclear size	monotonous, small	monotonous or variable; enlarged	slightly variable, slightly to moderately enlarged
Nuclear shape	elongated/oval	oval to round	round to oval, slightly irregular
Nucleoli	inconspicuous; small	may be conspicuous	small to prominent
Position of nuclei	basal	usually central	basal
Microcalcifications	+	+	+
Luminal secretion	+	+	+
Luminal mucin	rare	rare	-
Intralobular stroma	**normal**	**normal**	**expanded and mildly cellular, often myxoid**
Immunohistochemistry	**CK5 negative**	**CK5 negative**	**CK5 mosaic in hyperplastic areas**
Molecular pathology	16q loss	16q loss	no 16q loss

Legend table 1: + = usually present; +/- = may be present; - = not present, CCL=columnar cell lesion, BDA = blunt duct adenosis, CK=cytokeratin

Another lookalike of a CCL can be intraductal papilloma. In **Chapter 6**, we describe two papillary breast lesions with fibrovascular cores lined by a single layer of monotonous luminal cells throughout the lesions, morphologically resembling the monoclonal cells of atypical CCL/flat epithelial atypia (FEA). We compared these two

CCL-like papillary lesions with 13 morphologically benign intraductal papillomas with limited UDH and two papillomas with areas displaying ADH/DCIS grade 1 features. All lesions were immunohistochemically stained for ER, progesterone receptors (PR), CK5 and Cyclin D1. ER and especially PR expression were variable in the different papillary lesions, with areas with ≥85% hormone receptor positivity in both morphologically normal papillomas and papillomas with ADH. In areas with ADH, CK5 expression was seen in 5% or less of cells while Cyclin D1 expression was high (>60%). The two atypical CCL-like papillary lesions were 100% ER and 90% Cyclin D1 positive, and low on PR and CK5. There was one morphologically normal papilloma with similar areas of low CK5 (5%) and high Cyclin D1 expression. In all other morphologically benign papillomas, CK5 expression varied between 10-50% and Cyclin D1 expression was 50% or lower. Analysis by MLPA for 16q loss, the hallmark genetic change in low grade nuclear breast neoplasms showed loss of 11 probes for genes on chromosome 16q in the one CCL-like papillary lesion that could be tested, while none of the 9 morphologically benign papillomas that could be analysed showed losses on chromosome 16q. Only one of the two papillomas with areas with ADH/DCIS grade 1 features showed loss of one 16q probe. The two index cases were lesions with a papillomatous architecture but with morphologically atypical CCL-like features and clonal status by immunohistochemistry, corroborated by losses on chromosome 16q in the single case that could be analysed. This points towards a clonal precursor status comparable to FEA/atypical CCL or ADH, but morphologically these lesions seem to fall outside the spectrum of these diagnostic categories because of the papillary architecture. We propose the term “papillary FEA” for these lesions, to be preferred over “papilloma with FEA” since the index lesions were purely clonal without a background of otherwise benign papillomas. A papillary CCL variant has never been described before and it would be interesting to know if other pathologists also encounter this variant in daily practice and whether there is more information about follow-up of these lesions.

References

1. Rye IH, Lundin P, Maner S, Fjelldal R, Naume B, Wigler M, et al. Quantitative multigene FISH on breast carcinomas identifies der(1;16)(q10;p10) as an early event in luminal A tumors. Genes Chromosomes Cancer. 2015;54(4):235-48.
2. Privitera AP, Barresi V, Condorelli DF. Aberrations of Chromosomes 1 and 16 in Breast Cancer: A Framework for Cooperation of Transcriptionally Dysregulated Genes. Cancers (Basel). 2021;13(7).
3. Nordgard SH, Johansen FE, Alnaes GI, Bucher E, Syvanen AC, Naume B, et al. Genome-wide analysis identifies 16q deletion associated with survival, molecular subtypes, mRNA expression, and germline haplotypes in breast cancer patients. Genes Chromosomes Cancer. 2008;47(8):680-96.

Appendices

Nederlandse samenvatting
Curriculum Vitae
Acknowledgements
List of publications

Nederlandse samenvatting

In de algemene introductie, **Hoofdstuk 1**, beschrijven we morfologische, immunohistochemische en moleculaire kenmerken van cilindercellaesies (CCL's) en kijken we naar de overeenkomsten en verschillen tussen CCL's en andere benigne en premaligne dubbelgangers, om hun plek in de carcinogenese van borstkanker beter te definiëren en de reproduceerbaarheid van de classificatie te verbeteren. Op basis van literatuuranalyse identificeren we een aantal hiaten die we trachten op te vullen in de daaropvolgende hoofdstukken van dit proefschrift.

In **Hoofdstuk 2** beoordelen we de rol van chromosoom 16q verlies in de carcinogenese van borstkanker. Chromosoom 16q verlies is een kenmerkende genetische verandering van de laaggradige borst neoplasie familie. Deze laaggradige, oestrogeen receptor alfa (ER**α**) positieve (pre)invasieve laesies hebben een andere genetische progressie dan hooggradige (pre)invasieve laesies in de borst. CCL's worden voorgesteld als de eerste morfologisch herkenbare precursor laesies in de laaggradige borst neoplasie familie. Het kennishiaat rondom chromosoom 16q verlies in CCL's met en zonder atypie en daarop lijkende laesies vormen een belangrijke basis voor de andere hoofdstukken in dit proefschrift. Er is nog steeds geen chromosoom 16q-specifieke tumorsuppressorgen geïdentificeerd dat het carcinogene effect kan verklaren, anders dan CDH1 dat (functioneel) verloren is in de carcinogenese van invasief lobulair carcinoom (ILC). Mogelijk wijst dit op een multifactorieel effect van verschillende genen op chromosoom 16q.

Een morfologisch fenomeen dat in dit kader recent onze aandacht heeft getrokken is de aanwezigheid van afgeronde cellen met bleek cytoplasma, net onder de luminale cilindrische cellen in een CCL, welke we "bleke cellen" ofwel "pale cells" zijn gaan noemen. Dimorfe (bleke) cellen zijn eerder beschreven in laaggradige DCIS en onze indruk uit de klinische praktijk is dat we regelmatig "bleke cellen" aantreffen in laaggradige precursor laesies. Dimorfe differentiatie is echter, voor zo ver wij weten, niet eerder beschreven in CCL's en atypische ductale hyperplasie (ADH). In **Hoofdstuk 3** onderzoeken we systematisch retrospectief de aanwezigheid van deze "bleke cellen" in een groep van ADH en CCL's, om ook het vroege spectrum van de laaggradige precursorlaesies te dekken. Mogelijk kan dit morfologische kenmerk ook gebruikt worden om in CCL's onderscheid te maken tussen de aan- of afwezigheid van "atypie". Coupes van 185 biopten en resecties van borstweefsel, allen formaline gefixeerd, parafine-ingebed, met CCL's (N=60), ADH (N=41) en DCIS graad 1 (N=84) werden verzameld en gescreend op de aanwezigheid van "bleke cellen". Diagnostische criteria van de WHO werden gebruikt voor de classificerende diagnose, en atypie

werd geclassificeerd op basis van de Schnitt criteria. “Bleke cellen” werden gezien in 0% (0/30), 73% (22/30), 56% (23/41), en 76% (64/84) van de CCL’s zonder atypie, CCL’s met atypie, ADH, DCIS graad 1, respectievelijk. “Bleke cellen” lijken daarbij voor te komen in het vroege spectrum van de laaggradige borst neoplasieën. Omdat CCL’s zonder atypie geen “bleke cellen” bevatten, kan de aanwezigheid van “bleke cellen” mogelijk gebruikt worden als diagnostisch morfologisch kenmerk van atypie in CCL’s. De biologische achtergrond van deze “bleke cellen” is nog niet duidelijk. “Bleke cellen” tonen expressie van ERα, E-Catherine en P120 en wisselend Cycline D1 en geen expressie van Cytokertine 5 (CK5) en P63. We veronderstellen daarom dat deze bleke cellen neoplastische luminale epitheliale cellen zijn. We hebben echter geen verklaring voor de opvallende morfologie van deze cellen. Als laesies volledig bestaan uit bleke cellen kan het lastig zijn ze te herkennen als “bleek”, omdat het contrast met niet-bleke cellen ontbreekt. Hierdoor kunnen de gerapporteerde frequenties van aanwezigheid van bleke cellen een onderschatting betreffen. In de toekomst zou het interessant zijn om deze bevindingen in een ander diagnostisch centrum te valideren, een kappa waarde vast te stellen en de diagnostische waarde voor de differentiatie tussen CCL’s met en zonder atypie te bevestigen. Ook zou het interessant zijn om middels “single cell RNA/DNA-sequencing” deze bleke cellen (met microdissectie) te vergelijken met omliggend klonaal en normaal epitheel. Mogelijk zijn de bleke cellen een subkloon van het niet-bleke clonale epitheel, aangezien we soms ook een klonale expansie van bleke cellen zien, met vorming van groepen, die de precursorlaesie deels over lijken te nemen.

Om de frequentie van chromosoom 16q verlies in CCL’s met en zonder atypie, CCL gelijkende laesies en andere leden van de laaggradige borst neoplasie familie te onderzoeken, hebben we naar chromosoom 16q verlies gekeken in 23 CCL’s, 19 ADH laesies (ontstaan in CCL’s), UDH, Blunt Duct Adenosis (BDA), DCIS, Lobulaire Neoplasie (LN) en invasieve carcinomen in **Hoofdstuk 4**. Copynumbervariatie van 6 genen op chromosoom 16p en 20 genen op chromosoom 16q werden geanalyseerd door middel van multiplex ligatie-afhankelijke probe amplificatie (MLPA) in 165 laesies van 103 patiënten. UDH en BDA hadden geen verlies van de complete arm van chromosoom 16q. Daarentegen werden in CCL’s zonder atypie, CCL’s met atypie, ADH, laaggradig DCIS en laaggradig invasieve carcinoom een toenemend aantal verlies van de complete arm van chromosoom 16q gezien (17%, 27%, 47% en 57%, respectievelijk). Dit onderstreept de rol van CCL’s met en zonder atypie, als precursor in de laaggradige borst carcinogenese. Bij enkele patiënten werden overeenkomstige veranderingen van chromosoom 16q gezien in de bij dezelfde borst voorkomende CCL, ADH, DCIS of invasief caricinoom, wat sequentiële progressie ondersteunt. Er waren indicaties voor een breekpunt op chromosoom 16q nabij het

centromeer. Er kon echter geen overlappend gebied met verlies van specifieke genen geïdentificeerd worden, wat het onwaarschijnlijk maakt dat het carcinogenetische effect veroorzaakt wordt door een belangrijke genetische verandering van één afzonderlijk gen op chromosoom 16q. Haploinsufficiëntie zou een rol kunnen spelen. Om meer inzicht in dit proces te krijgen zou het interessant zijn om meer te weten te komen over eiwit expressie van genen op chromosoom 16q. Ook is er in de literatuur de suggestie gedaan van intratumorale heterogeniteit van chromosoom 16q verlies (1). Het zou derhalve interessant zijn om te onderzoeken of heterogeniteit kan worden bevestigd en of dit een rol speelt in vroege precursorlaesies. Chromosoom 1q status in vroege precursor laesies zou ook een interessant focus zijn voor nader onderzoek. In de literatuur is chromosoom 16q verlies vaak geassocieerd met een toename van chromosoom 1q (2). Er is zelfs gesuggereerd dat overexpressie van genen op chromosoom 1q en verminderde expressie van genen op chromosoom 16q functioneel samenwerken in de carcinogenese. (2). Daarnaast is er ook een associatie tussen niet op chromosoom 16q gelegen "single nucleotide polymorfisms" (SNP's) en deletie van chromosoom 16q (3). Het is daarom waarschijnlijk dat een groot aantal genen op chromosoom 16q, mogelijk in combinatie met overexpressie van genen op chromosoom 1q en/of SNP's in een nog onbekend samenspel bijdragen aan de ontwikkeling van laaggradige borstkanker, in plaats van grote events in een beperkt aantal sleutelgenen. In onze data wordt een toename van de complete arm van chromosoom 16p relatief weinig gezien. Ook was er geen relatie vast te stellen tussen toename van de complete arm van chromosoom 16p en progressie van laesies in de laaggradige borst neoplasie familie. Daarom concluderen we dat chromosoom 16p geen significante rol lijkt te spelen in progressie van CCL's.

Het ontbreken van verlies van chromosoom 16q in BDA is interessant, omdat in het verleden BDA vaak werd gezien als een synoniem van CCL zonder atypie, of een groeipatroon van CCL's. Onze bevindingen suggereren dat BDA een aparte entiteit is en geen precursor laesie van de laaggradige borst kanker familie. Dit onderstreept het belang van de morfologische discriminatie tussen BDA en CCL's. Dit heeft geleid tot een voorstel van diagnostische criteria voor BDA in **Hoofdstuk 5**. Gebaseerd op de gemene deler van onze ervaring en literatuur, ondersteunt met moleculaire kenmerken van **Hoofdstuk 4** stellen we voor BDA te definiëren als vergrote terminale duct lobulaire unit met specifieke karakteristieken welke zijn weergegeven in tabel 1.

Tabel 1. Differentiaal diagnose van blunt duct adenosis (BDA) versus cilindercellaesie's (CCL's) met en zonder atypie (de belangrijkste kenmerken zijn dikgedrukt).

Tabel 1: + = meestal aanwezig; +/- = kan aanwezig zijn; - = niet aanwezig, CCL=cilindercellaesie, BDA = blunt duct adenosis, CK=cytokeratine

	CCL zonder atypie	CCL met atypie	BDA
Vorm van de acini/ ducten	**Rond tot ovaal**	**Rond tot ovaal**	**Gedilateerd, onregelmatig, tubulair**
Architectuur	Vlak, "plukjes" of heuvels	Vlak, "plukjes" of heuvels. Geen goed gevormde bruggen of papillaire structuren.	Vlak, "plukjes" of heuvels
Stapeling van de cellen	+ bij CCL met hyperplasie	+/-	+/- met name bij geringe hyperplasia
Opvallende celgrenzen	**+**	**+**	**-**
Luminale cytoplasma uitstulpingen (snouts)	+	+	+
Intracytoplasmatische vacuolen	Zeldzaam	Zeldzaam	-
Dimorfe celpolulatie (bleke cellen)	-	Vaker	-
Myoepitheel	**Onopvallend**	**Onopvallend**	**Opvallend**
Overlapping kernen	**-**	**-**	**Enigszins**
Kernligging ten opzichte van elkaar	Regelmatig	Regelmatig of or wanordelijk	Wanordelijk
Kerngrootte	Monotoon, klein	Monotoon of wisselend vergroot	Licht wisselend, licht tot matig vergroot
Kernvorm	Verlengd/ovaal	Ovaal tot rond	Rond tot ovaal, licht onregelmatig
Nucleoli	Onopvallend; klein	Kunnen opvallend zijn	Klein tot prominent
Positie van de kernen	Basaal	Meestal centraal	Basaal
Microcalcificaties	+	+	+
Luminale secreties	+	+	+
Luminaal slijm	Zeldzaam	Zeldzaam	-
Intralobulair stroma	**Normaal**	**Normaal**	**Toegenomen en licht celrijk, vaak myxoid**
Immunohistochemie	**CK5 negatief**	**CK5 negatief**	**CK5 mozaïek in hyperplastische gebieden**
Moleculaire pathologie	16q verlies	16q verlies	Geen 16q verlies

Deze kenmerken kunnen iets variëren in de levensloop van een BDA. In de vroege (proliferatieve) fase domineren de irregulaire acini de lobulaire architectuur. Het intralobulaire stroma is meer myxoid en minder cellulair en de kernen tonen meer overlap en prominente nucleoli. In de latere (inactieve) fase hebben de acini meer de neiging om af te ronden en worden deze bekleed met een enkele laag luminale

cellen zonder stapeling. De cellen hebben een cilindrische of kubische vorm en een geringe hoeveelheid apicaal cytoplasma of zijn meer afgeplat. De kernen zijn ovaal en nucleoli zijn juist minder opvallend. Het myoepitheel blijft prominent aanwezig en het celrijke intralobulaire stroma blijft toegenomen maar is meer fibrotisch dan myxoid. De inactieve fase van een BDA is lastiger te onderscheiden van cilindercelveranderingen. In de dagelijkse praktijk heeft immuunhistochemie beperkte waarde, maar moleculair testen op de aanwezigheid van chromosoom 16q verlies kan helpen om onderscheid te maken tussen BDA en CCL's.

We denken dat het belangrijk is om BDA als een aparte entiteit te beschouwen omdat we geloven dat dit niet een precursor laesie is. In de toekomst zal de reproduceerbaarheid van de diagnose van BDA versus CCL gebaseerd op de genoemde criteria moeten worden onderzocht. Ook zal follow-up data moeten aantonen dat het risico op invasieve maligniteit niet hoger is na de diagnose BDA dan bij andere benigne laesies. De rol van CCL's zonder atypie in de borst carcinogenese was moeilijk aan te tonen in de eerdere literatuur. Mogelijk omdat de inclusie van BDA in de groep van CCL zonder atypie de moleculaire en follow-up data in eerdere studies heeft vertroebeld. Onderscheid tussen BDA en CCL's zonder atypie zou meer inzicht kunnen geven en zou zelfs de follow-up protocollen kunnen verbeteren als het gaat om CCL zonder atypie in een biopt. Met deze kennis, zou het onderzoek met betrekking tot het upgrade risico van CCL's en BDA in biopten moeten worden herhaald.

Een intraductaal papilloom kan in bepaalde gevallen ook lijken op een CCL. **In Hoofdstuk 6** beschrijven we twee papillaire mamma laesies met fibrovasculaire kernen die door de gehele laesie bekleed zijn met een enkele laag monotone luminale cellen. De bekledende cel populatie lijkt morfologisch op de monoclonale cellen van een atypische CCL/"flat epithelial atypia" (FEA). We vergeleken deze twee papillomateuze mamma laesies met atypische CCL kenmerken met 13 morfologisch benigne intraductale papillomen met beperkte UDH en twee papillomen met gebieden met ADH/DCIS graad 1. Alle laesies werden immunohistochemisch gekleurd met ER, progesteron receptor (PR), CK5 en Cycline D1. ER en vooral PR expressie waren variabel in de verschillende papillaire laesies, met gebieden van ≥85% hormoon receptor positiviteit in zowel de morfologisch normale papillomen als de papillomen met ADH/DCIS graad 1. In gebieden met ADH was de CK5 5% of minder terwijl de cycline D1 expressie hoog was (>60%). De twee papillomateuze mamma laesies met atypische cilindercel kenmerken waren 100% ER positief en 90% Cycline D1 positief, met een lage expressie van PR en CK5. Er was één morfologisch normaal papilloom met vergelijkbare gebieden met een lage CK5 (5%) en hoge cycline D1 expressie. In alle andere morfologisch benigne papillomen was de CK5 expressie tussen de 10 en

50% en de cycline D1 expressie 50% of lager. Analyse voor chromosoom 16q verlies, het kenmerk van laaggradige borst neoplasieën, door middel van MLPA, toonde verliezen van 11 probes voor genen op chromosoom 16q in de enige papillomateuze laesie met atypische cilindercel kenmerken die we konden analyseren. Geen van de 9 morfologisch benigne papillomen die konden worden geanalyseerd toonde verliezen op chromosoom 16q. Slechts één van de twee papillomen met ADH/DCIS graad 1 toonde verlies van één probe op chromosoom 16q. Beide indexcases tonen een laesie met een papillomateuze architectuur maar morfogisch met karakteristiek van een atypische cilindercellaesie/FEA en een klonaal immunohistochemisch profiel. Één van de twee cases kon geanalyseerd worden middels MLPA, waarbij verliezen op chromosoom 16q werden aangetoond. Deze bevindingen wijzen in de richting van een klonale precursor status, vergelijkbaar met een atypische cilindercellaesie/FEA of ADH. Echter, door de papillaire architectuur vallen deze laesies buiten de criteria van deze diagnostische categorieën. Voor deze laesies stellen we de nieuwe term "papillaire FEA" voor. Deze term prefereren we boven de term "papilloom met CCL" omdat de index laesies compleet bestonden uit een klonale, CCL-gelijkende celpopulatie en de achtergrond van een normaal papilloom ontbrak. Een papillaire variant van een atypische CCL/FEA is nooit eerder beschreven en het zou interessant zijn om te weten of andere pathologen deze variant ook in de dagelijkse praktijk tegenkomen en om meer informatie te verzamelen over de follow-up van deze laesies.

Referenties

1. Rye IH, Lundin P, Maner S, Fjelldal R, Naume B, Wigler M, et al. Quantitative multigene FISH on breast carcinomas identifies der(1;16)(q10;p10) as an early event in luminal A tumors. Genes Chromosomes Cancer. 2015;54(4):235-48.
2. Privitera AP, Barresi V, Condorelli DF. Aberrations of Chromosomes 1 and 16 in Breast Cancer: A Framework for Cooperation of Transcriptionally Dysregulated Genes. Cancers (Basel). 2021;13(7).
3. Nordgard SH, Johansen FE, Alnaes GI, Bucher E, Syvanen AC, Naume B, et al. Genome-wide analysis identifies 16q deletion associated with survival, molecular subtypes, mRNA expression, and germline haplotypes in breast cancer patients. Genes Chromosomes Cancer. 2008;47(8):680-96.

Curriculum Vitae

Mirthe de Boer werd geboren op 7 april 1986 in Alkmaar. In 2004 behaalde ze haar VWO diploma aan het Petrus Canisius College in Alkmaar. Vanaf 2004 studeerde ze Geneeskunde aan de Universiteit van Utrecht. Tijdens de geneeskundeopleiding werkte ze onder andere als student-assistent bij het onderwijscentrum van het UMCU en assisteerde ze bij microscopie practica. Na haar arts-examen in 2010 startte ze in september met de specialisatie tot klinisch patholoog in het Universitair Medisch Centrum in Utrecht (opleiders Jan van den Tweel en Roos Leguit). Vanaf de start van haar specialisatie leverde ze een bijdrage aan het onderwijs binnen het curriculum van Geneeskunde en Biomedische Wetenschappen in Utrecht.

Daarnaast startte ze in 2012 met haar promotieonderzoek onder begeleiding Paul van Diest. Een deel van haar opleiding volgde ze in Gelre Ziekenhuizen (opleider Heleen Doornewaard) en in het Antoni van Leeuwenhoek ziekenhuis (opleider Loes van Velthuysen), voor extra verdieping in de cytologie.

Na de opleiding als patholoog heeft ze van 2016 tot en met 2022 gewerkt in het UMC Utrecht, met als aandachtsgebieden cytologie, hematopathologie en mammapathologie. Daarnaast was ze unithoofd van de cytologie. Vanaf 2022 werkt ze bij Pathologie-DNA (locatie Rijnstate).

Mirthe woont samen met Clemens in Driebergen-Rijsenburg, samen met hun 3 kinderen, Benter (2012), Fosse (2018) en Sverre (2022).

Acknowledgements

Prof.dr Paul van Diest, beste Paul, bedankt voor de begeleiding en je vertrouwen in mij. Ik heb van jou geleerd pragmatisch te zijn. Naast dat we heel veel hebben samengewerkt, hebben we muziek gemaakt en veel gepraat. En soms hadden we een andere kijk op iets, en dat is OK.

Cathy, bedankt voor de ondersteuning, met name bij de MLPA analyse.

Geachte leden van de leescommissie, bedankt voor jullie tijd en interesse in mijn proefschrift.

Willy, bedankt voor je warme ondersteuning en organisatorische hulp.

Beste pathologen, AIOS en analisten (in het bijzonder de cytologie analisten en Natalie) in het UMCU. Bedankt voor de prachtige samenwerking, het waren mooie en leerzame jaren. De samenwerking voelde als een geoliede machine, met wederzijds vertrouwen. Ik kon altijd terug vallen op jullie kennis, gezelligheid en support. Ik hoop jullie nog regelmatig tegen te komen en samen te kunnen blijven werken.

Beste collega pathologen van pathologie-DNA. Bedankt voor het vertrouwen in mij. Het voelt als een warm bad en ik ben blij dat ik met jullie dit feestje kan vieren.

Roos, ik heb zo ongelofelijk veel van je geleerd, daar kan ik je mijn hele carrière nooit genoeg voor bedanken. Je wijsheden gonzen nog regelmatig door mijn hoofd. Daarnaast heb ik er van genoten met je samen te werken. Bedankt voor al het vertrouwen en de mooie gesprekken. Je bent een mooi mens, gul, oprecht en met een scherpe blik. Ik ben dankbaar dat je mijn paranymf wil zijn.

Nathalie, ik weet dat ik altijd bij jou terecht kan. Ik ben blij dat je er als paranymf bij bent op dit voor mij belangrijke moment.

Lieve pap en mam, bedankt voor alles wat jullie me geleerd hebben. Jullie vormen een basis waar ik nog altijd op terug kan vallen.

Lieve Cleem, ik ben zo blij dat jij in mijn leven bent. Door jou kan ik het beste uit mezelf halen. Je bent mijn stevige rots waar ik op terug kan vallen. Ik kan met jou genieten van het leven en onze 3 mooie jongens.

Lieve Benter, Fosse en Sverre, lekkere schatten, kleine doerakken. Ik ben dankbaar dat ik van jullie mag genieten. Jullie zijn, alle drie op jullie eigen manier, bijzonder en soms voor mij uitdagend. Jullie vormen een spiegel, waardoor ik ook over mezelf blijf leren.

List of publications

de Boer M, Verschuur-Maes AHJ, Moelans C, van Diest PJ. Papillomatous breast lesions with atypical columnar cell features. J Clin Pathol. 2023 Apr;76(4):228-233

Koomen BM, **de Boer M**, van Dooijeweert C, van Lindert ASR, Deckers IAG, Voorham QJM, Willems SM. Nationwide differences in cytology fixation and processing methods and their impact on interlaboratory variation in PD-L1 positivity. Virchows Arch. 2023 Apr;482(4):707-720.

de Boer M, van Diest PJ. Dimorphic cells: a common feature throughout the low nuclear grade breast neoplasia spectrum. Virchows Arch. 2023 Feb;482(2):369-375

de Boer M, van Diest PJ. Blunt duct adenosis: a separate entity from columnar cell lesions? J Clin Pathol. 2022 Jan;75(1):5-9.

Koomen BM, Vreuls W, **de Boer M**, de Ruiter EJ, Hoelters J, Vink A, Willems SM. False-negative programmed death-ligand 1 immunostaining in ethanol-fixed endobronchial ultrasound-guided transbronchial needle aspiration specimens of non-small-cell lung cancer patients. Histopathology. 2021 Oct;79(4):480-490.

van den Elshout-den Uyl D, Spoto CPE, **de Boer M**, Leiner T, Leavis HL, Leguit RJ. First Report of IgG4 Related Disease Primary Presenting as Vertebral Bone Marrow Lesions. Front Immunol. 2019 Aug 13;10:1910.

Hebeda KM, Tzankov A, Boudova L, Saft L, Hasserjian RP, **de Boer M**, Fend F, Orazi A, Leguit R. Challenges in Diagnosing Myelodysplastic Syndromes in the Era of Genetic Testing: Proceedings of the 13th Workshop of the European Bone Marrow Working Group. Pathobiology. 2019;86(1):62-75.

Peltenburg B, de Keizer B, Dankbaar JW, **de Boer M**, Willems SM, Philippens MEP, Terhaard CHJ, de Bree R. Prediction of ultrasound guided fine needle aspiration cytology results by FDG PET-CT for lymph node metastases in head and neck squamous cell carcinoma patients. Acta Oncol. 2018 Dec;57(12):1687-1692.

de Boer M, Verschuur-Maes AHJ, Buerger H, Moelans CB, Steenkamer M, Savola S, van Diest PJ. Role of columnar cell lesions in breast carcinogenesis: analysis of chromosome 16 copy number changes by multiplex ligation-dependent probe amplification.Mod Pathol. 2018 Dec;31(12):1816-1833.

Hiemcke-Jiwa LS, Minnema MC, Radersma-van Loon JH, Jiwa NM, **de Boer M**, Leguit RJ, de Weger RA, Huibers MMH. The use of droplet digital PCR in liquid biopsies: A highly sensitive technique for MYD88 p.(L265P) detection in cerebrospinal fluid. Hematol Oncol. 2018 Apr;36(2):429-435.

Hiemcke-Jiwa LS, Leguit RJ, van der Veken LT, Buijs A, Leeuwis JW, **de Boer M**, Jiwa NM, Bloem AC, Petersen EJ, de Weger RA, Huibers MMH. Lymphoblastic lymphoma with a triple-hit profile: a rare butdistinct and relevant entity. Hum Patholog. 2017 May; 36:171-176.

Bürger H, **de Boer M**, van Diest PJ, Korsching E. Chromosome 16q loss – a genetic key to the understanding of breast carcinogenesis. Histol Histopathol. 2013 Mar;28(3):311-20.

de Boer M, Vink A, van de Graaf EA. Non-small cell lung carcinoma of donor origin after bilateral lung transplantation. Lung Cancer. 2012 May;76(2):259-61.