Avian Pathology

ISSN: 0307-9457 (Print) 1465-3338 (Online) Journal homepage: https://www.tandfonline.com/loi/cavp20

Major difference in clinical outcome and replication of a H3N1 avian influenza strain in young pullets and adult layers

J. J. de Wit, T. H. F. Fabri, R. J. Molenaar, R. Dijkman, N. de Bruijn & R. Bouwstra

To cite this article: J. J. de Wit, T. H. F. Fabri, R. J. Molenaar, R. Dijkman, N. de Bruijn & R. Bouwstra (2020) Major difference in clinical outcome and replication of a H3N1 avian influenza strain in young pullets and adult layers, Avian Pathology, 49:3, 286-295, DOI: 10.1080/03079457.2020.1731423

To link to this article: https://doi.org/10.1080/03079457.2020.1731423

Published online: 12 Mar 2020.

AVIAN PATHOLOGY
2020, VOL. 49, NO. 3, 286–295
https://doi.org/10.1080/03079457.2020.1731423

Taylor & Francis
Taylor & Francis Group

ORIGINAL ARTICLE

Major difference in clinical outcome and replication of a H3N1 avian influenza strain in young pullets and adult layers

J. J. de Wit [a,b], T. H. F. Fabri[a], R. J. Molenaar [a], R. Dijkman[a], N. de Bruijn[a] and R. Bouwstra[a]

[a]Royal GD, Deventer, The Netherlands; [b]Department of Farm Animal Health, Faculty of Veterinary Medicine, Utrecht University, Utrecht, The Netherlands

ABSTRACT

In this study, we investigated the pathogenicity, replication and tropism of the low pathogenic avian influenza (LPAI) strain A/chicken/Belgium/460/2019(H3N1) in adult SPF layers and young SPF males. The inoculated hens showed 58% mortality and a 100% drop in egg production in the second week post inoculation. The high viral loads in the cloacal samples coincided with the period of the positive immunohistochemistry of the oviduct, acute peritonitis and time of mortality, suggesting that the replication of H3N1 in the oviduct was a major component of the onset of clinical disease and increased level of excretion of the virus. In the inoculated young birds, the clinical signs were very mild with the exception of one bird. The results suggest that the time of replication of the virus was much shorter than in the adult layers; some of the young males did not show any proof of being infected at all. To conclude, the results of the study in young birds confirmed the intravenous pathogenicity test results but also showed that the clinical signs in adult layers were very severe. Based on the mortality without a bacterial component, complete drop of egg production and *post mortem* findings, this H3N1 strain is a moderately virulent strain, the highest category for LPAI strains. It is important to realize that if HPAI did not exist, this moderately virulent H3N1 virus would most likely to be considered as a very virulent virus.

ARTICLE HISTORY
Received 26 September 2019
Accepted 14 February 2020

KEYWORDS
Low pathogenic avian influenza; H3N1; SPF layers; pathogenesis; mortality; virulence

Introduction

Avian influenza virus strains can be divided into highly pathogenic (HP) and low pathogenic (LP) strains based on the results of the intravenous pathogenicity index (IVPI) in 6-week-old chickens, and presence of multiple basic amino acids at the cleavage site of the haemagglutinin molecule (H0) (Swayne *et al.*, 2013; OIE, 2018). Natural infection by avian influenza viruses results in a wide range of clinical outcomes which are dependent on virus strain, host species, host age, host immunity, co-infections with other primary or secondary pathogens, and environmental factors. Outbreaks of highly pathogenic avian influenza (HPAI) strains were all of the H5 and H7 subtype and have been responsible for dramatic losses in the poultry industry, especially since 1996 (Brown *et al.*, 2017; Sims & Brown, 2017). HPAI strains are highly virulent for chickens and closely related gallinaceous birds and cause a severe, fatal, peracute systemic disease with high mortality. Low pathogenic avian influenza (LPAI) viruses of any haemagglutinin (HA) or neuraminidase (NA) subtype can be categorized into three clinical groups: (1) avirulent, (2) mildly virulent, and (3) moderately virulent (Swayne *et al.*, 2013).

The avirulent category are LPAI strains that cause subclinical infections. Many primary introductions of AI strains from wild birds into chickens result in subclinical infections, usually they are detected by routine serological monitoring (Bouwstra *et al.*, 2017).

The mildly virulent group of strains results from infection by LPAI virus producing low mortality and mild respiratory disease or drops in egg production. Mortality is usually less than 5%, and is typically in older birds (Swayne *et al.*, 2013). In the presence of other primary or secondary pathogens, immunosuppression or other complicating factors, these infections can still be very detrimental (Landman *et al.*, 2019).

Moderately virulent LPAI strains are strains that are able to cause a higher level of mortality that varies but ranges from 5% to 97% with the highest mortality occurring in young birds, reproductively active hens, or severely stressed birds (Johnson & Maxfield, 1976; Capua *et al.*, 2000; Kim *et al.*, 2006; Swayne *et al.*, 2013; Landman *et al.*, 2019).

In May 2019, a low pathogenic H3N1 avian influenza virus was isolated from a Belgian layer flock of 36 weeks of age with highly increased mortality and a very severe drop in egg production. At *post mortem* examination of 12 hens, egg peritonitis was a common finding from which *Escherichia coli* (*E. coli*) was detected in high amounts. Testing by PCR was positive for AI (matrix gene, H3 and N1). The PCR tests for infectious bronchitis virus (IBV), avian metapneumovirus (AMPV), infectious laryngotracheitis virus (ILTV), *Mycoplasma*

CONTACT J.J. de Wit j.d.wit@gdanimalhealth.com, j.d.wit@gddiergezondheid.nl

gallisepticum (Mg), *Mycoplasma synoviae* (Ms), and infectious Coryza were negative on tracheal and cloacal samples. Two H3N1 strains from neighbouring farms had been tested in the intravenous pathogenicity test (IVPI) and showed IVPI indexes of 0.13 and 0.28 (personal communication Dr Mieke Steensel, Sciensano, Brussels, Belgium), meaning both strains caused only mild clinical signs in the infected young chickens. In this H3N1 outbreak affecting 82 flocks of chickens, turkeys and ostriches. clinical signs in the laying birds were very severe in contrast to mild signs in young flocks (personal communication Dr Philippe Gelaude, Dierengezondheidszorg Vlaanderen, Belgium). Because of the major difference between the IVPI index in the young birds and the severe clinical signs that had been reported in Belgian laying birds, and to be able to implement effective measures based on knowledge of the virus to prevent spread to The Netherlands, it was decided to infect SPF laying chickens with this H3N1 strain. After obtaining the results in the adult layers, an experiment using young birds was performed as well. This report shows the results of this bird experiment using 34-week-old SPF laying hens and 4-week-old males including clinical signs, egg production, *post mortem* examination results, immunohistochemistry (IHC) and RT–PCR. Whole genome sequencing was performed as well.

Materials and methods

Virus isolation

A/chicken/Belgium/460/2019(H3N1) was isolated from both tracheal and cloacal swabs from 36-week-old layers that showed a severe drop in egg production and fast increasing mortality. At *post mortem* examination, tracheitis (three out of 12 birds) and peritonitis (10 out of 12 birds) were detected. The flock had already been found positive for H3N1 by the Belgian authorities. The bacteriological examination of the liver and spleen showed *E. coli*. Testing by PCR was negative for Mg, Ms, *Avibacterium paragallinarum*, IBV, NDV, AMPV and ILTV. The avian influenza virus was grown in the allantoic cavity of 8-day-old SPF embryonated eggs (Landman *et al.*, 2019). The first passage was already PCR positive for avian influenza virus from both tracheal and cloacal swabs. A second passage was performed, titrated and used for inoculation of the hens. The inoculate used for the experiments was free of bacteria including Mg, Ms, *Avibacterium paragallinarum*, and free of IBV, AMPV, NDV and ILTV.

The H3N1 genotype of the avian influenza strain was confirmed by whole genome sequencing.

RNA extraction and matrix gene PCR

RNA was extracted from the allantoic fluid using the High Pure RNA isolation kit (Roche Applied Science, Penzberg, Germany), according to the manufacturer's instructions. A generic PCR targeting the Influenza A matrix gene used for the detection of Influenza A virus was performed as described by Ward *et al.* (2004) with some modifications. For quantification of the number of viral copies a standard curve ranging from 10^0 to 10^9 viral copies/ml was constructed using influenza strain A/chicken/Belgium/460/2019(H3N1).

Whole genome sequencing

The extracted RNA was used for the preparation of total RNA libraries using the Nextera XT library preparation kit (Illumina, San Diego, CA, USA). 300-cycle sequence reads (2 × 150-bp paired-end) were generated using the Illumina NovaSeq 6000 system. Initial quality assessment was based on data passing the Illumina chastity filtering. Subsequently, reads containing PhiX control signal were removed using an in-house filtering protocol (Baseclear, Leiden, the Netherlands). In addition, reads containing (partial) adapters were clipped (up to a minimum read length of 50 bp). The second quality assessment was based on the remaining reads using the FASTQC quality control tool version 0.11.5. De-multiplexed and adapter clipped reads were analysed using the CLC Genomics Workbench version 12.0.3. *De novo* assembly was performed using the slow mapping mode with minimum expected contig size of 300 nucleotides. Max paired read distance allowed was 500 nucleotides. The parameters for mapping back the reads were: mismatch cost = 2; insertion cost = 3; deletion cost = 3; length fraction = 0.5 and similarity fraction = 0.8. Following *de novo* assembly, contigs were mapped to a database restricted to Influenza A virus and the NCBI ORFfinder tool was used to search for open reading frames and potential protein encoding segments. Non-coding regions were trimmed off and the PB2, PB1, PA, HA, NP, NA, M and NS segments were annotated using the SMART BLAST option.

Design of experiment 1: 34-week-old SPF layers

Thirty-six 34-week-old specific pathogen free (SPF) layer-type chicks were housed in two negative pressure high-efficiency particle air filtered isolators of 2.14 m^2 each at the facilities of Royal GD. SPF birds were used to exclude the presence of other pathogens interfering in the outcome of the experiment. One-third of the floor of the isolator was covered with bedding. Each isolator had a nest box and perches. Feed and drinking water were supplied *ad libitum*. After an acclimatization period of 7 days, the hens were inoculated with $10^{6.7}$ EID_{50} of A/chicken/Belgium/460/2019(H3N1) by eye-drop application.

At 2, 4 and 7 days post inoculation (d.p.i.) two birds of each isolator were taken out and euthanized by inhalation of a O_2–CO_2 gas mixture with subsequent

bleeding. A full *post mortem* examination was performed and samples were taken from trachea, oviduct (magnum and uterus), duodenum, pancreas, and kidney for RT–PCR, histopathological investigation, and IHC. The same samples were collected from representatives of sick or dead birds during the study and at the end of the study. In the case that a bird had to be euthanized according to animal welfare reasons, the bird was euthanized by an intravenous injection with 20% sodium-pentobarbital (AST Farma, Oudewater, the Netherlands). At 21 d.p.i., all remaining birds were euthanized and bled for serum collection. The number of eggs was recorded daily for each isolator from 5 days before the inoculation till the end of the experiment.

Design of experiment 2: 4-week-old SPF males

Two groups of fifteen 4-week-old SPF male layer-type chicks were housed in two negative pressure high-efficiency particle air filtered isolators of 2.14 m^2 each. One-third of the floor of the isolator was covered with bedding. Feed and drinking water were supplied *ad libitum*. After an acclimatization period of 7 days, the young males of one isolator were inoculated with $10^{6.7}$ EID_{50} of A/chicken/Belgium/460/2019(H3N1) by eye-drop application. The birds of the second isolator served as negative controls.

Cloacal and tracheal swabs were taken from each bird of the inoculated group at 7, 14 and 21 d.p.i. for PCR testing. The same was done at 21 d.p.i. for the negative control group. At 21 d.p.i. all birds of both groups were euthanized by inhalation of a O_2–CO_2 gas mixture with subsequent bleeding, and *post mortem* examination was performed. Samples from trachea, duodenum and caecal tonsil were collected for IHC and histology, blood was collected for antibody testing by ELISA and HI test.

Immunohistochemistry

The presence of Influenza A virus antigen in the trachea, duodenum, pancreas, oviduct, kidney and caecal tonsils was investigated using IHC. After fixation for at least 24 h in buffered 10% formalin followed by dehydration in absolute ethanol and embedding in paraffin wax, sections were cut at 4 µm and mounted on glass slides. Endogenous peroxidase activity was blocked by incubation with 1% H_2O_2 containing 0.1% NaN_3 for 20 min at room temperature, and subsequent boiling in Tris (0.01 M) EDTA (0.001 M), pH 9.0 for 10 min. The binding of Fc-receptors was blocked by incubation with 10% foetal bovine serum for 20 min at room temperature. The immunostaining of influenza A virus-positive cells was performed using 1:1000 diluted anti-influenza A virus nucleoprotein monoclonal antibody (Meridian Life Science, Memphis, TN, USA) in Normal Antibody Diluent (Klinipath, Duiven, The Netherlands) for 30 min at room temperature. After three subsequent wash steps with phosphate-buffered saline, the sections were treated with anti-mouse Dako EnVision+ (Dako UK Ltd, Cambridgeshire, UK) for 30 min at room temperature. Again, sections were washed three times with phosphate-buffered saline and then treated with DAB+ (Dako UK Ltd) for 5 min at room temperature. Finally, the sections were counter-stained using haematoxylin. Sections incubated in the absence of primary antibody were taken along as negative controls.

ELISA

Blood samples were tested by ELISA for antibodies against avian influenza using the IDEXX AI MultiScreen Ab test (IDEXX Europe B.V., Hoofddorp, Netherlands) according the instructions of the producer.

HI-test H3N1

The haemagglutination inhibition (HI) test using the homologous H3N1 antigen was performed as stipulated by the OIE manual of diagnostic tests and vaccines for terrestrial animals 2018 with 8 haemagglutinating units (HAU) instead of 4 HAU (OIE, 2018). Serum dilutions ranged from 1:2 to, and including, 1:1024. All HI titres were expressed as $\log_2$ of the reciprocal of the highest serum dilution showing complete haemagglutination inhibition.

Ethical statement

All experiments were conducted with the formal approval of the local animal welfare committee and registered according to Dutch legislation.

Results

Whole genome sequencing

From the whole genome sequencing the full genome sequence of Influenza A strain A/chicken/Belgium/460/2019(H3N1) (MN435593-MN435600) was obtained. Annotation using the Orffinder and Smartblast tools demonstrated that segment 1 (PB2) was 2280 nucleotides, segment 2 (PB1) was 2274, segment 3 (PA) was 2151, segment 4 (HA) was 1701, segment 5 (NP) was 1497, segment 6 (NA) was 1338, segment 7 (M) was 982 and segment 8 (NS) was 838 nucleotides in size. Comparison of the obtained sequences to known Influenza A sequences showed that all segments were of avian origin (Table 1). Sequence similarity was the highest with the recent Belgian isolate A/Gallus gallus/Belgium/3497_0001/2019(H3N1) that originates from the same outbreak, showing a common ancestry. The percentage similarity of the different viral

Table 1. Comparison of the whole genome sequence (MN435593-MN435600) of avian influenza strain A/chicken/Belgium/460/2019(H3N1) with known Influenza A sequences deposited in GenBank.

Influenza challenge strain A/chicken/Belgium/460/2019(H3N1)		
Viral segment	**Similarity with H3N1 from Belgium**	**Percentage similarity**
PB2	A/Gallus gallus/Belgium/3497_0001/2019 (H3N1) (MN006987)	99.90%
PB1	A/Gallus gallus/Belgium/3497_0001/2019 (H3N1) (MN006986)	99.80%
PA	A/Gallus gallus/Belgium/3497_0001/2019 (H3N1) (MN006985)	99.80%
HA	A/Gallus gallus/Belgium/3497_0001/2019 (H3N1) (MN006984)	99.70%
NP	A/Gallus gallus/Belgium/3497_0001/2019 (H3N1) (MN006983)	99.90%
NA	A/Gallus gallus/Belgium/3497_0001/2019 (H3N1) (MN006982)	99.80%
M	A/Gallus gallus/Belgium/3497_0001/2019 (H3N1) (MN006981)	99.90%
NS	A/Gallus gallus/Belgium/3497_0001/2019 (H3N1) (MN006980)	99.80%
Viral segment	**Strain with highest similarity (Global)**	**Percentage similarity**
PB2	A/tufted duck/Georgia/1/2012(H2N3) (MF147767)	97.64%
PB1	A/duck/Hubei/ZYSYG3/2015(H6N2) (KY415829)	98.37%
PA	A/mallard duck/Netherlands/56/2015 (H3N2) (MF755261)	98.59%
HA	A/Mallard/Netherlands/37/2015(H3N8) (MK414733)	98.21%
NP	A/duck/Mongolia/543/2015(H4N6) (LC121413)	98.30%
NA	A/mallard duck/Georgia/7/2015(H6N1) (MF694086)	97.94%
M	A/mallard/Netherlands/89/2017(H4N6) (MK192396)	98.81%
NS	A/mallard duck/Netherlands/31/2013 (H10N7) (KX979173)	99.19%
Viral segment	**Strain with highest similarity (Europe)**	**Percentage similarity**
PB2	A/mallard duck/Netherlands/56/2015 (H3N2) (MF755242)	96.99%
PB1	A/mallard duck/Netherlands/26/2010 (H4N6) (KX979822)	97.85%
PA	A/mallard duck/Netherlands/56/2015 (H3N2) (MF755261)	98.59%
HA	A/Mallard/Netherlands/37/2015(H3N8) (MK414733)	98.21%
NP	A/mallard duck/Netherlands/8/1999(H1N1) (MF682691)	96.88%
NA	A/Mallard/Sweden/816/2014(H1N1) (KY320434)	97.36%
M	A/mallard/Netherlands/89/2017(H4N6) (MK192396)	98.81%
NS	A/mallard duck/Netherlands/31/2013 (H10N7) (KX979173)	99.19%

segments compared to that strain varied from 99.70% to 99.90%. The highest similarity of the eight segments of this chicken isolate with Influenza A sequences collected globally and deposited in GenBank was, for each segment, an isolate from a duck species.

Experiment in 34-week-old SPF layers

Clinical signs and egg production

No clinical signs were seen in any hen including the 12 birds (of 36) that were removed at 2, 4 and 7 for routine sampling during the first week, with the exception of one hen that was found dead at 7 d.p.i. (selected for routine sampling) and two other hens that became depressed with ruffled feathers at the same day (Figure 1).

At 8 d.p.i. another four birds showed depression and ruffled feathering. At 9 and 10 d.p.i., the peak in mortality (including euthanizing for animal welfare reasons) appeared, at 13 d.p.i. another bird died. In the second week post inoculation, 14 of 24 hens died (58%). The ten birds that survived had not shown clinical signs at any day. The egg production was stable at about 80% till 8 d.p.i. when the production of the remaining birds collapsed till 9% at 10 d.p.i. and 0% at 13 d.p.i. The egg production stayed at 0% till the end of this experiment at 21 d.p.i.

Gross pathology clinically healthy birds

Post mortem findings in clinically healthy birds that were sacrificed at 2 d.p.i. ($n = 4$) were unremarkable and all of them had an egg in the oviduct. At 4 d.p.i., one out of four had acute regression of the ovary, two others had mild splenomegaly and two of the four hens had an egg in the oviduct. At 7 d.p.i., ($n = 3$) findings were unremarkable and two hens had an egg in the oviduct.

At the end of the trial (21 d.p.i.) the remaining 10 hens that had had not shown any clinical signs during the study were sacrificed. Three of them had regression of the ovary and marked fibrinous to caseous exudate in the coelomic cavity (Figure 2). The other seven hens had a normal productive ovary but no egg in the oviduct and five also had fibrinous to caseous exudate in the coelomic cavity.

Gross pathology diseased and dead birds

Fifteen hens either died or were euthanized for animal welfare reasons after they developed severe clinical signs. At 7 d.p.i. one hen with an ovary in regression had acute fibrinous peritonitis.

At 9 d.p.i. seven hens had acute fibrinous peritonitis as well slightly opaque greyish fluid with fibrin in the coelomic cavity. Three hens had albumen-like material in the lumen of the distended oviduct (Figure 3). Two of these seven hens had died before removal from the experiment and these two had dark skeletal muscles and a pale spleen. At 10 d.p.i., *post mortem* examination was done on three out of the six hens that were taken out of the experiment. All three had an oviduct that was distended by yellow caseous material and they had yellow egg-yolk-like fluid in the coelomic cavity mixed with flakes of fibrinous material that also covered the mesenterium and the ovarium. One of the three hens also had an egg in the oviduct. At 13 d.p.i., one hen that died had acute regression of the ovary and acute fibrinous peritonitis. Bacteriology of the bone marrow of the four hens from 10 and 13 d.p.i. remained negative.

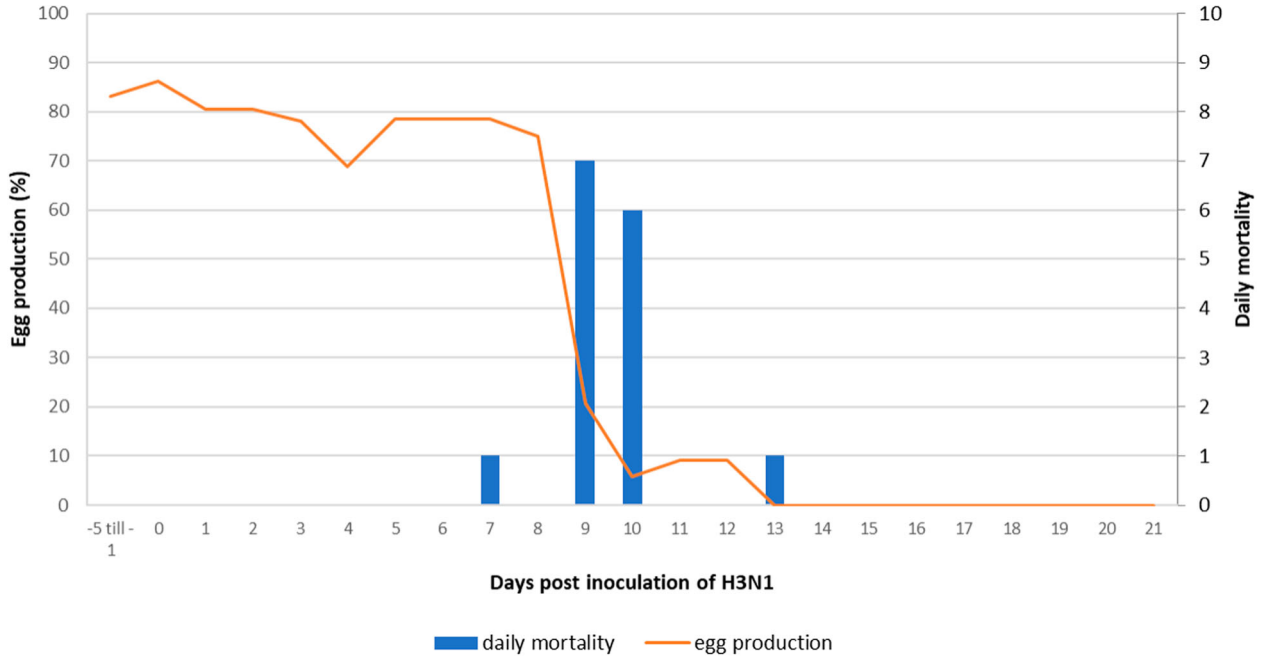

Figure 1. Daily egg production and daily mortality post inoculation of avian influenza strain A/chicken/Belgium/460/2019 in 34-week-old SPF laying hens.

RT–PCR layers

The results of the RT–PCR are listed in Table 2. At 4 d.p.i., the first bird was found positive in both tracheal and cloacal swabs. At 7 d.p.i., four birds were tested, all tracheal swabs were positive for avian influenza virus RNA whereas two cloacal swabs were positive. All sampled birds at 9, 10 and 13 d.p.i. were positive in both samples. At 21 d.p.i., tracheal swabs from

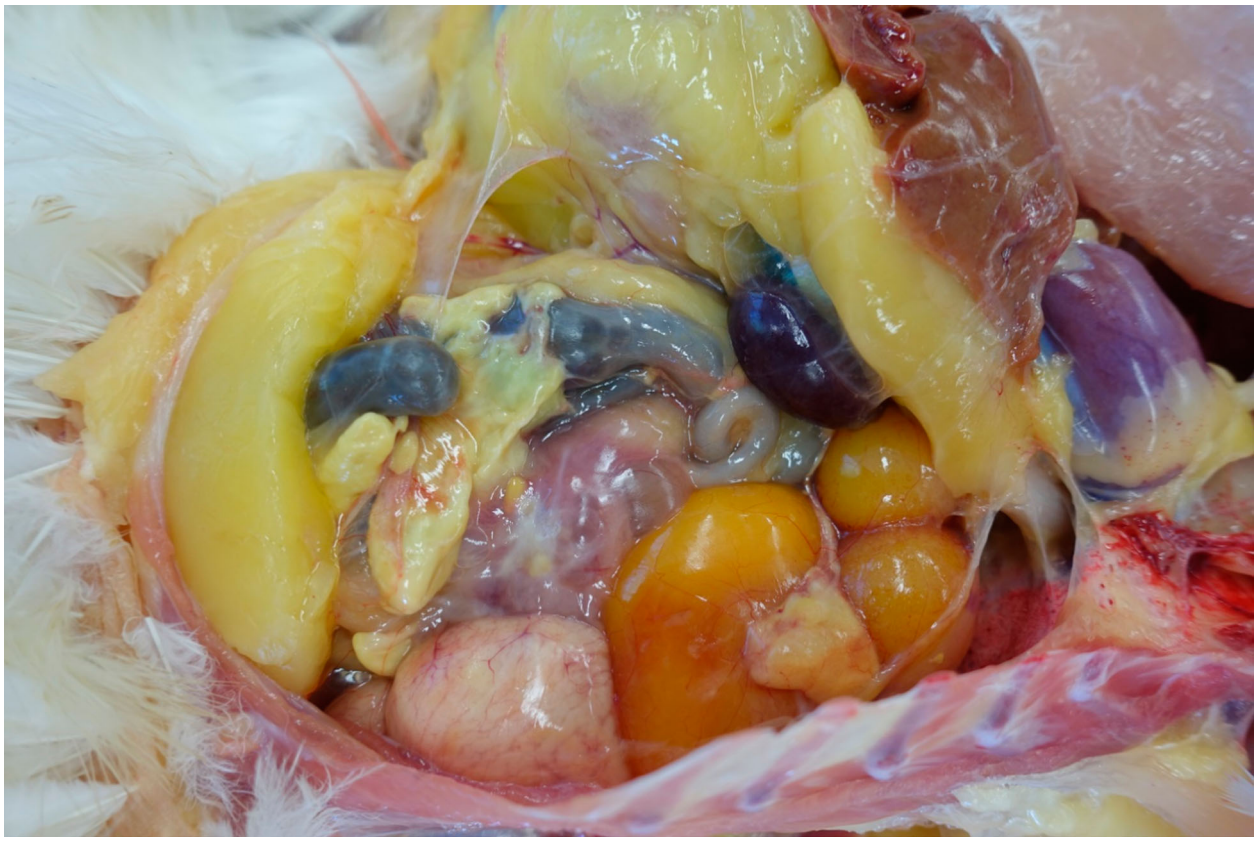

Figure 2. Surviving hen, sacrificed at 21 d.p.i. with avian influenza strain A/chicken/Belgium/460/2019(H3N1). Lateral view of the body cavity after lifting the sternum and liver, showing the fibrinous to caseous exudate in the coelomic cavity, often adhering to serosal surfaces.

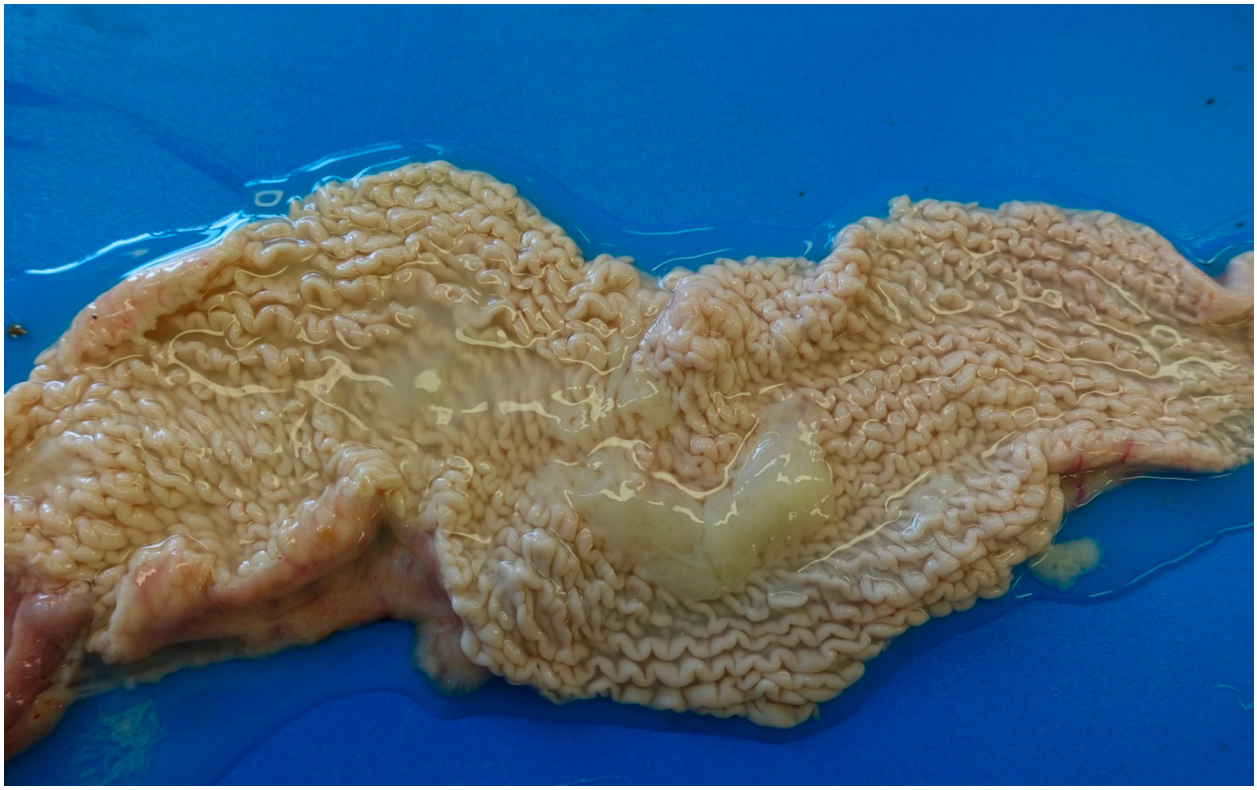

Figure 3. Oviduct from a clinically ill hen at 9 d.p.i. with avian influenza strain A/chicken/Belgium/460/2019(H3N1) with albumen-like material in the lumen of the distended oviduct.

six of the remaining 10 birds were still positive in the PCR compared to nine for the cloacal swabs. The viral concentration for the positive samples varied from $10^{1.9}$ to $10^{8.1}$ viral copies/gram. The average viral concentration for the positive tracheal swabs was $10^{3.6}$ viral copies/gram, and the average of the cloacal swabs was $10^{4.2}$ viral copies/gram. The highest concentrations were found in the samples from 9 to 13 d.p.i., the average value was $10^{4.6}$ viral copies/gram for the tracheal swabs and $10^{6.1}$ viral copies/gram for the cloacal swabs.

ELISA and HI

The first positive results in the ELISA and HI-test were detected at 9 d.p.i. (Table 2). At 21 d.p.i. all birds were strongly positive in both tests, and the HI titres of these birds varied from 7 to 9 $\log_2$.

IHC and histology

Immunoreactivity against influenza virus was detected in the oviducts of hens sampled at 9 and 10 d.p.i. (Table 3). In these hens both sampled pieces of the

Table 2. Results of RT-PCR, ELISA and HI tests in samples from 34-week-old SPF laying hens and 4-week-old SPF males after inoculation with A/chicken/Belgium/460/2019(H3N1).

	Number of positive samples of the total number of samples at days post inoculation									
Test and organ	0	2	4	5[c]	7	9[c]	10[c]	13[c]	14	21
34-week-old SPF laying hens										
RT-PCR trachea (mean viral load[d])	–	0/4	1/4 ($10^{1.9}$)	–	4/4 ($10^{2.9}$)	4/4 ($10^{5.0}$)	3/3 ($10^{4.4}$)	100 ($10^{4.1}$)	–	6/10 ($10^{2.9}$)
RT-PCR cloaca (mean viral load)	–	0/4	1/4 ($10^{2.9}$)	–	2/4 ($10^{2.9}$)	4/4 ($10^{5.3}$)	3/3 ($10^{6.3}$)	100 ($10^{8.1}$)	–	9/10 ($10^{2.9}$)
ELISA		–	0/3	–	0/4	3/5 [a]	5/5 [b]	–	–	10/10
HI H3N1 (mean titre)		–	0/3	–	0/4 (<1)	1/5 (1.4)	1/5 (0.6)	–	–	10/10 (8.0)
4-week-old SPF males inoculated with H3N1										
RT-PCR trachea (mean viral load)				1/1 ($10^{1.3}$)	3/14 ($10^{2.9}$)				0/14	0/14
RT-PCR cloaca (mean viral load)				1/1 ($10^{3.5}$)	4/14 ($10^{2.9}$)				0/14	0/14
ELISA									–	6/14
HI H3N1 (mean titre)									–	5/14 (2.4)
4-week-old SPF males (not inoculated)										
RT-PCR trachea (mean viral load)									–	0/15
RT-PCR cloaca (mean viral load)									–	0/15
ELISA									–	0/15
HI H3N1 (mean titre)									–	0/15 (<1)

[a]One additional bird was tested in the ELISA and HI tests.
[b]Two additional birds were tested in the ELISA and HI tests.
[c]Bird was found dead or euthanized for animal welfare reasons.
[d]Mean viral load of the positive samples in viral copies/gram.

Table 3. Results of IHC in samples from various organs of 34-week-old SPF laying hens after inoculation with H3N1.

	Number of positive organs in the IHC for avian influenza virus				
Days post inoculation	Trachea	Oviduct	Duodenum	Pancreas	Kidney
2	0/4	0/4	0/4	0/4	0/4
4	0/4	0/4	0/4	0/4	0/4
7	0/4	0/4	0/4	0/4	0/4
9	0/4	4/4	0/4	0/4	0/3
10	0/3	2/2	0/3	0/3	0/3
21	0/2	0/10	0/2	0/2	0/2

oviduct, both magnum and uterus, had immunoreactivity in low to moderate numbers of cells lining the tubular glands (Figure 4). All samples from the trachea, duodenum, pancreas and kidney were negative in IHC. Analysis of HE-stained tissue sections of oviduct from hens sacrificed at 21 d.p.i. showed multifocal moderate lymphoplasmacytic infiltrates in the mucosa of all sampled tissues. Infiltrates were not associated with any tissue damage and the overall histologic appearance of the tissue was that of a normal oviduct of a productive mature hen.

Experiment in 4-week-old SPF males

Clinical signs

The birds of the negative control groups showed no clinical signs during the experiment. In the inoculated group, no clinical signs were seen till 7 d.p.i. except for one bird that showed ruffled feathering and severe depression at 5 d.p.i. and was taken out of the study for animal welfare reasons. In the period of 7–9 d.p.i., in total four birds showed some depression and ruffled feathers during 1 or 2 days and recovered completely. No other abnormalities were observed till the end of the experiment at 21 d.p.i.

Gross pathology

No abnormalities were noticed in the 15 negative control birds. The bird that had been euthanized at 5 d.p.i. had mild splenomegaly at *post mortem* examination but was otherwise unremarkable. In the fourteen surviving birds no abnormalities were noted, except for four birds that had hyperaemic caecal tonsils.

RT–PCR

In total, a detectable level of avian influenza virus RNA was found in swabs of only five out of fifteen young males that had been inoculated with $10^{6.7}$ EID_{50} of H3N1 (Table 2). One of these birds was the bird that showed severe depression at 5 d.p.i. (PCR positive on the swabs from the trachea and caecal tonsil). The four other PCR positive birds were all at 7 d.p.i. (3× both tracheal and cloacal swab positive, the fourth bird was only positive in the cloacal swab). Viral

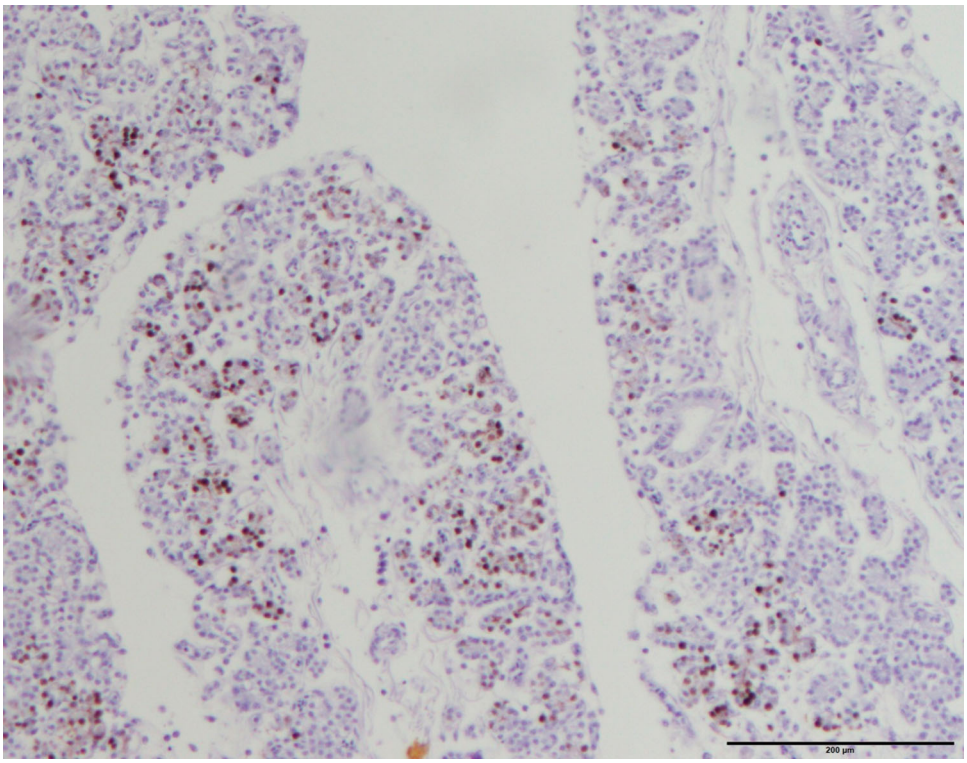

Figure 4. Magnum of a hen with clinical disease at 10 d.p.i. with H3N1 showing immunoreactivity against influenza virus (brown staining) in cells lining the tubular glands.

loads that were detected ranged from $10^{1.3}$ to $10^{4.1}$ viral copies/gram. All samples from 14 and 21 d.p.i. remained negative. The other 10 birds remained negative in the RT–PCR at all three sampling days.

ELISA and HI

All results of the negative control birds were negative. The four birds that had become PCR-positive and survived until the end of the study all became ELISA- and HI-positive at 21 d.p.i. The ELISA results of these four birds were strongly positive, the HI titres of these birds varied from 5 to 7 $\log_2$, the mean titre of all birds was 2.4 $\log_2$.

Eight of the 10 birds that had remained negative in the PCR at 7, 14 and 21 d.p.i. also remained negative in both antibody tests, one bird became ELISA positive and HI negative, the other bird became positive in both antibody tests.

IHC and histology

All samples from 21 d.p.i of the trachea, duodenum and caecal tonsils were negative in the IHC. Analysis of haematoxylin & eosin-stained tissue sections of the same samples showed no relevant abnormalities.

Discussion

In this study, we investigated the pathogenicity, replication and tropism of the low pathogenic A/chicken/Belgium/460/2019(H3N1) in laying SPF layers and young SPF males. This avian influenza virus strain was isolated in May 2019 from a Belgian free range layer flock of 36 weeks of age with highly increased mortality and a very severe drop in egg production. A common *post mortem* finding in 12 examined hens was acute peritonitis from which abundant *E. coli* was cultured. The PCR tests for IBV, AMPV, ILTV, Mg, Ms and *Avibacterium paragallinarum* were negative on tracheal and cloacal samples.

Comparison of the results of the whole genome sequencing of H3N1 with the available sequences in GenBank showed, for each of the eight segments, a highest similarity with Influenza A sequences from wild ducks. This shows the avian origin of the virus, and outdoor housing is a well-known risk factor for primary introductions of LPAI infections (Bouwstra *et al.*, 2017).

Replication and tropism of H3N1 was investigated using RT–PCR and IHC. The difference in replication in the adult layers and in the young males was remarkable. In the 34-week-old layers, the first positive results were detected by PCR at 4 d.p.i. in both trachea and cloaca. RT–PCR remained positive on samples up to 21 d.p.i. when nine out of 10 and six out of 10 of the cloacal and tracheal swabs, respectively, were still positive. Viral loads were comparable for both types of samples during the first days of positivity. At 10 and 13 d.p.i. the viral loads were much higher in the cloacal swabs compared to the tracheal swabs. The IHC was negative on trachea, duodenum, pancreas and kidney during the whole experiment. There was positive immunostaining at 9 and 10 dpi in the oviduct (magnum and uterus). Comparing the results of the RT–PCR and IHC, RT–PCR seemed to be more sensitive. The high viral loads in the cloacal samples coincided with the period of the positive IHC of the oviduct, acute peritonitis and time of mortality, suggesting that the replication of H3N1 in the oviduct is a major component of the onset of clinical disease and increased level of excretion of the virus.

In the young birds, no positive IHC on trachea, duodenum or caecal tonsils nor high viral loads on tracheal or cloacal swabs were detected; on the contrary, most birds remained negative in all samples including the ELISA and HI test. The birds that got infected after the ocular inoculation of $10^{6.7}$ EID_{50} of H3N1, RT–PCR were only positive at 7 d.p.i. and not at 14 d.p.i. and 21 d.p.i., suggesting that the time of replication of the virus was much shorter in the young males than in the adult layers. The finding that most young males remained negative for 3 weeks supports the limited replication as these birds apparently were not infected either by the inoculation, or by the excretion of the birds around 7 d.p.i. Apparently, the transmission was very low. The big difference in virus excretion between the layers and young birds might also explain why the virus did not spread from Belgium to The Netherlands despite the intensive trade contacts. Bird transport is mainly restricted to younger birds and hatching eggs. Based on the results of this study, the younger birds are less sensitive for an effective infection.

The clinical signs in the young males that got infected were very mild with the exception of one bird that died at 5 d.p.i. These results are in accordance with the field observations in broiler flocks and the IVPI results of 0.13 that have been reported for this strain and confirm the official low pathogenicity of this strain in young birds. However, the results of the infection of the adult laying hens were strikingly similar with the field findings in the layers and breeders. The mortality of 58% and egg drop of 100% in the second week post inoculation, and *post mortem* findings of acute fibrinous peritonitis after the experimental infection in SPF birds, showed that H3N1 can cause the findings in the field by itself, without the presence of a bacterial and/or viral co-infection.

The appearance of the acute peritonitis and salpingitis coincided with the time that the IHC was positive on the oviduct samples. For the LPAI viruses, replication is usually limited to the respiratory or intestinal tracts (Swayne *et al.*, 2013). In those cases, illness or death is most often from respiratory damage, especially if accompanied by secondary bacterial infections. This

is especially the case when co-infections occur as is seen in the areas with H9N2 and IBV infections (Perez & De Wit, 2017). Some LPAI strains have the capacity to spread systematically, replicating and causing damage in the kidney (Shinya *et al.*, 1995; Ziegler *et al.*, 1999; Mosleh *et al.*, 2009), pancreatic acinar epithelium (Shinya *et al.*, 1995), oviduct (Ziegler *et al.*, 1999; Bonfante *et al.*, 2018), and other organs with epithelial cells having trypsin-like enzymes (Swayne *et al.*, 2013). In several reports, the systemic effects were seen after intravenous application only and not after a mucosal application (Shalaby *et al.*, 1994; Swayne & Slemons, 1994).

The pathological findings of the H3N1 infected hens are similar to the findings of Ziegler *et al.* (1999) who found salpingitis, and fluid, fibrinous, and egg yolk material in the abdomen in the LP H7N2 infected hens. Both mortality and egg drop in these flocks were moderate (less than 4% for both parameters). Bonfante *et al.* (2018) infected hens by the oro-nasal route with H9N2 A/chicken/Israel/1163/2011 and found a drop in egg production of 49% at 2 weeks post inoculation. No mortality was reported but at 80 d.p.i., non-laying birds showed egg yolk peritonitis, and the histopathological analyses revealed profound alteration of the infundibulum architecture, while the rest of the oviduct and ovary appeared normal. IHC on oviduct samples taken in the acute stage of the infection showed that the H9N2 strain replicated in high levels in the infundibulum, magnum and uterus. They concluded this H9N2 virus was a primary pathogen in layer hens, and that its replication in the infundibulum was responsible for acute and chronic lesions that limits the effective functionality of the oviduct. In our study, we did not collect samples of the infundibulum, only of the magnum and uterus. Regarding the H3N1 IHC findings and the similarity of the pathological findings in the hens that did not die, it might be that H3N1 affected the infundibulum in the same way as the H9N2 strain of Bonfante *et al.* (2018).

The findings of the present experiments with H3N1 also have diagnostic implications. The results show that both tracheal and cloacal swabs are suitable materials for testing by RT–PCR. For the chronic phase of the infection in layers, cloacal samples might be more suitable. In both experiments, both ELISA and the HI-test became positive to the same extent although the ELISA seemed to become positive some days earlier (experiment 1). Maybe the most relevant finding was the required sample size for layers compared to young birds. Although no transmission experiments were performed, the data suggest that the sample size in the infected layers needs to be less extensive as in young birds. In young birds, the percentage of infected birds can be much lower than in adult birds, requiring a bigger sample size to be able to detect or to exclude an infection.

To conclude, the results indicate that a single infection with LPAI A/chicken/Belgium/H3N1/460/2019 causes little damage in young males but severe clinical disease in adult layers which resulted in high mortality and production losses. Based on the 58% mortality in the second week post inoculation without a bacterial component, complete drop of egg production and *post mortem* findings that confirm the findings in the field, this H3N1 strain is a moderately virulent strain, the highest category for LP strains (Swayne *et al.*, 2013). It is important to realize that if HPAI did not exist, this moderately virulent H3N1 virus would most likely to be considered as a very virulent virus.

Acknowledgements

We would like to thank Irene Jorna and John Fundter for their help at Royal GD.

Disclosure statement

No potential conflict of interest was reported by the author(s).

Funding

The authors would like to acknowledge the funding by AVINED [H3N1] and the Dutch Ministry of Agriculture, Nature and Food Quality [H3N1].

ORCID

J. J. de Wit http://orcid.org/0000-0002-3459-1000
R. J. Molenaar http://orcid.org/0000-0003-0336-1226

References

Bonfante, F., Mazzetto, E., Zanardello, C., Fortin, A., Gobbo, F., Maniero, S., Bigolaro, M., Davidson, I., Haddas, R., Cattoli, G. & Terregino, C. (2018). A G1-lineage H9N2 virus with oviduct tropism causes chronic pathological changes in the infundibulum and a long-lasting drop in egg production. *Veterinary Research*, 49, 83.

Bouwstra, R., Gonzales, J.L., de Wit, S., Stahl, J., Fouchier, R.A.M. & Elbers, A.R.W. (2017). Risk for low pathogenicity avian influenza virus on poultry farms, the Netherlands, 2007–2013. *Emerging Infectious Diseases*, 23, 1510–1516.

Brown, I.H., Abolnik, C., Garcia-Garcia, J., McCullough, S., Swayne, D.E. & Cattoli, G. (2017). High-pathogenicity avian influenza outbreaks since 2008, excluding multi-continental panzootic of H5 Goose/Guangdong-lineage viruses. In D.E. Swayne (Ed.), *Avian influenza* (2nd ed., pp. 248–270). Singapore: Wiley Blackwell.

Capua, I., Mutinelli, F., Marangon, S. & Alexander, D.J. (2000). H7N1 avian influenza in Italy (1999 to 2000) in intensively reared chickens and turkeys. *Avian Pathology*, 29, 537–543.

Johnson, D.C. & Maxfield, B.G. (1976). An occurrence of avian influenza virus infection in laying chickens. *Avian Diseases*, 20, 422–424.

Kim, J.A., Cho, S.H., Kim, H.S. & Seo, S.H. (2006). H9N2 influenza viruses isolated from poultry in Korean live bird markets continuously evolve and cause the severe clinical signs in layers. *Veterinary Microbiology*, 118, 169–176.

Landman, W.J.M., Germeraad, E.A. & Kense, M.J. (2019). An avian influenza virus H6N1 outbreak in commercial layers: case report and reproduction of the disease. *Avian Pathology*, 48, 98–110.

Mosleh, N., Dadras, H. & Mohammadi, A. (2009). Molecular quantitation of H9N2 avian influenza virus in various organs of broiler chickens using TaqMan real time PCR. *Journal of Molecular and Genetic Medicine*, 3, 152–157.

OIE. (2018). Chapter 3.3.4. Avian influenza (infection with avian influenza viruses). In *Manual of diagnostic tests and vaccines for terrestrial animals 2018* (pp. 821–843).

Perez, D.R. & De Wit, J.J. (2017). Low-pathogenicity avian influenza. In D.E. Swayne (Ed.), *Animal influenza* (2nd ed., pp. 271–301). Ames, IA: Wiley.

Shalaby, A.A., Slemons, R.D. & Swayne, D.E. (1994). Pathological studies of A/chicken/Alabama/7395/75 (H4N8) influenza virus in specific-pathogen-free laying hens. *Avian Diseases*, 38, 22–32.

Shinya, K., Awakura, T., Shimada, A., Silvano, F.D., Umemura, T. & Otsuki, K. (1995). Pathogenesis of pancreatic atrophy by avian influenza A virus infection. *Avian Pathology*, 24, 623–632.

Sims, L.D. & Brown, I.H. (2017). Multi-continental panzootic of H5 highly pathogenic avian influenza (1996–2015). In D.E. Swayne (Ed.), *Avian influenza* (2nd ed., pp. 202–247). Singapore: Wiley Blackwell.

Swayne, D., Suarez, D.L. & Sims, L.D. (2013). Influenza. In D. Swayne, J.R. Glisson, L. McDougald, L. Nolan, D. Suarez & V. Nair (Eds.), *Diseases of Poultry* (13th ed., pp. 181–218). Ames, IA: Blackwell Publishing Professional.

Swayne, D.E. & Slemons, R.D. (1994). Comparative pathology of a chicken-origin and two duck-origin influenza virus isolates in chickens: the effect of route of inoculation. *Veterinary Pathology*, 31, 237–245.

Ward, C.L., Dempsey, M.H., Ring, C.J., Kempson, R.E., Zhang, L., Gor, D., Snowden, B.W. & Tisdale, M. (2004). Design and performance testing of quantitative real time PCR assays for influenza A and B viral load measurement. *Journal of Clinical Virology*, 29, 179–188.

Ziegler, A.F., Davison, S., Acland, H. & Eckroade, R.J. (1999). Characteristics of H7N2 (nonpathogenic) avian influenza virus infections in commercial layers, in Pennsylvania, 1997–98. *Avian Diseases*, 43, 142–149.