



Survival time of juvenile dogs with oral squamous cell carcinoma treated with surgery alone: A Veterinary Society of Surgical Oncology retrospective study

Surabhi Sharma BVSc&AH, MSc¹ | Sarah E. Boston DVM, DVSc, DACVS¹ |
 Owen T. Skinner BVSc, DECVS, DACVS-SA²  |
 James A. Perry DVM, PhD, DACVIM-Oncology, DACVS_SA³ |
 Frank J. M. Verstraete DrMedVet, MMedVet, DECVS, AVDC, EVDC⁴ |
 Da Bin Lee DVM⁵ | Lucinda L. L. Van Stee DVM⁶ | Chris Thompson DVM⁷  |
 Matthew Boylan MVB¹ | Talon McKee CVT⁸ |
 Philip J. Bergman DVM, PhD, DACVIM-Oncology⁸

¹Small animal surgical oncology service, VCA Canada–Surgical Oncology, VCA Canada, 404 Veterinary Emergency and Referral Hospital, Newmarket, Ontario, Canada

²Department of Veterinary Medicine and Surgery, University of Missouri College of Veterinary Medicine, Columbia, Missouri

³Department of Surgery, University of Pennsylvania, Philadelphia, Pennsylvania

⁴Department of Surgical and Radiological Sciences, School of Veterinary Medicine, University of California-Davis, Davis, California

⁵WR Pritchard Veterinary Medical Teaching Hospital, School of Veterinary Medicine, University of California - Davis, Davis, CA

⁶Department of Clinical Sciences of Companion Animals, Faculty of Veterinary Medicine, Utrecht University, Utrecht, The Netherlands

⁷Department of Veterinary Clinical Sciences, University of Minnesota, Saint Paul, Minnesota

⁸Department of clinical studies, VCA Clinical Studies, Los Angeles, California

Correspondence

*Surabhi Sharma, VCA 404 Veterinary Emergency and Referral Hospital, Newmarket, Ontario, Canada.
 Email: surabhi.drssvet.sharma@gmail.com

[Correction added on 20 April 2021, after first online publication: The name and affiliation of Dr. Da Bin Lee were incorrect in the initial publication. They have been corrected.]

Abstract

Objective: To report the signalment, staging, surgical treatment, and survival time of juvenile dogs treated surgically for oral squamous cell carcinoma (OSCC).

Study design: Retrospective study.

Animals or sample population: Twenty-five dogs, <2 years of age with OSCC treated with surgery.

Methods: Cases were solicited from the Veterinary Society of Surgical Oncology. Data retrieved included sex, breed, age, weight, clinical signs, tumor location, preoperative diagnostics and staging, histopathological diagnosis with margin evaluation, disease-free interval, and date and cause of death. A minimum follow-up time of 3 months was required for inclusion.

Results: Eighteen dogs were <12 months of age, and seven were <24 months. Various breeds were represented, with a mean body weight of 22.3 ± 14.4 kg. No dogs had evidence of metastatic disease prior to surgery. All dogs underwent partial maxillectomy or mandibulectomy. Histological margins were complete in 24 dogs and incomplete in one. No dogs had evidence of metastatic

disease or tumor recurrence. The median follow-up time was 1556 days (92 to 4234 days). All dogs were alive at the last follow-up except for one documented death, due to dilated cardiomyopathy. Median disease-specific survival time was not reached.

Conclusion: The prognosis after wide surgical excision of OSCC in juvenile dogs was excellent.

Clinical significance: OSCC in juvenile dogs can be effectively treated with surgery alone.

1 | INTRODUCTION

Juvenile oral squamous cell carcinoma (OSCC) in dogs is not well described in the literature, with limited information available on the expected course of disease after treatment in juvenile canine population. OSCC is an invasive, locally aggressive neoplastic disease that is reportedly the second most common malignant oral neoplasm in dogs.^{1,2} In dogs, OSCC is categorized as either tonsillar or nontonsillar.^{1,2} Nontonsillar OSCC is more common and constitutes approximately 50%–78% of reported OSCC cases.^{1,3} Nontonsillar OSCC is uncommonly metastatic⁴; however, metastasis has been noted to occur to both the regional lymph nodes (10%–30%) and lungs (3%–36%).^{5–8} The prognosis for dogs with nontonsillar OSCC is considered good, in particular for tumors located at the rostral aspect of the oral cavity as this increases the likelihood of complete excision.^{1,5} Surgery is the most common treatment for the nontonsillar form of OSCC, with wide excision (1 cm) via mandibulectomy or maxillectomy often performed.^{1,7–9}

OSCC generally affects older dogs with a median reported age of 8–10 years.^{4,10,11} Sex predilection has not been commonly reported, with one study indicating females to be at an increased risk of development of lingual SCC,¹² while reportedly males are at a higher risk for the development of tonsillar carcinoma.^{13,14} The etiology of canine OSCC is unclear, and similar to humans, its early stages often go unnoticed.¹⁵ Although exposure to household tobacco smoke, flea collars, and high intake of canned tuna fish have been reported risk factors in cats,¹⁶ no similar studies of etiology have been performed in dogs. OSCC is commonly associated with osseous involvement and osteolysis.⁴ Surgical excision of the regional lymph nodes for staging has been recommended.^{6,7} Also, histologic evaluation of one regional lymph node is insufficient and bilateral lymphadenectomy of mandibular and medial retropharyngeal lymph nodes is recommended to rule out regional metastasis.^{6,17} Surgical excision of OSCC is recommended and excision with complete histopathological margins has the potential to be curative for nontonsillar

OSCC.¹ Adjuvant radiation therapy can be considered in cases of incomplete surgical margins.¹⁸ Chemotherapy (such as carboplatin and doxorubicin) can be considered adjuvant therapy in cases with aggressive features of malignancy on histopathology or evidence of metastatic disease.¹⁹

OSCC comprised only 9.8% of oral tumors in dogs <12 months old in a recent retrospective study on pediatric oncology but was the most common malignant oral tumor.²⁰ The two most common oral tumors in that study were papilloma and ossifying and fibromatous epulis.²⁰ Similar to dogs, OSCC in humans has been reported to occur in older patients more commonly, with most patients more than 45 years of age.²¹ However, OSCC has been rarely reported in human pediatric and adolescent patients.²²

Human pediatric and adult OSCC had a similar disease-free interval (DFI) and median survival time when matched for variables known to trigger the disease in humans.²³ Similar data are not available in dogs.

The objective of this study was to report the signalment, staging, surgical procedure, and survival times in juvenile dogs (<2 years) treated surgically for OSCC. Our hypothesis was that with wide excision and complete surgical margins, long-term local control would be possible, and that OSCC would not be a life-limiting health problem in treated dogs.

2 | MATERIALS AND METHODS

This study was approved through the Veterinary Society of Surgical Oncology (VSSO) research committee and was initiated by requesting case submissions from VSSO members. Inclusion criteria were dogs less than 24 months of age treated with mandibulectomy or maxillectomy and a histopathological diagnosis of OSCC. Patients with less than 3 months of follow-up were excluded from the study. Data retrieved included signalment, clinical signs and presenting complaint, tumor location, preoperative clinical staging and diagnostics, postoperative diagnostics, histopathological diagnosis

with margin evaluation, postoperative therapies if applicable, date of detection of recurrence or distant metastatic disease if applicable, and date and cause of death. Tumors of the mandible or maxilla located rostral to the third premolar tooth were defined as rostral and those located caudal to the third premolar were defined as caudal.²⁴ Although planned surgical margins (in cm) were not documented in the surgery reports, the excision was considered to be wide as extensive surgeries (mandibulectomy or maxillectomy) were performed. The histopathological diagnosis and margin assessment were based on assessment by a board-certified veterinary pathologist at the time of original sample submission.

Outcome measures were DFI and disease-specific survival time (DST). DFI was defined as the time in days from surgical excision until the date that metastatic disease or local tumor recurrence was noted. DST was defined as the survival time (in days) between surgical excision and death due to OSCC. Follow-up was determined through telephone interviews with referring veterinarians and owners. Cause of death was then subclassified as either tumor related or nontumor related. Dogs where no cause of death was identified in the record were presumed to have died due to tumor-related causes. Dogs that died of nontumor-related causes or were alive at last follow-up were censored in the survival analysis.

2.1 | Statistical analysis

Descriptive statistics were performed for the available data, and a frequency data table was generated for all variables. As data were predominately categorical, they were presented as frequencies (proportions or percentages). For normally distributed data, mean was calculated and for non-normally distributed data, median was reported. Kaplan–Meier (KM) analysis was performed with the help of commercially available statistics software (Prism 8; GraphPad, San Diego, California).

3 | RESULTS

Twenty-five medical records were accrued from 14 veterinary hospitals from Canada, USA, and the Netherlands from January 2000 to January 2019. Eighteen dogs (72%) were <12 months old at the time of surgery, and seven dogs (28%) were between 12 and 24 months of age at the time of surgery. The median age at the time of surgery was 218 days (7 months). Breeds included in this study were four Labrador retrievers, four golden retrievers, three German shepherds, two standard poodles, three terriers, two mixed breeds, and one of each of the following breeds: Great Pyrenees, Cocker spaniel, Great Dane, Clumber

spaniel, Shih Tzu, collie, and Havanese. Mean (\pm SD) weight of the dogs under study was 22.3 ± 14.4 kg. Ten male dogs (eight neutered and two intact) and 15 female dogs (seven spayed and eight intact) were included in the study. The maxilla was affected in 13 dogs (52%) and the mandible in 12 (48%). Twenty dogs (80%) had a rostral tumor location, and four dogs (16%) had a caudal location. In one case (4%), the lesion involved the entire mandible unilaterally.

Twelve dogs (48%) underwent computed tomography (CT) of the head, and four dogs (16%) underwent dental/skull radiography for surgical planning. Preoperative diagnostic imaging was not obtained in nine (36%). Thoracic imaging was performed in 19 (76%) dogs, consisting of thoracic radiographs (15 dogs) or a thoracic CT (one dog). Two dogs had both modalities performed. No evidence of metastasis to the lungs was detected. Local lymph nodes were enlarged on physical examination in four dogs (16%), within normal limits in 17 dogs (68%), and this information was not available for four dogs (16%) (Table 1). Ten dogs (40%) had mandibular lymph node aspirates performed for cytology. Seven of 10 lymph nodes (70%) were considered reactive on cytology, and 3 lymph nodes (30%) were unremarkable on cytology. Lymphadenectomy was performed in six dogs (24%), and no evidence of metastasis was noted in any case on histopathology.

Surgical procedures performed included unilateral rostral maxillectomy (five dogs, 20%), unilateral caudal maxillectomy (three dogs, 12%), bilateral rostral maxillectomy (five dogs, 20%), unilateral rostral mandibulectomy (seven dogs, 28%), bilateral rostral mandibulectomy (three dogs, 12%), unilateral caudal mandibulectomy (one dog, 4%), and hemimandibulectomy (one dog, 4%) (Table 1). All surgeries were performed by a board-certified veterinary specialist in surgery or dentistry. Histopathological margins were described as complete in 24 dogs (96%) and incomplete in one dog (4%). Histopathology was consistent with squamous cell carcinoma with no subclassification in 12 dogs (48%), papillary SCC in 11 dogs (44%), odontogenic cyst with SCC in one case (4%), and verrucous SCC in one case (4%) (Table 1).

Three dogs (12%) were diagnosed with a second neoplasia in their lifetime, including OSCC in the contralateral mandible, cutaneous histiocytoma, and a mammary tumor (Table 1). The follow-up period of the study population ranged from 92 to 4234 days, with a median of 1556 days. The median DST could not be reached as 24 dogs were alive at the last follow-up, and one dog died of dilated cardiomyopathy. The survival time for the dog with incomplete histopathological margins was 2834 days. Up until the last follow-up examination, no recurrence or metastasis of the OSCC was reported, preventing calculation of the DFI. No dogs were

TABLE 1 Summary of data collected from medical records of dogs with oral squamous cell carcinoma

Case	Breed	Sex	Age (days)	Days until last follow-up	Surgical procedure	Lymph node palpation	Lymph node cytology	Lymph node biopsy	Subsequent neoplastic process	Histo diagnosis	Histo margins
1	Gr Py	MN	467	230	U Ca Max	WNL	Re	Normal	No	SCC	C
2	Ter	FI	122	1006	Hemi Man	NA	NP	NP	No	PSCC	C
3	Lab	FI	134	1311	U Ro Max	WNL	NP	NP	No	PSCC	C
4	St Po	MN	574	2953	U Ca Max	WNL	Re	NP	SCC on the contralateral maxilla	PSCC	C
5	MB	FS	152	1839	B Ro Man	WNL	Normal	NP	No	PSCC	C
6	GSD	FS	225	3665	U Ro Man	NA	NP	NP	No	VSCC	C
7	GD	MI	255	4234 ^a	U Ro Man	NA	NP	NP	Cutaneous Histiocytoma	SCC	C
8	Hav	MN	253	303	U Ca Max	WNL	NP	Normal	No	PSCC	C
9	Lab	MI	198	244	U Ro Max	WNL	NP	NP	No	SCC	C
10	Sh Tz	FI	251	1559	U Ro Man	EN	Re	Normal	No	SCC	C
11	Co Sp	FI	210	92	B Ro Man	EN	NP	Normal	No	SCC	C
12	MB	FS	723	3845	B Ro Max	WNL	Re	NP	No	SCC	C
13	GSD	MN	550	766	U Ro Man	WNL	Re	NP	No	PSCC	C
14	Ter	FS	194	4040	B Ro Max	WNL	NP	NP	No	SCC	C
15	Ter	MN	218	761	B Ro Man	WNL	Re	NP	No	PSCC	C
16	GR	FI	239	584	B Ro Max	WNL	NP	Normal	No	SCC	C
17	GR	MN	499	1729	U Ro	WNL	Normal	NP	No	PSCC	C

(Continues)

TABLE 1 (Continued)

Case	Breed	Sex	Age (days)	Days until last follow-up	Surgical procedure	Lymph node palpation	Lymph node cytology	Lymph node biopsy	Subsequent neoplastic process	Histo diagnosis	Histo margins
18	St Po	FS	450	1556	Man U Ro Man	WNL	NP	NP	No	PSCC	C
19	Collie	MN	175	166	U Ro Max	WNL	NP	NP	No	SCC	C
20	GSD	FI	133	1296	B Ro Max	WNL	NP	NP	No	SCC	C
21	GR	FS	718	2693	B Ro Max	EN	Re	NP	No	PSCC	C
22	Lab	FI	210	3776	U Ro Man	WNL	NP	NP	No	SCC	C
23	GR	FS	164	1442	U Ro Max	WNL	NP	Normal	Mammary tumor	PSCC	C
24	Lab	MN	206	3118	U Ca Man	EN	Normal	NP	No	SCC	C
25	Cl Sp	FI	160	2834	U Ro Max	NA	NP	NP	No	SCC (with odontogenic cyst)	I

Abbreviations: B Ro Max, bilateral rostral maxillectomy; B Ca Man, bilateral caudal mandibulectomy; B Ca Max, bilateral caudal maxillectomy; B Ro Man, bilateral rostral mandibulectomy; C, clean; Cl Sp, Clumber spaniel; Co Sp, Cocker spaniel; En, enlarged; FI, female intact; FS, female spayed; GR, golden retriever; Gr Py, Great Pyrenees; GSD, German Shepherd; Hav, Havanese; Hemi Man, hemimandibulectomy; Histo, histopathological; I, incomplete; Lab, Labrador; MB, mixed breed; MI, male intact; MN, male neutered; NA, not available; NP, not performed; PSCC, papillary squamous cell carcinoma; Re, reactive; SCC, squamous cell carcinoma; St Po, Standard Poodle; Sh Tz, Shih Tzu; Ter, Terrier; U Ca Man, unilateral caudal mandibulectomy; U Ca Max, unilateral caudal maxillectomy; U Ro Man, unilateral rostral mandibulectomy; U Ro Max - unilateral rostral maxillectomy; VSCC, verrucous squamous cell carcinoma; WNL, within normal limits.

^aDied due to dilated cardiomyopathy (DCM).

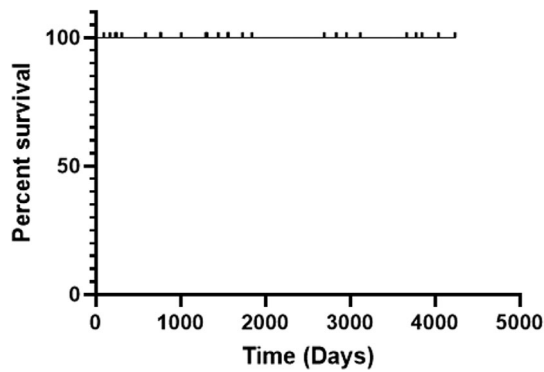


FIGURE 1 Kaplan–Meier (KM) curve depicting disease-specific survival time

documented to have died or been euthanized due to their OSCC; hence, median DST was not reached. The KM curve was plotted to depict the DST (Figure 1).

4 | DISCUSSION

This study documents the long-term survival of dogs treated with wide excision of juvenile OSCC. No evidence of recurrence or metastasis was reported, and all but one dog were alive at the last follow-up.

Medium to large breed dogs have been found at higher risk for SCC,^{2,25,26} consistent with the body weight (22.3 kg) of our population. English cocker spaniels and Shetland sheepdogs have been overrepresented in previous reports. Such predilection was not observed in our study, but our small sample size prevents conclusions regarding breed predisposition.^{2,25,26} Spayed female dogs²⁵ and female human pediatric patients have also been overrepresented in previous studies.²⁷ Although our population includes more female dogs, no statistical inference could be drawn due to the small sample size.

The lack of preoperative metastasis recorded in our study is consistent with previous publications, reporting low rates of metastasis of OSCC to lymph nodes (10%–30%).^{5–7} Cytology or histopathology was not performed in every dog, preventing us from establishing the absence of metastasis to the regional lymph nodes. However, dogs with undiagnosed metastatic disease should have exhibited secondary clinical signs during their follow-up. Similarly, CT examination of the head was only available in half of dogs enrolled in our study. CT has been found more sensitive and specific modality than standard radiography when evaluating osseous changes and tumor extension into the adjacent tissue.²⁸ Although complete margins were achieved in our study based on skull radiographs alone, CT is considered standard of care for planning a mandibulectomy or maxillectomy to treat oral tumors.²⁸

Squamous cell carcinoma in humans has been classified into conventional SCC, verrucous carcinoma, basaloid SCC, papillary SCC, spindle cell carcinoma, acantholytic SCC, adenosquamous carcinoma, and carcinoma cuniculatum.^{27,29} No such classification exists in dogs, but recognized forms of SCC in dogs include conventional carcinoma, papillary SCC, and verrucous carcinoma.²⁵ In the present study, most dogs were either diagnosed with papillary SCC or conventional SCC, supporting the concept of young dogs being predisposed to papillary OSCC.^{30,31}

Tobacco and alcohol abuse are known risk factors for OSCC in older human patients.⁸ The pathogenesis of these tumors remains unclear in younger individuals.²² Fanconi's anemia and DNA repair defects are some of the risk factors that have been associated with SCC development in the younger human population.³² Human papilloma virus has also been implicated in the formation of OSCC in pediatric population.^{33,34} Canine papilloma virus has also been postulated as a risk factor in dogs.^{30,35,36} Canine papilloma is the most common benign oral tumor, and OSCC is the most common malignant oral tumor in dogs.²⁰ In the present study, no patient had a prior recorded history of papilloma virus. However, infected dogs do not always have visible clinical signs.³⁷ As such, the absence of history of papilloma virus does not preclude the presence of the virus in the dogs and it is possible that this virus may play a role in tumor development in juvenile dogs. Most neoplasms in the present study involved the rostral oral cavity. A predisposition of juvenile dogs to rostral OSCC has previously been suggested.^{22,31,38,39} This predisposition may relate to canine papilloma virus infections and their potential for malignant transformation.^{30,35,36} The transmission of papilloma virus by contact between dogs⁴⁰ may explain why the rostral jaws are more predisposed to formation of papillomas and potentially papillary SCC. Alternately, the frequency of rostral OSCC in our study may just reflect the fact that this location is more amenable to surgical excision.⁸

Juvenile OSCC appears to have low metastatic potential and recurrence rate, and no recurrence or evidence of metastasis was recorded in this study. The only dog with incomplete histopathological margins was alive at the last follow-up after 2834 days (7.8 years). One dog did develop OSCC in the contralateral mandible, most likely a de novo tumor, but metastasis from the original OSCC cannot be ruled out. This dog had a reported survival time of 2953 days. In author's experience, most affected dogs are old, consistent with the reported age at presentation in OSCC of 8–10 years.^{4,10,11} In this older population, death may be secondary to the malignant tumor or due to concurrent non-neoplastic and/or age-related disease. Death due to nontumor causes may indicate actual cure or may occur within that patient's DFI. By contrast, the

excellent long-term follow-up in our study prompts us to suggest that young dogs with OSCC may be cured. The National Cancer Institute (NIH) defines cure in humans as a patient with no evidence of disease for 5 years after treatment.⁴¹ This 5-year term is arbitrary, given the difficulty in defining cure in the cancer patients. With the compressed life span of a dog compared to a human, a median follow-up time of over 4 years with no evidence of disease recurrence may equate to a high chance of cure after wide excision of canine juvenile OSCC.

The major limitations of this study are its retrospective nature and small sample size. Medical records varied in detail over time and between institutions, which may have resulted in classification bias. Detailed information on the postoperative recovery period and long-term quality of life measures was not available. As regional lymph node extirpation was not performed in every case, the actual rate of regional metastasis could not be estimated.

In conclusion, the prognosis after wide surgical excision of OSCC in juvenile dogs was excellent in this population and surgery may be curative. Future investigations would benefit from a larger study population with standardized medical records. Future prospective studies should evaluate the risk factors for the development of OSCC in juvenile dogs and the potential relationship between canine papilloma virus and OSCC. Studies investigating the hypothesis that the rostral jaw of juvenile canines are at a higher risk for formation of OSCC (and ensuing factors) could be considered.

ACKNOWLEDGMENTS

We thank Veterinary Society of Surgical Oncology (VSSO) members for providing the support for this study.

CONFLICT OF INTEREST


The authors declare no conflicts of interest related to this report.

AUTHOR CONTRIBUTION

Sarah E. Boston, DVM, DVSc, DACVS, contributed to conception, acquisition, analysis, and review of the work (5 cases). The author also reviewed the final version of the manuscript. Owen T. Skinner, BVSc, DECVS, DACVS-SA, contributed to conception, acquisition, analysis, and review of the work (4 cases). The author also reviewed the final version of the manuscript. James A. Perry, DVM, PhD, DACVIM-Oncology, DACVS_SA, contributed to acquisition and review of the work (4 cases). The author also reviewed the final version of the manuscript. Frank J. M. Verstraete, DrMedVet, MMedVet, DECVS, AVDC, EVDC, contributed to acquisition and review of the work (3 cases). The author also reviewed the final version of the manuscript. Da B. Lee,

DVM, contributed to acquisition and review of the work. The author also reviewed the final version of the manuscript. Lucinda L. L. Van Stee, DVM, contributed to acquisition, analysis and review of the work (3 cases). The author also reviewed the final version of the manuscript. Chris Thompson, DVM, contributed to acquisition, analysis, and review of the work (6 cases). The author also reviewed the final version of the manuscript. Matthew Boylan, MVB, contributed to conception, acquisition, analysis, and review of the work. The author also reviewed the final version of the manuscript. Talon McKee, CVT, contributed to analysis and review of the work. The author contributed to the statistical analysis of the work. Philip J. Bergman, DVM, PhD, DACVIM-Oncology, contributed to conception, acquisition, analysis, and review of the work. The author contributed to the statistical analysis of the work. The author also reviewed the final version of the manuscript.

ORCID

Owen T. Skinner  <https://orcid.org/0000-0002-3765-429X>

Chris Thompson  <https://orcid.org/0000-0002-3673-7800>

REFERENCES

1. Liptak JM. Cancer of the gastrointestinal tract, section A: oral tumors. In: Vail DM, Thamm DH, Liptak JM, eds. *Small Animal Clinical Oncology*. 6th ed. St. Louis, MO: Elsevier; 2019:432-448.
2. Todoroff RJ, Brodey RS. Oral and pharyngeal neoplasia in the dog: a retrospective survey of 361 cases. *J Am Vet Med Assoc*. 1979;175(6):567-571.
3. White RAS. Tumours of the oropharynx. In: Dobson JM, Lascelles BDX, eds. *BSAVA Manual of Canine and Feline Oncology*. 3rd ed.; Quedgeley, UK: British small animal veterinary association; 2011:206-213.
4. Webb JL, Burns RE, Brown HM, LeRoy BE, Kosarek CE. Squamous cell carcinoma. *Compendium*. 2009;31(3):E9-E9.
5. White RAS. Mandibulectomy and maxillectomy in the dog: long term survival in 100 cases. *J Small Anim Pract*. 1991;32(2):69-74.
6. Grimes JA, Mestrinho LA, Berg J, et al. Histologic evaluation of mandibular and medial retropharyngeal lymph nodes during staging of oral malignant melanoma and squamous cell carcinoma in dogs. *J Am Vet Med Assoc*. 2019;254(8):938-943.
7. Fulton AJ, Nemecek A, Murphy BG, Kass PH, Verstraete FJM. Risk factors associated with survival in dogs with nontonsillar oral squamous cell carcinoma 31 cases (1990-2010). *J Am Vet Med Assoc*. 2013;243(5):696-702.
8. Kosovsky JK, Matthiesen DT, Marretta SM, Patnaik AK. Results of partial mandibulectomy for the treatment of oral tumors in 142 dogs. *Vet Surg*. 1991;20(6):397-401.
9. Wallace J, Matthiesen DT, Patnaik AK. Hemimaxillectomy for the treatment of oral tumors in 69 dogs. *Vet Surg*. 1992;21(5):337-341.
10. Nemecek A, Murphy BG, Jordan RC, Kass PH, Verstraete FJM. Oral papillary squamous cell carcinoma in twelve dogs. *J Comp Pathol*. 2014;150(2):155-161.

11. Kuhnel S, Kessler M. Prognosis of canine oral (gingival) squamous cell carcinoma after surgical therapy. A retrospective analysis in 40 patients. *Tierarztl Prax Ausg K Kleintiere Heimtiere*. 2014;42(6):359-366.
12. Dennis MM, Ehrhart N, Duncan CG, Barnes AB, Ehrhart EJ. Frequency of and risk factors associated with lingual lesions in dogs: 1,196 cases (1995–2004). *J Am Vet Med Assoc*. 2006;228(10):1533-1537.
13. MacMillan R, Withrow SJ, Gillette EL. Surgery and regional irradiation for treatment of canine tonsillar squamous cell carcinoma: retrospective review of eight cases [in the dog]. *J Am Anim Hosp Assoc*. 1982;18(2):311-314.
14. Brooks MB, Matus RE, Leifer CE, Alfieri AA, Patnaik AK. Chemotherapy versus chemotherapy plus radiotherapy in the treatment of tonsillar squamous cell carcinoma in the dog. *J Vet Intern Med*. 1988;2(4):206-211.
15. Markopoulos AK. Current aspects on oral squamous cell carcinoma. *Open Dent J*. 2012;6:126-130.
16. Bertone ER, Snyder LA, Moore AS. Environmental and lifestyle risk factors for oral squamous cell carcinoma in domestic cats. *J Vet Intern Med*. 2003;17(4):557-562.
17. Skinner OT, Boston SE, CHdM S. Patterns of lymph node metastasis identified following bilateral mandibular and medial retropharyngeal lymphadenectomy in 31 dogs with malignancies of the head. *Vet Comp Oncol*. 2017;15(3):881-889.
18. Riggs J, Adams VJ, Hermer JV, Dobson JM, Murphy S, Ladlow JF. Outcomes following surgical excision or surgical excision combined with adjunctive, hypofractionated radiotherapy in dogs with oral squamous cell carcinoma or fibrosarcoma. *J Am Vet Med Assoc*. 2018;253(1):73-83.
19. Mestrinho LA, Bernardo E, Niza M, Lloret A, Buracco P. Neoadjuvant chemoradiotherapy and surgery as treatment for oral maxillary squamous cell carcinoma in a dog. *Aust Vet J*. 2012;90(7):264-268.
20. Schmidt JM, North SM, Freeman KP, Ramiro-Ibañez F. Canine paediatric oncology: retrospective assessment of 9522 tumours in dogs up to 12 months (1993–2008). *Vet Comp Oncol*. 2010;8(4):283-292.
21. Krolls SO, Hoffman S. Squamous cell carcinoma of the oral soft tissues: a statistical analysis of 14,253 cases by age, sex, and race of patients. *J Am Dent Assoc*. 1976;92(3):571-574.
22. Bodner L, Manor E, Friger MD, van der Waal I. Oral squamous cell carcinoma in patients twenty years of age or younger—review and analysis of 186 reported cases. *Oral Oncol*. 2014;50(2):84-89.
23. Mborris LGT, Patel SG, Shah JP, Ganly I. Squamous cell carcinoma of the oral tongue in the pediatric age group: a matched-pair analysis of survival. *Arch Otolaryngol Head Neck Surg*. 2010;136(7):697-701.
24. Verstraete FJM. Mandibulectomy and maxillectomy. *Vet Clin North Am Small Anim Pract*. 2005;35(4):1009-1039.
25. Nemeč A, Murphy B, Kass PH, Verstraete FJM. Histological subtypes of oral non-tonsillar squamous cell carcinoma in dogs. *J Comp Pathol*. 2012;147(2–3):111-120.
26. Fiani N, Verstraete FJM, Kass PH, Cox DP. Clinicopathologic characterization of odontogenic tumors and focal fibrous hyperplasia in dogs: 152 cases (1995–2005). *J Am Vet Med Assoc*. 2011;238(4):495-500.
27. Thompson LDR. World Health Organization classification of tumours: pathology and genetics of head and neck tumours. *Ear Nose Throat J*. 2006;85(2):74-75.
28. Ghirelli CO, Villamizar LA, Pinto AC. Comparison of standard radiography and computed tomography in 21 dogs with maxillary masses. *J Vet Dent*. 2013;30(2):72-76.
29. Pereira MC, Oliveira DT, Landman G, Kowalski LP. Histologic subtypes of oral squamous cell carcinoma: prognostic relevance. *J Can Dent Assoc*. 2007;73(4):339-344.
30. Ogilvie GK, Sundberg JP, O'Banion MK, Wheaton LG, Reichmann ME. Papillary squamous cell carcinoma in three young dogs. *J Am Vet Med Assoc*. 1988;192(7):933-936.
31. Stapleton BL, Barrus JM. Papillary squamous cell carcinoma in a young dog. *J Vet Dent*. 1996;13(2):65-68.
32. Stolk-Liefferink SAH, Dumans AG, Van der Meij EH, Knegt PP, Van der Wal KGH. Oral squamous cell carcinoma in children; review of an unusual entity. *Int J Pediatr Otorhinolaryngol*. 2008;72(1):127-131.
33. Miller CS, White DK. Human papillomavirus expression in oral mucosa, premalignant conditions, and squamous cell carcinoma: a retrospective review of the literature. *Oral Surg Oral Med Oral Pathol Oral Radiol Endod*. 1996;82(1):57-68.
34. Khan SM, Gossweiler MK, Zunt SL, Edwards MD, Blanchard SB. Papillary squamous cell carcinoma presenting on the gingiva. *J Periodontol*. 2005;76(12):2316-2321.
35. Watrach AM, Small E, Case MT. Canine papilloma: progression of oral papilloma to carcinoma. *J Nail Cancer Inst*. 1970;45(5):915-920.
36. Thaiwong T, Sledge DG, Wise AG, Olstad K, Maes RK, Kiupel M. Malignant transformation of canine oral papillomavirus (CPV1)-associated papillomas in dogs: an emerging concern? *Papillomavirus Res*. 2018;6:83-89.
37. Lange CE, Zollinger S, Tobler K, Ackermann M, Favrot C. Clinically healthy skin of dogs is a potential reservoir for canine papillomaviruses. *J Clin Microbiol*. 2011;49(2):707-709.
38. Van Rensburg IBI. Oral verrucous carcinoma in two dogs. *J S Afr Vet Assoc*. 1982;53(3):209-210.
39. Lownie JF, Altini M, Austin JC, Le Roux PL. Verrucous carcinoma presenting in the maxilla of a dog. *J Am Anim Hosp Assoc*. 1981;53(3):209-210.
40. Lane HE, Weese JS, Stull JW. Canine oral papillomavirus outbreak at a dog daycare facility. *Can Vet J*. 2017;58(7):747-749.
41. Understanding cancer prognosis. National Cancer institute. <https://www.cancer.gov/about-cancer/diagnosis-staging/prognosis>. Accessed December 1, 2019.

How to cite this article: Sharma S, Boston SE, Skinner OT, et al. Survival time of juvenile dogs with oral squamous cell carcinoma treated with surgery alone: A Veterinary Society of Surgical Oncology retrospective study. *Veterinary Surgery*. 2021;50:740–747. <https://doi.org/10.1111/vsu.13625>