




OPEN ACCESS

HORSES AND OTHER EQUIDS

Cutaneous mastocytoma with eosinophilia and eosinophilic infiltration of the small intestine in an Arabian gelding

Natasha Jane Williams,¹ Robin van den Boom ²

¹Department of Veterinary Clinical Sciences, Oklahoma State University Center for Veterinary Sciences, Stillwater, Oklahoma, USA

²Equine Sciences, Faculty of Veterinary Medicine, Utrecht, The Netherlands

Correspondence to

Dr Robin van den Boom; r.vandenboom@uu.nl

Received 16 November 2018

Revised 6 February 2020

Accepted 18 March 2020

SUMMARY

A 12-year-old Arabian gelding presented to the University of Adelaide for investigation of a firm subcutaneous mass, just proximal to the digital flexor tendon sheath of the right forelimb, that had appeared two weeks prior. The skin overlying the mass was intact. Fine needle aspiration identified eosinophilic and mastocytic infiltrates. One week later, the gelding re-presented for persistent colic signs. Blood examination showed eosinophilia, and on palpation per rectum the mesenteric root was very firm and enlarged and a number of small intestinal loops had subjectively thickened walls. Colic signs were unabated by the administration of pain relief. The owner declined surgery and the gelding was euthanased. Postmortem examination confirmed a diagnosis of cutaneous mastocytoma and revealed eosinophilic infiltration of the small intestine.

BACKGROUND

This case involved a subcutaneous mass that was visible externally, which was subsequently diagnosed as a mast cell tumour. A short time later, the horse presented with colic, and it is speculated that the colic was related to the tumour, due to the presence of peripheral eosinophilia and eosinophilic infiltration of the small intestine.

Mast cell tumours comprise a neoplastic disease involving mast cells and their progenitors. They are sometimes described as mastocytosis or mastocytomas, because in many cases it is unclear whether the proliferation of mast cells in the lesion is truly neoplastic.¹⁻³

Mast cell tumours in horses have been reported sporadically in the literature since 1908.⁴ They are uncommon in horses compared with some other species of domestic animals, representing only 6.9 per cent of cases in one survey of cutaneous neoplasms at a large equine referral hospital.⁵ Solitary tumours are the most common form described,⁶ and these are most frequently located in the skin, similar to cutaneous mastocytosis recognised in man and other species.^{1 3 6-9}

Although considered uncommon cutaneous tumours, mast cell tumours have been rarely described in other locations such as the eye, the respiratory tract and the oral cavity.¹⁰⁻¹² A case report by Brown and others¹³ provides details of another unusual location of this tumour in the horse, the testes.

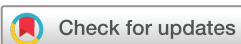A wide range of ages of affected horses have been reported, from one year to 18 years (mean age 9.5 years).⁶ Arabian horses appear to be over-represented, with 10 of 30 (33 per cent) cases recorded by McEntee⁶ and 5 of 11 (45 per cent) cases reported by Mair and Krudewig¹⁴ being Arabian horses. Male horses may also be predisposed.^{1 9 15-17}

Solitary cutaneous tumours typically demonstrate a slowly progressive or static growth pattern,⁶ and are usually non-metastatic and superficial. Typically, they are well demarcated, and vary from 0.5 to 20 cm in diameter, and are non-painful and non-pruritic. The most common locations are the head (lip, nostril, jaw, periorbital area), trunk and limbs.⁵ The tumours found in the dermis or subcutaneous tissues may be firm or fluctuant on palpation, and often are partially encapsulated. Mast cell tumours on the limbs, however, are often firm and immovable, and found in close proximity to joints.⁵ In these tumours, calcification is often present and may be visible radiographically.¹⁷

In horses, malignant mast cell tumours are rare, although a number of cases have been reported, including an intraosseous mast cell tumour (MCT) in the third phalanx,¹⁸ an MCT with synovial infiltration¹⁹ and spread to local lymph nodes.^{20 21} In other species, most notably in cats, simultaneous occurrence of MCTs in multiple organs has been reported, likely representing multicentric mastocytosis.²² Recently, multicentric mastocytoma has also been described in the horse, involving both the thoracic and abdominal cavities.²³

Cytology or histopathology is required for diagnosis of mast cell tumours, either by fine needle aspiration or surgical excisional biopsy. Histologically, these tumours show a well-differentiated cellular pattern, with single to multifocal coalescing nodules and sheets of mast cells.^{1 6} Mitotic figures are usually few in number. Neoplastic mast cells in the horse are usually well differentiated and contain numerous granules, but these are often not visible with haematoxylin and eosin staining.

As visceral metastasis is rare, most equine cutaneous mast cell tumours have a good prognosis, and in many cases treatment is only required for cosmetic reasons or to ameliorate local effects. Treatment options include surgical excision, which may be successful even if incomplete.^{3 5 6 14 15 17} Other therapeutic options include laser ablation, cryotherapy, intralesional injection of corticosteroids or water, and radiotherapy.¹⁴



© British Veterinary Association 2020. Re-use permitted under CC BY-NC. No commercial re-use. Published by BMJ.

To cite: Williams NJ, van den Boom R. *Vet Rec Case Rep* Published Online First: [please include Day Month Year]. doi:10.1136/vetreccr-2018-000773

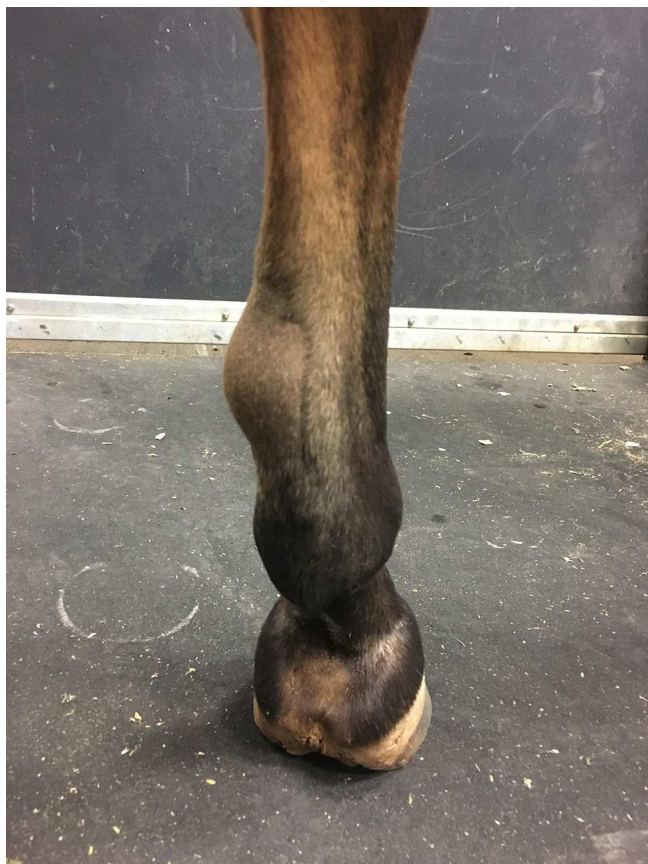


Figure 1 Firm mass on the mediopalmar aspect of the right forelimb, just proximal to the metacarpophalangeal joint.

CASE PRESENTATION

A 12-year-old Arabian gelding presented to the University of Adelaide Equine Health and Performance Centre ambulatory service with signs of mild colic, which resolved with the administration of flunixin meglumine (1.1 mg/kg intravenously) and a 5-litre bolus of isotonic fluids administered via a nasogastric tube.

Approximately three weeks later the gelding presented to the hospital for a dental examination after the owners had noted weight loss and a reduced appetite, since the colic episode. Sharp enamel points on the buccal aspects of the maxillary arcades and the lingual aspects of the mandibular arcades were apparent on dental examination, and these were removed using a power float. The horse also had a firm, non-painful subcutaneous mass, approximately 4 cm in diameter, on the mediopalmar aspect of the right forelimb, just proximal to the digital flexor tendon sheath (figure 1). The centre of the mass was fluctuant. Ultrasonography was performed, which showed the mass to be composed of heterogeneous echogenic material, with no apparent communication with the tendon sheath. A fine needle aspirate was performed, and cytology of the mass revealed it to contain a high proportion of eosinophils (39 per cent). As the horse did not appear to be showing clinical signs related to the subcutaneous mass and the horse was not in work, it was decided to see what the natural progression of the swelling would be.

One week later again, the horse showed signs of acute colic (rolling). It had been observed normal the previous night and in the hours before presentation. At the time of examination in the field, the gelding had a mildly elevated heart rate (48 beats per minute (bpm)), with remaining cardiovascular parameters within

normal limits. Borborygmi were reduced in all four abdominal quadrants. The horse was sedated with xylazine (200 mg intravenously), and passage of a nasogastric tube yielded no reflux of either fluid or gas. The horse was then administered flunixin meglumine (1.1 mg/kg intravenously) and given a bolus of 6 litres of isotonic fluids. The owners were directed to withhold feed until later that evening and to slowly reintroduce feed the following day.

INVESTIGATIONS

The horse continued to display mild colic signs and was admitted to the teaching hospital for further work-up and treatment as needed. At the time of presentation, the gelding was not actively colicking, had a mildly elevated heart rate (48 bpm), and normal borborygmi in the left abdominal quadrants, but markedly reduced borborygmi in the right ventral quadrant. Remaining cardiovascular parameters, respiratory rate and temperature were all within normal limits. Palpation per rectum revealed very firm faecal balls within the rectum, and a very firm and enlarged mesenteric root, and a number of small intestinal loops appeared to be thick-walled, but were not distended. A nasogastric tube was passed, but no reflux was obtained. A complete blood count was performed which identified the presence of eosinophilia (1.89×10^9 cells/l, reference $0.00\text{--}0.80 \times 10^9$ cells/l).²⁴

DIFFERENTIAL DIAGNOSIS

- ▶ Mast cell tumour/mastocytosis.
- ▶ Multisystemic eosinophilic epitheliotropic disease (MEED).
- ▶ Eosinophilic enterocolitis.
- ▶ Spasmodic colic.
- ▶ Equine gastric ulcer syndrome.
- ▶ Intestinal displacement.
- ▶ Inflammatory bowel disease.
- ▶ Strangulating intestinal lesion.
- ▶ Endoparasites (cyathostominosis, *Strongylus vulgaris*).

TREATMENT

The horse was treated medically with paraffin oil (1 litre) and isotonic fluids (5 litres), before being commenced on continuous isotonic enteral fluids at a rate of 2 l/hour.

OUTCOME AND FOLLOW-UP

The gelding colicked overnight and was administered flunixin meglumine (1.1 mg/kg intravenously). Five hours later, the gelding had passed four piles of manure, but was again displaying colic signs (laying down, rolling, flank watching), with a heart rate of 60 bpm and absent borborygmi. After discussion with the owners regarding poor prognosis and the value of the horse as a paddock pet, the decision was made to euthanase.

A limited postmortem examination was performed. No displacement or strangulation of the intestine was observed, and the intestines were not macroscopically abnormal. Samples of the small intestine (duodenum and jejunum) and the mass on the right forelimb were collected and submitted for histopathology. The mass contained granular material and was closely associated with the superficial digital flexor tendon (figure 2). Examination of the slides revealed the mass to be a mast cell tumour with central eosinophilic granuloma formation, with infiltration of the superficial digital flexor tendon. Histological examination of the small intestine revealed mild, and in some areas moderate,

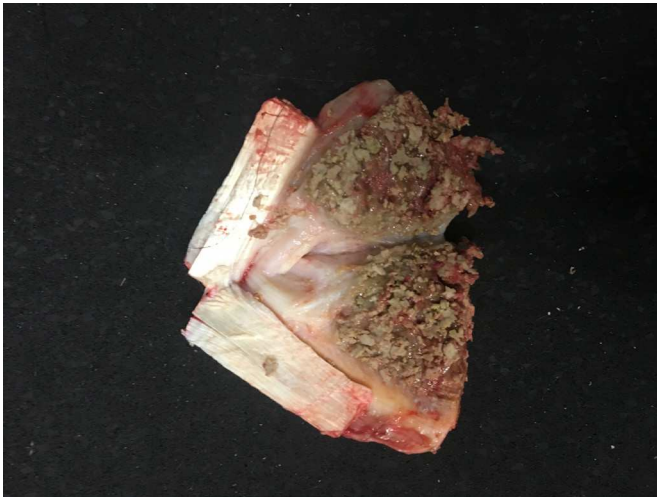

Figure 2 Cut surface of mass showing granular appearance of the centre of the lesion and infiltration of the superficial digital flexor tendon.

eosinophilic enteritis with eosinophilic infiltration of the submucosa and small numbers of lymphocytes and plasma cells.

Unfortunately, a full postmortem examination was not performed due to owners' financial constraints. It would have been worthwhile taking samples from the skin, liver, mesenteric root and large intestine, as eosinophils commonly infiltrate these organs in cases of MEED or eosinophilic enteritis.²⁵

DISCUSSION

This case report describes a 12-year-old Arabian gelding with a subcutaneous mast cell tumour on the distal limb, eosinophilia, (recurrent) colic, weight loss and eosinophilic infiltration of the small intestine.

Although most mast cell tumours are benign, they may cause local untoward effects, such as lameness, depending on their location. Leadbeater and others²⁶ described a mast cell tumour within the common carpal sheath of the digital flexor tendons in a 13-year-old Morgan gelding, associated with tenosynovitis and lameness.²⁶ Twenty-two months after surgical excision, the mastocytoma recurred and the owners elected conservative treatment, which included intrathecal injection of triamcinolone. Thirty months postoperatively the horse was in sound health, with no effusion of the tendon sheath and being used for Western pleasure and trail riding. Similarly, Taylor and others¹⁹ described a 14-year-old Arabian/Morgan mare with progressive hindlimb lameness and worsening effusion of the tarsocrural joint. Synovial biopsy contained diffuse, dense sheets of mast cells within fibrous connective tissue. The lameness resolved following intra-articular triamcinolone injection, suggesting that inhibition of secondary inflammation was necessary for clinical improvement.¹⁹ In the present case, infiltration of the superficial digital flexor tendon may have caused lameness if the horse had survived, and complete surgical excision would have been impossible without damaging the tendon. Intralesional corticosteroid injection may have been the most appropriate therapeutic option for the subcutaneous mast cell tumour.

Malignant mastocytosis with metastasis to the local lymph nodes may also occur. Riley and others²⁰ described two such cases, one involving an MCT on the dorsal aspect of the tarsus, with metastasis to the inguinal lymph nodes, and a second case involving an MCT over the caudolateral aspect of the carpus,

with ulceration of the overlying skin.²⁰ In the second case, surgical excision was performed, and the horse experienced an uneventful recovery with successful return to racing. At re-examination 18 months later, there was no evidence of the original tumour and no palpable evidence of metastasis to the regional lymph nodes. Reppas and Canfield²¹ also reported a 12-year-old Arabian horse with an MCT of the carpus, with eosinophilia and metastasis to the axillary lymph nodes.

Mast cell tumours are common in dogs and less so in cats. Simultaneous occurrence in multiple organs has been reported, mainly in cats, and likely represents multicentric mastocytoma.²² Uehlinger and others²⁷ described findings consistent with multicentric mast cell tumours in a 4.5-year-old Quarter Horse gelding with masses over the zygomatic arc, xiphoid process, abdomen and hindlimb. Punch biopsy of the mass of the head revealed it to be a cutaneous mast cell tumour. Biochemical and haematological values were within reference intervals, but mild eosinophilia and eosinophilic effusion of the right hind flexor tendon sheath and metatarsophalangeal joint were diagnosed. Treatment was attempted with intralesional triamcinolone and systemic dexamethasone, but following months of treatment, during which exacerbation of the swelling, lameness and self-trauma would follow attempted lowering of the dexamethasone dose, the horse was humanely euthanased.

Another case of multicentric mastocytoma was reported by Tan and others.²³ A nine-year-old Paint horse gelding presented with mild lethargy and inappetence, followed by the development of multiple, small cutaneous nodules on the face, neck, thorax, abdomen and upper limbs, and subsequently developed increased respiratory rate and effort. Biopsies were performed of the cutaneous lesions, revealing mast cell tumours. A large volume of fluid was drained from the pleural cavity, and after the horse failed to improve with two days of broad-spectrum antibiotics, fluid therapy, non-steroidal anti-inflammatories and saline nebulisation, the horse was euthanased. At post-mortem examination, a multilobulated mass was discovered at the thoracic inlet, infiltrating the sternal and cranial mediastinal lymph nodes, and multiple nodules were present throughout the pulmonary parenchyma. The mediastinal masses had large areas of necrosis surrounded by numerous poorly differentiated neoplastic mast cells displaying marked anisokaryosis and a few well-differentiated mast cells intermixed with numerous eosinophils. Neoplastic masses were also found within the hepatic parenchyma and the spleen and adjacent to the kidney. Eosinophilic and mast cell infiltration was present in the mucosal lamina propria and submucosa of the small intestine and colon, and submucosa of the stomach.

In the present case, the subcutaneous mast cell tumour was associated with eosinophilia and eosinophilic infiltration of the small intestine. The enlargement of the mesenteric root, as palpated per rectum, may have been the result of mesenteric lymph node involvement. The colic may have been related to the eosinophilic infiltration of the intestine, which can be observed in cases of eosinophilic enterocolitis,²⁵ other forms of inflammatory bowel disease, and rarely with MEED.²⁸ Intestinal parasites can also lead to eosinophilic infiltration of the intestine. The gelding in this case report demonstrated insufficient response to pain relief, and surgery, to diagnose and/or treat surgical causes of colic, was declined by the owner. Hence, the horse was euthanased. It cannot be determined if there was a relationship between the mast cell tumour and intestinal eosinophilic infiltration.

Learning points

- ▶ Mast cell tumour in a horse with a mass should be considered.
- ▶ Mast cell tumours appear to be more common in Arabian (cross) horses.
- ▶ Diagnosis needs to be confirmed by biopsy.
- ▶ Equine mast cell tumours may be associated with eosinophilia.

Contributors Both authors were involved in the clinical work-up of the case and preparation of the manuscript, and gave final approval of the manuscript.

Funding The authors have not declared a specific grant for this research from any funding agency in the public, commercial or not-for-profit sectors.

Competing interests None declared.

Provenance and peer review Not commissioned; externally peer reviewed.

Data availability statement All data relevant to the study are included in the article.

Open access This is an open access article distributed in accordance with the Creative Commons Attribution Non Commercial (CC BY-NC 4.0) license, which permits others to distribute, remix, adapt, build upon this work non-commercially, and license their derivative works on different terms, provided the original work is properly cited, an indication of whether changes were made, and the use is non-commercial. See: <http://creativecommons.org/licenses/by-nc/4.0/>.

ORCID iD

Robin van den Boom <http://orcid.org/0000-0001-8103-092X>

REFERENCES

- 1 Altera K, Clark L. Equine cutaneous mastocytosis. *Pathol Vet* 1970;7:43–55.
- 2 Prasse KW, Lundvall RL, Cheville NF. Generalised mastocytosis in a foal, resembling urticarial pigmentosa of man. *J Am Vet Med Ass* 1975;166:78–70.
- 3 Johnson PJ. Dermatologic tumors (excluding sarcoids). *Vet Clin North Am Equine Pract* 1998;14:625–58.
- 4 Rooney JR, Robertson JL. Mastocytosis and mastocytoma. In: *Equine pathology*. Ames: Iowa State University Press, 1996: 307.
- 5 Scott DW, Miller WH. Jr. Mast cell tumour. In: *Equine dermatology*. St Louis: Elsevier Science, 2003: 746–53.
- 6 McEntee MF. Equine cutaneous mastocytoma: morphology, biological behaviour and evolution of the lesion. *J Comp Pathol* 1991;104:171–8.
- 7 Nyrop KA, Debowes RM, Coffman JR, et al. Equine cutaneous mastocytoma. *Comp Cont Educ Pract Vet* 1986;8:757–61.
- 8 Nyrop KA. Cutaneous mastocytosis. In: Robinson ME, ed. *Current therapy in equine medicine*. 3rd edn. Philadelphia: W.B. Saunders, 1992: 702–3.
- 9 Brown HM, Cuttino E, LeRoy BE. A subcutaneous mass on the neck of a horse. *Vet Clin Pathol* 2007;36:109–13.
- 10 Richardson JD, Lane JG, Nicholls PK. Nasopharyngeal mast cell tumour in a horse. *Vet Rec* 1994;134:238–40.
- 11 Lykkjen S, Strand E, Haga HA, et al. Radical surgical resection of locally invasive orocutaneous tumors in the buccal region of 2 horses. *Vet Surg* 2006;35:319–23.
- 12 Seeliger F, Hess O, Pröpsting MJ, et al. Confocal laser scanning analysis of an equine oral mast cell tumor with atypical expression of tyrosine kinase receptor c-kit. *Vet Pathol* 2007;44:225–8.
- 13 Brown JA, O'Brien MA, Hodder ADJ, et al. Unilateral testicular mastocytoma in a Peruvian Paso stallion. *Equine Vet Educ* 2008;20:172–5.
- 14 Mair TS, Krudewig C. Mast cell tumours (mastocytosis) in the horse: a review of the literature and report of 11 cases. *Equine Vet Educ* 2008;20:177–82.
- 15 Stannard AA. Equine cutaneous mastocytoma (mastocytosis). *Proc Am Ass Equine Practns* 1976;22:284–6.
- 16 Doran RE, Collins LG. Mastocytoma in a horse. *Equine Vet J* 1986;18:500–2.
- 17 Samii VF, O'Brien TR, Stannard AA. Radiographic features of mastocytosis in the equine limb. *Equine Vet J* 1997;29:63–6.
- 18 Ritmeester AM, Denicola DB, Blevins WE, et al. Primary Intraosseous mast cell tumour of the third phalanx in a quarter horse. *Equine Vet J* 1997;29:151–2.
- 19 Taylor S, Martinelli MJ, Trostle SS, et al. Articular mastocytosis in the tarsocrural joint of a horse. *Equine Vet Educ* 2005;17:207–11.
- 20 Riley CB, Yovich JV, Howell JM. Malignant mast cell tumours in horses. *Aust Vet J* 1991;68:346–7.
- 21 Reppas GP, Canfield PJ. Malignant mast cell neoplasia with local metastasis in a horse. *N Z Vet J* 1996;44:22–5.
- 22 Kiupel M. Mast Cell Tumors. In: *Tumors in domestic animals*. Ames, Iowa: John Wiley and Sons, 2017: 176.
- 23 Tan RHH, Crisman MV, Clark SP, et al. Multicentric mastocytoma in a horse. *J Vet Intern Med* 2007;21:340–3.
- 24 Latimer KS, Rakich PM. Peripheral blood smears. In: *Diagnostic cytology and hematology of the horse*. St. Louis: Mosby, 2002: 201.
- 25 Gibson KT, Alders RG. Eosinophilic enterocolitis and dermatitis in two horses. *Equine Vet J* 1987;19:247–52.
- 26 Leadbeater JC, Gutierrez-Nibeyro SD, Brown JA. Mastocytoma in the common carpal sheath of the digital flexor tendons of a horse. *Aust Vet J* 2010;88:20–4.
- 27 Uehlinger FD, Burton SA, Riley CB, et al. Cutaneous and tendon sheath mastocytomas with eosinophilic joint and tendon sheath effusions in a horse. *J Vet Intern Med* 2010;24:1233–6.
- 28 Sanchez LC. Disorders of the gastrointestinal system. In: Reed, Bayly S, ed. *Equine internal medicine*. 4th ed. St Louis: Saunders Elsevier, 2018: 745.

Copyright 2020 British Veterinary Association. All rights reserved. For permission to reuse any of this content visit <http://www.bmj.com/company/products-services/rights-and-licensing/permissions/>
 Veterinary Record Case Reports subscribers may re-use this article for personal use and teaching without any further permission.

Subscribe to Vet Record Case Reports and you can:

- ▶ Submit as many cases as you like
- ▶ Enjoy fast sympathetic peer review and rapid publication of accepted articles
- ▶ Access all the published articles
- ▶ Re-use any of the published material for personal use and teaching without further permission

For information on Institutional Fellowships contact consortiasales@bmjgroup.com

Visit vetrecordcasereports.bvapublications.com for more articles like this and to become a subscriber