



Short communication

Thermal disbudding in goat kids in the Netherlands: Current practice, complications and considerations



R. Van den Brom^{a,*}, S. Greijdanus-van der Putten^b, M. Van der Heijden^c, K. Lievaart-Peterson^a, P. Vellema^a, J. De Grauw^d

^a Department of Small Ruminant Health, PO Box 9, 7400 AA Deventer, Netherlands

^b Department of Pathology, PO Box 9, 7400 AA Deventer, Netherlands

^c Veterinary Practice for Farm Animals (ULP), Reijerscopse Overgang 1, 3481 LZ Harmelen, Netherlands

^d Utrecht University, Department Equine Sciences, Netherlands

ARTICLE INFO

Keywords:

(Thermal) disbudding

Goat kids

Complications

Anaesthesia

ABSTRACT

Objectives of the present paper were to review the process of thermal disbudding in goat kids in the Netherlands. We describe possible complications and propose considerations and suggestions for best practice for disbudding of goat kids. Thermal disbudding of approximately one to two week old female dairy goat kids is common practice in Dutch dairy goat farming in order to prevent injuries and optimise use of feeding space. Thermal disbudding is a painful procedure. This should be addressed to prevent potential welfare problems as well as subsequent complications. This report describes current practice as well as complications noted following disbudding of goat kids in the Netherlands. Complications include failure to recover from anaesthesia as well as neurological symptoms and subsequent death up to two weeks after the procedure. Considerations for optimal disbudding management, including practical, legislative, technical, and anaesthesiologic concerns are briefly discussed. Data on both the safety and efficacy of local anaesthetic injections for disbudding in goat kids are scarce. Therefore, more field studies focusing on feasibility and efficacy of local anaesthetic approaches with or without sedation, and the use of NSAID's peri- and postoperatively, are recommended.

1. Introduction

Thermal disbudding of kids on Dutch dairy goat farms is, with the exception of some organic farms, standard practice to prevent fighting injuries and because disbudded does require less feeding space. Because of rapid horn development, disbudding is preferably performed within the first two weeks of life. Thermal disbudding is an inherently painful procedure that requires particular attention to prevent potential welfare problems and complications (Sanford, 1989; Thompson et al., 2005). Disbudding is considered a husbandry procedure that is allowed under Dutch legislation (2014), but 'anaesthetic administration' is required and must be performed by a qualified veterinarian. No minimum standard for peri-operative anaesthesia or analgesia has been laid down by law. According to Kwaliteit (sector wide good practice guidelines) (2019), post-operative analgesia should be administered according to farm-specific treatment protocols. In practice, the veterinarian will usually delegate supervision of recovery after disbudding to the farmer. However, the veterinarian remains responsible and legally liable for the entire procedure. Annually, farmers and veterinarians report

complications after thermal disbudding of goat kids to Royal GD (formerly GD Animal Health). Problems include failure to recover from anaesthesia, neurological symptoms, and sudden death in the weeks after disbudding. The exact incidence of problems during and after disbudding is unknown.

The aims of this short communication are to: 1) describe current standard practice for thermal disbudding of dairy goat kids in the Netherlands, 2) describe complications noticed at post mortem examination after thermal disbudding, and 3) propose considerations and suggestions for best practice with regard to this procedure.

2. Current standard practice for thermal disbudding of dairy goat kids in the Netherlands

Kids are on average 1–2 weeks old, and body weight varies from approximately 3–7 kg at the time of the procedure. Generally there are no facilities to provide supplemental heat, intravenous (IV) fluids or oxygen (which could constitute a fire hazard in conjunction with hot disbudding irons).

* Corresponding author.

E-mail address: r.vd.brom@gddeventer.com (R. Van den Brom).

Disbudding is performed with a gas- or electrically heated iron; alternative methods to thermal disbudding are currently prohibited under Dutch legislation. At present, the vast majority of dairy goat kids are disbudded under general anaesthesia. A commonly used total intravenous anaesthetic (TIVA) for this purpose consists of a pre-mixed combination of xylazine, ketamine and atropine (Table 2) as described by Pieterse and van Dieten (1995). A slightly modified version is currently used and taught by the farm animal ambulatory practice ('ULP') of the Faculty of Veterinary Medicine (Utrecht, the Netherlands; Table 2).

Local anaesthetic techniques such as simple infiltration or a ring block at each horn bud with procaine, or blocking the cornual branches of the infratrochlear and zygomaticotemporal nerves, are not routinely performed. The administration of an NSAID (IV or per os (PO)) during and/or after the procedure likewise is not yet standard of care.

3. Complications reported after thermal disbudding

Royal GD has regularly been consulted by veterinarians and farmers about goat kids not recovering from anaesthesia after disbudding. In most cases, pre-existing illness of individual kids or (relative) anaesthetic overdosage could not be excluded as possible causes. Annually, small numbers of goat kids are submitted for post mortem examination after disbudding. The available clinical information received is typically minimal and varies from "sudden death" to "neurological signs after disbudding", with variable timing up to two weeks after disbudding. The disbudding procedure is not always mentioned, but can be inferred from age and horn bud (dis)appearance.

Reported sudden deaths shortly after disbudding may be related to hypothermia, but also to anaesthesia-induced cardiopulmonary depression and resultant hypoxic organ damage. Death occurring more than a week following disbudding was often due to skull invasion of the thermal disbudding lesion. In latter cases, typical macroscopic findings include haemorrhage, exudative inflammatory signs and necrosis of the epidermis around the horn bud remnant and the subcutaneous tissue. In some cases, the bone of the skull was grossly damaged (Fig. 1a). Also, purulent inflammatory processes may be present at the cerebral meninges (Fig. 1b), and/or adhesions on the inside of the skull bone (Fig. 1c). At histopathology, an extensive purulent meningitis can be noted, sometimes with progression to malacia of brain tissue (1d), which can be caused by the influx of several more or less ubiquitous bacteria.

4. Considerations for thermal disbudding in goat kids

4.1. Physiological considerations

Although small ruminants mature quickly, the hepatic, renal and central nervous systems of goat kids less than two weeks of age have not yet reached full adult function (Baggot and Short, 1984). Cardiac output in neonates is very heart rate dependent, meaning bradycardia is poorly tolerated. The neonatal thorax is very compliant, which leads to small airway collapse during normal tidal breathing, and higher work of breathing. Due to small body weight, little to no fat reserves and low liver glycogen stores, goat kids are susceptible to hypoglycaemia, hypothermia, and relative or absolute (in case of dosage errors) anaesthetic overdose (Schwark, 1992).

4.2. Anaesthetic considerations

Ideally, a local anaesthetic technique supplemented with systemic analgesics would be used, as this avoids cardiopulmonary and central nervous system depression. Reasons cited to omit local anaesthetic blocks include: concerns regarding local anaesthetic (procaine) toxicity, perceived lack of benefit, and doubts about practical feasibility (Pieterse and Van Dieten, 1995). Alternatively, a short-acting and/or

reversible general anaesthetic could be used. Inhalant agents are short-acting and reversible, but do not provide post-procedural analgesia and require equipment that is not available in the field (Matthews, 2009). Since dairy goats are food producing animals, many suitable injectable agents (like benzodiazepines, low-dose propofol and/or opioids) cannot be used by law; neither can specific alpha-2 receptor antagonists like atipamezole. Available agents allowed for use in dairy goats in the Netherlands are shown in Table 1.

The currently common use of a TIVA mixture of xylazine, ketamine and atropine (Table 1) is disputable in several ways. In principle, performing a very brief locally painful procedure under relatively long-acting general anaesthesia in a neonate without careful monitoring or support is undesirable. As for the drugs, goats are known to be very sensitive to xylazine and due to their small size, kids are very easily overdosed. In theory, one would rather avoid the use of alpha-2 agonists altogether in neonates, as they cause bradycardia and reduce cardiac output. While ketamine and xylazine both provide analgesia, full recovery may take up to one hour, during which kids are prone to hypothermia, hypoglycaemia and/or hypoventilation, which may all contribute to failure to recover from anaesthesia. Inclusion of atropine may cause saliva and airway secretions to become more viscous and harder to clear (Reid and Titchen, 1988). Its stimulatory effect on heart rate may increase blood pressure (Kokkonen and Eriksson, 1987) but also cardiac work load, a combination of effects that has been shown to trigger arrhythmias in dogs (Congdon et al., 2011). Many small ruminant anaesthesia texts warn for local anaesthetic toxicity in goat kids, stating they would be specifically sensitive to procaine or lidocaine (Matthews, 2009); however, no toxicity studies in goat kids have been reported to date. Procaine is the only local anaesthetic agent allowed for use in food producing ruminants in the Netherlands. In a field study in the UK where 99 goat kids (median body weight 5.3 kg) were disbudded after a procaine ring block at each horn bud (total dose 12.2–28.2 mg/kg procaine per kid), the procedure could be performed satisfactorily in the vast majority of animals, although transient muscle twitching and lethargy was noted in some (Pollard, 2008; Kathy Clarke, personal communication 2017). Given that local infiltration with more than 10 mg/kg procaine was apparently well tolerated in this study, relative anaesthetic overdose due to errors in weight estimation and/or drug preparation may be a much more likely cause of CNS signs after use of local anaesthetic agents than specific sensitivity of goat kids to these drugs. The efficacy of local nerve blocks for disbudding in goat kids is debated based on conflicting reports (Pollard, 2008; Alvarez et al., 2015). It is likely that blockade of specific nerve branches requires greater anatomic accuracy with small volumes of local anaesthetic, which may be one of the causes of poor efficacy noted in the latter experimental study. The one prerequisite noted in the UK field trial was that adequate time be permitted for the procaine to take effect; at least 20 min was deemed optimal (Pollard, 2008). Even in the absence of placebo-controlled studies conclusively proving the value of local blocks for disbudding in goat kids, one would argue that simple local anaesthetic infiltration should be included on ethical grounds, as it is a safe, easy, affordable, and minimally invasive technique that can reduce acute pain from disbudding (Winder et al., 2018). A similar rationale can be offered for the inclusion of an NSAID in the anaesthetic protocol. The impact of short-term NSAID use at recommended dosages on new-born kidney function in small ruminants appears to be limited (Ebenezar et al., 2007; Rac et al., 2006), while disbudding causes local tissue inflammation with consequent inflammatory pain that can be adequately treated with an NSAID. The requirement for such post-operative analgesia was evidenced by a study demonstrating reduced pain behaviour on day one after disbudding in kids treated with meloxicam (Ingvast-Larsson et al., 2011). In the UK, the British Veterinary Association and the Goat Veterinary Society have released a joint position paper endorsing the use of post-operative analgesia with meloxicam (BVA, 2018). The veterinary duty of provision of care during anaesthesia extends to the end of the recovery period. The recovery period is

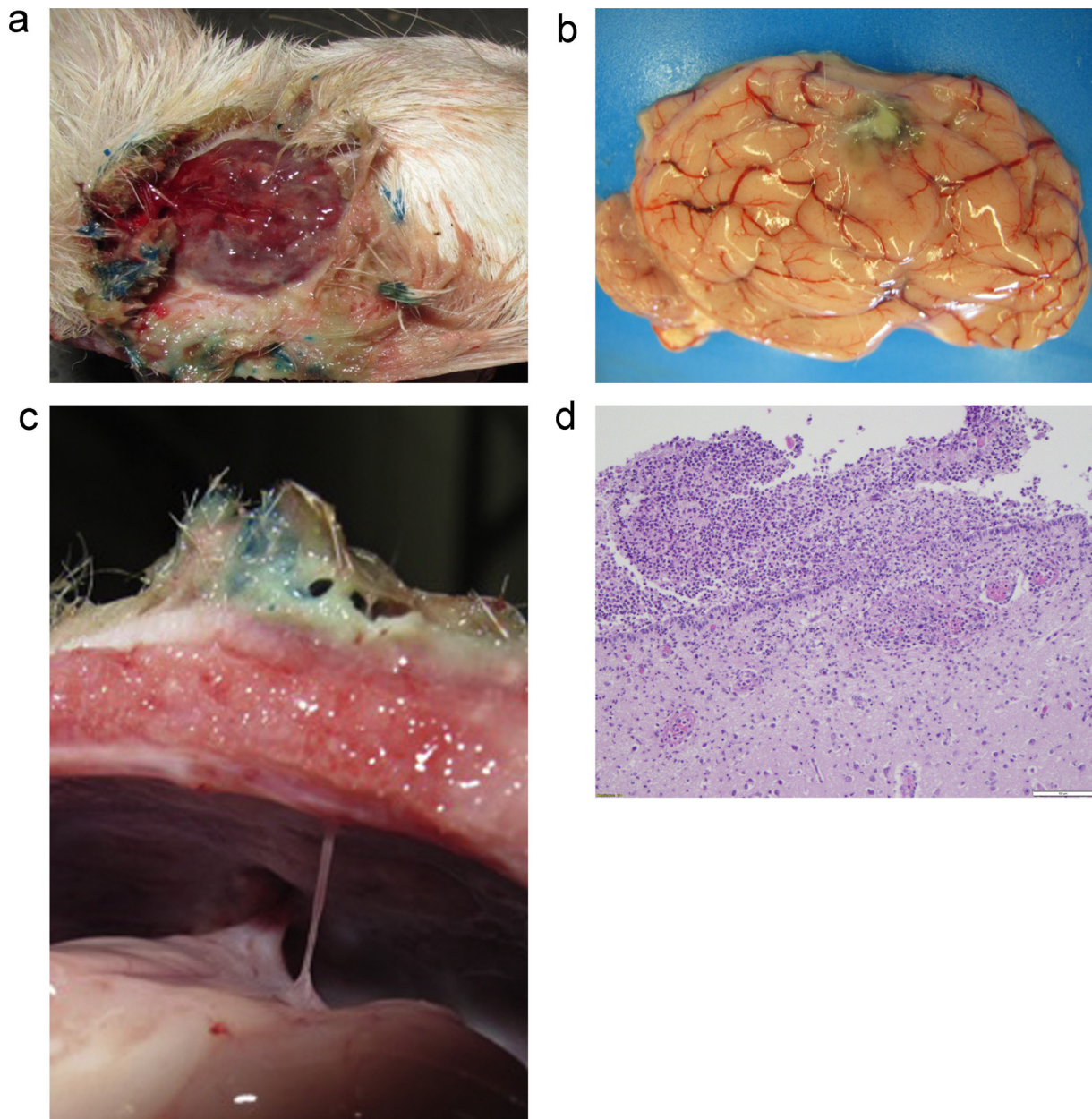


Fig. 1. a) Area of haemorrhage, exudate, and necrosis at the disbudded horn pit of a young goat kid. b) Focus of meningeal inflammation after thermal disbudding of a young goat kid. c) Adhesions (arrows) at the inside of the skull between cerebrium and bone after thermal disbudding of a young goat kid. d) Histopathology image of meningeal inflammatory changes and brain malacia.

Table 1
Available anaesthetic and analgesic drugs allowed for use in food producing goats under EU legislation (EC37/2010) in the Netherlands.

Drug	Registration status for goats	Marketing authorisation	Marketing authorisation species
Xylazine	extra label	yes	cattle
Ketamine			
Procaine (2 %, and 4 % with adrenalin)		yes	sheep
Sodium salicylate	extra label	yes	cattle
Ketoprofen	extra label	yes	cattle
Flunixin	extra label	yes	cattle
			(currently suspended)
Meloxicam	extra label	yes	cattle

the time that most anaesthetic deaths and complications are noted in veterinary anaesthesia (Brodgelt et al., 2008). Lack of adequate supervision and/or support during this period seems to contribute to the high percentage of fatalities.

4.3. Technical considerations

Although in terms of anaesthesia one would rather delay disbudding until kids are at least two weeks old, this is undesirable as the rapid

Table 2
Goat anaesthetic TIVA mixtures commonly used in the Netherlands.

	Pieterse and van Dieten (1995)	ULP
20x diluted xylazine hydrochloride (0.1 % = 1 mg/mL)*	1.6 mL	1.6 mL
Ketamine (10 % = 100 mg/mL)*	4.0 mL	4.0 mL
Atropine*	0.8 mL (0.5 % = 5 mg/mL)	2.4 mL (0.1 % = 1 mg/mL)
Aqua dest	1.6 mL	
Total	8.0 mL	8.0 mL

Table 2 shows the composition of the 'goat anaesthetic mixture' as described by Pieterse and van Dieten (1995) and the 'goat anaesthetic mixture' as currently used and taught by the Utrecht University farm animal ambulatory practice ('ULP'). The dosage regime for both 'goat anaesthetics' is 0.2 mL/kg body weight. The anaesthetics can be administered subcutaneously, intramuscularly or intravenously. Within a couple of minutes, depending of the route of administration, kids are unable to stand, after twelve to fifteen minutes thermal disbudding can be performed, and 45 min after injection, kids are able to stand (Pieterse and van Dieten, 1995).

* Maximum Residual Level (MRL) determined and described in http://www.ema.europa.eu/ema/index.jsp?curl=pages/medicines/landing/vet_mrl_search.jsp.

development of the horn buds will limit the ability to remove them completely, leading to (painful) malformed horny outgrowths. Hair growth over the horn bud may also hinder effective disbudding. Thermal disbudding should be performed as briefly as possible, with skull contact time minimized (5 s has been noted as a maximum; Pieterse and Van Dieten, 1995), because the skull of goat kids is very thin and can easily be penetrated (Thompson et al., 2005). Alternatives for thermal disbudding such as a local injection with clove oil in order to prevent horn growth have recently been described and investigated (Molaei et al., 2015; Hempstead et al., 2018), but will need further study before application on a larger scale can be considered. These and other alternatives may in fact not be permitted according to local legislation.

5. Recommendations and suggestions for best practice in thermal disbudding of goat kids

5.1. Anaesthesia

5.1.1. Pre-anaesthetic examination and preparation

Goat kids should be briefly examined to ensure they are in good general health, and an accurate body weight must be obtained. Fasting for more than one hour is not advised in order to prevent hypoglycaemia.

5.1.2. Local block

Infiltration with a local anaesthetic at the base of each horn bud is recommended. Procaine is currently the only agent allowed in the Netherlands for this use. As a safety measure in the absence of species and age-specific toxicity studies it seems wise to limit the total dose of procaine for local infiltration to 10 mg/kg; this equates to 2.5 mL of a 2 % solution (1.25 mL per side) or 3.5 mL of a 1.33 % solution (4 % procaine + adrenaline diluted 1:2 with saline) for a 5 kg goat kid. Disbudding is ideally performed 20 min after procaine injection – this must be taken into account when performing disbudding in groups of animals at a time.

5.1.3. Injectable anaesthetics

Systemic injectable anaesthetics may be useful for disbudding to provide analgesia, reduce the stress of handling, and to ensure accurate placement of local blocks as well as the disbudding iron. A practical

approach for Dutch veterinarians used to working with the TIVA mixture described by Pieterse and Van Dieten (1995) could be to combine an IV or IM injection with a low dose of xylazine (0.02 mg/kg, i.e. 0.1 mL of a 20x diluted 2 % solution for a 5 kg kid) and ketamine (0.5–1 mg/kg; 0.25 - 0.5 mL of a 10x diluted 10 % solution for a 5 kg kid) with a local block at each horn bud as described above. Ideally, the practical efficacy of this approach, including the actual need for any systemic xylazine and/or ketamine use, needs to be tested under field conditions at (Dutch) dairy goat farms.

5.1.4. Recovery

Recovery should take place in a clean, warm, and draught-free environment. Preventing kids from hypothermia and huddling together, which may contribute to hypoventilation and potential asphyxia, is important. Therefore, surrounding and floor temperature should be sufficient and it is advised never to leave goat kids unsupervised until they are completely awake and able to stand.

5.1.5. Post-operative analgesia

Administration of an NSAID (e.g., meloxicam 0.5 mg/kg IV/IM/SC or 2 mg/kg PO loading dose, followed by 0.5 mg/kg IM or SC after disbudding) is highly recommended. Application of a topical anesthetic spray following disbudding may be beneficial, but effects may vary depending on tissue exposure / penetration; also, this will not provide intra-operative analgesia.

5.2. Disbudding

Both electrical and gas-heated irons can be used. Hair around the horn base must be removed before thermal disbudding with a hot (!) iron, and a diameter of the instrument of at least 2 cm (for male kids even a minimum of 2.5 cm) is recommended. Skull contact time should be limited to 5 s with the whole horn bud removed, and tetanus prophylaxis must be administered if maternal vaccination status or colostrum intake is artificial, unknown or insufficient.

5.3. Follow-up studies

A justification for the routine practice of disbudding should be provided by a study identifying the baseline level of horn related injuries in non-disbudded herds at Dutch dairy goat farms. This could help establish whether the problem of horn-related injury is of sufficient frequency and magnitude to justify disbudding or not. Data on both the safety and efficacy of local anaesthetic injections for disbudding in goat kids are scarce. These blocks can be performed safely but appear to be underutilized. We identified a need for field studies that may help confirm the safety, efficacy and feasibility in Dutch dairy goat practice of performing local infiltration with procaine at the horn bud, with or without the currently common systemic administration of xylazine and/or ketamine, for routine thermal disbudding. A similar field study may help to further clarify the cost-benefit ratio of providing an NSAID, like meloxicam, peri- and postoperatively.

6. Concluding remarks

Veterinarians should be aware of considerations for optimal disbudding management, including practical, legislative, technical, and anaesthesiological concerns.

Declaration of Competing Interest

The authors have nothing to disclose.

References

Alvarez, L., De Luna, J.B., Gamboa, D., Reyes, M., Sánchez, A., Terrazas, A., Rojas, S.,

- Galindo, F., 2015. Cortisol and pain-related behavior in disbudded goat kids with and without cornual nerve block. *Physiol. Behav.* 138, 58–61.
- Baggot, J.D., Short, C.R., 1984. Drug disposition in the neonatal animal, with particular reference to the foal. *Equine Vet. J.* 16, 364–367.
- Brodgelt, D.C., Pfeiffer, D.U., Young, L.E., Wood, J.L., 2008. Results of the confidential enquiry into perioperative small animal fatalities regarding risk factors for anesthetic-related death in dogs. *J. Am. Vet. Med. Assoc.* 233, 1096–1104.
- BVA, 2018. *BVA Policy Position on Goat Kid Disbudding and Analgesia*. August 2018, v1. https://www.bva.co.uk/uploadedFiles/Content/News_campaigns_and_policies/Policies/Ethics_and_welfare/goatdisbudding.pdf.
- Clarke, K., 2017. Personal Communication on UK Field Study in 99 Dairy Goat Kids Performed by Pollard (2008).
- Congdon, J.M., Marquez, M., Niyom, S., Boscan, P., 2011. Evaluation of the sedative and cardiovascular effects of intramuscular administration of dexmedetomidine with and without concurrent atropine administration in dogs. *J. Am. Vet. Med. Assoc.* 239, 81–89.
- Dutch legislation, 2014. http://wetten.overheid.nl/BWBR0035091/2016-09-01#Hoofdstuk2_Paragraaf1_Artikel2.3 (website in Dutch).
- Ebenezar, K.K., Ghane, F.S., Smith, F.G., 2007. Effects of indomethacin on systemic and renal haemodynamics in conscious lambs. *Exp. Physiol.* 92, 575–581.
- Hempstead, M.N., Waas, J.R., Stewart, M., Cave, V.M., Sutherland, M.A., 2018. Evaluation of alternatives to cauterization of dairy goat kids using physiological measures of immediate and longer-term pain. *J. Dairy Sci.* 101, 5374–5387.
- Ingvast-Larsson, C., Högberg, M., Mengistu, U., Olsén, L., Bondesson, U., Olsson, K., 2011. Pharmacokinetics of meloxicam in adult goats and its analgesic effect in disbudded kids. *J. Vet. Pharmacol. Ther.* 34, 64–69.
- Kokkonen, U.M., Eriksson, L., 1987. Cardiovascular and allied actions of xylazine and atropine in the unanaesthetized goat. *J. Vet. Pharmacol. Ther.* 10, 11–16.
- Kwaligeit, 2019. <https://www.ngzo.nl/kwaligeit> (website in Dutch).
- Matthews, J., 2009. *Diseases of the Goat*, third edition. Wiley Blackwell ISBN: 978-1-444-35803-2.
- Molaei, M.M., Mostafavi, A., Kheirandish, R., Azari, O., Shaddel, M., 2015. Study of disbudding goat kids following injection of clove oil essence in horn bud region. *Vet. Res. Forum* 6, 17–22.
- Pieterse, M.C., van Dieten, J.S., 1995. [Dehorning of goats and kids]. *Tijdschr. Diergeneesk.* 15 (120), 36–38 (Article in Dutch).
- Pollard, V., 2008. *Potential Toxicity and Efficacy of Local Anaesthetic When Used for Disbudding in the Goat Kid*. B. Vet. Med. Dissertation 2008. University of London, London.
- Rac, V.E., Small, C., Scott, C.A., Adamson, S.L., Rurak, D., Challis, J.R., Lye, S.J., 2006. Meloxicam effectively inhibits preterm labor uterine contractions in a chronically catheterized pregnant sheep model: impact on fetal blood flow and fetal-maternal physiologic parameters. *Am. J. Obstet. Gynecol.* 195, 528–534.
- Reid, A.M., Titchen, D.A., 1988. Atropine-resistant secretory responses of the ovine parotid gland to reflex and direct parasympathetic stimulation. *Q. J. Exp. Physiol.* 73, 413–424.
- Sanford, S.E., 1989. Meningoencephalitis caused by thermal disbudding in goat kids. *Can. Vet. J.* 30, 832.
- Schwark, W.S., 1992. Factors that affect drug disposition in food-producing animals during maturation. *J. Anim. Sci.* 70, 3635–3645.
- Thompson, K.G., Bateman, R.S., Morris, P.J., 2005. Cerebral infarction and meningoencephalitis following hot-iron disbudding of goat kids. *N. Z. Vet. J.* 53, 368–370.
- Winder, C.B., Miltenburg, C.L., Sargeant, J.M., LeBlanc, S.J., Haley, D.B., Lissemore, K.D., Godkin, M.A., Duffield, T.F., 2018. Effects of local anesthetic or systemic analgesia on pain associated with cauterization of dairy goat kids: a systematic review and meta-analysis. *J. Dairy Sci.* 101 (June (6)), 5411–5427. <https://doi.org/10.3168/jds.2017-14092>.