

REVIEW

Molecular pathology of tumors of the central nervous system

B. W. Kristensen^{1,2*}, L. P. Priesterbach-Ackley³, J. K. Petersen^{1,2} & P. Wesseling^{3,4,5*}

¹Department of Pathology, Odense University Hospital, Odense; ²Department of Clinical Research, University of Southern Denmark, Odense, Denmark; ³Department of Pathology, University Medical Center Utrecht, Utrecht; ⁴Princess Máxima Center for Pediatric Oncology, Utrecht; ⁵Department of Pathology, Amsterdam University Medical Centers/VU Medical Center, Amsterdam, The Netherlands

*Correspondence to: Prof. Bjarne W. Kristensen, Department of Pathology, Odense University Hospital, J. B. Winsloews Vej 15, 3 Floor, 5000 Odense C, Denmark. Tel: +45-23963602; E-mail: bwk@rsyd.dk

Prof. Pieter Wesseling, Department of Pathology, Amsterdam University Medical Centers/VU Medical Center, De Boelelaan 1107, 1081 HV Amsterdam, The Netherlands. Tel: +31-20-4444979; E-mail: p.wesseling@vumc.nl

Since the update of the 4th edition of the WHO Classification of Central Nervous System (CNS) Tumors published in 2016, particular molecular characteristics are part of the definition of a subset of these neoplasms. This combined 'histo-molecular' approach allows for a much more precise diagnosis of especially diffuse gliomas and embryonal CNS tumors. This review provides an update of the most important diagnostic and prognostic markers for state-of-the-art diagnosis of primary CNS tumors. Defining molecular markers for diffuse gliomas are *IDH1/IDH2* mutations, 1p/19q codeletion and mutations in histone H3 genes. Medulloblastomas, the most frequent embryonal CNS tumors, are divided into four molecularly defined groups according to the WHO 2016 Classification: wingless/integrated (WNT) signaling pathway activated, sonic hedgehog (SHH) signaling pathway activated and tumor protein p53 gene (*TP53*)-mutant, SHH-activated and *TP53*-wildtype, and non-WNT/non-SHH-activated. Molecular characteristics are also important for the diagnosis of several other CNS tumors, such as *RELA* fusion-positive subtype of ependymoma, atypical teratoid rhabdoid tumor (AT/RT), embryonal tumor with multilayered rosettes, and solitary fibrous tumor/hemangiopericytoma. Immunohistochemistry is a helpful alternative for further molecular characterization of several of these tumors. Additionally, genome-wide methylation profiling is a very promising new tool in CNS tumor diagnostics. Much progress has thus been made by translating the most relevant molecular knowledge into a more precise clinical diagnosis of CNS tumors. Hopefully, this will enable more specific and more effective therapeutic approaches for the patients suffering from these tumors.

Key words: CNS tumor, molecular pathology, glioma, medulloblastoma, embryonal tumor, integrated diagnosis

Introduction

Up until the 4th edition of World Health Organization (WHO) Classification of Central Nervous System (CNS) Tumors that was published in 2007 [1], definitions of CNS tumor entities were mainly based on histological characteristics and resemblance with a supposed cell type of origin. This approach was increasingly supplied by panels of immunohistochemical markers giving information on differentiation and proliferation. Although many microscopy-based diagnoses were and still are rather robust, review panels have revealed considerable diagnostic inter-observer variation with a danger of detrimental consequences for patients

[2, 3]. This situation prompted the identification and implementation of more robust diagnostic markers.

The tremendous increase in knowledge of the molecular characteristics of CNS tumors during the last decade has allowed for a paradigm shift. In the update of the 4th edition of the WHO classification CNS tumors published in 2016 [4], molecular aberrations are part of the definition of particular brain tumor entities for the first time. Especially, the classification of the most frequent primary neoplasms of the CNS parenchyma itself, the diffuse gliomas, has undergone major restructuring based on the status of a few key molecular aberrations. Similarly, major changes have been introduced in the classification of

medulloblastomas and some other embryonal tumors. This situation brings new challenges for the work-up of these tumors. Meanwhile, technology continues to develop along with reduced costs of molecular diagnostic platforms. This, combined with the possibility to make a ‘molecular diagnosis’ based on immunohistochemical analysis, brings a state-of-the-art, integrated morphological and molecular diagnosis of CNS tumors within reach of an increasing number of centers.

In this review, the most significant developments with respect to molecular diagnosis of primary tumors of the CNS are highlighted, with a strong focus on markers conveying diagnostic and/or prognostic information. An overview of these markers is given in Tables 1–3. Some of these diagnostic and/or prognostic markers may provide leads for specific therapeutic management, an aspect that is briefly covered in this review as well. For more detailed information on purely predictive markers for the efficacy of particular therapeutic approaches such as targeted treatment, the reader is referred to other reviews [5–8]. For a recent overview of the molecular diagnostic tools that may be used, see our recent review on this topic [9].

Gliomas

Gliomas comprise a very heterogeneous group of primary CNS tumors, originally classified according to their microscopic similarity with or presumed origin of non-neoplastic glial (precursor) cells (e.g. astrocytes—astrocytoma; oligodendroglial cells—oligodendroglioma; ‘glioblast’—glioblastoma). Gliomas are traditionally divided into two major categories: ‘diffuse’ gliomas and ‘non-diffuse’ gliomas. Diffuse gliomas are characterized by tumor cell migration over large distances into the CNS parenchyma, thereby precluding curative surgical resection. Diffuse gliomas have for decades been diagnosed as diffuse astrocytomas and oligodendrogliomas, or as tumors with a mixed astrocytic and oligodendroglial phenotype (oligoastrocytomas). In addition, a malignancy grade was assigned based on the presence or the absence of marked mitotic activity, necrosis and/or florid microvascular proliferation. In contrast to diffuse gliomas, non-diffuse gliomas are generally much more circumscribed. Examples from this category are pilocytic astrocytoma and different variants of ependymoma. Now, molecular information helps to categorize glial tumors into different diffuse and non-diffuse glioma entities as explained below.

Discovery of 1p/19q codeletion as a marker for oligodendroglial tumors

In 1994, it was reported that many oligodendroglial tumors show loss of heterozygosity (LOH) for the short arm of chromosome 1 (1p) and the long arm of chromosome 19 (19q) [10]. Soon after, it became clear that 1p/19q codeletion is associated with sensitivity to procarbazine–lomustine–vincristine (PCV) chemotherapy and improved outcome [11]. Since then, testing for the presence/absence of this codeletion has increasingly been used for recognition of this subset of diffuse gliomas.

Discovery of isocitrate dehydrogenase mutations

The discovery of point mutations in the isocitrate dehydrogenase 1 and 2 (*IDH1/IDH2*) genes by large scale next-generation sequencing (NGS) in glioblastomas [12], and soon after also in lower grade diffuse gliomas [13–16], has been a major driver of classifying diffuse gliomas on a molecular basis. *IDH1/IDH2* mutations were found at low frequency in glioblastomas but at much higher frequencies in WHO grade II and III diffuse astrocytomas, oligodendrogliomas, and oligoastrocytomas. The glioblastomas with *IDH1/IDH2* mutations were later on considered to be ‘secondary’ glioblastomas originating from such lower grade diffuse gliomas, and the IDH-wildtype glioblastomas as ‘*de novo*’ or ‘primary’ glioblastomas [12, 14, 17]. Patients with an IDH-mutant glioblastoma generally showed substantially longer overall survival than those with IDH-wildtype glioblastoma [12]. This prognostic impact of IDH mutation was later confirmed for WHO grade II and III diffuse gliomas [13–16]. In fact, the impact of IDH mutation on survival was so pronounced that the overall survival for patients with IDH-wildtype anaplastic astrocytoma (WHO grade III) was found to be worse than for patients with IDH-mutant glioblastoma (WHO grade IV) [18]. IDH mutations are considered to be the initiating event in the oncogenesis of IDH-mutant gliomas [19]. The mutant IDH protein is a tumor-specific neoantigen/immunogenic epitope and may represent a promising therapeutic target, especially the *IDH1* R132H mutation, which accounts for ~90% of the IDH mutations in gliomas [16, 20, 21]. Mutation-specific antibodies allow for a very reliable detection of IDH1 R132H protein [17, 18].

Impact of 1p/19q codeletion and IDH mutations on WHO classification

Based on the above described findings, the following three major categories of diffuse gliomas have been defined in the WHO 2016 Classification of CNS tumors:

- diffuse astrocytic tumors (astrocytoma/anaplastic astrocytoma/glioblastoma), IDH-wildtype;
- diffuse astrocytic tumors (astrocytoma/anaplastic astrocytoma/glioblastoma), IDH-mutant;
- oligodendroglial tumors (oligodendroglioma/anaplastic oligodendroglioma), IDH-mutant and 1p/19q-codeleted.

The armamentarium required to adequately diagnose diffuse gliomas has thus become more complex. Recognizing that molecular testing cannot always be carried out due to lack of resources or suboptimal quality/quantity of the tissue samples, a ‘not otherwise specified’ (NOS) category has been introduced in the WHO 2016 Classification for cases in which relevant molecular information is not available because molecular testing could not (successfully) be carried out [22].

Other molecular markers in diffuse gliomas - *TERT* promoter, *ATRX* and *TP53* mutations

Almost all IDH-mutant, 1p/19q-codeleted oligodendroglial tumors have activating mutations in the telomerase reverse transcriptase gene (*TERT*) promoter region [23–25], making this genetic aberration a valuable diagnostic marker in the right context. However, these mutations are also frequent in IDH-

Table 1. Genetic aberrations presented in alphabetical order for gliomas

| Genetic aberration | Diagnostic (D), prognostic (P) and therapeutic/predictive (T) value |
|---|--|
| <i>ATRX</i> mutation (Alpha-thalassemia/mental retardation syndrome X) | D Frequently present in IDH-mutant astrocytic tumors |
| <i>BRAF</i> V600E mutation (B-raf) | D Present in 65%–75% of pleomorphic xanthoastrocytomas, 25%–60% of gangliogliomas, and ~50% of epithelioid glioblastomas D Also found in dysembryoplastic neuroepithelial tumors, SEGAs, pilocytic astrocytomas T Possible therapeutic target |
| <i>CDKN2A/B</i> homozygous deletion (Cyclin-dependent kinase inhibitor 2A/B) | D Frequent feature in pleomorphic xanthoastrocytomas D Occurs in IDH-wildtype astrocytic tumors with piloid features P Associated with aggressive course in IDH-mutant diffuse astrocytic tumors |
| <i>CIC</i> mutation (Homolog of <i>capicua drosophila</i>) | D Present in majority of (but not specific for) oligodendroglial tumors |
| <i>EGFR</i> amplification/ <i>EGFRvIII</i> (Epidermal growth factor receptor) | D High copy number amplification common in IDH-wildtype glioblastomas (~40%) D <i>EGFRvIII</i> present in about half of <i>EGFR</i> -amplified glioblastomas T Possible therapeutic target |
| <i>FUBP1</i> mutation (Far upstream element binding protein) | D Present in a subset of oligodendrogliomas |
| H3 G34 mutation [H3 Histone Family Member 3A (H3F3A)] | D Occurs most often in high-grade, IDH-wildtype tumors in the cerebral hemisphere in young patients with glial or embryonal histology |
| H3 K27M mutation [H3 Histone Family Member 3A (H3F3A) or Histone Cluster 1 H3 Family Member B/C (HIST1H3B/C)] | D Required for the diagnosis 'diffuse midline glioma (DMG), H3 K27M-mutant' D Occasionally also found in other tumors such as posterior fossa ependymomas, gangliogliomas, pilocytic astrocytomas. P Signifies poor prognosis in DMG, H3 K27M-mutant (mean survival of +/- 9 months for both pediatric and adult patients); prognostic meaning in other tumors less clear T Potentially predictive of effect of EZH2 inhibitors |
| <i>IDH1/IDH2</i> mutation (Isocitrate dehydrogenase1/2) | D Frequent in WHO grade II and III astrocytomas (>80%), oligodendrogliomas and 'secondary' glioblastomas P IDH-mutant status of astrocytic tumor signifies better prognosis compared with that of IDH-wildtype astrocytic tumor with the histologically same WHO grade T <i>IDH1</i> R132H mutation may represent a promising target for mutation specific vaccination |
| <i>KIAA1549-BRAF</i> gene fusion (<i>KIAA1549</i> , uncharacterized; abbreviation for <i>BRAF</i> listed above) | D Present in ~70% of pilocytic astrocytomas D Also found in diffuse DLGNT, pilomyxoid astrocytoma and ganglioglioma D Rare in other gliomas |
| <i>MGMT</i> promoter hypermethylation (O-6-methylguanine–DNA methyltransferase) | P Reported as independent favorable prognostic factor in glioblastomas (irrespective of treatment) T Predictive for response to temozolomide |
| <i>RELA</i> fusion to <i>C11orf95</i> (V-rel avian reticuloendotheliosis viral oncogene homolog A) (<i>C11orf95</i> , uncharacterized) | D Defining feature for the diagnosis 'ependymoma, <i>RELA</i> fusion-positive' T <i>C11orf95-RELA</i> fusion protein potential therapeutic target |
| <i>TERT</i> promoter mutation (Telomerase reverse transcriptase) | D Present in almost all IDH-mutant, 1p/19q-codeleted oligodendrogliomas D Frequent in IDH-wildtype GBM D/P <i>TERT</i> promoter mutation in histologically lower-grade, IDH-wildtype astrocytoma indicates aggressive behavior ('molecular glioblastoma') |
| <i>TP53</i> mutation (Tumor protein p53) | D Frequent in IDH-mutant astrocytic tumors (>80%), but also quite frequent in IDH-wildtype diffuse gliomas; very infrequent in oligodendrogliomas |
| <i>YAP1</i> fusion (Yes-associated protein 1) | D Present in some supratentorial ependymomas, primarily in children P Generally favorable prognosis T Potential therapeutic target |
| 1p/19q codeletion [Short arm of chromosome 1(1p)] [Long arm of chromosome 19 (19q)] | D Required for diagnosis of 'canonical' oligodendroglioma (as it is the complete codeletion of these arms that counts, ideally the molecular test allows for discriminating complete from partial loss of 1p and 19q) |

Table 2. Genetic aberrations presented in alphabetical order for embryonal CNS tumors

| Genetic aberration | Diagnostic (D) and prognostic (P) value |
|---|---|
| <i>APC</i> mutation (may be germline) (Adenomatous polyposis coli) | D May occur in WNT-activated medulloblastomas |
| <i>BCOR</i> exon 15 internal tandem duplication (<i>BCL6</i> , corepressor/ <i>BCL6</i> , corepressor like 1) | D Described in subgroup of CNS embryonal tumors: ' <i>BCOR</i> -altered neuroepithelial tumor (<i>BCOR</i> -NET); N.B. Non-embryonal pediatric CNS tumors, esp. pediatric high-grade gliomas may show other <i>BCOR</i> (or <i>BCORL1</i>) alterations such as fusion, truncating mutation |
| <i>BRCA2</i> mutation (may be germline) (Breast cancer 2 gene) | D May occur in SHH-activated medulloblastoma and non-WNT/non-SHH medulloblastoma. |
| Chromosome 6 monosomy | D Present in ~85% of WNT-activated medulloblastomas |
| <i>CIC-NUTM1</i> gene fusion or <i>CIC</i> frameshift deletion (For <i>CIC</i> mutation, see Table 1, Genetic aberrations in gliomas) (<i>NUT</i> midline carcinoma family member 1) | D Characteristic of subgroup of CNS embryonal tumors described as Ewing's sarcoma family tumor with <i>CIC</i> alteration (EFT- <i>CIC</i>) |
| <i>CTNNB1</i> mutation (Catenin beta-1) | D Present in 90% of WNT-activated medulloblastomas P Children with WNT-activated medulloblastomas generally have a good prognosis |
| C19MC (19q13.42) alteration (amplification or fusion with <i>TTYH1</i>) (Tweety family member 1) | D High level amplicon is detected in majority of embryonal tumors with multilayered rosettes/ETMRs (specific and sensitive diagnostic marker for these tumors). |
| <i>DICER1</i> mutation (may be germline) (Dicer 1, ribonuclease III) | D Predisposing event to the development of a pituitary blastoma. |
| <i>FOXR2</i> fusion with different gene fusion partners (Forkhead box R2) | D Defining feature of subgroup of CNS embryonal tumors: 'CNS neuroblastoma with <i>FOXR2</i> activation' |
| <i>MN1</i> with different gene fusion partners [Meningioma (disrupted in balanced translocation)1] | D Defining feature of subgroup of CNS embryonal tumors described as 'high-grade neuroepithelial tumor with <i>MN1</i> alteration' (HGNET- <i>MN1</i>) P Better prognosis than other CNS embryonal tumors |
| <i>PALB2</i> (may be germline) (Partner and localizer of <i>BRCA2</i>) | D May occur in SHH-activated medulloblastoma and non-WNT/non-SHH medulloblastoma. |
| <i>PTCH1</i> (may be germline) (Patched 1) | D May occur in SSH-activated medulloblastoma |
| <i>SMARCB1/SMARCA4</i> loss (may be germline) (SWI/SNF related, matrix associated, actin dependent regulator of chromatin, subfamily B, member 1) (SWI/SNF related, matrix associated, actin dependent regulator of chromatin, subfamily A, member 4) | D Required for diagnosis of atypical teratoid/rhabdoid tumor (AT/RT) |
| <i>SUFU</i> mutation (may be germline) (Suppressor of fused homolog) | D May occur in SSH-activated medulloblastoma |
| <i>GAB1</i> (GRB2 associated binding protein 1) | D Surrogate marker for activated hedgehog signaling seen in SSH-activated medulloblastoma |
| <i>TP53</i> mutation (may be germline) (Tumor protein p53) | D Discriminates medulloblastoma, SSH-activated & <i>TP53</i> -mutant vs. SHH-activated & <i>TP53</i> -wildtype P Presence of a <i>TP53</i> mutation in SSH-activated medulloblastoma indicates poor prognosis |

wildtype glioblastomas [24]. In fact, in a histologically lower-grade, diffuse, IDH-wildtype astrocytoma the presence of a *TERT* promoter mutation and/or of epidermal growth factor receptor (*EGFR*) gene amplification and/or of combined gain of whole chromosome 7 plus loss of whole chromosome 10 signifies

behavior of the tumor as of glioblastoma (WHO grade IV) [23, 24]. Unlike IDH-mutant and 1p/19q-codeleted oligodendrogliomas, IDH-mutant astrocytic tumors frequently carry an alpha-thalassemia/mental retardation syndrome X-linked gene (*ATRX*) and a tumor protein p53 gene (*TP53*) mutation [26–28]. Loss of

Table 3. Genetic aberrations presented in alphabetical order for 'other' (i.e. non-gliial, non-embryonal) CNS tumors

| Genetic aberration | Diagnostic (D), and prognostic (P) value |
|--|---|
| <i>AKT1</i> mutation (AKT serine/threonine kinase 1) | D Associated with meningothelial and transitional variants of meningioma |
| <i>BRAF</i> V600E mutation (B-raf) | D Present in > 90% of papillary craniopharyngiomas |
| <i>CDKN2</i> inactivation (Cyclin-dependent kinase inhibitor 2A) | D Combined <i>CDKN2</i> and <i>NF1</i> inactivation is frequent in malignant peripheral nerve sheath tumors (MPNSTs) |
| <i>CTNNB1</i> mutation (Catenin beta 1) | D Present in >90% of adamantinomatous craniopharyngiomas |
| <i>DICER1</i> mutation (may be germline) (Dicer 1, ribonuclease III) | D Frequent in intracranial sarcomas with rhabdomyosarcoma-like features in children |
| <i>GNAQ/GNA11</i> hotspot mutation (Guanine nucleotide-binding protein) | D Frequent in primary melanocytic tumors of the CNS in adults (and uveal melanomas, but very infrequent in skin melanomas; therefore very helpful in differential diagnosis with metastatic cutaneous melanoma) |
| <i>KLF4</i> mutation (Kuppel like factor 4) | D Characteristic of secretory meningiomas |
| <i>NAB2-STAT6</i> gene fusion (NGFI-A Binding Protein 2) (Signal Transducer and Activator of Transcription 6) | D Typically found in CNS solitary fibrous tumors/hemangiopericytomas (CNS SFTs/HPCs); STAT6 staining of tumor cell nuclei is a very reliable immunohistochemical surrogate marker for presence of <i>NAB2-STAT6</i> fusion |
| <i>NF1</i> inactivation (Neurofibromin 1) | D Combined <i>NF1</i> and <i>CDKN2</i> inactivation is frequent in malignant peripheral nerve sheath tumors (MPNSTs) |
| <i>NRAS</i> mutation (Neuroblastoma RAS viral oncogene homolog) | D Occurs in primary melanocytic tumors of the CNS, especially in children |
| <i>SMARCE1</i> mutation (may be germline) (SWI/SNF related, matrix associated, actin dependent regulator of chromatin, subfamily E, member 1) | D Associated with clear cell meningiomas |
| <i>TERT</i> promoter mutation (Telomerase reverse transcriptase) | P Signifies more aggressive clinical behavior in meningiomas |
| <i>TRAF7</i> mutation (TNF receptor associated factor 7) | D Characteristic of secretory meningiomas |

nuclear ATRX immunohistochemical staining (IHC) is a strong predictor of presence of *ATRX* mutation [29], while strong and extensive nuclear staining of tumor cell nuclei for tumor protein p53 (p53) signifies presence of a *TP53* mutation.

Oligoastrocytomas

For decades, unequivocal histopathological delineation of oligoastrocytoma from astrocytoma or oligodendroglioma remained very difficult [2, 3]. Accumulation of molecular knowledge has now revealed that, at the molecular level, 'real oligoastrocytomas' are very rare. The WHO 2016 Classification still encompasses a diagnosis of (anaplastic) oligoastrocytoma, NOS. In the very rare cases in which both an IDH-mutant (and *ATRX/TP53*-mutant) astrocytic and an IDH-mutant, 1p/19q-codeleted component can be demonstrated, one may want to add that this denotes a molecularly-proven 'dual genotype' oligoastrocytoma [30–32].

Diffuse midline glioma, H3 K27M-mutant

Another new entity in the WHO 2016 Classification is 'diffuse midline glioma, H3 K27M-mutant'. This entity must harbor a K27M mutation in either the H3 Histone Family Member 3A (*H3F3A*) or Histone Cluster 1 H3 Family Member B/C (*HIST1H3B/C*) gene, have a glial phenotype, be located in the midline, and show a diffuse growth pattern. Both the morphological and molecular parts of the definition are important, since H3 K27M mutations are not exclusive to midline gliomas. Recent studies have identified H3 K27M mutations in, e.g. a subset of posterior fossa ependymomas [33] and rarely in gangliogliomas [34] and (anaplastic) pilocytic astrocytomas [35, 36]. H3 K27M mutation in these tumors seems to implicate more aggressive behavior.

Diffuse midline gliomas occur primarily in children, but may occur in adults as well [37]. Most of the tumors previously diagnosed as diffuse intrinsic pontine glioma are H3 K27M-mutant and thus belong to the 'diffuse midline glioma, H3 K27M-

mutant' entity. This tumor carries a very poor prognosis, with a 2-year survival rate below 10% [38, 39] and a mean survival of ~9 months [40, 41]. Presence of H3 K27M mutation can now also reliably be demonstrated using immunohistochemistry [37, 38].

RELA fusion-positive ependymoma

Until the WHO 2016 Classification, ependymal tumors were classified based on morphology, but the correlation between malignancy grade as assessed by histopathological examination and clinical behavior remained unclear [42, 43]. Based on DNA methylation profiling analysis, nine distinct molecular subgroups of ependymal tumors were reported (three in each of the following compartments: supratentorial, posterior fossa, and spinal canal) [44]. In the supratentorial compartment, 'ependymoma, v-rel avian reticuloendotheliosis viral oncogene homolog A (*RELA*) fusion-positive' was considered to be so distinct that it was designated a separate entity in the WHO 2016 Classification. These tumors are characterized by oncogenic fusions between *RELA*, the principal effector of canonical nuclear factor kappa-light-chain-enhancer of activated B cells (NF- κ B) signaling, and *C11orf95* (an uncharacterized gene). *RELA* fusion-positive ependymomas represent the majority of pediatric supratentorial ependymal tumors but can also occur in adults. L1 cell adhesion molecule (L1CAM) and cyclin D1 expression, as detected by immunohistochemistry, are useful but non-specific surrogate markers for *RELA* fusion-positive ependymomas [45].

Other molecular markers in gliomas

Detection of the B-raf proto-oncogene (*BRAF*) V600E mutation can be of value in the diagnosis of CNS tumors, its contribution depending on the exact differential diagnostic context. *BRAF* V600E mutation occurs in about half of all epithelioid glioblastomas [46, 47], pleomorphic xanthoastrocytomas and gangliogliomas, and in a smaller subset of subependymal giant cell astrocytomas (SEGAs), pilocytic astrocytomas and dysembryoplastic neuroepithelial tumors. Demonstration of *BRAF* V600E mutation in a tumor may provide a useful therapeutic target [48, 49].

The oncogenic *KIAA1549* and B-raf proto-oncogene (*KIAA1549-BRAF*) fusion is present in ~70% of pilocytic astrocytomas and has high differential diagnostic value as it is only found in the rare diffuse leptomeningeal glioneuronal tumor (DLGNT) and very rarely in other gliomas [50].

Most oligodendroglial tumors harbor drosophila homolog of capicua gene (*CIC*) mutations, and a smaller subset of far upstream element binding protein gene (*FUBP1*) mutations [28, 51, 52]. These mutations may be of differential diagnostic value but their prognostic meaning is so far unclear.

Glioblastomas were the first tumors for which an epigenetic biomarker came into clinical use. The DNA repair enzyme O-6-methylguanine-DNA methyltransferase (*MGMT*) removes the alkyl groups and thereby repairs the mutagenic DNA lesions, whereby DNA damage and apoptosis are prevented. Accordingly, promoter methylation of the *MGMT* gene has been found to be a useful predictive marker for the responsiveness to temozolomide [53]. Most clinical information on the impact of

hypermethylation of the *MGMT* promoter focusses on glioblastomas. Its implication for other (diffuse) gliomas is much less clear, also because in previous studies of patients with oligodendrogliomas PCV rather than temozolomide was used as chemotherapy, and treatment of histologically lower grade astrocytomas often did not include chemotherapy.

Emerging glioma entities

It is expected that more subgroups of gliomas will emerge as distinct entities in the near future. High-grade IDH-wildtype gliomas with an H3 G34 mutation (or, dependent on the nomenclature used, H3 G35 mutation) occur most often in the cerebral hemispheres in adolescents and young adult patients and may histologically show glioblastoma as well as embryonal tumor histology. While the microscopic phenotype is not associated with a clear difference in prognosis, presence of *MGMT* promoter methylation and lack of oncogene amplification has been reported to be associated with longer survival [54].

Another group of gliomas that may deserve its own 'entity' in CNS tumor classification are high-grade, IDH-wildtype astrocytic tumors with piloid features that relatively frequently occur in the posterior fossa of adult patients. Molecularly, these often show cyclin-dependent kinase inhibitor 2A/B gene (*CDKN2A/B*) deletion, mitogen-activated protein kinase pathway gene alteration and, somewhat less frequently, *ATRX* mutation [55].

In the overarching category of ependymomas, some new entities are emerging as well. Yes-associated protein 1 gene (*YAP1*) fusion-positive supratentorial ependymomas occur primarily in children and generally have a favorable prognosis [44]. Regarding ependymal tumors in the posterior fossa, based on methylation profiling analysis, group-A and group-B ependymomas can be identified, with, respectively, relatively poor and good prognosis. Recently, loss of global H3 K27 trimethylation (H3 K27me3), which can be detected by immunohistochemistry, has been reported to be very powerful tool for discriminating group A posterior fossa ependymomas from the group B tumors, the latter showing retained nuclear H3 K27me3 expression [56].

CNS embryonal tumors

In the WHO 2016 Classification, the term 'primitive neuroectodermal tumor' (PNET) has been replaced by 'CNS embryonal tumor', partly to avoid further confusion with non-CNS PNETs, and partly because the term PNET was increasingly used as a poorly defined waste basket. CNS embryonal tumors predominantly occur in children and are histologically characterized by very high cellularity with densely packed and poorly differentiated small cells that generally show a limited amount of cytoplasm, variable nuclear pleomorphism and marked mitotic activity. This category encompasses medulloblastomas, embryonal tumors with multilayered rosettes (ETMRs), atypical teratoid/rhabdoid tumors (AT/RTs) and a heterogeneous group of other embryonal CNS tumors.

Medulloblastomas

The vast majority of embryonal tumors in the posterior fossa are medulloblastomas. The histologic medulloblastoma subtypes

(classic, desmoplastic/nodular, extensive nodularity, large cell/anaplastic) described in the WHO 2016 Classification have not substantially changed compared with the WHO 2007 Classification [4, 57]. More recent studies, however, revealed particular molecular medulloblastoma subgroups and have showed that molecular and histological data provide complementary diagnostic information [4, 58, 59]. The WHO 2016 Classification proposes an integrated 'histo-molecular' diagnosis of medulloblastomas and lists four molecular groups:

WNT-activated. These tumors encompass ~10% of all medulloblastomas, and generally show the classic, but occasionally the large cell/anaplastic, phenotype. Over 90% of wingless/integrated (WNT)-activated medulloblastomas carry a beta-catenin gene (*CTNNB1*) mutation. Less frequently, mutations in other components of the WNT-signaling pathway, such as the axis inhibition protein 1 gene (*AXIN1*) and adenomatous polyposis coli gene (*APC*), are found. The defect in the WNT-signaling pathway results in nuclear accumulation of beta-catenin as can be demonstrated by immunohistochemistry. About 85% of the tumors in this group show monosomy for chromosome 6. Children with WNT-activated medulloblastomas generally have a good prognosis, but in adults the prognosis may be less favorable [60, 61].

Sonic hedgehog-activated and TP53-wildtype. About 30% of all medulloblastomas belong to the Sonic hedgehog (SHH)-activated group and the vast majority of these are *TP53*-wildtype. The nodular/desmoplastic and the much less frequently occurring extensive nodularity histologic subtype are almost exclusively found in this molecular group. These tumors occur predominantly in infants and adulthood and are considered low risk. Especially in younger patients, patched 1 gene (*PTCH1*) or suppressor of fused [(*SUFU*), *negative regulator of hedgehog signaling*] gene germline mutations may be found.

SHH-activated and TP53-mutant. A small percentage of SHH-activated medulloblastomas is *TP53*-mutant. These tumors occur predominantly in childhood, often show the large cell/anaplastic phenotype and have a poor prognosis. Up to half of the patients in this group have a *TP53* germline mutation [62].

Non-WNT/non-SHH. This last category encompasses the 'group 3 and group 4' molecular categories as recognized in multiple studies. Group 3 and group 4 medulloblastomas, representing, respectively, ~20% and 40% of all medulloblastomas, occur especially in infancy/childhood. Because in many centers, demonstration of these subcategories is still difficult due to a lack of easily accessible diagnostic tools, groups 3 and 4 are still included under the umbrella of the non-WNT/non-SHH molecular category in the WHO 2016 Classification. Histologically, these medulloblastomas are almost always of the classic or large cell/anaplastic phenotype.

Assessment of the molecular subtype of medulloblastoma can often be achieved by performing immunohistochemistry for (surrogate) markers like beta-catenin, GRB2 associated binding protein 1 (GAB1), YAP1, p53, homeobox protein OTX2 (OTX2) and/or low-affinity nerve growth factor receptor (p75NGFR) [63]. Across different histologic and molecular medulloblastoma

groups, v-Myc avian myelocytomatosis viral oncogene homolog (*MYC*) and/or v-Myc avian myelocytomatosis viral oncogene neuroblastoma-derived homolog (*MYCN*) are often amplified and may provide prognostic information, but the exact prognostic impact appears to be subgroup dependent [64, 65]. In ~5% of the children diagnosed with medulloblastoma, a germline mutation accounts for the development of the tumor. This is most frequently seen in the SHH-activated subgroup (*TP53*, *SUFU*, *PTCH1*), but can also be found in the WNT-activated subgroup (*APC*) and rarely based on partner and localizer of BRCA2 (*PALB2*) or BRCA2, DNA repair associated gene (*BRCA2*) germline mutation (in SHH-activated and non-WNT/non-SHH subgroups) [66]. In order to improve outcome and reduce side-effects, a molecularly driven, risk-adapted treatment approach is crucial and may necessitate further subgrouping of medulloblastomas [65, 67–69].

Atypical teratoid/rhabdoid tumors

AT/RT was already introduced as an entity in previous WHO classifications, but in the WHO 2016 Classification demonstration of an underlying defect in SWI/SNF related, matrix-associated, actin-dependent regulator of chromatin, subfamily B, member 1 gene (*SMARCB1*) or, rarely, SWI/SNF related, matrix-associated, actin-dependent regulator of chromatin, subfamily A, member 4 gene (*SMARCA4*) is now required for the diagnosis of canonical AT/RT. The products of these genes are essential components of the SWI/SNF chromatin remodeling complex. Defect function of *SMARCB1* or *SMARCA4* results in lack of nuclear staining for the intact integrase interactor 1 (INI1) or Brahma-related gene 1 (BRG1) protein, respectively [70]. In the WHO 2016 Classification, tumors with AT/RT phenotype but with INI1 and BRG1 nuclear staining are now designated CNS embryonal tumor with rhabdoid features. Further molecular subgrouping of AT/RTs may become clinically relevant, e.g. because of differences in therapeutic targets in these subgroups [71, 72].

Embryonal tumors with multilayered rosettes

'ETMR, C19MC-altered' has been introduced in the WHO 2016 Classification as a separate entity. In the past, these tumors were generally diagnosed as ependymoblastoma, medulloepithelioma, or embryonal tumor with abundant neuropil and true rosettes [73]. The C19MC alteration generally consists of a focal high-level amplicon of chromosome 19q13.42, covering a large microRNA cluster that can be detected by fluorescence *in situ* hybridization (FISH) or high-resolution cytogenetic techniques [74–76]. Strong and diffuse lin-28 homolog A (LIN28A) cytoplasmic immunostaining of tumor cells is a highly sensitive surrogate marker for 'ETMR, C19MC-altered', but medulloepitheliomas lacking the C19MC alteration and some other CNS tumors (e.g. gliomas, AT/RTs and germ cell tumors) can be LIN28A positive as well [77, 78]. ETMRs in which the C19MC status is not tested or demonstrated are designated in the WHO 2016 Classification as 'ETMR, NOS', or, in case of the medulloepithelioma phenotype, as medulloepithelioma.

Embryonal tumors of the pineal and pituitary region

Compared with other embryonal CNS tumors, pineoblastomas are reported to have fewer cytogenetic alterations. RB transcriptional corepressor 1 (*RB1*) mutations (+/– germline defect) and Dicer 1, ribonuclease III (*DICER1*) mutations are linked to pineoblastoma [79, 80]. Pituitary blastoma is an extremely rare embryonal tumor of the pituitary gland, with *DICER1* mutation as a key predisposing event [81]. Recently, it was reported that intracranial sarcomas with rhabdomyosarcoma-like features in children often carry a *DICER1* mutation as well (in some patients, a germline mutation without evidence of a cancer-related syndrome at the time of diagnosis) [82]. Pineal anlage tumors are very rare pineal tumors with an embryonal component combined with heterologous differentiation (e.g. skeletal muscle, chondroid differentiation) and often contain melanin. So far, no distinctive diagnostic molecular features of this tumor have been identified.

Other embryonal CNS tumors

Apart from the abovementioned embryonal tumors, the WHO 2016 Classification lists CNS neuroblastoma, CNS ganglioneuroblastoma and CNS embryonal tumor NOS. Meanwhile, detailed molecular (including methylation) analysis of tumors previously diagnosed as CNS PNET has revealed that some of these tumors could be reclassified as glioblastoma, ependymoma or Ewing sarcoma, and four new subgroups with recurrent gene fusions [83, 84]:

- CNS neuroblastoma with forkhead box R2 (*FOXR2*) activation (NB-*FOXR2*), typically showing *FOXR2* fusions.
- High-grade neuroepithelial tumor with meningioma 1 gene (*MNI*) alteration (HGNET-*MNI*), often carrying an *MNI* fusion that can be identified by FISH using an *MNI* break apart probe. These tumors may have an astroblastoma-phenotype and are reported to be associated with a somewhat less grim prognosis compared with other embryonal CNS tumors.
- Ewing sarcoma family tumor with *CIC* alteration (EFT-*CIC*), typically characterized by structural variants involving *CIC* that can be detected by break-apart FISH (in case of *CIC-NUTM1* fusion) or RNA sequencing (in case of *CIC* frameshift deletion) and positive NUT Midline Carcinoma Family Member 1 (*NUTM1*) nuclear immunohistochemistry as a surrogate marker.
- *BCL6* corepressor (*BCOR*)-altered neuroepithelial tumor (*BCOR*-NET), characterized by typically an internal tandem repeat in the *BCOR* gene.

Further study is necessary to assess the exact clinical significance of such a refined classification of ‘other embryonal CNS tumors’. Also, since e.g. EFT-*CIC* and *BCOR*-NET are not limited to the CNS, these tumors may in fact represent malignant mesenchymal tumors/sarcomas [64].

‘Other’ (non-glial, non-embryonal) primary CNS tumors

The group of ‘other’ primary CNS tumors encompasses a very heterogeneous collection of neoplasms, including meningiomas (malignant) peripheral nerve sheath tumors, primary melanocytic tumors of the CNS, and craniopharyngiomas. Hematologic tumors and

neoplasms of the soft tissues and bone occur elsewhere in the body as well and are beyond the scope of this review. Further information on these tumors can be found in the respective WHO classifications [85, 86]. Pituitary adenomas, by far the most frequent pituitary tumors, are dealt with in the WHO Classification of endocrine neoplasms and are also not further discussed. Immunohistochemical transcription termination factor 1 (TTF1) nuclear staining is very helpful for the diagnosis of primary neurohypophyseal tumors including granular cell tumor, pituicytoma and spindle cell oncocytoma. Meanwhile, molecular diagnostics so far does not yet play an important role in the clinical diagnosis of most pituitary neoplasms [87]. Also, the diagnosis of the heterogeneous group of primary CNS germ cell tumors generally does not yet require molecular diagnostics.

Regarding ‘meningiomas’, there is now increasing evidence that presence of a *TERT* promoter mutation signifies more aggressive clinical behavior [88, 89]. Furthermore, some mutations are clearly associated with particular histological phenotypes (secretory meningioma-combined kruppel like factor 4 gene (*KLF4*) and TNF receptor associated factor 7 (*TRAF7*) mutations [90, 91]; clear cell meningioma—*SMARCE1* (germline) mutation [92]; meningothelial and transitional meningioma—AKT serine/threonine kinase 1 gene (*AKT1*) mutations [93, 94]). Recently, DNA methylation profiling was reported to allow for better prediction of tumor recurrence/prognosis compared with WHO grading [95]. This potentially influences the clinical follow-up plan and whether patients should be offered radiotherapy. However, according to the WHO 2016 Classification, molecular analysis is not yet required for the diagnosis of meningiomas. Re-evaluation of previous clinical trials combined with information obtained by future clinical studies is necessary to address more precisely how DNA methylation profiling and other molecular alterations can help to improve the therapeutic management of these patients [96].

High-grade ‘malignant peripheral nerve sheath tumors’ (MPNSTs) frequently show combined inactivation of neurofibromin gene 1 (*NF1*), *CDKN2A*, and of the polycomb repressive complex 2 (PRC2) complex, irrespective if it concerns sporadic, radiation-induced or *NF1*-associated tumors. Loss of H3 K27me3 nuclear staining is now used as an important aid in the diagnosis of MPNSTs [97–99]. For cases with a challenging differential diagnosis between a benign and malignant nerve sheath tumor, this marker helps to increase the number of patients being treated based on the correct diagnosis [100]. Other immunohistochemical markers that may be helpful in this realm are neurofibromin (the product of *NF1*) [97, 101], EGFR, *CDKN2A* (p16), SRY-Box 10 (*SOX10*) [102] and in some cases INI-1 [103, 104].

As ‘CNS solitary fibrous tumors/hemangiopericytomas’ (SFTs/HPCs), like SFTs elsewhere in the body, typically show gene fusion between NGFI-A Binding Protein 2 gene (*NAB2*) and signal transducer and activator of transcription 6 gene (*STAT6*) (*NAB2-STAT6*), they are now considered as tumors that may show differences in histology but belong to the same entity. In order to ‘smoothen’ the transition towards a new classification, these tumors are still listed in the WHO 2016 Classification as SFT/HPC, rather than just SFT as is done in the WHO classification of soft tissue tumors. *NAB2-STAT6* fusion results in aberrant accumulation of STAT6 protein in tumor cell nuclei, which can reliably be demonstrated by simple STAT6 immunohistochemistry.

In adult patients, activating *GNAQ* or *GNA11* hotspot mutations are frequent in ‘primary melanocytic tumors of the CNS’

Illustration of integrated workflow for pathological diagnosis of (CNS) tumors

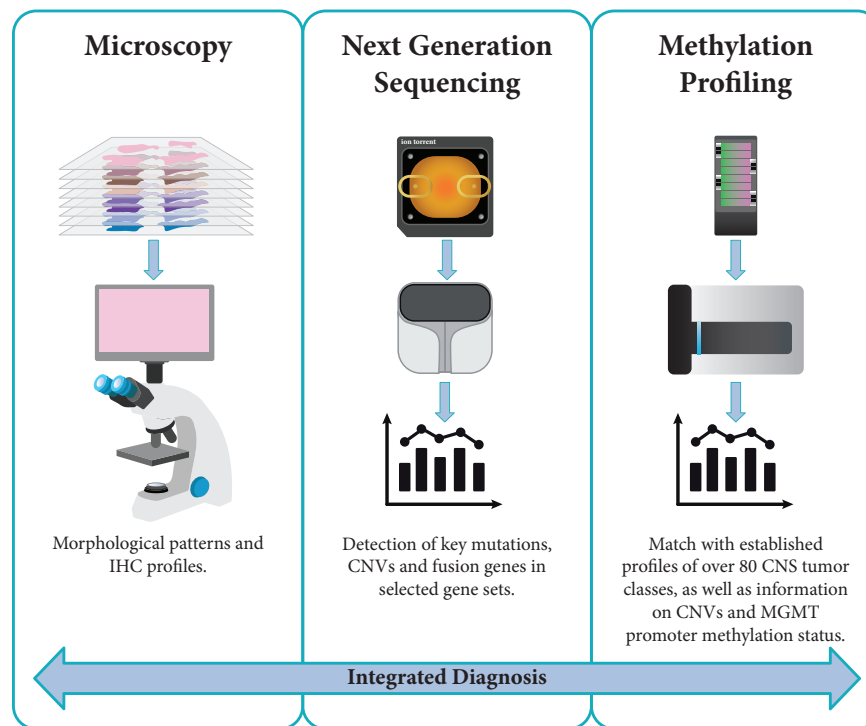


Figure 1. The integrated diagnostic workflow used in CNS tumor diagnostics depicted here is based on novel molecular platforms for next-generation sequencing (NGS) and genome-wide DNA methylation profiling besides conventional microscopy. Microscopy for standard histological evaluation includes panels of immunohistochemical staining (IHC) and in some laboratories also FISH analyses. NGS panels with selected genes allow for the detection of mutations, copy number variations (CNVs) and gene fusions. Genome-wide DNA methylation profiling is a novel approach with high potential as a support tool for a more refined and robust classification of CNS tumors.

(melanocytomas, melanomas). Thereby, these CNS tumors closely resemble uveal melanomas at the molecular level. Demonstration of guanine nucleotide-binding protein gene (*GNAQ* or *GNA11*) mutations in a melanocytic CNS tumor very strongly favors a primary CNS tumor over metastasis of cutaneous melanoma. Especially in children, primary melanocytic CNS tumors relatively frequently harbor a neuroblastoma RAS viral oncogene homolog (*NRAS*) mutation, especially so in the context of neurocutaneous melanosis [105–108].

Most ‘craniopharyngiomas’ are of the adamantinomatous subtype, and more than 90% of these tumors carry a *CTNNB1* mutation, resulting in aberrant nuclear beta-catenin expression that can be demonstrated by immunohistochemistry. In contrast, the vast majority of craniopharyngiomas of the much less frequent papillary subtype carry the *BRAF* V600E mutation, which can be demonstrated by IHC for the mutant protein as well and may be used as a therapeutic target [109–112].

Discussion

Conclusions and future perspectives

Current neuro-oncological practice is increasingly dependent on molecular diagnostics of tumor tissue. To provide the best patient

care possible, it is important to carefully select the assays used as well as to monitor their validity and accuracy. Simpler techniques such as Sanger sequencing, FISH and LOH analysis can provide very valuable molecular information but have their shortcomings. For example, for the detection of 1p/19q codeletion in diffuse gliomas preferably a platform is used that allows for discriminating partial 1p and/or 19q losses from the clinically relevant, complete 1p/19q codeletion [9].

The rapidly growing number of mutations to detect and the increased possibilities for targeted therapies has propelled the development of NGS panels, where multiple mutations can be detected in a single analysis. Some of these panels allow for simultaneous detection of fusions and chromosomal copy number aberration, as well [9]. More recently, genome-wide methylation profiling has been reported as a very valuable tool for CNS tumor diagnostics [113, 114]. Indeed, in an increasing number of laboratories, advanced setups have been established with integrated diagnostic workflows covering microscopy-based methods, NGS and genome-wide methylation profiling (Figure 1). In addition, recent advances in neuro-imaging with techniques that assess, e.g. IDH status and 1p/19q-codeletion, are emerging and are playing an increasingly important role in diagnosis of CNS tumors [115, 116].

Acknowledging that the WHO Classification is meant to be used world-wide, it is important to keep a balance between

Table 4. Structure of four-layered conclusion in the pathology report on CNS tumors with three examples

| Four layers | Contents of the four layers | Example 1 | Example 2 | Example 3 |
|---------------------------|--|--|---|---|
| 1. Integrated diagnosis | Diagnosis based on integration of all tissue-based (especially histological and molecular) information | Diffuse astrocytoma, IDH-mutant (WHO grade II) | Diffuse astrocytic glioma, IDH-wildtype, with molecular features of glioblastoma (WHO grade IV) | Ependymoma, <i>RELA</i> fusion-positive |
| 2. Histological diagnosis | Classification of tumor based on (immuno)histochemical evaluation | Diffuse astrocytoma | Anaplastic astrocytoma | Ependymoma |
| 3. WHO grade | 'Standard' histological WHO tumor grade | WHO grade II | WHO grade III | WHO grade II |
| 4. Molecular information | Most important data from molecular analyses (e.g. sequencing, FISH, methylation profiling) | <i>IDH1</i> R132H-mutant; <i>ATRX</i> -mutant; <i>TP53</i> -mutant | IDH-wildtype; <i>TERT</i> promoter-mutant; <i>EGFR</i> amplification | <i>C11orf95-RELA</i> fusion |

Now that the definition of some CNS tumors is based on a combination of histological and molecular features, a layered reporting format of the conclusion in the pathology report helps to convey not only the message of the 'integrated diagnosis', but also provides in a nutshell the most relevant information on the 'building blocks' used to reach this diagnosis. Of note, the WHO grade in layer 3 is based on standard histological evaluation. In some situations this grade may be overruled by information obtained by molecular analysis (WHO grade IV instead of WHO grade III in the integrated diagnosis in example 2), in other cases, the WHO grade may be left out in the integrated diagnosis as assigning an unequivocal WHO grade is (still) difficult (example 3).

incorporation of the latest molecular findings into a classification and the fact that in many places around the world testing for such aberrations is not possible. Indeed, the 'NOS' categories in the updated WHO Classification allow a WHO diagnosis based on histopathological analysis alone for tumors that ideally are further characterized at the molecular level.

Meanwhile, further elucidation of the molecular underpinnings of CNS tumors is occurring at a rapid pace and can be expected to allow for an even more precise and objective diagnosis of a substantial subset of these tumors in the near future. In 2016, the Consortium to Inform Molecular and Practical Approaches to CNS Tumor Taxonomy (cIMPACT-NOW consortium) consisting of expert-neuropathologists and a clinical advisory panel, was established with the goal of facilitating implementation of such novel, relevant molecular information into the clinical diagnosis of CNS tumors and into future classifications of these neoplasms [117]. This consortium has already published recommendations on how to use the term NOS versus 'not elsewhere classified' in the context of CNS tumor diagnostics according to the WHO 2016 Classification [22], a clarification of the diagnosis of H3 K27M-mutant gliomas and diffuse low grade and anaplastic, IDH-mutant astrocytomas [118].

Acknowledging that, with the introduction of molecularly defined subgroups of diffuse gliomas the traditionally used microscopic criteria for grading of these neoplasms might not suffice anymore [119, 120], the recently published cIMPACT-NOW update 3 explains that *EGFR* amplification, *TERT* promoter mutation, and/or combined gain of complete chromosome 7 and loss of complete chromosome 10 can be used to make a diagnosis of 'molecular glioblastoma'. These tumors are designated as WHO grade IV based on the molecular parameters [121]. This supports treatment of IDH-wildtype anaplastic

astrocytoma and potentially also IDH-wildtype diffuse astrocytoma having these molecular alterations as glioblastomas, although these tumors histologically appear as WHO grade III and II tumor, respectively. Also, new insights are emerging with regard to how to improve grading within the category of IDH-mutant diffuse astrocytic tumors, with homozygous *CDKN2A/B* loss as a molecular marker strongly associated with aggressive clinical behavior in this category [122]. Very recently, a cIMPACT-NOW update 4 has been published dealing with the indolent clinical behavior and rare anaplastic progression of diffuse IDH-wt/H3-wt gliomas with either a *BRAF* V600E mutation, an *FGFR* alteration, or an *MYB* or *MYBL1* rearrangement. These diffuse gliomas mainly present in children but sometimes in adults. Identification of these molecular alterations warrant different approaches to the post-operative management of a WHO grade II diffuse glioma and, for some patients, even targeted therapies [123]. Detection of homozygous deletion at the *CDKN2A/B* locus is a molecular marker that should direct the neuropathologist away from a diagnosis of 'pediatric-type' diffuse glioma [123].

Of note, current neuro-oncological treatment guidelines are still generally based on studies and experiences dating from the time before the availability of detailed molecular information. It is essential that treatment guidelines and neuro-oncology practices are soon re-evaluated in light of this more precise diagnostic information. Importantly, novel trials like the N²M² (NOA20) phase I/II trial offering molecularly matched targeted therapies to patients with IDH-wildtype non-*MGMT* promoter hypermethylated glioblastomas take the molecular status of the tumor into account and investigate the value of novel targeted drugs and radiotherapy in this context [124].

In conclusion, enormous progress has been made by the elucidation of the molecular underpinnings of CNS tumors and by

From 'Histo-Molecular' Pathological Diagnosis to Therapeutic Management

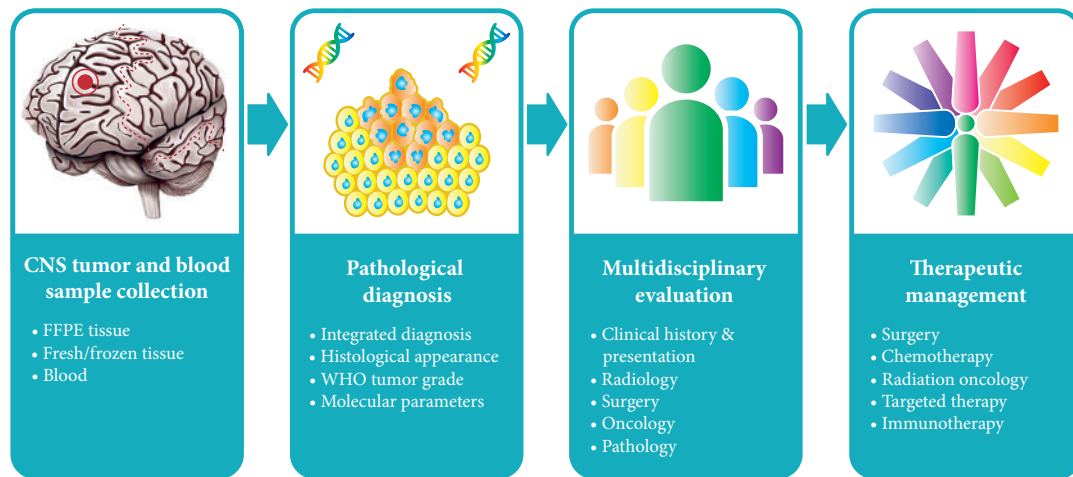


Figure 2. The pathological diagnosis of CNS tumors is a multi-step process starting with tumor tissue and in some cases also blood samples being analyzed with multiple tests to provide an integrated diagnosis. Evaluation and discussion of the pathological diagnosis by a multidisciplinary board of specialists from radiology, surgery, oncology, and (neuro)pathology is crucial for translating the findings into optimal therapeutic management for individual patients.

translating this information into a more precise clinical diagnosis. For conveying the essence of the molecular findings to clinicians using a layered reporting format of the conclusion has been proposed [59] as given in Table 4. More recently, the International Collaboration on Cancer Reporting (ICCR) has established guidelines about how to structure a pathology report that encompasses both histopathological and molecular information using the layered diagnostic approach (<http://www.iccr-cancer.org/datasets/published-datasets/central-nervous-system>). Evaluation of the molecular information in multidisciplinary teams will further facilitate optimal use of molecular diagnostics of CNS tumors in clinical practice (Figure 2). Hopefully, in this way, an integrated 'histo-molecular' diagnosis of CNS tumors will boost more specific and effective therapeutic approaches for patients that suffer from these tumors.

Funding

None declared.

Disclosure

The authors have declared no conflicts of interest.

References

- Louis DN, Ohgaki H, Wiestler OD et al. WHO Classification of Tumours of the Central Nervous System, 4th edition. Lyon: International Agency for Research on Cancer (IARC) 2007.
- Kros JM, Gorlia T, Kouwenhoven MC et al. Panel review of anaplastic oligodendroglioma from European Organization For Research and Treatment of Cancer Trial 26951: assessment of consensus in diagnosis, influence of 1p/19q loss, and correlations with outcome. *J Neuropathol Exp Neurol* 2007; 66(6): 545–551.
- van den Bent MJ. Interobserver variation of the histopathological diagnosis in clinical trials on glioma: a clinician's perspective. *Acta Neuropathol* 2010; 120(3): 297–304.
- Louis DN, Ohgaki H, Wiestler OD et al. World Health Organization Histological Classification of Tumours of the Central Nervous System. Lyon: International Agency for Research on Cancer (IARC) 2016.
- Berghoff AS, Stefanits H, Woehrer A et al. Clinical neuropathology practice guide 3-2013: levels of evidence and clinical utility of prognostic and predictive candidate brain tumor biomarkers. *Clin Neuropathol* 2013; 32(05): 148–158.
- Berghoff AS, Bartsch R, Woehrer A et al. Predictive molecular markers in metastases to the central nervous system: recent advances and future avenues. *Acta Neuropathol* 2014; 128(6): 879–891.
- Simonelli M, Persico P, Perrino M et al. Checkpoint inhibitors as treatment for malignant gliomas: "A long way to the top". *Cancer Treat Rev* 2018; 69: 121–131.
- Passiglia F, Caglevic C, Giovannetti E et al. Primary and metastatic brain cancer genomics and emerging biomarkers for immunomodulatory cancer treatment. *Semin Cancer Biol* 2018; 52: 259–268.
- Priesterbach-Ackley LP, Wesseling P, Snijders TJ et al. Molecular Tools for the Pathologic Diagnosis of CNS Tumors 2018. *Neuro-oncology Practice*.
- Reifenberger J, Reifenberger G, Liu L et al. Molecular genetic analysis of oligodendroglial tumors shows preferential allelic deletions on 19q and 1p. *Am J Pathol* 1994; 145: 1175–1190.
- Cairncross JG, Ueki K, Zlatescu MC et al. Specific genetic predictors of chemotherapeutic response and survival in patients with anaplastic oligodendrogliomas. *J Natl Cancer Inst* 1998; 90(19): 1473–1479.
- Parsons DW, Jones S, Zhang X et al. An integrated genomic analysis of human glioblastoma multiforme. *Science* 2008; 321(5897): 1807–1812.
- Balss J, Meyer J, Mueller W et al. Analysis of the *IDH1* codon 132 mutation in brain tumors. *Acta Neuropathol* 2008; 116(6): 597–602.
- Ichimura K, Pearson DM, Kocalkowski S et al. *IDH1* mutations are present in the majority of common adult gliomas but rare in primary glioblastomas. *Neuro Oncol* 2009; 11(4): 341–347.
- Watanabe T, Nobusawa S, Kleihues P, Ohgaki H. *IDH1* mutations are early events in the development of astrocytomas and oligodendrogliomas. *Am J Pathol* 2009; 174(4): 1149–1153.

16. Yan H, Parsons DW, Jin G et al. *IDH1* and *IDH2* mutations in gliomas. *N Engl J Med* 2009; 360(8): 765–773.
17. Ohgaki H, Burger P, Kleihues P. Definition of primary and secondary glioblastoma–response. *Clin Cancer Res* 2014; 20(7): 2013.
18. Hartmann C, Hentschel B, Wick W et al. Patients with *IDH1* wild type anaplastic astrocytomas exhibit worse prognosis than *IDH1*-mutated glioblastomas, and *IDH1* mutation status accounts for the unfavorable prognostic effect of higher age: implications for classification of gliomas. *Acta Neuropathol* 2010; 120(6): 707–718.
19. Barthel FP, Wesseling P, Verhaak R. Reconstructing the molecular life history of gliomas. *Acta Neuropathol* 2018; 135(5): 649–670.
20. Schumacher T, Bunse L, Pusch S et al. A vaccine targeting mutant *IDH1* induces antitumour immunity. *Nature* 2014; 512(7514): 324–327.
21. Waitkus MS, Diplasi BH, Yan H. Biological role and therapeutic potential of *IDH* mutations in cancer. *Cancer Cell* 2018; 34(2): 186–195.
22. Louis DN, Wesseling P, Paulus W et al. cIMPACT-NOW update 1: not otherwise specified (NOS) and not elsewhere classified (NEC). *Acta Neuropathol* 2018; 135(3): 481–484.
23. Arita H, Narita Y, Fukushima S et al. Upregulating mutations in the *TERT* promoter commonly occur in adult malignant gliomas and are strongly associated with total 1p19q loss. *Acta Neuropathol* 2013; 126(2): 267–276.
24. Killela PJ, Reitman ZJ, Jiao Y et al. *TERT* promoter mutations occur frequently in gliomas and a subset of tumors derived from cells with low rates of self-renewal. *Proc Natl Acad Sci USA* 2013; 110(15): 6021–6026.
25. Koelsche C, Sahm F, Capper D et al. Distribution of *TERT* promoter mutations in pediatric and adult tumors of the nervous system. *Acta Neuropathol* 2013; 126(6): 907–915.
26. Sahm F, Reuss D, Koelsche C et al. Farewell to oligoastrocytoma: in situ molecular genetics favor classification as either oligodendroglioma or astrocytoma. *Acta Neuropathol* 2014; 128(4): 551–559.
27. Eckel-Passow JE, Lachance DH, Molinaro AM et al. Glioma groups based on 1p/19q, *IDH*, and *TERT* promoter mutations in tumors. *N Engl J Med* 2015; 372(26): 2499–2508.
28. Suzuki H, Aoki K, Chiba K et al. Mutational landscape and clonal architecture in grade II and III gliomas. *Nat Genet* 2015; 47(5): 458–468.
29. Reuss DE, Sahm F, Schrimpf D et al. *ATRX* and *IDH1-R132H* immunohistochemistry with subsequent copy number analysis and *IDH* sequencing as a basis for an “integrated” diagnostic approach for adult astrocytoma, oligodendroglioma and glioblastoma. *Acta Neuropathol* 2015; 129(1): 133–146.
30. Huse JT, Diamond EL, Wang L, Rosenblum MK. Mixed glioma with molecular features of composite oligodendroglioma and astrocytoma: a true “oligoastrocytoma”? *Acta Neuropathol* 2015; 129(1): 151–153.
31. Wilcox P, Li CC, Lee M et al. Oligoastrocytomas: throwing the baby out with the bathwater? *Acta Neuropathol* 2015; 129(1): 147–149.
32. Barresi V, Lioni S, Valori L et al. Dual-genotype diffuse low-grade glioma: is it really time to abandon oligoastrocytoma as a distinct entity? *J Neuropathol Exp Neurol* 2017; 76(5): 342–346.
33. Gessi M, Capper D, Sahm F et al. Evidence of H3 K27M mutations in posterior fossa ependymomas. *Acta Neuropathol* 2016; 132(4): 635–637.
34. Joyon N, Tauziède-Espariat A, Alentorn A et al. K27M mutation in H3F3A in ganglioglioma grade I with spontaneous malignant transformation extends the histopathological spectrum of the histone H3 oncogenic pathway. *Neuropathol Appl Neurobiol* 2017; 43(3): 271–276.
35. Hochart A, Escande F, Rocourt N et al. Long survival in a child with a mutated K27M-H3.3 pilocytic astrocytoma. *Ann Clin Transl Neurol* 2015; 2(4): 439–443.
36. Rodriguez FJ, Brosnan-Cashman JA, Allen SJ et al. Alternative lengthening of telomeres, *ATRX* loss and h3-k27m mutations in histologically defined pilocytic astrocytoma with anaplasia. *Brain Pathol* 2019; 29: 126–140.
37. Solomon DA, Wood MD, Tihan T et al. Diffuse midline gliomas with histone H3-K27M mutation: a series of 47 cases assessing the spectrum of morphologic variation and associated genetic alterations. *Brain Pathol* 2016; 26(5): 569–580.
38. Buczkowicz P, Bartels U, Bouffet E et al. Histopathological spectrum of paediatric diffuse intrinsic pontine glioma: diagnostic and therapeutic implications. *Acta Neuropathol* 2014; 128(4): 573–581.
39. Khuong-Quang DA, Buczkowicz P, Rakopoulos P et al. K27M mutation in histone H3.3 defines clinically and biologically distinct subgroups of pediatric diffuse intrinsic pontine gliomas. *Acta Neuropathol* 2012; 124(3): 439–447.
40. Kim HW, Park T, Quiring S, Barrett D. The anti-human trafficking collaboration model and serving victims: providers’ perspectives on the impact and experience. *J Evid Inf Soc Work* 2018; 15: 185–202.
41. Karremann M, Gielen GH, Hoffmann M et al. Diffuse high-grade gliomas with H3 K27M mutations carry a dismal prognosis independent of tumor location. *Neuro Oncol* 2018; 20(1): 123–131.
42. Venkatramani R, Dhall G, Patel M et al. Supratentorial ependymoma in children: to observe or to treat following gross total resection? *Pediatr Blood Cancer* 2012; 58(3): 380–383.
43. Ellison DW, Kocak M, Figarella-Branger D et al. Histopathological grading of pediatric ependymoma: reproducibility and clinical relevance in European trial cohorts. *J Negat Results Biomed* 2011; 10: 7.
44. Pajtler KW, Witt H, Sill M et al. Molecular classification of ependymal tumors across all CNS compartments, histopathological grades, and age groups. *Cancer Cell* 2015; 27(5): 728–743.
45. Parker M, Mohankumar KM, Punchihewa C et al. *C11orf95-RELA* fusions drive oncogenic NF-kappaB signalling in ependymoma. *Nature* 2014; 506(7489): 451–455.
46. Broniscer A, Tavevossian RG, Sabin ND et al. Clinical, radiological, histological and molecular characteristics of paediatric epithelioid glioblastoma. *Neuropathol Appl Neurobiol* 2014; 40(3): 327–336.
47. Kleinschmidt-DeMasters BK, Aisner DL, Birks DK, Foreman NK. Epithelioid GBMs show a high percentage of *BRAF* V600E mutation. *Am J Surg Pathol* 2013; 37(5): 685–698.
48. Myung JK, Cho H, Park CK et al. Analysis of the *BRAF*(V600E) mutation in central nervous system tumors. *Transl Oncol* 2012; 5: 430–436.
49. Kieran MW. Targeting *BRAF* in pediatric brain tumors. *Am Soc Clin Oncol Educ Book* 2014; 34: e436–e440.
50. Rodriguez FJ, Schmierer MJ, Nicolaidis T et al. High rate of concurrent *BRAF-KIAA1549* gene fusion and 1p deletion in disseminated oligodendroglioma-like leptomeningeal neoplasms (DOLN). *Acta Neuropathol* 2015; 129(4): 609–610.
51. Sahm F, Koelsche C, Meyer J et al. *CIC* and *FUBP1* mutations in oligodendrogliomas, oligoastrocytomas and astrocytomas. *Acta Neuropathol* 2012; 123(6): 853–860.
52. Yi KS, Sohn CH, Yun TJ et al. MR imaging findings of extraventricular neurocytoma: a series of ten patients confirmed by immunohistochemistry of *IDH1* gene mutation. *Acta Neurochir* 2012; 154(11): 1973–1979; discussion 1980.
53. Esteller M, Garcia-Foncillas J, Andion E et al. Inactivation of the DNA-repair gene *MGMT* and the clinical response of gliomas to alkylating agents. *N Engl J Med* 2000; 343(19): 1350–1354.
54. Korshunov A, Capper D, Reuss D et al. Histologically distinct neuroepithelial tumors with histone 3 G34 mutation are molecularly similar and comprise a single nosologic entity. *Acta Neuropathol* 2016; 131(1): 137–146.
55. Reinhardt A, Stichel D, Schrimpf D et al. Anaplastic astrocytoma with piloid features, a novel molecular class of *IDH* wildtype glioma with recurrent *MAPK* pathway, *CDKN2A/B* and *ATRX* alterations. *Acta Neuropathol* 2018; 136(2): 273–291.
56. Panwalkar P, Clark J, Ramaswamy V et al. Immunohistochemical analysis of H3K27me3 demonstrates global reduction in group-A childhood posterior fossa ependymoma and is a powerful predictor of outcome. *Acta Neuropathol* 2017; 134(5): 705–714.
57. Louis DN, Ohgaki H, Wiestler OD et al. The 2007 WHO classification of tumours of the central nervous system. *Acta Neuropathol* 2007; 114(2): 97–109.

58. Taylor MD, Northcott PA, Korshunov A et al. Molecular subgroups of medulloblastoma: the current consensus. *Acta Neuropathol* 2012; 123(4): 465–472.
59. Louis DN, Perry A, Burger P et al. International Society Of Neuropathology–Haarlem consensus guidelines for nervous system tumor classification and grading. *Brain Pathol* 2014; 24(5): 429–435.
60. Gajjar A, Pfister SM, Taylor MD, Gilbertson RJ. Molecular insights into pediatric brain tumors have the potential to transform therapy. *Clin Cancer Res* 2014; 20(22): 5630–5640.
61. Zhao F, Ohgaki H, Xu L et al. Molecular subgroups of adult medulloblastoma: a long-term single-institution study. *Neuro Oncol* 2016; 18(7): 982–990.
62. Zhukova N, Ramaswamy V, Remke M et al. Subgroup-specific prognostic implications of *TP53* mutation in medulloblastoma. *J Clin Oncol* 2013; 31(23): 2927–2935.
63. Pfister S, Remke M, Benner A et al. Outcome prediction in pediatric medulloblastoma based on DNA copy-number aberrations of chromosomes 6q and 17q and the *MYC* and *MYCN* loci. *J Clin Oncol* 2009; 27(10): 1627–1636.
64. Pickles JC, Hawkins C, Pietsch T, Jacques TS. CNS embryonal tumours: WHO 2016 and beyond. *Neuropathol Appl Neurobiol* 2018; 44: 151–162.
65. Schwalbe EC, Lindsey JC, Nakjang S et al. Novel molecular subgroups for clinical classification and outcome prediction in childhood medulloblastoma: a cohort study. *Lancet Oncol* 2017; 18(7): 958–971.
66. Waszak SM, Northcott PA, Buchhalter I et al. Spectrum and prevalence of genetic predisposition in medulloblastoma: a retrospective genetic study and prospective validation in a clinical trial cohort. *Lancet Oncol* 2018; 19(6): 785–798.
67. Cavalli FMG, Remke M, Rampasek L et al. Intertumoral heterogeneity within medulloblastoma subgroups. *Cancer Cell* 2017; 31(6): 737–754. e6.
68. Northcott PA, Buchhalter I, Morrissy AS et al. The whole-genome landscape of medulloblastoma subtypes. *Nature* 2017; 547(7663): 311–317.
69. Robinson GW, Rudneva VA, Buchhalter I et al. Risk-adapted therapy for young children with medulloblastoma (SJYC07): therapeutic and molecular outcomes from a multicentre, phase 2 trial. *Lancet Oncol* 2018; 19(6): 768–784.
70. Miller S, Ward JH, Rogers HA et al. Loss of INI1 protein expression defines a subgroup of aggressive central nervous system primitive neuroectodermal tumors. *Brain Pathol* 2013; 23(1): 19–27.
71. Torchia J, Golbourn B, Feng S et al. Integrated (epi)-genomic analyses identify subgroup-specific therapeutic targets in CNS rhabdoid tumors. *Cancer Cell* 2016; 30(6): 891–908.
72. Johann PD, Erkek S, Zapatka M et al. Atypical teratoid/rhabdoid tumors are comprised of three epigenetic subgroups with distinct enhancer landscapes. *Cancer Cell* 2016; 29(3): 379–393.
73. Korshunov A, Sturm D, Ryzhova M et al. Embryonal tumor with abundant neuropil and true rosettes (ETANTR), ependymoblastoma, and medulloepithelioma share molecular similarity and comprise a single clinicopathological entity. *Acta Neuropathol* 2014; 128(2): 279–289.
74. Li M, Lee KF, Lu Y et al. Frequent amplification of a chr19q13.41 microRNA polycistron in aggressive primitive neuroectodermal brain tumors. *Cancer Cell* 2009; 16(6): 533–546.
75. Pfister S, Remke M, Castoldi M et al. Novel genomic amplification targeting the microRNA cluster at 19q13.42 in a pediatric embryonal tumor with abundant neuropil and true rosettes. *Acta Neuropathol* 2009; 117(4): 457–464.
76. Kleinman CL, Gerges N, Papillon-Cavanagh S et al. Fusion of *TTYH1* with the C19MC microRNA cluster drives expression of a brain-specific DNMT3B isoform in the embryonal brain tumor ETMR. *Nat Genet* 2014; 46(1): 39–44.
77. Korshunov A, Ryzhova M, Jones DT et al. LIN28A immunoreactivity is a potent diagnostic marker of embryonal tumor with multilayered rosettes (ETMR). *Acta Neuropathol* 2012; 124(6): 875–881.
78. Spence T, Sin-Chan P, Picard D et al. CNS-PNETs with C19MC amplification and/or LIN28 expression comprise a distinct histogenetic diagnostic and therapeutic entity. *Acta Neuropathol* 2014; 128(2): 291–303.
79. Miller S, Rogers HA, Lyon P et al. Genome-wide molecular characterization of central nervous system primitive neuroectodermal tumor and pineoblastoma. *Neuro Oncol* 2011; 13(8): 866–879.
80. de Kock L, Sabbaghian N, Druker H et al. Germ-line and somatic *DICER1* mutations in pineoblastoma. *Acta Neuropathol* 2014; 128(4): 583–595.
81. de Kock L, Sabbaghian N, Plourde F et al. Pituitary blastoma: a pathognomonic feature of germ-line *DICER1* mutations. *Acta Neuropathol* 2014; 128(1): 111–122.
82. Koelsche C, Mynarek M, Schrimpf D et al. Primary intracranial spindle cell sarcoma with rhabdomyosarcoma-like features share a highly distinct methylation profile and *DICER1* mutations. *Acta Neuropathol* 2018; 136(2): 327–337.
83. Sturm D, Orr BA, Toprak UH et al. New brain tumor entities emerge from molecular classification of CNS-PNETs. *Cell* 2016; 164(5): 1060–1072.
84. Gessi M, Gielen GH, Hammes J et al. H3.3 G34R mutations in pediatric primitive neuroectodermal tumors of central nervous system (CNS-PNET) and pediatric glioblastomas: possible diagnostic and therapeutic implications? *J Neurooncol* 2013; 112(1): 67–72.
85. Fletcher CDM, Bridge JA, Hogendoorn PCW et al. WHO Classification of Tumours of Soft Tissue and Bone. Lyon: International Agency for Research on Cancer (IARC) 2013.
86. Swerdlow SHC, Campo E, Harris NL et al. WHO Classification of Tumours of Haematopoietic and Lymphoid Tissues. Lyon: International Agency for Research on Cancer (IARC) 2017.
87. Lopes M. The 2017 World Health Organization classification of tumors of the pituitary gland: a summary. *Acta Neuropathol* 2017; 134(4): 521–535.
88. Goutagny S, Nault JC, Mallet M et al. High incidence of activating *TERT* promoter mutations in meningiomas undergoing malignant progression. *Brain Pathol* 2014; 24(2): 184–189.
89. Sahm F, Schrimpf D, Olar A et al. *TERT* promoter mutations and risk of recurrence in meningioma. *J Natl Cancer Inst* 2015; 108.
90. Clark VE, Erson-Omay EZ, Serin A et al. Genomic analysis of non-NF2 meningiomas reveals mutations in *TRAF7*, *KLF4*, *AKT1*, and *SMO*. *Science* 2013; 339(6123): 1077–1080.
91. Reuss DE, Piro RM, Jones DT et al. Secretory meningiomas are defined by combined *KLF4* K409Q and *TRAF7* mutations. *Acta Neuropathol* 2013; 125(3): 351–358.
92. Smith MJ, O’Sullivan J, Bhaskar SS et al. Loss-of-function mutations in *SMARCE1* cause an inherited disorder of multiple spinal meningiomas. *Nat Genet* 2013; 45(3): 295–298.
93. Brastianos PK, Horowitz PM, Santagata S et al. Genomic sequencing of meningiomas identifies oncogenic *SMO* and *AKT1* mutations. *Nat Genet* 2013; 45(3): 285–289.
94. Sahm F, Bissel J, Koelsche C et al. *AKT1E17K* mutations cluster with meningothelial and transitional meningiomas and can be detected by SFRP1 immunohistochemistry. *Acta Neuropathol* 2013; 126(5): 757–762.
95. Sahm F, Schrimpf D, Stichel D et al. DNA methylation-based classification and grading system for meningioma: a multicentre, retrospective analysis. *Lancet Oncol* 2017; 18(5): 682–694.
96. Suppiah S, Nassiri F, Bi WL et al. Molecular and translational advances in meningiomas. *Neuro Oncol* 2019; 21(Suppl 1): i4–i17.
97. Rohrich M, Koelsche C, Schrimpf D et al. Methylation-based classification of benign and malignant peripheral nerve sheath tumors. *Acta Neuropathol* 2016; 131: 877–887.
98. Prieto-Granada CN, Wiesner T, Messina JL et al. Loss of H3K27me3 expression is a highly sensitive marker for sporadic and radiation-induced MPNST. *Am J Surg Pathol* 2016; 40(4): 479–489.

99. Schaefer IM, Fletcher CD, Hornick JL. Loss of H3K27 trimethylation distinguishes malignant peripheral nerve sheath tumors from histologic mimics. *Mod Pathol* 2016; 29(1): 4–13.
100. Sahm F, Reuss DE, Giannini C. WHO 2016 classification: changes and advancements in the diagnosis of miscellaneous primary CNS tumours. *Neuropathol Appl Neurobiol* 2018; 44(2): 163–171.
101. Reuss DE, Habel A, Hagenlocher C et al. Neurofibromin specific antibody differentiates malignant peripheral nerve sheath tumors (MPNST) from other spindle cell neoplasms. *Acta Neuropathol* 2014; 127(4): 565–572.
102. Pekmezci M, Reuss DE, Hirbe AC et al. Morphologic and immunohistochemical features of malignant peripheral nerve sheath tumors and cellular schwannomas. *Mod Pathol* 2015; 28(2): 187–200.
103. Jo VY, Fletcher CD. Epithelioid malignant peripheral nerve sheath tumor: clinicopathologic analysis of 63 cases. *Am J Surg Pathol* 2015; 39(5): 673–682.
104. Jo VY, Fletcher C. SMARCB1/INI1 loss in epithelioid schwannoma: a clinicopathologic and immunohistochemical study of 65 cases. *Am J Surg Pathol* 2017; 41(8): 1013–1022.
105. Kusters-Vandavelde HV, Klaasen A, Kusters B et al. Activating mutations of the *GNAQ* gene: a frequent event in primary melanocytic neoplasms of the central nervous system. *Acta Neuropathol* 2010; 119: 317–323.
106. Koelsche C, Hovestadt V, Jones DT et al. Melanotic tumors of the nervous system are characterized by distinct mutational, chromosomal and epigenomic profiles. *Brain Pathol* 2015; 25(2): 202–208.
107. Kinsler VA, Thomas AC, Ishida M et al. Multiple congenital melanocytic nevi and neurocutaneous melanosis are caused by postzygotic mutations in codon 61 of *NRAS*. *J Invest Dermatol* 2013; 133(9): 2229–2236.
108. Kusters-Vandavelde HV, Kusters B, van Engen-van Grunsven AC et al. Primary melanocytic tumors of the central nervous system: a review with focus on molecular aspects. *Brain Pathol* 2015; 25: 209–226.
109. Kim JH, Paulus W, Heim S. *BRAF* V600E mutation is a useful marker for differentiating Rathke's cleft cyst with squamous metaplasia from papillary craniopharyngioma. *J Neurooncol* 2015; 123(1): 189–191.
110. Larkin SJ, Preda V, Karavitaki N et al. *BRAF* V600E mutations are characteristic for papillary craniopharyngioma and may coexist with *CTNNB1*-mutated adamantinomatous craniopharyngioma. *Acta Neuropathol* 2014; 127(6): 927–929.
111. Schweizer L, Capper D, Holsken A et al. *BRAF* V600E analysis for the differentiation of papillary craniopharyngiomas and Rathke's cleft cysts. *Neuropathol Appl Neurobiol* 2015; 41(6): 733–742.
112. Brastianos PK, Taylor-Weiner A, Manley PE et al. Exome sequencing identifies *BRAF* mutations in papillary craniopharyngiomas. *Nat Genet* 2014; 46(2): 161–165.
113. Capper D, Jones DTW, Sill M et al. DNA methylation-based classification of central nervous system tumours. *Nature* 2018; 555(7697): 469–474.
114. Capper D, Stichel D, Sahm F et al. Practical implementation of DNA methylation and copy-number-based CNS tumor diagnostics: the Heidelberg experience. *Acta Neuropathol* 2018; 136(2): 181–210.
115. Zhou H, Chang K, Bai HX et al. Machine learning reveals multimodal MRI patterns predictive of isocitrate dehydrogenase and 1p/19q status in diffuse low- and high-grade gliomas. *J Neurooncol* 2019; 142(2): 299–307.
116. Zhang B, Chang K, Ramkissoon S et al. Multimodal MRI features predict isocitrate dehydrogenase genotype in high-grade gliomas. *NEUONC* 2017; 19(1): 109–117.
117. Louis DN, Aldape K, Brat DJ et al. Announcing cIMPACT-NOW: the Consortium to inform molecular and practical approaches to CNS tumor taxonomy. *Acta Neuropathol* 2017; 133(1): 1–3.
118. Louis DN, Giannini C, Capper D et al. cIMPACT-NOW update 2: diagnostic clarifications for diffuse midline glioma, H3 K27M-mutant and diffuse astrocytoma/anaplastic astrocytoma, IDH-mutant. *Acta Neuropathol* 2018; 135(4): 639–642.
119. Olar A, Wani KM, Alfaro-Munoz KD et al. *IDH* mutation status and role of WHO grade and mitotic index in overall survival in grade II-III diffuse gliomas. *Acta Neuropathol* 2015; 129(4): 585–596.
120. Reuss DE, Mamatjan Y, Schrimpf D et al. IDH mutant diffuse and anaplastic astrocytomas have similar age at presentation and little difference in survival: a grading problem for WHO. *Acta Neuropathol* 2015; 129(6): 867–873.
121. Brat DJ, Aldape K, Colman H et al. cIMPACT-NOW update 3: recommended diagnostic criteria for “Diffuse astrocytic glioma, IDH-wildtype, with molecular features of glioblastoma, WHO grade IV”. *Acta Neuropathol* 2018; 136(5): 805–810.
122. Shirahata M, Ono T, Stichel D et al. Novel, improved grading system(s) for IDH-mutant astrocytic gliomas. *Acta Neuropathol* 2018; 136(1): 153–166.
123. Ellison DW, Hawkins C, Jones DTW et al. cIMPACT-NOW update 4: diffuse gliomas characterized by *MYB*, *MYBL1*, or *FGFR1* alterations or *BRAF*(V600E) mutation. *Acta Neuropathol* 2019; 137(4): 683–687.
124. Wick W, Dettmer S, Berberich A et al. N2M2 (NOA-20) phase I/II trial of molecularly matched targeted therapies plus radiotherapy in patients with newly diagnosed non-*MGMT* hypermethylated glioblastoma. *Neuro Oncol* 2019; 21(1): 95–105.