



## High rate of unexpected lymphatic drainage patterns and a high accuracy of the sentinel lymph node biopsy in oral cancer after previous neck treatment

Inne J. den Toom<sup>a,b,1</sup>, Koos Boeve<sup>c,d,1</sup>, Stijn van Weert<sup>b</sup>, Elisabeth Bloemena<sup>e,f</sup>,  
Adrienne H. Brouwers<sup>g</sup>, Otto S. Hoekstra<sup>h</sup>, Bart de Keizer<sup>i</sup>, Bert van der Vegt<sup>d</sup>, Stefan M. Willems<sup>j</sup>,  
C. René Leemans<sup>b</sup>, Max J.H. Witjes<sup>c</sup>, Remco de Bree<sup>a,\*</sup>

<sup>a</sup> Department of Head and Neck Surgical Oncology, UMC Utrecht Cancer Center, University Medical Center Utrecht, the Netherlands

<sup>b</sup> Department of Otolaryngology-Head and Neck Surgery, Amsterdam UMC, Amsterdam, the Netherlands

<sup>c</sup> Department of Oral and Maxillofacial Surgery, University of Groningen, University Medical Center Groningen, the Netherlands

<sup>d</sup> Department of Pathology & Medical Biology, University of Groningen, University Medical Center Groningen, the Netherlands

<sup>e</sup> Department of Oral and Maxillofacial Surgery/Oral Pathology, Amsterdam UMC/Academic Center for Dentistry (ACTA), Amsterdam, the Netherlands

<sup>f</sup> Department of Pathology, Amsterdam UMC, Amsterdam, the Netherlands

<sup>g</sup> Department of Nuclear Medicine and Molecular Imaging, University of Groningen, University Medical Center Groningen, the Netherlands

<sup>h</sup> Department of Radiology and Nuclear Medicine, Amsterdam UMC, the Netherlands

<sup>i</sup> Department of Nuclear Medicine, University Medical Center Utrecht, the Netherlands

<sup>j</sup> Department of Pathology, University Medical Center Utrecht, the Netherlands

### ARTICLE INFO

#### Keywords:

Sentinel lymph node biopsy  
Lymphatic drainage  
Lymph node metastases  
Oral cancer  
Second primary  
Recurrence  
Neck treatment

### ABSTRACT

**Rationale:** This study evaluates the lymphatic drainage patterns and determines the accuracy of the sentinel lymph node biopsy (SLNB) in patients diagnosed with a cT1-2N0 OSCC and a history of neck surgery or radiotherapy in three Dutch head and neck centers.

**Materials and Methods:** Retrospective analysis of 53 cT1-2N0 OSCC patients, who underwent SLNB between 2007 and 2016, after a history of neck surgery or radiotherapy. Ten patients had previous treatment of the neck only contralateral from the current tumour. These ten patients were not used for the analysis of lymphatic drainage patterns. The 43 patients with previous ipsilateral or bilateral treatment of the neck had a history of ipsilateral SLN extirpation (n = 9; 21%), neck dissection (n = 16; 37%), radiotherapy (n = 10; 23%), or combined neck dissection and radiotherapy (n = 8; 19%).

**Results:** SLNs were detected in 45 patients, resulting in an identification rate of 85% (45/53). Three patients (7%) had at least one positive SLN. One patient (1/45; 2%) was diagnosed with regional recurrence during the follow-up after a negative SLNB (sensitivity 75%, negative predictive value 98%). The first SLN was detected in level I-III in 58% of the patients, unexpected drainage patterns were observed in 30% (first SLN level IV 9% and level V 5% and contralateral neck in well-lateralized tumours 16%). In 12% no lymphatic drainage pattern was visible.

**Conclusions:** SLNB seems to be a reliable procedure for neck staging of cT1-2N0 OSCC patients with a previously treated neck. SLNB determines the individual lymphatic drainage patterns, enabling visualization of unexpected drainage pattern variability in 30% of these patients.

### Introduction

Presence of lymphatic metastases in the neck is consistently observed as main prognostic factor in patients with oral squamous cell carcinoma (OSCC) [1–3]. Sentinel lymph node biopsy (SLNB) proved to

be reliable as diagnostic staging modality for detection of occult lymph node metastases: in a large recent meta-analysis a pooled sensitivity of 87% (95% CI 85–89%), a negative predictive value of 94% (95% CI 93%–95%) and an AUC of 0.98 (95% CI 0.97–0.99) were found [4]. These meta-analysis results are based on patients with primary OSCC

\* Corresponding author at: Department of Head and Neck Surgical Oncology, UMC Utrecht Cancer Center, University Medical Center Utrecht, Utrecht, P.O. Box 85500, 3508 GA Utrecht, The Netherlands.

E-mail address: [r.debree@umcutrecht.nl](mailto:r.debree@umcutrecht.nl) (R. de Bree).

<sup>1</sup> Both authors contributed equally to this study.

<https://doi.org/10.1016/j.oraloncology.2019.05.007>

Received 25 October 2018; Received in revised form 28 April 2019; Accepted 5 May 2019

Available online 21 May 2019

1368-8375/ © 2019 Elsevier Ltd. All rights reserved.

and a previously untreated neck. Despite the relatively common local recurrences and second primary tumours in head and neck cancer, only one study of Flach et al. reported about the accuracy of the SLNB in 22 patients with a previously treated neck [5].

It is well known that patients with OSCC suffer a high risk for local recurrences (10–30%) and an annual risk of 3–4% for developing second primary tumours [3,6–8]. Previous treatment of the neck most likely alters lymphatic drainage patterns. Current evidence about the drainage patterns in previously treated OSCC patients using SLNB is limited to a study by Flach et al. (n = 22) and a feasibility study by Pitman et al. (n = 5) [5,9]. Experience of alteration in lymphatic drainage patterns after previous treatment has also been reported in breast cancer and melanoma [10–15]. While gaining more and more experience with SLNB in our institutions during the last years, SLNB has been used increasingly as staging method in patients with a previously treated neck. Moreover, SLNB is valuable in assessment of the individual lymphatic drainage patterns, compensating for potential variabilities as a result of previous treatment which were reported in 67% of the cases by Flach et al [5].

However, since the study of SLNB in OSCC patients with a previously treated neck consisted of only 22 patients, more research had to be performed to confirm the findings of that study [5]. The aim of this study was to assess the accuracy of SLNB and secondly, to evaluate the lymphatic drainage patterns in a consecutive cohort of cT1-2N0 patients with a previously treated neck in three Dutch head and neck cancer centers.

## Methods

In three Dutch head and neck centers 53 patients diagnosed between 2007 and 2016 met the inclusion criteria and were retrospectively analyzed. Patients with early stage local recurrent disease or second (or even third) primary squamous cell carcinoma of the oral cavity or oropharynx with a clinically negative neck and surgical resection of the tumour combined with SLNB staging of the neck were included (cT1-2N0, following the 7th TNM staging classification, Table 1). In their history, all patients had received prior treatment of the neck with SLNB, neck dissection, (chemo)radiotherapy or a combination of these modalities (supplementary data 1). Twelve patients were previously included in the study by Flach et al., their follow-up was updated [5].

The SLNB procedure was described extensively before [16,17]. Briefly, patients received preoperatively injections with <sup>99m</sup>Tc-nanocolloid followed by dynamic and static lymphoscintigraphy and SPECT/CT scanning one day before surgery, intra-operatively gamma probe detection and postoperative step serial sectioning of the sentinel lymph node with additional immunohistochemical keratin staining.

As visualized in our study design (Fig. 1) all 53 patients were used for analysis regarding the accuracy of the procedure and 43 patients were included for the drainage pattern analysis. Earlier studies showed the potential of bilateral drainage patterns in well-lateralized patients. Because of this potential bilateral drainage also 10 patients were included with a history of only contralateral treatment of the neck (their first tumour was contralateral of the second) whom might affect the SLNB accuracy [16,18].

In OSCC lymphatic drainage is at least expected in level I–III at the ipsilateral side of the neck [18]. With the second aim to detect unexpected drainage patterns, only 43 patients with previous treatment of the ipsilateral side of the neck were used for lymphatic drainage pattern analysis.

In this study, definition of lateralization of the neck is related to the site of the local recurrence or second primary tumour.

## Ethical consideration

Due to the retrospective design no approval was required from the

**Table 1**

Patient characteristics. Ipsilateral and contralateral side of the neck is related to the side of the local recurrence or the second primary. Abbreviations: FOM, floor of mouth; RT, radiotherapy; ND, neck dissection; CRT, chemoradiation; SLNB, sentinel lymph node biopsy.

Characteristics	No.	(%)
Total number of patients	53	(100)
Gender		
Male	29	(55)
Female	24	(45)
Age y mean (SD) (range)	65	(55–75) (44–88)
pT status (7th TNM)		
1	44	(83)
2	9	(17)
Tumour locations		
Tongue	31	(58)
FOM	9	(17)
Buccal mucosa	5	(9)
Inferior alveolar process	4	(8)
Other	4	(8)
Previous treatment or surgery ipsilateral neck		
No	10	(19)
RT alone	8	(15)
ND alone	16	(30)
ND + RT	8	(15)
CRT	2	(4)
SLNB	9	(17)
Previous treatment or surgery contralateral neck		
No	25	(47)
RT alone	9	(17)
ND alone	6	(11)
ND + RT	6	(11)
CRT	2	(4)
SLNB	5	(9)
Follow-up		
Follow-up time months, median (IQR)	26	(13–42)
Regional recurrence	1	(1)
Death	13	(25)
Death of local recurrence or second primary	4	(8)

hospital research ethics board of our centers according to the Dutch ethical regulations. SLNB was part of the standard management of these patients and patient information regarding clinical and pathological characteristics and follow-up was retrospectively collected from electronic patient files.

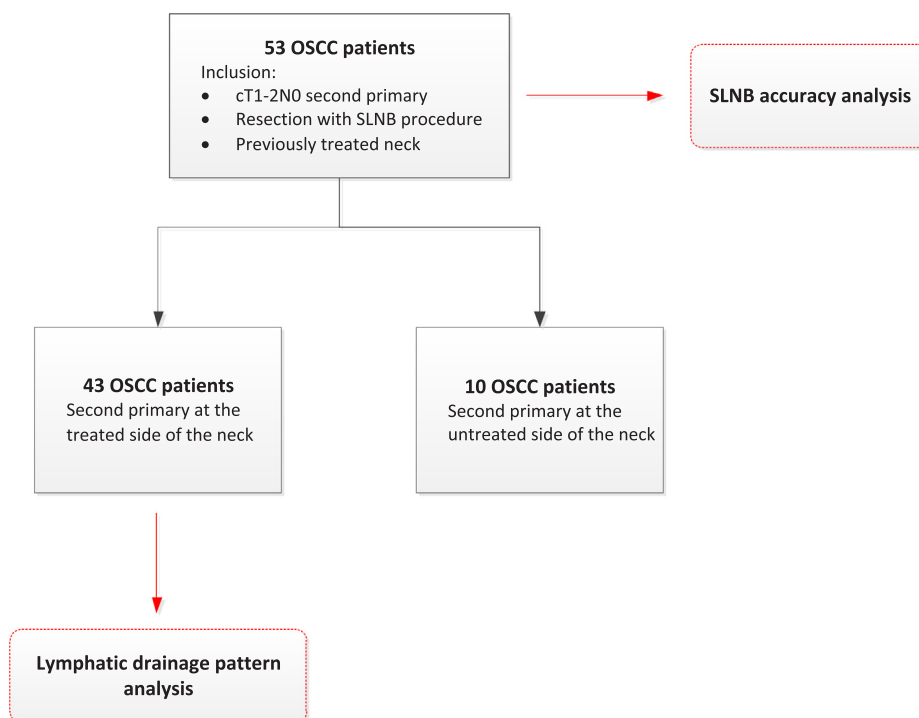
## Results

The data of 53 patients, 29 male (55%) and 24 female (45%) were used for analysis. Mean age was 65 years. Tongue was the most affected tumour location (59%), followed by floor of mouth. Forty-four patients (83%) were diagnosed with a pathologically T1 tumour and 9 patients (17%) with a T2 tumour. These and other characteristics are summarized in Table 1. Characteristics per patient are given in supplementary data 1.

## SLNB accuracy

Fifty-three patients were used for the SLNB accuracy analysis. Neck dissection, with or without postoperative radiotherapy, was seen most as previous treatment in both the ipsilateral and contralateral neck compared to the local recurrence or second primary side (Table 1). Thirteen patients (25%) died during follow-up of which four (8%) died as a result of the local recurrence or second primary tumour in the oral cavity (disease specific death: median 26 months, IQR 13 – 42 months).

No SLNs were visualized by lymphoscintigraphy in 7 of these 53 patients resulting in an 87% imaging detection rate. In one patient no SLNs were detected intraoperatively, despite preoperative visualization. In two patients with bilateral drainage on lymphoscintigraphy the SLNs



**Fig. 1.** Study design. All 53 patients were used for the SLNB accuracy analysis, only the 43 patients with a history of neck treatment at the ipsi- or bilateral side were used for the analysis of altered lymphatic drainage patterns.

were not detected in one neck side intraoperatively, but were harvested in the other side of the neck, resulting in a surgical detection rate of 93% (43/46, [supplementary data 1](#)). In total, at least one SLN was harvested in 85% of the patients (45/53). Three patients had a positive SLN, respectively in the ipsilateral neck with a history of a SLNB, in the ipsilateral neck without a history of pretreatment and in the ipsilateral neck with a history of chemoradiation therapy. In the first two patients, no additional metastases were detected after harvesting respectively 21 and 17 lymph nodes in the completed neck dissection specimens. Because of the history of chemoradiation and the metastasis size (ITC), the last patient received watchful waiting instead of a neck dissection. These 3 patients did not show regional disease during follow-up.

One patient (2%) was diagnosed with regional recurrence without local disease in level II at the ipsilateral side of the neck after 7 months of follow-up. This patient had a second primary tumour located in the buccal mucosa and only negative SLNs were found in level I at the contralateral side. This patient was previously treated with a MRND at the ipsilateral side of the neck for the first primary tumour, followed by postoperative chemoradiation at both sides of the neck. This patient was still alive after 19 months of follow-up after the regional recurrence was surgically removed and postoperatively irradiated.

One regional recurrence resulted in a 75% sensitivity with a 95% CI of 22–98% (3 of 4 true positive) and 98% NPV with a 95% CI of 88–100% (42 of 43 true negative) of the SLNB in patients with a previously treated neck.

If we restrict the accuracy analysis to patients with a history of neck dissection and/or radiotherapy in the ipsilateral neck, one out of 34 patients showed a positive SLN and one patient showed regional recurrence after a negative SLNB, resulting in a 50% sensitivity (1 of 2 true positive) with a 95% CI of 3–97% and a NPV of 97% (32 of 33 true negative) with a 95% CI of 82–100%.

#### Lymphatic drainage patterns

In 38 of the 43 patients with a second primary or local recurrence at the previously treated neck side SLNs were detected, resulting in an

88% identification rate. The five patients without detectable SLNs had in common a history of radiotherapy of the neck ([supplementary data 1](#)). Since lymphatic drainage is expected generally in levels I–III for OSCC, in 30% (13/43) patients unexpected drainage was found. Of these 13 patients, four patients showed SLNs located ipsilaterally in level IV as closest located SLN, in two patients this closest location was ipsilaterally in level V. Seven patients had only SLNs located contralateral from the side of the well-lateralized local recurrence or second primary tumour ([supplementary data 1](#)). Besides a lower identification rate, unexpected drainage was more common in patients with a history of neck irradiation compared to patients with a history of a SLNB and comparable to patients with a previous neck dissection, respectively 40% versus 11% and 38%. However the highest unexpected drainage was found after a history of neck dissection combined with postoperative radiotherapy (88%). Localization of harvested SLNs per patient and per different prior treatment are given in [supplementary data 2](#). Some SLNs were found in earlier dissected neck levels. For example, eight of the 13 patients with a history of a selective supraohyoid neck dissection had SLNs located in level I–III, also three of the seven patients with a history of a MRND had SLNs located in level II–IV ([supplementary data 2](#)).

If we restrict the drainage pattern analysis to patients with a history of treatment of the ipsilateral neck, unexpected drainage patterns were found in 12 (35%) of the 34 patients and no drainage to any side of the neck was found in 5 patients (12%).

#### Discussion

This study demonstrates that SLNB in a previously treated neck can be performed with a high accuracy (sensitivity 75%, NPV 98%). In this study unexpected lymphatic drainage patterns were found in 30% of the patients and no drainage was found in 12% of the patients.

SLNB in early stage OSCC has been frequently described in literature during the last decade with high sensitivity rates and negative predictive values [4]. SLNB was initially implemented in our institutions for patients with primary OSCC without previous treatment of the neck.

However, after gaining more experience with SLNB, this staging technique was also extended to patients with a previously treated neck [5]. As a result of the previous treatment, lymphatic drainage patterns could be disrupted resulting in aberrant drainage patterns compared to primary OSCC. Lack of knowledge about these aberrant drainage patterns resulted in missing a standard neck staging and standard elective neck dissection in previously treated patients. Flach et al. showed in a study of 22 patients that the SLNB could be useful in previously treated patients with a high sensitivity and negative predictive value for neck staging and especially for assessment of the individual lymphatic drainage patterns after previous treatment [5].

As mentioned in the introduction, only one feasibility study and the above mentioned study of Flach et al. are published for SLNB in patients with a pretreated neck [5,9]. However, interesting studies in a variety of tumour types have been published regarding SLNB in recurrent or second primary tumours. In a recent meta-analysis of aberrant lymphatic drainage in recurrent breast cancer an 59.6% intraoperatively SLN identification rate was found [10]. The authors concluded that SLNB in these patients avoided unnecessary axillary lymph node dissection and provide targeted localized surgery [10]. Similarly, in recurrent vulvar cancer the SLNB procedure seemed feasible, although the authors stated that the procedure appears technically more challenging compared to initial surgery. In a cohort of 27 patients, SLNs were found in two groins at unpredicted localizations and four lateral tumours showed bilateral SLNs [19]. Beasley et al. reported about the feasibility of SLNB in recurrent melanoma (107 patients) and also found in 24% of the patients additional sites of SLNs compared to the first SLNB procedure [15].

Although it is difficult to compare different tumour types, a trend towards a lower identification rate of SLNs compared to untreated patients was observed in present and all above mentioned studies. The most common explanation is the damage of lymphatic pathways due to prior treatment and a more difficult technical procedure to harvest SLNs in previously treated nodal basins. In untreated OSCC identification rates of 97–98% have been reported, while in this study a rate of 85% was found [16,17,20,21]. All patients without harvested SLNs had radiotherapy in history, sometimes combined with surgery. This lower identification rate was not observed in patients with a prior SLNB procedure, possibly reflecting that SLNB ensures less damage to lymphatic vessels compared to radiotherapy. Furthermore, despite the lower identification rate in previously treated patients no lower NPV of the SLNB for neck staging was found in this study. This might indicate that lymphatic drainage patterns in these patients are not only aberrant, but may even be absent. Nonetheless, this study included only three patients with positive SLNs and one patient with a regional recurrence after a negative SLNB procedure. Due to the low number of SLN positive patients and regional recurrences, it might be prematurely to conclude that SLNB is a reliable procedure in previously treated patients. This is also reflected in a sensitivity rate with a wide 95% CI. However, the high NPV of 98% with a 95% CI of 88–100% strongly suggest that SLNB is a promising procedure for these pretreated patients, but its reliability needs further investigation.

Although surgery of the lymphatic drainage patterns is part of the SLNB procedure, the procedure is strictly not part of the treatment but belongs to the diagnostic modalities for neck staging. Therefore sub-analysis of patients with a history of neck treatment (neck dissection and/or radiotherapy) are presented in the results regarding the accuracy of the SLNB procedure and lymphatic drainage patterns. These figures indicate that in OSCC patients who had undergone more extensive treatment of the neck (i.e. neck dissection and/or radiotherapy) lymphatic drainage follow more frequently an unexpected pattern or was absent (35% vs 30%). Due to the low number of lymph node metastases (2 and 3) the sensitivity of SLNB (50% and 75%) could not sensibly be compared.

Unexpected drainage pathways are generally reported in all tumour types, including our study. These findings strengthen the value of SLNB

in assessing the individual lymphatic drainage pattern. In patients who received already prior treatment (e.g. radiotherapy) it is perhaps even more important to select the actual lymph nodes at risk for metastasis, considering the fact that treatment options are limited due to their prior therapy. In this study an overall unexpected drainage pattern was found in 30% of the patients, which was most frequently found after prior radiotherapy (40%) and especially when this was preceded by a neck dissection (88%). In early stage OSCC patients with an untreated neck unexpected drainage patterns were reported in up to 16% in a large multicenter trial [22].

Even though it is well possible to determine individual drainage patterns with the SLNB, one of the disadvantages is to perform an additional neck dissection during a second surgical procedure in case of a positive SLNB procedure. Although improvements, a recent review concluded that still no other modality (e.g., ultrasound, CT, MRI and PET-CT) is accurate enough to detect occult metastasis preoperatively in a clinically negative neck reliably [23]. Moreover, posttreatment effects and the high rate of unexpected drainage in pretreated patients might affect the sensitivity of these modalities in detecting occult metastasis.

A limitation of the accuracy analysis is the low number of metastasis and regional recurrences in our cohort. A possible explanation for these low numbers compared to untreated patients (with an often reported risk of nodal metastases of approximately 25–30%) could be our close follow-up scheme after treatment of their first tumour. Patients in follow-up are potentially earlier diagnosed with recurrent or second primary OSCC, which might cause a relatively high number of early T1 tumours in this cohort. Despite these limitations, this study showed that metastasis appear in early stage local recurrences and second primary tumours. Currently, no guidelines about neck treatment are available for cT1-2N0 OSCC patients with a previously treated neck. In untreated OSCC prognosis was better after an elective neck dissection (of the standard lymph node levels at risk for metastasis) compared to a ‘wait and see’ policy [24]. Because of the aberrant drainage patterns, we advocate to use the SLNB also in patients with early stage second primaries or local recurrences to select patients who might benefit from treatment of the neck. However, more extensive research is needed to confirm that this strategy actually improves the prognosis of these patients.

## Conclusion

SLNB seems to be a reliable procedure for neck staging of cT1-2N0 OSCC patients with a previously treated neck. Moreover, SLNB determines the individual lymphatic drainage patterns, enabling visualization of drainage pattern variability in 30% of these patients.

## Declaration of Competing Interest

The authors of the manuscript ‘High rate of unexpected lymphatic drainage patterns and high accuracy of sentinel lymph node biopsy in oral cancer after previous neck treatment’ have no conflict of interest to declare.

## Appendix A. Supplementary material

Supplementary data to this article can be found online at <https://doi.org/10.1016/j.oraloncology.2019.05.007>.

## References

- [1] Argiris A, Karamouzis MV, Raben D, Ferris RL. Head and neck cancer. *Lancet* 2008;371:1695–709.
- [2] Larsen SR, Johansen J, Sorensen JA, Kroghdahl A. The prognostic significance of histological features in oral squamous cell carcinoma. *J Oral Pathol Med* 2009;38:657–62.
- [3] Leemans CR, Tiwari R, Nauta JJ, van der Waal I, Snow GB. Regional lymph node

- involvement and its significance in the development of distant metastases in head and neck carcinoma. *Cancer* 1993;71:452–6.
- [4] Liu M, Wang SJ, Yang X, Peng H. Diagnostic efficacy of sentinel lymph node biopsy in early oral squamous cell carcinoma: a meta-analysis of 66 studies. *PLoS ONE* 2017;12:e0170322.
- [5] Flach GB, Broglie MA, van Schie A, Bloemena E, Leemans CR, de Bree R, et al. Sentinel node biopsy for oral and oropharyngeal squamous cell carcinoma in the previously treated neck. *Oral Oncol* 2012;48:85–9.
- [6] Leemans CR, Braakhuis BJ, Brakenhoff RH. The molecular biology of head and neck cancer. *Nat Rev Cancer* 2011;11:9–22.
- [7] Licciardello JT, Spitz MR, Hong WK. Multiple primary cancer in patients with cancer of the head and neck: second cancer of the head and neck, esophagus, and lung. *Int J Radiat Oncol Biol Phys* 1989;17:467–76.
- [8] Snow GB, De Vries N, Van Zandwijk N, Pinedo HM. Second primary cancers in the lung in head and neck cancer patients: a challenge. *Eur J Cancer Clin Oncol* 1987;23:883–6.
- [9] Pitman KT, Johnson JT, Brown ML, Myers EN. Sentinel lymph node biopsy in head and neck squamous cell carcinoma. *Laryngoscope* 2002;112:2101–13.
- [10] Ahmed M, Baker R, Rubio IT. Meta-analysis of aberrant lymphatic drainage in recurrent breast cancer. *Br J Surg* 2016;103:1579–88.
- [11] Derkx F, Maaskant-Braat AJ, van der Sangen MJ, Nieuwenhuijzen GA, van de Poll-Franse LV, Roumen RM, et al. Staging and management of axillary lymph nodes in patients with local recurrence in the breast or chest wall after a previous negative sentinel node procedure. *Eur J Surg Oncol* 2010;36:646–51.
- [12] Kaur P, Kiluk JV, Meade T, Ramos D, Koeppl W, Jara J, et al. Sentinel lymph node biopsy in patients with previous ipsilateral complete axillary lymph node dissection. *Ann Surg Oncol* 2011;18:727–32.
- [13] Palit G, Jacquemyn Y, Tjalma W. Sentinel node biopsy for ipsilateral breast cancer recurrence: a review. *Eur J Gynaecol Oncol* 2008;29:565–7.
- [14] van der Ploeg IM, Oldenburg HS, Rutgers EJ, Baas-Vrancken Peeters MJ, Kroon BB, Valdes Olmos RA, et al. Lymphatic drainage patterns from the treated breast. *Ann Surg Oncol* 2010;17:1069–75.
- [15] Beasley GM, Hu Y, Youngwirth L, Scheri RP, Salama AK, Rossfeld K, et al. Sentinel lymph node biopsy for recurrent melanoma: a multicenter study. *Ann Surg Oncol* 2017;24:2728–33.
- [16] Boeve K, Schepman KP, Schuurings E, Roodenburg JLN, Halmos GB, van Dijk BAC, et al. High sensitivity and negative predictive value of sentinel lymph node biopsy in a retrospective early stage oral cavity cancer cohort in the Northern Netherlands. *Clin Otolaryngol* 2018. <https://doi.org/10.1111/coa.13107>.
- [17] Den Toom IJ, Heuveling DA, Flach GB, van Weert S, Karagozoglu KH, van Schie A, et al. Sentinel node biopsy for early-stage oral cavity cancer: the VU University Medical Center experience. *Head Neck* 2015;37:573–8.
- [18] Shah JP, Candela FC, Poddar AK. The patterns of cervical lymph node metastases from squamous carcinoma of the oral cavity. *Cancer* 1990;66:109–13.
- [19] van Doorn HC, van Beekhuizen HJ, Gaarenstroom KN, van der Velden J, van der Zee AG, Oonk MH, et al. Repeat sentinel lymph node procedure in patients with recurrent vulvar squamous cell carcinoma is feasible. *Gynecol Oncol* 2016;140:415–9.
- [20] Pedersen NJ, Jensen DH, Hedback N, Frendo M, Kiss K, Lelkaitis G, et al. Staging of early lymph node metastases with the sentinel lymph node technique and predictive factors in T1/T2 oral cavity cancer: a retrospective single-center study. *Head Neck* 2016;38(Suppl 1):E1033–40.
- [21] Schilling C, Stoeckli SJ, Haerle SK, Broglie MA, Huber GF, Sorensen JA, et al. Sentinel European Node Trial (SENT): 3-year results of sentinel node biopsy in oral cancer. *Eur J Cancer* 2015;51:2777–84.
- [22] Tartaglione G, Stoeckli SJ, de Bree R, Schilling C, Flach GB, Bakholt V, et al. Sentinel node in oral cancer: the nuclear medicine aspects. A survey from the sentinel European node trial. *Clin Nucl Med* 2016;41:534–42.
- [23] de Bree R, Takes RP, Castelijns JA, Medina JE, Stoeckli SJ, Mancuso AA, et al. Advances in diagnostic modalities to detect occult lymph node metastases in head and neck squamous cell carcinoma. *Head Neck* 2015;37(12):1829–39.
- [24] D'Cruz AK, Vaish R, Kapre N, Dandekar M, Gupta S, Hawaldar R, et al. Elective versus therapeutic neck dissection in node-negative oral cancer. *N Engl J Med* 2015;373(6):521–9.