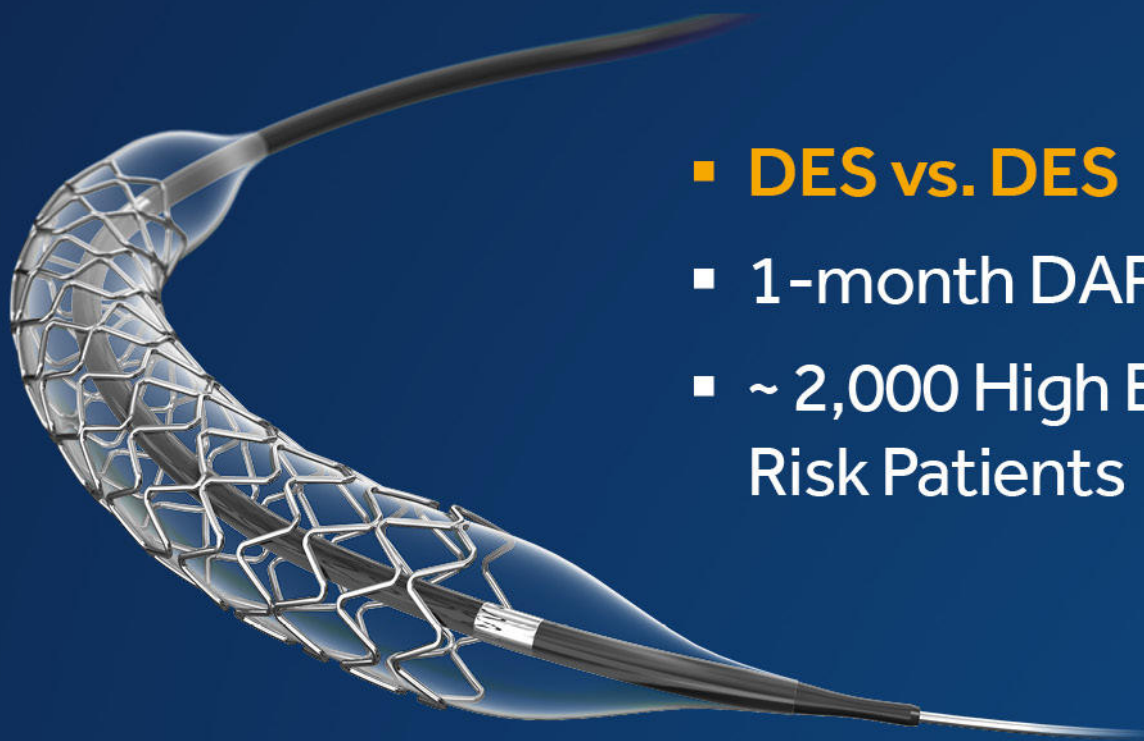

ONYX ONE GLOBAL STUDY



- **DES vs. DES**
- 1-month DAPT
- ~ 2,000 High Bleeding Risk Patients

[VIEW THE RESULTS](#)

Medtronic

CASE REPORT

Endovascular coil embolization of a complex aortic arch pseudoaneurysm following arch stenting

Timion A. Meijs MD¹  | Gregor J. Krings MD, PhD² | Mirella M. C. Molenschot MD² | Michiel Voskuil MD, PhD¹

¹Department of Cardiology, University Medical Center Utrecht, Utrecht, The Netherlands

²Department of Pediatric Cardiology, Wilhelmina Children's Hospital, Utrecht, The Netherlands

Correspondence

Timion A. Meijs, MD, Department of Cardiology, University Medical Center Utrecht, Heidelberglaan 100, 3584 CX Utrecht, The Netherlands.
Email: t.a.meijs-5@umcutrecht.nl

Abstract

Pseudoaneurysm formation is a life-threatening complication of thoracic aortic stenting due to the high risk of rupture. When located in the aortic arch, anatomic features may pose difficulties in choosing the optimal treatment strategy. Here, we describe the first poststenting aortic arch pseudoaneurysm treated by endovascular coil embolization. This approach, which we performed in a multidisciplinary setting, may be a feasible alternative in patients not considered suitable for open repair or stent-grafting. As an acute pseudoaneurysm may develop and rapidly expand during the first days after aortic stenting, early follow-up imaging is preferable.

KEYWORDS

aortic arch stenting, coil embolization, false aneurysm

1 | INTRODUCTION

Over the last years, stent implantation has become the treatment of choice in adults with native or recurrent aortic coarctation.¹ In addition, stenting is increasingly used to correct aortic arch obstruction due to hypoplasia or aberrant geometry of the arch.² Although rare, stenting of the thoracic aorta may be complicated by acute aortic wall injury, including dissection and pseudoaneurysm formation.³ In this case, we illustrate that the complex anatomy associated with aortic arch pseudoaneurysms may limit standard treatment options and may therefore require an alternative, multidisciplinary approach.

2 | CASE REPORT

A 36-year-old male presented with systolic hypertension despite treatment with three antihypertensive agents. He had a history of surgical repair of aortic coarctation by patch angioplasty during infancy. Balloon angioplasty and surgical aortoplasty were performed to treat recurrent coarctation at age 17 and 28, respectively. At age 35, two overlapping ev3 Max LD stents (ev3 Inc., Plymouth, MN)

were placed for aortic arch obstruction due to pronounced gothic geometry of the arch. Because of persistent hypertension under medication, recatheterization was performed. In response to the blood pressure-lowering effect of conscious sedation, 40 µg of epinephrine was administered to reach a systolic blood pressure comparable to daily life. Although no pressure gradient was detected across the coarctation site, a pressure gradient of 25 mmHg was measured across the aortic arch. This gradient matched the most narrow and rigid aspect of the stented gothic arch. Balloon dilatation with a 22 × 20 mm Atlas PTA balloon (Bard Peripheral Vascular Inc., Tempe, AZ) at 26 atm was ineffective, showing recoil of the previously placed ev3 stents and a residual pressure gradient of 15 mmHg. Therefore, a 45 mm non-covered Cheatham-Platinum (CP) stent (NuMED Inc., Hopkinton, NY) on a 24 × 45 mm balloon-in-balloon catheter (NuMED) was implanted for additional radial strength. Although angiography showed an improved anatomical result, the elevated pressure gradient persisted. Consequently, postdilatation with a 24 × 20 mm Atlas PTA balloon at 12 atm was performed, resulting in near elimination of the pressure gradient. Final angiography showed no evidence of iatrogenic aortic wall injury.

At our institution, computed tomography angiography (CTA) is routinely performed the day after aortic stenting. This CTA revealed

This is an open access article under the terms of the Creative Commons Attribution-NonCommercial License, which permits use, distribution and reproduction in any medium, provided the original work is properly cited and is not used for commercial purposes.

© 2019 The Authors. *Catheterization and Cardiovascular Interventions* published by Wiley Periodicals, Inc.

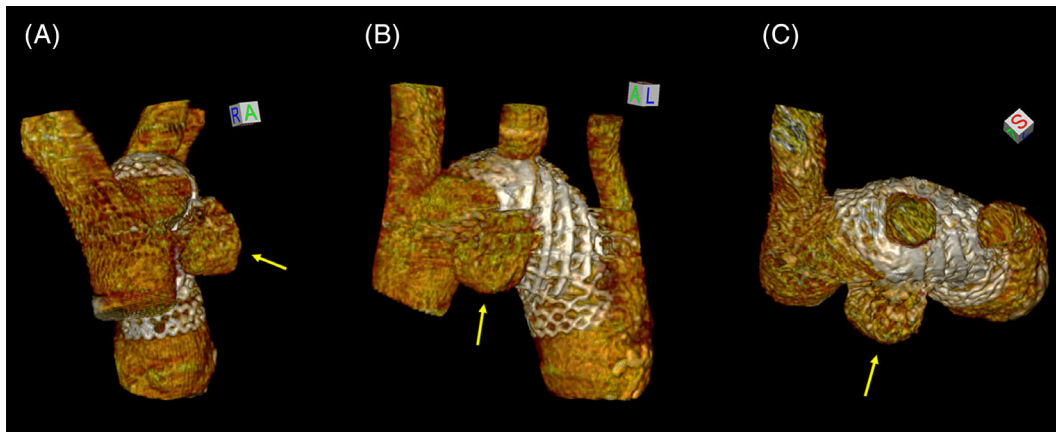


FIGURE 1 Three-dimensional reconstruction of the follow-up CTA performed after additional CP stent implantation, displayed in frontal (A), lateral (B), and cranial (C) planes. Note the 20 × 14 mm pseudoaneurysm located ventroproximally to the CP stent (yellow arrows). CP, Cheatham-Platinum; CTA, computed tomography angiography [Color figure can be viewed at wileyonlinelibrary.com]

a 17 × 12 mm pseudoaneurysm located ventroproximally to the additionally placed CP stent. The patient was asymptomatic. Despite the severity of this complication, the acute risk of rupture was considered limited due to the presence of excessive scar tissue as a result of multiple prior surgical procedures. Therefore, initial management was conservative, consisting of serial imaging and strict heart rate and blood pressure regulation with a systolic blood pressure target below 120 mmHg. After 4 days, CTA showed no spontaneous thrombosis of the aneurysm. Instead, it had expanded to 20 × 14 mm (Figure 1A–C). Therefore, it was decided to perform endovascular coiling of the pseudoaneurysm. Under general anesthesia, a 6 Fr sheath (Glidesheath Slender, Terumo Corp., Tokyo, Japan) was inserted into the right brachial artery. A 6 Fr RDC guiding catheter (Boston Scientific Corp., Marlborough, MA) was then advanced, accommodating a 5 Fr headhunter-shaped TEMPO AQUA catheter (Cordis Corp., Fremont, CA). Subsequently, a 45° PX SLIM microcatheter (Penumbra Inc., Alameda, CA) was introduced, which enabled placement of 16 coils (Ruby Coil, Penumbra Inc.) in the aneurysm sac. This resulted in successful exclusion of the pseudoaneurysm from the circulation (Figure 2A,A',B,B'). However, follow-up imaging after 1 week showed that coil impaction had caused a residual defect of 8 × 7 mm in the cranial part of the aneurysm, requiring additional coiling. Similarly to the first coiling procedure, the right brachial artery was punctured, a 6 Fr sheath was introduced (Glidesheath Slender, Terumo Corp.), and a 6 Fr RDC guiding catheter (Boston Scientific Corp.) was advanced. After the subsequent introduction of a 45° Headway 17 microcatheter (MicroVention Inc., Aliso Viejo, CA), 8 additional coils (Ruby Coil, Penumbra Inc.) were placed (Figure 2C,C',D,D'). Follow-up imaging at 6 months showed a good result with complete closure of the pseudoaneurysm (Figure 3). The patient was normotensive, although still on antihypertensive medication.

3 | DISCUSSION

An aortic pseudoaneurysm is defined as a disruption of all layers of the aortic wall with containment of blood by periaortic connective

tissue.⁴ Although pseudoaneurysms of the thoracic aorta are rare, they may be caused by blunt trauma, surgical or transcatheter interventions, infections (mycotic aneurysms), or penetrating ulcers.^{5,6} Development of these aneurysms is potentially fatal due to the high risk of rupture, aortoesophageal fistula formation and compression of surrounding tissues.⁶ As a consequence, early detection and treatment are of importance, particularly in a rapidly expanding aneurysm as in our case. Ascending aortic aneurysms are generally treated by open surgical repair, whereas aneurysms of the descending thoracic aorta have been increasingly managed by endovascular stent-grafting due to improved short-term survival and neurological outcomes compared to surgery.⁷ However, the optimal treatment of aortic arch aneurysms is less evident. Their anatomy often presents unique challenges to avoid malperfusion of the supra-aortic branches. The choice of intervention should be determined on an individual basis, taking into account the extent and expansion of the aneurysm, location in the arch, comorbidities, and prior aortic interventions. Generally, arch aneurysms may be treated by open surgical repair, stent-grafting, or a hybrid approach.⁸ Our patient was considered a poor candidate for open repair or a hybrid procedure, due to the multiple prior cardiothoracic interventions and relatively high complication rates associated with these procedures.⁹ Taking into account the proximity of the left carotid artery and the large aortic arch diameter poststenting, implantation of an additional covered stent-graft was not our preferred option either. Furthermore, the subacute setting did not allow for the fabrication of a customized branched or fenestrated stent-graft. However, we found a limited number of reports describing coil embolization as a feasible alternative treatment of arch aneurysms that developed after surgical repair of type A aortic dissection.^{10–12} To our knowledge, we present the first coiling procedure of an aortic arch pseudoaneurysm following stenting. Coil embolization is frequently used by interventional radiologists in the treatment of intracranial aneurysms.¹³ Complex intracranial aneurysms may even be treated by stent-assisted coiling, which has shown to reduce recurrence rates compared to standard coiling.¹⁴ The analogy with the current case is striking and emphasizes the added value of a multidisciplinary approach to treat complex aneurysms.

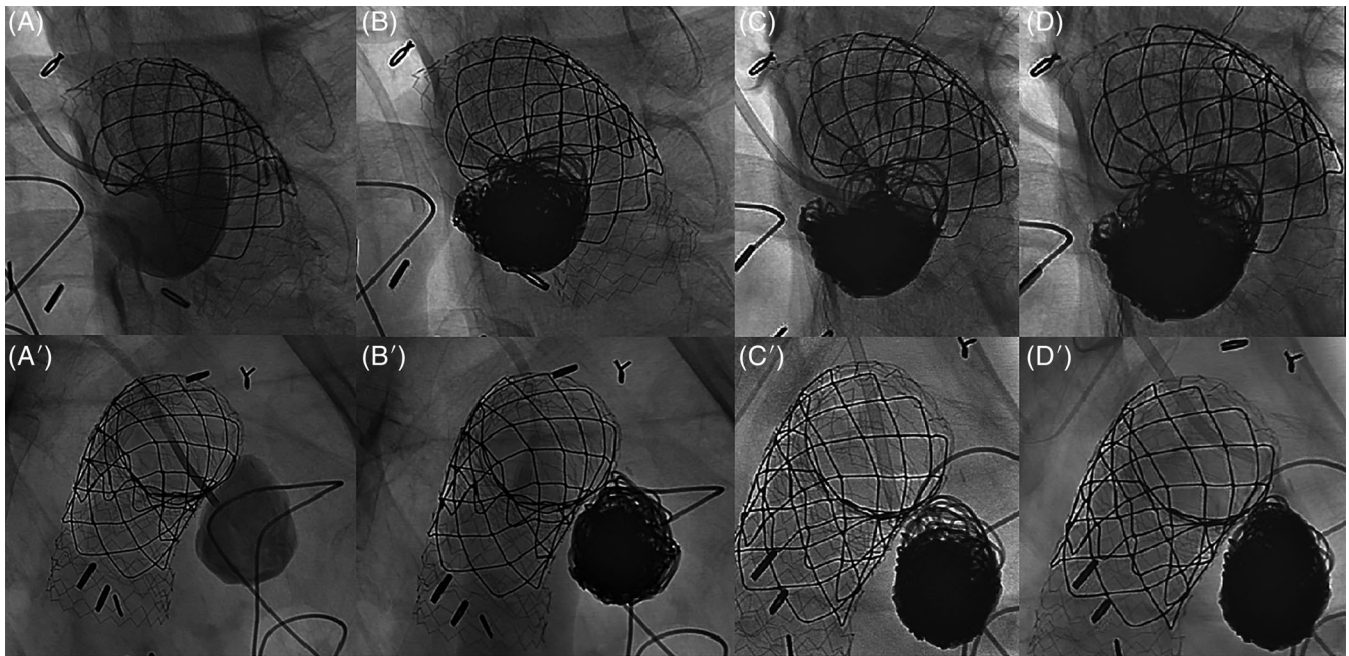


FIGURE 2 Angiography showing the pseudoaneurysm before (A,A') and after (B,B') the first coiling procedure. Due to coil impaction, an 8 × 7 mm cranial defect with residual contrast filling developed within 1 week (C,C'). Consequently, additional coiling was performed, resulting in successful closure of the pseudoaneurysm (D,D')

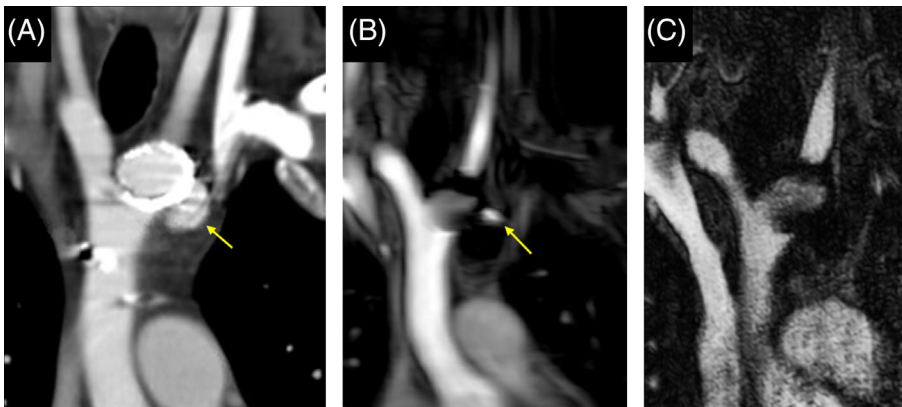


FIGURE 3 Serial imaging of the proximal aorta in a coronal plane. Part (A) shows the pseudoaneurysm (yellow arrow) prior to coil embolization on CTA. Magnetic resonance angiography (MRA) after the first coiling procedure (B) showed residual contrast filling in the cranial part of the aneurysm sac (yellow arrow). After additional coiling, no residual contrast filling was observed on follow-up MRA (C). CTA, computed tomography angiography [Color figure can be viewed at wileyonlinelibrary.com]

Currently, the timing of follow-up imaging after aortic stenting varies widely across institutions.¹⁵ Although AHA/ACC guidelines state that postinterventional imaging is recommended, no timing interval is provided.¹ As demonstrated by this case, aortic wall injury may not be present or recognized at the end of the stenting procedure, but instead develop during the first days after the procedure. In our opinion, this underlines the importance of routine CTA early after stent implantation, preferably before hospital discharge. Prospective studies are needed to determine the optimal timing of follow-up imaging after aortic stenting.

4 | CONCLUSION

An aortic arch pseudoaneurysm is a rare and anatomically challenging complication of aortic stenting. In this report, we show that endovascular

coil embolization may be a feasible alternative option when the patient is not suitable for open repair or stent-grafting.

ACKNOWLEDGMENTS

We would like to thank Gertjan Sieswerda, MD, PhD, Folkert Meijboom MD, PhD, FESC, and Evert-Jan Vonken, MD, PhD for their contribution to this patient's care and the preparation of this case report.

CONFLICT OF INTEREST

The authors have no conflict of interest to disclose.

ORCID

Timion A. Meijs  <https://orcid.org/0000-0002-7320-996X>

REFERENCES

1. Stout KK, Daniels CJ, Aboulhosn JA, et al. 2018 AHA/ACC guideline for the management of adults with congenital heart disease. *Circulation*. 2019;139(14):e698-e800.
2. Pushparajah K, Sadiq M, Brzezińska-Rajszyś G, Thomson J, Rosenthal E, Qureshi SA. Endovascular stenting in transverse aortic arch hypoplasia. *Catheter Cardiovasc Interv*. 2013;82(4):E491-E499.
3. Qureshi AM, McElhinney DB, Lock JE, Landzberg MJ, Lang P, Marshall AC. Acute and intermediate outcomes, and evaluation of injury to the aortic wall, as based on 15 years experience of implanting stents to treat aortic coarctation. *Cardiol Young*. 2007;17(3):307-318.
4. Hiratzka LF, Bakris GL, Beckman JA, et al. 2010 ACCF/AHA/AATS/ACR/ASA/SCA/SCAI/SIR/STS/SVM guidelines for the diagnosis and management of patients with thoracic aortic disease. *J Am Coll Cardiol*. 2010;55(14):e27-e129.
5. Atik FA, Navia JL, Svensson LG, et al. Surgical treatment of pseudoaneurysm of the thoracic aorta. *J Thorac Cardiovasc Surg*. 2006;132(2):379-385.
6. Erbel R, Aboyans V, Boileau C, et al. 2014 ESC guidelines on the diagnosis and treatment of aortic diseases: document covering acute and chronic aortic diseases of the thoracic and abdominal aorta of the adult. *Eur Heart J*. 2014;35(41):2873-2926.
7. Cheng D, Martin J, Shennib H, et al. Endovascular aortic repair versus open surgical repair for descending thoracic aortic disease a systematic review and meta-analysis of comparative studies. *J Am Coll Cardiol*. 2010;55(10):986-1001.
8. De Rango P, Ferrer C, Coscarella C, et al. Contemporary comparison of aortic arch repair by endovascular and open surgical reconstructions. *J Vasc Surg*. 2015;61(2):339-346.
9. Clare R, Jorgensen J, Brar SS. Open versus endovascular or hybrid thoracic aortic aneurysm repair. *Curr Atheroscler Rep*. 2016;18(10):60.
10. Ma T, Dong ZH, Fu WG, Chen B, Jiang JH, Shi Y. Endovascular management of a ruptured aortic arch pseudoaneurysm using the snorkel technique and coil embolization. *Ann Vasc Surg*. 2017;41:281.e7-281.e10.
11. Ishii H, Nakamura K, Nakamura E, Furukawa K, Ochiai K. Successful embolization therapy through reentry tear in the right subclavian artery for treating patent false lumen in the aortic arch formed after type A dissection repair. *Ann Vasc Dis*. 2017;10(3):261-264.
12. Zink JN, Maness MR, Powell CS, et al. Coil embolization of persistent false lumen after type A dissection repair. *Ann Thorac Surg*. 2014;97(6):2193-2196.
13. Pierot L, Wakhloo AK. Endovascular treatment of intracranial aneurysms: current status. *Stroke*. 2013;44(7):2046-2054.
14. Yang H, Sun Y, Jiang Y, et al. Comparison of stent-assisted coiling vs coiling alone in 563 intracranial aneurysms: safety and efficacy at a high-volume center. *Neurosurgery*. 2015;77(2):241-247. discussion 247.
15. Boccalini S, den Harder AM, Witsenburg M, et al. Complications after stent placement for aortic coarctation: a pictorial essay of computed tomographic angiography. *J Thorac Imaging*. 2017;32(6):W69-W80.

How to cite this article: Meijs TA, Krings GJ, Molenschot MMC, Voskuil M. Endovascular coil embolization of a complex aortic arch pseudoaneurysm following arch stenting. *Catheter Cardiovasc Interv*. 2019;94:1006–1009. <https://doi.org/10.1002/ccd.28424>