

---

## REVIEW ARTICLE

---

# Safe Use of Epidural Corticosteroid Injections: Recommendations of the WIP Benelux Work Group

---

Koen Van Boxem, MD, FIPP, PhD<sup>\*</sup>; Mienke Rijdsdijk, MD, PhD<sup>†</sup>; Guy Hans, MD, PhD<sup>‡,§</sup>; Jasper de Jong, MD<sup>¶</sup>; Jan Willem Kallewaard, MD, FIPP<sup>\*\*</sup>; Kris Vissers, MD, FIPP, PhD<sup>††</sup>; Maarten van Kleef, MD, FIPP, PhD<sup>‡‡</sup>; James P. Rathmell, MD, FIPP<sup>§§,¶¶</sup>; Jan Van Zundert, MD, FIPP, PhD<sup>\*,‡‡</sup>

*\*Department of Anesthesiology, Critical Care and Multidisciplinary Pain Center, Ziekenhuis Oost-Limburg, Genk/Lanaken, Belgium; †Pain Clinic, Department of Anesthesiology, University Medical Center Utrecht, Utrecht, The Netherlands; ‡Multidisciplinary Pain Center, Antwerp University Hospital, Edegem; §Laboratory for Pain Research, University of Antwerp, Wilrijk, Belgium; ¶Department of Pain Management, Westfriesgasthuis, Hoorn; \*\*Department of Anesthesiology and Pain Management, Rijnstate Ziekenhuis, Arnhem; ††Department of Anesthesiology, Pain and Palliative Medicine, Radboud University Nijmegen Medical Center, Nijmegen; ‡‡Department of Anesthesiology and Pain Management, University Medical Centre Maastricht, Maastricht, The Netherlands; §§Department of Anesthesia and Critical Care, Massachusetts General Hospital, Boston, Massachusetts; ¶¶Department of Anesthesiology, Perioperative, and Pain Medicine, Brigham and Women's Hospital, Boston, Massachusetts, U.S.A.*

### ■ Abstract

**Background:** Epidural corticosteroid injections are used frequently worldwide in the treatment of radicular pain. Concerns have arisen involving rare major neurologic injuries after this treatment. Recommendations to prevent these

Address correspondence and reprint requests to: Koen Van Boxem, MD, FIPP, PhD, Department of Anesthesiology, Critical Care and Multidisciplinary Pain Center, Ziekenhuis Oost-Limburg, Bessemerstraat 478, 3620 Lanaken, Belgium. E-mail: koen.vb@telenet.be.

Submitted: February 21, 2018; Revision accepted: May 3, 2018  
DOI: 10.1111/papr.12709

---

© 2018 The Authors. *Pain Practice* published by Wiley Periodicals, Inc. on behalf of World Institute of Pain. This is an open access article under the terms of the Creative Commons Attribution-NonCommercial License, which permits use, distribution and reproduction in any medium, provided the original work is properly cited and is not used for commercial purposes., 1530-7085/18/\$15.00  
*Pain Practice*, Volume 19, Issue 1, 2019 61–92

complications have been published, but local implementation is not always feasible due to local circumstances, necessitating local recommendations based on literature review.

**Methods:** A work group of 4 stakeholder pain societies in Belgium, The Netherlands, and Luxembourg (Benelux) has reviewed the literature involving neurological complications after epidural corticosteroid injections and possible safety measures to prevent these major neurologic injuries.

**Results:** Twenty-six considerations and recommendations were selected by the work group. These involve the use of imaging, injection equipment particulate and nonparticulate corticosteroids, epidural approach, and maximal volume to be injected.

**Conclusion:** Raising awareness about possible neurological complications and adoption of safety measures recommended by the work group aim at reducing the risks for these devastating events. ■

**Key Words:** epidural, corticosteroid, complications, dexamethasone, safe use

## INTRODUCTION

### Purpose

Epidural corticosteroid injections (ESIs) are used frequently worldwide for their symptomatic effect.<sup>1</sup> Reports of complications published in the past decade involving the use of epidural corticosteroids led the U.S. Food and Drug Administration (FDA) in April 2014 to request that an additional warning be added for the epidural use of corticosteroids in the prescribing information of all available corticosteroids, including non-particulate steroids. This was confirmed in a publication in the *New England Journal of Medicine*.<sup>2</sup> In this warning, it was emphasized that epidural injections of steroids may cause spinal cord infarction, paraplegia, quadriplegia, cortical blindness, and stroke.

Furthermore, the epidural administration of corticosteroids has not officially been approved by the FDA or the European Medicines Agency (EMA),<sup>2</sup> which means that it is classified as “off-label” use. The latter reflects the current clinical practice<sup>3</sup> but is also a challenge since the effectiveness of treatment must be weighed against the risk for complications.

The FDA’s “Safe Use Initiative” aided in convening a group of experts on ESIs and led to the publication of a consensus paper of 13 stakeholder societies.<sup>3</sup> In this consensus, dexamethasone was given a prominent place for transforaminal (TF) epidural injections; however, this product is only distributed in the Benelux Union by 1 compounding pharmacy, and the long-term safety of this product is not known.<sup>4</sup> The simple implementation of these U.S. guidelines was therefore not feasible and necessitated the organization of a local task force to review the literature. The Benelux work group reviewed the literature on complications of ESIs to provide an updated and practical set of safety recommendations regarding the use of ESIs.

## METHODS

To identify the potential complications of epidural corticosteroid administration, a literature search was conducted in January 2016 using the search strategy on abstract words [Steroid] or [Corticosteroid] and [Epidural] and [Complications]. The 148 titles and abstracts retrieved were reviewed by the senior author (K.V.B.) to

define the type of complications that needed further evaluation and to identify the papers to be used for this review.

The research questions were divided among the authors, who each performed a review and formulated a response. After compilation of the responses, the members of the work group commented on the complete paper. Once a consensus was obtained in the work group, the manuscript was reviewed by the board of the different pain societies (World Institute of Pain Benelux section, Nederlandse Vereniging Anesthesiologie section pain medicine, Vlaamse Anesthesiologische Vereniging voor Pijnbestrijding, Belgian Pain Society). The comments were incorporated, and the final version was then validated by the board of the different pain societies.

### Complications After Epidural Corticosteroids: Overview

**Physiological Effects. Bone demineralization** – There is uncertainty about the dose of corticosteroids above which clinically significant bone loss and increased risk for fracture occurs. However, doses as low as 2.5 mg prednisone may be enough.<sup>5</sup> The number of fractures doubles even with oral or intermittent administration, such as an ESI.<sup>6</sup> A group of postmenopausal women sensitive to bone loss who received an epidural injection of triamcinolone 80 mg were followed prospectively. A reduction in the mineral bone density of the hip and an increase in serum markers for bone turnover were observed at a 6-fold increase compared to the average annual bone loss in a matched control group.<sup>7</sup> Retrospective studies confirm that postmenopausal women who are given multiple ESIs have a lower mineral bone density score when they receive higher doses of corticosteroids (cumulative dose of triamcinolone >200 mg).<sup>8</sup> A large retrospective cohort study compared the data of 3,000 patients with spinal pain who received a lumbar ESI with the data of 3,000 matched controls who did not receive injections. Each ESI increased the fracture risk by 31%.<sup>9</sup> It is therefore recommended to keep the corticosteroid exposure to a minimum, particularly for high-risk patients such as the elderly and women with a prior history of osteoporosis or osteopenia.<sup>10</sup>

**Suppression of the hypothalamic-pituitary-adrenal (HPA) axis** – An ESI can cause Cushing’s syndrome. In exceptional cases the HPA axis can still be suppressed 6 to 8 months after the injection.<sup>11,12</sup> HPA axis

suppression without Cushing's syndrome occurs frequently and can continue for 3 to 6 weeks.<sup>13,14</sup>

**Immune system** – Corticosteroids can cause a dose-dependent suppression of the immune system that arises as a result of the transcriptional changes that suppress the inflammatory genes, upregulate the anti-inflammatory genes, and inhibit B and C cell phagocytes.<sup>15</sup> There are no retrospective studies on rates of infection following ESI, but case reports have shown that, after ESI, an infection can occur in patients with existing immunosuppressive conditions, such as diabetes, cancer (with and without metastases), and neutropenia, and in patients taking oral corticosteroids, with a history of infections,<sup>16</sup> and with renal failure.<sup>17</sup>

**Glucose values** – Immediately following ESI, elevated glucose levels can be seen in diabetes patients (insulin-dependent and non-insulin-dependent)<sup>18</sup>; elevated glucose levels may persist for two<sup>19</sup> to six<sup>20</sup> days after the injection. Patients with diabetes must be given information on hyperglycemia after the injection and understand the possible need to adjust their diet and/or their diabetic treatment.<sup>10</sup>

**Minor Complications.** Minor complications are complications without permanent damage that may occur after caudal, interlaminar, or TF administration in the lumbar region or after interlaminar cervical corticosteroid administration. There is no information available on thoracic interlaminar or cervical TF injections.<sup>21</sup> Table 1 summarizes the types of complications and their incidence.

Other minor complications after cervical interlaminar ESIs<sup>22</sup> are axial neck pain, neck pain not position related, flushing in the face, nausea and vomiting, fever the night after the intervention (0.3%), sensitivity at the injection site, a hypotensive episode, respiratory

insufficiency,<sup>23</sup> subjective weakness in the arms for 24 hours, and insomnia.

When using the “loss of resistance” technique, accidental dural puncture may result in pneumocephalus (air injected in the subarachnoid space that rises to the brain), as described in 8 cases.<sup>24</sup> This type of headache is different from postdural puncture headache because it results in an immediate headache, is not related to a certain position, and is sometimes coupled with neurological symptoms.<sup>25</sup>

Flushing can arise during both interlaminar and TF injections as a result of immunoglobulin E-mediated mechanisms. The reported incidence varies from 0.1% to 11%.<sup>26</sup> This can be prevented by the prophylactic administration of an antihistamine.

Persistent hiccup, probably due to the stimulation of the afferent hiccup reflex curve of the phrenic nerve, vagal nerve, or sympathetic nerves of T6–T12, disappears with conservative measures or chlorpromazine.<sup>27</sup>

**Intradiscal injections** – Unwanted injection in the intervertebral disc during ESI is not uncommon; it can be overlooked by those performing the procedure and is therefore insufficiently reported in the literature.<sup>28</sup> This happens more frequently with TF injections (from 0.17% to over 2%) than with interlaminar procedures (0.02% to 0.07%).<sup>28–31</sup>

If the needle is placed in the antero-inferior aspect of the foramen (ie, closer to the disc), this will probably increase the chances for intradiscal injection. Despite optimal placement of the needle, it is possible for intradiscal spread of contrast fluid to occur; this is due to the routes that link the epidural space with the intervertebral disc. This emphasizes the need to use fluoroscopy to track down this complication.<sup>30</sup> Intradiscal injection is typically of no consequence, but if infection occurs, such as spondylodiscitis, this can have catastrophic results. That is why some experts suggest the administration of prophylactic antibiotics in higher-risk patients.<sup>28,30</sup>

**Major Complications. Needle trauma** – In 1994, Bogduk pointed out that most complications are not related to the type of corticosteroid that is injected, but more closely linked to the use of needles or the injection of substances other than corticosteroids.<sup>32</sup> This was later confirmed in closed medical malpractice claims studies, in which the majority of complications involved direct nerve trauma or spinal cord injury.<sup>33,34</sup> Temporary damage to the spinal nerves can occur, especially with

**Table 1. Minor Complications Reported after Epidural Corticosteroid Injections**

Type of Complication	Frequency
All minor complications	2.4% (per injection)
Accidental disc puncture <sup>21</sup>	2.3% (lumbar)
Transient exacerbation of pain	1.1%
Accidental dural puncture <sup>22</sup>	0.33% to 1% (lumbar) and 0.25% to 2.65% (cervical)
Pain at injection	0.33%
Persistent numbness	0.14%
Vasovagal response	0% to 1% (lumbar) and 0.04% to 8% (cervical)

**Table 2. Information Regarding Injectable Corticosteroids that Are Approved by the U.S. Food and Drug Administration<sup>1</sup>**

Corticosteroid	Tradename	Sponsor	Suspension or Solution	Solubility in H <sub>2</sub> O	Notable Excipients
Betamethasone acetate, betamethasone sodium phosphate	Celestone Soluspan	Merck Sharpe Dohme	Suspension	Acetate form insoluble; sodium phosphate form soluble	Benkalkonium chloride
Dexamethasone sodium phosphate Hydrocortisone sodium succinate	Generic only Solu-Cortef	Multiple Pharmacia and Upjohn (Pfizer)	Solution Powder for solution	Freely soluble Very soluble	Benzyl alcohol
Methylprednisolone acetate	Depo-Medrol	Pharmacia and Upjohn (Pfizer)	Suspension		Benzyl alcohol polyethylene glycol
Methylprednisolone sodium succinate	Solu-Medrol	Pharmacia and Upjohn (Pfizer)	Powder for solution	Soluble	+/- Benzyl alcohol
Triamcinolone acetonide	Kenalog-10 Kenalog-40	Bristol Myers Squibb	Suspension		Benzyl alcohol
Triamcinolone Hexacetonide	Aristospan	Sandoz	Suspension		Benzyl alcohol

lumbar TF injections (4.6%), followed by interlaminar injections at all levels (0.25% to 0.33%).<sup>35</sup> Because nerve damage can be minimized or avoided altogether if a patient reports a paresthesia during needle placement and the procedure is aborted before injection of any substance within a neural structure itself, the use of deep sedation is not recommended during these procedures.<sup>10,36</sup>

*Ophthalmological* – Retinal venous hemorrhage and amblyopia were reported after ESIs in volumes over 40 mL. This complication is hypothesized to be secondary to increased spinal fluid pressure in the subarachnoid space with subsequently raised retinal venous pressure.<sup>37</sup> Transient bilateral vision defects have been reported after cervical TF application of triamcinolone 15 mg.<sup>38</sup> Central serous chorioretinopathy, with detachment of the central retina, was described in 7 cases and can arise secondarily to fluid retention due to epidural corticosteroids, with a normal healing process requiring weeks to months. All these complications are only described in case reports; thus, the incidence is not known.<sup>10</sup>

*Neurovascular* – Epidural hematoma and ischemia are examples of potential vascular complications. Most of the major complications are neurological and are described further in this article.

**Incidence of Major Complications.** A department of the FDA, the Division of Pharmacovigilance II, evaluated serious neurological complications after the epidural use of corticosteroids via the FDA Adverse Event Reporting System (FAERS) database. A search was conducted from January 1, 1965, to April 23, 2014, for

cases of arachnoiditis, and from November 1, 1997, to April 23, 2014, for cases of serious nervous system disorders. This yielded a total of 131 cases (including 18 published case reports), which included 41 cases of arachnoiditis and 90 serious cases of nervous system disorders.<sup>1</sup> Cases of fungal infections due to contamination of the compounded corticosteroid were not included.

The exact incidence of these major complications cannot be estimated due to a number of factors:

- Underreporting of complications in the literature.
- The total number of epidural injections per year is unknown. However, we do know that 1.3 million epidural injections were given to patients 65 years of age and older in the United States in 2013.<sup>1</sup> IMS Health data show that approximately 604,000 additional patients under 65 years of age received an epidural corticoid injection in 2013.<sup>2</sup> It is estimated that the total number of ESIs performed annually in the United States amounts to 9 million.<sup>10</sup>
- The low incidence, such that this could never be reported in retrospective, prospective, or cohort studies, but only in case reports or in “closed claims.” A retrospective study involved 4,265 epidural injections (interlaminar, TF, and caudal) performed on 1,857 patients over a period of 7 years.<sup>39</sup> Not a single major complication could be identified. The number of minor complications was less after a TF injection (2.1%) than after an interlaminar injection (6.0%). Various cohort studies involving a total of over 16,000 consecutive ESIs at all levels also failed to show any major complications.<sup>40–42</sup>

In summary, the exact incidence of complications associated with epidural steroid injections can currently not be determined, since this requires an extensive population screening,<sup>2</sup> but it is estimated that around 9 million epidural injections are performed annually in the United States alone. The large number of epidural injections relative to the number of reports of major complications justifies the assumption that these are rare.<sup>1,2,39</sup>

**Neurological Complications and Region. Cervical** – The interlaminar route is predominantly related to spinal cord injury secondary to needle trauma,<sup>34,43</sup> while several case reports describe vascular injury after a cervical TF approach.<sup>34,44–55</sup>

**Thoracic** – The literature on complications in this region is scarcer,<sup>56,57</sup> but procedures in this region are less frequent, which could explain the lower incidence.

**Lumbar** – At least 18 cases could be found in the literature, of which 4 cases had an unclear etiology: possibly secondary to tumor tissue, hematoma, or damage to the radicular medullary artery (from the aorta via arteria lumbalis to arteria spinalis).<sup>58–61</sup>

Paraplegia after TF injection was reported in 14 cases.<sup>62–68</sup> The most frequent nerve root level that led to complications was L3 (5 cases), followed by L5 (3 cases), L1 and L2 (each 2 cases), and L4 and S1 (each 1 case).

To conclude, complications are most likely to occur with the interlaminar technique at the cervical level from direct trauma to the spinal cord and with the TF technique from a neurovascular complication (cervical and thoracic more often than lumbar) with a possibility of an infarction of the spinal cord, the brain stem, the cerebrum, or the cerebellum.<sup>36</sup> There are multiple hypotheses for this observed damage to the central nervous system with the TF technique:

1. Direct damage to the arterial supply of the spinal cord.<sup>54</sup>
2. Neurotoxic effect of the injected corticosteroid and/or preservatives/solvents (“carriers”). The concentrations of the solvent in the commercially available preparation makes toxicity unlikely to occur.<sup>69,70</sup>
3. Embolization resulting in ischemia after injection of a corticosteroid suspension.<sup>48,53</sup>

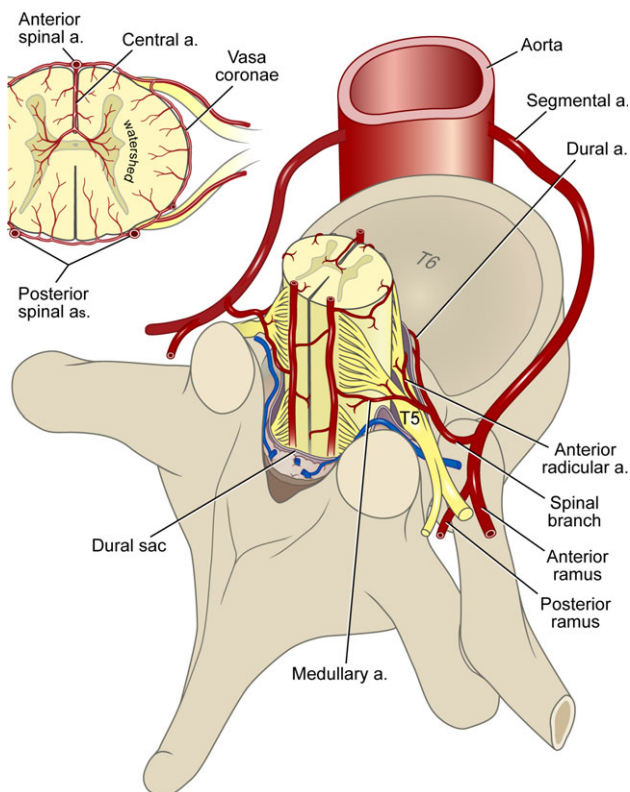
Although nerve injury due to direct needle trauma comprises a clear share of the described complications,<sup>33,34</sup> the literature in the past decade has largely focused on the described complications of accidental intravascular injection of particulate corticosteroids. The literature often differentiates between particulate corticosteroids (as these mixtures contain particles that are larger than red blood cells) and nonparticulate corticosteroids (if they contain no particles). That is why the same terminology will be used in this text. The FDA does not use this terminology; instead, it differentiates between 2 chemical categories based on solubility: specifically, solutions and suspensions. This does not necessarily coincide with the physical arrangement of particulate and nonparticulate corticosteroids, but it is largely comparable.

Data from Medicare and IMS Health up to and including 2013 show that particulate corticosteroids make up over 80% of the commercially available products.<sup>2</sup> However, there are also at least 3 cases with serious neurological complications involving dexamethasone (1 at the cervical and 2 at the lumbar level),<sup>1</sup> but it is unclear whether this was in the particulate or nonparticulate form.

**Vascularization.** The vascularization of the spinal cord (Figure 1) usually originates from the aorta via the radicular artery, arising bilaterally at the level of each vertebra. The radicular arteries run adjacent to the segmental spinal nerve in the neuroforamen and provide vascularization of the nerve, where they also usually end. However, when these branches continue to the spinal artery, they are referred to as spinal medullary arteries (anterior or posterior).

The posterior one-third of the spinal cord is vascularized by 2 posterior spinal arteries. The latter are relatively small and run posterolaterally along the spinal cord. They receive their blood supply from the posterior spinal medullary arteries.

Thus, the greatest vascularization of the spinal cord (anterior two-thirds) runs through the anterior spinal artery. This receives cranial arterial blood via branches of the vertebral artery, at the cervical level by an average of 3 radicular medullary arteries and below thoracic level 8, in the majority of cases by 1 single large artery: the artery of Adamkiewicz (Figure 2). The spinal medullary artery typically (92% of individuals) runs anterosuperior to the nerve root<sup>71</sup> with an average intraforaminal diameter of 1.20 mm (0.84 to 1.91 mm).

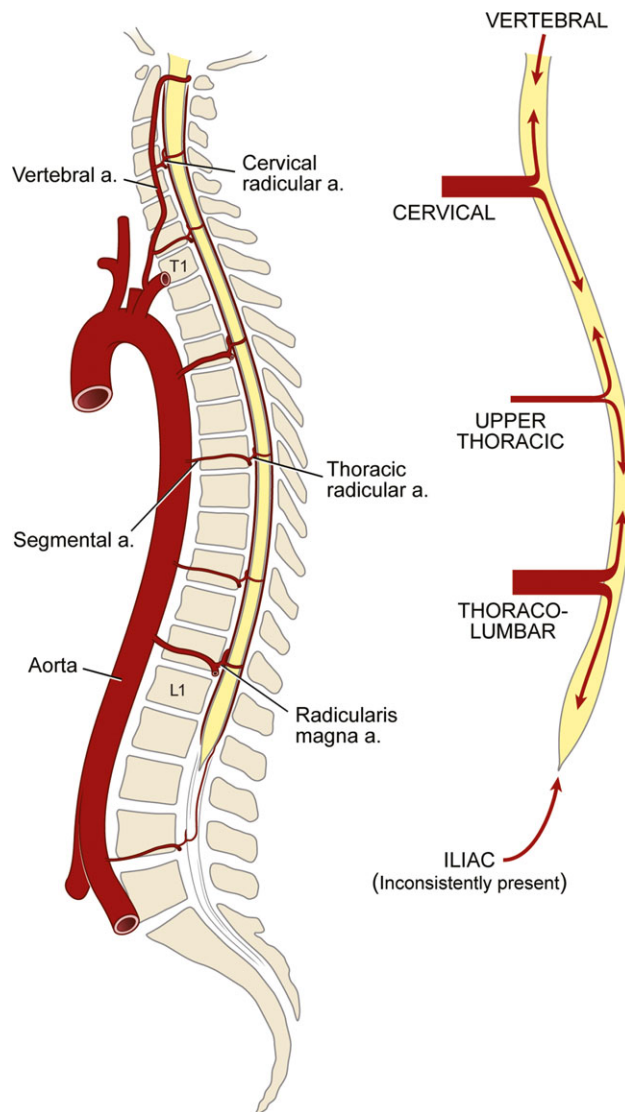


**Figure 1.** Spinal cord arterial supply. Reproduced with permission from Neal and Rathmell.<sup>229</sup>

This artery is the main blood supply to the conus medullaris, but the course is unpredictable. Anatomic studies have shown that the artery of Adamkiewicz arises, in 75% of cases, from the left posterior intercostal artery between T9 and T12 and in 10% of cases from the lumbar arteries between L1 and L2. A cadaver study showed the artery of Adamkiewicz between T12 and L3 in 83.9% of the cases. The variability of the artery of Adamkiewicz was studied based on 4,000 spinal angiograms, which showed that it arises at the level of L2 in 1% of cases and at the level of L4 in 0.075%.

Directly injecting corticosteroid into the anterior spinal artery or the artery of Adamkiewicz and the resultant embolism may lead to an infarction of the spinal cord. On the other hand, material that is injected into the abdominal aorta below the level of the artery of Adamkiewicz may reach the conus via the collaterals.

Normal vascularization can be disrupted by prior surgery with an increased risk for vascular injury due to direct damage of the arterial wall. The innermost blood vessel wall is lined with the tunica intima, which consists of endothelial cells and subendothelial layers of loose connective tissue. Direct needle trauma can lead to the



**Figure 2.** Blood supply of the spinal cord via the arteria vertebralis and radicular medullary arteries. From website anesthesia key: <https://aneskey.com/local-anesthetic-neurotoxicity-and-cauda-equina-syndrome/>.

development of an intimal flap that can cause arterial obstruction.<sup>56</sup>

### Other Complications.

1. Infection due to contamination.<sup>72,73</sup> Several reports of fungal infection after epidural corticosteroid administration have been published. These cases occurred in the United States due to contamination of methylprednisolone acetate with the *Exserohilum rostratum* fungus. The product was produced in 1 compounding pharmacy and did not contain preservatives. The

epidural use of this specific preparation led to 753 infections and hundreds of cases of meningitis, at least 24 of which are known to have resulted in death.<sup>74</sup>

2. Two cases of meningitis were possibly attributed to the activation of latent infections by immunosuppression of corticosteroids.<sup>37</sup>
3. Arachnoiditis. Both epidural and caudal approaches were associated with a limited number of cases of arachnoiditis.<sup>75,76</sup>
4. Subdural injection.<sup>22</sup> The subdural space is larger in the cervical region, increasing the risk for subdural injection. It is important to differentiate between the signs of subdural and intrathecal block. Respiratory depression occurs slowly (5 to 30 minutes) with subdural injection; upon direct intrathecal (subarachnoid) injection, apnea and acute cardiovascular collapse occur rapidly (2 to 3 minutes).

In summary, there appear to be more major neurological complications associated with procedures carried out at the cervical compared to the lumbar region. This is likely due to the proximity of a greater number of vascular structures and the spinal cord itself, which may be punctured during procedures adjacent to the cervical spine. Considering this complexity, thorough training of the pain specialist and use of image guidance is mandatory before proceeding with cervical procedures. There is little information on the thoracic region.

**Conclusions of the Work Group.** Considering the possible complications, cervical procedures are reserved for pain specialists with a special competence in interventional pain therapy.

#### Is There a Link Between Corticosteroids and/or Additives and Neurological Complications?

**Pharmacokinetics of Corticosteroids<sup>1</sup>.** *Chemical classification of corticosteroids* – Corticosteroids are synthetic derivatives of the endogenous hormones from the adrenal cortex (eg, cortisol, or hydrocortisone in medicinal form), with several gradations of water solubility. In general, synthetic corticosteroids are lipophilic and are supplied as suspensions (eg, triamcinolone acetate, triamcinolone hexacetonide, methylprednisolone acetate [MPA], betamethasone acetate). If corticosteroids are used in the form of a salt structure (eg, betamethasone sodium phosphate, dexamethasone sodium phosphate, methylprednisolone sodium

succinate), they are soluble in water and are supplied as a solution.

Triamcinolone acetate and MPA tend to precipitate in larger aggregates, but dexamethasone usually does not contain particles (although they may be present). Betamethasone is a different case altogether, because the FDA-approved form has both a soluble (saline) and nonsoluble (ester) component. Depending on the formulation used, the microscopic analysis of the particle size differs (Table 2).

It is assumed that the specific formulation of corticosteroids can help determine the clinical effect. An ester formulation, for example, first must undergo hydrolysis in order to release the active ingredient, causing a longer onset time but also a longer duration of action.<sup>77</sup>

It is also possible that additives play a role. However, there is concern about the potential neurotoxicity with regard to certain ingredients (eg, benzyl alcohol and polyethylene glycol [PEG]; see later subsection on Animal Experimental Data).

Methylprednisolone sodium succinate (Solu-Medrol<sup>®</sup>) is easily soluble; however, MPA (Depo-Medrol<sup>®</sup>) is slowly released in a biological matrix and becomes slowly biologically available. MPA is hydrolyzed into its active form by serum cholinesterase.<sup>78</sup> In humans, methylprednisolone demonstrates a weak bond (40% to 90% bound) with albumin and transcortin. The intracellular activity of glucocorticoids results in a clear difference between the plasma half-life (2 to 5 hours) and the pharmacological half-life (12 to over 36 hours). The pharmacological activity continues after measurable plasma levels have ceased to be present.<sup>79</sup>

*Dilution and size aggregations* – The particles in corticosteroid suspensions have different sizes and degrees of aggregation. Methylprednisolone has the largest particles, triamcinolone is average, and betamethasone has the smallest particles.<sup>48,80,81</sup>

Corticosteroids are frequently diluted to reduce the concentration of benzyl alcohol and PEG prior to the epidural injection.<sup>82,83</sup> The size of particles/aggregates can also depend upon the dilution agent. For example, the dilution of methylprednisolone 80 mg/mL with 0.9% NaCl shows an increase in the proportion of larger particles, contrary to dilution with lidocaine of compounded betamethasone, which causes the proportion of larger particles to decrease. Dilution with 0.9% NaCl or lidocaine had no effect on the distribution of particles in methylprednisolone 40 mg/mL, triamcinolone, or commercial betamethasone.<sup>81</sup>

*Penetration in the cerebrospinal fluid (CSF)* – The penetration of corticosteroids into the CSF depends on the degree of plasma protein binding and chemical composition. Animal experiments<sup>84</sup> as well as clinical studies have shown that IV or oral prednisolone can pass through the blood–brain barrier, with increased values in the CSF 6 hours after administration.<sup>85</sup> The penetration in the CSF was limited in animal studies by the degree of protein binding in plasma, whereby a higher free fraction (ie, not protein bound) of the corticosteroid leads to higher CSF concentrations. For example, after oral administration of dexamethasone or prednisolone in children, higher dexamethasone concentrations are reached in the CSF, as the dexamethasone is relatively less protein bound than prednisolone<sup>84</sup> after oral administration.

Methylprednisolone succinate (Solu-Medrol®) administered systemically leads to very low levels in the CSF.<sup>86,87</sup> It is suspected that the poor biological availability of methylprednisolone is due to an active exclusion by P-glycoprotein.<sup>86,88</sup>

*Neurotoxicity in Function of Route of Administration.* Toxicity can arise because of a chemical reaction of corticosteroid preparations in tissue, or by unintentional intravascular<sup>89</sup> or intrathecal injections. Potential mechanisms leading to neurotoxicity are described in the ensuing sections.

*Chemical irritation due to particles in suspension in tissue*<sup>90</sup> – There are indications that in some tissues, such as lungs and joint prostheses, particles of suspension or nanoparticles can cause cytokine release, including, for example, macrophages and neutrophil immigration. The degree of inflammatory response is conversely proportionate to the particle size and directly proportionate to the surface area. In suspensions containing MPA, 30% to 40% of the particles have a diameter greater than 20 µm, while in addition the number of large particles increases due to aggregation upon dilution. In prosthetic joints, the critical size of particles to create an inflammatory response is between 0.2 and 10 µm. This implies that most corticosteroid particles are too large to cause serious inflammation, but it is possible that this mechanism is nonetheless partially responsible for inflammatory response upon intrathecal administration. Such a response was not observed at the intrathecal administration of nonparticulate methylprednisolone succinate.

*Intra-arterial* – There are various arteries that supply blood to the spinal cord, as described earlier. Upon unintentional intravascular injection with corticosteroids,

relatively high corticosteroid concentrations occur in the spinal cord. Accidental intra-arterial injection of particulate corticosteroids can cause clusters or aggregates of the corticosteroid<sup>81</sup> and remotely create an embolus. At the cervical level, they can thus cause a stroke or spinal cord infarction; at lumbar levels, infarction of the conus medullaris can result in paraparesis or paraplegia. This can result in serious and permanent limitations, disability, or death.

An animal experimental study<sup>69</sup> showed that intra-arterial injection of the carotis interna can cause significant brain damage, not only with suspension MPA (particulate), but also with solution methylprednisolone sodium succinate (nonparticulate corticosteroid) solution as well as the solution fluid of MPA suspension. The latter was not further specified. The lesions studied were mainly hemorrhagic. A study with Evans blue dye could demonstrate a disruption of the blood–brain barrier. This animal experimental study suggests that corticosteroid solutions can cause damage to the central nervous system not only by means of an embolic process, but also that the preparation itself and the solution fluid can have a neurotoxic effect. An additional animal experimental study showed edema on MRI in the upper part of the spinal cord and the brain stem after the injection of MPA in the carotid arteries of 4 pigs. Injection of dexamethasone ( $n = 4$ ) and methylprednisolone sodium succinate ( $n = 3$ ) (nonparticulate forms) showed no deviations on MRI.<sup>91</sup> Therefore, the possible toxic effect of methylprednisolone could not be confirmed.

*Intrathecal – Clinical.* The intrathecal use of corticosteroids (such as triamcinolone, MPA) has been described for 19 different conditions, such as contrast-induced arachnoiditis after myelography, spasticity in progressive multiple sclerosis, Guillain-Barré syndrome, failed back surgery syndrome, post-herpetic neuralgia, amyotrophic lateral sclerosis, complex regional pain syndrome, and trigeminal neuralgia.<sup>87,90,92,93</sup> Because of reports of serious complications, particularly after repeated intrathecal injections, such as cerebral hemorrhage, meningitis, cauda equina syndrome, progressive muscle weakness, bladder dysfunction, and paresthesias,<sup>37,94</sup> this treatment is no longer used.

*Animal experimental data* – Animal experimental safety studies with intrathecal corticosteroids report neurotoxicity.<sup>95–97</sup> The observed neurotoxicity could also be caused by the neurotoxic preservatives in the corticosteroid preparations used.

In a canine study, MPA was administered after removing practically all the neurotoxic preservative



myristyl-gamma-picolinium chloride. Dose-dependent neurotoxicity was nonetheless observed.<sup>95</sup>

It remains unclear if the preservatives in corticosteroid preparations are responsible for the observed neurotoxicity in humans and animals, but there are indications that the particles of the corticosteroid suspension and/or the corticosteroid itself may play a role in the development of neurotoxicity. The role of additives and preservatives therefore requires further investigation. This subject had already been extensively studied and described by Bogduk in 1994.<sup>32</sup>

- Buffers: eg, phosphate buffer; no side effects described after intrathecal or epidural administration.
- Polysorbates: no side effects described after intrathecal injection.
- Citrate: can induce convulsions in mice after spinal injection.
- Ethylene diamine tetra-acetic acid (EDTA): can induce convulsions in mice after spinal injection.
- Sodium sulphite: irreversible paralysis in rabbits after subarachnoid administration.
- Benzalkonium chloride: bacteriostatic preservative. Celestone chronodose contains benzylalkonium chloride and can cause arachnoid fibrosis after intrathecal injection of over 2 mL in sheep<sup>32</sup> and is potentially toxic.<sup>37</sup>
- Phenol: chemical meningitis has been reported and can cause convulsions.

Creatinine: Is used as a bulking agent for freeze-drying. No toxicity reported, but rather a neuroprotective effect.<sup>98</sup>

- Polyethylene glycol (PEG): preservative and increases viscosity with improvement of the stability of formulation PEG 3% (sometimes added to methylprednisolone). No inference with neural function 30 minutes after application at the vagal nerve of rabbits. PEG >20% can reversibly reduce the compound action potentials of the A, B, and C fibers.<sup>83</sup> Although there are concerns about the neurotoxicity of PEG,<sup>37</sup> PEG is directly applied to the myelum in spinal cord injury models to promote recovery and functional-structural integrity of nerve tissue. It is also clinically used for dura-recovery, whereby no neurotoxicity or inflammatory responses were determined. There is therefore also no proof of direct neurotoxicity with the intrathecal use of PEG.<sup>90</sup>

- Benzyl alcohol: preservative effective against Gram-positive bacteria, and Gram-negative *Serratia marcescens* (sometimes present in epidural abscesses).<sup>37</sup> After the intrathecal injection of benzyl alcohol solutions, the following have been reported:
  - “flaccid paraplegia” and demyelization with 5 mL benzyl alcohol solution
  - nerve degeneration and paraplegia after 20 mL methotrexate injection intrathecally with 0.9% benzyl alcohol
  - “flaccid paralysis”
  - leg paralysis
  - transient neurological problems after the epidural injection of 40 mL 0.9% NaCl with 1.5% benzyl alcohol. This resulted in flaccid paraplegia that continued for 16 months.<sup>99</sup> In some countries, methylprednisolone contains 3% PEG and 0.9% benzyl alcohol.
- Hydroxybenzoates
  - neurological damage, paraplegia
  - neuronal block (paraparesis)
  - neurotoxicity, paraparesis
  - leg paralysis
- Myristyl gamma picolinium chloride: used to promote the solubility of MPA. Retains the stability of particulate size and reduces aggregation and is a preservative that is effective against Gram-positive bacteria.
  - A safety study in dogs, whereby the neurotoxic preservative gamma-picolinium chloride was virtually entirely removed from the MPA preparation,<sup>95</sup> showed dose-dependent neurotoxicity. These finding sheds doubt over the toxicity of the preservative.
  - A study into the toxicity of MPA on dorsal root ganglion neurons in rats showed that MPA has cytotoxic effects. MPA with preservatives (PEG and Myristyl gamma picolinium chloride) results in more apoptosis than MPA with reduced preservatives. MPA with reduced preservatives results in 12.5% more apoptosis of neurons than in the control group (normal saline); however, this difference is not significant.<sup>70</sup>

Most studies on toxicity used corticosteroids with preservatives, making it unclear as to specifically indicate which ingredient caused the neurotoxicity.

**Epidural Use.** When MPA or triamcinolone is injected into the epidural space, the risk for complications is small.<sup>32,100</sup> The above-mentioned additives, such as preservatives like alcohol or phenol, or substances that change solubility such as glycols, were added to these products, substances that might indeed be toxic if administered into the epidural space.

The work group under Bogduk in 1994 decided that there is no evidence of negative effects of corticosteroid compounds if they are accurately injected into the epidural space. It is unclear whether a single intrathecal injection represents a risk for significant injury. The reported cases of arachnoiditis occurred after repeated intrathecal injections, and in most cases in the presence of pre-existing neurological complaints. Arachnoiditis and aseptic meningitis are complications of intrathecally, and not epidurally, administered corticosteroids.<sup>21</sup>

**Conclusion. Neurotoxicity and type of particulate corticosteroids** – The study of the toxicity of particulate corticosteroids is complicated by the variety in the composition of the same product from a single manufacturer (eg, MPA from Europe vs. MPA from the United States, a different composition over the course of time), manufacturing locations (official companies or industrial pharmacies), and the presence or absence of preservatives or solvents. The toxicity also depends on the administration site (epidural, arterial, intrathecal). Because the composition is usually not specified when reporting complications, it is very difficult to determine a causal link between the product and a rare complication from the literature. The analysis of the FDA FAERS of serious neurological complications showed that MPA was involved in 39 of 90 (43%) of the cases, and that triamcinolone acetate with its smaller particles was involved in 31 of 90 (34%) of the cases. There are also 3 known cases in which dexamethasone was involved with serious neurological complications.<sup>1</sup>

The neurotoxicity of particulate corticosteroids seems less important when they are injected into the epidural space, but the composition of the suspension may play a role in accidental intrathecal or intravascular injection. Animal experimental data show that an intrathecal or intravascular injection can cause complications induced by both the corticosteroid as well as the preservatives and/or solvents.

Currently it is not possible to differentiate between the particulate corticosteroids/suspensions for a better safety profile.

**Neurotoxicity and additives** – The administration of corticosteroids with as little preservative or solvent as possible is prompted by fear of intrathecal (with arachnoiditis) or intravascular injection (neurotoxicity). The studies of the FDA established 41 cases of arachnoiditis during a period of almost 50 years (search strategy between January 1, 1965, and April 23, 2014), usually after repeated intrathecal injections, and in most cases in the presence of previously existing neurological complaints. This is not related to the 24 deaths after injection of fungal-contaminated corticosteroid without preservatives. It is unclear as to what degree the avoidance of preservatives or solvents can prevent complications after intravascular injection.

#### **Conclusions of the Work Group.**

- The chance for neurotoxicity is small when glucocorticoids are correctly administered into the epidural space.
- It is unclear whether the omission of preservatives and solvents for the prevention of arachnoiditis or vascular complications outweighs the infection risk in case of accidental contamination.
- There are currently no indications that any one type of particulate corticosteroid is safer than any other.

#### **What Is the Place of Dexamethasone?**

Dexamethasone is a solution and therefore a potential alternative to the epidural injection of particulate steroids. This section describes the effectiveness and safety/toxicity of this compound.

**Pharmacokinetics.**<sup>79</sup> Dexamethasone is a synthetic glucocorticoid, with a strong anti-inflammatory effect approximately 25 times greater than hydrocortisone and 7 times greater than prednisolone. Dexamethasone has predominantly glucocorticoid activity and only a very slight effect on sodium and water retention.

After administration of dexamethasone sodium phosphate, it is rapidly hydrolyzed to dexamethasone, which is 68% bound to plasma proteins.

After local administration, some absorption into the systemic circulation is likely. The plasma half-life is 200 minutes for males and 140 minutes for females. The biological half-life is 35 to 54 hours. There is no direct link between the plasma concentration and the therapeutic effect, because a glucocorticoid effect is only expressed after protein synthesis (including of enzymes) in sensitive tissue.

Dexamethasone has particles that are either absent or 5 to 10 times smaller than red blood cells ( $\leq 0.5 \mu\text{m}$ ) and does not form aggregates, not even upon dilution with lidocaine 1% or contrast.<sup>48,80</sup> Dexamethasone and betamethasone sodium phosphate are therefore considered pure liquids,<sup>81</sup> although small particles are also found in these preparations.<sup>48</sup>

However, a recent publication demonstrated that the combination of dexamethasone 1 mL (both 4 mg/mL and 10 mg/mL concentrations) with 1 mL ropivacaine 0.75% results in almost instantaneous formation of crystals large enough to act as emboli. Ropivacaine therefore seems not suitable for the dilution of dexamethasone.<sup>101</sup>

**Safety/Neurotoxicity.** In August 2015, we performed a search over the preceding 5 years using the abstract words “dexamethasone” AND “epidural” or “intrathecal” and found 376 publications; all abstracts were screened to establish an inventory of reported side effects and complications.

**Basic research – Intramuscular.** The intramuscular administration of dexamethasone in a spinal cord compression model resulted in a more rapid neurologic recovery than in control animals.<sup>102</sup>

**Perineural.** The perineural administration of triamcinolone hexacetonide, triamcinolone diacetate, or dexamethasone considerably reduced the spontaneous ectopic discharges that arise in experimental nerve end neuromas. They prevent the further development of ectopic impulses in freshly severed nerves.<sup>103</sup> The survival of sensory neurons of the spinal ganglion was studied *ex vivo* in a study during which they were exposed to ropivacaine and additives, including dexamethasone, for 2 or 24 hours. After 2-hour exposure, the association of dexamethasone did not increase the toxicity of ropivacaine. After 24-hour exposure, the toxicity of ropivacaine proved far greater than that of additives, including dexamethasone. However, the combination of a higher concentration of dexamethasone, along with equal doses of ropivacaine, clonidine,

and buprenorphine, did increase toxicity (no toxicity at 66  $\mu\text{g/mL}$  dexamethasone; toxicity at 133  $\mu\text{g/mL}$ ). The authors therefore decided that the concentration effect of dexamethasone with ropivacaine requires further study.<sup>104</sup> The same group then did an *in vivo* study through a single injection or a continuous infusion at the sciatic nerve of rats with the combination of dexamethasone 66  $\mu\text{g/mL}$  with bupivacaine and clonidine. No behavioral changes were observed, nor any histopathological changes at the sciatic nerve, spinal ganglion, or dorsal/ventral roots. It was concluded that these mixtures and concentrations could be safely used on the sciatic nerve of rats.<sup>105</sup>

**Intra-arterial.** Animal experimental studies showed no neurological complications upon injection of 4 to 10 mg dexamethasone in the vertebral artery of pigs,<sup>91</sup> in contrast to particulate corticosteroids.

**Epidural.** In a formalin pain model, epidural dexamethasone reduced hyperalgesia via an inhibition of intraspinal phospholipase A<sub>2</sub> expression via lamina I to II in the dorsal horn.<sup>106</sup> A dexamethasone gelatine sponge applied after laminectomy in rats significantly reduced the occurrence of adhesions and epidural scar tissue hyperplasia.<sup>107</sup>

**Intrathecal.** Intrathecally administered dexamethasone weakens glutamate dehydrogenase and glutamate downregulation, as well as antinociceptive tolerance in rats in the long term.<sup>108</sup> Subdural administration during 1 week of dexamethasone in a rat model of spinal cord injury resulted in the inhibition of a serious inflammatory response to the damaged myelin.<sup>109</sup> In another study,<sup>110</sup> intrathecally administered dexamethasone worsened thermal hyperalgesia and mechanical allodynia in rats with a chronic constriction injury. The intrathecal administration of a glucocorticoid receptor antagonist reversed the nociceptive behavior.<sup>110,111</sup> The intrathecal administration of nonparticulate corticosteroids in animal experiments resulted in convulsions.<sup>112–114</sup> In continuous intrathecal administration, a low dose of dexamethasone resulted in no neuropathology in rats ( $\leq 12.5 \text{ ng/hour}$ ), but a higher dose (125 ng/hour) did result in inflammation of the lumbar subarachnoid space.<sup>115</sup>

**Conclusion.** *Dexamethasone toxicity –*

- Perineural injection resulted in increased toxicity when ropivacaine, clonidine, and buprenorphine are used together with a high concentration of dexamethasone (133  $\mu\text{g/mL}$ ).

- Intrathecal administration of higher doses of dexamethasone (125 ng/hour) resulted in inflammation.
- There is no evidence for toxicity upon intra-arterial or epidural administration. Upon epidural administration, inflammation is countered.

*Clinical studies – Intrathecal.* Glucocorticoids such as dexamethasone are administered intrathecally to prolong the duration of sensory block in spinal anesthesia and anecdotally for the treatment of various syndromes like radicular pain, bacterial meningitis, chronic lymphocytic leukemia, and nervous involvement in lupus erythematosus.<sup>115,116</sup>

*Epidural.* The epidural use of dexamethasone is described for the prevention of back pain after epidural anesthesia,<sup>117,118</sup> and for perioperative analgesia during orchiopexy<sup>118</sup> or after cholecystectomy.<sup>119</sup>

In a monocentric study conducted on 150 patients, the side effects of dexamethasone (AAP Pharmaceuticals, 10 mg/mL) were prospectively recorded for a 14-day period after injection of 15 mg cervically or 20 mg lumbosacrally in the epidural space. This showed that in 19.5% of the cases, side effects were experienced during the first 30 minutes (numbness and tingling in the limbs in 11.95%, sometimes followed by perineal pruritus in 4.4% of the cases). Within 3 days, headaches, insomnia, hiccups, flushing, and increased radicular pain were also reported. No major complications were registered.<sup>120</sup> In 28%, flushing was observed after interlaminar epidural administration of 16 mg dexamethasone in a retrospective study. These symptoms mainly occurred in females, but disappeared within 48 hours.<sup>121</sup> The epidural administration of 15 mg dexamethasone resulted in a significant drop in serum cortisol and adrenocorticotropic hormone, and of urine cortisol between 2 and 7 days after injection. This normalized after 21 days.<sup>122</sup>

The FDA received 3 reports of nonfatal serious neurological adverse events following the epidural use of dexamethasone. In all cases a new pain in the extremities was reported, but final neurological outcome is unknown.<sup>1</sup>

**Conclusion. Safety** – Animal experimental data show that at higher concentrations of dexamethasone, neurotoxicity is present after perineural or intrathecal injection. The possibility of toxicity produced by the concurrent administration of local anesthesia does

make it difficult to interpret these data. It is therefore unclear whether the doses of dexamethasone used clinically are safe; at present, the FDA has received 3 reports of complications, and recently a conus medullaris infarction was reported after a TF injection of 6 mg of dexamethasone at the level of L4.<sup>123</sup>

In view of the low incidence of neurovascular complications after TF injections of corticosteroids and the relatively less frequent use of dexamethasone, the safety of dexamethasone remains uncertain and can only be determined by long-term epidemiological studies and clinical reporting.<sup>4</sup>

**Effectiveness. At the cervical level** – The TF administration of dexamethasone for cervicobrachialgia was investigated in 2 retrospective studies<sup>124,125</sup> and 1 randomized controlled trial (RCT).<sup>126</sup> In 2 studies, a nonsignificant trend was observed in favor of triamcinolone as particulate corticosteroid. The retrospective study of 2013 with the largest patient group ( $n = 441$ ) showed no difference in pain reduction between dexamethasone and triamcinolone.<sup>124</sup>

**At the lumbar level** – In the first studies at the lumbar level, the effectiveness of dexamethasone appeared inferior compared to particulate corticosteroids,<sup>127–129</sup> but these were of lower quality (not clearly blinded, short follow-up period, unclear methodology, underpowered, or retrospective). Until 2013, there was low-quality evidence that dexamethasone provided less pain reduction in comparison with particulate corticosteroids.<sup>126</sup> Afterwards, the equality of dexamethasone (10 mg/mL) compared to particulate corticosteroids was shown in 1 retrospective study (10 mg)<sup>130</sup> and 2 RCTs (7.5 and 15 mg).<sup>131,132</sup>

**Conclusion. Effectiveness** – Until 2013, there was evidence that dexamethasone conferred less pain reduction in comparison to particulate corticosteroids for cervicobrachialgia and lumbosacral radicular syndrome; the 2 largest randomized studies also found greater effectiveness of particulate corticosteroids.<sup>129,133</sup>

Since then, some studies have indeed been published that showed an equal effect. However, the latter have insufficient power and there is currently no direct evidence that dexamethasone is superior to sham injections.<sup>3</sup> In this conclusion, however, no consideration was taken of the latest publication<sup>132</sup> with 29 and 27

patients, respectively, in each group (dexamethasone vs. betamethasone).

**Considerations of the Work Group. The place for dexamethasone** – The work group believes that there are no clear arguments for the interlaminar approach to choose dexamethasone over particulate corticosteroids, in view of the low chance for arachnoiditis or complications after accidental intravascular injection. However, in order to rule this out, contrast must indeed always be used first. The risk for intra-arterial injection when steroid is applied via an interlaminar route is negligible owing to the lack of any arterial structures in normal individuals in the posterior aspect of the epidural space.

**Safety** – Clinically there are currently only 4 reports of serious neurological complications with dexamethasone, but the underlying pathophysiology thereof cannot be determined. The safety of the class of nonparticulate corticosteroids has still not been sufficiently established, because in 1 animal experimental study, injection in the carotid artery of methylprednisolone succinate or its carrier also affected the brain.<sup>69</sup> The injection of dexamethasone without preservative did not cause any brain damage, one reason why this formulation is preferred in practice.

However, the majority of deaths secondary to epidural steroid injections are due to a single contamination of preservative-free corticosteroids. The work group therefore balances the risk for accidental contamination in preservative-free dexamethasone on the one hand, and the risk for an accidental intravascular injection with neurological complications on the other.

Moreover, in Belgium and the Netherlands the availability of preservative-free dexamethasone has not been guaranteed up till now and is only available from 1 compounding pharmacy, making it not feasible to make its use obligatory as a first-line treatment. This is in sharp contrast with clinical practice in the United States and explains the difference in final recommendations between the U.S. and Benelux guidelines.

It is therefore felt that below the level of L3 the vascular risk is smaller, and that particulate steroids still have a place.

Because the relative safety and effectiveness of nonparticulate corticosteroids remains an open question, the FDA does not make an exception for solutions/nonparticulate corticosteroids in the warning of the package leaflet of glucocorticoids.<sup>2</sup>

**Effectiveness** – The effectiveness of dexamethasone in comparison to sham injections has not yet been demonstrated, and the equality with particulate corticosteroids was established in studies with insufficient power.

In summary, there is less chance for neurological complications as a result of accidental intra-arterial or intrathecal injection with dexamethasone (on the basis of 1 animal experimental study and only 4 documented serious neurological complications with dexamethasone). Due to insufficient clarity about the equivalency of dexamethasone and safety in the long term, it is not mandatory to use dexamethasone. However, the use of particulate corticosteroids is not advisable for patients with a contrast allergy, and in this situation dexamethasone is the first choice.

#### **Conclusions of the Work Group.**

- Both particulate corticosteroids and dexamethasone can be used for lumbar TF injections at level L3 or lower. Concerning dexamethasone, there are still insufficient data concerning equivalence and long-term safety that this cannot be made obligatory at present.
- There are currently no arguments for switching to dexamethasone for interlaminar epidural injection.
- In the presence of a contrast allergy or above L3, dexamethasone should be used transforaminally.
- In patients with an allergy for the contrast medium or for corticosteroids, the injection of a local anesthetic alone can be considered. There is also evidence for the use of pulsed radiofrequency treatment adjacent to the ganglion spinale (dorsal root ganglion).

**Effectiveness of Epidural Corticoids.** In order to draw up the risk/benefit balance of epidural corticosteroids, the effectiveness of this technique must be reviewed separately. There are more than 45 RCTs available that study the effectiveness of epidural corticosteroids for spine-related pain, of which 30 are placebo controlled.<sup>21,134,135</sup> Despite this extensive research, this subject continues to be surrounded by much controversy.

**Cervical** – Four reviews on cervical epidural corticosteroids conclude that these are effective in the short term. Two of these reviews concluded that the intervention is effective in the long-term<sup>135–137</sup> and 2 others found insufficient evidence for effectiveness in the long term.<sup>137–139</sup>

**Lumbar** – There are various systematic reviews and meta-analyses that have studied the effect of epidural

corticosteroids on spinal pain. The analyses of effectiveness, however, were mixed.<sup>140–143</sup> Although there is still substantive criticism,<sup>144</sup> the latest reviews usually point in the same direction: there is proof of moderate to high quality that epidural corticosteroids have a significant but clinically limited effect on lumbosacral radicular pain in comparison with a placebo on leg pain and function during the first weeks, but this effect disappears after 3 months.<sup>10,21,135,145</sup> There are indications that surgery can be avoided in 1 study that assessed this as the primary outcome parameter<sup>146</sup> and various studies that included this as a secondary outcome parameter,<sup>147–150</sup> although the latter is inconsistent.<sup>151,152</sup>

### What Is the Place of Epidural Corticoid Injections with Respect to Subacute Lumbosacral Radicular Pain?

The initial approach to radicular pain is conservative due to the favorable natural history of this problem (spontaneous resolution of pain) or the disappearance of the complaints within 3 months in 75% of the patients.<sup>153</sup> In case of early surgical intervention (6 to 12 weeks after onset of the symptoms), at 8 weeks follow-up a significant but clinically no longer relevant improvement is achieved in comparison to a conservatively treated group.<sup>154</sup> That is why it is preferable to wait 12 weeks before performing surgery. Between 6 and 12 weeks, there may be consultation with the patient concerning the pros and cons of conservative vs. surgical intervention, knowing that the chance for spontaneous recuperation is still present and the outcome is the same after 1 year. Recovery evolves in the same way whether a patient with limited motoric drop-out undergoes surgery or not. To allow an informed decision, the potential complications of discectomy should be discussed with the patient. New or increased neurological drop-out can occur in 1% to 3%, direct nerve damage in 1% to 2%, and wound infection in 1% to 2% of the procedures.<sup>155</sup> One study reported a mortality rate of 0.6 on 1,000 procedures within 60 days after a lumbar procedure.<sup>156</sup>

A shared decision is therefore indicated after correct information is given, since surgery will only mitigate the acute pain.<sup>157,158</sup> In general, a conservative attitude is recommended in the first phase, depending on the patient's preference for rapid pain relief, aversion for the risks of surgery, and other personal preferences.<sup>159</sup>

Preferably surgery should only take place after 12 weeks, because then the chance for spontaneous recovery becomes very small. Patients will require adequate analgesia during this period, reducing the radicular irritation and facilitating rehabilitation.<sup>152</sup>

Due to the limited effects of rest, physical therapy, paracetamol (acetaminophen), nonsteroidal anti-inflammatory drugs, anti-epileptics, or antidepressants,<sup>159–161</sup> TF epidural injection with corticosteroids is frequently carried out. The risk for complications is so low that the FDA states that the exact incidence cannot be defined for this procedure, which is frequently performed worldwide. The efficacy of epidural corticosteroids is predominantly proven for the short term.

There is also the chance that this treatment can make it possible to forego surgery,<sup>146,162</sup> although there is still discussion on the subject.<sup>10,145</sup> Carrying out an epidural steroid injection is cost effective.<sup>163</sup> The decision to use epidural steroids as a stepped-up approach before opting for surgery is also cost effective<sup>164</sup> and has therefore also been included in the National Institute for Health and Care Excellence guidelines of the National Health Service 2014.<sup>165</sup>

### Which Route for Administering Epidural Corticoids?

**Cervical.** The added value of TF administration of corticosteroids is unclear for cervicobrachialgia.<sup>166,167</sup> Although there are theoretical arguments to also opt for the TF route here, the possible advantage does not outweigh the described serious neurological complications when using particulate corticosteroids.<sup>21</sup> The use of dexamethasone has rekindled the discussion on the ideal approach of epidural corticosteroids, because complications are also recorded after interlaminar injection due to a direct needle trauma.

**Lumbar.** Although not unanimous,<sup>168–170</sup> the TF route is considered superior to the caudal or interlaminar route in 5 of the 8 comparative RCTs.<sup>21</sup> Of the other studies evaluating the TF approach, 1 was underpowered and 1 indicated a trend toward better results with the TF route.<sup>21</sup>

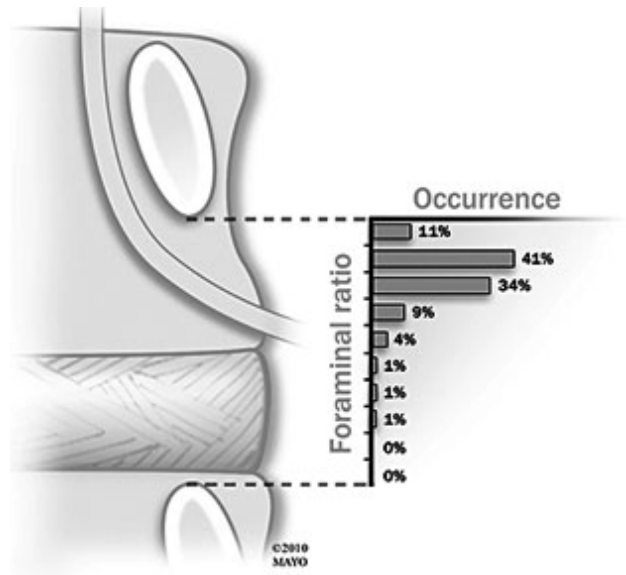
Various technical approaches are possible for the TF injection. The classic method is done via the safe triangle; in lateral view, the final point should be anterior to the neuroforamen (posterior to the vertebra or the subpedicular position), or alternatively, more posterior in the neuroforamen (the retroneural position) (Figure 3).<sup>171,172</sup> Although the final position of the needle in the cranial part of the neuroforamen can avoid accidental nerve root trauma and is therefore promoted as a standard method in textbooks, it does have the disadvantage that there is a greater chance to come across a radicular medullary artery at the

endpoint (Figure 4).<sup>71,173</sup> For the purposes of avoiding a vascular injection at level L3 or above, a more inferior and posterior approach seems more appropriate.<sup>173</sup>

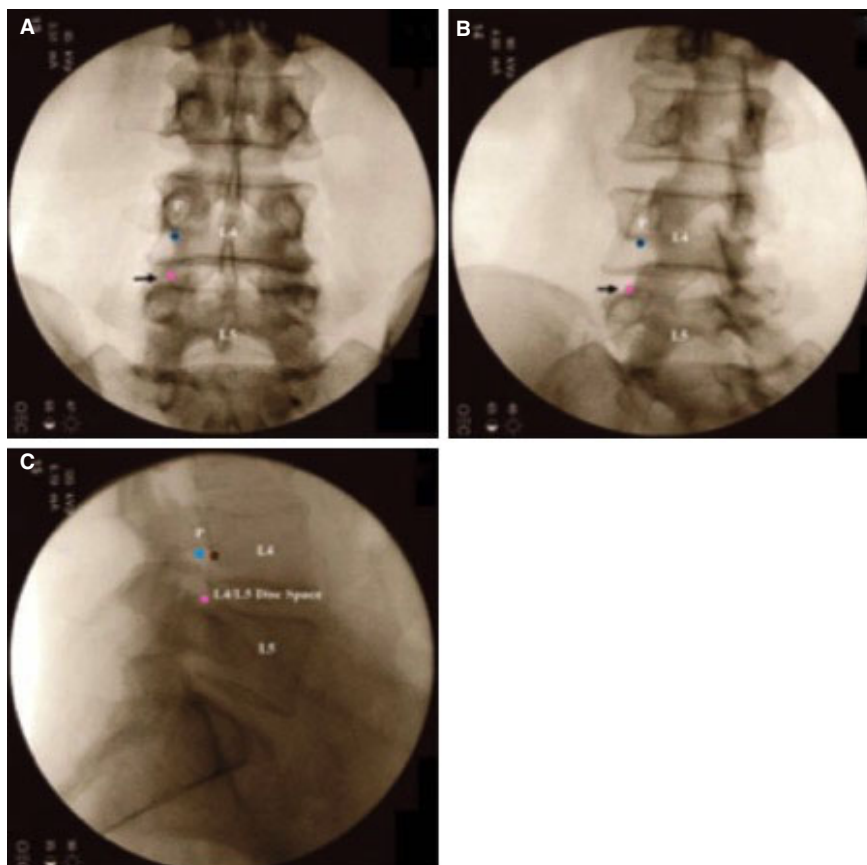
To avoid intra-arterial injection some schools recommend approaching the inferior part of the neuroforamen (especially for injections above L3), as the artery of Adamkiewicz rarely traverses this part of the foramen<sup>173</sup> The approach is therefore in accordance with the Kambin triangle<sup>174,175</sup> (Figure 5) and is also referred to as the retrodiscal technique. As the endpoint is located immediately posterior of the disc, it provides a higher chance for accidental disc punctures.<sup>176</sup> It is also unclear to which extent a correct epidural contrast flow can be achieved with this approach.

*Consideration of the Work Group. Cervical –*

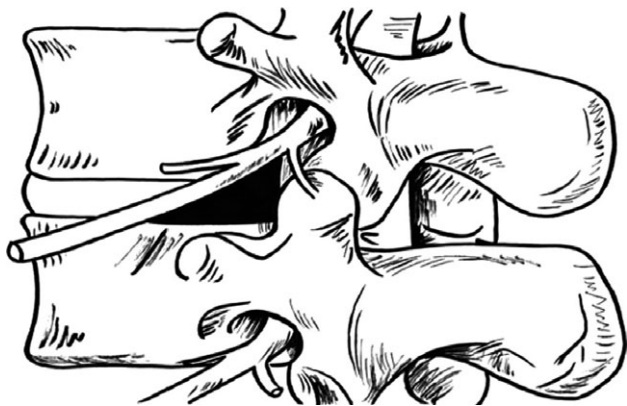
- The work group advises against the TF administration of particulate corticosteroids in light of the lack of proven added value and the potential risks.



**Figure 4.** Distribution of the intraforaminal location of radicular medullary arteries at the middle of the pedicle. In 97% of the cases the artery of Adamkiewicz is located in the upper half of the neuroforamen.<sup>6</sup>



**Figure 3.** Fluoroscopy images of a transforaminal approach of the nerve route L4 left. The blue and brown circles illustrate the approach via the safe triangle with the final point subpedicular (brown circle and posterior of vertebra) or retro neural (blue circle and in the dorso-cranial part of the neuroforamen). The pink circle illustrates the Kambin triangle technique with an approach lateral of the superior articular process (SAP) and the final point retrodiscal behind the disc of L4–5.<sup>139</sup>



**Figure 5.** The Kambin triangle, the slanted side of which is formed by the withdrawing nerve route, the basis for the underlying vertebra and the side by the processus articularis superior.<sup>146</sup>

The TF use of dexamethasone is not recommended due to the lack of added value, but it is currently suspected that dexamethasone is safer in case of an accidental intra-arterial injection. In the treatment of subacute cervicobrachialgia with interlaminar corticosteroid injections, no clear vascular complications were described with particulate corticosteroids. Therefore, particulate corticosteroids and dexamethasone can be used as of the first injection. In light of the extensive experience with particulate corticosteroids and their proven added value in comparison with control treatment, these are preferred. The corticosteroid is usually diluted. This can be done with 0.9% NaCl or lidocaine 1% to 2%.

- Alternatively, a diagnostic root block is recommended for chronic cervicobrachialgia, possibly followed by a pulsed radiofrequency treatment. In the event of a short-term or insufficient effect, a conventional radiofrequency treatment at the spinal ganglion can be considered.
- Due to the possible complications, cervical procedures are best performed by algologists with a special competence in interventional pain therapy.

**Lumbar** – At the L3 level or lower, the work group recommends the TF approach in light of the added value and the lower risk for perforating the artery of Adamkiewicz. It must be stressed that the vascularization is highly variable, with numerous spinal medullary arterial branches that can be transversing the neural foramina adjacent to the spinal nerves. The work group

still recommends the approach via the safe triangle, and for this reason with a clear preference to maintain the needle tip posterior in the neuroforamen to avoid the spinal medullary artery. If an intravascular puncture is detected, it is recommended to move the needle tip to the posterior middle of the neuroforamen as there is a smaller chance for encountering blood vessels. Some researchers propose stopping the procedure after an accidental arterial puncture as there is a risk that corticoids will still enter the arterial system after repositioning.<sup>177</sup> However, there is lack of any published literature on this subject; moreover, it is not always possible to distinguish between an arterial or venous puncture with digital subtraction angiography (DSA).<sup>178</sup>

#### *Conclusions of the Work Group. Cervical subacute cervicobrachialgia –*

- Negative recommendation for cervical TF injection of particulate corticosteroids. Although not recommended, there are currently no counterarguments for the cervical TF injection of dexamethasone.
- For interlaminar injection, no vascular complications were reported, and a particulate corticosteroid (or dexamethasone 10 mg) can be used. If required, 0.9% NaCl or lidocaine 1% to 2% can be used for dilution.

#### *Subacute lumbosacral radicular syndrome –*

- The TF approach is recommended via the safe triangle, with a clear preference to keep the needle tip placed posterior in the neuroforamen. Particulate corticosteroids must only be transforaminally injected at level L3 or lower; this limitation does not apply for dexamethasone.

#### **Which Dose (Lumbar Level)?**

Two RCTs reviewed the dose of epidural corticosteroids. In the first study, the interlaminar administration of 40 to 80 mg methylprednisolone provided the same result on pain, while the 40-mg group suffered fewer side effects.<sup>179</sup> An 80-mg dose did give patients with disc extrusion a greater chance to eventually undergo an operation.<sup>180</sup>

The second RCT did not show any difference in effectiveness between the TF administration of 10, 20,



or 40 mg triamcinolone.<sup>181</sup> The lowest dose of 5 mg did provide less pain alleviation.

An RCT looked into whether a dose effect of TF dexamethasone could be determined. There was no difference in pain or disability 3 months after treatment between the groups receiving 4, 8, or 12 mg dexamethasone.<sup>4</sup> The most effective dose in studies that showed a similarity between dexamethasone and the particulate corticosteroids varied between 7.5 and 15 mg.<sup>130–132</sup> These studies all used a concentration of 10 mg/mL, after first having injected a local anesthetic. A prospective study on the side effects of dexamethasone with 150 patients was performed also using 10 mg (10 mg/mL concentration).<sup>120</sup>

**Considerations of the Work Group.** In view of the possible physiological side effects, the lack of superiority of higher doses, and animal experimental data that indicated a higher chance for neurotoxicity in the event of accidental intrathecal injection with higher doses, the work group recommends using the lowest effective dose of the corticosteroid. Reducing the corticosteroid can increase the safety of ESI without fully compromising the pain reduction.<sup>182</sup> For triamcinolone this is 10 to 20 mg, for methylprednisolone 40 mg, and for dexamethasone 10 mg (concentration 10 mg/mL), usually after application of a local anesthetic.

#### **Conclusions of the Work Group.**

- It is recommended to use the lowest effective dose of corticosteroids for the epidural injection. This amounts to 40 mg for MPA, 10 to 20 mg for triamcinolone acetate, and 10 mg (10 mg/mL) for dexamethasone phosphate.

#### **Epidural Corticosteroids for Subacute or Chronic Pain?**

Although evidence is still inconsistent,<sup>149</sup> there seems to be a negative correlation between the duration of existing complaints and the clinical effectiveness of epidural corticosteroids.<sup>183–187</sup> As a rule, epidural corticosteroids are therefore best reserved for radicular pain that has been continuously present for less than 6 months.

#### **Does the Injected Volume Play a Role?**

**Cervical.** At the cervical level, the optimum volume that needs to be injected is unknown. Two milliliters of contrast will spread bilaterally and cranially up to C3, even after an

interlaminar approach from C6–7 or C7–T1.<sup>188</sup> A volume of 4 mL will spread epidurally to the level of C2.<sup>43</sup> Considering the narrow epidural margin present at the cervical level (average 3 mm),<sup>189</sup> it is theoretically possible that the injection of higher volumes in the epidural space can involve a higher risk for dural puncture.

**Lumbar.** There is a significant correlation of higher injected volumes and better outcome for caudal and lumbar interlaminar administration.<sup>21,190</sup> This was not determined for the TF lumbar injections; however, from an anatomical point of view, a volume of 4 mL in a lumbar TF administration reached the superior part of the upper disc as well as the inferior part of the underlying disc in 93% of the cases.<sup>191</sup> In a study with dexamethasone, the clinical relevance could not be determined. The additional rapid administration of 5 mL 0.9% NaCl after a mixture of 4 mg dexamethasone plus 0.33% lidocaine (3-mL solutions, 8 mL in total) did not result in better pain relief after 4 weeks in comparison to the dexamethasone mixture of 3 mL.<sup>192</sup>

Animal experimental<sup>193</sup> and clinical data<sup>194</sup> often include the phenomenon of endoneural edema with secondary ischemia and electromyographic deviations in the event of traction/pressure on the nerve root. If after correct positioning of the needle tip an exacerbation still occurs during epidural injection of local anesthetics and/or corticosteroids, it is recommended to inject sufficiently slowly or intermittently. It is possible that this involves a maximum volume injected cervically or an ischemia of the nerve root secondary to pressure increases. In certain circumstances, it can be necessary to reduce the volume.

**Considerations of the Work Group.** There is no scientific added value for injecting large volumes at the cervical level and for lumbar TF injections. It is reasonable to recommend a reduction of volumes and to inject sufficiently slowly for safety reasons.<sup>36</sup>

#### **Conclusions of the Work Group.**

- Limit the cervical interlaminar and (lumbar) TF volume to 4 mL and inject sufficiently slowly.

#### **Number of Injections?**

There is no ideal number of injections; the number of treatments should be individually adjusted in accordance with clinical response. However, consensus has been reached that additional treatments may only be administered after a 2-week interval in order to allow proper evaluation and minimize endocrine side effects.<sup>177</sup>

### Type of Needle for Transforaminal Injections?

There are different types of needles available that are expected to decrease the chance for accidental intravascular injection. A Whitacre (pencil point) needle demonstrated lower intravascular access (5.4%) than a Quincke needle (16.2%).<sup>195</sup> However, this is contrary to other publications. In TF injections, needles with a blunt tip (22 gauge), or threading up a blunt catheter through a sharp needle (20 gauge) showed a lower incidence of vascular penetration in comparison with fine needles with a sharp tip (Whitacre pencil point, 25 gauge). In a comparative study between these 3 types of needles, there was significantly less vascular injection with the blunt catheter (4.9%) that was inserted through a sharp needle in comparison with blunt-tipped and sharp-tipped needles (15.6% and 16.5%, respectively). These results, however, were tempered by the technical problems that were experienced with both the blunt catheter with a sharp needle and needles with a blunt tip. Needles with a blunt tip resulted in additional persistent intravascular injections despite repositioning, presumably by causing blunt trauma in larger foraminal veins, such that probably a route was created along which the contrast always ran intravenously. The authors concluded that no distinction could be made between the different types of needles when it came to preventing accidental intravascular injections.<sup>196</sup>

By using needles with extension lines, the number of unexpected movements of the needle could be kept to a minimum<sup>197</sup> and real-time imaging could be carried out without the proceduralist's hands being directly in the radiation path.

**Considerations of the Work Group.** There is no needle whatsoever with superior safety when it comes to preventing accidental intravascular injection. The use of needles with extension lines is, however, recommended.

### Conclusions of the Work Group.

- The use of needles with extension lines is recommended for TF injections.

### Practical Recommendations for Prevention of Neurological Complications in the Benelux Union

**Fluoroscopy and Contrast in Interlaminar Procedures.** *Cervical: preventing dural puncture/subdural injection* – At the cervical level, the epidural space at C6–7 and C7–T1 is the widest, with an average dimension of 3 mm (1 to 4 mm).<sup>189</sup> At C7–T1, in the dorsal epidural space 1 to 2 mm of fat may be visible on

MRI (rarely more than this), such that this level has somewhat more margin on interlaminar approach.<sup>198</sup>

All of this means that interlaminar procedures may take place preferably at C7–T1, and at the highest at C6–7, after prior radiological evaluation.<sup>198,199</sup> There are no additional clinical reasons to infiltrate at higher levels.<sup>200,201</sup> Radiological evaluation preferably uses the MRI to correctly assess the distance between dura and bone since this is the limiting factor. However, the minimum distance required for a safe procedure is unclear.

Fluoroscopy is additionally essential since the ligamentum flavum is frequently not fused at the midline at the cervical level (67% not fused to C6–7, C7–T1), whereby the loss-of-resistance technique is not reliable to correctly estimate the depth.<sup>202</sup> At the first approach at the cervical level without fluoroscopy, in 53% of cases a false loss of resistance is found with incorrect needle placement.<sup>201</sup>

Fluoroscopy is therefore recommended via a lateral (profile) image (patient seated, using hanging-drop technique), whereas others recommend an approach via a contralateral oblique view<sup>22,203</sup> (patient in prone position with the head positioned on a pillow). However, the hanging-drop technique in a patient in a seated position can also incorrectly identify the epidural space, such that fluoroscopy and contrast administration continues to be necessary.<sup>201,204</sup> The technique with the patient in the prone position makes it possible to nonetheless approach the C7–T1 level, despite the presence of a significant superpositional image due to broad shoulders. The use of the hanging-drop technique is not suitable due to the positive cervical pressure in this position.<sup>204,205</sup> There are no data to compare the safety of these 2 recognized techniques.

**Considerations of the Work Group.** A prior radiological review using MRI (or second choice, CT) is required to rule out red flags. In addition, it is recommended to assess the available cervical space,<sup>36,206</sup> but it is unclear what the minimum requirement is for safe administration of epidural corticoids. If there is limited space between the dura and the bone, it is recommended to keep the injection volume and concentration to a minimum, in order to reduce segmental spread and to better allow neurological evaluation by limiting local anesthetics.<sup>36</sup> Because a volume of 4 mL will also reach the higher cervical segments, and there are no reasons to use greater volumes, it is reasonable to inject maximally 4 mL.

The work group recognizes the importance of fluoroscopy with contrast administration in the execution of

cervical epidural injections. This can be done using either a lateral image or an image with an oblique view (contralateral oblique).

#### *Conclusions of the Work Group.*

- Interlaminar cervical level: preferably at C7–T1, and at the highest at C6–7.
- For cervical epidural injection, prior radiological review is necessary by MRI (or second choice, CT scan) to rule out red flags. Additionally, it is recommended to first assess the available cervical epidural space.
- Limit the total volume to be injected to maximally 4 mL.

#### **Avoidance of Vascular Injection**

*Interlaminar Procedures.* In a retrospective study, the vascular pattern of the imaging was studied independently after an injection of contrast after interlaminar lumbar injection, TF lumbar injection, or (paramedian) interlaminar injection at the cervical level. This demonstrated a vascular pattern in 3%, 8.9%, and 2%, respectively, of the cases. Although the TF path involves a greater risk for an accidental intravascular injection, this is also possible after an interlaminar injection.<sup>207</sup> Other authors found the incidence of an intravascular pattern for the TF path at the lumbar level between 11.2% and 15.5%<sup>208,209</sup> and at the cervical level 19.4%.<sup>89</sup> The chance for TF intravascular injection is greater at the S1 level (21.3%) in comparison with the lumbar level (8.1%).<sup>208</sup>

*Considerations of the Work Group.* Imaging with contrast administration for an interlaminar injection is always needed because a correct positioning of the needle in the lumbar epidural space with the loss-of-resistance technique yields many false positive results (lumbar up to 25%), and for the exclusion of a vascular puncture (2% at cervical level and 3% at lumbar level).<sup>210–212</sup> No data are available with respect to the thoracic level.

#### *Conclusions of the Work Group.*

- In the interlaminar technique (lumbar and cervical), fluoroscopy with contrast is required. At the very least, a lateral image is required to reliably assess the depth of needle penetration; there are arguments for carrying out this procedure in a face-down position in the interest of better visualization of the contrast

course in an anteroposterior image. There is no technique (sitting vs. lying down) that has demonstrated superior safety.

*Fluoroscopy and Contrast in Interlaminar Procedures.* The administration of contrast is essential for the exclusion of incorrect positioning of the needle tip<sup>89,120</sup>:

- Intravenous: the flow can run longitudinally or transversely, across the center line or to outside the vertebral canal. If such a pattern is recognized, it may be sufficient to reposition the needle.
- Intra-arterial: an accidental injection in a radicular artery (certainly in the artery of Adamkiewicz) will cause flow medially and cranially at the midline (anterior spinal artery).

DSA is advised by some,<sup>213</sup> but in 1 case an intra-arterial injection with secondary paraplegia could not be prevented despite the use of fluoroscopy, 2 sequences of DSA, and a test dose with lidocaine.<sup>67</sup> At present, there is insufficient evidence supporting the use of DSA with ESIs, and DSA does not guarantee a better clinical outcome or a reduction in complications.<sup>214</sup> It may be considered if the contrast course is difficult to visualize, for example, if previously administered contrast is still present, or in the presence of osteosynthetic material.

*Considerations of the Work Group.* Contrast administration with real-time imaging is essential for the TF administration of corticoids, since the chance for a vascular puncture at the lumbar level is between 8% and 15.5% (21.3% at S1) and at the cervical level 19.4%,<sup>89,196</sup> with a reasonable chance for crossing the vertebral artery.<sup>215</sup> At the cervical level, it was determined by CT-fluoroscopy that the needle path in a cervical TF procedure in 30 out of 70 injections was on the path of the vertebral artery.<sup>215</sup>

Because of the possible puncture of the artery of Adamkiewicz above vertebra L3 and the lack of added value of the TF epidural administration of epidural corticosteroids at higher levels, this technique was only recommended by the work group for root L3 or lower.

No recommendation can be made concerning DSA, since it is not clear to what extent this can prevent intravascular injection, and there is a slightly higher radiation load on the patient and practitioner.

It is recommended to save images with the final needle position in the medical record.

### *Conclusions of the Work Group.*

- With the TF technique, fluoroscopy with contrast under real-time imaging is mandatory. DSA is optional.
- Despite fluoroscopy with contrast application, an intravascular injection cannot be fully ruled out.
- The use of a needle with an extension line is recommended to avoid moving the needle during the procedure. Despite fluoroscopy contrast administration/DSA, intravascular injection cannot be completely ruled out.

**Test Dose with Local Anesthetic.** In the literature, 1 case is known of a neurological deficit after a cervical TF injection of contrast and 0.8 mL lidocaine 2%. Symptoms occurred 60 seconds after injection of the local anesthetic. In the subsequent 2 to 3 minutes, the patient experienced paralysis of all limbs, which completely disappeared after 20 minutes.<sup>53</sup> Based on this case, it was suggested to use a test dose of local anesthetic before injecting a corticosteroid.<sup>46,214,216</sup> However, this is the only known case in which it was not clear to what extent the injection of contrast or lidocaine was responsible for this effect. In addition, in the above section, a case was already reported in which fluoroscopy, 2 sequences of DSA, followed by a test block with lidocaine could not prevent the occurrence of tetraplegia.<sup>217</sup> A retrospective study on the use of test blocks in cervical TF injections was able to detect central nervous system symptoms (after real-time imaging) in 4 of 532 patients (0.75%). However, it is possible that there were also false-positive central nervous system symptoms.<sup>216</sup>

In case of accidental intrathecal injection of local anesthetic, a motor block can be observed after 3 to 5 minutes.<sup>21</sup> Frequently, 1 mL of lidocaine or bupivacaine is administered before a TF corticosteroid injection. In a study in pregnant women, the effective doses (for 50% and 95% of the sample) of the above were determined in order to obtain a reliable motor block after intrathecal injection via an interlaminar approach.<sup>218</sup> This proved for lidocaine 2% to be 13.7 mg (0.69 mL) and 16 mg (0.8 mL), respectively, and for bupivacaine 0.5% to be 3.4 mg (0.68 mL) and 5.9 mg (1.02 mL), respectively. With 1 mL local anesthetic, it is possible to effectively detect a motor block upon accidental intrathecal injection, but this can only be done reliably 3 to 5 minutes after injection of a test dose. The usual tests for this are the Bromage scale and the hip test, the reliability of which in a patient in the prone position is not clear. Moreover, the clinical course

of a motor block by an intrathecal injection could potentially vary for an interlaminar vs. TF approach.

**Considerations of the Work Group.** Because local anesthetics decrease pain and have a dilution effect on potential neurotoxic substances in corticosteroid mixtures, it is common practice to first inject local anesthetics. It is unclear to what extent a test dose with a local anesthetic can detect accidental intravascular or intrathecal injection, especially at the lumbar level, because this is an extrapolation of the cervical level based on 1 case.

### *Conclusions of the Work Group.*

- The injection of a local anesthetic is recommended prior to a TF corticosteroid injection. Be attentive to neurological symptoms during the minutes after an injection. The exact value of these in detecting accidental intravascular or intrathecal injection at the lumbar level is not clear.

**Avoiding Air.** In 1 study, pneumocephalus was observed after a cervical interlaminar injection, probably after accidental dural puncture. The patient lost consciousness 5 minutes after injection of dexamethasone 5 mg and ropivacaine, but regained consciousness after manual ventilation.<sup>219</sup>

A neurological deficit with blindness occurred in another case, a few seconds after the TF administration of 1 mL of air followed by contrast at the cervical level (after prior accidental puncture of the vertebral artery).<sup>47</sup> The prevention of an air embolus using 0.9% NaCl for the loss-of-resistance interlaminar technique, or flushing the TF needle and extension line, is therefore a logical safety measure. Whether this can really avoid the problem is not known.

**Considerations of the Work Group.** The avoidance of unnecessary air in the epidural space is recommended. It is unclear to what extent the flushing of a puncture needle with a liquid can prevent pneumocephalus.

### *Conclusions of the Work Group.*

- Preventing unnecessary air in extension lines/needles by flushing them with a liquid is recommended.

**Avoiding Excessive Sedation.** In a closed claims analysis after cervical procedures,<sup>34</sup> the most important

reason was found to be direct needle trauma (31% of the complications). The impact of anesthesia or sedation on the procedure is shown by the ratio between patients with spinal cord trauma who received sedation/anesthesia (67%) compared to patients with complications not related to the spinal cord (19%) ( $P < 0.001$ ). Of the patients who underwent a cervical procedure and suffered secondary spinal trauma, 25% could no longer give adequate replies during the procedure, in comparison with only 5% who did not have spinal cord injuries ( $P < 0.05$ ).

**Considerations of the Work Group.** It is the opinion of the work group that excessive sedation should be avoided. According to the American Society of Anesthesiologists, this is a drug-induced depression of consciousness during which patients cannot be easily aroused but respond purposefully following repeated or painful stimulation. It is preferable that a patient be able to respond adequately during a procedure.<sup>36</sup>

#### **Conclusions of the Work Group.**

- Excessive sedation should be avoided. It is preferable that a patient be able to respond adequately during a procedure.

**Are Prophylactic Antibiotics Needed Upon (Accidental) Disc Puncture?** As already stated, some experts, and the most recent guidelines from the United Kingdom, suggest the administration of prophylactic antibiotics for patients at higher risk.<sup>28,30,220</sup> On the other hand, there was a study in which 200 patients were followed for at least 3 months after discography (2-needle technique) without the prophylactic use of antibiotics. Not a single case of discitis was reported. In an additional literature search, 10 studies were found. In 9 studies without the use of prophylactic antibiotics, an incidence of discitis was reported in 12 of 4,891 patients (0.25%). The only study with prophylactic antibiotics (127 patients) showed no cases of discitis whatsoever. The authors concluded that, given the low number of patients in the only study that used prophylactic antibiotics, and the low incidence of discitis after discography, there is not enough evidence to recommend prophylactic antibiotics to prevent discitis.<sup>221</sup> A similar incidence of discitis after discography was found in a systematic review dealing with cervical discography. Discitis was observed in 21 of 4,804 patients (0.44%). The authors concluded that

the incidence is low and that it may decline further through the prophylactic use of antibiotics.<sup>222</sup>

**Considerations of the Work Group.** The incidence of discitis after discography is 0.25% to 0.44%. In view of the seriousness of discitis, prophylactic antibiotics should be considered in high-risk patients.

#### **Conclusions of the Work Group.**

- The routine use of prophylactic antibiotics in disc puncture is not recommended; however, it may be considered in high-risk patients.

**Sterility.** Sterility is essential for the prevention of major infections such as meningitis and epidural abscess. Therefore, some guidelines are very strict and stipulate, in addition to the classic preventive sterility measures, the use of a sterile surgical gown during all epidural procedures.<sup>220,223</sup> Guidelines related to sterility during invasive procedures were developed by the Work Group on Infection Prevention.<sup>224</sup>

Concern has arisen regarding the possibility that antiseptics, particularly chlorhexidine/alcohol solutions, may cause arachnoiditis. However, the causal link is not clear. Conversely, a retrospective cohort study involving more than 12,000 patients failed to demonstrate an increased risk for neuro-axial complications using chlorhexidine as a skin disinfectant. Moreover, an *in vitro* study showed that the use of chlorhexidine in clinical concentrations was no more cytotoxic than povidone-iodine, and that possible residual chlorhexidine (if given time to dry) that reached the epidural space through the needle tip was diluted up to 1:145,000.<sup>36</sup> The American Society of Regional Anesthesia and Pain Medicine work group decided that, based on the superiority of chlorhexidine as an antiseptic agent, this is the first choice as disinfectant in the implementation of neuro-axial procedures.

#### **Conclusions of the Work Group.**

- It is advised to follow the guidelines of the Work Group on Infection Prevention ([www.wip.nl](http://www.wip.nl)).
- Chlorhexidine/alcohol is the first choice for skin disinfection in neuro-axial procedures. Sufficient time must be allowed for the skin to dry, and it should not encounter sterile materials such as needles, syringes, or medications.

**Anticoagulants.** Many complications related to anticoagulants and epidural infiltrations have been reported. We refer the reader to recent guidelines regarding this subject.<sup>225</sup>

### What to Do if You Suspect Neurological Complications

**Medullary Ischemia<sup>36</sup> and Conus Medullaris Syndrome<sup>226</sup>.** If neurological function is not restored within 2 to 3 hours after epidural corticosteroid administration, an MRI should be performed to rule out medullary ischemia secondary to an epidural hematoma or abscess; if negative, this study should be repeated after 24 hours, since a delayed effect may also be observed. If no direct access to an MRI is available, an emergency CT scan should be performed to identify compressive space-occupying processes that may be eligible for surgical decompression. This should best be done within 8 to 12 hours after the start of the symptoms to achieve complete or partial (40% to 66%) neurological recovery. A recent study does cast some doubt on this conclusion, because in 7 patients, after laminectomy due to epidural hematoma, no relationship could be found between the speed of intervention and the neurological outcome.<sup>227</sup> In medicolegal procedures, the early detection of a neurological complication is stressed. Often, a neurological deficit is erroneously attributed to the block with local anesthetic itself, so that time is lost before the diagnosis is made. The severity of the neurological deficit at the time of intervention is also a predictor of the outcome.

If an epidural hematoma or abscess is ruled out, but medullary ischemia is suspected/confirmed, there are arguments for maintaining the blood pressure at high-normal, maintaining normoglycemia, and considering drainage of CSF. The usefulness of the latter has not been proven for anesthesia–pain procedure–related spinal cord ischemia, but it has been demonstrated for surgery-related spinal cord ischemia. This technique can be considered since it is safe in case of spinal cord ischemia. The utility of the use of IV corticosteroids specifically for anesthesia or pain-related nerve injury is not known. These can be advantageous in cases of direct spinal cord trauma through interventional procedures. Conversely, however, there is an association between a worse neurologic outcome, directly through corticosteroid-induced neurotoxicity and indirectly through hyperglycemia, whereby corticosteroids are probably best avoided if spinal cord ischemia is suspected. This can best be discussed with a neurologist or neurosurgeon consultant.<sup>36</sup>

**Considerations of the Work Group.** The work group recognizes the importance of rapid diagnosis on the suspicion of nerve injury after epidural injection. This can be complicated considerably if a high concentration of a local anesthetic is used, due to the possible masking of motor block secondary to a severe neurological cause.

If the procedure is followed by an unexpectedly prolonged sensory or motor block, the reappearance of sensory or motor symptoms after an initial disappearance thereof or a nerve block outside the expected distribution area, treatable causes should be adequately ruled out. The preferable diagnostic measure is MRI (or CT if MRI is not immediately available) to rule out compression by epidural hematoma or abscess. If only CT is available and this is negative, an MRI should still be made to rule out spinal cord ischemia.

If no surgically treatable compression is present, and spinal cord ischemia is suspected, it is advisable to maintain the blood pressure at high-normal, monitor glycemia, and consider drainage of CSF.

### Conclusions of the Work Group.

- In case of unexpectedly prolonged sensory or motor block, the reappearance of sensory or motor symptoms after an initial disappearance or the occurrence of a nerve block outside the expected distribution area, an MRI is recommended within 3 hours:
  - MRI negative: new MRI after 24 hours
  - MRI shows epidural hematoma or abscess: urgent decompression
  - MRI shows spinal cord ischemia: maintain high-normal blood pressure, normoglycemia, consider draining CSF
- It is therefore recommended to use short-acting and low doses of local anesthetics in epidural mixtures to allow rapid neurological evaluation. The preference is for lidocaine 1% to 2%.

**Arachnoiditis<sup>228</sup>.** Arachnoiditis is a painful condition caused by inflammation of the arachnoids, one of the membranes that surround and protect the spinal cord. The arachnoids may become inflamed by chemical irritation, bacterial or viral infection, direct injury to the spinal cord, chronic compression of the spinal nerves, or complications of spinal surgery or other invasive spinal procedures. Inflammation can sometimes

**Table 3. Summary of Conclusions****Toxicity and glucocorticoids**

- The chances of neurotoxicity are extremely small when the corticosteroids correctly enter the epidural space
- It is still unclear whether leaving out preservatives and solvents for the purposes of preventing arachnoiditis or vascular complications outweighs the infection risk in the event of accidental contamination
- There are currently no indications that one type of particulate corticosteroid is safer
- It is recommended to inject a local anesthetic prior to a transforaminal corticosteroid injection. Pay attention to any neurological symptoms occurring within a minute after the injection. The exact value in tracking down an accidental intravascular or intrathecal injection at the lumbar level is unclear
- It is recommended to use the lowest possible dose of a glucocorticosteroid for the epidural injection. Considering effectiveness, this amounts to 40 mg for methylprednisolone acetate, 10 to 20 mg for triamcinolone acetate, and 10 mg (10 mg/mL) for dexamethasone phosphate

**Place of dexamethasone**

- In the event of contrast allergy or above the L3 level, transforaminal corticosteroid injections should always be done with dexamethasone.
- Both particulate corticosteroids and dexamethasone are permitted for lumbar transforaminal infiltrations at level L3 or lower. As we currently have too little information on the long-term safety of dexamethasone and the availability of safe formulations is limited (in the Benelux), this cannot be required at the moment

- There are currently no arguments in favor of switching to dexamethasone for interlaminar epidural infiltration

**Cervical subacute cervico-brachialgia**

- Cervical Interlaminar level: preferably at C7–T1, and no higher than C6–7
- A radiological assessment must be performed, including MRI (or CT as a second option) to rule out any red flags before conducting a cervical epidural infiltration. It is also recommended to assess the available cervical epidural space at the cervical level first
- Negative recommendation for cervical transforaminal injection of particulate corticosteroids. Although not recommended, there are currently no counterarguments for the cervical transforaminal administration of dexamethasone
- For the interlaminar injection, no vascular complications are reported and a particulate corticosteroid (or dexamethasone 10 mg) can be used. If required, 0.9% NaCl or lidocaine 1% to 2% can be used for dilution
- Limit the total volume to be injected to no more than 4 mL

**Place of radiology**

- Fluoroscopy with contrast is compulsory for the interlaminar technique at the cervical level and recommended at the lumbar level. At the very least, a latero-lateral recording must be done; there are arguments to perform this procedure in the prone position as the visualization of the course of the contrast medium is better in an anteroposterior recording. No superior safety has been determined for any one technique (seated vs. prone)
- With the transforaminal technique, fluoroscopy with contrast under real-time imaging is also compulsory. Digital subtraction angiography is optional
- Despite fluoroscopy with contrast administration/digital subtraction angiography, an accidental intravascular injection cannot be fully ruled out

**Lumbar subacute lumbosacral radicular syndrome**

- The transforaminal approach is recommended via the “safe triangle,” with a clear preference to keep the needle tip posterior in the neuroforamen. Particulate corticosteroids may only be transforaminally injected at level L3 or lower; this limitation does not apply for dexamethasone
- After an accidental intrathecal puncture, the needle must be placed in a different location. Once correct epidural positioning has been confirmed, a glucocorticosteroid may be injected

**Epidural volume**

- Limit the cervical interlaminar and (lumbar) transforaminal volume to 4 mL (or less if it is too painful) and inject sufficiently slowly

**Sterility**

- Chlorhexidine/alcohol is the first choice as skin disinfectant for neuro-axial procedures. Allow sufficient time for the skin to dry and avoid contact with sterile material such as needles, syringes, or medication

**What to do in the event of a suspected neurological complication**

- In case of unexpectedly prolonged sensory or motor block, the reappearance of sensory or motor symptoms after an initial disappearance or the occurrence of a nerve block outside the expected distribution area, an MRI is recommended within 3 hours:
  - MRI negative: new MRI after 24 hours
  - MRI shows epidural hematoma or abscess: urgent decompression
  - MRI shows spinal cord ischemia: maintain high-normal blood pressure and normoglycemia, consider drainage of cerebrospinal fluid
- It is therefore recommended to use short-acting and low-dose local anesthetics in epidural mixtures to enable a rapid neurological evaluation. Lidocaine is therefore preferred

**Miscellaneous**

- The use of needles with extension lines is recommended for transforaminal injections. It is recommended rinsing with a fluid to avoid any unnecessary air
- Excessive sedation must be avoided. Preferably a patient should be able to respond appropriately during a procedure
- The routine use of prophylactic antibiotics in case of (accidental) disc puncture is not recommended; however, this may be considered for high-risk patients
- Collaborations: establish agreements with emergency services, the radiology and neurology departments, and back surgeons as to what is to be done in the event of a suspected neurological complication after epidural corticosteroids

lead to scarring and adhesions, such that the spinal nerves stick together.

*Symptoms* – Arachnoiditis can cause several symptoms such as numbness, tingling, and the characteristic stabbing and burning in the lower back and legs. Some people with arachnoiditis may have disabling cramps, tremors, or spasms. It can interfere with the bladder,

bowel, and sexual function. In severe cases, arachnoiditis can cause paralysis of the legs.

*Diagnosis* – MRI may show meningeal thickening and clumping or marginalization of the nerve roots.

*Treatment* – Arachnoiditis is a disease that is difficult to treat, and the long-term results are unpredictable. Most

**Table 4. Summary of Positive Recommendations for the Prevention of Neurological Complications**

<p>Transforaminal lumbar</p> <ul style="list-style-type: none"> <li>• Evaluate MRI or CT to determine the level and to rule out red flags</li> <li>• Use needles with extension lines and flush these beforehand with contrast (or lidocaine)</li> <li>• Under fluoroscopic control, enter the needle tip into the posterior part of the neuroforamen</li> <li>• Anteroposterior image: control contrast pattern under real-time imaging. Consider digital subtraction angiography if the image is unclear</li> <li>• Inject lidocaine 1 mL 1% to 2% Wait 1 minute</li> <li>• Particulate corticosteroids (only L3 or lower) or dexamethasone 10 mg Interlaminar cervical</li> <li>• Evaluate MRI (CT) beforehand</li> <li>• Infiltration level: preferably at C7–T1, and no higher than C6–7</li> <li>• Always use fluoroscopy with at least 1 latero-lateral view or contralateral oblique and contrast (except in the event of contrast allergy)</li> <li>• Use lidocaine 1% to 2% as local anesthetic</li> <li>• Limit the volume to 4 mL</li> </ul> <p>Contrast allergy</p> <ul style="list-style-type: none"> <li>• Interlaminar: carry out infiltration without contrast</li> <li>• Transforaminal: only use dexamethasone 10 mg</li> </ul>
--

treatments for arachnoiditis concentrate on pain reduction and improvement of the symptoms that impede daily functioning. Combined treatment consisting of pain management, physical therapy, exercise, and psychotherapy is recommended.

**Epidural Abscess: Meningitis**<sup>36</sup>. A spinal epidural abscess or meningitis may manifest slowly with symptoms several days after the procedure, with fever and back pain, followed by a rapid progression to paralysis. Rapid diagnosis and treatment is important because both have a mortality rate of 15%. A rapid diagnosis is associated with less severe neurological sequelae.

In summary, early detection and appropriate intervention can improve the outcome of patients with hemorrhagic, infectious, or inflammatory insult. Unfortunately, the same cannot be said of an injury due to ischemia, anesthetic neurotoxicity, and/or direct mechanical injury.

## CONCLUSIONS

Epidural corticosteroid administration is frequently performed in pain medicine, predominantly to help the patient overcome the (sub)-acute phase of radicular pain. The reports on serious neurological complications have triggered actions by the FDA and the elaboration of work groups to define a series of considerations for improving the safety of the epidural corticosteroid administration.

The Benelux work group has reviewed the side effects and complications reported after epidural corticosteroid administration, and based on the available evidence and

recommendations, including the U.S. safe use recommendation, suggestions are made to improve the safety of epidural corticosteroid administration. The conclusions are summarized in Table 3 and the recommendations in Table 4.

## ACKNOWLEDGEMENTS

The authors wish to thank Nicole Van den Hecke for administrative support and editing, and the board of the different pain societies for their time and expertise. This consensus was reached through the voluntary efforts of the authors. Administrative support and translation of the initial Dutch version of the consensus was made possible by the World Institute of Pain, Benelux section.

## CONFLICT OF INTEREST

None of the authors have conflicts of interest.

## REFERENCES

1. U.S. Food and Drug Administration. Epidural steroid injections (ESI) and the risk of serious neurologic adverse reactions. In: Anesthetic and Analgesic Drug Products Advisory Committee, ed. *Anesthetic and Analgesic Drug Products Advisory Committee: Briefing Document*. Silver Spring, MD: U.S. Food and Drug Administration; 2014:8–56.
2. Racoosin JA, Seymour SM, Cascio L, Gill R. Serious neurologic events after epidural glucocorticoid injection—the FDA’s risk assessment. *N Engl J Med*. 2015;373:2299–2301.
3. Rathmell JP, Benzon HT, Dreyfuss P, et al. Safeguards to prevent neurologic complications after epidural steroid injections: consensus opinions from a multidisciplinary working group and national organizations. *Anesthesiology*. 2015;122:974–984.
4. Ahadian FM, McGreevy K, Schulteis G. Lumbar transforaminal epidural dexamethasone: a prospective, randomized, double-blind, dose-response trial. *Reg Anesth Pain Med*. 2011;36:572–578.
5. De Vries F, Bracke M, Leufkens HG, Lammers JW, Cooper C, Van Staa TP. Fracture risk with intermittent high-dose oral glucocorticoid therapy. *Arthritis Rheum*. 2007;56:208–214.
6. Steinbuch M, Youket TE, Cohen S. Oral glucocorticoid use is associated with an increased risk of fracture. *Osteoporos Int*. 2004;15:323–328.
7. Al-Shoha A, Rao DS, Schilling J, Peterson E, Mandel S. Effect of epidural steroid injection on bone mineral density and markers of bone turnover in postmenopausal women. *Spine (Phila Pa 1976)*. 2012;37:E1567–E1571.
8. Kim S, Hwang B. Relationship between bone mineral density and the frequent administration of epidural steroid



injections in postmenopausal women with low back pain. *Pain Res Manag.* 2014;19:30–34.

9. Mandel S, Schilling J, Peterson E, Rao DS, Sanders W. A retrospective analysis of vertebral body fractures following epidural steroid injections. *J Bone Joint Surg.* 2013;95:961–964.

10. Bicket MC, Chakravarthy K, Chang D, Cohen SP. Epidural steroid injections: an updated review on recent trends in safety and complications. *Pain Manag.* 2015;5:129–146.

11. Tuel SM, Meythaler JM, Cross LL. Cushing's syndrome from epidural methylprednisolone. *Pain.* 1990;40:81–84.

12. Horani MH, Silverberg AB. Secondary Cushing's syndrome after a single epidural injection of a corticosteroid. *Endocr Pract.* 2005;11:408–410.

13. Friedly JL, Comstock BA, Turner JA, et al. A randomized trial of epidural glucocorticoid injections for spinal stenosis. *N Engl J Med.* 2014;371:11–21.

14. Kay J, Findling JW, Raff H. Epidural triamcinolone suppresses the pituitary-adrenal axis in human subjects. *Anesth Analg.* 1994;79:501–505.

15. Gensler LS. Glucocorticoids: complications to anticipate and prevent. *Neurohospitalist.* 2013;3:92–97.

16. Hooten WM. Infectious complications of commonly performed spinal injections. *Semin Pain Med.* 2004;2:208–214.

17. Cansever T, Kabatas S, Civelek E, et al. Transforaminal epidural steroid injection via a preganglionic approach for the treatment of lumbar radicular pain. *Turk Neurosurg.* 2012;22:183–188.

18. Even JL, Crosby CG, Song Y, McGirt MJ, Devin CJ. Effects of epidural steroid injections on blood glucose levels in patients with diabetes mellitus. *Spine (Phila Pa 1976).* 2012;37:E46–E50.

19. Gonzalez P, Laker SR, Sullivan W, Harwood JE, Akuthota V. The effects of epidural betamethasone on blood glucose in patients with diabetes mellitus. *PM&R.* 2009;1:340–345.

20. Younes M, Neffati F, Touzi M, et al. Systemic effects of epidural and intra-articular glucocorticoid injections in diabetic and non-diabetic patients. *Joint Bone Spine.* 2007;74:472–476.

21. Cohen SP, Bicket MC, Jamison D, Wilkinson I, Rathmell JP. Epidural steroids: a comprehensive, evidence-based review. *Reg Anesth Pain Med.* 2013;38:175–200.

22. Abbasi A, Malhotra G, Malanga G, Elovic EP, Kahn S. Complications of interlaminar cervical epidural steroid injections: a review of the literature. *Spine.* 2007;32:2144–2151.

23. Catchlove RF, Braha R. The use of cervical epidural nerve blocks in the management of chronic head and neck pain. *Can Anaesth Soc J.* 1984;31:188–191.

24. Verdun AV, Cohen SP, Williams BS, Hurley RW. Pneumocephalus after lumbar epidural steroid injection: a case report and review of the literature. *A A Case Rep.* 2014;3:9–13.

25. Sweni S, Senthilkumaran S, Balamurugan N, Thirumalaikolundusubramanian P. Tension pneumocephalus: a case report with review of literature. *Emerg Radiol.* 2013;20:573–578.

26. Everett CR, Baskin MN, Speech D, Novoseletsky D, Patel R. Flushing as a side effect following lumbar transforaminal epidural steroid injection. *Pain Physician.* 2004;7:427–429.

27. Abbasi A, Roque-Dang CM, Malhotra G. Persistent hiccups after interventional pain procedures: a case series and review. *PM&R.* 2012;4:144–151.

28. Cohen SP, Maine DN, Shockey SM, Kudchadkar S, Griffith S. Inadvertent disk injection during transforaminal epidural steroid injection: steps for prevention and management. *Pain Med.* 2008;9:688–694.

29. Candido KD, Katz JA, Chinthagada M, McCarthy RA, Knezevic NN. Incidence of intradiscal injection during lumbar fluoroscopically guided transforaminal and interlaminar epidural steroid injections. *Anesth Analg.* 2010;110:1464–1467.

30. Plastaras CT, Casey E, Goodman BS, Chou L, Roth D, Rittenberg J. Inadvertent intradiscal contrast flow during lumbar transforaminal epidural steroid injections: a case series examining the prevalence of intradiscal injection as well as potential associated factors and adverse events. *Pain Med.* 2010;11:1765–1773.

31. Hong JH, Lee SM, Bae JH. Analysis of Inadvertent Intradiscal Injections during lumbar transforaminal epidural injection. *Korean J Pain.* 2014;27:168–173.

32. Bogduk N, Brazer G, Chrisotophidis N. *Epidural Use of Steroids in Management of Back Pain.* Canberra, ACT: National Health and Medical Research Council; 1994:2.

33. Fitzgibbon DR, Posner KL, Domino KB, et al. Chronic pain management: American Society of Anesthesiologists Closed Claims Project. *Anesthesiology.* 2004;100:98–105.

34. Rathmell JP, Michna E, Fitzgibbon DR, Stephens LS, Posner KL, Domino KB. Injury and liability associated with cervical procedures for chronic pain. *Anesthesiology.* 2011;114:918–926.

35. Manchikanti L, Malla Y, Wargo BW, Cash KA, Pampati V, Fellows B. A prospective evaluation of complications of 10,000 fluoroscopically directed epidural injections. *Pain Physician.* 2012;15:131–140.

36. Neal JM, Barrington MJ, Brull R, et al. The second ASRA practice advisory on neurologic complications associated with regional anesthesia and pain medicine: executive summary 2015. *Reg Anesth Pain Med.* 2015;40:401–430.

37. Nelson DA, Landau WM. Intraspinial steroids: history, efficacy, accidentality, and controversy with review of United States Food and Drug Administration reports. *J Neurol Neurosurg Psychiatry.* 2001;70:433–443.

38. Kim W, Kim JS, Lim SC, Kim YI, Moon DE. Reversible posterior leukoencephalopathy syndrome after cervical transforaminal epidural steroid injection presenting as transient blindness. *Anesth Analg.* 2011;112:967–970.

39. McGrath JM, Schaefer MP, Malkamaki DM. Incidence and characteristics of complications from epidural steroid injections. *Pain Med.* 2011;12:726–731.

40. El-Yahouchi C, Plastaras C, Maus T, et al. Complication rates of transforaminal and interlaminar epidural

steroid injections: a multi-institutional study. International Spine Intervention Society 22nd Annual Scientific Meeting Research Abstracts. *Pain Med.* 2014;15:1436–1446.

41. Kennedy D, Plastaras C, Pingree M, et al. Delayed complications in interventional pain procedures: a multi-institutional study. International Spine Intervention Society 22nd Annual Scientific Meeting Research Abstracts. *Pain Med.* 2014;15:1436–1446.

42. Carr CM, Plastaras CT, Pingree MJ, et al. Immediate adverse events in interventional pain procedures: a multi-institutional study. *Pain Med.* 2016;17:2155–2161.

43. Hodges SD, Castleberg RL, Miller T, Ward R, Thornburg C. Cervical epidural steroid injection with intrinsic spinal cord damage. Two case reports. *Spine.* 1998;23:2137–2142.

44. Lee JH, Lee JK, Seo BR, Moon SJ, Kim JH, Kim SH. Spinal cord injury produced by direct damage during cervical transforaminal epidural injection. *Reg Anesth Pain Med.* 2008;33:377–379.

45. Bose B. Quadriplegia following cervical epidural steroid injections: case report and review of the literature. *Spine J.* 2005;5:558–563.

46. Scanlon GC, Moeller-Bertram T, Romanowsky SM, Wallace MS. Cervical transforaminal epidural steroid injections: more dangerous than we think? *Spine.* 2007;32:1249–1256.

47. McMillan MR, Crumpton C. Cortical blindness and neurologic injury complicating cervical transforaminal injection for cervical radiculopathy. *Anesthesiology.* 2003;99:509–511.

48. Tiso RL, Cutler T, Catania JA, Whalen K. Adverse central nervous system sequelae after selective transforaminal block: the role of corticosteroids. *Spine J.* 2004;4:468–474.

49. Windsor RE, Storm S, Sugar R, Nagula D. Cervical transforaminal injection: review of the literature, complications, and a suggested technique. *Pain Physician.* 2003;6:457–465.

50. Beckman WA, Mendez RJ, Paine GF, Mazzilli MA. Cerebellar herniation after cervical transforaminal epidural injection. *Reg Anesth Pain Med.* 2006;31:282–285.

51. Ziai WC, Ardelt AA, Llinas RH. Brainstem stroke following uncomplicated cervical epidural steroid injection. *Arch Neurol.* 2006;63:1643–1646.

52. Muro K, O'Shaughnessy B, Ganju A. Infarction of the cervical spinal cord following multilevel transforaminal epidural steroid injection: case report and review of the literature. *J Spinal Cord Med.* 2007;30:385–388.

53. Karasek M, Bogduk N. Temporary neurologic deficit after cervical transforaminal injection of local anesthetic. *Pain Med.* 2004;5:202–205.

54. Rozin L, Rozin R, Koehler SA, et al. Death during transforaminal epidural steroid nerve root block (C7) due to perforation of the left vertebral artery. *Am J Forensic Med Pathol.* 2003;24:351–355.

55. Wallace MA, Fukui MB, Williams RL, Ku A, Baghai P. Complications of cervical selective nerve root blocks

performed with fluoroscopic guidance. *Am J Roentgenol.* 2007;188:1218–1221.

56. Glaser SE, Falco F. Paraplegia following a thoracolumbar transforaminal epidural steroid injection. *Pain Physician.* 2005;8:309–314.

57. Tripathi M, Nath SS, Gupta RK. Paraplegia after intracord injection during attempted epidural steroid injection in an awake-patient. *Anesth Analg.* 2005;101:1209–1211.

58. McLain RF, Fry M, Hecht ST. Transient paralysis associated with epidural steroid injection. *J Spinal Disord.* 1997;10:441–444.

59. Lenoir T, Deloin X, Dauzac C, Rillardon L, Guigui P. [Paraplegia after interlaminar epidural steroid injection: a case report]. *Rev Chir Orthop Reparatrice Appar Mot.* 2008;94:697–701.

60. Thefenne L, Dubecq C, Zing E, et al. A rare case of paraplegia complicating a lumbar epidural infiltration. *Ann Phys Rehabil Med.* 2010;53:575–583.

61. Chung JY, Han JH, Kang JM, Lee BJ. Paraplegia after epidural steroid injection. *Anaesth Intensive Care.* 2012;40:1074–1076.

62. Houten JK, Errico TJ. Paraplegia after lumbosacral nerve root block: report of three cases. *Spine J.* 2002;2:70–75.

63. Huntoon MA, Martin DP. Paralysis after transforaminal epidural injection and previous spinal surgery. *Reg Anesth Pain Med.* 2004;29:494–495.

64. Wybier M, Gaudart S, Petrover D, Houdart E, Laredo JD. Paraplegia complicating selective steroid injections of the lumbar spine. Report of five cases and review of the literature. *Eur Radiol.* 2010;20:181–189.

65. Lyders EM, Morris PP. A case of spinal cord infarction following lumbar transforaminal epidural steroid injection: MR imaging and angiographic findings. *Am J Neuroradiol.* 2009;30:1691–1693.

66. Kennedy DJ, Dreyfuss P, Aprill CN, Bogduk N. Paraplegia following image-guided transforaminal lumbar spine epidural steroid injection: two case reports. *Pain Med.* 2009;10:1389–1394.

67. Chang Chien GC, Candido KD, Knezevic NN. Digital subtraction angiography does not reliably prevent paraplegia associated with lumbar transforaminal epidural steroid injection. *Pain Physician.* 2012;15:515–523.

68. Somayaji HS, Saifuddin A, Casey AT, Briggs TW. Spinal cord infarction following therapeutic computed tomography-guided left L2 nerve root injection. *Spine (Phila Pa 1976).* 2005;30:E106–E108.

69. Dawley JD, Moeller-Bertram T, Wallace MS, Patel PM. Intra-arterial injection in the rat brain: evaluation of steroids used for transforaminal epidurals. *Spine (Phila Pa 1976).* 2009;34:1638–1643.

70. Knezevic NN, Candido KD, Cokic I, Krbanjevic A, Berth SL, Knezevic I. Cytotoxic effect of commercially available methylprednisolone acetate with and without reduced preservatives on dorsal root ganglion sensory neurons in rats. *Pain Physician.* 2014;17:E609–E618.

71. Kroszczynski AC, Kohan K, Kurowski M, Olson TR, Downie SA. Intraforaminal location of thoracolumbar anterior medullary arteries. *Pain Med.* 2013;14:808–812.
72. Chiller TM, Roy M, Nguyen D, et al. Clinical findings for fungal infections caused by methylprednisolone injections. *N Engl J Med.* 2013;369:1610–1619.
73. Centers for Disease Control and Prevention. *Multistate outbreak of fungal meningitis and other infections.* <http://www.cdc.gov/hai/outbreaks/meningitis.html>. 2012 (accessed January 23, 2013).
74. McCotter OZ, Smith RM, Westercamp M, et al. Update on multistate outbreak of fungal infections associated with contaminated methylprednisolone injections, 2012–2014. *MMWR.* 2015;64:1200–1201.
75. Nanjayan SK, Swamy GN, Yallappa S, Bommireddy R. Arachnoiditis following caudal epidural injections for the lumbo-sacral radicular pain. *Asian Spine J.* 2013;7:355–358.
76. Na EH, Han SJ, Kim MH. Delayed occurrence of spinal arachnoiditis following a caudal block. *J Spinal Cord Med.* 2011;34:616–619.
77. MacMahon PJ, Eustace SJ, Kavanagh EC. Injectable corticosteroid and local anesthetic preparations: a review for radiologists. *Radiology.* 2009;252:647–661.
78. Meyers C, Lockridge O, La Du BN. Hydrolysis of methylprednisolone acetate by human serum cholinesterase. *Drug Metab Dispos.* 1982;10:279–280.
79. Belgisch Centrum voor Farmacotherapeutische Informatie. Corticosteroiden. In: *Gecommentarieerd geneesmiddelen repertorium 2015.* Gent: BCFI; 2015.
80. Derby R, Lee SH, Date ES, Lee JH, Lee CH. Size and aggregation of corticosteroids used for epidural injections. *Pain Med.* 2008;9:227–234.
81. Benzon HT, Chew TL, McCarthy RJ, Benzon HA, Walega DR. Comparison of the particle sizes of different steroids and the effect of dilution: a review of the relative neurotoxicities of the steroids. *Anesthesiology.* 2007;106:331–338.
82. Benzon HT. Epidural steroid injections for low back pain and lumbosacral radiculopathy. *Pain.* 1986;24:277–295.
83. Benzon HT, Gissen AJ, Strichartz GR, Avram MJ, Covino BG. The effect of polyethylene glycol on mammalian nerve impulses. *Anesth Analg.* 1987;66:553–559.
84. Balis FM, Lester CM, Chrousos GP, Heideman RL, Poplack DG. Differences in cerebrospinal fluid penetration of corticosteroids: possible relationship to the prevention of meningeal leukemia. *J Clin Oncol.* 1987;5:202–207.
85. Bannwarth B, Schaeferbeke T, Pehourcq F, Vernhes JP, D'Yvoire MB, Dehais J. Prednisolone concentrations in cerebrospinal fluid after oral prednisone. Preliminary data. *Rev Rhum Engl Ed.* 1997;64:301–304.
86. Koszdin KL, Shen DD, Bernards CM. Spinal cord bioavailability of methylprednisolone after intravenous and intrathecal administration: the role of P-glycoprotein. *Anesthesiology.* 2000;92:156–163.
87. Sehgal AD, Tweed DC, Gardner WJ, Foote MK. Laboratory studies after intrathecal corticosteroids: determination of corticosteroids in plasma and cerebrospinal fluid. *Arch Neurol.* 1963;9:64–68.
88. Schinkel AH, Mayer U, Wagenaar E, et al. Normal viability and altered pharmacokinetics in mice lacking mdr1-type (drug-transporting) P-glycoproteins. *Proc Natl Acad Sci USA.* 1997;94:4028–4033.
89. Furman MB, Giovanniello MT, O'Brien EM. Incidence of intravascular penetration in transforaminal cervical epidural steroid injections. *Spine.* 2003;28:21–25.
90. Rijsdijk M, van Wijck AJ, Kalkman CJ, Yaksh TL. The effects of glucocorticoids on neuropathic pain: a review with emphasis on intrathecal methylprednisolone acetate delivery. *Anesth Analg.* 2014;118:1097–1112.
91. Okubadejo GO, Talcott MR, Schmidt RE, et al. Perils of intravascular methylprednisolone injection into the vertebral artery. An animal study. *J Bone Joint Surg Am.* 2008;90:1932–1938.
92. Dullerud R, Morland TJ. Adhesive arachnoiditis after lumbar radiculography with Dimer-X and Depo-Medrol. *Radiology.* 1976;119:153–155.
93. Duchesneau P, Weinstein M, Wesolowski D. Lumbar arachnoiditis: long term effects of intrathecal Depo-Medrol (presented at annual meeting ASNR, New Orleans, Louisiana). *Neuroradiology.* 1978;15:244.
94. Abel R Jr, Nelson DA, Bernat JL. Complications from methylprednisolone acetate (Depo-Medrol) when injected into the orbit, subarachnoid, or subdural spaces. *Del Med J.* 1977;49:331–343.
95. Rijsdijk M, van Wijck AJ, Kalkman CJ, et al. Safety assessment and pharmacokinetics of intrathecal methylprednisolone acetate in dogs. *Anesthesiology.* 2012;116:170–181.
96. Latham JM, Fraser RD, Moore RJ, Blumbergs PC, Bogduk N. The pathologic effects of intrathecal betamethasone. *Spine (Phila Pa 1976).* 1997;22:1558–1562.
97. Lima RM, Navarro LH, Carness JM, et al. Clinical and histological effects of the intrathecal administration of methylprednisolone in dogs. *Pain Physician.* 2010;13:493–501.
98. Beal MF. Neuroprotective effects of creatine. *Amino Acids.* 2011;40:1305–1313.
99. Craig DB, Habib GG. Flaccid paraparesis following obstetrical epidural anesthesia: possible role of benzyl alcohol. *Anesth Analg.* 1977;56:219–221.
100. Cicala RS, Turner R, Moran E, Henley R, Wong R, Evans J. Methylprednisolone acetate does not cause inflammatory changes in the epidural space. *Anesthesiology.* 1990;72:556–558.
101. Schneider BJ, McCormick ZL, Smith CC, Spine Intervention Society's Patient Safety Committee. Particulate or nonparticulate steroids for lumbar transforaminal injections. *Pain Med.* 2017;18:1817–1818.
102. Delattre JY, Arbit E, Rosenblum MK, et al. High dose versus low dose dexamethasone in experimental epidural spinal cord compression. *Neurosurgery.* 1988;22:1005–1007.
103. Devor M, Govrin-Lippmann R, Raber P. Corticosteroids suppress ectopic neural discharge originating in experimental neuromas. *Pain.* 1985;22:127–137.

104. Williams BA, Hough KA, Tsui BY, Ibinson JW, Gold MS, Gebhart GF. Neurotoxicity of adjuvants used in perineural anesthesia and analgesia in comparison with ropivacaine. *Reg Anesth Pain Med.* 2011;36:225–230.
105. Williams BA, Butt MT, Zeller JR, Coffee S, Pippi MA. Multimodal perineural analgesia with combined bupivacaine-clonidine-buprenorphine-dexamethasone: safe in vivo and chemically compatible in solution. *Pain Med.* 2015;16:186–198.
106. Min SH, Soh JS, Park JY, et al. Epidural dexamethasone decreased inflammatory hyperalgesia and spinal cPLA(2) expression in a rat formalin test. *Yonsei Med J.* 2014;55:1631–1639.
107. Tian F, Dou C, Qi S, et al. Preventive effect of dexamethasone gelatin sponge on the lumbosacral epidural adhesion. *Int J Clin Exp Med.* 2015;8:5478–5484.
108. Wu GJ, Wen ZH, Chen WF, Chang YC, Cherng CH, Wong CS. The effect of dexamethasone on spinal glutamine synthetase and glutamate dehydrogenase expression in morphine-tolerant rats. *Anesth Analg.* 2007;104:726–730.
109. Kwicien J, Jarosz B, Urdzikova LM, Rola R, Dabrowski W. Subdural infusion of dexamethasone inhibits leukomyelitis after acute spinal cord injury in a rat model. *Folia Neuropathol.* 2015;53:41–51.
110. Wang S, Lim G, Zeng Q, Sung B, Yang L, Mao J. Central glucocorticoid receptors modulate the expression and function of spinal NMDA receptors after peripheral nerve injury. *J Neurosci.* 2005;25:488–495.
111. Takasaki I, Kurihara T, Saegusa H, Zong S, Tanabe T. Effects of glucocorticoid receptor antagonists on allodynia and hyperalgesia in mouse model of neuropathic pain. *Eur J Pharmacol.* 2005;524:80–83.
112. Abram SE. Treatment of lumbosacral radiculopathy with epidural steroids. *Anesthesiology.* 1999;91:1937–1941.
113. Ildirim I, Furcolow ML, Vandiviere HM. A possible explanation of posttreatment convulsions associated with intrathecal corticosteroids. *Neurology.* 1970;20:622–625.
114. Oppelt WW, Rall DP. Production of convulsions in the dog with intrathecal corticosteroids. *Neurology.* 1961;11:925–927.
115. Kroin JS, Schaefer RB, Penn RD. Chronic intrathecal administration of dexamethasone sodium phosphate: pharmacokinetics and neurotoxicity in an animal model. *Neurosurgery.* 2000;46:178–182.
116. Bani-Hashem N, Hassan-Nasab B, Pour EA, Maleh PA, Nabavi A, Jabbari A. Addition of intrathecal dexamethasone to bupivacaine for spinal anesthesia in orthopedic surgery. *Saudi J Anaesth.* 2011;5:382–386.
117. Wang YL, Tan PP, Yang CH, Tsai SC, Chung HS. Epidural dexamethasone reduces the incidence of backache after lumbar epidural anesthesia. *Anesth Analg.* 1997;84:376–378.
118. Kim EM, Lee JR, Koo BN, Im YJ, Oh HJ, Lee JH. Analgesic efficacy of caudal dexamethasone combined with ropivacaine in children undergoing orchiopexy. *Br J Anaesth.* 2014;112:885–891.
119. Thomas S, Beevi S. Epidural dexamethasone reduces postoperative pain and analgesic requirements. *Can J Anaesth.* 2006;53:899–905.
120. El Abd O, Amadera JE, Pimentel DC, Gomba L. Immediate and acute adverse effects following transforaminal epidural steroid injections with dexamethasone. *Pain Physician.* 2015;18:277–286.
121. Kim CH, Issa MA, Vaglianti RM. Flushing following interlaminar lumbar epidural steroid injection with dexamethasone. *Pain Physician.* 2010;13:481–484.
122. Maillefert JF, Aho S, Huguenin MC, et al. Systemic effects of epidural dexamethasone injections. *Rev Rhum Engl Ed.* 1995;62:429–432.
123. Gharibo CG, Fakhry M, Diwan S, Kaye AD. Conus medullaris infarction after a right L4 transforaminal epidural steroid injection using dexamethasone. *Pain Physician.* 2016;19:E1211–E1214.
124. Shakir A, Ma V, Mehta B. Comparison of pain score reduction using triamcinolone vs. dexamethasone in cervical transforaminal epidural steroid injections. *Am J Phys Med Rehabil.* 2013;92:768–775.
125. Lee JW, Park KW, Chung SK, et al. Cervical transforaminal epidural steroid injection for the management of cervical radiculopathy: a comparative study of particulate versus non-particulate steroids. *Skel Radiol.* 2009;38:1077–1082.
126. Dreyfuss P, Baker R, Bogduk N. Comparative effectiveness of cervical transforaminal injections with particulate and nonparticulate corticosteroid preparations for cervical radicular pain. *Pain Med.* 2006;7:237–242.
127. Kim D, Brown J. Efficacy and safety of lumbar epidural dexamethasone versus methylprednisolone in the treatment of lumbar radiculopathy: a comparison of soluble versus particulate steroids. *Clin J Pain.* 2011;27:518–522.
128. O'Donnell C, Cano W, D'Eramo G. Comparison of triamcinolone to dexamethasone in the treatment of low back and leg pain via lumbar transforaminal epidural steroid injection. *Spine J.* 2008;8:65S.
129. Park CH, Lee SH, Kim BI. Comparison of the effectiveness of lumbar transforaminal epidural injection with particulate and nonparticulate corticosteroids in lumbar radiating pain. *Pain Med.* 2010;11:1654–1658.
130. El-Yahchouchi C, Geske JR, Carter RE, et al. The noninferiority of the nonparticulate steroid dexamethasone vs the particulate steroids betamethasone and triamcinolone in lumbar transforaminal epidural steroid injections. *Pain Med.* 2013;14:1650–1657.
131. Kennedy DJ, Plastaras C, Casey E, et al. Comparative effectiveness of lumbar transforaminal epidural steroid injections with particulate versus nonparticulate corticosteroids for lumbar radicular pain due to intervertebral disc herniation: a prospective, randomized, double-blind trial. *Pain Med.* 2014;15:548–555.
132. Denis I, Claveau G, Filiatrault M, Fugere F, Fortin L. Randomized double-blind controlled trial comparing the effectiveness of lumbar transforaminal epidural injections of

- particulate and nonparticulate corticosteroids for lumbosacral radicular pain. *Pain Med.* 2015;16:1697–1708.
133. Datta R, Upadhyay B. A randomized clinical trial of three different steroid agents for treatment of low backache through the caudal route. *Med J Armed Forces India.* 2011;67:25–33.
134. Chou R, Hashimoto R, Friedly J, et al. *Pain Management Injection Therapies for Low Back Pain.* Rockville, MD: AHRQ Technology Assessments; 2015.
135. Chou R, Hashimoto R, Friedly J, et al. Epidural corticosteroid injections for radiculopathy and spinal stenosis: a systematic review and meta-analysis. *Ann Intern Med.* 2015;163:373–381.
136. Benyamin RM, Singh V, Parr AT, Conn A, Diwan S, Abdi S. Systematic review of the effectiveness of cervical epidurals in the management of chronic neck pain. *Pain Physician.* 2009;12:137–157.
137. Manchikanti L, Nampiaparampil DE, Candido KD, et al. Do cervical epidural injections provide long-term relief in neck and upper extremity pain? A systematic review. *Pain Physician.* 2015;18:39–60.
138. Stout A. Epidural steroid injections for cervical radiculopathy. *Phys Med Rehabil Clin North Am.* 2011;22:149–159.
139. Carragee EJ, Hurwitz EL, Cheng I, et al. Treatment of neck pain: injections and surgical interventions: results of the Bone and Joint Decade 2000–2010 Task Force on Neck Pain and Its Associated Disorders. *Spine.* 2008;33:S153–S169.
140. Staal JB, de Bie R, de Vet HC, Hildebrandt J, Nelemans P. Injection therapy for subacute and chronic low-back pain. *Cochrane Database Syst Rev.* 2008:CD001824.
141. Abdi S, Datta S, Trescot AM, et al. Epidural steroids in the management of chronic spinal pain: a systematic review. *Pain Physician.* 2007;10:185–212.
142. Staal JB, de Bie RA, de Vet HC, Hildebrandt J, Nelemans P. Injection therapy for subacute and chronic low back pain: an updated Cochrane review. *Spine.* 2009;34:49–59.
143. Roberts ST, Willick SE, Rho ME, Rittenberg JD. Efficacy of lumbosacral transforaminal epidural steroid injections: a systematic review. *PM&R.* 2009;1:657–668.
144. Berliner E. Multisociety letter to the Agency for Healthcare Research and Quality: serious methodological flaws plague technology assessment on pain management injection therapies for low back pain. *Pain Med.* 2016;17:10–15.
145. Pinto RZ, Maher CG, Ferreira ML, et al. Epidural corticosteroid injections in the management of sciatica: a systematic review and meta-analysis. *Ann Intern Med.* 2012;157:865–877.
146. Riew KD, Yin Y, Gilula L, et al. The effect of nerve-root injections on the need for operative treatment of lumbar radicular pain. A prospective, randomized, controlled, double-blind study. *J Bone Joint Surg Am.* 2000;82-A:1589–1593.
147. Karppinen J, Malmivaara A, Tervonen O, et al. Severity of symptoms and signs in relation to magnetic resonance imaging findings among sciatic patients. *Spine.* 2001;26:E149–E154.
148. Wang JC, Lin E, Brodke DS, Youssef JA. Epidural injections for the treatment of symptomatic lumbar herniated discs. *J Spinal Disord Tech.* 2002;15:269–272.
149. Ghahreman A, Ferch R, Bogduk N. The efficacy of transforaminal injection of steroids for the treatment of lumbar radicular pain. *Pain Med.* 2010;11:1149–1168.
150. Manson NA, McKeon MD, Abraham EP. Transforaminal epidural steroid injections prevent the need for surgery in patients with sciatica secondary to lumbar disc herniation: a retrospective case series. *Can J Surg.* 2013;56:89–96.
151. Bicket MC, Horowitz JM, Benzoni HT, Cohen SP. Epidural injections in prevention of surgery for spinal pain: systematic review and meta-analysis of randomized controlled trials. *Spine J.* 2015;15:348–362.
152. van Helvoirt H, Apeldoorn AT, Ostelo RW, et al. Transforaminal epidural steroid injections followed by mechanical diagnosis and therapy to prevent surgery for lumbar disc herniation. *Pain Med.* 2014;15:1100–1108.
153. Peul WC, Brand R, Thomeer RT, Koes BW. Influence of gender and other prognostic factors on outcome of sciatica. *Pain.* 2008;138:180–191.
154. Peul WC, van den Hout WB, Brand R, Thomeer RT, Koes BW. Prolonged conservative care versus early surgery in patients with sciatica caused by lumbar disc herniation: two year results of a randomised controlled trial. *BMJ.* 2008;336:1355–1358.
155. Shriver MF, Xie JJ, Tye EY, et al. Lumbar microdiscectomy complication rates: a systematic review and meta-analysis. *Neurosurg Focus.* 2015;39:E6.
156. Smith JS, Saulle D, Chen CJ, et al. Rates and causes of mortality associated with spine surgery based on 108,419 procedures: a review of the Scoliosis Research Society Morbidity and Mortality Database. *Spine (Phila Pa 1976).* 2012;37:1975–1982.
157. Peul WC, van Houwelingen HC, van den Hout WB, et al. Surgery versus prolonged conservative treatment for sciatica. *N Engl J Med.* 2007;356:2245–2256.
158. Jacobs WC, van Tulder M, Arts M, et al. Surgery versus conservative management of sciatica due to a lumbar herniated disc: a systematic review. *Eur Spine J.* 2011;20:513–522.
159. Deyo RA, Mirza SK. Clinical practice. Herniated lumbar intervertebral disk. *N Engl J Med.* 2016;374:1763–1772.
160. Goldberg H, Firtch W, Tyburski M, et al. Oral steroids for acute radiculopathy due to a herniated lumbar disk: a randomized clinical trial. *JAMA.* 2015;313:1915–1923.
161. Dahm KT, Brurberg KG, Jamtvedt G, Hagen KB. Advice to rest in bed versus advice to stay active for acute low-back pain and sciatica. *Cochrane Database Syst Rev.* 2010:CD007612.
162. Riew KD, Park JB, Cho YS, et al. Nerve root blocks in the treatment of lumbar radicular pain. A minimum five-year follow-up. *J Bone Joint Surg Am.* 2006;88:1722–1725.

163. Spijker-Huiges A, Vermeulen K, Winters JC, van Wijhe M, van der Meer K. Costs and cost-effectiveness of epidural steroids for acute lumbosacral radicular syndrome in general practice: an economic evaluation alongside a pragmatic randomized control trial. *Spine (Phila Pa 1976)*. 2014;39:2007–2012.
164. Fitzsimmons D, Phillips CJ, Bennett H, et al. Cost-effectiveness of different strategies to manage patients with sciatica. *Pain*. 2014;155:1318–1327.
165. Bernstein IA, Malik Q, Carville S, Ward S. Low back pain and sciatica: summary of NICE guidance. *BMJ*. 2017;356:i6748.
166. Anderberg L, Annertz M, Persson L, Brandt L, Saveland H. Transforaminal steroid injections for the treatment of cervical radiculopathy: a prospective and randomised study. *Eur Spine J*. 2007;16:321–328.
167. Engel A, King W, Macvicar J. The effectiveness and risks of fluoroscopically guided cervical transforaminal injections of steroids: a systematic review with comprehensive analysis of the published data. *Pain Med*. 2013;2014:15.
168. Candido KD, Raghavendra MS, Chinthagada M, Badiee S, Trepashko DW. A prospective evaluation of iodinated contrast flow patterns with fluoroscopically guided lumbar epidural steroid injections: the lateral parasagittal interlaminar epidural approach versus the transforaminal epidural approach. *Anesth Analg*. 2008;106:638–644.
169. Kolsi I, Delecrin J, Berthelot JM, Thomas L, Prost A, Maugars Y. Efficacy of nerve root versus interspinous injections of glucocorticoids in the treatment of disk-related sciatica. A pilot, prospective, randomized, double-blind study. *Joint Bone Spine*. 2000;67:113–118.
170. Chang-Chien GC, Knezevic NN, McCormick Z, Chu SK, Trescot AM, Candido KD. Transforaminal versus interlaminar approaches to epidural steroid injections: a systematic review of comparative studies for lumbosacral radicular pain. *Pain Physician*. 2014;17:E509–E524.
171. Goodman BS, Posecion LW, Mallempati S, Bayazitoglu M. Complications and pitfalls of lumbar interlaminar and transforaminal epidural injections. *Curr Rev Musculoskel Med*. 2008;1:212–222.
172. Botwin KP, Natalicchio J, Hanna A. Fluoroscopic guided lumbar interlaminar epidural injections: a prospective evaluation of epidurography contrast patterns and anatomical review of the epidural space. *Pain Physician*. 2004;7:77–80.
173. Murthy NS, Maus TP, Behrns CL. Intraforaminal location of the great anterior radiculomedullary artery (artery of Adamkiewicz): a retrospective review. *Pain Med*. 2010;11:1756–1764.
174. Kambin P. Arthroscopic microdiscectomy. *Mt Sinai J Med*. 1991;58:159–164.
175. Kambin P, Savitz MH. Arthroscopic microdiscectomy: an alternative to open disc surgery. *Mt Sinai J Med*. 2000;67:283–287.
176. Levi D, Horn S, Corcoran S. The incidence of intradiscal, intrathecal, and intravascular flow during the performance of retrodiscal (infraneural) approach for lumbar transforaminal epidural steroid injections. *Pain Med*. 2016;17:1416–1422.
177. Bogduk N. *Practice Guidelines for Spinal Diagnostic and Treatment Procedures*. San Francisco, CA: International Spine Intervention Society; 2013.
178. Nagpal AS, Chang-Chien GC, Benfield JA, Candido KD, Rana MV, Eckmann M. Digital subtraction angiography use during epidural steroid injections does not reliably distinguish artery from vein. *Pain Physician*. 2016;19:255–266.
179. Owlia MB, Salimzadeh A, Alishiri G, Haghghi A. Comparison of two doses of corticosteroid in epidural steroid injection for lumbar radicular pain. *Singapore Med J*. 2007;48:241–245.
180. Karppinen J, Ohinmaa A, Malmivaara A, et al. Cost effectiveness of periradicular infiltration for sciatica: subgroup analysis of a randomized controlled trial. *Spine*. 2001;26:2587–2595.
181. Kang SS, Hwang BM, Son HJ, et al. The dosages of corticosteroid in transforaminal epidural steroid injections for lumbar radicular pain due to a herniated disc. *Pain Physician*. 2011;14:361–370.
182. Bicket MC, Gupta A, Brown CHT, Cohen SP. Epidural injections for spinal pain: a systematic review and meta-analysis evaluating the “control” injections in randomized controlled trials. *Anesthesiology*. 2013;119:907–931.
183. Hopwood MB, Abram SE. Factors associated with failure of lumbar epidural steroids. *Reg Anesth*. 1993;18:238–243.
184. Jeong HS, Lee JW, Kim SH, Myung JS, Kim JH, Kang HS. Effectiveness of transforaminal epidural steroid injection by using a preganglionic approach: a prospective randomized controlled study. *Radiology*. 2007;245:584–590.
185. Cyteval C, Fescquet N, Thomas E, Decoux E, Blotman F, Taourel P. Predictive factors of efficacy of periradicular corticosteroid injections for lumbar radiculopathy. *Am J Neuroradiol*. 2006;27:978–982.
186. Kaufmann TJ, Geske JR, Murthy NS, et al. Clinical effectiveness of single lumbar transforaminal epidural steroid injections. *Pain Med*. 2013;14:1126–1133.
187. Murthy NS, Geske JR, Shelerud RA, et al. The effectiveness of repeat lumbar transforaminal epidural steroid injections. *Pain Med*. 2014;15:1686–1694.
188. Goel A. Meralgia paresthetica secondary to limb length discrepancy: case report. *Arch Phys Med Rehabil*. 1999;80:348–349.
189. Aldrete JA, Vascello LA, Ghaly R, Tomlin D. Paraplegia in a patient with an intrathecal catheter and a spinal cord stimulator. *Anesthesiology*. 1994;81:1542–1545; discussion 1527A–1528A.
190. Rabinovitch DL, Peliowski A, Furlan AD. Influence of lumbar epidural injection volume on pain relief for radicular leg pain and/or low back pain. *Spine J*. 2009;9:509–517.
191. Furman MB, Mehta AR, Kim RE, et al. Injectate volumes needed to reach specific landmarks in lumbar transforaminal epidural injections. *PM&R*. 2010;2:625–635.
192. Byun JM, Park HS, Woo JH, Kim J. The effects of a forceful transforaminal epidural steroid injection on radicular pain: a preliminary study. *Korean J Pain*. 2014;27:334–338.

193. Rydevik B, Brown MD, Lundborg G. Pathoanatomy and pathophysiology of nerve root compression. *Spine*. 1984;9:7–15.
194. Kobayashi S, Shizu N, Suzuki Y, Asai T, Yoshizawa H. Changes in nerve root motion and intradiscal blood flow during an intraoperative straight-leg-raising test. *Spine (Phila Pa 1976)*. 2003;28:1427–1434.
195. Hong J, Jung S, Chang H. Whitacre needle reduces the incidence of intravascular uptake in lumbar transforaminal epidural steroid injections. *Pain Physician*. 2015;18:325–331.
196. Smuck M, Paulus S, Patel A, Demirjian R, Ith MA, Kennedy DJ. Differential rates of inadvertent intravascular injection during lumbar transforaminal epidural injections using blunt-tip, pencil-point, and catheter-extension needles. *Pain Med*. 2015;16:2084–2089.
197. Baker R, Dreyfuss P, Mercer S, Bogduk N. Cervical transforaminal injection of corticosteroids into a radicular artery: a possible mechanism for spinal cord injury. *Pain*. 2003;103:211–215.
198. Derby R. Point of view: cervical epidural steroid injection with intrinsic spinal cord damage: two case reports. *Spine*. 1998;23:2141–2142.
199. Neal JM, Bernardis CM, Hadzic A, et al. ASRA practice advisory on neurologic complications in regional anesthesia and pain medicine. *Reg Anesth Pain Med*. 2008;33:404–415.
200. Goel A, Pollan JJ. Contrast flow characteristics in the cervical epidural space: an analysis of cervical epidurograms. *Spine (Phila Pa 1976)*. 2006;31:1576–1579.
201. Stojanovic M, Vu T, Caneris O. The role of fluoroscopy in cervical epidural steroid injections: an analysis of epidurograms. *Spine*. 2002;27:509–514.
202. Lirk P, Kolbitsch C, Putz G, et al. Cervical and high thoracic ligamentum flavum frequently fails to fuse in the midline. *Anesthesiology*. 2003;99:1387–1390.
203. Abbasi A, Malhotra G. The, “swimmer’s view” as alternative when lateral view is inadequate during interlaminar cervical epidural steroid injections. *Pain Med*. 2010;11:709–712.
204. Moon JY, Lee PB, Nahm FS, Kim YC, Choi JB. Cervical epidural pressure measurement: comparison in the prone and sitting positions. *Anesthesiology*. 2010;113:666–671.
205. Gil NS, Lee JH, Yoon SZ, Jeon Y, Lim YJ, Bahk JH. Comparison of thoracic epidural pressure in the sitting and lateral decubitus positions. *Anesthesiology*. 2008;109:67–71.
206. Field J, Rathmell JP, Stephenson JH, Katz NP. Neuropathic pain following cervical epidural steroid injection. *Anesthesiology*. 2000;93:885–888.
207. Stretanski MF, Chopko B. Unintentional vascular uptake in fluoroscopically guided, contrast-confirmed spinal injections: a 1-yr clinical experience and discussion of findings. *Am J Phys Med Rehabil*. 2005;84:30–35.
208. Furman MB, O’Brien EM, Zgleszewski TM. Incidence of intravascular penetration in transforaminal lumbosacral epidural steroid injections. *Spine (Phila Pa 1976)*. 2000;25:2628–2632.
209. Hong JH, Lee YH. Comparison of incidence of intravascular injections during transforaminal epidural steroid injection using different needle types. *Korean J Anesthesiol*. 2014;67:193–197.
210. White AH. Injection techniques for the diagnosis and treatment of low back pain. *Orthop Clin North Am*. 1983;14:553–567.
211. Bartynski WS, Grahovac SZ, Rothfus WE. Incorrect needle position during lumbar epidural steroid administration: inaccuracy of loss of air pressure resistance and requirement of fluoroscopy and epidurography during needle insertion. *Am J Neuroradiol*. 2005;26:502–505.
212. Manchikanti L, Cash KA, Pampati V, Damron KS, McManus CD. Evaluation of lumbar transforaminal epidural injections with needle placement and contrast flow patterns: a prospective, descriptive report. *Pain Physician*. 2004;7:217–223.
213. McLean JP, Sigler JD, Plastaras CT, Garvan CW, Rittenberg JD. The rate of detection of intravascular injection in cervical transforaminal epidural steroid injections with and without digital subtraction angiography. *PM&R*. 2009;1:636–642.
214. Candido KD, Knezevic N. Cervical epidural steroid injections for the treatment of cervical spinal (neck) pain. *Curr Pain Headache Rep*. 2013;17:314.
215. Fitzgerald RT, Bartynski WS, Collins HR. Vertebral artery position in the setting of cervical degenerative disease: implications for selective cervical transforaminal epidural injections. *Interv Neuroradiol*. 2013;19:425–431.
216. Smuck M, Maxwell MD, Kennedy D, Rittenberg JD, Lansberg MG, Plastaras CT. Utility of the anesthetic test dose to avoid catastrophic injury during cervical transforaminal epidural injections. *Spine J*. 2010;10:857–864.
217. Chang Chien G. Spinal epidural hematoma resulting in tetraplegia after cervical interlaminar epidural steroid injection and intramuscular ketorolac: a case report. *Phys Med Rehabil*. 2012;4/10:S320.
218. Camorcica M, Capogna G, Columb MO. Estimation of the minimum motor blocking potency ratio for intrathecal bupivacaine and lidocaine. *Int J Obstet Anesth*. 2008;17:223–227.
219. Kim WJ, Park HG, Park YH, Shin MR, Koo GH, Shin HY. Pneumocephalus during cervical transforaminal epidural steroid injections: a case report. *Am J Phys Med Rehabil*. 2015;94:63–69.
220. British Pain Society and Faculty of Pain Medicine of the Royal College of Anaesthetists. Standards of good practice for spinal interventional procedures in pain medicine. In: The British Pain Society, ed. *Standards of Good Practice*. London: The British Pain Society; 2015:4–19.
221. Willems PC, Jacobs W, Duinkerke ES, De Kleuver M. Lumbar discography: should we use prophylactic antibiotics? A study of 435 consecutive discograms and a systematic review of the literature. *J Spinal Disord Tech*. 2004;17:243–247.

222. Kapoor SG, Huff J, Cohen SP. Systematic review of the incidence of discitis after cervical discography. *Spine J.* 2010;10:739–745.
223. Faculty of Pain Medicine of the Royal College of Anaesthetists. *Recommendations for Good Practice in the Use of Epidural Injection for the Management of Pain of Spinal Origin in Adults*. London: Association of Anaesthetists of Great Britain and Ireland, and British Pain Society; 2011.
224. Werkgroep Infectie Preventie. [https://www.rivm.nl/Onderwerpen/W/Werkgroep\\_Infectie\\_Preventie\\_WIP/WIP\\_Richtlijnen/Ziekenhuizen\\_ZKH2011](https://www.rivm.nl/Onderwerpen/W/Werkgroep_Infectie_Preventie_WIP/WIP_Richtlijnen/Ziekenhuizen_ZKH2011) (accessed 12, January 2016).
225. Narouze S, Benzon HT, Provenzano D, et al. Interventional spine and pain procedures in patients on antiplatelet and anticoagulant medications (second edition): guidelines from the American Society of Regional Anesthesia and Pain Medicine, the European Society of Regional Anaesthesia and Pain Therapy, the American Academy of Pain Medicine, the International Neuromodulation Society, the North American Neuromodulation Society, and the World Institute of Pain. *Reg Anesth Pain Med.* 2018;43:225–262.
226. Tackla RD, Keller JT, Ernst RJ, Farley CW, Bohinski RJ. Conus medullaris syndrome after epidural steroid injection: case report. *Int J Spine Surg.* 2012;6:29–33.
227. Bateman BT, Mhyre JM, Ehrenfeld J, et al. The risk and outcomes of epidural hematomas after perioperative and obstetric epidural catheterization: a report from the Multicenter Perioperative Outcomes Group Research Consortium. *Anesth Analg.* 2013;116:1380–1385.
228. National Institutes of Health. *Arachnoiditis, National Institute of Neurological disorders and Stroke*. <https://www.ninds.nih.gov/Disorders/All-Disorders/Arachnoiditis-Information-Page> (accessed 8, January 2016).
229. Neal JM, Rathmell JP. *Complications in Regional Anesthesia and Pain Medicine*. 2nd. ed. Philadelphia: Lippincott Williams & Wilkins; 2013.