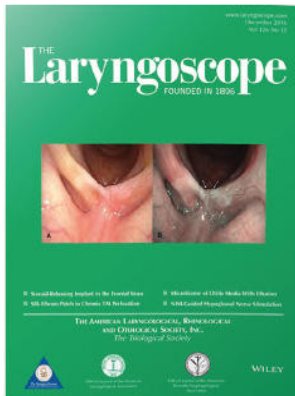



Premiere Publications from The Triological Society

Read all three of our prestigious publications, each offering high-quality content to keep you informed with the latest developments in the field.




THE Laryngoscope FOUNDED IN 1896

Editor-in-Chief: Michael G. Stewart, MD, MPH

The leading source for information in head and neck disorders.

Laryngoscope.com




Laryngoscope Investigative Otolaryngology Open Access

Editor-in-Chief: D. Bradley Welling, MD, PhD, FACS

Rapid dissemination of the science and practice of otolaryngology-head and neck surgery.

InvestigativeOto.com



ENTtoday A publication of the Triological Society



Editor-in-Chief: Alexander Chiu, MD

Must-have timely information that Otolaryngologist-head and neck surgeons can use in daily practice.

Enttoday.org

WILEY

Clinical Value of (Dedicated) 3 Tesla and 7 Tesla MRI for cT1 Glottic Carcinoma: A Feasibility Study

Sylvia L. van Egmond, MD ; Bernard M.D. Vonck, MD; Johanna J. Bluemink; Frank A. Pameijer, MD, PhD; Jan Willem Dankbaar, MD, PhD ; Inge Stegeman, PhD; Marielle E.P. Philippens, MD, PhD; Cornelis A.T. van den Berg, MD, PhD; Luuk M. Janssen, MD, PhD; Chris H. Terhaard, MD, PhD

Objective: To assess the feasibility of the clinical use of 3 Tesla and 7 Tesla Magnetic Resonance Imaging for early (cT1) glottic carcinoma, including structural assessment of technical image quality and visibility of the tumor; and if feasible, to correlate MRI findings to routine diagnostics.

Methods: Prospective feasibility study. Twenty patients with primary clinical T1 glottic carcinoma underwent both routine clinical staging and CT. In addition, a 3 T and 7 T MRI protocol, developed for small laryngeal lesions, was performed in a 4-point immobilization mask, using dedicated surface coils. Afterwards, routine endoscopic direct suspension laryngoscopy under general anaesthesia was performed.

Results: Only 2 of 7 (29%) of 7 T MRI scans were rated as moderate to good technical image quality. After exclusion of three patients with only mild to moderate dysplasia at the time of MRI, 13 of 17 (76%) of 3 T MRIs were of adequate technical image quality. Tumor visualization was adequate in 8 of 13 (62%) of patients with invasive squamous cell carcinomas. With exclusion of the four MRIs with motion artefacts, the tumor and its boundaries could be adequately seen in 8 of 9 (89%) patients with squamous cell carcinoma versus only one in four (25%) of patients with carcinoma in situ lesions.

Conclusions: 7 Tesla MRI was considered not feasible. 3 Tesla MRI, with adequate patient selection, namely clinical exclusion of patients with a history of claustrophobia and inclusion of only histologically proven invasive squamous cell carcinoma, can be feasible. Especially with further improvement of MR image quality.

Key Words: MRI, magnetic resonance imaging, 3 Tesla, 7 Tesla, early glottic cancer.

Level of Evidence: 2B, prospective diagnostic study

INTRODUCTION

Early stage squamous cell carcinoma (SCC) of the glottic larynx, treated by radiotherapy or endoscopic laser surgery, is characterized by a low tumor volume and rare incidence of regional or distant metastatic spread.^{1,2} Reported local control rates for both treatment modalities are equally high (71–95%), depending on invasion of the anterior commissure (AC).³ Therefore, the aim of treatment is to achieve local control with the best possible functional outcome. Topic of controversy remains which treatment modality results in tumor eradication with preservation of functions, especially when the cancer

involves the AC, involves the vocal muscle, or extends laterally in the laryngeal ventricle. The main factor that prohibits the systematic evaluation and pooling of data is the uncertainty of tumor comparability, due to an absence of a standardized method that accurately measures tumor extent and depth.

Both flexible laryngoscopy, videolaryngostroboscopy (VLS), and direct suspension laryngoscopy with an operating microscope can evaluate AC invasion, but no claims can be made about the extent of the tumor in depth, as well as submucosal intralaryngeal growth. Rates reported of correct staging of AC invasion vary between 40% to 72%.^{4,5} Visualization of early glottic tumors by computed tomography (CT) imaging can also be difficult due to small tumor size and volume and the poor soft tissue detail. Invasion of the AC is more difficult to detect. Diagnostic value of CT varies widely in literature with a reported accuracy of 83% to 86%,^{6,7} a sensitivity of 43% and a specificity of 83% when compared to histopathological results.⁵ However, these numbers account for all T1–T4 laryngeal tumors. No subanalysis was done for cT1 tumors only. False-positive results may be caused by difficulty to discriminate reactive inflammation and edema from tumor.⁸

A recent systematic review evaluating the diagnostic value of MRI for pre-therapeutic staging of early glottic cancer, showed that MRI data of T1 and T2 glottic carcinoma is limited, heterogeneous and based on subanalysis.⁹

This is an open access article under the terms of the Creative Commons Attribution-NonCommercial-NoDerivs License, which permits use and distribution in any medium, provided the original work is properly cited, the use is non-commercial and no modifications or adaptations are made.

From the Department of Otorhinolaryngology and Head & Neck Surgery (S.L.E.), Leiden University Medical Center, Leiden, The Netherlands; the Department of Otorhinolaryngology and Head & Neck Surgery (S.L.E., B.M.D.V., I.S.); Department of Radiotherapy (J.J.B., M.E.P.P., C.A.T.B., C.H.T.); Department of Radiology (F.A.P., J.W.D.); Rudolf Magnus Institute of Neuroscience (I.S.); and the Department of Head and Neck Surgical Oncology (L.M.J.), University Medical Center Utrecht, Utrecht, The Netherlands

The authors report no conflicts of interest or funding.

Send correspondence to S.L. van Egmond, Leiden University Medical Center, Department of Otorhinolaryngology and Head & Neck Surgery, Albinusdreef 2, 2333 ZA, Leiden, The Netherlands. Email: sylvianegmond@gmail.com

DOI: 10.1002/liv.2.246

Both slice thickness and the use of neck receive coils varied and was suboptimal for small laryngeal lesions.

7 T ultra-high field MRI has the potential to depict smaller lesions.^{10,11} In the head and neck region, the inner ear and the parotid gland and duct have been visualized with varying results.^{12,13} Up to now, no studies have been performed to assess the diagnostic value of 7 T for glottic carcinomas.

The primary goal of this study was to assess the feasibility of the clinical use of both an dedicated 3 T MRI protocol for small laryngeal lesions, and 7 T MRI of clinical T1 glottic carcinoma; Both (technical) image quality and tumor visibility were evaluated. Secondary goals were comparison of MRI data to routine diagnostics, including suspension laryngoscopy and computed tomography. And, in case of laser excision, verification of MRI with histopathological data.

MATERIALS AND METHODS

Ethical Considerations

This prospective feasibility study was approved by the local ethics committee and written informed consent was obtained from all patients included in the study.

Methods

Following flexible laryngoscopy and videolaryngostroboscopy at the Out Patients Department, patients were staged by two independent head and neck surgeons according to the International TNM classification for malignant glottic tumors.¹⁴ All patients with clinically staged T1 glottic carcinomas, referred to a tertiary referral center (Utrecht University Medical Center) between December 2014 and March 2017, were considered for this study. All patients had a histologically proven carcinoma in situ or invasive SCC of the vocal cord(s). We excluded patients with a history of previous glottic surgery, patients with previous radiation therapy for a head and neck carcinoma, patients with recurrence of glottic disease, patients with legal incapability or insufficient command of the Dutch language, or patients who did not pass MRI screening criteria. Videolaryngoscopy was recorded and saved and glottal closure, regularity, mucosal wave and symmetry were scored using a 4-point (0–3) grading scale by two ENT surgeons, specialized in head and neck oncology. Patients subsequently underwent CT, 3 Tesla MRI, and 7 Tesla MRI.

CT Imaging Protocol

All contrast enhanced CT studies were performed on a 128 detector-row scanner (Philips iCT, Cleveland, OH, USA). For the acquisition, first an injection of 90 ml of nonionic contrast material (Ultravist (Iopromide) 300 mg/ml, Bayer Healthcare, Whippany, NJ), at a rate of 4 ml/s followed by a 40-ml saline flush was given. Forty seconds after the first injection a second injection of 30 ml of contrast material and a 30-ml saline flush at a rate of 4 ml/s was given. A bolus triggered scan was started simultaneously with the second bolus with a locator in the descending aorta at a Hounsfield Units (HU) threshold of 170 with no scan delay. Acquisition was performed in axial plane during quiet breathing. Scanning parameters were: 128 x 0.625 mm collimation, 120 kVp, 143 mAs, a rotation time of 0.4 s, pitch of 0.914, 250 mm Field of View, and 512 x 512 matrix. Also, 3-mm axial, coronal and sagittal sections were reconstructed. The axial images were reconstructed parallel to the plane of the true vocal cords.

MR Imaging Protocol

To minimize movements of the head and neck region, 3 Tesla and 7 Tesla MRI were both performed using a 4-point immobilization mask for the head and neck region with individual head support, made prior to scanning at the Department of Radiotherapy. This mask is an adaption of the 5-point immobilization mask used for head and neck radiotherapy, covering the region from the chin to the shoulders. Its use is standard practice for MRI performed for patients who are scheduled for radiotherapy of the head and neck region at our center.¹⁵ Both MRI exams were performed with administration of 0.1 ml/kg single-dose intravenous contrast agent gadolinium (Gadovist) and 30-cc saline flush. Scans were angulated along the C3–C4 or C4–C5 disk space (ie, parallel to the plane of the true vocal cords).

The 3 T and 7 T protocol, optimized after a pilot study with healthy volunteers, consisted of planning scans, preparation scans to optimize the radiofrequency (RF) transmit field and for 7 T the magnetic field homogeneity in the region of interest and T1 and T2 weighted scans optimized in volunteers.

The 3 T and 7 T sequences (following the scans for planning and optimization of the RF and magnetic field homogeneity) are listed in Table I. For the 7 Tesla MRI exam, a dedicated transmit neck coil was used in the form of a dielectric waveguide.¹⁶ The weight of the dielectric bag filled with deuterated water was not sensed by the patient due to the stiffness of the mask material. Local receive coils were used to maximize the signal intensity obtained from the glottic area.¹⁷ The receive coils were placed on the mask, covering the region of the larynx. Prior to the study, a risk analysis was performed in cooperation with the Department of Medical Technology.

Diagnostic Evaluation

CT, 3 T MRI, and 7 T MRI scans were individually assessed for technical image quality and visibility of the tumor, scored with a 4-point Likert scale, by three independent researchers (two experienced head and neck radiologists and one experienced head and neck radiation oncologist), blinded for patient data. In a second joint meeting, in case of visible tumor, the tumor was delineated and location, tumor size (in mm), tumor volume and depth were assessed.

Following imaging, as part of standard clinical procedure, direct suspension laryngoscopy with a rigid endoscope was performed under general anaesthesia. Extent of the tumor was evaluated by visual examination through an operating microscope with a standard eye-to-object-distance of 400 mm and by palpation with microforceps. Images were recorded using a measuring tape (Fig. 1). Lesions were staged according to the international TNM (for Tumor, regional lymph Nodes, distant Metastasis) Classification of Malignant Tumors in T1a, T1b, or T2. Furthermore, appearance (exophytic growth pattern), length (in mm), expected depth invasion of the tumor (after palpation) and possible paraglottic or subglottic extension as well as involvement of the anterior commissure were reported. The decision for direct endoscopic excision with CO2 laser or radiotherapy was made during direct suspension laryngoscopy by the head and neck surgeon, independent of MRI (and CT) results. In general, lesions with involvement of the anterior commissure, lesions with paraglottic extension or patients in which tumor visualization was inadequate, were not considered suitable for laser resection. When endoscopic laser resection was performed, pathologic specimens were fixed with needles onto a standardized full-scale image of the larynx, to enable optimal structured histopathological evaluation of tumor margins. When considered unsuitable for endoscopic excision, Intensity Modulated Radiotherapy (IMRT) was commenced with a daily fraction of 2.4 Gy, 5 days/week, for 25 days, resulting in a total irradiation fraction dose of 60 Gy in 5 weeks.

TABLE I.
3 T and 7 T Scan Protocol Sequences.

Subsequent scan protocols	3 Tesla MRI				7 Tesla MRI		
	1	2	3	4	1	2	3
Sequence	3D T2W SE	3D T2W SE	MS T1W SE + and - Gado	3D T1W SE Gado	MS T2W SE	MS T1W SE + and - Gado	MS T1W SE + Gado
Orientation	Transverse	Transverse	Transverse	Sagittal	Transverse	Transverse	Sagittal
TE/TR (ms)	157/2225	235/2100	20/500	25/400	68/3500	37/800	37/700
TSE factor	80	145	3	20	11	8	8
Flip angle (degrees)	90	90	90	90	90	100	100
Refocusing angle (degrees)	40-120	25-120	*	40	80	90	90
Field of view (mm3)	160x160x34	160x160x39	160x160x44	160x160x44	140x140x35	140x140x35	140x140x50
No transverse slices	34	39	20	88	32	16	65 - C
Acquisition pixel size (m3)	0.5x0.5x1	1x1x1	0.6x0.6	1x1x0.5	0.5x0.5x1	0.4x0.4x2	0.7x0.7x0.7
Imaging matrix	320x318	160x158	272x270	160x160	280x275	348x346	200x200
NSA	2	2	2	2	2	2	2
Sense factor	1.9	1.9	2	2	1	2	2
Scan duration (minutes)	6	2	4	3	6	2.5	4

3 T = 3 Tesla; 7 T = 7 Tesla; C = coronal; MS = multislice; NSA = number of signal averages; TE/TR = echo time/repetition time; TSE = turbo spin echo.
*No refocusing control

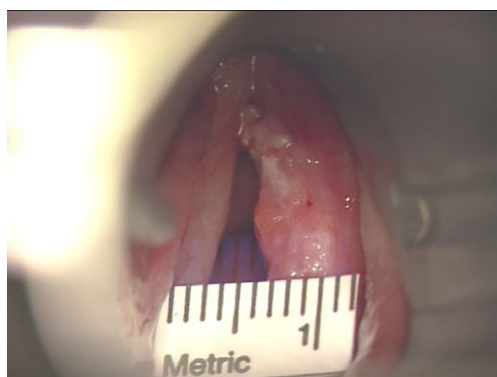


Fig. 1. Tumor was measured with a measuring tape during direct laryngoscopy

Statistics

Since direct laryngoscopy cannot be used as a reference standard and a pathology specimen was not available in each patient, no diagnostic accuracy measures could be calculated. Results will be descriptive.

RESULTS

Number of Scans

A flow diagram of all included patients and performed scans is shown in Figure 2. After 10 patients, we evaluated the scan quality of both 3 T and 7 T MRI and considered the 7 T MRI not feasible. Technical image quality was moderate to good in only one or two out of seven patients. As a result, the tumor was not adequately visible in 72% to 86% of the patients (Tables II and III). With these results, the clinical burden to undergo 7 T MRI for the remaining 10 patients to be included in the study could therefore not be justified. Therefore, the last 10 patients did not undergo 7 T scanning. In retrospect, two carcinoma in situ lesions and one SCC were excised during an

initial biopsy at the referral hospital. These three patients only had mild to moderate dysplasia during time of scanning and were excluded for evaluation. Therefore, 17 3 T MRIs and seven 7 T MRIs were included in our analysis.

Inter Observer Agreement

Assessment of MRI data by two radiologists and one radiation oncologist appeared to be heterogeneous. Intra-class correlation coefficient for image quality and tumor visibility for CT was 0.76 and 0.80. Intra-class correlation coefficient for image quality and tumor visibility for 3 Tesla MRI was 0.86 and 0.91. When classified as "acceptable" (moderate or good) or "unacceptable" (bad or poor), a higher degree of inter observer agreement was reached.

Histopathological Results

Five out of 17 tumors were considered suitable for endoscopic laser resection. Four tumors were excised, one was evaporated. Tumor diameters could only be assessed in the four excision histopathological specimens. A total of 12 patients received radiotherapy.

Technical Image Quality of CT and MRI

Data following exclusion of three patients with only mild/moderate dysplasia are presented in Table II. Ninety-four percent to 100%, 76%, and 14% to 29% of CT, 3 T MRI, and 7 T MRI scans were rated as moderate to good technical image quality, respectively.

Tumor Visibility of CT and MRI

Data are presented in Table III. In 30% to 59%, 47% to 53% and 14% to 29% of CT, 3 T MRI, and 7 T MRI, respectively, the tumor and boundaries could be identified.

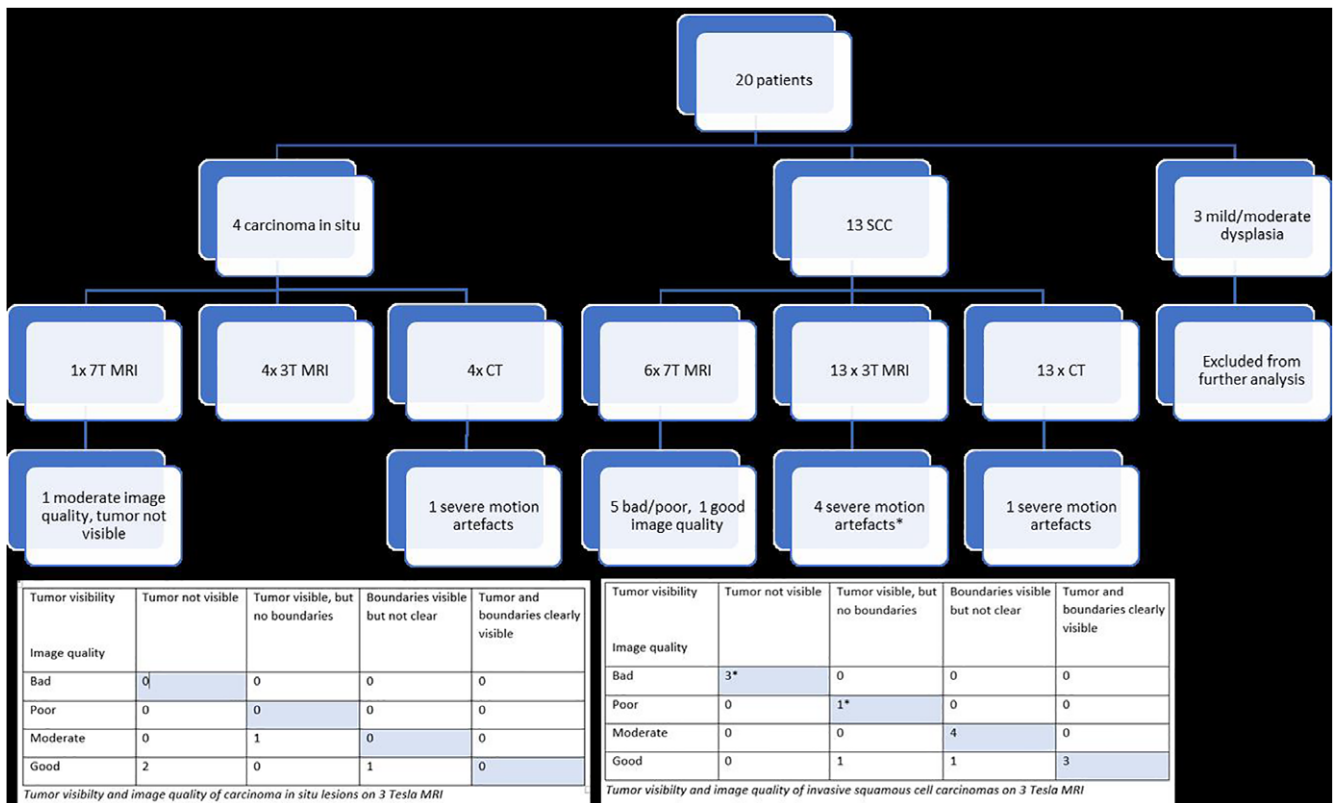


Fig. 2. Flow diagram of included patients, number of scans, scan quality, and tumor visibility

TABLE II.
Assessment of Image Quality by Three Independent Observers, Blinded for Clinical Data.

Image quality	CT			3 Tesla MRI			7 Tesla MRI		
	R1	R2	R3	R1	R2	R3	R1	R2	R3
Bad	1 (6%)	0	0	3 (18%)	1(6%)	1 (6%)	3 (43%)	1 (14%)	4 (57%)
Poor	0	0	1 (6%)	1 (6%)	3 (18%)	3 (18%)	2 (29%)	4 (57%)	2 (29%)
Moderate	0	2 (12%)	10 (59%)	5 (29%)	8 (47%)	3 (18%)	1 (14%)	1 (14%)	0
Good	16 (94%)	15 (88%)	6 (35%)	8 (47%)	5 (29%)	10 (59%)	1 (14%)	1 (14%)	1 (14%)
Total	17	17	17	17	17	17	7	7	7

CT = computed tomography; MRI = magnetic resonance imaging; R1 = radiologist 1 (FP); R2 = radiologist 2 (JD); R3 = radiation oncologist (CT).

TABLE III.
Assessment of Image Quality by Three Independent Observers, Blinded for Clinical Data.

Tumor visibility	CT			3 Tesla MRI			7 Tesla MRI		
	R1	R2	R3	R1	R2	R3	R1	R2	R3
Tumor not visible	4 (24%)	4 (24%)	7 (41%)	5 (29%)	5 (29%)	5 (29%)	5 (72%)	2 (29%)	5 (72%)
Tumor visible, but not the tumor boundaries	3 (18%)	3 (18%)	5 (29%)	3 (18%)	4 (24%)	4 (24%)	1 (14%)	3 (43%)	1 (14%)
Tumor boundaries visible, but not clear	6 (35%)	2 (12%)	2 (12%)	6 (35%)	5 (29%)	3 (18%)	0	1 (14%)	0
Both tumor and boundaries clearly visible	4 (24%)	8 (47%)	3 (18%)	3 (18%)	3 (18%)	5 (29%)	1 (14%)	1 (14%)	1 (14%)
Total	17	17	17	17	17	17	7	7	7

CT = computed tomography; MRI = magnetic resonance imaging; R1 = radiologist 1 (FP); R2 = radiologist 2 (JD); R3 = radiation oncologist (CT).

One of the patients with the best quality on 3 T MRI and 7 T MRI is shown in Figure 3. CT and a clinical image during suspension laryngoscopy shows a comparable lesion

of the left anterior vocal cord. This tumor was clinically scored as a T1b tumor, with involvement of the anterior commissure. In this case, radiotherapy was performed.

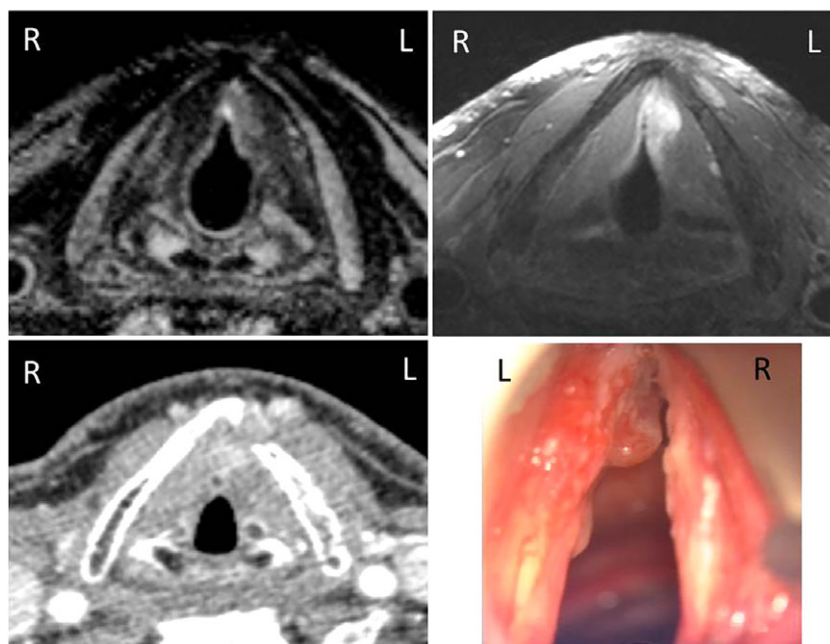


Fig. 3. Axial images at the mid glottic level showing a lesion on the anterior half of the left true vocal cord with extension to the anterior commissure (arrows). On CT the lesion is isointense to the vocal cord and therefore difficult to see. 3 T MRI (a), 7 T MRI (b), contrast enhanced CT (c) and clinical photo during suspension laryngoscopy (d) of the same study patient. 3 T = 3 Tesla; 7 T = 7 Tesla; CT = computed tomography; MRI = magnetic resonance imaging.

Findings could therefore not be related to histopathological results.

Relation Between Image Quality, Tumor Visibility, and Tumor Dimensions in Subgroups of Patients on 3 T MRI and CT

Patients with carcinoma in situ lesions

Four out of 17 patients had carcinoma in situ lesions. Although all 3 T MRI scans were of moderate to good (“acceptable”) image quality, in only one patient (25%), tumor boundaries could be visualized, although not clear. Concerning CT, the technical quality of all scans were good, but the tumor seen on MRI was not visible on CT. In another patient with Cis, visibility of tumor boundaries was slightly better on CT than on MR, leading to an “acceptable” tumor visibility on CT.

Patients with invasive squamous cell carcinoma

Thirteen out of 17 patients had an invasive scc on histopathological report. Eight patients had a cT1a lesion, four patients had a cT1b tumor, and one patient had an SCC staged as T2. Four MRI scans were of bad image quality due to severe motion artefacts. One of these patients suffered from claustrophobia. The remaining nine scans were of moderate to good (“acceptable”) image quality. In eight patients, the tumor and its boundaries could be adequately visualized. On CT, image quality was good in all patients, except for the one with claustrophobia. Tumor visibility was adequate in nine patients.

Comparison of tumor dimensions on CT, 3 T, 7 T and direct laryngoscopy

In eight patients with invasive SCC, the tumor and its boundaries could be adequately visualized on 3 T MRI and tumor dimensions could be measured (Table IV). In a consensus meeting, tumors were delineated on 3 T MRI and CT. Volumes varied from 0.036 to 2.38 cc and were slightly larger on MRI than on CT for all tumors. Tumor volume was not related to visibility of the tumor. In only one of these eight patients, laser excision was performed. Correlation of tumor diameters to pathological specimens was therefore not contributive.

Assessment of anatomical glottic subsites

Presence or absence of tumor involvement of anatomical subsites was scored on both imaging and during suspension laryngoscopy. For the anterior commissure, concordance between CT, 3 T MRI and laryngoscopy was low for the whole study population (including both superficial carcinoma in situ lesions and invasive bulky disease). For the eight patients with invasive SCC with adequate tumor visualization, shown in Table IV, concordance was higher. For these patients, a consensus was reached by the observers, blinded for clinical data. Two out of eight CTs and 3 T MRIs (of the same patients) were false negative for tumor invasion of the AC, which was visible during direct laryngoscopy. This was due to superficial tumor extension of a more bulky midcord lesion into the AC. Four out of eight CTs and MRIs (of the same patients) were true positive. Two CT and MRIs were true negative.

TABLE IV.
Tumor Dimensions Measured on Imaging and Direct Laryngoscopy.

In mm	Anterior-posterior dimeter (mm)			Lateral diameter (mm)		
	CT	3 T MRI	Laryngoscopy	CT	3 T MRI	Laryngoscopy
Pt 2	8.6	14.2	17	3.7	8.9	5
Pt 3	8.6	9	10	4.5	4.2	5
Pt 4	20	27	15	8.5	10	10
Pt 9	5	11	7	5	5	3
Pt 12	10	10	12	3.4	3.4	3.5
Pt 14	11.8	26.0	15	5.0	9.0	8
Pt 16	5.2	6.4	7	3.8	3.5	5
Pt 20	4	5.8	9	1.4	2.3	1

3 T = 3 Tesla; CT = computed tomography; MRI = magnetic resonance imaging.

The vocal muscle was scored as involved in five patients on both CT and MRI, it was scored as not involved in two patients and was scored as involved on MRI but not involved on CT in the same patient. No verification with histopathology could be done. Other subsites were not, or rarely, involved.

DISCUSSION

Feasibility: Primary Endpoint

Twenty percent of patients refused 7 T scanning because of claustrophobia. In contrast to our expectations, based on pilot data with detailed laryngeal visualization in healthy subjects, in only one out of seven 7 T scans, the tumor and its boundaries could be clearly seen. We therefore considered 7 T MRI not feasible.

Although the vast majority of 3 T scans was of moderate to good technical quality, this only resulted in adequate tumor visibility on 3 T MRI in nine out of the total group of 17 patients (53%) versus 10 out of 17 patients (59%) on CT. The tumor visibility was adequate in nine out of 13 (69%) 3 T MRIs with moderate to good image quality, versus 10 out of 16 patients (63%) with good CT image quality. This was probably due to inadequate visibility of superficial (carcinoma in situ) lesions. When subgroup analysis was done, tumor visualization was adequate in 62% (or even 89% after exclusion of four MRIs with bad technical quality) with SSC versus only 25% of patients with carcinoma in situ lesions. On CT, tumor visibility was adequate in 25% of Cis lesions and in 69% of SCC lesions (or 75% after exclusion of one CT with bad technical quality).

Study Limitations

This study has several limitations. First, histopathology could not be used as a reference standard to validate the diagnostic value of the scans. Random biopsy of anatomic subsites, only for study purposes, was considered unethical and harmful for the study patients. Second, data were very heterogeneous. The low concordance between laryngoscopy and CT does not allow for a

combined reference standard to validate MRI findings.¹⁸ Third, the moderate intraclass correlation coefficient on a 4-point scale between two experienced head and neck radiologists and the radiation oncologist reflects the difficulty of image interpretation. When scored as “adequate/acceptable” or “inadequate/unacceptable,” agreement was high. The intra-observer and inter-observer reproducibility in the delineation of head and neck tumors have a wide range, with a reported percentage measurement error for primary tumors of 0% to 53%.^{19–21} Between observers, the size of the largest gross tumor volume (GTV) can be more than eight times the size of the smallest volume. Last limitation of this study is that the majority of the glottic tumors were clinically superficial lesions. Four out of 17 were carcinoma in situ lesions. Another three lesions were biopsied in the referral hospital as carcinoma in situ lesions, but were invasive carcinomas after second biopsy at our tertiary hospital. Lesions that were cT2 on first visit were excluded from this study. This could have influenced the results. In larger glottic carcinomas MRI has been shown to be of additional value in delineating tumor boundaries and differentiating tumor from edema or fibrosis.^{22,23}

Comparison of MRI Data to Routine Diagnostics; Secondary Endpoint

Anterior-posterior diameters measured during laryngoscopy compared to MRI and CT were comparable. However, clinical measurements can be difficult due to both invasive and exophytic tumor components with varying shapes of the vocal cord. The superficial component results in larger tumor diameters measured during laryngoscopy, which was not detected on imaging. Because of the lack of histopathological data, unfortunately, no relation between tumor visibility and depth invasion of the tumor could be addressed.

Challenges of 3 T and 7 T MRI Scanning for Small Laryngeal Lesions

For optimal detection of small laryngeal lesions and to avoid partial volume effect of scanning small lesions, we

used a slice thickness of 0.5 to 1 mm. However, small slice thickness results in a diminished Signal to Noise Ratio (SNR). To optimize the signal in the area of interest, we used neck receive coils close to the larynx. At the surface the subcutaneous fat is located. This fat can cause large artefacts when patients move (for example due to breathing). These artefacts are more pronounced in the 7 T scans than in the 3 T MRI scans, due to the high sensitivity of the small surface coils in the 7 T setup close to the surface.

To minimize motion artefacts, all patients were scanned in a 4-point immobilization mask. A benefit of the stiff mask material was that the transmit neck coil used on 7 T, consisting of a dielectric bag filled with deuterated water, which can be quite heavy on the neck, was not sensed by the patient. Although the immobilization mask minimizes external movements of the head and neck, internal motion as a result of breathing and swallowing cannot be prevented. To diminish the susceptibility for motion artefacts, we performed four dynamic scans with one-fourth scan duration each, but this was not beneficial. A solution for this problem appears to be “in-vivo respiratory triggering,” a method in which data acquisition is only done during expiration, since internal breathing motion will reduce and swallowing cannot occur.²⁴

At 7 T, the SNR increases linearly with field strength. However, the image homogeneity is generally less due to the smaller RF wavelength causing RF interferences.^{25,26} For this reason, a body coil is very hard to manufacture at such high field strength. We used a dedicated neck transmit coil with 2 antenna's to homogenize the transmit field based on the principle of a dielectric waveguide¹⁶. Another challenge, especially at 7 T, is the energy absorbed by the human body (Specific Absorption Ratio of SAR in W/kg), which scales quadratically with the field strength. The higher SAR at 7 T has to be compensated by fewer RF pulses per time unit, resulting in a longer acquisition time. Also, the water-fat shift is increased at 7 T compared to 3 T. This can be compensated for by a higher read-out bandwidth, this however reduces the SNR.

Further improvement of scan quality at 3 T might be accomplished by a neck receive coil consisting of multiple elements. At 7 T, we already used receive coils with multiple elements. At 3 T, we used a receive coil with two elements. Adding receive coils can lead to a higher acceleration factor with a shorter scan duration. This will especially be of benefit when data acquisition is limited to the expiration phase of breathing. With multiple elements, the signal remains high enough for optimal tumor visibility.

CONCLUSION

We conducted a feasibility study for 3 T and 7 T MRI for clinically staged Tis, T1a and T1b glottic carcinoma. 7 T MRI was considered not feasible. 3 T MRI, with clinical exclusion of patients with a history of claustrophobia, and with histologically proven invasive squamous cell carcinoma, can be feasible. Especially with further improvement of MRI quality. However, its superiority to CT could

not be confirmed in this study. Superficial tumor extension remains difficult to detect on imaging.

BIBLIOGRAPHY

1. Van Loon Y, Sjogren E, Langeveld T, et al. Functional outcomes after radiotherapy or laser surgery in early glottic carcinoma: a systematic review. *Head Neck* 2012;34(8):1179–1189.
2. Abdurehim Y, Hua Z, Yasin Y, Kukurhan A, Imam I, Yuqin F. Transoral laser surgery versus radiotherapy: systematic review and meta-analysis for treatment options of T1a glottic cancer. *Head Neck* 2012;34(1):23–33.
3. Hakeem AH, Tubachi J, Pradhan SA. Significance of anterior commissure involvement in early glottic squamous cell carcinoma treated with transoral CO2 laser microsurgery. *Laryngoscope* 2013;123(8):1912–1917.
4. Barbosa MM, Araújo VJ Jr, Boasquevisque E, et al. Anterior vocal commissure invasion in laryngeal carcinoma diagnosis. *Laryngoscope* 2005;115:724–730.
5. Naiboglu B, Kinis V, Toros SZ, et al. Diagnosis of anterior commissure invasion in laryngeal cancer. *Eur Arch Otorhinolaryngol* 2010;267(4):551–555.
6. Zbären P, Christe A, Caversaccio MD, Stauffer E, Thoeny HC. Pretherapeutic staging of laryngeal carcinoma; clinical findings, computed tomography, and magnetic resonance imaging compared with histopathology. *Otolaryngol Head Neck Surg* 2007;137(3):487–491.
7. Hu Q, Luo F, Zhu SY, Zhang Z, Mao YP, Hui Guan X. Staging of laryngeal carcinoma: comparison of high-frequency sonography and contrast-enhanced computed tomography. *Clin Radiol* 2012;67(2):140–147.
8. Becker M, Burkhardt K, Dulguerov P, Allal A. Imaging of the larynx and hypopharynx. *Eur J Radiol* 2008;66(3):460–479.
9. van Egmond SL, Stegeman I, Pameijer FA, Bluemink JJ, Terhaar CH, Janssen LM. Systematic review of the diagnostic value of Magnetic Resonance Imaging for early glottic carcinoma. *Laryng Invest Otolaryngol* 2018;3(1):49–55.
10. Heverhagen JT, Bourekas E, Sammet S, Knopp MV, Schmalbrock P. Time-of-flight magnetic resonance angiography at 7 Tesla. *Invest Radiol* 2008;43:568–573.
11. Kollia K, Maderwald S, Putzki N, et al. First clinical study on ultra-high-field MR imaging in patients with multiple sclerosis: comparison of 1.5 T and 7 T. *AJNR Am J Neuroradiol* 2009;30:699–702.
12. Van Egmond SL, Visser F, Pameijer FA, Grolman W. Ex vivo and in vivo imaging of the inner ear at 7 Tesla MRI. *Otol Neurotol* 2014;35(4):725–729.
13. Kraff O, Theysohn JM, Maderwald S, et al. High-resolution MRI of the human parotid gland and duct at 7 Tesla. *Invest Radiol* 2009;44(9):518–524.
14. National Comprehensive Cancer Network. NCCN Clinical Practice Guidelines in Oncology: Head and Neck Cancers. version 1, 2015. Available at http://www.nccn.org/professionals/physician_gls/pdf/head-and-neck.pdf
15. Verdijn GM, Bartels LW, Raaijmakers CP, Terhaar CH, Pameijer FA, van den Berg CA. Magnetic resonance imaging protocol optimization for delineation of gross tumor volume in hypopharyngeal and laryngeal tumors. *Int J Radiat Oncol Biol Phys* 2009;74(2):630–636.
16. Bluemink JJ, Raaijmakers AJE, Koning W, et al. Dielectric waveguides for ultrahigh field magnetic resonance imaging. *Magn Reson Med* 2016;76:1314–1324.
17. Koning W, Bluemink JJ, Langenhuizen EAJ, et al. High-resolution MRI of the carotid arteries using a leaky waveguide transmitter and a high-density receive array at 7T. *Magn Reson Med* 2013;69:1186–1193.
18. Naaktgeboren CA, de Groot JH, Rutjes AWS, Bossuyt PMM, Reitsma JB, Moons KGM. Anticipating missing reference standard data when planning diagnostic accuracy studies. *BMJ* 2016;352:i402.
19. Weiss E, Hess CF. The impact of gross tumor volume (GTV) and clinical target volume (CTV) definition on the total accuracy in radiotherapy theoretical aspects and practical experiences. *Strahlenther Onkol* 2003;179(1):21–30.
20. Njeh CF. Tumor delineation: the weakest link in the search for accuracy in radiotherapy. *J Med Phys* 2008;33(4):136–140.
21. Gordon AR, Loevner LA, Shukla-Dave A, et al. Intraobserver variability in the MR determination of tumor volume in squamous cell carcinoma of the pharynx. *Am J Neuroradiol* 2004;25(6):1092–1098.
22. Allegra E, Ferrise P, Trapasso S, et al. Early glottic cancer: role of MRI in the preoperative staging. *Biomed Res Int* 2014;2014:890385.
23. Maroldi R, Ravanelli M, Farina D. Magnetic resonance for laryngeal cancer. *Curr Opin Otolaryngol Head Neck Surg* 2014;22(2):131–139.
24. Ruytenberg T, Verbist BM, Vonk-van Oosten J, Astreimidou E, Sjogren EV, Webb AG. Improvements in High Resolution Laryngeal Magnetic Resonance Imaging for Preoperative Transoral Laser Microsurgery and Radiotherapy Considerations in Early Lesions. *Front Oncol*. 2018;8:216.
25. Vaughan JT, Garwood M, Collins CM, et al. 7 T vs 4T: RF power, homogeneity, and signal-to-noise comparison in head images. *Magn Reson Med* 2001;46(1):24–30.
26. Theysohn JM, Maderwald S, Kraff O, Moeninghoff C, Ladd ME, Ladd SC. Subjective acceptance of 7 Tesla MRI for human imaging. *MAGMA* 2008;21:63–72.