


# Diagnostic accuracy of point-of-care ultrasound for evaluation of early blood-induced joint changes: Comparison with MRI

W. Foppen<sup>1</sup>  | I. C. van der Schaaf<sup>1</sup> | F. J. A. Beek<sup>1</sup> | W. P. T. M. Mali<sup>1</sup> | K. Fischer<sup>2,3</sup> 

<sup>1</sup>Department of Radiology, University Medical Centre Utrecht, Utrecht, The Netherlands

<sup>2</sup>Julius Centre for Health Sciences and Primary Care, University Medical Centre Utrecht, Utrecht, The Netherlands

<sup>3</sup>Van Creveldkliniek, Department of Hematology, University Medical Centre Utrecht, Utrecht, The Netherlands

## Correspondence

Wouter Foppen, University Medical Centre Utrecht, Department of Radiology, HP E.01.132, PO Box 85500, 3508 GA Utrecht, The Netherlands.

Email: W.Foppen@umcutrecht.nl

## Funding information

This study was financially supported by an unrestricted research grant from Baxalta BV/Shire, The Netherlands. The ultrasound scanner and training were funded by an unrestricted grant from Pfizer.

**Introduction:** Recurrent joint bleeding is the hallmark of haemophilia. Synovial hypertrophy observed with Magnetic Resonance Imaging (MRI) is associated with an increased risk of future joint bleeding.

**Aim:** The aim of this study was to investigate whether point-of-care ultrasound (POCUS) is an accurate alternative for MRI for the detection of early joint changes.

**Methods:** In this single centre diagnostic accuracy study, bilateral knees and ankles of haemophilia patients with no or minimal arthropathy on X-rays were scanned using POCUS and 3 Tesla MRI. POCUS was performed by 1 medical doctor, blinded for MRI, according to the "Haemophilia Early Arthropathy Detection with Ultrasound" (HEAD-US) protocol. MRIs were independently scored by 2 radiologists, blinded for clinical data and ultrasound results. Diagnostic accuracy parameters were calculated with 95% confidence intervals (CI).

**Results:** Knees and ankles of 24 haemophilia patients (96 joints), aged 18-34, were studied. Synovial hypertrophy on MRI was observed in 20% of joints. POCUS for synovial tissue was correct (overall accuracy) in 97% (CI: 91-99) with a positive predictive value of 94% (CI: 73-100) and a negative predictive value of 97% (CI: 91-100). The overall accuracy of POCUS for cartilage abnormalities was 91% (CI: 83-96) and for bone surface irregularities 97% (CI: 91-99).

**Conclusion:** POCUS could accurately assess synovial hypertrophy, bone surface irregularities and cartilage abnormalities in haemophilia patients with limited joint disease. As POCUS is an accurate and available alternative for MRI, it can be used for routine evaluation of early joint changes.

## KEYWORDS

arthropathy, haemarthrosis, MRI, Sensitivity, Specificity, Ultrasound

## 1 | INTRODUCTION

Due to low levels of coagulation factor VIII or IX, haemophilia is characterized by repeated joint bleeding. Prophylactic clotting factor replacement therapy (prophylaxis) to reduce bleeding is the

preferred treatment for patients with severe haemophilia.<sup>1,2</sup> Current prophylaxis regimens are insufficient to prevent all joint bleeding episodes. Repeated traumatic or spontaneous joint bleeds result in synovial hypertrophy and progressive osteochondral changes due to mechanical and metabolic processes.<sup>3,4</sup> Synovial hypertrophy on MRI is not observed in all joints with a history of bleeding<sup>5</sup> and may be responsive to treatment.<sup>6</sup> As synovial hypertrophy is associated

Preliminary results have been presented and awarded with the best poster prize on the 10th Congress of the European Association for Haemophilia and Allied Disorders 2017, Paris.

This is an open access article under the terms of the Creative Commons Attribution-NonCommercial License, which permits use, distribution and reproduction in any medium, provided the original work is properly cited and is not used for commercial purposes.

© 2018 The Authors. *Haemophilia* published by John Wiley & Sons Ltd



with an increased risk of bleeding,<sup>7</sup> early detection may be relevant in order to guide treatment changes.

Magnetic Resonance Imaging (MRI) is the most sensitive imaging modality to demonstrate early intra-articular joint changes.<sup>8</sup> As MRI is relatively expensive and time consuming, routine assessment of multiple joints of haemophilia patients is not feasible. As ultrasound showed to be highly accurate in assessing synovial hypertrophy, it may provide an alternative for MRI.<sup>9-11</sup> Various clinicians perform ultrasound examinations themselves for specific indications, known as point-of-care ultrasound (POC-US).<sup>12</sup> The "Haemophilia Early Arthropathy Detection with Ultrasound" (HEAD-US) protocol has been developed to allow joint assessment in haemophilia by non-radiologists.<sup>13</sup> Although the HEAD-US protocol is increasingly used in addition to physical examination, the diagnostic accuracy of this POC-US protocol has not been evaluated yet. The primary objective of this study was to assess the diagnostic accuracy of POC-US for synovial hypertrophy in haemophilia patients by comparison with MRI. Secondary objectives were to assess the diagnostic accuracy of POC-US for the presence or absence of cartilage abnormalities and bone surface irregularities.

## 2 | MATERIALS AND METHODS

This diagnostic accuracy study was performed at the Van Creveldkliniek, University Medical Centre Utrecht, the Netherlands, and reported according to the "Standards for the Reporting of Diagnostic accuracy studies" (STARD).<sup>14</sup> The research protocol was approved by the institutional ethical review board and written informed consent was obtained from all patients.

### 2.1 | Participants

An established imaging cohort of male adult haemophilia patients, born between 1980-1995, was invited for this cross-sectional diagnostic accuracy study.<sup>5</sup> Inclusion criteria were moderate or severe haemophilia ( $\leq 5\%$  factor VIII or IX activity) and at most 1 joint with moderate-severe arthropathy on X-rays (Pettersson score  $\geq 4$ ).<sup>15</sup> Exclusion criteria were a history of inhibitors for clotting factor concentrates or a contraindication for MRI. Additional haemophilia patients fulfilling the same in- and exclusion criteria were invited to achieve an adequate sample size (see "Sample size").

### 2.2 | Imaging

Bilateral knees and ankles of patients were examined by both POC-US and MRI on the same day. The index test was POC-US according to the Haemophilia Early Arthropathy Detection with UltraSound (HEAD-US) scanning protocol and score.<sup>13</sup> A single ultrasound scanner (Esaote, type MyLab25 Gold, Italy) with a linear probe (adjustable central frequency at 7.5, 10, and 12 MHz) was used. POC-US was performed by 1 medical doctor who followed a course on imaging physics, received repeated HEAD-US training

and scanned over 200 joints before the start of this study. POC-US was performed without knowledge of MRI results. According to the HEAD-US protocol, synovial tissue was assessed in the major joint recesses and scored as "absent/minimal"; "mild/moderate"; or "severe". Cartilage and bone surface were assessed at 1 surface per joint: the femoral condyles in the knees (in hyperflexion) and the talar dome in the ankles (in plantar flexion).

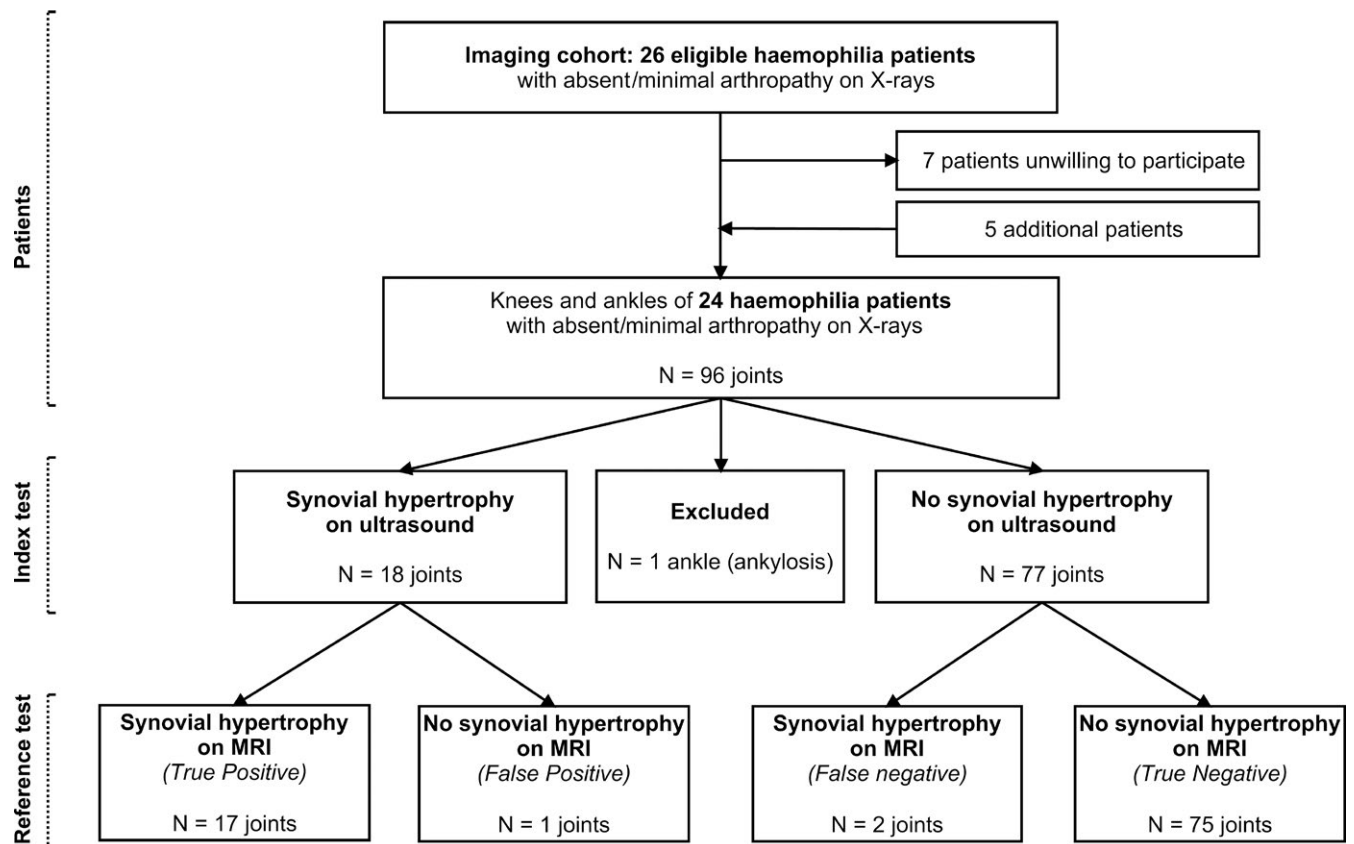
The reference test was 3 Tesla MRI (Philips, type Achieva 3T TX; Koninklijke Philips Electronics NV, the Netherlands). The MRI protocol for the knee consisted of 2 mm sagittal 3D Water only Selection (WATS), a 3.5 mm sagittal and transversal Proton Density Weighted (PDW) Spectral Adiabatic Inversion Recovery (SPAIR) and a 3.5 mm coronal T1-weighted Spin echo (SE) using a 16-Channel Knee Coil. For the ankle the imaging protocol consisted of 2 mm coronal 3D WATS, a 2.5 mm coronal PDW SPAIR and a 2.5 mm sagittal T1-weighted SE using a send-receive coil. MR images were scored by 2 radiologists, blinded for the ultrasound findings, according to the International Prophylaxis Study Group (IPSG) MRI scale.<sup>16</sup> Inconclusive results were discussed until consensus in separate meetings. Synovial hypertrophy is scored using surface measurements on a single MRI slice (acquired voxel size:  $3.5 \times 0.7 \times 0.5$  mm in knees;  $2.5 \times 0.8 \times 0.6$  mm in ankles). However, neither the IPSG MRI score, nor the MRI atlas for haemophilic arthropathy state lower cut-off values.<sup>16,17</sup> Lower cut-off values for the presence/absence of synovial hypertrophy were determined as a group decision ( $0.50 \text{ cm}^2$  for knees,  $0.25 \text{ cm}^2$  for ankles) in order to use objective criteria and prevent attribution of positive scores for synovial hypertrophy smaller than shown in the MRI atlas.

### 2.3 | Sample size

The sample size was based on our aim to establish the diagnostic accuracy of POC-US for synovial hypertrophy. For clinical interpretation, the positive and negative predictive values are the most valuable diagnostic accuracy parameters. Based on preliminary data, the prevalence of synovial hypertrophy in the imaging cohort was estimated at 23%.<sup>5</sup> Based on recent data on a different ultrasound protocol,<sup>9</sup> a sensitivity of 90% and a specificity of 95% were expected with POC-US. The minimal acceptable positive and negative predictive values were considered to be  $\geq 70\%$ . Including at least 24 patients would therefore suffice to detect a positive predictive value of 91% (95% confidence interval (CI): 71-99) and a negative predictive value of 97% (CI: 91-100).

### 2.4 | Analysis

Medians with interquartile ranges (IQR) or percentages were calculated for patient and joint characteristics. POC-US and MRI scores of synovial hypertrophy, cartilage abnormalities and bone surface irregularities were dichotomized as absent (0) or present ( $\geq 1$ ). Calculated diagnostic accuracy parameters with 95% CI were the sensitivity, specificity, positive predictive value, negative predictive value and percentage of findings correctly identified with POC-US (accuracy). Spearman's correlation was used to analyze



**FIGURE 1** Study design

the association between the ordinal HEAD-US score and IPSP MRI score for the severity of synovial hypertrophy, cartilage abnormalities and bone surface irregularities. Analyses were performed using SPSS (IBM SPSS Statistics version 21.0, Armonk, NY).

### 3 | RESULTS

In total, 96 joints of 24 patients were included between November 2014 and August 2015. Seven of the 26 patients of the original imaging cohort were unwilling to participate in this study. Five additional patients fulfilling the same inclusion criteria were included to reach the inclusion target of 24 patients. All patients underwent POC-US (index test) and MRI (reference test) as shown in Figure 1. One ankle with ankylosis was excluded in the analyses.

Baseline patient and joint characteristics are presented in Table 1. The median age of patients studied was 26.5 years (IQR: 23.0-29.5). In total, 17/24 patients (71%) had severe haemophilia A and the majority of patients (75%) received prophylaxis. Most joints (81%) had a history of bleeding although minimal X-ray changes were observed in 18% of joints only (median Pettersson score: 0, range: 0-6).

#### 3.1 | Test results

POC-US and MRI were performed on the same day in all patients. No adverse events occurred during this study. Although MRI

abnormalities were present in 68% of joints, minimal abnormalities were detected only: the median IPSP MRI score was 1 out of 17 points (IQR: 1-3). Synovial hypertrophy on MRI was observed in 3 knees (6%) and in 16 ankles (34%). In total, 16/19 joints (84%) with synovial hypertrophy showed concomitant haemosiderin deposits on MRI. Haemosiderin on MRI without synovial hypertrophy was observed in only 4/76 joints (5%). These joints showed small amounts of haemosiderin without fulfilling the criteria for synovial hypertrophy on ultrasound or MRI. For identification of synovial hypertrophy, POC-US was true positive in 17 joints, true negative in 75 joints, false positive in 1 joint and false negative in 2 joints (Figure 1). Cartilage abnormalities on ultrasound involved <25% of target surface in 4/95 joints (4%), 25%-50% of target surface in 3/95 joints (3%) and >50% of target surface in 7/95 joints (7%). Observed bone surface abnormalities by ultrasound predominantly consisted of mild irregularities (13/15 joints, 87%). Ultrasound and corresponding MRI findings of synovial hypertrophy, cartilage abnormalities and bone surface irregularities for knees and ankles are presented in Table 2.

#### 3.2 | Diagnostic accuracy estimates

The presence/absence of synovial hypertrophy was correctly identified using POC-US in 94% (CI: 86-100). As shown in Figure 2, synovial hypertrophy can be clearly visualized by POC-US. For synovial hypertrophy POC-US had a sensitivity of 89% (CI: 67-99),



specificity of 99% (CI: 93-100), positive predictive value of 94% (CI: 73-100) and a negative predictive value of 97% (CI: 91-100). The accuracy of POC-US for synovial hypertrophy was comparable in knees and ankles, except for a higher sensitivity (100% in knees vs 88% in ankles) and lower positive predictive value in knees (75% in knees vs 100% in ankles) (Table 3). A strong correlation between the ordinal HEAD-US score and IPSPG MRI score for the severity of synovial hypertrophy was observed ( $r = .90$ ,  $P < .01$ ).

Peripheral cartilage abnormalities and bone surface irregularities can be visualized by POC-US as well, as shown in Figure 3. The overall accuracy of POC-US for assessment of the presence/absence of cartilage abnormalities was 91% (CI: 83-96) and for bone surface irregularities 97% (CI: 91-99). Negative predictive values for cartilage abnormalities and bone surface irregularities were >90% and significantly better than 70%. Although the positive predictive values for cartilage abnormalities and bone surface irregularities were 86% and 87% respectively, the wide confidence intervals included the minimal acceptable threshold of 70% (Table 3). The HEAD-US score showed a strong correlation with the IPSPG MRI score for severity of

cartilage abnormalities ( $r = .73$ ,  $P < .01$ ) and bone surface irregularities ( $r = .88$ ,  $P < .01$ ).

## 4 | DISCUSSION

This study shows that POC-US according to the HEAD-US protocol can accurately assess the presence/absence of synovial hypertrophy in joints of haemophilia patients. POC-US had an overall accuracy above 90% for the presence/absence of synovial hypertrophy, cartilage abnormalities and bone irregularities. For synovial hypertrophy, the positive and negative predictive values were 94% and 97% respectively and significantly higher than the minimal acceptable threshold of 70%.

Joints were assessed using a standardized POC-US protocol and IPSPG MRI score.<sup>13,16</sup> The operator dependency of ultrasound may be a disadvantage in clinical practice. The HEAD-US protocol has shown a good reliability when performed by non-radiologists with limited training only.<sup>18,19</sup> In this study, ultrasound was performed by a single medical doctor who was trained with the HEAD-US protocol and had an experience of scanning over 200 joints. A similar diagnostic accuracy of POC-US is expected if performed by observers with comparable training and experience.

The IPSPG MRI score was developed and evaluated without the use of contrast agents.<sup>16</sup> As a result, subtle synovial hypertrophy may have been undetected in this study as MRI without contrast has shown to be less sensitive for synovial hypertrophy in Juvenile Idiopathic Arthritis.<sup>20</sup> Consequently, the sensitivity and positive predictive value of POC-US in the evaluation of synovial hypertrophy may have been overestimated in our study. However, this is unlikely as synovial hypertrophy according to the IPSPG MRI score is evaluated using robust surface measurements in a single MRI slice only.<sup>17,21</sup> Therefore, MRI with contrast is not expected to change the classification of synovial hypertrophy according to the haemophilia specific MRI score.

**TABLE 1** Baseline patient and joint characteristics

Patient characteristics		n = 24 patients	
Age in years (inter quartile range)		26.5 (23.0-29.5)	
Severe haemophilia		17 (71%)	
Prophylactic treatment		18 (75%)	
Joint characteristics	Knees (n = 48)	Ankles (n = 47)	Overall (n = 95)
History of bleeding	71%	91%	81%
X-rays abnormalities	13%	23%	18%
MRI abnormalities	69%	68%	68%

One ankle with ankylosis was excluded in the analyses.

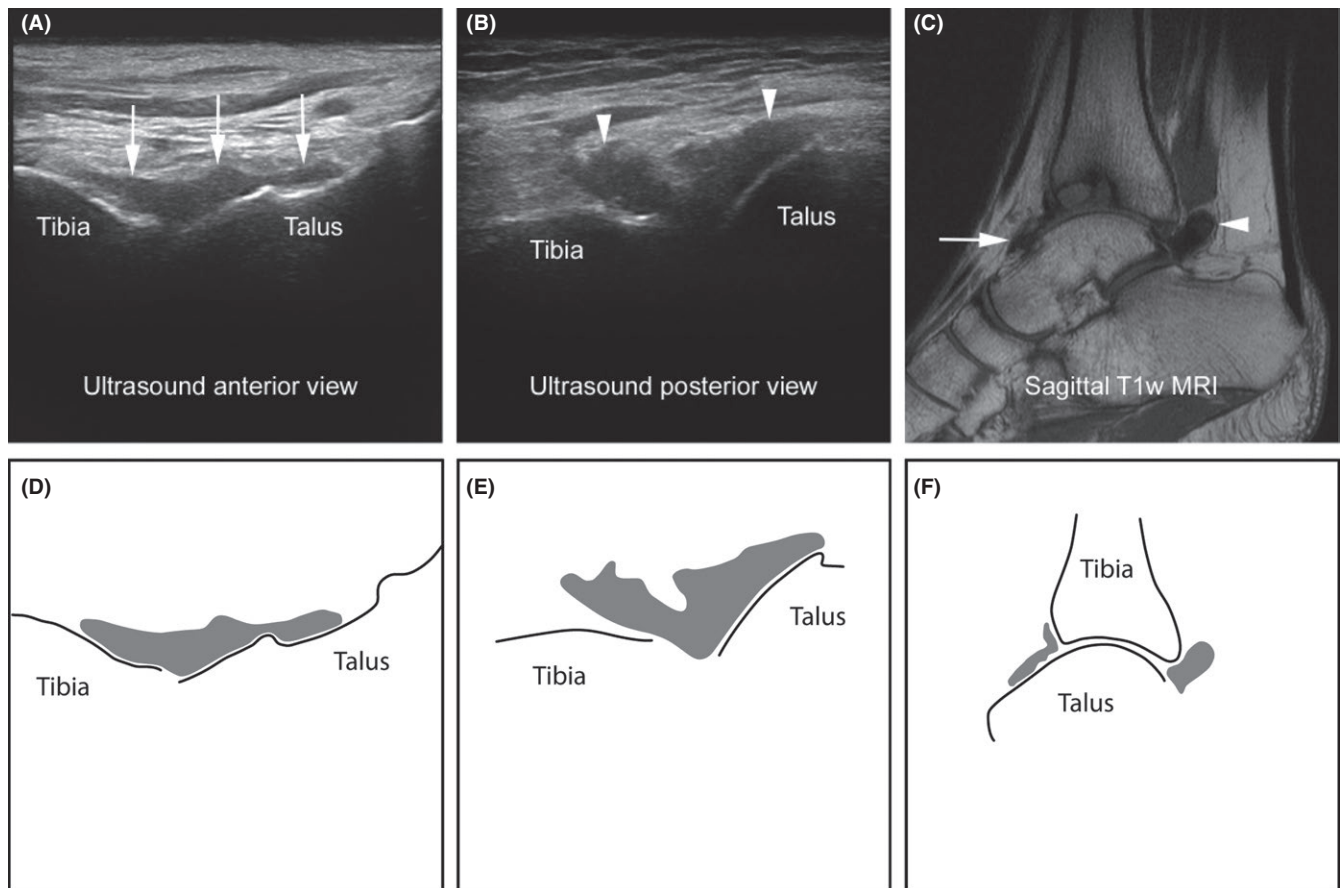
	Knees (n = 48)		Ankles (n = 47)		Overall (n = 95) <sup>a</sup>	
	MRI-	MRI+	MRI-	MRI+	MRI-	MRI+
Synovial hypertrophy						
POC-US-	44	0	31	2	75	2
POC-US+	1	3	0	14	1	17
Cartilage abnormalities						
POC-US-	43	3	31	4	74	7
POC-US+	0	2	2	10	2	12
Bone irregularities						
POC-US-	45	1	34	0	79	1
POC-US+	0	2	2	11	2	13

Values are true positives (ultrasound+, MRI+), true negatives (ultrasound-, MRI-), false positives (ultrasound+, MRI-), and false negatives (ultrasound-, MRI+).

POC-US, point-of-care ultrasound; MRI, magnetic resonance imaging.

<sup>a</sup>Knees and ankles combined. One ankle with ankylosis was excluded in the analyses.

**TABLE 2** Point-of-care ultrasound compared with MRI at joint level



**FIGURE 2** Synovial hypertrophy in the left ankle of a severe haemophilia patient aged 25 years. A, Anterior longitudinal ultrasound image with synovial hypertrophy (arrows) covering the talar dome. B, Posterior view obtained medially from the Achilles tendon showing synovial hypertrophy (arrowheads). C, Corresponding sagittal T1-weighted MRI of the left ankle showing synovial hypertrophy with low signal haemosiderin deposits in the anterior (arrow) and posterior (arrowhead) joint recesses. Subchondral cysts in the distal tibia present as well. D-F, Schematic representation of synovial hypertrophy (grey) in Figure 2A-C, respectively

**TABLE 3** Diagnostic accuracy of point-of-care ultrasound

	Sensitivity	Specificity	Positive PV	Negative PV	Accuracy <sup>a</sup>
Synovial hypertrophy					
Knees	100 (37-100)	98 (88-100)	75 (19-99)	100 (93-100)	98 (89-100)
Ankles	88 (62-98)	100 (91-100)	100 (81-100)	94 (80-99)	96 (85-99)
Overall <sup>b</sup>	89 (67-99)	99 (93-100)	94 (73-100)	97 (91-100)	97 (91-99)
Cartilage abnormalities					
Knees	40 (5-85)	100 (93-100)	100 (22-100)	93 (82-99)	94 (83-99)
Ankles	71 (42-92)	94 (80-99)	83 (52-98)	89 (73-97)	87 (74-95)
Overall <sup>b</sup>	63 (38-84)	97 (91-99)	86 (57-98)	91 (83-96)	91 (83-96)
Bone irregularities					
Knees	67 (9-99)	100 (94-100)	100 (22-100)	98 (88-100)	98 (89-100)
Ankles	100 (76-100)	94 (81-99)	85 (55-98)	100 (92-100)	96 (86-99)
Overall <sup>b</sup>	93 (66-100)	98 (91-100)	87 (60-98)	99 (93-100)	97 (91-99)

Values are percentages (95% confidence intervals).

PV, predictive value.

<sup>a</sup>Percentage correctly classified.

<sup>b</sup>Knees and ankles combined.



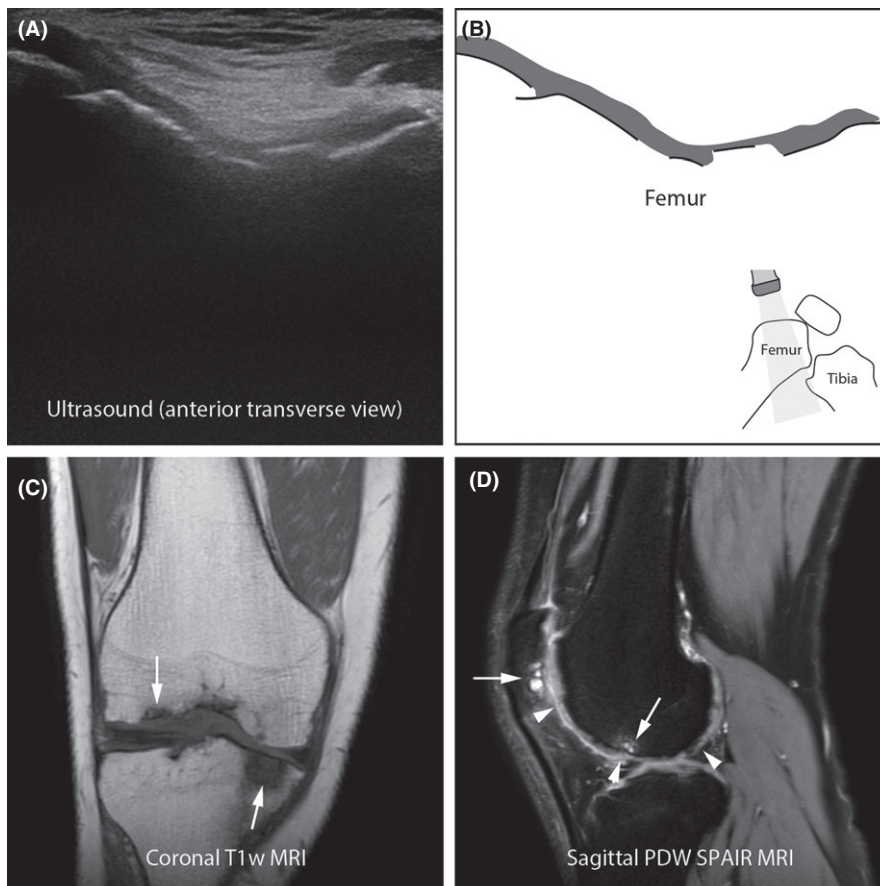
The diagnostic accuracy of POC-US for the presence/absence of cartilage abnormalities and bone irregularities was assessed as secondary objective in this study. Although the positive and negative predictive values of POC-US for cartilage abnormalities and bone irregularities were 85%–99%, the positive predictive values were not significantly better than 70% as the required sample size was calculated for the accuracy of POC-US for synovial hypertrophy only. However, POC-US may provide a general indication of cartilage and bone status in patients with no or limited abnormalities on X-rays.

#### 4.1 | Comparison with other studies

Although studies comparing ultrasound with MRI in haemophilia were performed previously,<sup>9,10</sup> none of them used point-of-care ultrasound. Recently, Doria et al reported the diagnostic accuracy of ultrasound in patient with haemophilia or von Willebrand disease.<sup>10</sup> Ultrasound was performed and interpreted by sonographers and radiologists according to a comprehensive ultrasound protocol described by Zukotynski.<sup>22</sup> Observers were not blinded for MRI findings in order to study maximum achievable diagnostic accuracy. The overall prevalence of synovial hypertrophy was 93% (compared to 20% in our study). Ultrasound was highly sensitive (100%, CI: 95–100) in detecting synovial hypertrophy although the specificity of detection of synovial hypertrophy in ankle joints was 50% only (CI:

7–93) (Table 4). Sierra Aisa et al studied haemophilia patients, aged 4–82 years, using ultrasound and MRI.<sup>9</sup> The ultrasound protocol described by Zukotynski et al<sup>22,23</sup> was used in their study too. The overall prevalence of synovial hypertrophy was 27%.<sup>9</sup> Diagnostic accuracy parameters were calculated from the results presented and are shown in Table 4.

Even though the populations and study designs of previous studies differed from our study, ultrasound showed high positive and negative predictive values for the presence/absence of synovial hypertrophy. Although only joints with no or minimal arthropathy were evaluated in this study, POC-US evaluation of synovial hypertrophy is not hampered by cartilage abnormalities and minimal bone surface irregularities as the presence/absence of synovial hypertrophy is evaluated in the joint recesses only. The results on the diagnostic accuracy of POC-US for synovial hypertrophy are therefore expected to be valid for patient with moderate arthropathy too. This is supported by a very recent publication by von Drygalski et al showing that ultrasound is highly sensitive in the identification of abnormal soft tissue in patients with more advanced arthropathy (mean Pettersson score at joint level 8, range 0–12).<sup>24</sup> More detailed ultrasound examination by an experienced musculoskeletal radiologist and/or using advanced ultrasound equipment is expected to reveal more subtle changes and may result in an even better diagnostic accuracy of ultrasound. However, the clinical relevance of these subtle changes remains to be established.



**FIGURE 3** Cartilage abnormalities and bone irregularities in the right knee of a severe haemophilia patient aged 29 years. A, Anterior transverse ultrasound image with cartilage abnormalities covering the irregular bone surface of the femoral condyles. B, Schematic representation of cartilage (grey) and bone surface (black lines) in Figure 3A. C, Coronal T1-weighted MRI of the right knee showing subchondral bone irregularities and cysts (arrows), most pronounced in the lateral femoral condyle and the medial tibial plateau. D, Sagittal PDW SPAIR MRI of the lateral aspect of the right knee showing irregular cartilage of the lateral femoral condyle (arrowheads) and subchondral bone irregularities in the patella and lateral femoral condyle (arrows)

**TABLE 4** Results of studies comparing ultrasound with MRI to detect synovial hypertrophy

Study characteristics	Sierra Aisa et al <sup>9</sup>	Doria et al <sup>10</sup>	Present study
Study population	Haemophilia (4-82 y)	Haemophilia and VWD (5-17 y)	Haemophilia (18-34 y)
Joints	60 knees, 60 ankles	25 knees, 34 ankles	48 knees, 47 ankles
Ultrasound protocol	Zukotynski et al <sup>22</sup>	Zukotynski et al <sup>22,23</sup>	Martinoli et al <sup>13</sup>
Operators/observers	Not reported	Sonographers & radiologists	Medical doctor
Blinding	Not reported	Unblinded for MRI	Blinded for MRI
Synovial hypertrophy			
Knees	Prevalence = 12%	Prevalence = 92%	Prevalence = 6%
Sensitivity	86 (42-100)	100 (85-100)	100 (37-100)
Specificity	96 (80-100)	100 (16-100)	98 (88-100)
Positive PV	86 (42-100)	100 (85-100)	75 (19-99)
Negative PV	96 (80-100)	100 (16-100)	100 (93-100)
Ankles	Prevalence = 42%	Prevalence = 94%	Prevalence = 34%
Sensitivity	100 (89-100)	100 (85-100)	88 (62-98)
Specificity	100 (55-100)	50 (1-99)	100 (91-100)
Positive PV	100 (89-100)	97 (84-100)	100 (81-100)
Negative PV	100 (55-100)	100 (3-100)	94 (80-99)
Overall <sup>a</sup>	Prevalence = 27%	Prevalence = 93%	Prevalence = 20%
Sensitivity	97 (94-100)	100 (95-100)	89 (67-99)
Specificity	96 (82-100)	50 (7-93)	99 (93-100)
Positive PV	97 (94-100)	96 (88-100)	94 (73-100)
Negative PV	96 (82-100)	100 (22-100)	97 (91-100)

Values are percentages (95% confidence intervals).

VWD, von Willebrand disease; PV, predictive value; VWD, von Willebrand disease.

<sup>a</sup>Knees and ankles combined.

## 4.2 | Clinical application

Point-of-care ultrasound is increasingly used in haemophilia patients to obtain direct information of joint status.<sup>25-28</sup> Operators should have received proper training before implementation of POC-US in haemophilia care in order to avoid incorrect diagnosis and misuse. Recommendations and guidelines on training standards, appropriate use and quality assurance have therefore been described.<sup>29</sup>

Although soft tissue abnormalities in joints may be accurately evaluated by ultrasound, ultrasound differentiation between synovial hypertrophy with or without haemosiderin deposits is unreliable.<sup>24,30,31</sup> Results on synovial hypertrophy in this study therefore represent both synovial hypertrophy with and synovial hypertrophy without haemosiderin deposits. In the evaluated population with limited arthropathy, synovial hypertrophy and haemosiderin were both present or both absent in the majority of joints. However, 5% of joints without synovial hypertrophy on ultrasound showed haemosiderin deposits on MRI. If detection of haemosiderin or differentiation between synovial hypertrophy with or without haemosiderin is clinically indicated, a more detailed evaluation using joint MRI may be warranted.

Ultrasound may be used to evaluate cartilage and bone surfaces too. In our study, the overall accuracy of POC-US in the detection of cartilage abnormalities and bone surface irregularities was based on the presence/absence of cartilage abnormalities and bone irregularities on ultrasound and MRI. The location and severity of abnormalities were not compared one-to-one with MRI. Furthermore, because ultrasound waves are reflected at bony surfaces, primarily the peripheral joint surfaces could be evaluated. As blood-induced joint damage is expected to affect the entire joint, the cartilage and bone status of select target surfaces provide a general rather than a detailed indication of the joint status. Taken together, our results on the POC-US accuracy therefore represent the presence/absence of any cartilage abnormality and any bone irregularity only, and MRI continues to be the best imaging modality for complete and accurate assessment of cartilage and bone alterations as these cannot be ruled out by ultrasound alone.

A recent report showed that synovial hypertrophy detected by MRI is predictive for joint bleeding in patients with limited arthropathy.<sup>7</sup> As POC-US can accurately evaluate the presence of synovial hypertrophy, it may be used to monitor treatment and/or to identify joints at risk of bleeding in these patients. Further studies using

POC-US are needed to assess its diagnostic accuracy in other centres and to evaluate the minimal expertise required. It remains to be evaluated in what way POC-US detected synovial hypertrophy may guide treatment changes and if these treatment changes could improve joint outcome.

## 5 | CONCLUSION

Point-of-care ultrasound according to the HEAD-US protocol can accurately assess the presence/absence of synovial hypertrophy in joints of haemophilia patients. The positive and negative predictive values of POC-US for synovial hypertrophy were high at 94% and 97% respectively. In addition, POC-US may also be used to provide a general indication of the cartilage and bone status. As synovial hypertrophy is associated with bleeding, POC-US performed by trained clinicians may play a role in tailoring haemophilia treatment in the future. Further studies are needed to establish the effects of POC-US guided treatment changes.

## DISCLOSURES

This study was financially supported by an unrestricted research grant from Baxalta BV/Shire, The Netherlands. The ultrasound scanner and training were funded by an unrestricted grant from Pfizer.

## ORCID

W. Foppen  <http://orcid.org/0000-0003-4970-8555>

K. Fischer  <http://orcid.org/0000-0001-7126-6613>

## REFERENCES

- Iorio A, Marchesini E, Marcucci M, Stobart K, Chan A. Clotting factor concentrates given to prevent bleeding and bleeding-related complications in people with hemophilia A or B (Review). *Cochrane Database Syst Rev* 2011;9:1-46.
- Srivastava A, Brewer AK, Mauser-Bunschoten EP, et al. Guidelines for the management of hemophilia. *Haemophilia*. 2013;19:e1-e47.
- Jansen NW, Roosendaal G, Lafeber FP. Understanding haemophilic arthropathy: an exploration of current open issues. *Br J Haematol*. 2008;143:632-640.
- Lafeber FPJG, Miossec P, Valentino L a. Physiopathology of haemophilic arthropathy. *Haemophilia*. 2008;14:3-9.
- Den Uijl IEM, De Schepper A, Camerlinck M, Grobbee DE, Fischer K. Magnetic resonance imaging in teenagers and young adults with limited haemophilic arthropathy: baseline results from a prospective study. *Haemophilia*. 2011;17:926-930.
- Pergantou H, Platokouki H, Matsinos G, et al. Assessment of the progression of haemophilic arthropathy in children. *Haemophilia*. 2010;16:124-129.
- Foppen W, Fischer K. Prognostic value of MRI synovial changes in haemophilia patients: preliminary results. *Haemophilia*. 2015;21:41-42.
- Chan MW, Leckie A, Xavier F, et al. A systematic review of MR imaging as a tool for evaluating haemophilic arthropathy in children. *Haemophilia*. 2013;19:e324-e334.
- Sierra Aisa C, Lucía Cuesta JF, Rubio Martínez A, et al. Comparison of ultrasound and magnetic resonance imaging for diagnosis and follow-up of joint lesions in patients with haemophilia. *Haemophilia*. 2014;20:e51-e57.
- Doria AS, Keshava SN, Mohanta A, et al. Diagnostic accuracy of ultrasound for assessment of hemophilic arthropathy: MRI correlation. *Am J Roentgenol*. 2015;204:W336-W347.
- Ligocki C, Abadeh A, Wang K, et al. A systematic review of ultrasound imaging as a tool for evaluating haemophilic arthropathy in children and adults. *Haemophilia*. 2017;23:598-612.
- Moore CL, Copel JA. Point-of-Care ultrasonography. *N Engl J Med*. 2011;364:749-757.
- Martinoli C, Della Casa Alberighi O, di Minno G, et al. Development and definition of a simplified scanning procedure and scoring method for Haemophilia Early Arthropathy Detection with Ultrasound (HEAD-US). *Thromb Haemost*. 2013;109:1170-1179.
- Bossuyt PM, Reitsma JB, Bruns DE, et al. Towards complete and accurate reporting of studies of diagnostic accuracy: the STARD initiative. *Radiology*. 2003;226:24-28.
- Pettersson H, Ahlberg A, Nilsson IM. A radiologic classification of hemophilic arthropathy. *Clin Orthop Relat Res*. 1980;149:153-159.
- Lundin B, Manco-Johnson ML, Ignas DM, et al. An MRI scale for assessment of haemophilic arthropathy from the International Prophylaxis Study Group. *Haemophilia*. 2012;18:962-970.
- Nuss R, Kilcoyne R. *The MRI Atlas of Hemophilic Arthropathy*. New York, NY: Professional Publishing Group, Ltd; 2002.
- Fischer K, Oldenburg J, Astermark J, et al. Ultrasound evaluation of haemophilic joints by haemophilia physicians: a reliability study. *J Thromb Haemost*. 2015;13:601.
- Lisi C, Di Natali G, Sala V, et al. Interobserver reliability of ultrasound assessment of haemophilic arthropathy: radiologist vs. non-radiologist. *Haemophilia*. 2016;22:e211-e214.
- Hemke R, Kuijpers TW, Van Den Berg JM, et al. The diagnostic accuracy of unenhanced MRI in the assessment of joint abnormalities in juvenile idiopathic arthritis. *Eur Radiol*. 2013;23:1998-2004.
- Lundin B, Berntorp E, Pettersson H, et al. Gadolinium contrast agent is of limited value for magnetic resonance imaging assessment of synovial hypertrophy in hemophiliacs. *Acta Radiol*. 2007;48:520-530.
- Zukotynski K, Jarrin J, Babyn PS, et al. Sonography for assessment of haemophilic arthropathy in children: a systematic protocol. *Haemophilia*. 2007;13:293-304.
- Keshava SN, Gibikote S, Mohanta A, Doria a. S. Refinement of a sonographic protocol for assessment of haemophilic arthropathy. *Haemophilia*. 2009;15:1168-1171.
- von Drygalski A, Moore RE, Nguyen S, et al. Advanced hemophilic arthropathy: sensitivity of soft tissue discrimination with musculoskeletal ultrasound. *J Ultrasound Med*. 2018;37:1945-1956.
- Ceponis A, Wong-Sefidan I, Glass CS, von Drygalski A. Rapid musculoskeletal ultrasound for painful episodes in adult haemophilia patients. *Haemophilia*. 2013;19:790-798.
- Foppen W, van der Schaaf IC, Fischer K. Value of routine ultrasound in detecting early joint changes in children with haemophilia using the "Haemophilia Early Arthropathy Detection with UltraSound" protocol. *Haemophilia*. 2016;22:121-125.
- Kidder W, Nguyen S, Larios J, et al. Point-of-care musculoskeletal ultrasound is critical for the diagnosis of hemarthroses, inflammation and soft tissue abnormalities in adult patients with painful haemophilic arthropathy. *Haemophilia*. 2015;21:530-537.
- Aznar JA, Pérez-Alenda S, Jaca M, et al. Home-delivered ultrasound monitoring for home treatment of hemarthrosis in haemophilia A. *Haemophilia*. 2015;21:e147-e150.



29. Lawson W, Uy M, Strike K, et al. Point of care ultrasound in haemophilia: building a strong foundation for clinical implementation. *Haemophilia*. 2017;23:648-651.
30. Martinoli C, Di Minno MND, Pasta G, Tagliafico A. Hemosiderin detection with ultrasound: reality or myth? *Am J Roentgenol*. 2016;206:W30.
31. Soliman M, Daruge P, Dertkigil SSJ, et al. Imaging of haemophilic arthropathy in growing joints: Pitfalls in ultrasound and MRI. *Haemophilia*. 2017;23:660-672.

**How to cite this article:** Foppen W, der Schaaf ICV, Beek FJA, Mali WPTM, Fischer K. Diagnostic accuracy of point-of-care ultrasound for evaluation of early blood-induced joint changes: Comparison with MRI. *Haemophilia*. 2018;24:971-979. <https://doi.org/10.1111/hae.13524>