



## Computed tomographic pelvimetry in English bulldogs

Tetyda P. Dobak<sup>a, \*</sup>, George Voorhout<sup>a</sup>, Johannes C.M. Vernooij<sup>b</sup>,  
Susanne A.E.B. Boroffka<sup>c</sup>

<sup>a</sup> Division of Diagnostic Imaging, Faculty of Veterinary Medicine, Utrecht University, Yalelaan 108, 3584CM Utrecht, The Netherlands

<sup>b</sup> Department of Farm Animal Health, Faculty of Veterinary Medicine, Utrecht University, Yalelaan 7, 3584CL Utrecht, The Netherlands

<sup>c</sup> Boroffka Diagnostic Imaging, Utrecht, The Netherlands

### ARTICLE INFO

#### Article history:

Received 7 December 2017

Received in revised form

8 May 2018

Accepted 23 May 2018

Available online 31 May 2018

#### Keywords:

Canine

Dystocia

Pelvimetry

Computed tomography

Morphometry

### ABSTRACT

English bulldogs have been reported to have a high incidence of dystocia and caesarean section is often performed electively in this breed. A narrow pelvic canal is the major maternal factor contributing to obstructive dystocia. The objective of this cross-sectional study was to assess the pelvic dimensions of 40 clinically healthy English bulldogs using computed tomography pelvimetry. A control group consisting of 30 non-brachycephalic dogs that underwent pelvic computed tomography was retrospectively collected from the patient archive system. Univariate analysis of variance was used to compare computed tomography pelvimetry of both groups and the effects of weight and gender on the measurements. In addition, ratios were obtained to address pelvic shape differences. A significantly ( $P = 0.00$ ) smaller pelvic size was found in English bulldogs compared to the control group for all computed tomography measurements: width and length of the pelvis, pelvic inlet and caudal pelvic aperture. The pelvic conformation was significantly different between the groups, English bulldogs had an overall shorter pelvis and pelvic canal and a narrower pelvic outlet. Weight had a significant effect on all measurements whereas gender that only had a significant effect on some (4/11) pelvic dimensions. Our findings prove that English bulldogs have a generally reduced pelvic size as well as a shorter pelvis and narrower pelvic outlet when compared to non-brachycephalic breeds. We suggest that some of our measurements may serve as a baseline for pelvic dimensions in English bulldogs and may be useful for future studies on dystocia in this breed.

© 2018 Elsevier Inc. All rights reserved.

### 1. Introduction

Obstructive dystocia can be caused by various complications of maternal origin such as a narrow birth canal and/or pelvic malformation, or of foetal origin such as malpresentation, oversized fetuses and/or foetal monstrosities. Dystocia in dogs occurs at an overall incidence of 5% but can reach 90% in brachycephalic breeds, such as the English bulldog [1–3]. Previous studies in dogs have shown that a narrow birth canal is the second most common maternal cause of dystocia after uterine inertia [4].

Brachycephalic and some terrier breeds are described with a narrow birth canal and a relatively large foetal head [5–8]. A study in two terrier breeds proved that a dorsoventrally flattened pelvic

conformation is significantly related to obstructive dystocia [1]. In cats, a brachycephalic conformation was found to be significantly associated with small pelvic dimensions and with a higher rate of dystocia relative to mesocephalic cats [9,10].

In the United States and Canada English bulldogs are among the five most common breeds to undergo emergency or elective caesarean section [11]. This is consistent with a later survey performed in the United Kingdom in which English bulldogs, Boston terriers and French bulldogs had the highest reported rates with more than 80% of caesarean sections [12]. A recent international survey of English bulldog reproduction revealed that caesarean section was performed in 94.8% of the cases, of which 89.2% were elective [13].

It is generally assumed that the English bulldog is susceptible to dystocia due to foetal-pelvic disproportion caused by the small pelvic canal and deep position of the pregnant uterus in combination with the foetal large head and shoulders [2].

Radiographic pelvimetry has been previously described a useful

\* Corresponding author.

E-mail addresses: [T.P.Dobak@uu.nl](mailto:T.P.Dobak@uu.nl) (T.P. Dobak), [G.Voorhout@uu.nl](mailto:G.Voorhout@uu.nl) (G. Voorhout), [J.C.M.Vernooij@uu.nl](mailto:J.C.M.Vernooij@uu.nl) (J.C.M. Vernooij), [sboroffka@gmail.com](mailto:sboroffka@gmail.com) (S.A.E.B. Boroffka).

method for morphometric assessment of the pelvis in dogs, cats and sheep [10,14–16] however it allows only two-dimensional evaluation of the pelvis and has a limited accuracy of acquired measurements based on distortion of the pelvis due to its angle relative to the detector. Computed tomography (CT) pelvimetry was reported in German shepherd dogs, rabbits and bovine cadavers [17–19], it is a high-resolution technique, which enables a precise three-dimensional evaluation of the pelvis.

To the authors knowledge, a morphologic evaluation of the pelvic conformation in English bulldogs has not been reported.

The objective of the present study was to establish the dimensions of the pelvis in a representative group of English bulldogs in comparison with the dimensions in non-brachycephalic dogs. In addition, correlations between the pelvic measurements, weight and gender were determined.

## 2. Materials and methods

### 2.1. Animals and sample collection

Forty clinically healthy client-owned English bulldogs were randomly recruited from registered breeders in cooperation with the Dutch English Bulldog Club (Engelse Bulldog Club Nederland E.B.C.N.) between November and December 2011. In order to assure that the selected animals were older than one year of age and no littermates or same parent combination offspring were included, the invitation process was performed under supervision of the Dutch Kennel Club (Raad van Beheer).

The study was performed with the informed consent of the owners. All procedures were approved by and conducted in accordance with the Animal Experiments Committee of Utrecht University as required by Dutch legislation.

For comparison, data were retrospectively collected of 30 non-brachycephalic dogs of various pure breeds (25/30) and crossbred dogs (5/30), of which a CT examination of the pelvis was available between January 2008 and January 2016. Inclusion criteria were a minimum age of one year and a weight range from 18 to 30 kg corresponding to the weight range of the English bulldogs included in this study. Dogs with diseases or injuries that could affect pelvic dimensions were excluded.

General data regarding the breed, gender, age, and body weight were recorded. Prior to anaesthesia all dogs were fasted for 12 h and underwent a complete physical examination that classified all as ASA (American Society of Anaesthesiologists) status class 2.

Computed tomography examination was performed under general anaesthesia using a standardized anesthetic protocol. A single slice helical CT scanner (Philips Secura, Philips NV, Eindhoven, the Netherlands) was used. All English Bulldogs were positioned in sternal recumbency. Of the control dogs, 15 were positioned in sternal and 15 in dorsal recumbence with neutral positioning of the pelvis and hind limbs. Technical settings utilized were: 3 mm thick helical slices, a pitch of 1, 1 s tube rotation time, 120 kV, 200 mA, 292 mm field of view, 512 × 512 matrix and a high spatial frequency algorithm. Dose parameters, slice thickness (range of 1–5 mm) and field of view (range of 144–342 mm) varied for the control group depending on the dog's size.

### 2.2. Computed tomographic pelvimetry

Images were reviewed on a DICOM workstation (IMPAX version 6.6.1, Agfa HealthCare NV, Mortsel, Belgium). Window width and level were standardized to the bone algorithm (WW 2500/WL 500) for optimal visualisation of the bony structures. On multiplanar reconstructions (transverse, sagittal and dorsal) the pelvis was positioned individually for each measurement.

Measurements of the pelvis and pelvic cavity [20] were obtained by a non-blinded single observer (TD) with an electronic calliper tool as follows: (1) width of the pelvis = (A) horizontal distance between both iliac tuber coxae at mid-height and (B) maximal horizontal distance between both lateral tuber ischiadicum, (2) length of the pelvis = (C) distance between most cranial aspect of tuber coxae to most caudal aspect of tuber ischiadicum of each side, averaged value of both measurements was used and (D) length of the pelvic symphysis, (3) height of the pelvis = (E) cranial conjugate of the pelvic inlet from the mid-promontorium sacrale to the pecten ossis pubis (cranial aspect of pelvic symphysis), (F) caudal conjugate from the mid-promontorium sacrale to the caudal end of the pelvic symphysis, (4) oblique diameter of the pelvic inlet = (Ga) from the left cranioventral aspect of the sacroiliac joint to the right iliopubic eminence and (Gb) from the right cranioventral aspect of the sacroiliac joint to the left iliopubic eminence, (5) transverse diameter of the pelvic inlet = (H) maximal horizontal width, and (6) caudal pelvic aperture = (Ia) course of the sacrotuberous ligament from the right lateral aspect of the vertebral body of the first coccygeal vertebra to the lateral aspect of the right ischial tuberosity and (Ib) from the left lateral aspect of the vertebral body of the first coccygeal vertebra to the lateral aspect of the left ischial tuberosity (Fig. 1).

The shape of the pelvis and pelvic canal was assessed as a relation between the length (C, F) and the width (A, H). Ratios of the pelvic inlet (E/H) and caudal pelvic aperture (Ia/H and Ib/H) were obtained.

### 2.3. Statistical analysis

Statistical tests were performed using commercially available software (SPSS Statistics 22, IBM Corporation, Hampshire, UK) comparing pelvimetric values obtained in English bulldogs and the control group.

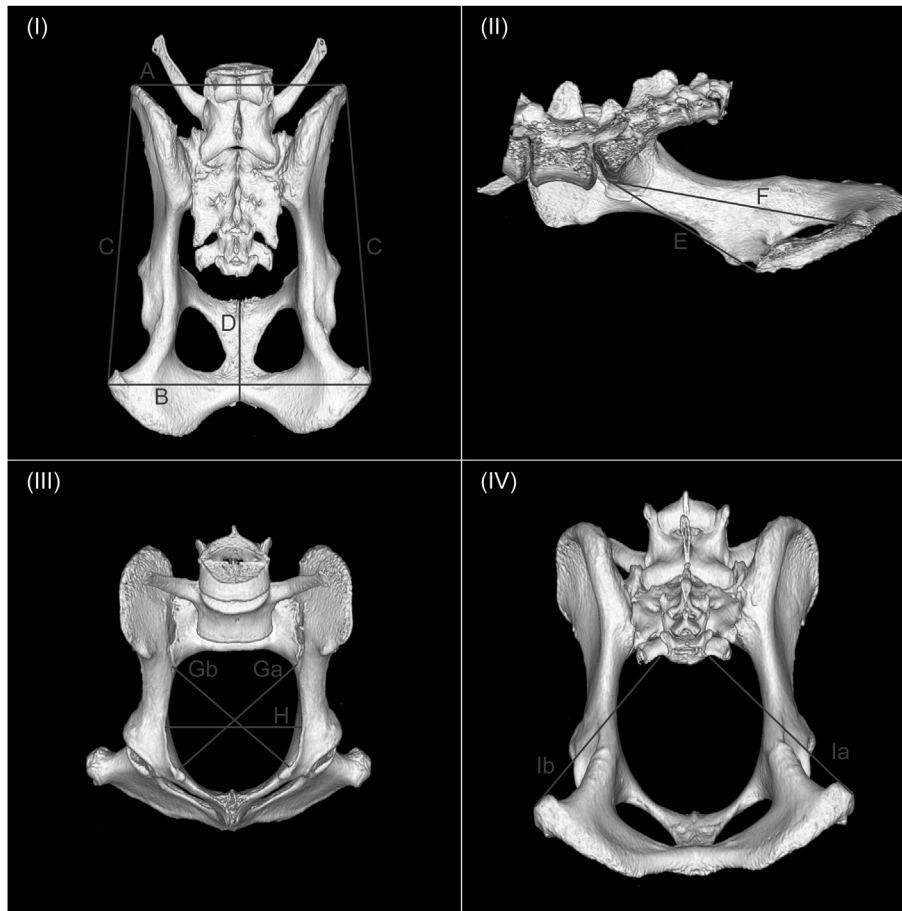
Univariate analysis of covariance (ANCOVA) was used to examine the association between means of the English bulldogs and control group for all pelvic measurements. The model was corrected for gender and weight and the interaction between both in order to estimate the group effect as good as possible. The final model was reduced for non-significant variables. A *P*-value of <0.05 was considered significant. Ratios were calculated, group means were compared and also corrected for weight and gender influences. The validity of the models was evaluated by the residuals for normality, linearity and homoscedasticity. The same models were run with the 15 lightest dogs of the control group for sensitivity analysis.

## 3. Results

Of the 40 English bulldogs, 26 (65%) were female dogs (22 intact and 4 neutered) and 14 males (11 intact and 3 neutered). The age range was 14–31 months (mean 20 months, median 16 months) and the weight range was 18.1–30.8 kg (mean 23.56 kg, median 23 kg).

The control group was composed of 16 breeds (Labrador retriever (*n* = 5), Flatcoated retriever (*n* = 4), Border Collie (*n* = 2), Labradoodle (*n* = 2) and one each of the following: Golden retriever, Bouvier des Flandres, German shepherd, Dutch shepherd, Belgian shepherd, Catalan sheepdog, Ibizan Hound, Nova Scotia duck tolling retriever, Welsh springer spaniel, German wirehair, Siberian husky, Vizsla. Additionally, five crossbred dogs (*n* = 5) were included of mainly shepherd cross breeds (*n* = 3).

Of the 30 control dogs, 18 (60%) were females (7 intact and 11 neutered) and 12 males (8 intact and 4 neutered). Their age ranged from 14 to 168 months (mean 78.7 months, median 81 months)



**Fig. 1.** Surface-rendered three-dimensional (3D) volume reconstruction of the canine pelvis based on CT images demonstrating the acquired measurements: (I) dorsal view with the measurements of pelvic width, (A) horizontal distance between both iliac tubera coxae and (B) maximal horizontal distance between both lateral tubera ischiadica and length (C) distance between most cranial aspect of tuber coxae to most caudal aspect of tuber ischiadicum of each side and (D) length of the pelvic symphysis. (II) sagittal view showing the (E) cranial conjugate of the pelvic inlet from the mid-promontorium sacrale to the pecten ossis pubis, (F) caudal conjugate from the mid-promontory to the caudal end of the pelvic symphysis. (III) cranial view with measurements of the pelvic inlet, including the oblique diameter of the pelvic inlet (Ga) from the left cranioventral aspect of the ileosacral joint to the right iliopubic eminence and (Gb) from the right cranioventral aspect of the ileosacral joint to the left iliopubic eminence and the transverse diameter of the pelvic inlet (H) maximal horizontal width. (IV) caudodorsal oblique view showing the measurements of the pelvic outlet (Ia) course of the sacrotuberous ligament from the right lateral aspect of the vertebral body of the first coccygeal vertebra to the lateral aspect of the right ischial tuberosity and (Ib) from the left lateral aspect of the vertebral body of the first coccygeal vertebra to the lateral aspect of the left ischial tuberosity.

with a weight range of 18–31.1 kg (mean 25.62, median 27 kg). The 15 lightest control dogs for sensitivity analysis had a weight range of 18–27 kg (mean 22.46 kg, median 22 kg).

Computed tomography pelvic measurements were obtained for all individuals of both groups. Their means and standard deviations, and p-values for the estimated difference between group means are listed in [Table 1](#).

There was a significant difference of the pelvic and pelvic canal length between groups. Our sample of the English bulldog population had a significantly shorter pelvis and pelvic canal, given by the measurements of the caudal conjugate (F) ( $P=0.00$ ), pelvic symphysis (D) ( $P=0.00$ ) and length between tuber coxae and tuber ischium (C) ( $P=0.00$ ).

The pelvic inlet, pelvic canal and pelvic outlet were significantly narrower in English bulldogs than in the control dogs. As the English bulldogs had significantly ( $P=0.00$ ) smaller oblique diameter (Ga and Gb) and transverse diameter (H) of the pelvic inlet, smaller cranial conjugate (E) and the measures for the caudal pelvic aperture (Ia and Ib).

The width of the pelvis was significantly smaller in English bulldogs at the level of the tuber coxae ( $P=0.00$ ) and tuber ischiadicum ( $P=0.00$ ) when compared to the control group.

The ratios between the length and width of the pelvis and pelvic canal (C/A:  $P=0.00$ , C/H:  $P=0.00$ , F/H:  $P=0.04$ ) were significantly smaller in English bulldogs as compared to control dogs. Furthermore, the caudal pelvic aperture (Ia/H:  $P=0.01$ , Ib/H:  $P=0.02$ ) in English bulldogs measured significantly smaller when compared to the control dogs. However, no significant difference for the pelvic inlet dimensions (E/H) was found between the groups ( $P=0.66$ ).

Weight and gender effects on the individual pelvic measurements were recorded. Gender was found to have a significant effect on measures of the pelvic inlet (E, H), length (C) of the pelvis and lengths and heights (F) of the pelvic canal and the ratios (C/A, C/H). Weight had a significant effect on all measures of pelvic size. A regression coefficient for weight was provided if no interaction with gender was present.

Comparing English bulldogs with the 15 lightest non-brachycephalic dogs, shows similar results as from the complete dataset: English bulldogs had a significantly ( $P \leq 0.00$ ) shorter pelvis (C) and pelvic canal (D, F) and a narrower pelvis (A, B), pelvic inlet (E, Ga, Gb, H) and pelvic outlet (Ia, Ib).

**Table 1**

Means, their standard deviations and final ANCOVA statistical results for each individual pelvic measurement corrected for weight and/or gender. The measurements (A–Ib) are illustrated in Fig. 1.

Pelvic Measurements (mm)		English Bulldogs (N = 40)	Other breeds (N = 30)	Estimated difference between group means	P-value
		Mean ± SD	Mean ± SD	95% confidence interval upper bound, lower bound	
Width	A	77 ± 4	84 ± 6	6.94, 2.85	0,00
	B	87 ± 4	113 ± 9	26.75, 21.49	0,00
Length	C	105 ± 6	130 ± 9	26.09, 20.28	0,00
	D	38 ± 2	50 ± 5	13.70, 10.54	0,00
Cranial Conjugate	E	59 ± 5	69 ± 6	11.72, 6.60	0,00
Caudal Conjugate	F	91 ± 5	106 ± 8	16.01, 10.25	0,00
Cranial Pelvic Aperture	Ga	56 ± 3	65 ± 5	9.98, 6.58	0,00
	Gb	57 ± 3	66 ± 4	9.71, 6.59	0,00
	H	50 ± 3	55 ± 4	6.03, 3.27	0,00
Caudal Pelvic Aperture	Ia	72 ± 4	83 ± 7	13.36, 8.24	0,00
	Ib	72 ± 4	83 ± 7	12.95, 7.71	0,00
Ratio Length/Width	C/A	1.4 ± 0.1	1.6 ± 0.1	0.24, 0.16	0,00
	C/H	2.0 ± 0.1	2.3 ± 0.1	0.30, 0.19	0,00
	F/H	1.8 ± 0.2	1.9 ± 0.1	0.15, 0.01	0,036
Ratio Caudal Pelvic Aperture	Ia/H	1.4 ± 0.1	1.5 ± 0.1	0.13, 0.02	0,01
	Ib/H	1.5 ± 0.1	1.5 ± 0.1	0.12, 0.01	0,024
Ratio Pelvic Inlet	E/H	1.2 ± 0.1	1.3 ± 0.1	0.12, <0.00	0,66

#### 4. Discussion

Our CT pelvimetric results demonstrate that English bulldogs have a significantly smaller pelvis and pelvic canal when compared to non-brachycephalic dogs of the same weight range. Additionally, the pelvic conformation of English bulldogs in our study was characterized by a significantly shorter pelvis and pelvic canal and a significantly narrower caudal pelvic aperture.

To the authors' knowledge, our paper is the first CT pelvimetric study in English bulldogs. As described in earlier studies, CT has proven to be an excellent technique for three-dimensional assessment of canine pelvic size and conformation. Computed tomographic pelvimetry has been reported a useful tool in people for the assessment of cephalopelvic disproportion [21] and has been performed in German shepherd dogs based on scout-view images, in rabbits and post mortem in cows [17–19]. Radiographic pelvimetry has been reported to be a useful method in dogs to assess the role of the pelvic anatomy in obstructive dystocia [1]. The distortion encountered with the radiographic technique, when assessing a large 3D structure as the pelvis, can be overcome using CT. Therefore, measurements acquired on the pelvis are deemed more precise. In addition, CT offers the possibility of acquiring measurements in 3D without superimposition of other anatomic structures. The measurement of the caudal pelvic aperture (Ia, Ib) follows the oblique course of the sacrotuberous ligament traversing 3 planes and cannot be accurately represented with a 2D technique such as radiography.

Anatomic landmarks, as conventionally established for the obstetric assessment of the pelvis [20], were clearly identified on CT reconstructions and all measurements could be obtained. Although, challenges were encountered identifying the base of the transverse process of the first coccygeal vertebra in one third of the English bulldogs due to the breed specific corkscrew shaped tail. Therefore, application of the caudal pelvic aperture (Ia, Ib) measurements may be limited as a reference value. Performance of the measurements by a single observer that was aware of the group distribution was not expected to affect the outcome. A previous study on CT pelvimetry in bovine cadavers showed excellent repeatability of the measurements [17]. It was not an objective of our study to evaluate the interobserver agreement.

A significant effect of gender on the pelvic dimensions was found for the length (C), cranial (E) and caudal (F) conjugate, and transverse diameter of the pelvic inlet (H), these are listed in table

2. Gender specific conformational differences were previously reported in cats, where male cats had generally larger pelvic measurements [10]. This correlation was not found in our study. The gender with the largest measurement varied between the above-mentioned dimensions and no significant gender effect was found on the remaining measurements.

Body biometrics have been demonstrated to be useful in predicting internal pelvic measurements, as some measurements are positively correlated with weight [22]. However, weight as selection criterion for the control group may be a limiting factor since it is not representative of the proportionate body size and is dependent on the body condition score which was not available for our study population. The significantly smaller pelvis of English bulldogs for all measurements may have been enhanced by their stocky, muscular body conformation, which makes them proportionate heavy for their body size. However, comparing the English bulldog pelvises to the 15 lightest dogs of the control group resulted in persistently significantly smaller pelvises of the English bulldog group. Another attempt to overcome this limitation was to obtain ratios of the pelvic measurements. These revealed a significantly shorter pelvis of English bulldogs and a significantly smaller pelvic outlet.

Our control group was composed of non-brachycephalic dogs. Inclusion criteria as non-brachycephalic breed were based on the classification reported in literature [23–25]. These classify dogs as brachycephalic, mesaticephalic or dolichocephalic by applying widely accepted craniometric discrimination indices [20]. The most represented breed in the control group was the Labrador retriever (17%). It remains possible that this has introduced some bias towards a direct interbreed comparison. Inclusion of cross-breed dogs in the non-brachycephalic group may have introduced a bias towards a more brachycephalic pelvic conformation. However, this impact is considered of minor relevance given the significant difference in pelvic size between both groups.

The significant effect of weight on the majority of the pelvic measurements indicated that pelvic measurements are influenced by weight and heavier dogs are likely to have a larger pelvis. Including a body condition score and external size measurements could be useful for further characterization of this correlation.

The correlation between pelvic conformation of the bitch and dystocia due to fetopelvic disproportion has been studied in two terrier breeds highly predisposed for dystocia. It showed that Scottish terrier bitches with a lighter, lower and shorter body type



are more predisposed to experience dystocia and a dorsoventrally flattened pelvic canal is significantly related to obstructive dystocia in Scottish terrier bitches [1]. A combination of a dorsoventrally flattened pelvic canal and big fetuses with large heads was found as main predisposing factor for obstructive dystocia in the Boston terrier [1]. However, no comparison was made with pelvises of other breeds. Our findings did not reveal a significantly dorsoventrally flattened conformation of the English bulldog pelvis. We could prove that the main conformational alterations were a shortening of the pelvis and a narrower pelvic outlet. The measurements of the pelvic outlet represent the course of the sacrotuberal ligament bilaterally, which is expected to widen during passage of the foetus. The possibility remains that the widening of the sacrotuberal ligament intrapartum may not be sufficient to compensate for its significantly reduced length. Nevertheless, the effect of a narrower pelvic outlet on the probability of occurrence of dystocia remains to be proven.

Considering to the very high rate of elective caesarean sections in the English bulldog [13], no information on natural breeding performance of the bitches and bitches paired with the male dogs included in our study could be obtained. Therefore, no conclusions regarding our results and a relation to possible occurrence of obstructive dystocia can be drawn.

Characteristics of the pelvic shape are inherited from either the maternal or the paternal side [26]. The pelvic cavity of the proposed breeding pair should be large enough to allow passage of foetuses during parturition. As part of the pre-mating consultation, the pelvic capacity of the proposed breeding pair can be estimated by external indication of the pelvic size. The distance between the wings of the ilia and the distance between the tubera ischiadica are used as external indication of the pelvic capacity [2]. We propose that the obtained data for these measurements in our study may serve as a baseline for direct and indirect pelvimetry in English bulldogs for breeding purposes.

The narrow geographic range of our sample of the English bulldogs' population may be a limiting factor since all recruited dogs were from the Dutch English bulldog Club. The obtained measurements may be representative for certain families of the breed and may differ from pelvises of other English bulldogs. However, a recent study on the genetics of the American English bulldog population suggests that the genetic diversity is extremely low resulting from a small founder population and pedigree imposed bottlenecks [27]. Therefore, our results obtained in a sample population of the English bulldog breed may also apply to the general English bulldog population.

In conclusion, the results of our study proved that English bulldogs have generally smaller pelvises with a shorter conformation and narrower pelvic outlet than non-brachycephalic dogs. Additionally, CT pelvimetric reference values in a sample of the English bulldog population were established. They could potentially serve as a reference for external measurements in the assessment of the pelvic capacity for breeding purposes.

A relation between the individual pelvic measurements and the incidence of obstructive dystocia should be the topic of future studies evaluating the predictive value of CT pelvimetry. Prospective studies in collaboration with the English Bulldog Kennel Clubs allowing a natural birth are needed to evaluate the heredity of pelvic size and the effect of selective breeding for a larger pelvic canal on the incidence of obstructive dystocia.

## Funding

This research did not receive any specific grant from funding agencies in the public, commercial, or not-for-profit sectors.

## Declaration of interests

None.

## List of author contributions

Conception and design: T.P. Dobak, G. Voorhout, S.A.E.B. Boroffka.

Acquisition of data: T.P. Dobak, G. Voorhout.

Analysis and interpretation of data: T.P. Dobak, G. Voorhout, J.C.M. Vernooij.

Drafting the article: T.P. Dobak.

Revising article for intellectual content: T.P. Dobak, G. Voorhout, J.C.M. Vernooij, S.A.E.B. Boroffka.

Final approval of the completed article: T.P. Dobak, G. Voorhout, J.C.M. Vernooij, S.A.E.B. Boroffka.

## Acknowledgments

The authors would like to acknowledge the Dutch English Bulldog Club (Engelse Bulldog Club Nederland E.B.C.N.) for their participation and the Dutch Kennel Club (DE.120470.2.99) (Raad van Beheer) for the financial support of the study. Ralph A. Edwards is greatly acknowledged for proofreading.

## Appendix A. Supplementary data

Supplementary data related to this article can be found at <https://doi.org/10.1016/j.theriogenology.2018.05.025>.

## References

- [1] Eneroth A, Forsberg CL. Radiographic pelvimetry for assessment of dystocia in bitches: a clinical study in two terrier breeds. *J Small Anim Pract* 1999;40: 257–64.
- [2] Jackson PGG. Handbook of veterinary obstetrics. second ed. Philadelphia: WB Saunders; 2004. p. 141–66.
- [3] Linde-Forsberg CL, Eneroth A. Textbook of veterinary obstetrics. London: WB Saunders Co; 2005. p. 1655–67.
- [4] Darvelid AW, Linde-Forsberg CL. Dystocia in the bitch: a retrospective study of 182 cases. *J Small Anim Pract* 1994;35:402–7.
- [5] Freak MJ. The whelping bitch. *Vet Rec* 1948;60:295–301.
- [6] Freak MJ. Practitioners'-breeders' approach to canine parturition. *Vet Rec* 1975;96:303–8.
- [7] Bennett D. Current therapy in theriogenology. Philadelphia: WB Saunders; 1980. p. 595–606.
- [8] Jones DE, Joshua JO. Reproductive clinical problems in the dog. second ed. London: Wright; 1988. p. 87–112.
- [9] Gunn-Moore DA, Thrusfield MV. Feline dystocia: prevalence and association with cranial conformation and breed. *Vet Rec* 1995;136:350–3.
- [10] Monteiro C, Campos A, Madeira V, Silva H. Pelvic differences between brachycephalic and mesaticephalic cats and indirect pelvimetry assessment. *Vet Rec* 2013;172:16.
- [11] Moon PF, Erb HN, Ludders JW, Gleed RD, Pascoe PJ. Perioperative management and mortality rates of dogs undergoing cesarean section in the United States and Canada. *J Am Vet Med Assoc* 1998;213:365–9.
- [12] Evans KM, Adams VJ. Proportion of litters of purebred dogs born by caesarean section. *J Small Anim Pract* 2010;51:113–8.
- [13] Wydooghe E, Berghmans E, Rijsselaere T, Van Soom A. International breeder inquiry into the reproduction of the English bulldog. *Vlaams Diergeneeskdt Tijdschr* 2013;82:38–43.
- [14] Cloete SWP, Haughey KG. Radiographic pelvimetry for the estimation of pelvic dimensions in merino, dorrner and SA mutton merino ewes. *J S Afr Vet Assoc* 1990;61:55–8.
- [15] Cloete SWP. Rearing performance of merino, SA mutton merino and dorrner ewes in relation to live mass, reproduction and pelvic dimensions. *J S Afr Vet Assoc* 1994;65:10–7.
- [16] Van Donkersgoed J. A critical analysis of pelvic measurements and dystocia in beef heifers. *Compend Contin Educ Vet - Food animals* 1992;14:405–7.
- [17] Ocal MK, Dabanoglu I, Kara ME, Turan E. Computed tomographic pelvimetry in German shepherd dogs. *Dtsch Tierarztl Wochenschr* 2003;110:17–20.
- [18] Özkadif S, Eken E, Kalaycı İA. Three-dimensional reconstructive study of pelvic cavity in the New Zealand rabbit (*Oryctolagus cuniculus*). *Sci World J* 2014;2014. <https://doi.org/10.1155/2014/489854>.
- [19] Tsousis G, Heun C, Becker M, Bollwein H. Application of computed

- tomography for the evaluation of obstetrically relevant pelvic parameters in German Holstein-Friesian cows.
- [20] Evans HE, de Lahunta A. *Miller's anatomy of the dog*. fourth ed. Philadelphia: WB Saunders; 2012.
- [21] Lenhard MS, Johnson TR, Weckbach S, Nikolaou K, Friese K, Hasbargen U. Pelvimetry revisited: analyzing cephalopelvic disproportion. *Eur J Radiol* 2010;74:107–11.
- [22] Campos AIM. Estabelecimento do padrão biométrico corpóreo e pélvico e da relação entre as medidas corpóreas externas e as medidas pelvimétricas de cadelas da raça Buldogue Francês. [Establishment of the pelvic and body biometric pattern and the relationship between the external body and pelvic measurements of female French bulldogs]. Master dissertation. Universidade Estadual do Ceará [Ceará State University]; 2010.
- [23] Hussein AK, Sullivan M, Penderis J. Effect of brachycephalic, mesaticephalic, and dolichocephalic head conformations on olfactory bulb angle and orientation in dogs as determined by use of in vivo magnetic resonance imaging. *Am J Vet Res* 2012;73:946–51.
- [24] Mielke B, Lam R, Haar Ter G. Computed tomographic morphometry of tympanic bulla shape and position in brachycephalic and mesaticephalic dog breeds. *Vet Radiol Ultrasound* 2017;58:552–8.
- [25] Schmidt MJ, Neumann AC, Amort KH, Failing K, Kramer M. Cephalometric measurements and determination of general skull type of Cavalier King Charles spaniels. *Vet Radiol Ultrasound* 2011;52:436–40.
- [26] Linde-Forsberg C. Pelvimetry to diagnose dystocia in the bitch. In: *Proceedings book. Proceedings of the 27th world small animal veterinary association world congress*. Granada, Spain; 2002. p. 591.
- [27] Pedersen NC, Pooch AS, Liu H. A genetic assessment of the English bulldog. *Canine Genet Epidemiol* 2016;3:6–22.