

SHORT REPORT

Constitutional mismatch repair deficiency in a healthy child: On the spot diagnosis?

M. Suerink¹  | T.P. Potjer¹ | A.B. Versluijs² | S.W. ten Broeke¹ | C.M. Tops¹ | K. Wimmer^{3†} | M. Nielsen^{1†}¹Department of Clinical Genetics, Leiden University Medical Centre, Leiden, The Netherlands²Department of Pediatric Hematology, University Medical Centre, Utrecht, The Netherlands³Division Human Genetics, Medical University of Innsbruck, Innsbruck, Austria

Correspondence

Dr Maartje Nielsen, Department of Clinical Genetics, Leiden University Medical Centre, Postbus 9600|2300 RC Leiden, The Netherlands.

Email: m.nielsen@lumc.nl

Funding information

Dutch Cancer Society, Grant/Award number: UL2012-5515

Constitutional mismatch repair deficiency (CMMRD) is a rare, recessively inherited childhood cancer predisposition syndrome caused by biallelic germline mutations in one of the mismatch repair genes. The CMMRD phenotype overlaps with that of neurofibromatosis type 1 (NF1), since many patients have multiple café-au-lait macules (CALM) and other NF1 signs, but no germline *NF1* mutations.

We report of a case of a healthy 6-year-old girl who fulfilled the diagnostic criteria of NF1 with >6 CALM and freckling. Since molecular genetic testing was unable to confirm the diagnosis of NF1 or Legius syndrome and the patient was a child of consanguineous parents, we suspected CMMRD and found a homozygous *PMS2* mutation that impairs MMR function.

Current guidelines advise testing for CMMRD only in cancer patients. However, this case illustrates that including CMMRD in the differential diagnosis in suspected sporadic NF1 without causative *NF1* or *SPRED1* mutations may facilitate identification of CMMRD prior to cancer development. We discuss the advantages and potential risks of this CMMRD testing scenario.

KEYWORDSbCMMRD, café-au-lait macules, CMMRD, hereditary cancer syndromes, HNPCC, Lynch syndrome, *PMS2*, recessive genetic conditions

1 | INTRODUCTION

Constitutional mismatch repair deficiency (CMMRD; MIM #276300) is a recessively inherited cancer predisposition syndrome caused by homozygous or compound heterozygous mutations in one of the mismatch repair (MMR) genes: *MLH1* (MIM *120436), *MSH2* (MIM *609309), *MSH6* (MIM *600678) and *PMS2* (MIM *600259). In a heterozygous state, MMR mutations lead to Lynch syndrome (LS; MIM #609310, #120435, #614350, #614337), causing a predisposition to develop mainly colorectal and endometrial cancer with an adult age at onset.¹ CMMRD has a more severe phenotype, with an extraordinarily high risk of developing a broad spectrum of different malignancies in childhood or adolescence,^{2,3} warranting rigorous surveillance measures.^{4–6}

Phenotypically, CMMRD overlaps with neurofibromatosis type 1 (NF1; MIM #162200) and Legius syndrome (MIM #611431). Six or

more café-au-lait macules (CALMs) and skinfold freckling, which are included in the NIH diagnostic criteria for NF1 (Table 1),^{7,8} are usually the first presenting sign in a child with NF1.⁹ At least 91/146 CMMRD patients were reported to have CALMs or hyperpigmented skin areas^{3,10} and signs reminiscent of NF1 are highly suggestive of CMMRD when present in a child with a non-NF1-associated malignancy. Therefore, NF1 signs, as well as other non-neoplastic features such as consanguinity of the parents, are included as criteria in a scoring system developed to raise the clinical suspicion of CMMRD among cancer patients.²

Due to phenotypic overlap, several CMMRD patients have been misdiagnosed with NF1 prior to development of their first malignancy. Earlier diagnosis of CMMRD in these patients might have led to prevention or diagnosis at an earlier stage of the malignancy. However, no guidance is currently available on when to consider CMMRD as a differential diagnosis in a (healthy) child referred for genetic testing due to ≥6 CALMs and/or other signs of NF1 but negative for *NF1*

†These authors contributed equally to this work.

TABLE 1 Adapted NIH diagnostic criteria for NF1^a

Clinical diagnosis based on presence of 2 of the following:
1. Six or more café-au-lait macules, over 5 mm in diameter, in prepubertal individuals and over 15 mm in greatest diameter in postpubertal individuals.
2. Two or more neurofibromas of any type or one plexiform neurofibroma.
3. Freckling in the axillary or inguinal regions.
4. Two or more Lisch nodules (iris hamartomas).
5. Optic glioma.
6. A distinctive osseous lesion such as sphenoid dysplasia or thinning of long bone cortex, with or without pseudarthrosis.
7. A parent or offspring with NF1 by above criteria. ^a

^a Changed according to the suggestions of Huson.⁸ Original diagnostic criteria stated "A first-degree relative (parent, sibling, or offspring) with NF1 by above criteria."⁷

or *SPRED1* mutations. Here we report of a girl, fulfilling the NF1 criteria, without a history of (pre)malignancies. Since she is the offspring of a consanguineous marriage, CMMRD was suspected after *NF1* and *SPRED1* testing rendered negative results. This diagnosis was confirmed by identifying a homozygous *PMS2* mutation.

2 | CASE

A 3-year-old girl, the child of first cousins, was referred by her pediatrician for genetic evaluation. With more than 6 CALMs (size between 1.5 and 2.5 cm) and freckling under the left axilla, she fulfilled the clinical criteria for NF1 (Figure 1). Prior to her referral to our department, analysis of *NF1* and *SPRED1* was performed by Sanger sequencing from genomic DNA and multiplex ligation dependent probe amplification (MLPA), but no mutations were found. To further rule out any gross chromosomal rearrangements involving the *NF1* locus on chromosome 17 we performed karyotyping. Both parents

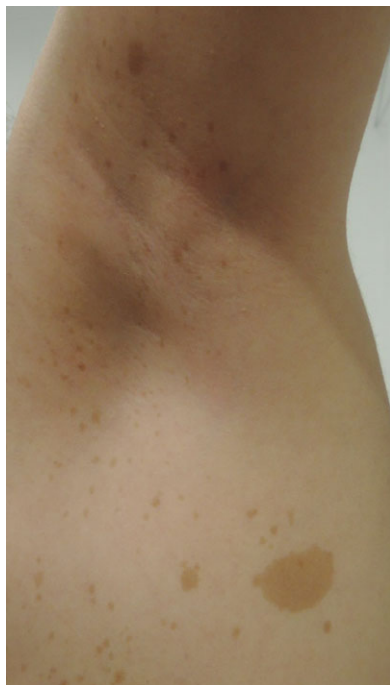

FIGURE 1 Axillary freckling and a café-au-lait macule in the child. [Color figure can be viewed at wileyonlinelibrary.com]

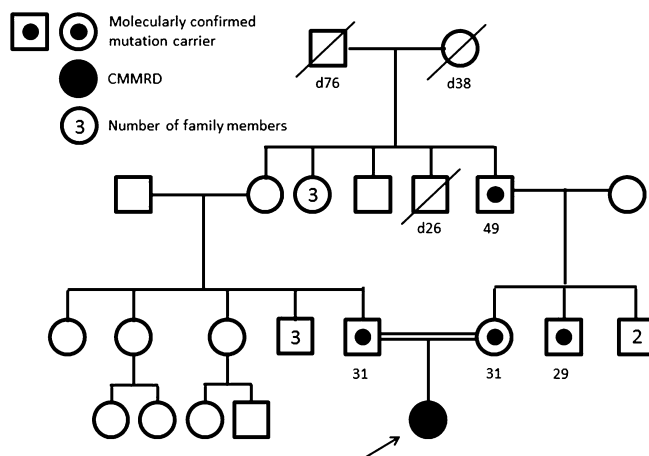


FIGURE 2 Pedigree of the family

were referred to a dermatologist and ophthalmologist, but neither showed clinical signs of neurofibromatosis.

Two years later, when the child returned for re-evaluation, we decided to offer testing for CMMRD despite the lack of a personal history of cancer and a 4-generation family history negative for malignancies (Figure 2). Since *PMS2* is the most commonly mutated gene in CMMRD,³ it was analyzed first and a homozygous mutation (c.2444C>T, p.Ser815Leu) was detected. Both parents proved to be heterozygous for the mutation. This mutation, reported to the Leiden Open Variation Database (<http://PMS2.lovd.nl>), was previously identified in 3 suspected LS patients with *PMS2*-expression loss in their tumor tissues. It is predicted to be deleterious by aGVGD and SIFT and an in vitro MMR-assay clearly showed loss of MMR-capacity.¹¹ Hence, it was accepted as the disease-causing mutation in these 3 LS patients, although it should be noted that one of the patients carried an additional variant of unknown significance (VUS) in *PMS2*.¹¹ To further substantiate that this mutation causes CMMRD when present in a homozygous state, we performed germline MSI (gMSI) analysis in our patient's leucocyte DNA.¹² All analyzed markers showed increased gMSI ratios when compared to laboratory-specific thresholds (mean +3 standard deviations of 80-90 control DNAs) supporting the CMMRD diagnosis.

Following diagnosis, our patient was offered screening in accordance with the recommendations of the C4CMMRD consortium.⁶ By this time, aged 6, she has undergone brain MRI, ultrasound of the abdomen and a blood count, all without identified abnormalities. Immunology results showed an isolated IgG4 deficiency (<0.01 g/L). IgA, IgG2 and IgG4 deficiency has previously been described in CMMRD patients and is a diagnostic criterion in the C4CMMRD scoring system.^{3,13} However, since isolated IgG4 deficiency is found in up to 15% of healthy children,¹⁴ this finding in our patient may be unrelated to CMMRD.

In accordance with the LS surveillance protocol, both parents underwent colonoscopies but no abnormalities were found.

3 | DISCUSSION

This is the first report of CMMRD diagnosis in a child with no personal or family history of malignancies but fulfilling the diagnostic

criteria for NF1. This case illustrates that CMMRD syndrome should be included in the differential diagnosis of children suspect for NF1, but without *NF1* or *SPRED1* mutations.

Given that there were no precedents for this particular case, the decision to offer testing for CMMRD was taken after intensive discussion within our team of the benefits and potential problems in the context of pre-symptomatic (with respect to tumor development) testing for CMMRD. A strong motivation to perform testing was the opportunity to offer surveillance. This includes brain MRI (warranting anesthesia in infants) and colonoscopy, and therefore represents a substantial burden to the patient.^{4,6} Furthermore, the effectiveness of surveillance has only been evaluated in a small number of CMMRD patients.⁴ Given that our current estimates of CMMRD cancer risks may be subject to ascertainment bias, and attenuated forms of CMMRD have been reported,¹⁵ the justification for the proposed surveillance protocols in a case without a personal and family history of cancer can be legitimately questioned. However, even in light of these reservations, we would argue that it is prudent to assume that the cancer risk in CMMRD is very substantial and therefore justifies subjecting the patient to an extensive program of surveillance.

Family planning was another issue that was taken into account when we considered pre-symptomatic testing, since the parents of our patient plan to have more children in the future. Early CMMRD diagnosis enables timely counseling of the parents regarding the 25% recurrence risk for siblings, thus giving the parents the opportunity to consider prenatal or pre-implantation genetic diagnostics.

A possible outcome of mutation analysis in any gene is the identification of a VUS. Typically in such cases, clinical management would take into account personal or family history of cancer. Due to the absence of a cancer history, predictive testing for CMMRD by mutation analysis can be seen as a special case. In particular, the identification of a homozygous VUS or a heterozygous VUS together with a clearly pathogenic MMR mutation will cause uncertainty regarding the correct diagnosis and, consequently, poses a serious problem in the appropriate management of the patient. *PMS2* variant p.Ser815Leu is still classified as a VUS class 3 under the Insight variant classification system (<http://www.insight-database.org/classifications/index.html>). Only the recent functional testing of this variant allowed us to classify it as pathogenic.¹¹ Parents should be made aware of the possibility of an uncertain outcome before initiating CMMRD diagnostics and the diagnostic lab should be prepared to undertake any measure necessary to definitely confirm or exclude a diagnosis of CMMRD in this situation. To reduce the risk of this problem arising, one option would be to offer MMR mutation analysis only when pre-screening with immunohistochemical staining of skin biopsies (for the presence of the 4 MMR-proteins) and/or gMSI testing (known to be insensitive in biallelic *MSH6* mutation carriers) provide substantial support for a diagnosis of CMMRD.^{5,12,16}

The diagnosis of CMMRD in a child also entails diagnosing parents and other family members with LS and thus having an increased risk of developing a tumor within the LS spectrum. Extensive investigation of LS surveillance has shown that it is effective.¹⁷ However, absence of a family history of cancer has frequently been observed in CMMRD patients³ and especially heterozygous *PMS2* mutations may confer a lower cancer risk than mutations identified in classical LS

families.¹⁸ LS surveillance protocols might therefore be adapted once more evidence has been gathered on cancer risks for these family members. For the time being, our patient's family members will be offered surveillance according to national guidelines (<http://www.oncoline.nl/erfelijke-darmkanker>), which recommend colonoscopy every 2 years from the age of 25, gynecologic surveillance from the age of 40 and, if necessary, eradication of *Helicobacter pylori* infection.

No recommendations are currently available that offer guidance on when to consider CMMRD testing in children with CALMs but lacking *NF1* or *SPRED1* mutations. In around 15% to 20% of sporadic patients meeting NF1 criteria no pathogenic *NF1* or *SPRED1* mutation is identified.^{9,19} Hence, CMMRD may be considered in a considerable number of children, even though CMMRD is rarely diagnosed. The estimated carrier frequencies for mutations in the MMR-genes (1 in 1946 for *MLH1*, 1 in 2841 for *MSH2*, 1 in 758 for *MSH6* and 1 in 714 for *PMS2*)²⁰ imply that CMMRD incidence should be about 1 per million. True incidence is probably somewhat higher, particularly among children with consanguineous parents.^{3,21}

The low incidence of CMMRD combined with the severity of the disease means that a delicate balance must be struck when considering pre-symptomatic testing. In our department we now consider pre-symptomatic testing if there are, in addition to CALMs, other indicators of CMMRD such as consanguinity or a positive family history of cancer. Other features included in the criteria that may raise the suspicion of CMMRD in a cancer patient,³ for example multiple pilomatricomas, may also be taken into consideration as indicators. With this case report we wish to highlight the need for national and international discussion and consensus on this question.

ACKNOWLEDGEMENTS

The work was supported by the Dutch Cancer Society (UL2012-5515). The authors thank Medactie.com for help with editing of this paper.

Conflict of interest

The authors have no conflict of interests to report.

Ethics approval

Investigations were performed in the course of routine clinical care. No new patient samples were required.

ORCID

M. Suerink  <http://orcid.org/0000-0001-7058-6973>

REFERENCES

1. Stoffel E, Mukherjee B, Raymond VM, et al. Calculation of risk of colorectal and endometrial cancer among patients with Lynch syndrome. *Gastroenterology*. 2009;137(5):1621-1627.
2. Wimmer K, Etzler J. Constitutional mismatch repair-deficiency syndrome: have we so far seen only the tip of an iceberg? *Hum Genet*. 2008;124(2):105-122.
3. Wimmer K, Kratz CP, Vasen HF, et al. Diagnostic criteria for constitutional mismatch repair deficiency syndrome: suggestions of the European consortium 'care for CMMRD' (C4CMMRD). *J Med Genet*. 2014;51(6):355-365.

4. Durno CA, Aronson M, Tabori U, Malkin D, Gallinger S, Chan HS. Oncologic surveillance for subjects with biallelic mismatch repair gene mutations: 10 year follow-up of a kindred. *Pediatr Blood Cancer*. 2012;59(4):652-656.
5. Durno CA, Sherman PM, Aronson M, et al. Phenotypic and genotypic characterisation of biallelic mismatch repair deficiency (BMMR-D) syndrome. *Eur J Cancer*. 2015;51(8):977-983.
6. Vasen HF, Ghorbanoghli Z, Bourdeaut F, et al. Guidelines for surveillance of individuals with constitutional mismatch repair-deficiency proposed by the European Consortium "Care for CMMR-D" (C4CMMR-D). *J Med Genet*. 2014;51(5):283-293.
7. National Institutes of Health Consensus Development Conference. Neurofibromatosis. *Arch Neurol*. 1988;45(5):575-578.
8. Huson S. The neurofibromatoses: classification, clinical features and genetic counselling. In: Kaufmann D, ed. *Neurofibromatoses*. Vol 16. Basel: Karger; 2008:1-20.
9. Messiaen L, Yao S, Brems H, et al. Clinical and mutational spectrum of neurofibromatosis type 1-like syndrome. *JAMA*. 2009;302(19):2111-2118.
10. Wimmer K, Rosenbaum T, Messiaen L. Connections between constitutional mismatch repair deficiency syndrome and neurofibromatosis type 1. *Clin Genet*. 2017;91:507-519.
11. van der Klift HM, Mensenkamp AR, Drost M, et al. Comprehensive mutation analysis of PMS2 in a large cohort of probands suspected of Lynch syndrome or constitutional mismatch repair deficiency (CMMRD) syndrome. *Hum Mutat*. 2016;37:1162-1179.
12. Ingham D, Diggle CP, Berry I, et al. Simple detection of germline microsatellite instability for diagnosis of constitutional mismatch repair cancer syndrome. *Hum Mutat*. 2013;34(6):847-852.
13. Peron S, Metin A, Gardes P, et al. Human PMS2 deficiency is associated with impaired immunoglobulin class switch recombination. *J Exp Med*. 2008;205(11):2465-2472.
14. Buckley RH. Immunoglobulin G subclass deficiency: fact or fancy? *Curr Allergy Asthma Rep*. 2002;2(5):356-360.
15. Li L, Hamel N, Baker K, et al. A homozygous PMS2 founder mutation with an attenuated constitutional mismatch repair deficiency phenotype. *J Med Genet*. 2015;52(5):348-352.
16. Bakry D, Aronson M, Durno C, et al. Genetic and clinical determinants of constitutional mismatch repair deficiency syndrome: report from the constitutional mismatch repair deficiency consortium. *Eur J Cancer*. 2014;50(5):987-996.
17. de Vos tot Nederveen Cappel WH, Jarvinen HJ, Lynch PM, Engel C, Mecklin JP, Vasen HF. Colorectal surveillance in Lynch syndrome families. *Fam Cancer*. 2013;12(2):261-265.
18. Broeke SW, Brohet RM, Tops CM, et al. Lynch syndrome caused by germline PMS2 mutations: delineating the cancer risk. *J Clin Oncol*. 2015;33(4):319-325.
19. van Minkelen R, van Bever Y, Kromosoeto JN, et al. A clinical and genetic overview of 18 years neurofibromatosis type 1 molecular diagnostics in the Netherlands. *Clin Genet*. 2014;85(4):318-327.
20. Win AK, Jenkins MA, Dowty JG, et al. Prevalence and penetrance of major genes and polygenes for colorectal cancer. Cancer epidemiology, biomarkers & prevention : a publication of the American Association for Cancer Research, cosponsored by the American Society of Preventive Oncology. 2016.
21. Amayiri N, Tabori U, Campbell B, et al. High frequency of mismatch repair deficiency among pediatric high grade gliomas in Jordan. *J Int Cancer*. 2016;138(2):380-385.

How to cite this article: Suerink M, Potjer TP, Versluijs AB, et al. Constitutional mismatch repair deficiency in a healthy child: On the spot diagnosis? *Clin Genet*. 2018;93:134-137. <https://doi.org/10.1111/cge.13053>