Interactive CardioVascular and Thoracic Surgery 24 (2017) 980–981
doi:10.1093/icvts/ivx042 Advance Access publication 23 February 2017

CASE REPORT

Cite this article as: Schrijver IT, Luijk B, Meijer RC, de Heer LM. Successful treatment of bronchial stenosis after lung transplantation. Interact CardioVasc Thorac Surg 2017;24:980–1.

Successful treatment of bronchial stenosis after lung transplantation

Irene T. Schrijver[a], Bart Luijk[a], Ronald C.A. Meijer[b] and Linda M. de Heer[b,*]

[a] Department of Pulmonology, University Medical Central Utrecht, Netherlands
[b] Department of Cardiothoracic Surgery, University Medical Center Utrecht, Netherlands

* Corresponding author. Department of Cardiothoracic Surgery, University Medical Center Utrecht, PO box 85500, 3508 GA Utrecht, Netherlands. Tel: +31-88-7556179; fax: +31-88-7555058; e-mail: l.m.deheer-3@umcutrecht.nl (L.M. de Heer).

Received 11 December 2016; received in revised form 16 January 2017; accepted 23 January 2017

Abstract

Treatment of stenotic anastomosis after lung transplantation can be challenging. In this case report, we present a case in which 3D computed tomography reconstructions guided the clinical decision towards operative bronchoplasty after which our patient was treated successfully.

Keywords: Lung transplantation • Stenotic anastomosis • 3D CT • Bronchoplasty • Pleuroparenchymal fibroelastosis

CASE REPORT

In May 2015, a 62-year-old woman underwent bilateral sequential lung transplantation for end-stage respiratory disease due to pleuroparenchymal fibroelastosis. Immunosuppression was directly initiated after transplantation using tacrolimus, mycophenolic acid and prednisone. The first period post-transplantation was complicated due to paroxysmal atrial fibrillation and the presence of airway colonization with *Pseudomonas aeruginosa* and *Aspergillus fumigatus* for which nebulized colistin and voriconazole were administered. Two months later, the patient presented with dyspnoea and stridor. Bronchoscopy revealed stenosis of the left main bronchial anastomosis showing stenotic area covering more than 50% of the ostium. She underwent laser bronchoscopy twice. The stricture relapsed within 3 months both times. A computed tomography (CT) scan (256-slice, Philips Medical, Best, The Netherlands) showed a 4.7-mm stenosis (Fig. 1). The 3D CT images show a circumscribed lesion with enough space for partial resection of the left main bronchus and re-anastomosis. This, in combination with the failure of the endoscopic treatment, led us to decide on a surgical approach in December 2015.

Through a left posterolateral thoracotomy, the previous anastomosis in the left main bronchus was isolated and exposed. After removal of 1–1.5 cm of the bronchus, an end-to-end anastomosis was made. Histological findings at the level of the stenosis revealed stenosis with scarring and focal ulceration (Fig. 2). The postoperative clinical course was complicated by a *Pseudomonas* airway infection that needed antibiotic treatment. She was discharged on postoperative Day 17. Two months postoperative, the patient's symptoms of dyspnoea were gone, her exercise tolerance was increased and her lung function parameters were improved. Postoperative re-evaluation by bronchoscopy and CT scan showed optimal healing of the anastomosis without stenosis (Fig. 2).

COMMENT

In all, 13–16% of patients after lung transplantation develop stenotic anastomosis in need of intervention [1].

This complication has high morbidity and mortality. Unfortunately, management of stenotic anastomosis can be challenging, and treatment differs among centres. Return of the anastomotic stricture is common with a 2-year relapsing rate of 35% after the first treatment and 70% after treatment of a second structure [2].

Risk factors of stenotic anastomosis include length of stay after lung transplantation, a postoperative tracheostomy and time to first fungal infection [1]. Also it has been reported that an increased length of donor bronchus may increase the risk of developing donor ischaemia, which consequently could lead to anastomotic stenosis [3].

3D CT has been shown to modify both radiology reports as surgery plans in more than 60% of complex cardiothoracic cases [4]. In case of stenotic anastomosis, 3D CT imaging can display the length and placement of the stricture and is therefore very beneficial in clinical decision making. Our patient had multiple risk factors, such as a longer length of stay and a fungal infection in the first period post-transplantation. The 3D CT showing an increased length of the donor bronchus and the detailed information of the circumscribed stenotic area and the possibility for re-anastomosis ultimately guided our decision towards a surgical approach.

Our case shows detailed 3D CT images pre- and post-surgery of a case of relapsing stenotic anastomosis. It underlines the

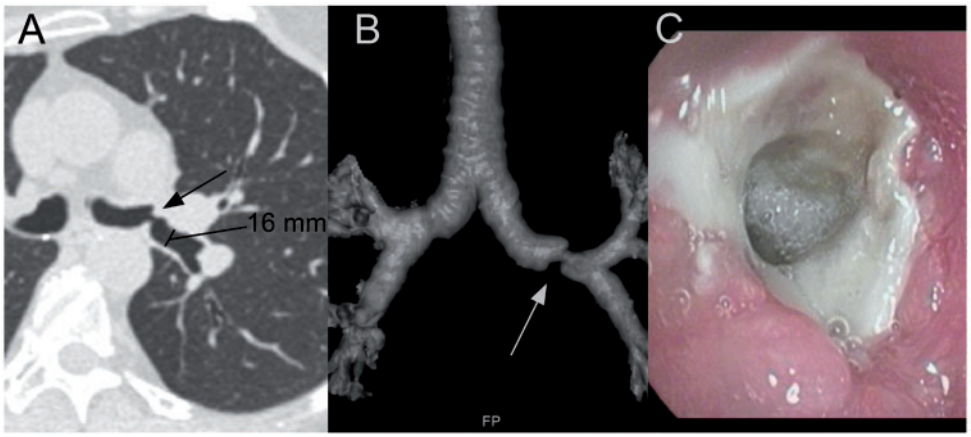

Figure 1: (**A**) Axial CT image of the left main bronchus stenosis; (**B**) 3D volume-rendered image, arrow indicates stenosis; and (**C**) bronchoscopy of the left main bronchus.

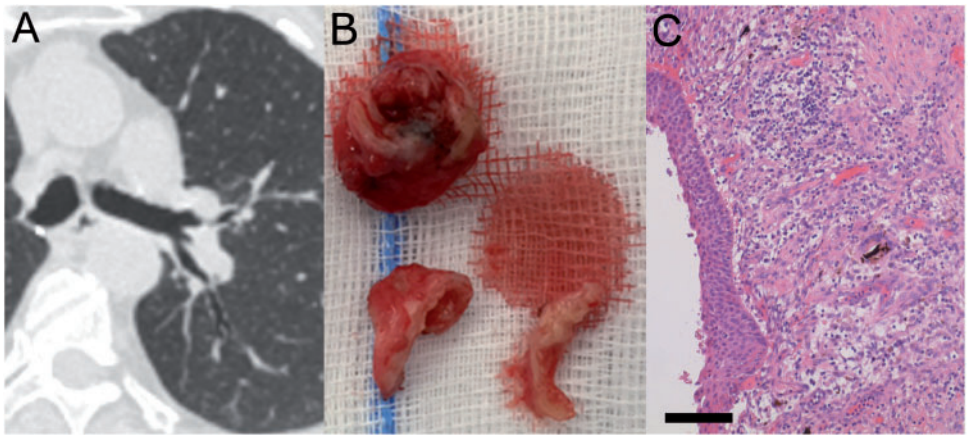

Figure 2: (**A**) CT scan 2 months postoperative; (**B**) gross of bronchial stenosis; and (**C**) histology, movatpentachrome stain, showing chronic inflammation with some foreign body giant cells and scar tissue. Bar 46 = 100 μm.

importance of 3D CT reconstructions in choosing the right treatment in complex cardiothoracic cases.

ACKNOWLEDGEMENTS

The authors would like to thank Aryan Vink for the histological assessment and Pim A. de Jong for the CT imaging and assessment.

Conflict of interest: none declared.

REFERENCES

[1] Shofer SL, Wahidi MM, Davis WA, Palmer SM, Hartwig MG, Lu Y *et al.* Significance of and risk factors for the development of central airway stenosis after lung transplantation. Am J Transplant 2013;13:383–9.

[2] Murthy, SC, Blackstone, EH, Gildea, TR, Gonzalez-Stawinski GV, Feng J, Budev FJ *et al.* Impact of anastomotic airway complications after lung transplantation. Ann Thorac Surg 2007;84:401–9.

[3] van Berkel V, Guthrie TJ, Puri V, Krupnick AS, Kreisel D, Patterson GA *et al.* Impact of anastomotic techniques on airway complications after lung transplant. Ann Thorac Surg 2011;92:316–20; discussion 320–1.

[4] Hemminger BM, Molina PL, Egan TM, Detterbeck FC, Muller KE, Coffey CS *et al.* Assessment of real-time 3D visualization for cardiothoracic diagnostic evaluation and surgery planning. J Digit Imaging 2005;18:145–53.