



Hanneke Hermans DVM,
Dipl.ECVS,
Tijn J.P. Spoomakers DVM,
Dipl.ECVS,
Jos M. Ensink DVM, PhD
Dipl.ECVS,
Michael H. Boevé DVM, PhD
Dipl.ECVO

Utrecht University, Faculty
of Veterinary Medicine,
Department of Equine
Sciences, Yalelaan 112,
3584CM Utrecht
The Netherlands

h.hermans@uu.nl

EQUINE KERATOMYCOSIS IN THE NETHERLANDS FROM 2007 TO 2017 (28 CASES)

Equine keratomycosis or fungal keratitis is a relatively common sight-threatening corneal disease in horses, particularly in warm, humid climates. Clinical manifestation includes corneal ulceration with or without corneal melting, microerosions, fungal plaque and stromal abscess.

Aim of the study

To determine clinical signs, diagnostic methods, predominant fungal isolates, treatment modalities and outcome of horses with keratomycosis in the Netherlands.

Material and Methods

Records of horses presented to the University of Utrecht, Equine Department suspected with keratomycosis between 2007 and 2017 were reviewed for this retrospective study. Information retrieved from the records included breed, ophthalmic examination findings, further diagnostics, treatment prior to and following presentation, and outcome.

Results

28 Horses were suspected with keratomycosis by ophthalmic examination over a 10 year time period. No breed predilection was apparent. All horses had received either topical antibiotics or topical corticosteroids pre-referral. Ophthalmic examination showed corneal edema without ulceration (1/28), cornea ulceration (12/28; Fig 1.) or stromal abscess (15/28; Fig 2.).

In 13 cases only a presumptive diagnosis was made by the ophthalmic findings of which 12/13 cases had a stromal abscess with an intact epithelium. In 15 cases keratomycosis was confirmed by fungal culture (13/15) and/or cytology (8/15). *Aspergillus* spp. was the most common isolate (92%). Treatment consisted of medication only (50%), medical combined with surgical treatment (32%), enucleation (11%) or euthanasia (7%). Miconazole was the topical antifungal medication utilized in all cases (100%). Globe retention was 88% (23/26). All cases that had follow-up available (12/26) developed corneal scarring (Fig 3).

Conclusion

Keratomycosis should be considered in horses presenting with keratitis (corneal edema, corneal ulceration and stromal abscess) in the Netherlands, with *Aspergillus* spp. being the most common isolate. It is a serious condition that commonly results in corneal ulceration and even corneal perforation, with loss of the globe. Definitive diagnosis of ulcerative keratomycosis depends on a positive fungal culture or identification of fungal hyphae on corneal cytology but is not always feasible due to the depth of the lesion (e.g. stromal abscess).

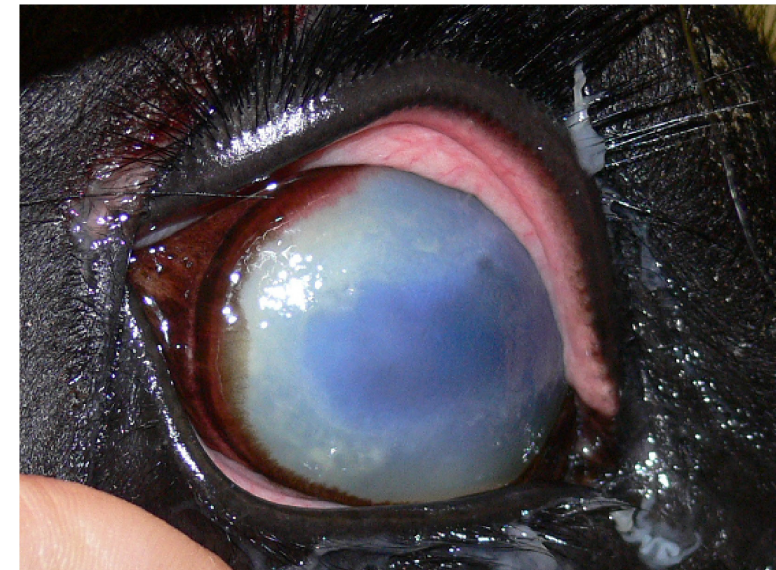


Fig 1. Corneal ulceration caused by equine keratomycosis (confirmed by cytology and fungal culture).

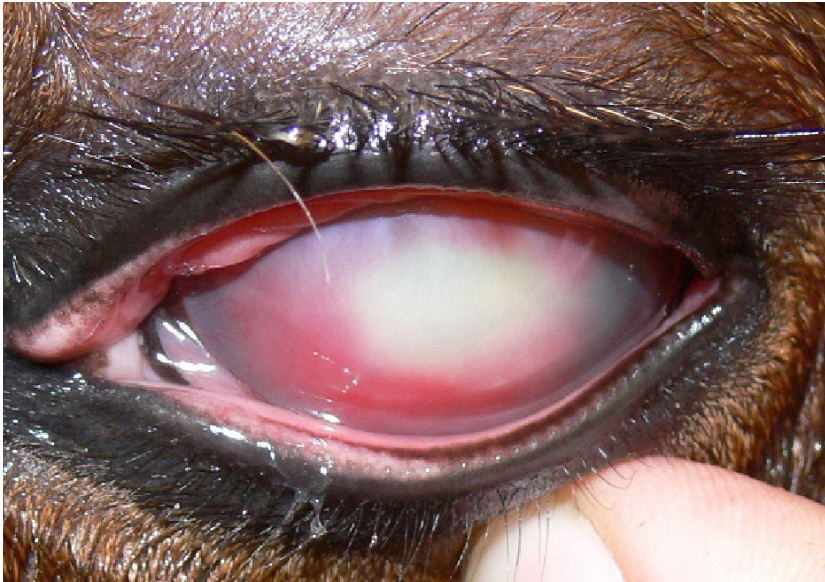

Fig 2. Suspected keratomycosis with stromal abscess without corneal ulceration.

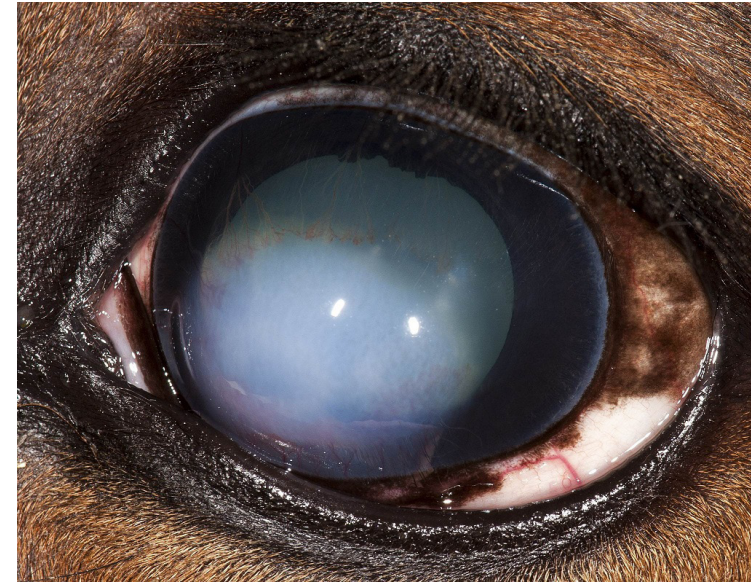

Fig 3. Corneal scarring after treatment with miconazole of a stromal abscess caused by equine keratomycosis.

References

- Scotty, NC. *Equine Keratomycosis*. Clin Tech Equine Pract. 2005. 4:29-36.
- Voelter-Ratson, K., Pot, SA. et al. *Equine keratomycosis in Switzerland: A retrospective evaluation of 35 horses (January 2000-August 2011)*. Equine Vet J. 2013. 45:608-612.
- Reed, Z., Thomas, SM. et al. *Equine keratomycosis in California from 1987 to 2010 (47 cases)*. Equine Vet J. 2013. 45:361-366.
- Gilger, BC. *Diseases of the cornea*. In: Equine Ophthalmology. 3rd ed. 2016. pg 252-368.