

Intracavitary deposits on Essure® hysteroscopic sterilization devices: A case report



L.W. Maassen^{a,*}, D.M. van Gastel^b, E.G.W.M. Lentjes^a, M.Y. Bongers^{b,c}, S. Veersema^a

^a University Medical Center Utrecht, Heidelberglaan 100, 3584 CX Utrecht, The Netherlands

^b Máxima Medical Centre Veldhoven, De Run 4600, 5504 DB Veldhoven, The Netherlands

^c Maastricht University, Department of Obstetrics and Gynaecology, Grow school of Oncology and Developmental Biology, Universiteitssingel 40, 6229 Maastricht, The Netherlands

ARTICLE INFO

Keywords:

Essure®
Hysteroscopic sterilization
Calcite deposits

ABSTRACT

Objective: To study the composition of intracavitary deposits on Essure® hysteroscopic sterilization devices.

Design: Case report.

Setting: Reproductive Medicine and Gynecology department of a University Hospital.

Patient(s): A 39 years old patient presenting with a request for surgical removal of Essure® sterilization devices. Diagnostic hysteroscopy showed a crystal like white deposit attached to one of the devices.

Intervention: Diagnostic hysteroscopy and surgical removal of Essure® devices was performed. The deposits were collected and infrared spectroscopy analysis was performed.

Main Outcome Measure: Chemical composition of the deposits attached to the device.

Result(s): Infrared spectroscopy of the material showed patterns conclusive with calcite (calcium carbonate, CaCO₃).

Conclusion: Until now, it is not clear if there is a relationship between reported complaints and formation of calcite deposits on Essure®.

Capsule: Infrared spectroscopy of deposits on Essure® devices showed a pattern conclusive with calcite. The relationship between reported complaints and the formation of calcite deposits on Essure® remains unclear.

1. Introduction

In 2002, Essure® (Bayer AG, Leverkusen, Germany) was the first hysteroscopic method for permanent contraception to be approved for use by the United States Food and Drug Association (FDA) [1,2]. Since its introduction on the market in 2002, over 750.000 devices were sold [3].

Recently, safety concerns were raised by women sterilized using the Essure® micro inserts. Large numbers of adverse events were reported to the FDA through its Manufacturer and User Facility Device Experience database (MAUDE). Adverse events included incomplete procedures, tubal perforations, unintended pregnancies, intractable pain and bleeding [3]. In addition, in March 2011 a Facebook group was launched by a patient experiencing severe complaints following Essure® implantation [4]. Currently this community, Essure Problems, has passed 30,000 members. Reported complaints include: chronic pelvic pain, fatigue, back pain, headache, alopecia, arthralgia and more.

Since this moment, women frequently present with a request for surgical removal of the devices. In some cases, an explanation of the complaints is found during surgery [5,6], while in others the answers remain indebted. In some cases, a notable observation is the presence of deposits on the intracavitary and intratubal part of the devices. We present a case in which we found a deposit on the device. We performed additional investigations to define the material present in order to find out the clinical significance of the deposits.

2. Material and Methods

2.1. Case Report

A 39 years old gravida 1, para 1 presented with a request for surgical removal of her Essure® devices. The devices were inserted 5 years before presentation. Her record showed a history of multiple sclerosis, an open appendectomy and a caesarean section. The patient experienced more frequent relapses of multiple sclerosis since implantation of

* Corresponding author at: University Medical Center Utrecht t.a.v. Drs. L. W. Maassen, Huispostnummer C05.202, Heidelberglaan 100, 3584 CX Utrecht, The Netherlands.

E-mail addresses: L.W.Maassen-3@umcutrecht.nl (L.W. Maassen), Danielle.van.Gastel@mmc.nl (D.M. van Gastel), EGWM.Lentjes@umcutrecht.nl (E.G.W.M. Lentjes), S.Veersema@umcutrecht.nl (S. Veersema).

<http://dx.doi.org/10.1016/j.crwh.2017.06.003>

Received 14 April 2017; Accepted 10 June 2017

Available online 13 June 2017

2214-9112/ © 2017 The Authors. Published by Elsevier B.V. This is an open access article under the CC BY-NC-ND license (<http://creativecommons.org/licenses/by-nc-nd/4.0/>).

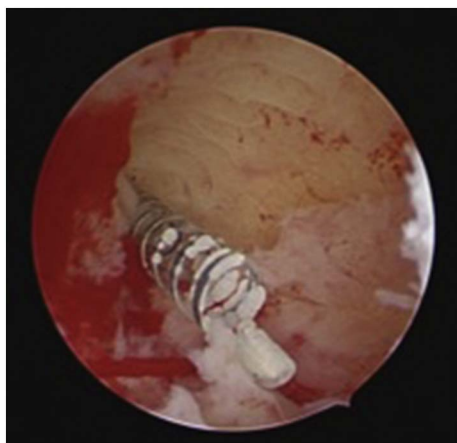

Fig. 1. Hysteroscopic view of right tubal ostia. The outer (nitinol) coil of the Essure device with a white deposit is visible. (Color figure).

the devices, together with a change in menstrual cycle. She reported longer and heavier menstrual bleeding. Results of gynecological examination and X-ray imaging of the pelvis showed no abnormalities.

The patient underwent diagnostic hysteroscopy followed by laparoscopic bilateral Essure® removal and bilateral salpingectomy. At hysteroscopy, the Essure® device was visible in the right tubal ostium. The device showed a crystal like white deposit [Fig. 1]. The outer coil of the device was cut and removed in order to prevent tearing of the metal. The left coil was not visible in the tubal ostium. Hysteroscopy was followed by laparoscopy. The uterus and ovaries showed no visible abnormalities. There was no evidence for endometriosis at the time of laparoscopy. However, there were adhesions seen between the caecum and the right adnexa. Adhesiolysis was performed followed by uncomplicated bilateral Essure® removal, using linear salpingotomy and

subsequently bilateral salpingectomy. Both devices were removed completely. Permission from the patient was obtained to perform further investigation and present her case.

The right device, including deposit, was evaluated by the clinical chemistry department. The chemical composition of the material attached was determined by means of an infrared spectrophotometric method, using the potassium bromide pallet technique. Infrared spectroscopy analysis was performed using the Perkin Elmer spectrophotometer. Semi-quantitative evaluation of infrared spectra was based on reference spectra, that were obtained from pure and mixed stone-forming chemicals.

3. Results

Infrared spectroscopy showed patterns conclusive with calcite (calcium carbonate, CaCO_3) [Fig. 2]. Histologic examination of the removed tissue showed double refracting acellular deposits, distributed over the tissue. Calcite is known for its double refracting properties [7].

4. Discussion

This is the first article to report on intrauterine deposits on the Essure® devices. However, this was not our first observation of the white deposits on the devices. In literature, similar observations have been described for copper and stainless steel intrauterine devices (IUD's) [8,9,10].

In 1980, incrustation on the surface of IUD's was first described [8]. Since then, multiple reports have been published regarding these deposits. It has been concluded that the presence of incrustments on IUD's increases the chance on side effects [9]. In an article by Patai et al., IUD's removed after several years after insertopn were investigated [10]. A white, strongly attached incrustment was observed. Deposits on 500 (different types) devices were investigated using four techniques:

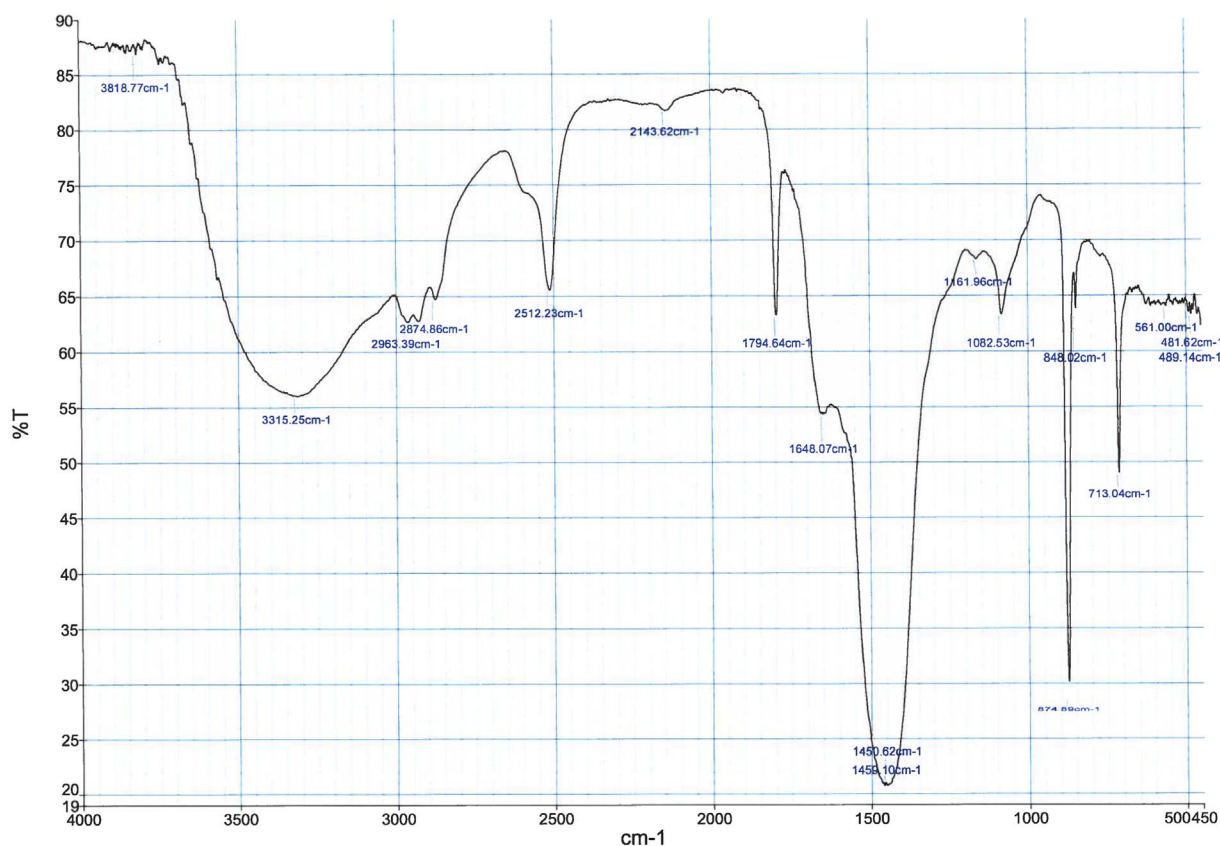


Fig. 2. Infrared spectroscopy of deposits found on Essure device. Pattern is conclusive with calcite (calcium carbonate CaCO_3). (Black-and-White figure).

Harzolith®, an ultramicrochemical stone analysis kit (Reanal, Budapest, Hungary), X-ray microprobe, infrared spectroscopy and x-ray diffractometry. All four techniques showed results comparable with our case: calcite (calcium carbonate or CaCO₃). In this article a distinction between healthy patients and patients with lower abdominal complaints was made. The researchers found that the amount of incrustment was significantly higher in the group patients with complaints. They concluded that inflammation increases the amount of deposit on IUD's. This suggests that the formation of calcite deposits on the Essure® devices might cause certain side effects or inflammation.

Furthermore, copper IUD's have been stimulated to provoke corrosion [11]. Corrosion is the process of destruction of metals by reactions with its environment. These reactions can be chemical as well as electrochemical [12]. Researchers found that corrosion products of copper IUD's mainly contain calcite. In contrast to copper, nitinol is known for its biocompatibility and resistance to corrosion [13]. On the other hand, articles describing corrosion of nitinol have been published [14]. In addition, a case report by Bibas et al., describes a case of systemic contact dermatitis following Essure® insertion [15]. The authors suggested that a systemic allergic reaction on the Essure® devices could be explained by corrosion of the nitinol wire after implantation, since corrosion would lead to the release of nickel into the bloodstream [16]. It is unclear if the formation of calcite deposits is the result of a corrosion process in the nitinol outer coil of Essure® sterilization device.

We present a case of calcite deposition formation on Essure® hysteroscopic sterilization devices, in a patient presenting with a request for surgical removal of the devices. Given the large numbers of women presenting with complaints, it is important to solve different questions regarding these problems. Until now it is unclear if a relationship between reported complaints and the formation of calcite deposits on Essure® exists. Also, if a relationship does exist, it is indistinct if the complaints are caused by the formation of the deposits or are the result of the processes causing them. Research to the cause of deposit formation on Essure® devices is needed in order to understand the mechanism of this process and to determine its clinical relevance. For this, it is necessary to collect data of patients presenting with complaints. These data should include reported complaints as well as laparoscopic and hysteroscopic findings.

Conflict of Interest

None declared.

References

- [1] S. Andersson, S. Eriksson, M. Mints, Hysteroscopic female sterilization with Essure in an outpatient setting, *Acta Obstet. Gynecol. Scand.* 88 (2009) 743–746.
- [2] S.G. Chudnoff, J.E. Nichols, M. Levie, Hysteroscopic Essure inserts for permanent contraception: extended follow-up results of a phase III multicenter international study, *J. Minim. Invasive Gynecol.* 22 (2015) 951–960.
- [3] S.S. Dhruva, J.S. Ross, A.M. Garipey, Revisiting Essure—toward safe and effective sterilization, *N. Engl. J. Med.* 373 (2015) e17.
- [4] Essure problems Facebook group, Available at <https://www.facebook.com/groups/Essureproblems/> (Accessed November 27, 2016).
- [5] A.W. Beckwith, Persistent pain after hysteroscopic sterilization with microinserts, *Obstet. Gynecol.* 111 (2008) 511–512.
- [6] N. Moawad, S. Mansuria, Essure perforation and chronic pelvic pain, *J. Minim. Invasive Gynecol.* 18 (2011) 285–286.
- [7] E. Bartholin, *Experimenta crystalli islandici disdiacastici quibus mira & infolita refractio detegitur*. Translated into English by Archibald T. Acta Historica Scientiarum Naturalium et medicinalium 40: Danish National Library of Science and Medicine, (1991).
- [8] B. Sheppard, J. Bonnar, Scanning and transmission electron microscopy of material adherent to intrauterine contraceptive devices, *Br. J. Obstet. Gynaecol.* 87 (1980) 155–162.
- [9] A. Kivijärvi, H. Järvinen, M. Grönroos, Microbiology of vaginitis associated with the intrauterine contraceptive device, *Br. J. Obstet. Gynaecol.* 91 (1984) 917–923.
- [10] K. Patai, M. Berényi, M. Sipos, B. Noszál, Characterization of calcified deposits on contraceptive intrauterine devices, *Contraception* 58 (5) (1998) 305–308.
- [11] J. Bastidas, E. Cano, N. Mora, Copper corrosion-simulated uterine solutions, *Contraception* 61 (2000) 395–399.
- [12] R.W. Revie, H.H. Uhlig, *Corrosion and Corrosion Control: An Introduction to Corrosion Science and Engineering*, John Wiley & Sons Inc., Hoboken, 2008.
- [13] J. Ryhänen, E. Niemi, W. Serlo, E. Niemelä, P. Sandvik, H. Pernu, et al., Biocompatibility of nickel-titanium shape memory metal and its corrosion behavior in human cell cultures, *J. Biomed. Mater. Res.* 35 (1997) 451–457.
- [14] G. Riepe, C. Heintz, E. Kaiser, N. Chakfe, M. Morlock, M. Delling, et al., What can we learn from explanted endovascular devices? *Eur. J. Vasc. Endovasc. Surg.* 24 (2002) 117–122.
- [15] N. Bibas, J. Lassere, C. Paul, C. Aquilina, F. Giordano-Labadie, Nickel-induced systemic contact dermatitis and intratubal implants: the baboon syndrome revisited, *Dermatitis* 24 (2013) 35–36.
- [16] S. Lerouge, R. Guidoin, T. Ashton, M. Guidoin, A. Legrand, Y. Douville, et al., Nitinol self-deployable endovascular prostheses: variability in corrosion resistance, *Ann. Chim.* 29 (2004) 41–52.