

Lipid Therapy for Intoxications



Joris Henricus Robben, DVM, PhD^{a,*}, Marieke Annet Dijkman, PhD^b

KEYWORDS

- Poisoning • Toxin • Lipid • Fat • Emulsion • Intralipid • ILE
- Lipid resuscitation therapy

KEY POINTS

- Intravenous lipid emulsion (ILE) is a promising treatment modality for poisonings with lipophilic agents, especially in situations whereby patients already have developed serious clinical signs as a result of the poisoning.
- Scientific evidence on mechanisms of action, such as the lipid sink/shuttle and the cardiovascular effects of ILE therapy, is increasing; but much remains to be elucidated.
- Current dosing protocols are derived from protocols used for the treatment of local anesthetic systemic toxicity in man; although they seem safe and represent a cost-effective therapeutic intervention, it remains obscure if these are the optimal dosing protocols.
- The veterinary literature on the efficacy of ILE therapy consists primarily of case reports and case series that limit interpretation as they represent low-quality evidence; they should be evaluated with caution.

INTRODUCTION

The use of intravenous lipid emulsions (ILEs) in human clinical toxicology has become common practice as a life-saving treatment of local anesthetic-induced cardiotoxicity. Weinberg and colleagues¹ first reported its potential as a treatment option in toxicology in 1998. It was first clinically used in humans for the treatment of local anesthetic systemic toxicity (LAST) in 2006,^{2,3} followed by its first use in other lipophilic drug poisonings in 2008.⁴ In recent years several position papers on ILE therapy have been published by medical organizations, such as the American and British/Irish societies of anesthesiology and the American Medical College of Toxicology.^{5–7} Since

Disclosure Statement: The authors have nothing to disclose.

^a Intensive Care Unit, Department of Clinical Sciences of Companion Animals, Faculty of Veterinary Medicine, Utrecht University, PO Box 80.154, Utrecht NL-3584 CM, The Netherlands;

^b Dutch Poisons Information Center, Division of Anesthesiology, Intensive Care and Emergency Medicine, University Medical Center Utrecht, Heidelberglaan 100, P.O. Box 85500, 3508 GA Utrecht, The Netherlands

* Corresponding author.

E-mail address: j.h.robben@uu.nl

Vet Clin Small Anim 47 (2017) 435–450
<http://dx.doi.org/10.1016/j.cvsm.2016.10.018>

vetsmall.theclinics.com

0195-5616/17/© 2016 Elsevier Inc. All rights reserved.

the introduction of ILE for the treatment of lipophilic drug toxicity, the interest in veterinary medicine has rapidly increased. The popularity of this treatment modality has been fed by the dramatic clinical improvement in reported clinical cases, the relative simplicity, low risks and low cost of its use, as well as the limited options that exist for the treatment of animals with certain poisonings. The use of ILE has been extensively discussed by Fernandez and colleagues⁸ in 2011 and addressed previously in this journal in 2012.⁹ This review discusses current information from the latest literature regarding the subject of ILE therapy in toxicology. Based on this information, insight in the possibilities for and efficacy of ILE therapy is provided.

MECHANISM OF ACTION

How lipid resuscitation works in systemic toxicity after intravenous administration of local anesthetics has been extensively investigated. The mechanisms of action are still not fully understood but include a dynamic scavenging component and direct cardiovascular effects.¹⁰

Scavenging/Partitioning Effect: from Lipid Sink to Lipid Shuttle

The original mechanistic hypothesis proposed by Weinberg and colleagues¹ in 1998 was that intravenous infusion of liposomes provides a compartment for lipophilic drugs in the circulation to partition into, making them unavailable to act on their target organs. This concept is known as the lipid sink (Fig. 1).

With improved understanding of lipid resuscitation, intravenous liposomes are viewed as a lipid shuttle or a capture/release mechanism to move a drug around and not a sink that captures and isolates the drug.¹⁰ An intravenous lipid compartment transiently sequesters the drug, accelerating its movement from drug-susceptible organs, such as brain and heart, to organs that can store (muscle, adipose), detoxify (liver), and excrete (kidney, bladder) the drug. In this respect, metabolism of exogenous lipid is thought to be similar to chylomicrons.

There is support for a lipid sink/shuttle mechanism by *in vitro*, *ex vivo*, and *in vivo* studies. Transient increase followed by a subsequent decrease in the blood concentration of lipophilic drugs after ILE treatment have been reported in experimental animals as well as in human and veterinary case reports. Ivermectin plasma concentration increased substantially after administration of ILE to a border collie and a Shetland pony, followed by a decrease in plasma concentration when compared with baseline.^{11–13} Confirmation of liposome partitioning does not necessarily translate into an improvement in clinical signs of intoxication *in vivo*. For example, decrease in target organ drug concentration may be insufficient to lead to clinical improvement; it might not be the drug itself but its metabolites that are responsible for the clinical effect, or the detoxification and excretion pathways may become saturated. In veterinary toxicology, this may play a role in ivermectin-intoxicated dogs with the ABCB-1 Δ gene mutation.¹⁴

Direct Cardiovascular Effects or Nonscavenging Mechanisms

Lipid emulsions have a direct effect on myocardial cells improving cardiac output. The underlying mechanisms by which ILE therapy exerts this effect have not been fully elucidated.¹⁵ The volume of the ILE bolus is definitely a factor, whereas other contributors are unclear. Several candidates for contributors have been suggested, with the calcium and fatty acid hypotheses being the two most popular. There is still conflicting experimental evidence whether fatty acids increase Ca²⁺ influx in the myocardial cells to produce a positive inotropic effect because inhibition of the Ca²⁺ influx also has been demonstrated. According to the fatty acid hypothesis, the infusion of ILE may

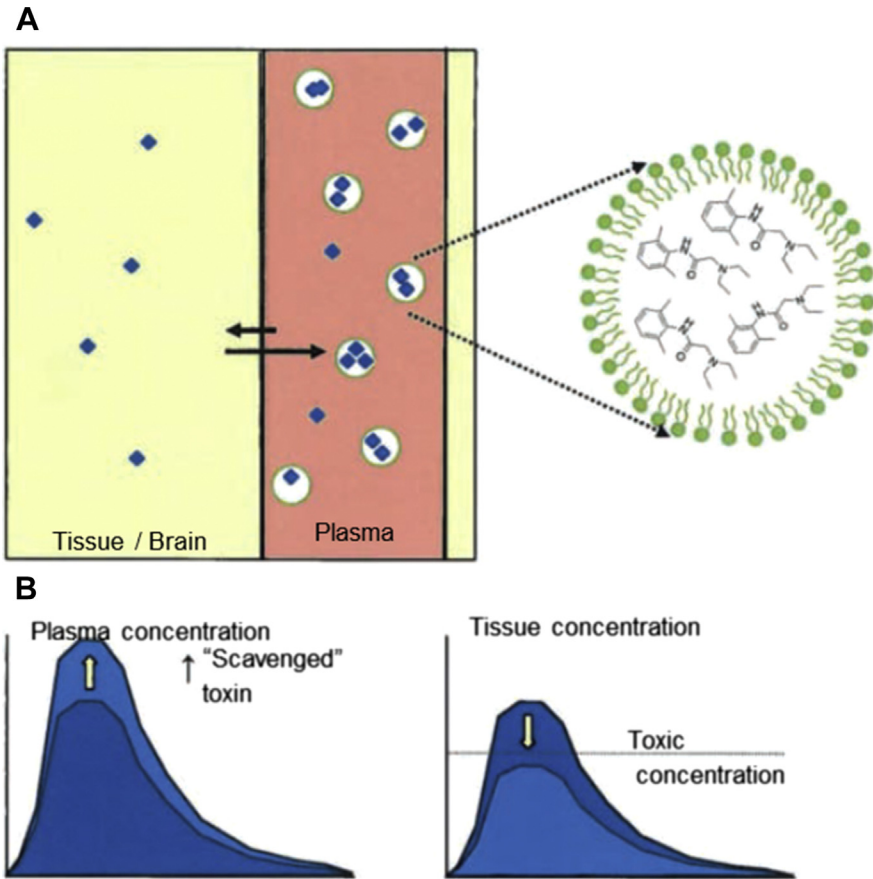


Fig. 1. (A) The lipid sink phenomenon. (B) The related fictitious changes in plasma and tissue concentration. (Adapted from Dijkman MA, van Rhijn N, de Vries I, et al. Intraveneuze vetemulsie als antidotum in de veterinaire praktijk - deel 1: Een literatuuroverzicht. Tijdschr Diergeneeskd 2015;5:25; with permission.)

reduce toxic effects by providing a source of energy to the myocardial cells to overcome a bupivacaine-induced block in fatty acid processing. This hypothesis may not be correct. There is evidence that the vasoconstrictive properties of intravenous liposomes in the vasculature play a role. However, the relative contribution of cardiac versus vascular aspects remains to be determined.¹⁰

Future Developments: Liposome-Based Nano-Antidota

Lipid emulsions have been used in parenteral nutrition protocols since the 1960s as well as a vehicle for drug delivery, for example, propofol. They have not been designed with the intention to absorb (lipophilic) toxins. The appropriateness of the currently applied lipid emulsions for their intended use and mechanisms of action needs to be determined. It is not known which component in the lipid emulsions determines its binding capacity. Other product properties could potentially be used to scavenge charged agents more effectively, such as the manipulation of the surface charge of ILE components. New products are now being developed, such as pH-gradient liposomes that have already demonstrated efficacy in proof-of-concept studies.^{16,17}

LIPID EMULSIONS: PRODUCT CHARACTERISTICS^a

- For lipid emulsions, 20% are used off label in the treatment of lipophilic drug intoxications.⁸
- Lipid emulsions are sterile mini-emulsions (liposomes are approximately 0.4–0.5 μm) of oil in water that have a turbid (white) appearance.⁸
- The oil component consists of neutral long-chain triglycerides (LCTs), or a mix of medium-chain triglycerides (MCTs) and LCTs, extracted from unsaturated plant fatty acids from soya bean oil (ie, Intralipid, Fresenius Kabi AB, Uppsala, Sweden).^a Newer products can also contain olive, fish, safflower, and coconut (MCT) oil. Although Intralipid is the one most often used, other products have been described for ILE treatment.⁸
- Sodium oleate and 1.2% egg phosphatides are added as emulsifiers to improve fat solubility. Sodium hydroxide is added to adjust pH. These additives represent 15 mmol/L phosphate and 5 mmol/L sodium. Additionally, 2.25% to 2.5% glycerol is present. Soybean oil is also known as a source of vitamin K₁.⁸
- The caloric value of a 20% product is about 2000 kcal/L or 8.4 MJ/L.⁸
- Currently marketed products have a pH of 6.0 to 9.0 and an osmolality of approximately 270 mOsm/L. They are ready to use and can be administered through a peripheral vein.⁸
- Containers are available in 200, 250, or 500 mL, with a shelf life of about 2 years when unopened. Lipid emulsions are relatively cheap.⁸

CHARACTERISTICS OF INTRAVENOUS LIPID EMULSION-SENSITIVE DRUGS AND TOXINS

The suitability of ILE for the treatment of a drug or toxin overdose is currently determined by the scavenging/partitioning property of ILEs.^{16,18,19} The overall partitioning effect depends on the biophysical and pharmacokinetic parameters of a particular drug or toxin, such as (pH-dependent) lipid solubility, charge at physiologic pH, amount of protein binding, and volume of distribution. Currently, the suitability is determined by the drugs' lipophilicity, measured as the ratio of concentrations the compound has in a mixture of 2 immiscible liquids, octanol and water. This lipophilicity is expressed as the partitioning coefficient ($\log P$). The higher the $\log P$ value, the more lipophilic an agent is.⁸ The octanol/water partition coefficient is an indication of the *in vitro* lipid solubility, whereas the actual partitioning of a drug between plasma and a lipid emulsion *in vivo* can be influenced by factors mentioned earlier. For example, the lipid solubility of charged molecules is typically negligible.

CURRENT KNOWLEDGE ON EFFICACY

Efficacy of intravenous lipid therapy is primarily based on human and veterinary case reports, and case series (**Table 1**). Although it is thought that the reversal of drug toxicity was related to ILE administration, case reports yield a low quality of evidence.^{20,21} In summary, current veterinary literature has the following limitations to determine the validity of ILE in the treatment of intoxications.

^a Product information Intralipid 20% (Fresenius Kabi AG, Bad Homburg, Germany) at http://www.accessdata.fda.gov/drugsatfda_docs/label/2007/017643s072,018449s039lbl.pdf.

- With the introduction of new treatment modalities there is often a tendency to publish cases that describe a positive clinical response that may overestimate the success rate of ILE therapy.
- Treatment protocols on ILE differ dramatically; for example, time of initial dosing, bolus size, rate of continuous infusion, number of treatments, and treatment intervals vary substantially. When ILE therapy is repeated, the protocol often differs from the initial one making the whole treatment plan unique and results difficult to compare or extrapolate.
- ILE is often applied as an adjunctive therapy to other, more conventional treatment modalities. It is difficult to determine which modality or combination of modalities ultimately elicited the clinical effect.
- The clinical effect of ILE therapy is not standardized but has been based on the subjective assessment of the veterinary team (see **Table 1**). Very acute and dramatic improvement as well as a slow and less spectacular response to ILE therapy have been observed. In this respect, the measurement of blood drug concentrations before, during, and after ILE treatment provides a more objective assessment.^{11–13,22,23} Measured changes in drug concentrations indicate a lipid sink/shuttle phenomenon, although not necessarily related to clinical improvement.¹⁴
- Some intoxications are not limited to one toxin. Ivermectin and moxidectin are often combined with other anthelmintics that may play a role in the toxicity. These additional drugs or toxins may interfere with the evaluation of the effect from ILE treatment.

In addition to the case reports and case series, there is one randomized controlled clinical trial with a standardized evaluation of the clinical outcome on permethrin poisoning in cats.⁴⁷

Popular Drug Treatment Scenarios

Permethrin

Permethrin is an insecticide commonly present in spot-on flea treatments for dogs. Cats are extremely sensitive to permethrin, most likely because of the poor ability of the feline liver to metabolize/detoxify pyrethroids. A minimal lethal dose of permethrin has not been established in cats, but a lethal dermal dose of 100 mg/kg has been reported in one cat.⁴⁸ Mortality rates have been reported to be between 2.4% and 16.9%.^{49–51} However, in a survey on 750 cats with permethrin toxicosis, almost a quarter (23.5%) of the deceased animals were euthanized because of the owners' financial constraints.⁴⁹ In the veterinary ILE case reports, all cats were dermally exposed, most with dog-formulated antifea and tick spot-on products. The cats displayed typical permethrin intoxication signs, including seizures, muscle fasciculation, generalized tremors, ataxia/disorientation, hyperthermia or hypothermia, tachycardia, mydriasis, and salivation. Long-lasting seizure activity causes myoglobinuria that may lead to acute kidney failure. Immediate stabilization of neuro-excitatory signs is required. Standard treatment includes administration of sedatives or muscle relaxants like diazepam, midazolam, barbiturates, propofol, dexmedetomidine, or methocarbamol. ILE has often been tried if standard therapy is solicited insufficient effect (see **Table 1**). Only one prospective randomized controlled clinical trial has compared the progression of clinical signs of cats with permethrin toxicosis before and after treatment with ILE or saline as control.⁴⁷ After enrollment of 36 cats, an interim statistical analysis was performed. A significant benefit of ILE was detected, and the trial was stopped early.

Permethrin does not affect the heart, suggesting that ILE-induced improvement of myocardial function will not contribute to its efficacy in these cases. More likely, lipid

Table 1
Summary of veterinary case reports and case series in which intravenous lipid emulsions have been used^a

Drug	Species	References	Number of Animals	Exposure Route	Improvement	
					Clinical ^b	Paired (Drug) ^c
Permethrin	Cat	Bruckner & Schwedes, ²⁴ 2012	2	SC	Yes	No
		Haworth & Smart, ²⁵ 2012	3	SC	Yes	No
		Kuo & Odunayo, ²⁶ 2013	2	SC	Yes	No
		Muentener et al, ²⁸ 2013	1	SC	Yes	No
		DeGroot, ²⁷ 2014	1	SC	Yes	No
		Ceccherini et al, ²⁹ 2015	4	SC	Yes	No
		Seitz & Burkitt-Creedon, ³⁰ 2016	1	SC	Yes	No
Total	14					
Ivermectin	Dog (ABCB-1Δ neg or unknown)	Clarke et al, ¹¹ 2011	1	PO	Yes	Yes
		Bates et al, ³¹ 2013	2	PO	Yes	No
		Epstein & Hollingsworth, ³² 2013	1	PO	Yes	No
		Total	4			
	Dog (ABCB-1Δ pos)	Wright et al, ¹⁴ 2011	3	PO	No	Yes
		Bolfer et al, ³³ 2013 ^d	1	PO	Yes	Yes
	Total	4				
	Cat	Pritchard, ³⁴ 2010	1	PO + SC	Yes	No
		Kidwell et al, ³⁵ 2014	1	PO + SC	Yes	No
		Jourdan et al, ³⁶ 2015	20	SC	n/a	No
Total		22				
Horse	Bruenisholz et al, ¹³ 2012	1	PO	Yes	Yes	
Lion	Saqib et al, ³⁷ 2015	1	PO	Yes	No	

Moxidectin	Dog	Gwaltney-Brant & Dunayer, ³⁸ 2008 ^d	1	PO	Yes	No
		Crandel & Weinberg, ³⁹ 2009	1	SC + PO	Yes	No
		Bates et al, ³¹ 2013	2	PO	Yes	No
		Total	4			
	Cat	Kammerer et al, ⁴⁰ 2013	1	SC	Yes	No
Baclofen	Dog	Bates et al, ³¹ 2013	1	PO	Yes	No
		Butler, ⁴² 2014	1	PO	Yes	No
		Khorzad et al, ⁴¹ 2012	5	n/a	Yes	No
		Total	7			
	Cat	Edwards et al, ⁴³ 2014	1	PO	Yes	No
Naproxen	Dog	Herring et al, ²³ 2015	3	PO	Yes	Yes
Ibuprofen	Dog	Bolfer et al, ²² 2014	1	PO	Yes	Yes
Lidocaine	Cat	O'Brien et al, ⁴⁴ 2010	1	SC	Yes	Yes
Diltiazem	Dog	Maton et al, ⁴⁵ 2013	1	PO	Yes	No
Marijuana	Dog	Meola et al, ⁴⁶ 2012	3	PO	n/a	No

Abbreviations: n/a, not available; neg, negative; PO, per os; pos, positive; SC, subcutaneous.

^a Full articles and abstracts, corrected for doubles.

^b As assessed and stated by the investigators.

^c Effect of ILE treatment as determined with before and after blood toxin concentrations.

^d Congress abstracts.

partitioning of permethrin occurs. However, blood permethrin concentrations before, during, and after ILE treatment have not yet been reported to support this hypothesis.

Ivermectin and other macrocyclic lactones

Macrocyclic lactones include 2 groups, avermectins and milbemycins. They are commonly used to prevent and treat internal and external parasites. Binding to gamma aminobutyric acid type A-gated chloride channels in the brain is the main mechanism by which macrocyclic lactones exert their toxic effect in mammals. Macrocyclic lactones have a wide safety margin when the blood-brain barrier is intact.⁵² Young animals with an immature blood-brain barrier and dogs affected by the ABCB-1 Δ gene (formerly MDR1 gene) mutation are predisposed to toxicity. Signs of toxicity mainly involve the central nervous system and include ataxia, lethargy, coma, tremors, seizures, mydriasis, and blindness.

Veterinary cases of ILE treatment of ivermectin (avermectin group) and moxidectin (milbemycin group) intoxications have been reported in various animal species, including cat, dog, horse, and a lion (see [Table 1](#)).^{12,31,36,37} A case series of ILE use in intoxications with other macrocyclic lactones, for example, milbemycin and doramectin, has also been published as an abstract.⁵³ Most often, ILE was administered to accelerate the resolution of clinical symptoms in prolonged intoxications refractory to standard treatment modalities.

Dogs Dogs are often accidentally exposed to horse deworming paste containing macrocyclic lactones. Serum ivermectin concentrations were measured in 4 ABCB-1 Δ -affected dogs, one ABCB-1 Δ -unaffected dog, and in one foal.^{12-14,32} The decrease in serum ivermectin concentration in these cases after ILE administration suggests a lipid sink phenomenon, enhancing elimination of ivermectin. However, ILE therapy may only be helpful in dogs that are not homogeneous ABCB-1 Δ mutant. The ABCB-1 Δ gene mutation decreases patients' ability to remove the drug from brain tissue, which could explain the absence of a quick clinical response to ILE, despite a decrease in ivermectin plasma levels.^{14,33} The affected transporter protein P-glycoprotein is also expressed in renal tubular epithelial and biliary canalicular cells. This expression may reduce the secretion rates during ivermectin toxicosis in ABCB-1 Δ homozygous mutant dogs, further worsening the toxic effect of ivermectin. Therefore, homozygous mutant dogs may solely rely on a concentration gradient for diffusion of ivermectin from the brain into the infused lipid.³² Early ILE treatment before clinical symptoms occur might prevent or reduce potential clinical severity in these cases.

Cats Ivermectin intoxications in cats are rare and occur primarily when excessive doses are administered.³⁴⁻³⁶ In both case reports (see [Table 1](#)), ILE was administered late in the clinical course after standard therapy elicited an insufficient effect. The effect of ILE varied from temporary improvement to extreme rapid improvement in clinical symptoms.^{34,35} A completely different approach was chosen after 20 cats were accidentally overdosed simultaneously with the topical application of ivermectin for the treatment of an ear mite infestation.³⁶ All cats were treated with an ILE bolus in order to prevent the development of ivermectin-induced clinical signs. Based on this experience, the investigators proposed that early ILE administration, creating a lipid sink, should be part of the initial management of ivermectin intoxication in cats.

Other Drug Treatment Scenarios

Traditionally, ILE therapy in human medicine has been used to manage LAST. In veterinary medicine, only one case has been reported on a cat with lidocaine-associated cardiotoxicity suggesting it may be a less common problem in veterinary medicine.⁴⁴

Some reports on nonsteroidal antiinflammatory drug intoxications are of interest as they support the lipid sink/shuttle hypothesis. ILE therapy was used as preventative measure because of a potential large naproxen overdose in 3 dogs.²³ Serum naproxen concentrations decreased by more than 60% 1 hour after ILE therapy. None of the dogs developed long-standing gastrointestinal, renal, or neurologic effects. In a case of ibuprofen poisoning in a dog, serum concentration decreased from 190 µg/mL at baseline to less than the detection limit 2 hours after completion of ILE infusion.²²

Therapy with ILE has also been advocated in the treatment of baclofen intoxications.⁵⁴ The two case reports in dogs and the one in a cat have claimed that ILE therapy is a useful adjunct to conventional treatment, despite the fact that baclofen is only weakly lipophilic.^{31,42,43} No serum concentrations before and after ILE treatment were measured in these studies.

The list of drugs in which ILE have been tried as an adjunctive or primary treatment rapidly grows, with recent reports on diltiazem, marijuana, and synthetic cannabinoid intoxications; tremorogenic mycotoxins in dogs (M.A. Dijkman, personal communication, Veterinary Poisons Information Service, 2016); and *Pieris japonica* poisoning in a flock of goats.^{45,46,55–57} Consultation with a (veterinary) poisons information center can help to decide whether ILE therapy might be useful in the treatment of a certain drug/toxin poisoning.

DOSING IN VETERINARY MEDICINE

In veterinary patients, ILE therapy has been recommended especially in patients with life-threatening clinical effects as an adjunctive therapy when the standard therapy seemed inadequate as evaluated by the severity and frequency of relapse of clinical signs. In large and overwhelming exposures with serious (eg, life threatening) consequences, ILE is advocated even before the development of clinical signs.³⁶

Dosing with Neurotoxicity Induced by (Orally Administered) Drugs

Poisonings treated with ILE in veterinary medicine occur primarily via the oral or the subcutaneous route, for example, permethrin (see **Table 1**). The drug concentrations and pharmacokinetics of intravenous drug overdose are different from those of overdose via the enteric route. For example, oral overdose is characterized by a longer absorption phase, in particular with slow-release formulations. There are concerns if early treatment with ILE in enteric, for example, oral, orogastric and rectal, overdose leads to an improved absorption from the gastrointestinal tract of the toxin, accelerating the development of systemic toxicity.^{58–60} It is questionable if this negative effect of ILE treatment is relevant in the clinical setting, as early treatment of an overdose is often delayed and consists of prior oral decontamination (eg, by the use of activated charcoal).

ILEs provide a dose-dependent response, with 10% emulsions having insufficient effect and 30% emulsions accelerating recovery relative to 20%.¹⁵ The ideal bolus volume, rate, and duration of the subsequent continuous infusion in enteric/oral overdose are still not known. They may be far from optimal, and current dosing in oral overdose may change as our understanding of the therapeutic mechanism of ILE improves.^{10,61,62}

In veterinary practice, ILE is most often used in long-term neurotoxicity induced by permethrin, ivermectin, and other macro-lactones. A dosing protocol is presented in **Box 1** with recommendations for maximum safe doses and infusion rates. The degree of lipemia can be used to help guide ILE dosing.

Box 1**Dosing protocol of intravenous lipid emulsions (20%) with severe, protracted neurotoxicity caused by (strong) lipophilic substances**

Sufficient response to standard therapy in a severe poisoning

- Yes: Use of ILE is not indicated.
- No: Consider the use of ILE.

Considerations before using ILE

- Check liver, pancreas, and kidney function, especially if organ function was compromised before.
- Correct electrolyte disturbances, especially hypokalemia, hypophosphatemia, and hyponatremia.

Dosing with neurotoxicity

1. Administer one intravenous bolus injection (peripheral or central) of 1.5 mL/kg in 1 to 2 minutes.
2. Start a CRI at 0.25 mL/kg/min (ie, 15 mL/kg/h) for 30 to 60 minutes or
3. If there is a risk of volume overload
 - a. Consider temporarily stopping all infusions.
 - b. Consider a reduced rate at 0.07 mL/kg/min (4 mL/kg/h) for 4 hours.
4. Monitor for pyrogenic and allergic responses (especially in the first 20 minutes), and stop CRI if they occur.

Evaluate patients 4 to 6 hours after stopping the ILE administration.

1. With insufficient or no clinical improvement, repeat the dose once or twice as soon as the plasma/serum is (macroscopically) no longer lipemic and there are no signs of hemolysis. Stop if there is little or no effect.
2. With distinct clinical improvement do the following:
 - a. Keep patients under observation for at least 12 hours.
 - b. Consider measuring plasma/serum triglyceride concentrations to track fat elimination.
3. Patients can be discharged if the clinical status permits.
4. The maximum total dose of ILE is 16.5 mL/kg in 60 minutes.

Abbreviation: CRI, continuous rate infusion.

Dosing in Cardiotoxicity Induced by Intravenously Administered Drugs

When delaying therapy is detrimental in acute, potentially life-threatening cardiotoxicity, it is important to administer ILE in a short time frame. The human protocol in cardiotoxicity as a result of intravenous LAST is presented in **Box 2**. This dosing regime is often used in the veterinary literature.

SIDE EFFECTS

Cautions

- The administration of ILE can interfere with other treatment modalities; the creation of a lipid sink/shuttle may affect other lipophilic therapeutic drugs administered concurrently with ILE.
- Recurrence of clinical signs may occur following cessation of ILE therapy in humans.⁶³ The lipid emulsion may be eliminated more quickly than the toxic agent, depending on the pharmacokinetics of the toxic drug. Substances with a large volume of distribution have a tendency to accumulate in fat tissue, which may act as a drug reservoir slowly releasing the drug over a longer time frame. As a result, a rebound effect can be expected after cessation of ILE.
- Hyperlipemia as a result of ILE administration can interfere with common laboratory testing. The analytical interferences can be due to volume depletion

Box 2**Dosing protocol of intravenous lipid emulsions (20%) with severe, potentially life-threatening cardiotoxicity by (strong) lipophilic substances**

1. Administer one intravenous bolus injection of 1.5 mL/kg in 1 minute.
2. Immediately follow it by a CRI of 0.25 mL/kg/min (ie, 15 mL/kg/h).
3. After 5 minutes the clinical condition of patients is evaluated.
 - If necessary, a second bolus of 1.5 mL/kg can be administered in 1 minute. A final third bolus injection may be administered again 5 minutes later. A maximum of 3 bolus injections can be given.
 - The CRI can be increased to 0.5 mL/kg/min (30 mL/kg/h).
4. As soon as heart function and circulation are restored, the CRI has to be continued for at least 10 minutes or until the maximum dose for 30 minutes has been reached.
5. The maximum total dose of ILE is 10 to 12 mL/kg in 30 minutes.

Abbreviation: CRI, continuous rate infusion.

(electrolyte exclusion effect), turbidity, physicochemical interferences, and excipients within the lipid emulsion product.^{64–66} Whenever possible, blood samples should be collected before initiating lipid therapy. During ILE treatment, centrifugation of a lipemic plasma or serum sample at $14,000 \times g$ for 10 minutes may be used to reduce interference with most analytes as this removes greater than 90% of the triglycerides.⁶⁴ However, no single procedure can be used for all analytical methods.⁶⁶

- The Food and Drug Administration limits the maximum dose of ILE 20% for use in parenteral nutrition to 12.5 mL/kg over 24 hours in adult and 15 mL/kg in pediatric human patients.^a The use of ILE in intoxications has been off-label and no limits have been established. In human medicine these maximum limits for parenteral nutrition are respected in case of LAST; but extreme daily doses have been reported in case reports concerning other lipophilic drug intoxications, most often without serious consequences.⁶¹ High doses may be well tolerated, as a 50% lethal dose (LD_{50}) of 67.7 ± 10.7 mL/kg after a single 30-minute bolus of ILE in rats has been established. This dose is significantly higher than the total doses advocated for use in the treatment of drug toxicosis.⁶⁷ Also the product information leaflet of ClinOleic 20% suggests that even higher maximum doses are tolerated: “Single-dose toxicity was investigated in the mouse and rat to compare the LD_{50} of ClinOleic (refined olive oil and refined soybean oil lipid emulsion) 20% with that of 20% refined soybean oil lipid emulsion. LD_{50} values were comparable at around 100 to 112 mL/kg (corresponding to approximately 20 g lipid/kg) in both species with rapid infusion.”^b

Safety Considerations

Do not use ILE or consider the risks when there is a known allergy to the components, hyperlipidemia, a limited fat elimination/metabolism, an increased bleeding tendency, hypokalemia, or hypophosphatemia.

^b Product monograph ClinOleic 20% (Baxter Corporation, Mississauga, Ontario, USA) at http://www.baxter.ca/en/downloads/product_information/ClinOleic_PM_30Jul2014_EN.pdf.

Adverse Effects

Adverse effects of ILE therapy are rare, and extensive descriptions of potential side effects should not discourage the practitioner from its use. Two primary events may occur with the use of ILE: contamination and a direct reaction to components of the lipid product.

- Microbial contamination can be minimized by following the manufacturer's recommendations for storage and by properly handling the product with sterile techniques during application. Similar guidelines as with the use in parenteral nutrition can be followed.^{68,69} Contamination of the product may result in local (thrombophlebitis) and systemic infection.
- Allergic or anaphylactoid reactions to the product or its components, such as the egg phospholipid or the soybean oil components, rarely occur. Clinical signs include fever, nausea, hypotension, and cardiovascular collapse.⁸
- The volumes that are administered over a relatively short period can result in volume overload. If volume overload is a concern, other fluids should be stopped while administering the ILE or dosing rates need to be decreased.
- Excessive amounts of lipid can overwhelm the endogenous lipid clearance mechanism, especially in patients with a known decreased lipid plasma clearance. This condition is commonly referred to as the fat overload syndrome and can occur with rates of administration greater than 0.11 g/kg/h.⁸ Persistent gross lipemia has been described in patients treated with ILE without apparent consequences.¹⁴ However, suspected reversible corneal lipidosis following ILE in a cat with permethrin toxicosis and persistent hyperlipemia has recently been reported.³⁰
- In people, ILE has been associated with neurologic complications and adverse changes in pulmonary function in septic patients and those with acute respiratory distress syndrome.⁸
- Pancreatitis has been suggested as a complication of chronic hyperlipidemia; the association of increased plasma amylase concentration and the risk for pancreatitis with the use of ILE is currently unclear. Poison information centers do deliver anecdotal information of a potential relationship.⁹
- As with pancreatitis, hemolysis has also been reported anecdotally by poison information centers after ILE therapy.⁹
- Extravasation of lipid emulsions may cause mild local swelling and pain.³¹

CONCLUDING REMARKS

ILE is a promising treatment modality for poisonings with lipophilic agents. Despite the reported positive effects of ILE, in the authors' opinion, a critical attitude toward its use and efficacy remains warranted at this time. With our growing understanding of the mechanisms of action and its clinical use in veterinary medicine, ILE may become a standard of practice in the treatment of poisonings by lipophilic drugs in the future. Until then, it is important for the veterinary community to continue to report on the clinical use of ILE and measure blood drug concentrations to quantify efficacy more objectively. Alternatively, by involving poison information centers, their data collection systems can also facilitate registration and be used for future analyses of poisonings treated with ILE.

REFERENCES

1. Weinberg GL, VadeBoncouer T, Ramaraju GA, et al. Pretreatment or resuscitation with a lipid infusion shifts the dose-response to bupivacaine-induced asystole in rats. *Anesthesiology* 1998;88(4):1071–5.

2. Rosenblatt MA, Abel M, Fischer GW, et al. Successful use of a 20% lipid emulsion to resuscitate a patient after a presumed bupivacaine-related cardiac arrest. *Anesthesiology* 2006;105(1):217–8.
3. Litz RJ, Popp M, Stehr SN, et al. Successful resuscitation of a patient with ropivacaine-induced asystole after axillary plexus block using lipid infusion. *Anaesthesia* 2006;61(8):800–1.
4. Siriani AJ, Osterhoudt KC, Calello DP, et al. Use of lipid emulsion in the resuscitation of a patient with prolonged cardiovascular collapse after overdose of bupropion and lamotrigine. *Ann Emerg Med* 2008;51(4):412–5.
5. American College of Medical Toxicology. ACMT position statement: interim guidance for the use of lipid resuscitation therapy. *J Med Toxicol* 2011;7(1):81–2.
6. Neal JM, Barrington MJ, Brull R, et al. The second ASRA practice advisory on neurologic complications associated with regional anesthesia and pain medicine: executive summary 2015. *Reg Anesth Pain Med* 2015;40(5):401–30.
7. The Association of Anaesthetists of Great Britain & Ireland. AAGBI safety guideline - management of severe local anaesthetic toxicity. 2010. Available at: http://www.aagbi.org/sites/default/files/la_toxicity_2010_0.pdf. Accessed March 20, 2016.
8. Fernandez AL, Lee JA, Rahilly L, et al. The use of intravenous lipid emulsion as an antidote in veterinary toxicology. *J Vet Emerg Crit Care (San Antonio)* 2011;21(4):309–20.
9. Gwaltney-Brant S, Meadows I. Use of intravenous lipid emulsions for treating certain poisoning cases in small animals. *Vet Clin North Am Small Anim Pract* 2012;42(2):251–62.
10. Fettiplace MR, Weinberg G. Past, present, and future of lipid resuscitation therapy. *JPEN J Parenter Enteral Nutr* 2015;39(1 Suppl):72S–83S.
11. Clarke DL, Lee JA, Murphy LA, et al. Use of intravenous lipid emulsion to treat ivermectin toxicosis in a border collie. *J Am Vet Med Assoc* 2011;239(10):1328–33.
12. Dally AM, Kupper JR, Bruenisholz H, et al. Determination of ivermectin in plasma of a mini Shetland pony after poisoning using LC-MS/MS – effectiveness of intravenous lipid therapy. *Ther Drug Monit* 2011;33(4):489.
13. Bruenisholz H, Kupper J, Muentener CR, et al. Treatment of ivermectin overdose in a miniature Shetland pony using intravenous administration of a lipid emulsion. *J Vet Intern Med* 2012;26(2):407–11.
14. Wright HM, Chen AV, Talcott PA, et al. Intravenous fat emulsion as treatment for ivermectin toxicosis in three dogs homozygous for the ABCB1-1DELTA gene mutation. *J Vet Emerg Crit Care (San Antonio)* 2011;21(6):666–72.
15. Fettiplace MR, Akpa BS, Ripper R, et al. Resuscitation with lipid emulsion: dose-dependent recovery from cardiac pharmacotoxicity requires a cardiotoxic effect. *Anesthesiology* 2014;120(4):915–25.
16. Damitz R, Chauhan A. Parenteral emulsions and liposomes to treat drug overdose. *Adv Drug Deliv Rev* 2015;90:12–23.
17. Forster V, Leroux JC. Nano-antidotes for drug overdose and poisoning. *Sci Transl Med* 2015;7(290):290ps14.
18. Mazoit JX, Le Guen R, Beloeil H, et al. Binding of long-lasting local anesthetics to lipid emulsions. *Anesthesiology* 2009;110(2):380–6.
19. French D, Smollin C, Ruan W, et al. Partition constant and volume of distribution as predictors of clinical efficacy of lipid rescue for toxicological emergencies. *Clin Toxicol (Phila)* 2011;49(9):801–9.

20. Levine M, Hoffman RS, Lavergne V, et al. Systematic review of the effect of intravenous lipid emulsion therapy for non-local anesthetics toxicity. *Clin Toxicol (Phila)* 2016;54:194–221.
21. Hoegberg LC, Bania TC, Lavergne V, et al. Systematic review of the effect of intravenous lipid emulsion therapy for local anesthetic toxicity. *Clin Toxicol (Phila)* 2016;54:167–93.
22. Bolfer L, McMichael M, Ngwenyama TR, et al. Treatment of ibuprofen toxicosis in a dog with IV lipid emulsion. *J Am Anim Hosp Assoc* 2014;50(2):136–40.
23. Herring JM, McMichael MA, Corsi R, et al. Intravenous lipid emulsion therapy in three cases of canine naproxen overdose. *J Vet Emerg Crit Care (San Antonio)* 2015;25(5):672–8.
24. Bruckner M, Schwedes CS. Successful treatment of permethrin toxicosis in two cats with an intravenous lipid administration. *Tierarztl Prax Ausg K Kleintiere Heimtiere* 2012;40(2):129–34.
25. Hawthorth MD, Smart L. Use of intravenous lipid therapy in three cases of feline permethrin toxicosis. *J Vet Emerg Crit Care (San Antonio)* 2012;22(6):697–702.
26. Kuo K, Odunayo A. Adjunctive therapy with intravenous lipid emulsion and methocarbamol for permethrin toxicity in 2 cats. *J Vet Emerg Crit Care (San Antonio)* 2013;23(4):436–41.
27. DeGroot WD. Intravenous lipid emulsion for treating permethrin toxicosis in a cat. *Can Vet J* 2014;55(1):1253–4.
28. Muentener CR, Spicher C, Page SW. Treating permethrin poisoning in cats [letter]. *Vet Rec* 2013;172(24):643.
29. Ceccherini G, Perondi F, Lippi I, et al. Intravenous lipid emulsion and dexmedetomidine for treatment of feline permethrin intoxication: a report from 4 cases. *Open Vet J* 2015;5(2):113–21.
30. Seitz MA, Burkitt-Creedon JM. Persistent gross lipemia and suspected corneal lipidosis following intravenous lipid therapy in a cat with permethrin toxicosis. *J Vet Emerg Crit Care (San Antonio)* 2016. <http://dx.doi.org/10.1111/vec.12440>.
31. Bates N, Chatterton J, Robbins C, et al. Lipid infusion in the management of poisoning: a report of 6 canine cases. *Vet Rec* 2013;172(13):339.
32. Epstein SE, Hollingsworth SR. Ivermectin-induced blindness treated with intravenous lipid therapy in a dog. *J Vet Emerg Crit Care (San Antonio)* 2013;23(1):58–62.
33. Bolfer L, Brandt C, Shih A, et al. Use of single pass lipid dialysis for the treatment of avermectin toxicity. *Crit Care Med* 2013;41(12):A286–7.
34. Pritchard J. Treating ivermectin toxicity in cats. *Vet Rec* 2010;166(24):766.
35. Kidwell JH, Buckley GJ, Allen AE, et al. Use of IV lipid emulsion for treatment of ivermectin toxicosis in a cat. *J Am Anim Hosp Assoc* 2014;50(1):59–61.
36. Jourdan G, Boyer G, Raymond-Letron I, et al. Intravenous lipid emulsion therapy in 20 cats accidentally overdosed with ivermectin. *J Vet Emerg Crit Care (San Antonio)* 2015;25(5):667–71.
37. Saqib M, Abbas G, Mughal MN. Successful management of ivermectin-induced blindness in an African lion (*Panthera leo*) by intravenous administration of a lipid emulsion. *BMC Vet Res* 2015;11(1):287.
38. Gwaltney-Brant S, Dunayer E. The use of intravenous lipid solution therapy in the treatment of moxidectin overdose in a dog. Proceedings of the 51st Annual AAVLD Conference. Greensboro, NC, October 22–27, 2008. p. 118.
39. Crandell DE, Weinberg GL. Moxidectin toxicosis in a puppy successfully treated with intravenous lipids. *J Vet Emerg Crit Care (San Antonio)* 2009;19(2):181–6.

40. Kammerer M, Triffe J, Leclerc S, et al. Use of intravenous lipid emulsion to treat moxidectin intoxication in a cat. *Point Vet* 2013;44:12–5.
41. Khorzad R, Lee JA, Whelan M, et al. Baclofen toxicosis in dogs and cats: 145 cases (2004-2010). *J Am Vet Med Assoc* 2012;241(8):1059–64.
42. Butler J. Successful treatment of baclofen overdose with intravenous lipid emulsion. *Vet Med* 2014;109(1):6, 8–10, 12.
43. Edwards P, Shihab N, Scott HW. Treatment of a case of feline baclofen toxicosis with intravenous lipid therapy. *Vet Rec Case Rep* 2014;2:e000059. <http://dx.doi.org/10.1136/vetreccr-2014-000059>.
44. O'Brien TQ, Clark-Price SC, Evans EE, et al. Infusion of a lipid emulsion to treat lidocaine intoxication in a cat. *J Am Vet Med Assoc* 2010;237(12):1455–8.
45. Maton BL, Simmonds EE, Lee JA, et al. The use of high-dose insulin therapy and intravenous lipid emulsion to treat severe, refractory diltiazem toxicosis in a dog. *J Vet Emerg Crit Care (San Antonio)* 2013;23(3):321–7.
46. Meola SD, Tearney CC, Haas SA, et al. Evaluation of trends in marijuana toxicosis in dogs living in a state with legalized medical marijuana: 125 dogs (2005-2010). *J Vet Emerg Crit Care (San Antonio)* 2012;22(6):690–6.
47. Peacock RE, Hosgood G, Swindells KL, et al. A randomized, controlled clinical trial of intravenous lipid emulsion as an adjunctive treatment for permethrin toxicosis in cats. *J Vet Emerg Crit Care (San Antonio)* 2015;25(5):597–605.
48. Hansen SR. Small animal toxicology. In: Peterson ME, Talcott PA, editors. *Small animal toxicology*. 3rd edition. St Louis (MO): Saunders Inc; 2013. p. 769–75.
49. Malik R, Ward MP, Seavers A, et al. Permethrin spot-on intoxication of cats literature review and survey of veterinary practitioners in australia. *J Feline Med Surg* 2010;12(1):5–14.
50. Sutton NM, Bates N, Campbell A. Clinical effects and outcome of feline permethrin spot-on poisonings reported to the veterinary poisons information service (VPIS), London. *J Feline Med Surg* 2007;9(4):335–9.
51. Boland LA, Angles JM. Feline permethrin toxicity: retrospective study of 42 cases. *J Feline Med Surg* 2010;12(2):61–71.
52. Merola VM, Eubig PA. Toxicology of avermectins and milbemycins (macrocylic lactones) and the role of P-glycoprotein in dogs and cats. *Vet Clin North Am Small Anim Pract* 2012;42(2):313–33.
53. Rawson-Harris P, Bates N, Edwards N. Lipid infusion: An analysis of cases reported to the veterinary poisons information service (VPIS). *Clin Toxicol* 2015; 53(4):274–5.
54. Kaplan A, Whelan M. The use of IV lipid emulsion for lipophilic drug toxicities. *J Am Anim Hosp Assoc* 2012;48(4):221–7.
55. Williams K, Wells RJ, McLean MK. Suspected synthetic cannabinoid toxicosis in a dog. *J Vet Emerg Crit Care (San Antonio)* 2015;25(6):739–44.
56. Bischoff K, Smith MC, Stump S. Treatment of pieris ingestion in goats with intravenous lipid emulsion. *J Med Toxicol* 2014;10(4):411–4.
57. Parratt C. Intravenous lipid rescue for tremorogenic mycotoxicosis; assessment of response to therapy using a smartphone. Proceedings of the 13th EVECCS Congress. Prague, Czech Republic, June 13-15, 2014. p. 272–3.
58. Perichon D, Turfus S, Gerostamoulos D, et al. An assessment of the in vivo effects of intravenous lipid emulsion on blood drug concentration and haemodynamics following oro-gastric amitriptyline overdose. *Clin Toxicol* 2013;51(4):208–15.
59. Dunn C, Bird SB, Gaspari R. Intralipid fat emulsion decreases respiratory failure in a rat model of parathion exposure. *Acad Emerg Med* 2012;19(5):504–9.

60. Harvey M, Cave G, Shaw T. Effect of intravenous lipid emulsion and octreotide on enteric thiopentone absorption; a pilot study. *Clin Toxicol (Phila)* 2013;51(2): 117–8.
61. Fettiplace MR, Akpa BS, Rubinstein I, et al. Confusion about infusion: rational volume limits for intravenous lipid emulsion during treatment of oral overdoses. *Ann Emerg Med* 2015;66(2):185–8.
62. Fettiplace MR, Lis K, Ripper R, et al. Multi-modal contributions to detoxification of acute pharmacotoxicity by a triglyceride micro-emulsion. *J Control Release* 2015; 198:62–70.
63. Marwick PC, Levin AI, Coetzee AR. Recurrence of cardiotoxicity after lipid rescue from bupivacaine-induced cardiac arrest. *Anesth Analg* 2009;108(4):1344–6.
64. Grunbaum AM, Gilfix BM, Gosselin S, et al. Analytical interferences resulting from intravenous lipid emulsion. *Clin Toxicol (Phila)* 2012;50(9):812–7.
65. Grunbaum AM, Gilfix BM, Hoffman RS, et al. Review of the effect of intravenous lipid emulsion on laboratory analyses. *Clin Toxicol (Phila)* 2016;54(2):92–102.
66. Nikolac N. Lipemia: causes, interference mechanisms, detection and management. *Biochem Med* 2014;24(1):57–67.
67. Hiller DB, Di Gregorio G, Kelly K, et al. Safety of high volume lipid emulsion infusion: a first approximation of LD50 in rats. *Reg Anesth Pain Med* 2010;35(2): 140–4.
68. Michel KE, Eirman L. Parenteral nutrition. In: Silverstein DC, Hopper K, editors. *Small animal critical care medicine*. 2nd edition. St Louis (MO): Elsevier Inc; 2015. p. 687–90.
69. Larsen J. Parenteral nutrition. In: Burkitt-Creedon JM, Davis H, editors. *Advanced monitoring and procedures for small animal emergency and critical care*. 1st edition. Chichester (United Kingdom): Wiley-Blackwell; 2012. p. 513–22.