

# Patent Ductus Arteriosus and Brain Volume

Petra M.A. Lemmers, MD, PhD,<sup>a</sup> Manon J.N.L. Benders, MD, PhD,<sup>a</sup> Rita D'Ascenzo, MD,<sup>a,b</sup> Jorine Zethof,<sup>a</sup> Thomas Alderliesten, MD,<sup>a</sup> Karina J. Kersbergen, MD, PhD,<sup>a</sup> Ivana Isgum, PhD,<sup>c</sup> Linda S. de Vries, MD, PhD,<sup>a</sup> Floris Groenendaal, MD, PhD,<sup>a</sup> Frank van Bel, MD, PhD<sup>a</sup>

abstract

**BACKGROUND AND OBJECTIVES:** A hemodynamically significant patent ductus arteriosus (PDA) can compromise perfusion and oxygenation of the preterm brain. Reports suggest that PDA is associated with increased mortality and morbidity. We hypothesize that long-standing low cerebral oxygenation due to PDA might affect brain volume at term equivalent age.

**METHODS:** Observational study in 140 infants investigating the relationship between near-infrared spectroscopy-monitored cerebral oxygen saturation (rScO<sub>2</sub>) and MRI-assessed regional brain volume and maturation of the posterior limb of the internal capsule at term-equivalent age in 3 groups: those whose PDA closed with indomethacin, those who needed additional surgical closure, and matched controls.

**RESULTS:** The surgery group had the lowest rScO<sub>2</sub> values before closure ( $n = 35$ ),  $48\% \pm 9.7\%$  (mean  $\pm$  SD) as compared with the indomethacin ( $n = 35$ ),  $59\% \pm 10.4$  ( $P < .001$ ), and control groups ( $n = 70$ ),  $66\% \pm 6.9$  ( $P < .001$ ); the highest postnatal age before effective treatment; and the lowest volumes of most brain regions at term-equivalent age. Multiple linear regression analysis showed a significant effect of preductal closure rScO<sub>2</sub> on cerebellar volume in this group. No differences were found in maturation of the posterior limb of the internal capsule.

**CONCLUSIONS:** Long-standing suboptimal cerebral oxygenation due to a PDA may negatively influence brain growth, affecting neurodevelopmental outcome.

FREE

<sup>a</sup>Department of Neonatology, Wilhelmina Children's Hospital/University Medical Center Utrecht, Netherlands; <sup>b</sup>Division of Neonatology, Salesi's Children Hospital/UPM, Ancona, Italy; and <sup>c</sup>Image Sciences Institute, University Medical Center Utrecht, Netherlands

Dr Lemmers co-conceptualized and designed the study, carried out the initial analysis, and drafted the initial manuscript; Prof Benders codesigned the advanced MRI studies, supervised data collection, analyzed results, and contributed to writing the manuscript; Drs D'Ascenzo and Zethof were responsible for proper patient inclusion, parental consent, and data collection and were involved in writing the initial draft of the manuscript; Dr Alderliesten contributed to the design of the MRI studies, statistical analysis, and manuscript writing; Dr Kersbergen and Dr Isgum contributed to and coordinated analysis of the MRI data; Prof de Vries reviewed the study design and critically reviewed the manuscript; Dr Groenendaal determined the statistical methods used, contributed to the data analysis, and reviewed the manuscript; Prof van Bel co-conceptualized and designed the study, reviewed and contributed to the writing of the manuscript, and supervised the progress of the study; and all authors approved the manuscript as submitted.

**DOI:** 10.1542/peds.2015-3090

Accepted for publication Jan 12, 2016

Address correspondence to Petra M.A. Lemmers, MD, PhD, University Medical Center/Wilhelmina Children's Hospital, Dept of Neonatology, Room KE 04.123.1, PO Box 85090, 3508 AB Utrecht, Netherlands. E-mail: p.lemmers@umcutrecht.nl

**WHAT'S KNOWN ON THIS SUBJECT:** A patent ductus arteriosus leads to lower cerebral oxygenation, a risk factor for brain damage and poor outcomes. Reduced brain volume and myelination may be important causes of neurodevelopmental disability in preterm infants.

**WHAT THIS STUDY ADDS:** Preterm infants who needed surgical closure had the lowest cerebral oxygenations and a trend toward lower volumes in almost all brain regions. Long-standing suboptimal cerebral oxygenation due to a patent ductus arteriosus is a risk factor for adverse neurodevelopmental outcomes.

**To cite:** Lemmers PM, Benders MJ, D'Ascenzo R, et al. Patent Ductus Arteriosus and Brain Volume. *Pediatrics*. 2016;137(4):e20153090

Hemodynamically significant patent ductus arteriosus (PDA) is a common problem in preterm infants and can compromise oxygenation and perfusion of the immature brain. Several reports suggest that PDA is related to increased mortality and morbidity.<sup>1-3</sup>

Conservative management strategies of the PDA have become more prevalent, with less pharmacological closure and more supportive management. However, there is no evidence yet to support these changes in policy, and the risks of such an approach are unclear. Additionally, there is an important risk for adverse neurodevelopmental outcome in infants who eventually need surgical closure.<sup>4-8</sup> Moreover, Kabra et al<sup>9</sup> reported neurosensory impairment after surgical closure, and others have suggested that surgical closure is related to increased risk for poor short- and long-term outcomes.<sup>10</sup> Additionally, Jhaveri et al<sup>11</sup> found that a conservative approach toward ductal closure decreased rates of ductal ligation without increasing rates of complications such as bronchopulmonary dysplasia (BPD), retinopathy of prematurity, and neurologic injury. This evidence suggests that routine early treatment of PDA may not be beneficial and that (selective) delayed treatment may be an alternative.<sup>12</sup>

Our group found that surgical ductal closure had undesirable effects on cerebral oxygenation and blood pressure.<sup>13</sup> It might be that monitoring blood pressure, monitoring electrical brain activity with amplitude-integrated EEG, and near infrared spectroscopy (NIRS) monitoring of cerebral oxygenation may prevent or reduce these side effects of surgical closure. We also reported that PDA, even without surgical closure, had a negative effect on cerebral

oxygenation and suggested that prevention of especially long-standing PDA may reduce brain damage.<sup>14</sup>

The brain is vulnerable to multiple insults to which the premature infant is exposed because of its rapid growth during the premature period.<sup>15,16</sup> Reduced brain volume and reduced white matter anisotropy, as indicators of disturbances of maturation of the white matter, are probably important expressions of neurodevelopmental disability in premature infants.<sup>17-19</sup>

In this observational study we investigated the relationship between NIRS-monitored cerebral oxygenation with MRI-measured volumes of important brain regions at term-equivalent age (TEA) and changes in white matter anisotropy in 3 groups of infants: those whose PDA closed with indomethacin, those who needed additional surgical closure, and a matched control group of infants without PDA. We hypothesized that preterm infants with PDA and low cerebral oxygenation for a prolonged time would be prone to loss of brain tissue volume in important brain regions and reduced maturation of the white matter.

## METHODS

### Patient Population

As part of an observational prospective study, cerebral oxygenation and physiologic parameters (arterial oxygen saturation [ $\text{SaO}_2$ ], heart rate [HR], and blood pressure) of all preterm infants, with gestational ages (GAs) <32 completed weeks and consecutively admitted to the NICU, were monitored at least for the first 72 hours of life and in case of suspected PDA. From this cohort 140 infants were selected when an MRI was performed at term and were included in this study: 35

infants with PDA whose duct closed after indomethacin, 35 infants with PDA who needed additional surgical closure, and 70 infants without clinical or echocardiographic signs of PDA who served as controls. Control infants were individually matched with infants of 1 of the study groups. Matching criteria were GA (weeks), birth weight ( $\pm 50$  g), gender, year of birth, and proven sepsis between birth and MRI performance. Infants with congenital malformations were excluded. Informed parental consent was obtained for all patients. The medical ethical committee of the University Medical Center Utrecht approved the study.

### Clinical Data

Obstetric and intrapartum data were collected from hospital records. Neonatal data were collected prospectively. Treatment decisions for PDA were made by attending neonatologists based on guidelines used in our NICU. Diagnosis of a hemodynamically significant PDA was based on clinical indices and confirmed by echocardiographic investigation (left atrial or left ventricular dilatation 1:4, internal ductal diameter  $>1.4$  mm/kg, and left pulmonary artery end diastolic flow  $>0.2$  m/second).

We monitored  $\text{Sao}_2$  by using pulse oximetry on a limb, and we measured arterial blood pressure with indwelling arterial catheters (umbilical, tibial, and radial artery). Blood pressure support was started as indicated by guidelines used in our NICU. A blood pressure support scoring system was used to assess intensity of blood pressure support<sup>20</sup>; in brief, score 0 = no support, score 1 = volume expansion or dopamine  $\leq 5$   $\mu\text{g}/\text{kg}/\text{minute}$ , score 2 = dopamine  $>5 \leq 10$   $\mu\text{g}/\text{kg}/\text{minute}$ ; score 3 = dopamine  $>10$   $\mu\text{g}/\text{kg}/\text{minute}$  or dopamine and dobutamine  $>5$   $\mu\text{g}/\text{kg}/\text{minute}$ , score 4 = dopamine and

dobutamine >10 µg/kg/minute, and score 5 = additional adrenaline or corticosteroids.

Respiratory problems (eg, pulmonary emphysema, long duration of mechanical ventilation, or oxygen requirement) were considered to potentially affect brain development if corticosteroids were necessary.<sup>21</sup>

Periventricular–intraventricular hemorrhage (PIVH) was categorized as mild if extensiveness was maximal grade 2 and moderate to severe if grade 3 or 4 (according to grading of Papile et al).<sup>22</sup>

### Monitoring of Cerebral Tissue Oxygenation and Oxygen Extraction

We used the NIRS-determined regional cerebral oxygen saturation (rScO<sub>2</sub>), as part of standard clinical care, as an estimator for changes in regional cerebral oxygenation. Although rScO<sub>2</sub> is not a robust quantitative estimator of cerebral oxygenation, it can be reliably used in individual patients to detect substantial changes in cerebral oxygenation.<sup>23,24</sup> We used INVOS 4100/5100 near infrared spectrometers (Covidien, Mansfield, MA) with the Small Adult SomaSensor (SAFB-SM). A transducer containing a light-emitting diode and 2 distant sensors was attached to the frontoparietal side of the head. We calculated rScO<sub>2</sub> from the differential signals obtained from these 2 sensors, expressed as venous-weighted percentage of oxygenated hemoglobin (oxygenated hemoglobin/total hemoglobin [oxygenated hemoglobin + deoxygenated hemoglobin]).<sup>25</sup>

### MRI Data Acquisition

MRI was performed around TEA in all infants. Infants born from 2007 onward were scanned on a 3.0 Tesla MR system (Achieva, Philips Medical Systems, Best, Netherlands)

with the 8-channel sense head coil. MRI of the brain was performed in all infants at TEA as routine clinical care. Between 2007 and June 2008, the imaging protocol contained axial three-dimensional T1-weighted and T2-weighted images (repetition time [TR] 9.4 milliseconds, echo time [TE] 4.6 milliseconds, slice thickness 2.0 mm; and TR 6293 milliseconds, TE 120 milliseconds, and slice thickness 2.0 mm, respectively). From June 2008 onward, three-dimensional T1-weighted and T2-weighted images were acquired in coronal planes (three-dimensional T1-weighted: TR 9.5 milliseconds, TE 4.6 milliseconds, slice thickness 1.2 mm and T2-weighted TR 4847 milliseconds, TE 150 milliseconds, slice thickness 1.2 mm). The diffusion tensor imaging (DTI) acquisition was a single-shot spin-echo echoplanar imaging sequence (echoplanar imaging factor 55, TR/TE 5685/70 milliseconds, field of view 180 × 146 mm, acquisition matrix 128 × 102 mm, reconstruction matrix 128 × 128 mm, 50 slices with 2-mm thickness without gap). Images were acquired in the axial plane with diffusion gradients applied in 32 noncollinear directions with a b-value of 800 seconds/mm<sup>2</sup> and 1 non-diffusion weighted image, with a total scan time of 4.28 minutes.<sup>26</sup>

Infants were sedated with oral chloral hydrate, at a maximum of 50 mg/kg. HR, SaO<sub>2</sub>, and respiratory rate were monitored. For hearing protection, Minimuffs (Natus Medical Incorporated, San Carlos, CA) were used. A neonatologist was present throughout the examination. All MRI examinations were reevaluated by 2 experienced neonatologists.

### Image Processing

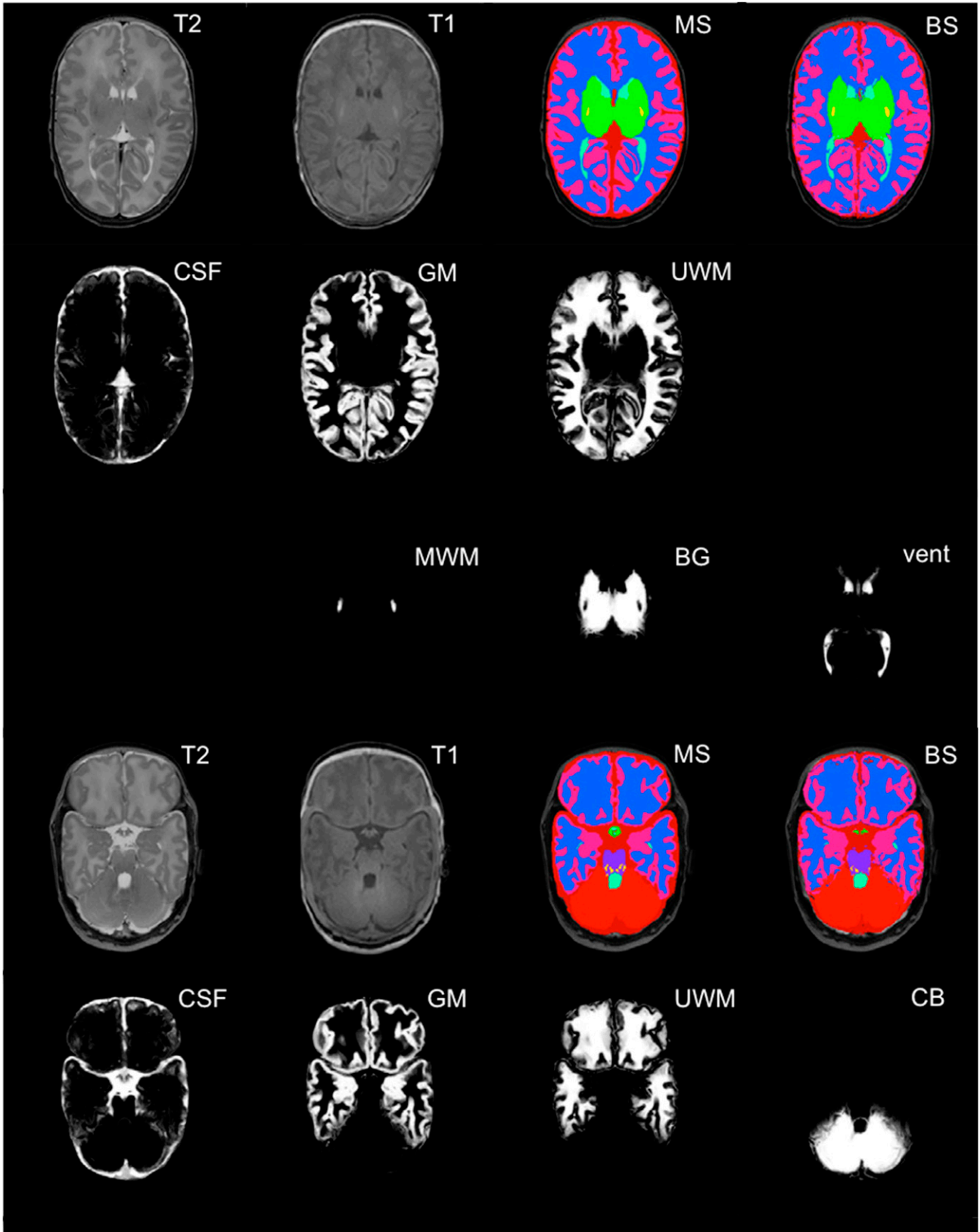
We used a fully automatic brain segmentation method for segmentation of 8 different brain

structures; cortical gray matter (GM), basal ganglia (BG), cerebral ventricles (Vent), unmyelinated white matter (UWM), brainstem (BS), cerebellum (CB), and total brain volume (TBV) were used for statistical analysis.

We used the algorithm of Anbeek et al.<sup>27</sup> The proposed segmentation algorithm is based on supervised pixel classification. T1- and T2-weighted images provided intensity information, and voxel position (ie, x-, y-, and z-coordinates in the coordinate system of the average brain) gave spatial characteristics. Based on these features, each brain voxel was assigned to 1 of the 8 tissue classes via the *k*-nearest neighbors classifier. In this way, probabilistic segmentation was generated for each tissue. To obtain binary segmentations, each voxel was assigned to the tissue class with the highest posterior probability determined by using the *k*-nearest neighbors classifier. An example is shown in Fig 1.

The Anbeek method was developed for axially acquired images. However, we tested for differences in volumes between coronal and axial acquired images in a subgroup of 5 infants scanned both coronally and axially and did not find any differences in volumes.<sup>28,29</sup> In addition, to confirm the quality of automatically obtained segmentations, results were visually inspected. This allowed us to combine these sets into 1 cohort. TBV was defined as the volume of all brain tissue, that is, intracranial volume without the volume of the ventricles and cerebrospinal fluid. Both absolute volumes and relative percentage of each tissue class in reference to TBV were analyzed.<sup>28,30</sup>

DTI data were analyzed with the diffusion MR toolbox ExploreDTI, version 4.8.3 (<http://www.ExploreDTI.com>)<sup>31</sup> and consisted of the following steps: (1) correction



**FIGURE 1**

Probabilistic segmentations of intracranial tissues on 2 different levels and colored binary segmentations. BG, basal ganglia and thalami; CSF, cerebrospinal fluid; GM, cortical gray matter; MWM, myelinated white matter; T1, T1-weighted image; T2, T2-weighted image; vent, ventricles. Additionally, the manual segmentations (MS) are shown, used as gold standard, to show the final obtained binary segmentation (BS).

for subject motion and eddy current-induced distortions<sup>32</sup>; (2) tensor estimation via the REKINDLE approach for outlier detection,<sup>33</sup> with iteratively reweighted linear least squares estimation after identification and removal of data outliers; and (3) automated atlas-based analysis with the neonatal atlas developed in by Oishi et al<sup>34</sup> (template and parcellated atlas regions are publicly available at <http://cmrm.med.jhmi.edu/>) using affine and elastic registration based on elastix.<sup>35</sup> All DTI data were visually checked in terms of quality of tensor estimation and quality of registration as described in Kersbergen et al.<sup>36</sup> After these preprocessing steps, diffusivity values were calculated in the left and right posterior limb of the internal capsule (PLIC).

### Study Design

Monitoring of arterial blood pressure, HR,  $SaO_2$ , and  $rScO_2$  was started shortly after birth and in case of suspected PDA, as is standard care in our unit. Each infant with hemodynamically significant PDA was treated with indomethacin (3 intravenous doses of 0.2 mg/kg every 12 hours). If the duct was responsive to indomethacin but not yet closed, a second course of indomethacin was administered. Infants whose PDA did not close with indomethacin underwent subsequent surgical ligation. The surgical procedure always was performed by experienced pediatric cardiovascular surgeons and anesthesiologists in the NICU. The end point of monitoring for this study was defined as 24 hours after the last dose of indomethacin or surgical closure, respectively. The simultaneously collected data were stored on a personal computer for offline analysis (sample frequency 1 Hz) (software: Poly 5, Inspektor Research Systems,

Amsterdam, Netherlands). The arterial hemoglobin concentration was measured daily or more frequently if indicated. Blood gases were measured just before, during, and immediately after the surgical procedure and then every 4 hours up to 24 hours after surgery, or more frequently if necessary. Cranial ultrasound was performed before and repeated within 24 hours after surgery (or more frequently where appropriate).

To reduce the data to manageable proportions and to be able to make comparisons over time, a 30-minute period of monitored data was selected and averaged for  $rScO_2$ ,  $SaO_2$ , mean arterial blood pressure (MABP), and HR for infants whose PDA closed with indomethacin just before the start of indomethacin and, in case of surgery, just before the start of the surgical procedure. Because no long-standing NIRS data (>72 hours after birth) of control infants were available, measurements were chosen on day 3 after birth during a hemodynamically stable time.

### Statistical Analysis

Data are summarized as mean values  $\pm$  SD, as median values and ranges, or as count and percentage where appropriate. Differences between clinical characteristics,  $rScO_2$ ,  $SaO_2$ , MABP, and HR between groups were evaluated as appropriate by Pearson  $\chi^2$  test, Mann-Whitney test, or analysis of variance. Adjustments for multiple comparisons were made by a Bonferroni test.

Multivariable linear regression (MLR) analyses were then used to investigate the relationship between respective volumes of interest of MRI-measured brain regions or diffusivity values of the PLIC on the one hand and  $rScO_2$ , postmenstrual age (PMA) at MRI (important

variable influencing the volumes and diffusivity measures of the measured brain regions) and 2 conditions that may have a negative effect on brain growth on the other hand (PIVH grade [mild or moderate to severe PIVH] and severe BPD, defined as BPD necessitating treatment with corticosteroids).

MLR models were then constructed with GM, BG, Vent, UWM, BS, CB volumes, and TBV as the respective dependent variables and  $rScO_2$ , PMA at MRI, PIVH grading (none, mild, or moderate to severe), and severe BPD (yes/no) as independent variables. Results were presented as coefficients of the independent variables with 95% confidence intervals (CIs). The final model was reduced to include only significant variables at the .05 level.

A  $P \leq .05$  was considered statistically significant. For statistical analysis, SPSS version 20.0 (IBM SPSS Statistics, IBM Corporation) was used.

## RESULTS

### Clinical Characteristics

Clinical data for the 3 groups are shown in Table 1. Gender, GA, birth weight, Apgar scores, and occurrence of proven sepsis did not differ between the groups. Hemoglobin concentrations were always stable, in the normal range, and not different between groups, as were arterial blood gases and  $Pco_2$  values (data not shown).

Days on artificial ventilation were significantly different between the groups, highest in surgery and lowest in controls ( $P < .05$ ). Also, the incidence of corticosteroid treatment was higher in indomethacin ( $P < .05$ ) and surgery ( $P < .05$ ) groups than in the control group.

## Patterns of rScO<sub>2</sub>, Sao<sub>2</sub>, MABP, and HR Before Ductal Closure

Figure 2 shows the rScO<sub>2</sub> values of the groups. The preclosure values of rScO<sub>2</sub> were lowest in the surgery group as compared with indomethacin group (mean ± SD, 48% ± 9.7% and 59% ± 10.4%; mean difference, -10; 95% CI, -15.7 to -5.7; *P* < .001) and controls (mean ± SD, 48% ± 9.7% and 66% ± 6.9%; mean difference, -18; 95% CI, -22.8 to -13.4; *P* < .001). Also, rScO<sub>2</sub> values of the indomethacin group were lower compared with controls (mean ± SD, 59% ± 10.4% and 66% ± 6.9%; mean difference, -7; 95% CI, -11.3 to -2.6; *P* < .001). Figure 3 shows the relationship between preductal closure values of the individual rScO<sub>2</sub> of indomethacin and surgery groups as function of postnatal age, revealing that lowest rScO<sub>2</sub> values were detected during advanced postnatal age, during a long-standing PDA (*r* = 0.5, *P* < .05). The postnatal age at ductal closure (median [range]) was 6 (3–21) and 9 (3–32) days after indomethacin and surgical closure, respectively.

Table 2 shows Sao<sub>2</sub>, HR, and MABP (mean ± SD) of the groups before ductal closure. Although MABP and HR were different in the indomethacin and surgery groups, respectively, as compared with controls (34 ± 5 mm Hg vs 39 ± 8 mm Hg, *P* < .05 and 161 ± 18 beats per minute vs 153 ± 9 beats per minute, *P* < .05), they were not considered to be clinically relevant.

### MRI-Measured Volumes of Selected Brain Regions and Diffusivity Values of Left/Right PLIC in Control, Indomethacin, and Surgery Groups and Their Relationship With rScO<sub>2</sub>

Table 3 summarizes MRI-measured volumes of 7 brain

**TABLE 1** Clinical Characteristics of the Studied Patient Groups

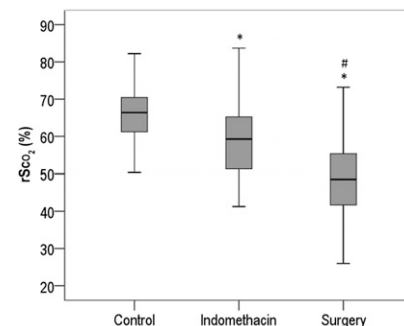
	Control <i>n</i> = 70	Indomethacin <i>n</i> = 35	Surgery <i>n</i> = 35
Gender, male (%)	46 (66)	21 (60)	23 (66)
GA mean, wk, mean ± SD	26.6 ± 0.9	26.4 ± 1.2	26.3 ± 1.3
BW, g, mean ± SD	925 ± 21	917 ± 171	918 ± 191
PNA start PDA treatment, d, median (range)	NA	4 (1–18)	9 (3–33)
PMA MRI at term, wk, mean ± SD	41.3 ± 0.8	41.3 ± 0.6	41.1 ± 0.6
5-min Apgar score, median (range)	8 (3–10)	8 (2–9)	8 (4–9)
Inotropic score ≥ 2, <i>n</i> (%)	12 (17)	11 (31)	13 (37)
Days of ventilation, median (range)	5 (0–42)*	9 (1–40)**	14 (0–42)***
BPD, <i>n</i> (%)	16 (23)	11 (31)**	21 (60)***
Sepsis, <i>n</i> (%)	26 (37)	19 (54)	17 (49)
PIVH, <i>n</i> (%)			
None	47 (67)	23 (66)**	12 (34)***
Mild	15 (21)	10 (29)	15 (43)
Moderate or severe	8 (11)	2 (6)	8 (23)
NEC, <i>n</i> (%)	0 (0)	0 (0)	2 (6)

BPD, bronchopulmonary disease defined as BPD necessitating corticosteroids; BW, birth wt; NEC, necrotizing enterocolitis; PNA, postnatal age.

\* Controls versus indomethacin *P* < .05.

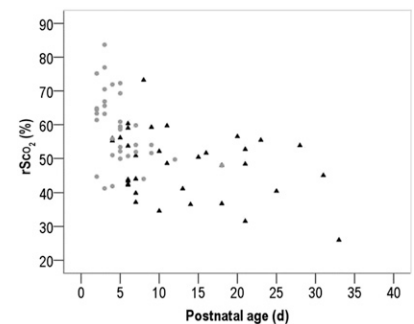
\*\* Indomethacin versus surgery *P* < .05.

\*\*\* Surgery versus controls *P* < .05.



**FIGURE 2**

Box-whisker plots of the rScO<sub>2</sub> percentage of the matched control, indomethacin, and surgery groups (\**P* < .001 indomethacin versus controls and surgery versus controls, respectively, and #*P* < .001 indomethacin versus surgery).



**FIGURE 3**

The preductal closure rScO<sub>2</sub> percentages of the indomethacin (circles) and surgery (triangles) groups as a function of postnatal age in days (*r* = 0.50, *P* < .05).

**TABLE 2** Sao<sub>2</sub> and Hemodynamic Measurements (mean ± SD) in the Study Groups

	Controls	Indomethacin	Surgery
Sao <sub>2</sub> , %	93 ± 5	93 ± 6	92 ± 4
MABP, mm Hg	39 ± 8*	34 ± 5	37 ± 7
HR, beats per minute	153 ± 9	153 ± 12	161 ± 18**

\* Controls versus indomethacin *P* < .05.

\*\* Surgery versus controls *P* < .05.

regions and diffusivity values of left and right PLIC of the groups. Although no significant differences were detected between groups, the surgery group had consistently the lowest volumes in brain regions as

compared with indomethacin and control groups.

Diffusivity values between groups did not differ and no relation was detected between diffusivity values and rScO<sub>2</sub>.

## MLR Analyses Between Regional Brain Volumes and rScO<sub>2</sub>, PMA at MRI, PIVH Grade, and Severity of BPD

MLR analysis revealed only a significant effect of the preductal closure value of rScO<sub>2</sub> on cerebellar volume of the surgery group (coefficient rScO<sub>2</sub>, +0.20 mL CB volume per % of rScO<sub>2</sub>). No additional relationships between the respective investigated regional brain volumes and rScO<sub>2</sub>, PMA, PIVH grade, or severity of BPD were found in any infant group.

## DISCUSSION

The results of our study showed that infants whose PDA had to be closed surgically had the lowest cerebral oxygenation before closure, often near or within pathologic ranges (rScO<sub>2</sub> <40%) reported to be related to brain damage if persisting for a prolonged period of time.<sup>37-39</sup> Although infants of the surgery group showed the lowest volumes in most brain regions, volumes were not significantly different between the 3 groups. This is in disagreement with our hypothesis and with Padilla et al,<sup>40</sup> who reported a significant reduction in MRI-measured global and regional brain volumes, especially cerebellar growth. Impairment of cerebellar growth associated with PDA was reported earlier, although differences in population and methods may hamper reliable comparison between the studies.<sup>41,42</sup>

Despite our inclusive results, we suggest that long-standing suboptimal oxygenation of the brain may negatively influence the growth of vulnerable brain regions such as the CB. This suggestion is also supported by results of the MLR analysis showing a relationship between cerebellar volume and preductal closure values of rScO<sub>2</sub> in the surgery group.

**TABLE 3** MRI-Measured Volumes (mean ± SD) of Important Brain Regions (mL) and Diffusivity Values of Left and Right PLIC of the 3 Study Groups at TEA

	Controls	Indomethacin	Surgery
CB	28.7 ± 4.2	28.2 ± 3.6	27.1 ± 4.4
BS	5.6 ± 0.9	5.7 ± 0.8	5.5 ± 0.9
BG	22.6 ± 3.5	22.3 ± 2.1	22.0 ± 3.2
Vent	9.0 ± 4.3	8.5 ± 3.4	10.0 ± 5.1
UWM	153.0 ± 17.4	150.1 ± 14.1	149.1 ± 22.5
GM	154.1 ± 24.3	147.9 ± 19.0	149.2 ± 22.6
TBV	369.4 ± 41.0	358.7 ± 29.8	365.2 ± 41.3
	N = 53	N = 26	N = 22
FA PLIC left	0.44 ± 0.03	0.43 ± 0.02	0.44 ± 0.03
FA PLIC right	0.42 ± 0.02	0.42 ± 0.02	0.43 ± 0.02
AD PLIC left	1.56 × 10 <sup>-3</sup> ± 6.2 × 10 <sup>-5</sup>	1.58 × 10 <sup>-3</sup> ± 6.0 × 10 <sup>-5</sup>	1.58 × 10 <sup>-3</sup> ± 6.8 × 10 <sup>-5</sup>
AD PLIC right	1.54 × 10 <sup>-3</sup> ± 5.6 × 10 <sup>-5</sup>	1.57 × 10 <sup>-3</sup> ± 6.8 × 10 <sup>-5</sup>	1.56 × 10 <sup>-3</sup> ± 7.1 × 10 <sup>-5</sup>
RD PLIC left	7.81 × 10 <sup>-4</sup> ± 6.0 × 10 <sup>-5</sup>	7.99 × 10 <sup>-4</sup> ± 4.6 × 10 <sup>-5</sup>	7.91 × 10 <sup>-4</sup> ± 7.0 × 10 <sup>-5</sup>
RD PLIC right	7.86 × 10 <sup>-4</sup> ± 5.2 × 10 <sup>-5</sup>	8.08 × 10 <sup>-4</sup> ± 4.2 × 10 <sup>-5</sup>	7.98 × 10 <sup>-4</sup> ± 5.6 × 10 <sup>-5</sup>
MD PLIC left	1.04 × 10 <sup>-3</sup> ± 5.9 × 10 <sup>-5</sup>	1.06 × 10 <sup>-3</sup> ± 4.6 × 10 <sup>-5</sup>	1.05 × 10 <sup>-3</sup> ± 6.5 × 10 <sup>-5</sup>
MD PLIC right	1.04 × 10 <sup>-3</sup> ± 5.1 × 10 <sup>-5</sup>	1.06 × 10 <sup>-3</sup> ± 4.6 × 10 <sup>-5</sup>	1.05 × 10 <sup>-3</sup> ± 5.8 × 10 <sup>-5</sup>

AD, axial diffusivity; FA, fractional anisotropy; MD, mean diffusivity; RD, radial diffusivity.

How can we explain the lack of difference in regional volumes in the surgery group as compared with the control and indomethacin groups, as opposed to earlier studies?<sup>40-42</sup> We postulate that the amount of time elapsed between the diagnosis of PDA and actual surgical closure may have played a role here. In our institution we aim to close the duct early: When a PDA is clinically diagnosed and confirmed by echocardiographic investigation, noninvasive closure is always initiated. If not responding to medical treatment, the duct will subsequently be closed surgically. This procedure is different from current practice in several centers, which postpone medical or surgical treatment. This tendency to postpone medical or surgical ductal closure<sup>4,11, 12</sup> and thus accept a longer episode of suboptimal cerebral oxygenation may be a reason for the reported negative effects of PDA on brain growth.<sup>40-42</sup> As stated earlier, the result of the MLR analysis, showing a relationship between cerebellar volume and cerebral oxygenation in the surgery group, which had the highest postnatal age and lowest cerebral oxygenation (see also Fig 3), may substantiate this assumption. Thus, our active approach to a hemodynamically significant PDA may have largely prevented negative

effects of suboptimal oxygenation on the immature brain<sup>43</sup> and in particular on the CB.<sup>44,45</sup>

Nonetheless, we cannot exclude the possibility that the surgical procedure itself may have compromised brain development,<sup>46</sup> because it is reported that opiates used for anesthesia increased supraspinal apoptosis in distinct anatomic regions of the brain, as has been shown in neonatal rats.<sup>47</sup> Additional research is warranted to explore this possibility.

Our study has an important limitation. We tried to match infants with PDA with non-PDA controls as closely as possible. However, the infants in the surgical group were also the sicker ones, as indicated by a higher incidence of corticosteroid treatment. Earlier studies showed that the corticosteroid dexamethasone, used mostly to prevent BPD, has a negative effect on brain growth and especially on cerebellar growth.<sup>48</sup> However, we did not find an independent effect of corticosteroid-treated BPD on the volume of any brain region. An explanation may be that in our institution hydrocortisone is used instead of dexamethasone. Recent studies showed that hydrocortisone did not negatively influence the

volumes of important brain regions, as investigated by MRI, compared with non-steroid-treated matched preterm infants.<sup>28</sup>

The question of whether infants with PDA and especially those who need surgical closure are at risk for suboptimal development of the immature brain is not fully answered by the results of our study. However, our findings indicate that not only the surgery and anesthesia procedures but also presurgical long-standing hypoxia may play a role with respect to a less favorable neurodevelopmental outcome of infants with surgically closed ducts, as has been reported in other studies.<sup>5,9</sup> We therefore suggest that the preferred treatment for PDA unresponsive to pharmacological treatment should be surgical closure to avoid long-standing periods of low cerebral saturations. We also suggest performing surgical procedures under close monitoring of blood pressure, cerebral oxygenation, and electrical brain activity to ensure optimal conditions during surgery.<sup>13</sup> It remains to be proven whether this approach can avoid additional brain damage. A recent

randomized controlled multicenter study (SafeboosC II) showed a significant reduction in burden of cerebral hypoxia due to monitoring with NIRS, compared with controls treated under predefined clinical guidelines.<sup>49</sup> Alternatively, one can decide to delay ductal closure under cerebral oxygenation monitoring. If cerebral oxygenation is not compromised, spontaneous ductal closure can then be awaited.

### CONCLUSIONS

We found that infants with surgical PDA closure had lowest (often long-standing) cerebral oxygen saturations before ductal closure and a tendency for lower volumes of important brain regions at TEA. Moreover, a relationship was detected between cerebellar volume and rScO<sub>2</sub>. Additional research is warranted to explore whether an expectant policy toward ductal closure, the current practice in several institutions, may lead to extended episodes of suboptimal cerebral oxygenation, which may explain the lower brain volumes reported in other studies.

### ABBREVIATIONS

BG:	basal ganglia
BPD:	bronchopulmonary dysplasia
BS:	brainstem
CB:	cerebellum
CI:	confidence interval
DTI:	diffusion tensor imaging
GA:	gestational age
GM:	gray matter
HR:	heart rate
MABP:	mean arterial blood pressure
MLR:	multivariable linear regression
NIRS:	near infrared spectroscopy
PDA:	patent ductus arteriosus
PIVH:	periventricular-intraventricular hemorrhage
PLIC:	posterior limb of the internal capsule
PMA:	postmenstrual age
rScO <sub>2</sub> :	regional cerebral oxygen saturation
Sao <sub>2</sub> :	arterial oxygen saturation
TBV:	total brain volume
TE:	echo time
TEA:	term-equivalent age
TR:	repetition time
UWM:	unmyelinated white matter
Vent:	lateral ventricles

PEDIATRICS (ISSN Numbers: Print, 0031-4005; Online, 1098-4275).

Copyright © 2016 by the American Academy of Pediatrics

**FINANCIAL DISCLOSURE:** The authors have indicated they have no financial relationships relevant to this article to disclose.

**FUNDING:** MRI studies in the years 2007 to 2009 were funded by The Netherlands Organisation for Health Research and Development (ZonMW project nr 945-27-022).

**POTENTIAL CONFLICT OF INTEREST:** The authors have indicated they have no potential conflicts of interest to disclose.

**COMPANION PAPER:** A companion to this article can be found online at [www.pediatrics.org/cgi/doi/peds.2015-4659](http://www.pediatrics.org/cgi/doi/peds.2015-4659).

### REFERENCES

1. Kluckow M, Evans N. Low superior vena cava flow and intraventricular haemorrhage in preterm infants. *Arch Dis Child Fetal Neonatal Ed*. 2000;82(3):F188–F194
2. Noori S, McCoy M, Friedlich P, et al. Failure of ductus arteriosus closure is associated with increased mortality in preterm infants. *Pediatrics*. 2009;123(1). Available at: [www.pediatrics.org/cgi/content/full/123/1/e138](http://www.pediatrics.org/cgi/content/full/123/1/e138)
3. Drougia A, Giapros V, Krallis N, et al. Incidence and risk factors for cerebral palsy in infants with perinatal problems: a 15-year review. *Early Hum Dev*. 2007;83(8):541–547
4. Noori S. Patent ductus arteriosus in the preterm infant: to treat or not to treat? *J Perinatol*. 2010;30(suppl):S31–S37
5. Noori S. Pros and cons of patent ductus arteriosus ligation: hemodynamic changes and other morbidities after patent ductus arteriosus ligation. *Semin Perinatol*. 2012;36(2):139–145
6. Jain A, Shah PS. Diagnosis, evaluation, and management of patent ductus arteriosus in preterm neonates. *JAMA Pediatr*. 2015;169(9):863–872
7. Benjamin JR, Smith PB, Cotten CM, Jaggars J, Goldstein RF, Malcolm WF. Long-term morbidities associated with vocal cord paralysis after surgical



- closure of a patent ductus arteriosus in extremely low birth weight infants. *J Perinatol*. 2010;30(6):408–413
8. Roze JC, Cambonie G, Marchand-Martin L, et al; Hemodynamic EPIPAGE 2 Study Group. Association between early screening for patent ductus arteriosus and in-hospital mortality among extremely preterm infants. *JAMA*. 2015;313(24):2441–2448
  9. Kabra NS, Schmidt B, Roberts RS, Doyle LW, Papile L, Fanaroff A. Neurosensory impairment after surgical closure of patent ductus arteriosus in extremely low birth weight infants: results from the Trial of Indomethacin Prophylaxis in Preterms. *J Pediatr*. 2007;150(3):229–234
  10. Madan JC, Kendrick D, Hagadorn JI, Frantz ID III; National Institute of Child Health and Human Development Neonatal Research Network. Patent ductus arteriosus therapy: impact on neonatal and 18-month outcome. *Pediatrics*. 2009;123(2):674–681
  11. Jhaveri N, Moon-Grady A, Clyman RI. Early surgical ligation versus a conservative approach for management of patent ductus arteriosus that fails to close after indomethacin treatment. *J Pediatr*. 2010;157(3):381–387
  12. Benitz WE. Learning to live with patency of the ductus arteriosus in preterm infants. *J Perinatol*. 2011;31(suppl 1):S42–S48
  13. Lemmers PM, Molenschot MC, Evens J, Toet MC, van Bel F. Is cerebral oxygen supply compromised in preterm infants undergoing surgical closure for patent ductus arteriosus? *Arch Dis Child Fetal Neonatal Ed*. 2010;95(6):F429–F434
  14. Lemmers PM, Toet MC, van Bel F. Impact of patent ductus arteriosus and subsequent therapy with indomethacin on cerebral oxygenation in preterm infants. *Pediatrics*. 2008;121(1):142–147
  15. Kostovic I, Judas M. Prolonged coexistence of transient and permanent circuitry elements in the developing cerebral cortex of fetuses and preterm infants. *Dev Med Child Neurol*. 2006;48(5):388–393
  16. Kostović I, Kostović-Srzić M, Benjak V, Jovanov-Milošević N, Radoš M. Developmental dynamics of radial vulnerability in the cerebral compartments in preterm infants and neonates. *Front Neurol*. 2014;5:139
  17. Inder TE, Warfield SK, Wang H, Hüppi PS, Volpe JJ. Abnormal cerebral structure is present at term in premature infants. *Pediatrics*. 2005;115(2):286–294
  18. Boardman JP, Counsell SJ, Rueckert D, et al. Abnormal deep grey matter development following preterm birth detected using deformation-based morphometry. *Neuroimage*. 2006;32(1):70–78
  19. Ball G, Pazderova L, Chew A, et al. Thalamocortical connectivity predicts cognition in children born preterm. *Cereb Cortex*. 2015;25(11):4310–4318
  20. Krediet TG, Valk L, Hempenius I, Egberts J, van Bel F. Nitric oxide production and plasma cyclic guanosine monophosphate in premature infants with respiratory distress syndrome. *Biol Neonate*. 2002;82(3):150–154
  21. Yeh TF, Lin YJ, Huang CC, et al. Early dexamethasone therapy in preterm infants: a follow-up study. *Pediatrics*. 1998;101(5). Available at: [www.pediatrics.org/cgi/content/full/101/5/e7](http://www.pediatrics.org/cgi/content/full/101/5/e7)
  22. Papile LA, Munsick-Bruno G, Schaefer A. Relationship of cerebral intraventricular hemorrhage and early childhood neurologic handicaps. *J Pediatr*. 1983;103(2):273–277
  23. van Bel F, Lemmers P, Naulaers G. Monitoring neonatal regional cerebral oxygen saturation in clinical practice: value and pitfalls. *Neonatology*. 2008;94(4):237–244
  24. Naulaers G, Meyns B, Miserez M, et al. Use of tissue oxygenation index and fractional tissue oxygen extraction as non-invasive parameters for cerebral oxygenation. A validation study in piglets. *Neonatology*. 2007;92(2):120–126
  25. Wyatt JS, Cope M, Delpy DT, Wray S, Reynolds EO. Quantification of cerebral oxygenation and haemodynamics in sick newborn infants by near infrared spectrophotometry. *Lancet*. 1986;2(8515):1063–1066
  26. Jones DK, Leemans A. Diffusion tensor imaging. *Methods Mol Biol*. 2011;711:127–144
  27. Anbeek P, Išgum I, van Kooij BJ, et al. Automatic segmentation of eight tissue classes in neonatal brain MRI. *PLoS One*. 2013;8(12):e81895
  28. Kersbergen KJ, de Vries LS, van Kooij BJ, et al. Hydrocortisone treatment for bronchopulmonary dysplasia and brain volumes in preterm infants. *J Pediatr*. 2013;163(3):666–71.e1
  29. Blok CA, Kersbergen KJ, van der Aa NE, et al. Unmyelinated white matter loss in the preterm brain is associated with early increased levels of end-tidal carbon monoxide. *PLoS One*. 2014;9(3):e89061
  30. Van Kooij BJ, Benders MJ, Anbeek P, Van Haastert IC, De Vries LS, Groenendaal F. Cerebellar volume and proton magnetic resonance spectroscopy at term, and neurodevelopment at 2 years of age in preterm infants. *Dev Med Child Neurol*. 2012;54(3):260–266
  31. Leemans A, Jeurissen B, Sijbers J, Jones DK. Explore DTI: a graphical toolbox for processing, analyzing and visualizing diffusion data. *Proc Int Soc Magn Reson Med*. 2009;17:3537
  32. Leemans A, Jones DK. The B-matrix must be rotated when correcting for subject motion in DTI data. *Magn Reson Med*. 2009;61(6):1336–1349
  33. Tax CM, Otte WM, Viergever MA, Dijkhuizen RM, Leemans A. REKINDLE: Robust extraction of kurtosis indices with linear estimation. *Magn Reson Med*. 2015;73(2):794–808
  34. Oishi K, Mori S, Donohue PK, et al. Multi-contrast human neonatal brain atlas: application to normal neonate development analysis. *Neuroimage*. 2011;56(1):8–20
  35. Klein S, Staring M, Murphy K, Viergever MA, Pluim JP. elastix: a toolbox for intensity-based medical image registration. *IEEE Trans Med Imaging*. 2010;29(1):196–205
  36. Kersbergen KJ, Leemans A, Groenendaal F, et al. Microstructural brain development between 30 and 40 weeks corrected age in a longitudinal cohort of extremely preterm infants. *Neuroimage*. 2014;103(C):214–224
  37. Hou X, Ding H, Teng Y, et al. Research on the relationship between brain anoxia at different regional oxygen

- saturations and brain damage using near-infrared spectroscopy. *Physiol Meas*. 2007;28(10):1251–1265
38. Kurth CD, McCann JC, Wu J, Miles L, Loepke AW. Cerebral oxygen saturation-time threshold for hypoxic–ischemic injury in piglets. *Anesth Analg*. 2009;108(4):1268–1277
  39. Dent CL, Spaeth JP, Jones BV, et al. Brain magnetic resonance imaging abnormalities after the Norwood procedure using regional cerebral perfusion [published retraction appears in *J Thorac Cardiovasc Surg*. 2006;131(6):1226]. *J Thorac Cardiovasc Surg*. 2006;131(1):190–197
  40. Padilla N, Alexandrou G, Blennow M, Lagercrantz H, Ådén U. Brain growth gains and losses in extremely preterm infants at term. *Cereb Cortex*. 2015;25(7):1897–1905
  41. Limperopoulos C, Soul JS, Gauvreau K, et al. Late gestation cerebellar growth is rapid and impeded by premature birth. *Pediatrics*. 2005;115(3):688–695
  42. Argyropoulou MI, Xydis V, Drougia A, et al. MRI measurements of the pons and cerebellum in children born preterm; associations with the severity of periventricular leukomalacia and perinatal risk factors. *Neuroradiology*. 2003;45(10):730–734
  43. Limperopoulos C, Gauvreau KK, O’Leary H, et al. Cerebral hemodynamic changes during intensive care of preterm infants. *Pediatrics*. 2008;122(5). Available at: [www.pediatrics.org/cgi/content/full/122/5/e1006](http://www.pediatrics.org/cgi/content/full/122/5/e1006)
  44. Connolly DJA, Widjaja E, Griffiths PD. Involvement of the anterior lobe of the cerebellar vermis in perinatal profound hypoxia. *AJNR Am J Neuroradiol*. 2007;28(1):16–19
  45. Limperopoulos C, Soul JS, Haidar H, et al. Impaired trophic interactions between the cerebellum and the cerebrum among preterm infants. *Pediatrics*. 2005;116(4):844–850
  46. Smith GC, Gutovich J, Smyser C, et al. Neonatal intensive care unit stress is associated with brain development in preterm infants. *Ann Neurol*. 2011;70(4):541–549
  47. Ibla JC, Hayashi H, Bajic D, Soriano SG. Prolonged exposure to ketamine increases brain derived neurotrophic factor levels in developing rat brains. *Curr Drug Saf*. 2009;4(1):11–16
  48. Parikh NA, Lasky RE, Kennedy KA, et al. Postnatal dexamethasone therapy and cerebral tissue volumes in extremely low birth weight infants. *Pediatrics*. 2007;119(2):265–272
  49. Hyttel-Sorensen S, Pellicer A, Alderliesten T, et al. Cerebral near infrared spectroscopy oximetry in extremely preterm infants: phase II randomised clinical trial. *BMJ*. 2015;350:g7635

## Patent Ductus Arteriosus and Brain Volume

Petra M.A. Lemmers, Manon J.N.L. Benders, Rita D'Ascenzo, Jorine Zethof, Thomas Alderliesten, Karina J. Kersbergen, Ivana Isgum, Linda S. de Vries, Floris Groenendaal and Frank van Bel

*Pediatrics* 2016;137;; originally published online March 30, 2016;

DOI: 10.1542/peds.2015-3090

<b>Updated Information &amp; Services</b>	including high resolution figures, can be found at: <a href="/content/137/4/e20153090.full.html">/content/137/4/e20153090.full.html</a>
<b>References</b>	This article cites 47 articles, 14 of which can be accessed free at: <a href="/content/137/4/e20153090.full.html#ref-list-1">/content/137/4/e20153090.full.html#ref-list-1</a>
<b>Subspecialty Collections</b>	This article, along with others on similar topics, appears in the following collection(s): <b>Fetus/Newborn Infant</b> <a href="/cgi/collection/fetus:newborn_infant_sub">/cgi/collection/fetus:newborn_infant_sub</a> <b>Neonatology</b> <a href="/cgi/collection/neonatology_sub">/cgi/collection/neonatology_sub</a> <b>Neurology</b> <a href="/cgi/collection/neurology_sub">/cgi/collection/neurology_sub</a>
<b>Permissions &amp; Licensing</b>	Information about reproducing this article in parts (figures, tables) or in its entirety can be found online at: <a href="/site/misc/Permissions.xhtml">/site/misc/Permissions.xhtml</a>
<b>Reprints</b>	Information about ordering reprints can be found online: <a href="/site/misc/reprints.xhtml">/site/misc/reprints.xhtml</a>

PEDIATRICS is the official journal of the American Academy of Pediatrics. A monthly publication, it has been published continuously since 1948. PEDIATRICS is owned, published, and trademarked by the American Academy of Pediatrics, 141 Northwest Point Boulevard, Elk Grove Village, Illinois, 60007. Copyright © 2016 by the American Academy of Pediatrics. All rights reserved. Print ISSN: 0031-4005. Online ISSN: 1098-4275.

American Academy of Pediatrics

DEDICATED TO THE HEALTH OF ALL CHILDREN™



# PEDIATRICS®

OFFICIAL JOURNAL OF THE AMERICAN ACADEMY OF PEDIATRICS

## **Patent Ductus Arteriosus and Brain Volume**

Petra M.A. Lemmers, Manon J.N.L. Benders, Rita D'Ascenzo, Jorine Zethof, Thomas Alderliesten, Karina J. Kersbergen, Ivana Isgum, Linda S. de Vries, Floris Groenendaal and Frank van Bel

*Pediatrics* 2016;137;; originally published online March 30, 2016;  
DOI: 10.1542/peds.2015-3090

The online version of this article, along with updated information and services, is located on the World Wide Web at:  
</content/137/4/e20153090.full.html>

PEDIATRICS is the official journal of the American Academy of Pediatrics. A monthly publication, it has been published continuously since 1948. PEDIATRICS is owned, published, and trademarked by the American Academy of Pediatrics, 141 Northwest Point Boulevard, Elk Grove Village, Illinois, 60007. Copyright © 2016 by the American Academy of Pediatrics. All rights reserved. Print ISSN: 0031-4005. Online ISSN: 1098-4275.

American Academy of Pediatrics

DEDICATED TO THE HEALTH OF ALL CHILDREN™

