

GROWTH FACTOR-INDUCED OSTEOGENESIS IN A NOVEL RADIOLUCENT BONE CHAMBER

M.T. Poldervaart¹, J. van der Stok², M.F.P. de Haas², M.C. 't Hart¹, F.C. Öner¹, W.J.A. Dhert^{1,3}, H. Weinans^{1,4,5}
and J. Alblas^{1*}

¹Department of Orthopaedics, University Medical Center Utrecht, Utrecht, the Netherlands.

²Department of Orthopaedics, Erasmus University Medical Center Rotterdam, Rotterdam, the Netherlands.

³Faculty of Veterinary Medicine, Utrecht University, Utrecht, the Netherlands.

⁴Department of Biomechanical Engineering, Delft University of Technology, Delft, the Netherlands.

⁵Department of Rheumatology, University Medical Center Utrecht, Utrecht, the Netherlands.

Abstract

Treatment of large bone defects is currently performed using mainly autograft or allograft bone. There are important drawbacks to bone grafting, such as limited availability, donor site morbidity in the case of autograft and inferior performance of allografts. Therefore, there is a great need for a suitable bone graft substitute. In order to evaluate efficiently newly developed biomaterials and factors intended for orthopaedic surgery, the bone chamber is a very suitable model. To allow longitudinal investigation of bone growth with μ CT, a new bone chamber made of radiolucent polyether ether ketone (PEEK) was developed and studied for its feasibility. Therefore, PEEK bone chambers were placed on rat tibiae, and filled with vehicle (Matrigel without growth factors, negative controls), with bone morphogenetic protein 2 (BMP-2, positive controls), or a mix of growth factors combining BMP-2, vascular endothelial growth factor and the chemokine stromal cell-derived factor 1 α , all laden on gelatin microspheres for controlled release (combined growth factors). Growth factor presence led to a significant increase in bone formation after 8 weeks, which subsided after 12 weeks, underlining the importance of longitudinal analysis. We conclude that the PEEK-bone chamber is a suitable translational animal model to assess orthotopic bone formation in a longitudinal manner.

Keywords: Bone chamber, growth factors, bone morphogenetic protein-2, vascular endothelial growth factor, stromal cell derived factor 1 α , bone regeneration, animal model.

Introduction

The majority of large bone defects are currently treated with auto- or allograft bone, which both have important drawbacks such as limited availability of donor bone and donor site morbidity for autograft, whereas allograft bone may lead to inferior performance (Khan *et al.*, 2005; Silber *et al.*, 2003). To reduce the need for auto- or allograft bone, tissue-engineered bone-constructs have become an important pillar in the field of regenerative medicine. A broad spectrum of biomaterials is currently under investigation in different *in vitro* and *in vivo* models for their suitability to function as a scaffold for bone regeneration (Barradas *et al.*, 2011; Van der Stok *et al.*, 2011). One of the *in vivo* models to study a material's osteopromotive quality is the bone chamber. The main advantages of bone chambers are that they are relatively easy to implant (they are non-weight bearing) and the osteogenicity of biomaterials can be measured as the total amount of bone formed and the bone height reached in the chamber. In the past, many bone chambers were made of titanium (Belfrage *et al.*, 2012; Hannink *et al.*, 2006; Mathijssen *et al.*, 2012; Wang and Aspenberg, 1994), a very strong and bone-friendly material which, however, is unsuitable for accurate evaluation of bone formation with micro computed tomography (μ CT), as the titanium creates large image artefacts. We developed a new radiolucent bone chamber based on polyether ether ketone (PEEK). PEEK has been used in medical devices and has good mechanical characteristics and biocompatibility (Toth *et al.*, 2006).

Growth factors are increasingly applied in regenerative medicine to improve construct characteristics. For example, bone morphogenetic protein 2 (BMP-2) is known to induce osteogenesis (Garrison *et al.*, 2010) and can be used in a bone chamber model (Jeppsson *et al.*, 1999). Application of vascular endothelial growth factor (VEGF) leads to angio- and vasculogenesis (Ferrara *et al.*, 2003), whereas the chemokine stromal cell-derived factor 1 α (SDF-1 α) can attract multipotent stromal cells (MSCs) (Hattori *et al.*, 2001). Even though SDF-1 α is known to play an important role in stem cell homing, its functionality in terms of osteogenic differentiation in tissue engineered constructs *in vivo* is not clear (Eman *et al.*, 2014). Some authors have reported a synergistic effect of SDF-1 α addition to BMP-2 laden scaffolds (Liu *et al.*, 2013; Ratanavaraporn *et al.*, 2011). These growth factors, that have short half-life times, can be laden on

*Address for correspondence:

Jacqueline Alblas
Department of Orthopaedics
University Medical Center Utrecht
Heidelberglaan 100
3584 CX Utrecht
the Netherlands

Telephone Number: +31 (0)887550294

FAX Number: +31 (0)302530638

E-mail: j.alblas@umcutrecht.nl

gelatin microspheres (GMP) for controlled release to ensure a prolonged presence (Patel *et al.*, 2008b). Gelatin is a natural product that is used in many FDA-approved devices. Growth factor encapsulation in GMPs is based on electrostatic interactions with the gelatin, as well as the gelatin degradation rate (Ikada and Tabata, 1998; Patel *et al.*, 2008a; Patel *et al.*, 2008b; Yamamoto *et al.*, 2001). The main advantages of the GMPs are the diffusional loading of growth factors and the non-covalent nature of the interaction between gelatin and growth factor, thus avoiding chemical reactions that could damage the protein. Furthermore, GMPs are non-cytotoxic, biodegradable and they have previously been used to deliver growth factors such as BMP-2, transforming growth factor β 1 (TGF β 1) and fibroblast growth factor (FGF) (Leeuwenburgh *et al.*, 2010; Yamamoto *et al.*, 2003).

The aim of this study was to investigate the applicability and effectivity of the PEEK bone chamber as a model to monitor orthotopic bone formation in a longitudinal manner. To that end, bone chambers were bilaterally implanted in the tibiae of rats, and growth factor-induced bone formation was measured at multiple time points with *in vivo* μ CT scans.

Materials and Methods

Study design

The objective of this study was to investigate the applicability and effectivity of the PEEK bone chamber model to monitor orthotopic bone formation in a longitudinal manner. To that end, a controlled laboratory experiment was performed. Bone chambers were bilaterally implanted in the tibiae of rats, and growth factor-induced bone formation was measured at multiple time points using *in vivo* μ CT. All samples were randomly allocated, and implanted and analysed by researchers who were blinded for the experimental groups.

Study endpoints and statistical methods were prospectively selected and documented. Sample size was calculated with a power analysis to achieve reliable measurement of the effect, and this number did not change during the course of the study. The standard guidelines for humane endpoints in animal experiments were applied, though none of the animals met these criteria. All data were included in the analysis and no outliers were detected.

Table 1. Experimental groups.

Group contents	Control	BMP-2 group	Combined GF group
BMP-2	-	100 μ g/mL	100 μ g/mL in GMP ¹
VEGF	-	-	25 μ g/mL in GMP
SDF-1 α	-	-	25 μ g/mL in GMP

¹GMP, gelatin microparticles applied; concentration mentioned after release in the entire bone chamber volume.

Bone chamber preparations

The experimental design is depicted in Table 1. Bone chambers were placed bilaterally on the tibiae of 10 rats, then filled with 20 μ L Matrigel (growth factor-reduced, cat no. 354230, BD Biosciences, Franklin Lakes, NJ, USA; negative controls), 20 μ L Matrigel with 100 μ g/mL BMP-2 (InductOS, Wyeth, Cambridge, MA, USA; positive controls), or 20 μ L Matrigel with 100 μ g/mL BMP-2, 25 μ g/mL VEGF and 25 μ g/mL SDF-1 α (R&D Systems, Minneapolis, MN, USA; combined growth factors), each laden on GMP for sustained release. GMP were fabricated as described previously (Poldervaart *et al.*, 2014). Combined growth factor containing chambers ($n = 10$) were implanted in one tibia, and were matched with either a positive ($n = 5$) or negative control ($n = 5$) chamber in the other tibia of the animal to allow paired data analysis.

Production of the bone chambers

The design of the PEEK bone chamber was an adaptation to the titanium bone conduction chamber (BCC) developed by Aspenberg and colleagues (van der Donk *et al.*, 2001), that consists of two parts. The inner part is a cylindrical chamber of 7×2 mm \varnothing (≈ 22 mm³), covered by a cap (Fig. 1) to create a confined chamber. Both parts were produced from solid PEEK plates (Vink Kunststoffen, Didam, the Netherlands). The design files of the PEEK bone chambers can be obtained by contacting the corresponding author.

Surgical technique, animals and operations

Animal experiments were performed, with permission of the Animal Ethical Committee of the Erasmus University for Animal Experimentation, in compliance with the Institutional Guidelines following the Dutch Law ('Wet




Fig. 1. The PEEK bone chamber. **A.** Design of the bone chamber. **B.** PEEK bone chambers; cap, screw and assembled chamber. **C.** Placement of the bone chamber (cutaway model). Scale bars represent 3 mm.

op de dierproeven') on the use of laboratory animals. Ten male Wistar rats (Charles River, Leiden, the Netherlands), 16 weeks of age, were housed in standard cages at the Laboratory Animal Institute. Prior to surgery, a single dose of antibiotics (enrofloxacin, 5 mg/kg body weight) was administered. Operations were performed aseptically under general anaesthesia (1-3.5 % isoflurane).

Implantation of bone chambers

Rats were placed in a supine position, both medial knee regions were shaved and disinfected. An elastic band, placed in the groin region, functioned as a tourniquet in order to temporarily reduce blood flow to the operated leg. Subsequently a 1 cm longitudinal incision was made over the medial plane of the proximal tibia. Underlying fascia and muscles were gently pushed to the medial side until the bone was fully exposed. A guiding hole was drilled with a thin bone drill (0.7 mm Ø) approximately 2 mm below the proximal growth plate and 1 mm anterior to the insertion of the semitendinosus and gracilis tendons. The guiding hole was enlarged up to 2 mm Ø by using 1, 1.5 and 2 mm diameter drill bits. Then the bone chambers were screwed into the hole, until the side openings reached the height of the adjacent cortex. After placement, the chambers were filled according to a randomised scheme. The cap was placed over the bone chamber before the skin was sutured using Vicryl 4-0. Postoperatively, the animals were weighed and given a subcutaneous injection of buprenorphine (0.05 mg/kg, Temgesic, Schering-Plough/Merck, Whitehouse Station, NJ, USA) twice a day for the first three days after surgery. Fluorochrome labels were administered at 4 (tetracycline, 25 mg/kg bodyweight), 8 (calcein, 25 mg/kg body weight), and 11 weeks (xylenol orange, 90 mg/kg body weight) to monitor the onset of bone formation (van Gaalen *et al.*, 2010). The 8 week label was not incorporated in any of our samples or control tissue and therefore was excluded from the fluorochrome analysis.

Clinical evaluation of the procedure

All bone chambers performed well and remained at the correct location during the entire study. The animals rapidly recovered and mobilised, limping was observed in the first week after surgery only, and no complications occurred.

µCT evaluation

Immediately after surgery, a baseline *in vivo* µCT scan was acquired of all implanted bone chambers using a SkyScan 1176 scanner (Bruker µCT, Kontich, Belgium), and after 4, 8 and 12 weeks subsequent scans were performed. An 18 µm-resolution protocol was used (65 kV, 270 ms exposure time, 1.0 mm Al filter, 0.5° rotation step), resulting in a 9 min scan. After explantation of the subcutaneously implanted biphasic calcium phosphate scaffolds (BCP-1150 containing 82 % HA and 18 % TCP, Xpand, Bilhoven, the Netherlands), *ex vivo* µCT scans were acquired using a 9 µm-resolution protocol (65 kV, 1320 ms exposure time, 1.0 mm Al filter, 0.32° rotation step, 53 min scan). All µCT images were reconstructed using volumetric reconstruction software NRecon version 1.5 (Bruker µCT). To measure bone formation inside the bone chamber calcified tissue was distinguished from non-calcified tissue

and noise by segmentation. Therefore, grayscale images were reconstructed by an automated algorithm using local thresholds (3D Calculator v0.9 (Waarsing *et al.*, 2004)). Subsequently, in the resulting 3D dataset (consisting of stacked black and white cross-sections) bone was measured inside a cylindrical volume of interest capturing the inner volume of the bone chambers using CTAnalyser version 1.11 software (Bruker µCT). All analysis and segmentation were performed on blinded data sets.

Histology

The rats were killed after 12 weeks using an injection of Euthanasol (Virbac, Fort Worth, TX, USA). Bone chambers were retrieved, fixed in 4 % buffered formalin, dehydrated using an ethanol series, and embedded in polymethylmethacrylate (MMA). Samples were sawed centrally into approximately 25 µm thick sections using a sawing microtome (Leica, Nussloch, Germany) and stained with methylene blue and basic fuchsin for histomorphometric analysis. High-resolution digital pictures of the samples were taken using transmitted light microscopy (Olympus-BX50, Olympus, Zoeterwoude, the Netherlands).

Statistical analysis

Bone formation was analysed by SPSS version 20 software (IBM, Chicago, IL, USA). Combined growth factor filled chambers ($n = 10$) were implanted in one tibia, and were matched with either a positive ($n = 5$) or negative control ($n = 5$) chamber in the other tibia of the animal to allow paired data analysis. Differences between treatments were analysed with a paired *t*-Test. *Post-hoc* testing to correct for the number of tests was performed using a Bonferroni correction. All bars represent mean values, with standard deviations depicted in the error bars. Significance between treatments was assumed when $p < 0.05$.

Results

Assessment of tissue ingrowth and bone formation in the PEEK chambers

Bone formation in the chambers, as seen on µCT, was confirmed by methylene blue and basic fuchsin staining on the MMA-embedded sections (Fig. 2). In the controls, that did not contain growth factors, little bone was formed (Fig. 2A, C), whereas the chambers were filled with bone that reached to the top of the chamber in the growth factor-containing chambers (Fig. 2B, D). The 4-week fluorochrome label (green) was not present in the bone in the chambers, the 11-week label (red) was. This confirms late onset of bone formation, which is in accordance with the µCT measurements and previous findings in spinal cassettes (Geuze *et al.*, 2012). Both labels were present in the cortical bone and epiphysis of the tibia, indicating normal active bone deposition during the entire study period.

The baseline µCT directly after surgery confirmed that no bone fragments were present in the chambers after implantation and that they were correctly placed, bicortically, on the tibiae. In the µCT scan after 4 weeks

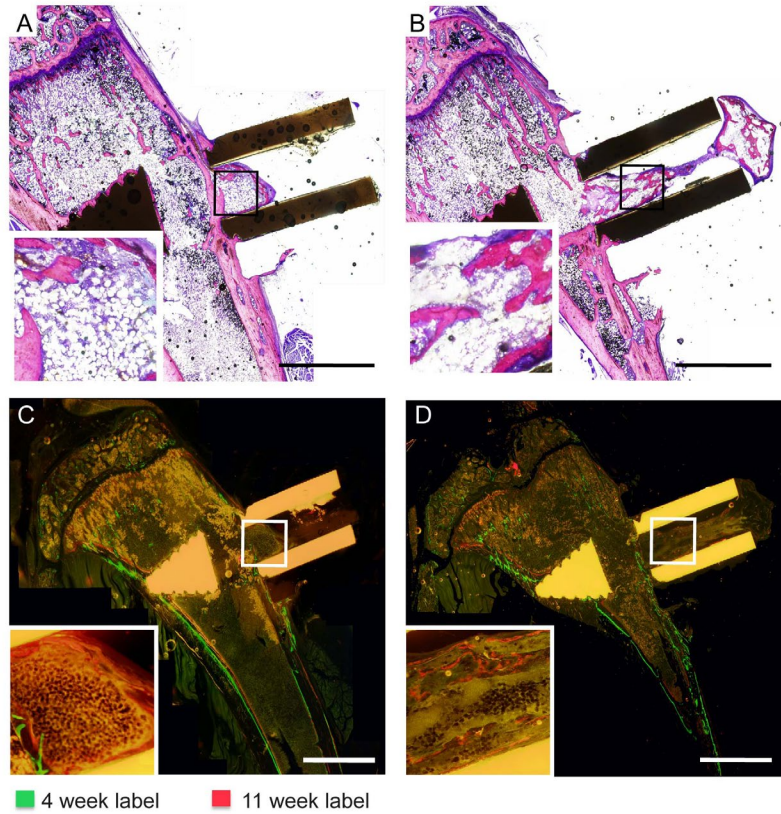


Fig. 2. Bone formation in the PEEK chambers. **A, B.** Methylene blue and basic fuchsin staining of a control (**A**) and a combined growth factor (**B**) bone chamber. **C, D.** Fluorochrome label incorporation from consecutive unstained sections (compared to **A, B**) in the bone chambers. In (**C**) there is no incorporation, in (**D**) only the red label is present. Insets depict details from the boxed regions. Representative pictures with respect to bone volume are shown, scale bars represent 3 mm.

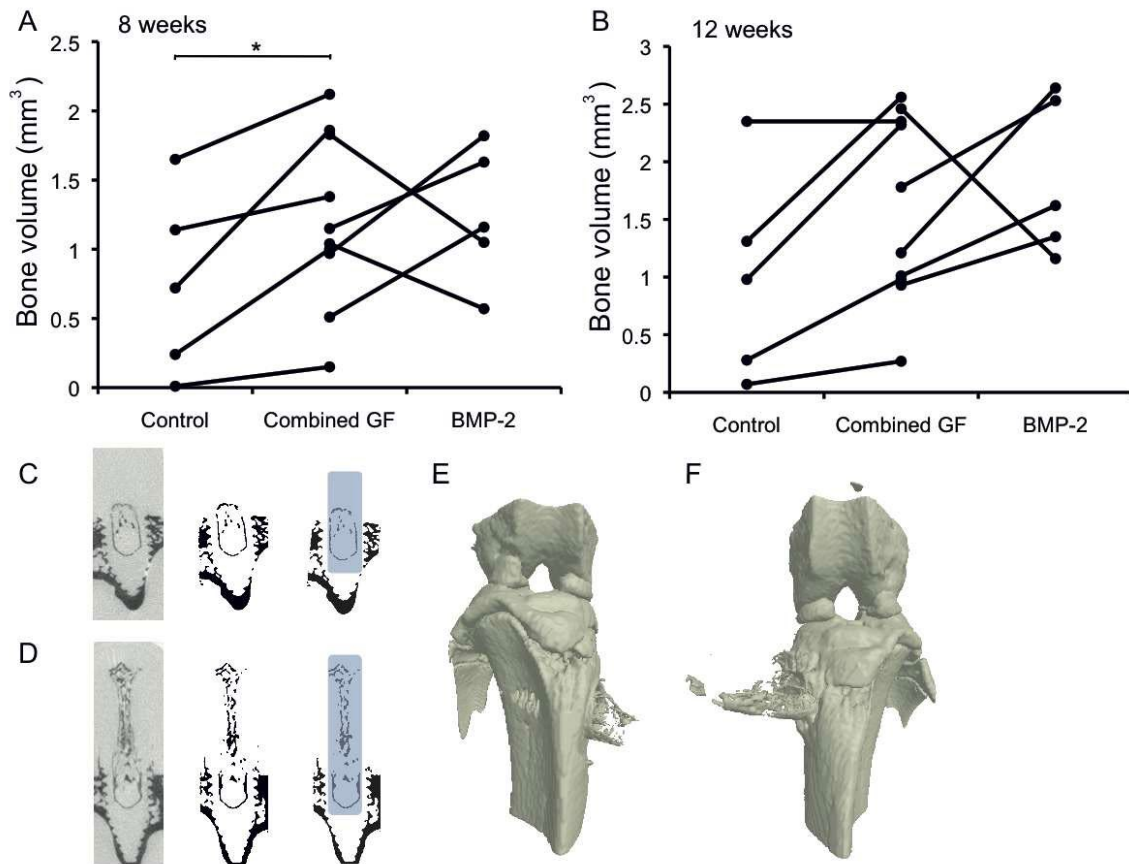


Fig. 3. μ CT analysis of bone formation in the chambers. **A, B.** Bone volume was measured in the bone chambers after 8 (**A**) and 12 weeks (**B**) of implantation by μ CT. * indicates $p < 0.05$. **C, D.** Original μ CT scan (grey) and segmentations (binary) of bone chambers, with the region of interest for segmentation depicted (blue) for the controls (**C**) and combined growth factor-laden bone chambers (**D**). **E, F.** 3D reconstructions of a control (**E**) and combined growth factor sample (**F**) μ CT scan, from the same animal. Representative pictures with respect to bone volume are shown.

of implantation, no bone formation was present, but bone ingrowth was clearly visible by μ CT from 8 weeks onwards (Fig. 3). Quantification of the bone volumes revealed that the chambers that contained the combination of growth factors showed significantly higher bone formation at 8 weeks than the empty chambers ($p = 0.04$). At 12 weeks this difference was no longer statistically significant ($p = 0.06$). Both the BMP-2 and combined growth factor-laden chambers contained bone volumes indistinguishable from each other at 8 and 12 weeks.

Discussion

This study showed that the PEEK bone chamber is a suitable model to assess (growth factor-induced) orthotopic bone formation. All chambers were easily implanted bicortically (without surgical failures), remained in the correct position, and the animal recovered within days after the surgery. The importance of longitudinal analysis of bone formation was underlined by the outcomes of this experiment, namely the significant difference in bone formation between the control and growth factor-laden chambers present at 8 weeks after implantation, which was no longer statistically significant at 12 weeks. We hypothesise that after 8 weeks, remodelling of the newly formed bone started playing a larger role than *de novo* bone formation, lowering the increase in bone volume and leading to larger inter-individual variations. Also, due to the small volume of the chamber, a plateau-phase was often already reached before 12 weeks of implantation. Longitudinal assessment of bone formation enabled detection of the significant differences in bone volume between the treatments, which would have been missed if only an end-point measurement had been performed.

Inclusion of the gold-standard treatment for bone augmentation, which is the application of autologous bone, was not chosen here, as this would complicate the analysis of new bone ingrowth. Bone induction by BMP-2 in rats is well studied with respect to dosage and kinetics, and so this was taken as a positive control. When we compared the BMP-2-laden chambers to the combined growth factor chambers, no differences were seen. The BMP-2 that was added to the chambers appeared to induce optimal bone formation in this time-frame and setting. Because the necessary cells were most likely able to migrate into the chambers through the openings at the cortical level, there may have been a limited need for VEGF and SDF-1 α addition. This would mean that, in order to assess growth factor synergy, the volume of the chambers should be enlarged to a size where vascularisation is critical for bone formation. Furthermore, the concentration of BMP-2 was based on findings in the literature (Jang *et al.*, 2012), and was supraphysiological. Together with the confined space offered by the chamber, this may have led to maximal bone induction, hereby masking possible synergistic or additive effects of the other growth factors, that are well established for VEGF (Kanczler *et al.*, 2010; Kempen *et al.*, 2009) and also reported for SDF-1 α (Ratanavaraporn *et al.*, 2011).

GMPs were applied because of their beneficial effects seen in our previous studies (Kempen *et al.*, 2008). In this experimental set-up the release of the growth factors was also expected to be gradual, because Matrigel is known to retain growth factors (Gao *et al.*, 2009). The use of GMPs is reported for BMP-2 and VEGF delivery (Patel *et al.*, 2008b), and there is evidence that controlled release of SDF-1 α leads to improved angiogenesis (Kimura and Tabata, 2010). Together, this argues against an insufficient availability of the individual growth factors in the combined growth factor-laden chambers.

The limitations of this study need to be optimised further, before the PEEK bone chamber can be applied in large animal models and translational research to screen the bone forming capacity of novel materials. First, the size of the bone chambers could be increased to introduce the need for early scaffold vascularisation in this model. Then, application of bone chambers at multiple implantation sites could be optimised. In the current setting, bone chambers are not weight bearing, resulting in less variation due to implant movement, but also complicating translation to weight bearing orthotopic implantation sites. When these limitations are addressed and the model is further optimised, implant components such as matrices and biologicals can be screened in small and large animal models, which is an important step to translate *in vitro* findings to clinical applications.

Conclusion

The PEEK bone chamber proved to be a suitable model to investigate orthotopic bone formation in a longitudinal manner. Our results showed that in all growth factor-laden chambers bone formation increased significantly compared to control.

Acknowledgements

This research forms part of the Project P2.04 BONE-IP of the research program of the BioMedical Materials institute, co-funded by the Dutch Ministry of Economic Affairs. Anna Foundation|NOREF provided financial support for this research project. We wish to confirm that there are no known conflicts of interest associated with this publication and there has been no significant financial support for this work that could have influenced its outcome.

References

- Barradas AM, Yuan H, van Blitterswijk CA, Habibovic P (2011) Osteoinductive biomaterials: current knowledge of properties, experimental models and biological mechanisms. *Eur Cell Mater* **21**: 407-429.
- Belfrage O, Isaksson H, Tagil M (2012) Local treatment of a bone graft by soaking in zoledronic acid inhibits bone resorption and bone formation. A bone chamber study in rats. *BMC Musculoskelet Disord* **13**: 240.

- Eman RM, Oner FC, Kruyt MMP, Dhert W, Alblas J (2014) Stromal cell-derived factor-1 stimulates cell recruitment, vascularization and osteogenic differentiation. *Tissue Eng Part A* **20**: 466-473.
- Ferrara N, Gerber HP, LeCouter J (2003) The biology of VEGF and its receptors. *Nat Med* **9**: 669-676.
- Gao Y, Zhu S, Luo E, Li J, Feng G, Hu J (2009) Basic fibroblast growth factor suspended in Matrigel improves titanium implant fixation in ovariectomized rats. *J Control Release* **139**: 15-21.
- Garrison KR, Shemilt I, Donell S, Ryder JJ, Mugford M, Harvey I, Song F, Alt V (2010) Bone morphogenetic protein (BMP) for fracture healing in adults. *Cochrane Database Syst Rev* **6**: CD006950.
- Geuze RE, Theyse LF, Kempen DH, Hazewinkel HA, Kraak HY, Oner FC, Dhert WJ, Alblas J (2012) A differential effect of bone morphogenetic protein-2 and vascular endothelial growth factor release timing on osteogenesis at ectopic and orthotopic sites in a large-animal model. *Tissue Eng Part A* **18**: 2052-2062.
- Hannink G, Aspenberg P, Schreurs BW, Buma P (2006) Development of a large titanium bone chamber to study *in vivo* bone ingrowth. *Biomaterials* **27**: 1810-1816.
- Hattori K, Heissig B, Tashiro K, Honjo T, Tateno M, Shieh JH, Hackett NR, Quitoriano MS, Crystal RG, Rafii S, Moore MA (2001) Plasma elevation of stromal cell-derived factor-1 induces mobilization of mature and immature hematopoietic progenitor and stem cells. *Blood* **97**: 3354-3360.
- Ikada Y, Tabata Y (1998) Protein release from gelatin matrices. *Adv Drug Deliv Rev* **31**: 287-301.
- Jang JW, Yun JH, Lee KI, Jung UW, Kim CS, Choi SH, Cho KS (2012) Osteoinductive activity of biphasic calcium phosphate with different rhBMP-2 doses in rats. *Oral Surg Oral Med Oral Pathol Oral Radiol* **113**: 480-487.
- Jeppsson C, Bostrom M, Aspenberg P (1999) Intraosseous BMP implants in rabbits. Inhibitory effect on bone formation. *Acta Orthop Scand* **70**: 77-83.
- Kanczler JM, Ginty PJ, White L, Clarke NM, Howdle SM, Shakesheff KM, Oreffo RO (2010) The effect of the delivery of vascular endothelial growth factor and bone morphogenetic protein-2 to osteoprogenitor cell populations on bone formation. *Biomaterials* **31**: 1242-1250.
- Kempen DH, Lu L, Hefferan TE, Creemers LB, Maran A, Classic KL, Dhert WJ, Yaszemski MJ (2008) Retention of *in vitro* and *in vivo* BMP-2 bioactivities in sustained delivery vehicles for bone tissue engineering. *Biomaterials* **29**: 3245-3252.
- Kempen DH, Lu L, Heijink A, Hefferan TE, Creemers LB, Maran A, Yaszemski MJ, Dhert WJ (2009) Effect of local sequential VEGF and BMP-2 delivery on ectopic and orthotopic bone regeneration. *Biomaterials* **30**: 2816-2825.
- Khan SN, Cammisa FP Jr, Sandhu HS, Diwan AD, Girardi FP, Lane JM (2005) The biology of bone grafting. *J Am Acad Orthop Surg* **13**: 77-86.
- Kimura Y, Tabata Y (2010) Controlled release of stromal-cell-derived factor-1 from gelatin hydrogels enhances angiogenesis. *J Biomater Sci Polym Ed* **21**: 37-51.
- Leeuwenburgh SC, Jo J, Wang H, Yamamoto M, Jansen JA, Tabata Y (2010) Mineralization, biodegradation, and drug release behavior of gelatin/apatite composite microspheres for bone regeneration. *Biomacromolecules* **11**: 2653-2659.
- Liu X, Zhou C, Li Y, Ji Y, Xu G, Wang X, Yan J (2013) SDF-1 promotes endochondral bone repair during fracture healing at the traumatic brain injury condition. *PLoS One* **8**: e54077.
- Mathijssen NM, Hannink G, Pilot P, Schreurs BW, Bloem RM, Buma P (2012) Impregnation of bone chips with alendronate and cefazolin, combined with demineralized bone matrix: a bone chamber study in goats. *BMC Musculoskelet Disord* **13**: 44.
- Patel ZS, Ueda H, Yamamoto M, Tabata Y, Mikos AG (2008a) *In vitro* and *in vivo* release of vascular endothelial growth factor from gelatin microparticles and biodegradable composite scaffolds. *Pharm Res* **25**: 2370-2378.
- Patel ZS, Young S, Tabata Y, Jansen JA, Wong ME, Mikos AG (2008b) Dual delivery of an angiogenic and an osteogenic growth factor for bone regeneration in a critical size defect model. *Bone* **43**: 931-940.
- Poldervaart MP, Gremmels H, van Deventer K, Fledderus JO, Öner FC, Verhaar MC, Dhert WJA, Alblas J (2014) Prolonged presence of VEGF promotes vascularization in 3D bioprinted scaffolds with defined architecture. *J Control Release* **184**: 58-66.
- Ratanavaraporn J, Furuya H, Kohara H, Tabata Y (2011) Synergistic effects of the dual release of stromal cell-derived factor-1 and bone morphogenetic protein-2 from hydrogels on bone regeneration. *Biomaterials* **32**: 2797-2811.
- Silber JS, Anderson DG, Daffner SD, Brislin BT, Leland JM, Hilibrand AS, Vaccaro AR, Albert TJ (2003) Donor site morbidity after anterior iliac crest bone harvest for single-level anterior cervical discectomy and fusion. *Spine* **28**: 134-139.
- Toth JM, Wang M, Estes BT, Scifert JL, Seim HB, 3rd, Turner AS (2006) Polyetheretherketone as a biomaterial for spinal applications. *Biomaterials* **27**: 324-334.
- van der Donk S, Buma P, Aspenberg P, Schreurs BW (2001) Similarity of bone ingrowth in rats and goats: a bone chamber study. *Comp Med* **51**: 336-340.
- Van der Stok J, Van Lieshout EM, El-Massoudi Y, Van Kralingen GH, Patka P (2011) Bone substitutes in the Netherlands – a systematic literature review. *Acta Biomater* **7**: 739-750.
- van Gaalen SM, Kruyt MC, Geuze RE, de Bruijn JD, Alblas J, Dhert WJ (2010) Use of fluorochrome labels in *in vivo* bone tissue engineering research. *Tissue Eng Part B Rev* **16**: 209-217.
- Waarsing JH, Day JS, van der Linden JC, Ederveen AG, Spanjers C, De Clerck N, Sasov A, Verhaar JA, Weinans H (2004) Detecting and tracking local changes in the tibiae of individual rats: a novel method to analyse longitudinal *in vivo* micro-CT data. *Bone* **34**: 163-169.
- Wang JS, Aspenberg P (1994) Basic fibroblast growth factor increases allograft incorporation. Bone chamber study in rats. *Acta Orthop Scand* **65**: 27-31.
- Yamamoto M, Ikada Y, Tabata Y (2001) Controlled release of growth factors based on biodegradation of gelatin hydrogel. *J Biomater Sci Polym Ed* **12**: 77-88.

Yamamoto M, Takahashi Y, Tabata Y (2003) Controlled release by biodegradable hydrogels enhances the ectopic bone formation of bone morphogenetic protein. *Biomaterials* **24**: 4375-4383.

Discussion with Reviewers

Reviewer I: It would appear that the 12-week time point was too long for the selected model. Why did the authors select this time point?

Authors: Since it was our first test with the model and we are measuring longitudinally, we chose a relatively long follow-up time of 12 weeks. For future experimental

designs we would implement this knowledge by choosing a follow-up time of 8 weeks.

Reviewer I: Do you think a bone chamber similar to the one described could be used to replace a drill-hole or segmental-defect model given that it is non-load bearing?

Authors: Indeed, this model could replace a segmental-defect or drill-hole model. The models have similarities; they are non-weight bearing at an orthotopic location, with good contact to periosteum and its vasculature. The bone chamber adds the advantages of relatively easy placement and more controllable conditions (for example, growth factor concentrations) in the confined space of the chamber.