Surgical innovations in canine gonadectomy

Bart Van Goethem

Cover: illustration by Harry Campbell©

Printing: University Press, Zelzate, België

B. Van Goethem: **Surgical innovations in canine gonadectomy**, PhD thesis, Faculty of Veterinary Medicine, Utrecht University, Utrecht, the Netherlands

ISBN: 978-90-9029-457-5

Correspondence and requests for pdf: bart.vangoethem@ugent.be

Surgical innovations in canine gonadectomy

Chirurgische innovaties bij gonadectomie van de teef

(met een samenvatting in het Nederlands)

Proefschrift

ter verkrijging van de graad van doctor aan de Universiteit Utrecht

op gezag van de rector magnificus, prof. dr. G.J. van der Zwaan,

ingevolge het besluit van het college voor promoties

in het openbaar te verdedigen op

dinsdag 5 januari 2016

des middags te 12.45 uur

door

Bart Van Goethem

geboren op 19 maart 1971 te Dendermonde, België

Promotoren: Prof. dr. J.W. Hesselink

Prof. dr. J. Kirpensteijn

Copromotor: Dr. S.A. van Nimwegen

Voor Viper, Voodoo, Sika, Pixie en al die andere honden die mijn leven verrijken.

Contents

1

Aim and scope of the thesis

For those of us who remember the rotary dial phone, cassette tapes, and the Commodore 64 home computer there is no doubt that the changes in electronics, communication, computing, and other technologies have been staggering. This rate of change does not experience any decline, but instead seems to be rising exponentially.[1] Pithy sayings like 'Stagnation means decline' and 'The only thing that is permanent, is change' reflect our acceptance of these continuous changes. Advances in technology have been critical to, and inseparable from, advances in medicine and surgery. Progressive knowledge of disease processes, improved diagnostic techniques and the development of new pharmaceuticals continuously change the current medical treatment modalities. Technology in medicine continues to improve, generally slowly but sometimes by leaps and bounds.[2] Surgeons are particularly accustomed to changes, since their instrumentation regularly benefits from progressive technological developments, and thus they repeatedly have to adapt their established surgical techniques. This is illustrated in the quote: 'If you don't like the way surgery is practiced today, just wait a while – it will change'.[3] For indeed, continuous innovations mark the progress in the craft of surgery. And any surgeon who doubts the progression in his field is advised to 'Visit the Mecca that produced you: you'll be surprised that what is considered Holy Grail has become anachronistic'.[3]

The aim of this thesis was to review some recent technological developments in human surgery and evaluate their potential as a surgical innovation for canine gonadectomy. It is therefore first necessary to define a surgical innovation. This is not as straightforward as one might think.[4] There is no uniform view about the definition of an innovation in medicine.[5] And even more, the very criteria for defining surgical progress can change. Human patients, for example, nowadays value more than simple reductions in morbidity and mortality.[6] To distinguish a true surgical innovation from being a variation in technique, five criteria can be used: newness or novelty, degree of change, level of risk, impact, and requirement of formal processes. According to these criteria several of the studies in this thesis undoubtedly meet the definition of a surgical innovation.

In **Chapter 2** a literature review is provided covering relevant knowledge on gonadectomy as a method of contraception, the traditional surgical techniques for gonadectomy, the history of minimally invasive surgery in medicine and veterinary medicine, the creation of a pneumoperitoneum, the different hemostatic techniques available in

minimally invasive surgery, hemostatic techniques available in traditional gonadectomy, and the principles of ovarian remnant syndrome in dogs.

In **Chapter 3** the use of a bidirectional barbed suture for the closure of a midline celiotomy incision is described. Barbed sutures achieve wound apposition without surgical knot tying and thus avoid knot-associated negative consequences (lengthy placement, impaired wound healing around bulky knots, and the effect of unsightly knots on cosmetics). The research study was set up to evaluate if barbed sutures would be an appropriate alternative to knotted suture closure of midline celiotomy incisions in dogs. The study is also the first in dogs to describe the use of ultrasonography of the abdominal wall to document wound healing-related complications.

In **Chapter 4** the literature on the surgical technique of gonadectomy available in 2003 is reviewed. After a detailed description of the two surgical procedures, ovariectomy and ovariohysterectomy, the review focusses on short-term and long-term complications associated with each of the techniques. Based on this literature study a recommendation is made to use the technique with the least morbidity as the procedure of choice for elective surgeries.

In **Chapter 5** the use of neuromuscular blocking agents during canine laparoscopic ovariectomy is evaluated. A double-blinded prospective clinical trial was performed to compare the effect of abdominal wall musculature relaxation during laparoscopic surgery. Since abdominal wall muscle relaxation might lead to a larger intra-abdominal working space it would potentially have a positive effect on surgical efficiency. Surgical variables (duration of surgery, intraoperative complications) but also anesthetic variables (respiratory and circulatory parameters) were recorded for predetermined procedural stages to detect positive or negative consequences related to neuromuscular blockade.

In **Chapter 6** the efficacy of a newly developed energy-based hemostatic surgical device for hemostasis (bipolar electrocoagulation grasping forceps - Take-Apart) is compared to hemostasis achieved with laparoscopic scissors connected to a monopolar electrocoagulation generator during canine laparoscopic ovariectomy. A nonrandomized, prospective clinical trial was performed, focusing on duration of surgery and intraoperative

complications, to decide if the newly developed instrument could improve the existing laparoscopic ovariectomy technique.

In **Chapter 7** the efficacy of a newly developed energy-based hemostatic surgical device for hemostasis (vessel sealing device - LigaSure) is compared to the bipolar electrocoagulation grasping forceps (Take-Apart) during canine laparoscopic ovariectomy. Surgical times are determined, intraoperative complications are recorded and collateral thermal tissue damage was histologically compared to evaluate if the newly developed instrument offers an improvement of the existing laparoscopic ovariectomy technique.

In **Chapter 8** the efficacy of a newly developed energy-based hemostatic surgical device (an all-in-one bipolar electrocoagulation forceps with built-in cutting function - HotBlade) is compared to the vessel sealant device (LigaSure) during canine laparoscopic ovariectomy. Since the combined coagulating-cutting bipolar forceps is a more economical alternative compared to the vessel sealing device, surgical times, intraoperative complications and the amount of collateral thermal tissue damage was compared to evaluate if the newly developed instrument offers an improvement of the existing laparoscopic ovariectomy technique.

In **Chapter 9** the use of a conventional surgery vessel sealing device (LigaSure) is evaluated during canine ovariectomy by traditional midline celiotomy. This most efficient hemostatic technique, accepted as the standard of care during laparoscopic surgery, was compared to the standard of care for conventional gonadectomy (suture ligation of the ovarian pedicle). Surgical times and the occurrence of intraoperative complications were noted. Also, since the intention of the study was to offer an affordable technique to general practitioners, a technique to sterilize and reuse the disposable instrument was described.

In **Chapter 10** a laparoscopic approach for removal of ovarian remnant tissue in 32 dogs is described. Because laparoscopic ovariectomy is able to remove normal ovarian tissue very efficiently and with less associated morbidity compared to conventional ovariectomy, a study was set up to evaluate if a minimally invasive approach would permit the detection and the location of the ovarian remnant tissue and allow for removal of all abnormal tissue from the abdominal cavity. Removed tissue was examined histologically, and dogs had long-term follow-up with hormonal testing when indicated.

In **Chapter 11** and **Chapter 12** the conclusions from the different studies are compared to the current literature, leading to a summarizing discussion and final conclusion of this thesis (in the English and Dutch languages, respectively).

Lord Moynihan (1865-1936), first Chairman of the British Journal of Surgery could not have been more wrong, when he stated that 'The craft of surgery has in truth nearly reached its limits in respect of both range and safety'.[3] Surgical progress has always depended on surgeons finding innovative solutions to their patients' problems. The combination of an insatiable curiosity (a typical trait for a cutting-edge surgeon), the continuous critical evaluation of current concepts (in fact in medicine nothing is truly set in stone), and the progressive technological advances guarantees us an ever evolving interesting medical future.

References

1. Strong VE, Forde KA, MacFadyen BV, Mellinger JD, Crookes PF, Sillin LF, Shadduck PP: Ethical considerations regarding the implementation of new technologies and techniques in surgery. Surg Endosc 2014;28:2272-2276.
2. Wilson TG: Advancement of technology and its impact on urologists: release of the Da Vinci Xi, a new surgical robot. Eur Urol 2014;66:793-794.
3. Campbell B: Surgical aphorisms. Brit J Surg 2013;100:1673-1674.
4. Hughes-Hallett A, Mayer EK, Marcus HJ, Cundy TP, Pratt PJ, Parston G, Vale JA, Darzi AW: Quantifying innovation in surgery. Ann Surg 2014;260:205-211.
5. Rogers WA, Lotz M, Hutchison K, Pourmoslemi A, Eyers A: Identifying surgical innovations: a qualitative study of surgeons' views. Ann Surg 2014;259:273-278.
6. Angelos P: Ethics and surgical innovations: challenges to the professionalism of surgeons. Int J Surg 2013;11 Suppl 1:S2-5.

2

General introduction

Part of the general introduction has been published:

Laparoscopie in de gezelschapsdierenpraktijk. Deel 1: instrumentarium en basisprincipes.

Van Goethem B, Bosch M, Stegen L

Vlaams Diergeneeskd Tijdschr 2009;78:365-371.

and

Diagnosestelling van ovarieel restsyndroom bij hond en kat

Van Soom A, Van Goethem B, Rijsselaere T

Vlaams Diergeneeskd Tijdschr 2008;77(6):435-441.

Gonadectomy as a method of contraception

Gonadectomy is often requested by owners when there is no desire to have offspring and to prevent perfectly normal, but to the owner potentially annoying, hormonally induced changes such as vaginal blood loss, attractiveness to neighboring dogs, increased aggression, roaming, pseudopregnancy, nesting, lactating and mothering behavior.[1] Veterinarians on the other hand encourage and actively promote contraception for societal reasons. The best-known societal reason is overpopulation. In many developed countries over half of all households own a dog or a cat.[2] One survey of dog-owning households found 56% of 154 canine litters to be unplanned.[3] Another study found that reproduction occurred in such numbers that the newborn animals no longer represented cash value, but actually cost money in the form of advertisement to be homed.[4]

The historical recommendation to prevent unwanted matings for bitches was indoor confinement and segregation from intact males. Although effective and least expensive this technique underestimates the animal's hormonal behavior and overestimates the pet owner's compliance.[5] Pet owners are often not committed to the continual responsibilities of pet care and either abandon their animal or its offspring. The most important risk factor for a pet to be abandoned by its owner was being sexually intact.[2] Unwanted and abandoned dogs roam the surroundings and may damage economically valuable domestic species, increase human dog bite incidents or act as reservoirs or vectors of transmissible diseases to man (rabies, rickettsia, echinococcosis, leptospirosis, toxoplasmosis, neosporum, sarcoptes, ctenocephalides, etc).[4,6,7] In developed countries unwanted dogs and cats are therefore caught and gathered in shelters before attempting rehoming. The Humane Society of the United States of America estimates the annual number of dogs and cats entering the shelters at 8 to 10 million.[5] Rehousing of such gigantic numbers of animals is virtually impossible and half of these animals are euthanized each year.[1] Euthanizing millions of animals each year raises serious ethical implications.

Non-surgical methods of contraception and sterilization have made great advances the last decades.[8] Exogenous steroid (progestins and androgens) aim on the reduction in luteinizing hormone (LH) and follicle-stimulating hormone (FSH) by inducing a negative

feedback (inhibition of secretion of LH and FSH) in response to increased levels of sexual steroids in the blood.[8] Increased levels of progestins are associated with an increased risk for the development of hyperplastic or neoplastic changes in the mammary gland, cystic endometrial hyperplasia, pyometra, acromegaly, diabetes mellitus, adrenal gland dysfunction, hair loss, lethargy or restlessness.[9] And elevated androgen levels are associated with clitoral hypertrophy, vaginitis, urinary incontinence, cervical dermis thickening, epiphora, ovarian fibroma, endometrial atrophy, vaginal mucosa atrophy and hepatic toxicity.[8] Their use has therefore been abandoned the last decade in favor of safer products. Gonadotropin releasing hormone (GnRH) agonists indirectly block conception via negative feedback mechanisms preventing the production of LH and FSH necessary for ovulation.[5] This method is safe, reliable and reversible. The subcutaneous implant suppresses ovulation for up to 27 months.[10] Which is a great improvement compared to older products (progestins) that needed to be injected every 6 months. Still, multiple injections remain necessary to cover the total reproductive period of a dog. And therefore the long-term efficacy of these techniques will ultimately rely on the pet owner's compliance to regularly repeat the contraception treatment.[8] Intrauterine devices for canine contraception have also been commercialized.[11] The contraceptive activity results from both mechanical disruptive effects as well as spermicidal effects of metallic ions released by electrolytic copper. This device has an effective life of 2 years. But, it is not practical for use in dogs due to the difficulty of transcervical cannulation.[5] Still, these non-surgical techniques have merit and form the mainstay of population control in countries where elective surgery is considered unethical or even illegal.[8,12] In Sao Paulo (Brazil), for instance, a survey of owners that adopted a shelter dog found that 56.5% was against surgical sterilization as a method of limiting pet reproduction, citing compassion (58.1%), unnecessary procedure (11.4%), cost (9.5%), and expecting behavioral change (4.8%) as reasons.[13] Since the financial aspect often is an important consideration it is important to keep non-surgical contraceptive or sterilization options widely available and affordable.[1]

The most commonly performed method of contraception worldwide is surgical sterilization.[8] It has the distinct advantage that it is a single procedure with permanent effect and therefore does not rely on pet owner's compliance afterwards.[14] To prevent overpopulation spay-neuter contracts are sent out with animals adopted from shelters. But even with low-cost surgical options readily available compliance with these contracts is lower

than 60%.[13,15] Because of this, many humane organizations in the United States of America are working towards gonadectomy for all shelter animals prior to adoption.[1] Prepubertal gonadectomy, often referred to as early-age neutering (between 6 - 16 weeks old) is often used at animal care and control facilities.[16] The anesthetic and surgical procedures are apparently safe for young puppies and kittens, morbidity is lower, and recovery is faster than in adult animals.[17-19] This information however should find its way to the dog owner. For only 52% of pet owners buying a new dog in the United States of America had their dog gonadectomized within one year of purchase.[1] So, owner education remains a key factor.

A second societal reason for gonadectomy is its use for breed improvement. Selective gonadectomy is performed to prevent the spread of unwanted genetic traits like: allergies, arthritis (hip dysplasia, elbow dysplasia, patella luxation, cranial cruciate ligament rupture), brachycephalic airway obstructive syndrome, hereditary epilepsy, heart disease (patent ductus arteriosus, aortic stenosis, cardiomyopathies), cryptorchidism, umbilical hernia, drug sensitivity (multi-drug resistance gen 1), ocular disorders (progressive retinal atrophy, cataract, lens luxation). It is the combined responsibility of veterinarians in close collaboration with breeders to identify such animals.[20] And when hereditary conditions are well established within certain dog breeds, selective gonadectomy to exclude the involved animals from the gene pool is essential.[21] This way selective individual gonadectomy will be beneficial for the entire pure-bred dog community. And it will also benefit future owners, saving money and preventing emotional distress, because their dog does not become sick from hereditary diseases.

Foremost important for individualized medicine, is that the gonadectomized animal itself obtains several clear benefits from the elective procedure. And this is certainly the case for gonadectomy in female dogs. Neutered animals, in general, have been found to live longer than intact animals.[22] Although it is unclear whether this is because of the preventive effect on reproductive disease or just reflects enhanced care by the owner. Pyometra is an infection of the uterus overlying cystic endometrial hyperplasia. With incidence rates of 15 - 25% in intact female dogs and associated mortality rates of 0 - 17%, this is a common reason for death in intact bitches.[17] But pyometra is excluded by gonadectomy, either through prevention of the development of cystic endometrial hyperplasia with ovariectomy or through removal of the uterus with ovariohysterectomy.[23] Malignant mammary tumors in dogs have an incidence

of 3.4%, and only 25 - 40% of surgically treated dogs are alive two years after diagnosis.[24] The incidence is hugely lowered when gonadectomy is performed at a young age.[25] Uterine, vaginal and vulvar tumors have a low incidence (0.27%) and are hormone dependent in 85 - 90% of described tumors (leiomyoma).[26] No leiomyomas have been described in gonadectomized animals and no recurrence is described after tumor removal and concurrent gonadectomy. Additional reproductive tract disease that is excluded after gonadectomy includes: ovarian diseases (cysts, tumors), extra-uterine pregnancy, and parturition-related disorders including metritis, mastitis and dystocia, and hormone-associated disorders such as vaginal edema. Gonadectomy is therefore one of the most commonly performed surgical procedures in veterinary practice.[27]

Surgical technique for celiotomy closure

Celiotomy wound dehiscence (incisional abdominal herniation) can lead to abdominal herniation and even evisceration, making secure and lasting closure of the abdominal wall essential. In human surgery the occurrence of incisional abdominal herniation is between 9 - 20%.[28] And high risk groups such as the morbidly obese have associated risk rates of 26 - 39%.[29] Quadrupeds are theoretically more at risk for midline celiotomy dehiscence and evisceration because of the gravitational pull on the incision. Yet, strangely enough abdominal wound dehiscence occurs with lower frequencies in veterinary medicine. In horses, incisional hernias after midline celiotomy is still a considerable problem with a reported frequency of 8 - 16%.[30-32] But in dogs incisional abdominal hernias are only infrequently described in case series.[33,34] In a study at a Veterinary Teaching Hospital it was found that closure of the abdominal wall took 53% of the surgical time of an ovariohysterectomy.[35] So, whether low evisceration rates reflect an insensitivity to incisional abdominal hernia or it is just the result of the increased attention spend on closing the abdominal wall in dogs, is unclear. But certainly any technological advancement that could speed up the surgical duration for abdominal wall incision closure, or that could decrease even further the number of complications would be welcome.

Fundamentally, little has changed with regard to the method of approximating tissues that have been separated as a result of trauma or a surgical procedure.[36] Modern surgeons close wounds with needles and thread much as the ancient Egyptians did.[37] Traditional sutures, placed to close surgical incisions, need knots to achieve their purpose. Surgical sutures will therefore rely on the surgeon's ability to tie secure knots, something that can be challenging and time consuming in large wounds. Improper tying and handling will result in knot breakage or slippage, leading to potential wound dehiscence.[38] The knot may impede wound healing, constrict blood flow, distort tissue, and increase scar formation.[39] When subjected to stress testing, a tied simple continuous suture will break at the knot 95% of the time.[40] Because the configuration of the knot is biomechanically the weakest part of the suture, the suture diameter is not tailored exactly to the strength of the tissues it approximates, but needs to be increased one size to prevent breakage at the knot.[41] Larger suture diameters, however, increase the risk for knot slippage, leading to an increased risk of dehiscence. A bulky knot structure can also cause a foreign body reaction leading to sinus formation or suture extrusion.[42] And thus knots are associated with the inherent risk of extrusion, palpability, micro infarcts, breakage, and slippage.[36] Moreover, the knot also creates a micro-environment where bacteria can evade phagocytosis by macrophages.[43]

Barbed sutures (Fig 2.1), a recent technological advancement of suture material, permit the apposition of two tissue layers without the need for knots. Barbed sutures therefore consist of many little barbs cut into the monofilament suture structure. Bidirectional barbed sutures have barbs arrayed in a helical fashion in opposing directions on either side of an unbarbed midsegment, and an atraumatic needle attached to each suture end (double armed suture).[44] The barbs anchor themselves in tissue making this a continuous suture effectively consisting of multiple interrupted sutures that optimally spread out traction forces along the wound edge without the sliding motion of the classical continuous suture. Unidirectional barbed suture constructs differ in that it has a loop on one end, barbs in the same direction and a needle on the other end. This suture locks itself in tissue by passing the suture through the loop, tightening this and then anchoring the barbs while continuously apposing tissue.[45] Unidirectional sutures still have a constricting loop on one side predisposing to ischemic necrosis and therefore not optimally benefit from the theoretical advantages of the barbed sutures. For this thesis a prospective study was performed that looked at the

performance of a bidirectional barbed suture for the closure of midline celiotomy incisions (abdominal wall, subcutaneous tissues and skin) (**Chapter 3**).



Figure 2.1 Bidirectional barbed sutures (Quill, Angiotech Pharmaceuticals Inc. - A) and unidirectional barbed sutures (V-Loc 180, Covidien - B) (adapted from Spah, Vet Surg, 2013).

Surgical technique for gonadectomy

Traditional gonadectomy can be performed by two different approaches: midline celiotomy or flank laparotomy. A claimed advantage for the lateral flank laparotomy is that the ovary can be retrieved with minimal manipulation of intra-abdominal organs thereby reducing surgical time and decreasing morbidity.[46] A study on 114 shelter dogs with a mean weight of 13.7 kg found mean surgical times of 11.07 minutes (range, 4.67 minutes to 37.42 minutes).[47] While midline ovariohysterectomy in the hands of experienced surgeons is associated with median surgical times of 17 min for dogs with a comparable weight (median 12.1 kg).[48] Other advantages are that in case of postoperative wound dehiscence the risk for evisceration is decreased, and that the incision site can be monitored postoperatively from a distance.[49] The risk for evisceration after a midline procedure in dogs is generally considered

very low.[34] But, when managing feral or stray animal populations, the improved ease of monitoring a laparotomy incision site is definitely an advantage.[49]

Disadvantages of the technique are that the limited exposure to the contralateral site (or cervical area) can be detrimental when complications arise.[46] Incision length in the previously mentioned study was only 22 mm (range, 10 to 53 mm) and therefore made any exploration of the abdominal cavity, to detect concurrent abnormalities or to exclude operative bleeding, impossible.[47] To improve visualization on the contralateral site, and reduce disruption of intra-abdominal organs, some authors have even advised to use bilateral flank incisions.[50] While closure of a midline celiotomy basically consists of two fascial layers (external and internal sheath), the flank laparotomy involves three muscle bellies with their respective fascial layers (transverse abdominal muscle, internal oblique abdominal and external oblique abdominal). The correct anatomical apposition of three separate muscle bellies with respect to their different fiber orientation increases surgical times. And the amount of incisional site trauma differs because of the difference between separating or cutting muscle bellies instead of opening a single fascial layer (linea alba). This resulted in an average recovery time of 3.7 days (range, 2 to 20 days) and the need for additional analgesics on day two in 13.9% of dogs in the study on 114 bitches in a shelter program.[47] Despite that experienced surgeons performed all operations, a relative high number of postoperative complications (7.8%), mainly consisting of partial wound dehiscence and surgical site infection, was observed.[47] The study on bilateral flank ovariectomy reported 22% of the dogs developing a seroma at the surgical site.[50] Disadvantages of lesser importance are the need for a wide surgical clip (less esthetic on the flank compared to the ventral abdomen) and the possibility for imperfections in hair color or regrowth patterns on the flank.[46] For all these reasons, traditional elective gonadectomy is generally performed through a midline celiotomy approach, while lateral flank laparotomy is offered as an alternative in selected cases.[14,51]

Surgical gonadectomy can be performed by ovariectomy or ovariohysterectomy.[52-54] Historically ovariohysterectomy was performed out of concerns of possible future uterine pathologies. When it became evident from comparative research that these concerns were ungrounded, some countries adopted their routine spaying procedure from ovario-hysterectomy to ovariectomy (situation in some European countries).[55-57] Others held on to the traditional method, guided by strong personal opinions and anxiety regarding law suits

(situation in the United States of America). A review of the current literature was performed to compare both gonadectomy techniques and evidence based arguments were sought for one over the other (**Chapter 4**).

The history of minimally invasive surgery

When performing elective surgical procedures it is not only of utmost importance to minimize intraoperative complications, but also to limit postoperative morbidity as much as possible. The development of minimally invasive surgery, also known as video-endoscopic surgery, is a major step forward in that regard.

Out of sheer curiosity, but certainly also to advance their knowledge of diseases, physicians have always been attempting to investigate the inside of human body cavities and orifices. The ability to examine less visible areas of the body has progressively increased since the 1970s, and technological advances during the past few years have allowed the evolution of diagnostic and therapeutic minimally invasive surgery to become meteoric. But even long before this time pioneers were already inventing instruments to overcome the obstacles that are inherent to any endoscopic procedure: expanding or creating entrances to the interior of the body, safely delivering enough light into the interior space, transmitting a clear and magnified image back to the eye, and expanding the field of vision. It is entertaining as well as inspirational to marvel at the tenacity and ingenuity the early pioneers displaced trying to outsmart these dilemmas. Seeing how some of the early medical pioneers where scorned by the established medical society and their ideas discouraged simply because they went against the current establishment, holds a lesson when we face new innovations in veterinary medicine. As philosopher George Santayana (1863-1952) stated: “Those who cannot remember the past are condemned to repeat it.”

Era of natural light (from Hippocrates to 1805)

The first obstacle to a successful endoscopic procedure is to expand an already existing entrance to a body orifice or to create a new entrance to the body's internal cavity. The use of tubes and crude specula in medicine dates from the earliest days of civilization as enemas for clysters were known to the ancient Egyptians, Greeks, and Romans.[58] With the technology available to overcome this first obstacle, different endoscopic procedures were described by the Greek physician Hippocrates of Kos (460 bce-370 bce) in his work 'The Art of Medicine'.[59] Hippocrates describes in great detail the use of a speculum, similar to the instruments used today, to examine the rectum of a patient with hemorrhoids.[58] This can be considered as the first diagnostic proctoscopy. Other types of specula were used for examining the inside of the mouth, the ear and the vagina and cervix.[59] Later the Babylonian Talmud (500) describes the use of a lead pipe with tilted mouthpiece to examine the origin of vaginal bleeding.[60,61] This can be considered the first diagnostic vaginoscopy. A shortcoming of all these devices was the inadequacy of illumination. The use of ambient light only allowed investigation of superficial areas, such as the mouth, nose, ears, rectum, and vagina.[58] However, bringing patients in full daylight under the sun was not always practical, nor was sunlight always available. Logically the next progressive steps were taken to control and improve the availability of light.

The second obstacle to overcome was the safe introduction of sufficient light into the body cavity. Arabian physician Albu-al-Qasim (936-1013) is therefore considered one of the most important pre-modern founders of endoscopy.[60,62] He described many endoscopic procedures in his comprehensive thirty-volume medical encyclopedia 'The Method'. Al-Qasim experimented with reflected light and developed trocar- and cannula-like instruments that, although not primarily intended for endoscopic procedures (but actually for lithotomies), could easily be used for it in later times. His contemporary Persian physician Ibn Sina (980-1037) documented the use of polished glass mirrors to focus light for the inspection of an internal organ (the cervix).[58,60,62]

The modern era of history started in 1500 and marked the beginning of the European scientific revolution (1500-1700).[63] German printer Johannes Gutenberg perfected earlier rudimentary forms of mass print production in his Guttenberg press, thus launching a new era in communications, and greatly enhanced the sharing of scientific knowledge.[64] European

physicians benefitting from the continued exchange of scientific knowledge with the, at that time, more sophisticated Chinese Ming Dynasty and the Middle Eastern Ottoman Empire. And when by the late 16th century the long-standing unease in Europe to inspect the interior of the human body, living or otherwise, had finally abated to the point where it could actually be conducted in full view of academic observers, Europe took a leading role in further developments.[62] Italian physician Giulio Cesare Aranzio (1529-1589) used the known principles of camera obscura and mirrored sunlight on a flask of water for rhinoscopy.[62] His contribution to endoscopy-like instruments was the ability to guide a more brilliant beam of sunlight and to produce a slightly enlarged image.

The 17th century was characterized by important optical improvements required to finally overcome the obstacle of introducing sufficient light. Quasi-lens systems (made of non-glass substance) were developed and led to the invention of the first compound microscope by Dutch lens maker Zacharias Janssen in 1596. Italian scientist Galileo Galilei (1564-1642) used better lenses to improve the existing telescope design in 1609,[65] and British scientist Isaac Newton (1643-1727) published on the theory of advanced optics in 1704.[66] Urologists introduced the term 'trocar' for a three-faced instrument consisting of a perforator enclosed in a metal cannula in 1706.[62,67] This instrument was used to help guide endoscopic probes into the kidney, bladder or gallbladder for the removal of stones or to help drain the bladder. These procedures were often associated with complications as the trocar would become blocked.[62] Despite urologists' efforts to use endoscopic techniques, technologies for laparoscopy were slower to develop relative to other endoscopic specialties. The second obstacle was finally breached by British physician Archibald Cleland (1700-1771) who developed a nasal illumination device that consisted of biconvex lenses placed in front of a wax candle in order to magnify and redirect light.[68]

Era of reflected candlelight (1805-1879)

The third obstacle to achieve modern endoscopy was the ability to transmit a clear and magnified image. The Italian-German physician Philip Bozzini (1773-1809) achieved this when he developed his 'light conductor' in 1806 (Fig 2.2).[60,69] He is considered the 'father of endoscopy' not because he made a novel innovation, but because he genially combined the

currently available technology to overcome the existing illumination limitations.[62] His endoscope could work independent from sunlight since it had a build-in light source: the light from a wax candle was mirrored through a tin instrument.[60] It proved clinically useful for the examination of the ear, urethra, rectum, female bladder, cervix, mouth, nasal cavity or wounds. But Bozzini was far ahead of his time and also recognized the endoscope's operative potential: "Uncertain operations, which depended on mere luck and chance, will now be relieved of uncertainty by the influence of sight".[62] His contemporaries did not share his views and focused on the instrument's technical flaws: visualization only consisted of a tiny, blurred speck because of the small diameter of the endoscope and special training to use the instrument and it's many attachments was required.[62] Thus, despite his accomplishment Bozzini was reprimanded for 'undue curiosity' by the Vienna Medical Society and his invention was discounted as a 'toy' and never put to practice by others.[60]

After an almost twenty-year absence the interest in endoscopy was revitalized in Europe by the French urologist Pierre Salomon Segalas (1792-1875), and in America by the American physician John D. Fisher (1798-1850).[60] Independent of each other they continued on Bozzini's work and made improvements to the lens system (a system of double lenses), the illumination source (gasoline gave a brighter light), and the ease of use (polished metal instead of tin). In particular they used their devices to visualize the urethra and the bladder, as well as the rectum and the vagina, providing some measure of diagnostic information and even used the opportunity for therapy (lithotripsy and cautery).[61] Although at this stage full visualization was not actually achieved endoscopic-assisted surgeries became nevertheless instrumental in treating urological pathologies.[62] The use of gas lamps and candles with reflectors also allowed for some ingress in the upper and lower gastrointestinal tract.[61]

A huge contribution to surgical progress was made by James Young Simpson (1811-1870) when he introduced chloroform narcosis in 1847.[70] This greatly boosted the successful performance of many surgical procedures.

The first effective open-tube endoscope was developed in 1853 (Fig 2.3) by the French surgeon Antoine Jean Desormeaux (1815-1882). He designed a burner that used kerosene (a mixture of alcohol and turpentine) with a chimney to enhance the flame, and create a more continuous form of illumination, and a lens to condense the beam to a more limited area to

Figure 2.2 Philip Bozzini's 'light conductor' (adapted from European Association of Urology – History Museum).

Figure 2.3 The first open-tube endoscope by Antoine Desormeaux (adapted from European Association of Urology – History Museum).

achieve a brighter spot.[58,60,69] Desormeaux also introduced the term 'endoscopy' (a procedure in which an instrument is used to examine the interior of a hollow viscus). Later Irish surgeon Francis Richard Cruise (1834-1912) improved the design of the instrument further and used petroleum as a light source. This more accurately displayed colors and allowed him to visualize the pleural cavity in a girl with empyema in 1866 (first diagnostic thoracoscopy).[71] Cruise also performed the first endoscopy-assisted cystotomy and urethrostomy.[60,72] A major problem reported with the use of these early endoscopes, however, was that the light source was insufficiently strong: bladder, vagina and cervix could be inspected but although the stomach could be reached light was insufficient to be of practical use.[60]

German physician Adolf Kussmaul (1822-1902) performed the first esophagoscopy in 1868. He used a rigid gastroscope consisting of a 13 mm wide, 47 cm long metal tube connected to the endoscope of Desormeaux for illumination.[61] Out of concern with patient safety he enlisted the help of a sword swallower to develop a safe introduction technique to explore the upper gastrointestinal tract (esophagus and stomach).[61] Despite problems including poor lighting, fluid collection, and positional reflux his new design was considered to be a great accomplishment.[60] However, difficulties with patient tolerance of the rigid instrument and suboptimal visualization dimmed Kussmaul's initial enthusiasm.[61]

Era of incandescent light (1879-1957)

One of the best known discoveries of American inventor Thomas Edison (1847-1931) was the development of the first commercially practical incandescent light in 1879.[73] This application was gratefully picked up in endoscopy since it provided a better and more reliable light source. Instead of working with a light source outside of the body an electrical light source was now moved to the front of the endoscope. But since incandescent light converts only 3% of the electrical energy to visible light and 97% to heat, the endoscope's tip became extremely hot.[60] Consequently many endoscopic procedures were unfortunately complicated by burn injuries.

The German urologist Maximilian Carl-Friedrich Nitze (1848-1906) together with Viennese instrument maker Joseph Leiter (1830-1892) developed the 'modern cystoscope' in

1879.[69] Their original instrument incorporated a platinum wire loop sheathed in a goose quill (from 1883 this was replaced with Edison's incandescent light bulb) and had different telescopic lenses to magnify the image, all encased in a 7 mm metal catheter (Fig 2.4). Cystoscopy was able to precede other forms of endoscopy since the necessity to cool the instrument's tip continuously with ice water was no disadvantage, but actually helped the evaluation of the bladder lumen.[60] And thus the Nitze endoscope became the first instrument to reliably remove all the previously mentioned obstacles for a successful endoscopic procedure.

Figure 2.4 The Nitze-Leiter irrigating ureterocystoscope (adapted from European Association of Urology – History Museum).

A dual channel scope that featured separate ocular and sheath components was introduced by the French physician Boisseau de Rocher in 1899.[60] Since this allowed the introduction of instruments and thus manipulation of tissues, esophagoscopy, laryngoscopy, and proctoscopy became routine investigations by the end of the 19th century.[60]

Several years later, in 1901, Russian physician Dimitrij Oscarovic Ott (1855-1929) performed the first Natural Orifice Transluminal Endoscopic Surgery (NOTES) procedure.[69,74]

He performed abdominal examinations via a transvaginal access and called this procedure ventroscopy'. By only one incision in the cul-de-sac and utilizing a head lamp system similar to reflector lamps used by otolaryngologists, he inspected the caudal abdominal cavity making use of a gynecological speculum.[58,74]

Era of diagnostic laparoscopy (1901-1938)

The first diagnostic laparoscopic procedure is credited to the German surgeon and gastro-enterologist George Kelling (1866-1945), who demonstrated this procedure on a dog at a meeting of the Society of German Natural Scientists and Physicians in 1901.[60,69,75] In an attempt to find a treatment for gastrointestinal abdominal bleeding Kelling created pneumoperitoneum in dogs.[61] He used an insufflation device, at that time used for oesophagoscopy, connected it to a Fiedler trocar and manually insufflated oxygen, filtered through sterile cotton (Fig 2.5).[76]



Figure 2.5 Kelling used an insufflation device for oesophagoscopy to achieve and control abdominal air insufflation thereby performing the first laparoscopy procedure (adapted from Schollmeyer, Arch Gynecol Obstet, 2007).

Kelling introduced a modified Nitze cystoscope into the abdominal cavity to examine the effects of the pneumoperitoneum on bleeding. He realized that the visual field created in the abdomen by the insufflated air allowed inspection of the abdominal organs ("Organs had shrunk and had become colorless").[75] Although his primary intent was different, he was the first to describe a successful diagnostic laparoscopic procedure and introduced the term 'coelioscopy' for it.[77] Kelling performed experiments on 20 dogs using insufflation pressures up to 100 mm Hg.[78] At that time the pathophysiology of pneumoperitoneum was not fully understood and the death of two of his dogs was thought to be unrelated. Kelling claimed the procedure to be perfectly harmless: "After an examination, a dog is as cheerful as it was before".[78] Kelling advocated a pressure of 50 - 80 mm Hg to achieve intra-abdominal vascular compression in humans.[79] By 1910 he had performed 45 successful diagnostic laparoscopies in humans, and described the method for safely establishing the pneumoperitoneum and introducing trocars.[58,60] Kelling was ahead of his time: he recognized that endoscopic procedures could replace diagnostic laparotomy in selected cases (1901) and saw the economic benefit of endoscopic operations (1923).[75] Despite his initial successes, Kelling, aware of the limitations of technology at that time did not advance his technique further.[61,77,78]

Swedish internist Hans Christen Jacobaeus (1879-1937), unaware of earlier reports, also used the Nitze cystoscope, but placed the trocar and endoscope before establishing a pneumoperitoneum.[58,60,80] He published his initial findings in 1910 after having performed 19 laparoscopies and 2 thoracoscopies.[81] That he encountered very few complications with his less advanced trocar entry technique in a larger case series, is attributed to patient selection: most of his laparoscopy patients had ascites and all thoracoscopy patients had pleural effusion or pneumothorax.[78,82] Jacobaeus described conditions such as liver cirrhosis, metastatic cancer, tuberculosis, and realized the immense diagnostic and therapeutic possibilities of this technique.[3] Jacobaeus also recognized technical difficulties and limits, including the need for training on animals and on corpses, and the potential for serious trocar-induced injuries.[83] In 1922 he published an article describing thoracoscopy to provide useful information for a subsequent thoracotomy in 5 tumor patients. At a time when medical imaging was in its infancy (first medical use of X-rays in 1896) he promoted this as a reliable preoperative staging procedure.[84] A total of more than 550 thoracoscopic procedures were accorded to him.[85]

Also in 1911 Bernard Moses Bernheim (1880-1958), unaware of Kelling's and Jacobaeus' experiences, performed the first published laparoscopic procedure in the United States of America.[86] He used an electric head lamp and a 12 mm proctoscope inserted into the abdominal cavity to view the stomach, gallbladder, and liver and named the procedure 'organoscopy'.[60,69,86] Bernheim believed this procedure had potential, but was encouraged by his hospital superiors to abandon the idea.[60]

The following years minor technical improvements were made: Trendelenburg position was described in 1912, a pneumoperitoneum needle was developed in 1918, a pyramidal trocar point was developed in 1920.[69] Swiss gynecologist Richard Zollikofer was the first in 1924 to recommended using carbon dioxide instead of filtered air or oxygen to obtain a pneumoperitoneum.[60] Since carbon dioxide is quickly resorbed from the abdominal cavity it alleviates postoperative discomfort from a stretched abdomen. The next indirect contribution to minimally invasive surgery was made in 1928 when the British biologist Alexander Fleming (1881-1955) discovered penicillin.[87]

German physician Heinz Kalk (1929-1973) pioneered the use of laparoscopy for investigating disorders of the liver and biliary tract. He used a 45 - 50° oblique endoscope with a 135° field of view and advocated rotating the endoscope during laparoscopy.[69] This allowed better inspection of the organs and popularized diagnostic laparoscopy. Kalk was an inventor that designed laparoscopic instruments and advocated the dual cannula system to simultaneously pass instruments into the cavities.[58,60] Between 1929 and 1959 he performed more than 2,000 laparoscopies, published over 21 papers on laparoscopy and managed to standardize diagnostic laparoscopy in internal medicine.[58,88]

American internist John Carroll Ruddock (1891-1961) also modified an existing cystoscope towards a forward-oblique optical instrument intended for viewing of the peritoneal cavity.[69] He named this instrument a 'peritoneoscope'.[61,89] Ruddock redesigned the trocar to accept biopsy instruments and introduced local anesthesia to facilitate the procedure. He described his initial experiences with 500 patients in 1937, covering a wide range of conditions, including inflammatory, degenerative, neoplastic and other lesions of pelvic viscera.[90] By the time Ruddock retired he had performed more than 5,000 laparoscopies with much success and low morbidity (8 perforations of hollow viscera by the

pneumoperitoneum needle and one death due to bleeding from a hepatic biopsy).[91] Nevertheless, the relatively clumsy nature of the instruments, and the limited visibility of some areas of the peritoneal cavity, hindered the widespread acceptance of this technique.[61]

Era of operative laparoscopy (1938- 987)

In 1938 Hungarian surgeon Janos Veress (1903-1979) developed a needle to safely induce pneumothorax for the treatment of tuberculosis.[92] His sharp-tipped instrument had a spring-loaded blunt inner stylet that protected against lung injury after the needle had passed through the pleura (Fig 2.6). Since it could also be used to insufflate air in the abdomen it was gratefully picked up by minimally invasive surgeons to create the pneumoperitoneum. A survey on entry techniques in 2002 evaluating 173,203 general surgical and gynecologic procedures found that the Veress needle was used in 78% of all procedures (81% gynecologic and 48% general surgical procedures).[93]

One of the instrument designs Ruddock developed in 1934 was a forceps with built-in monopolar electrocoagulation.[58,94] Oxygen was now completely replaced by carbon dioxide

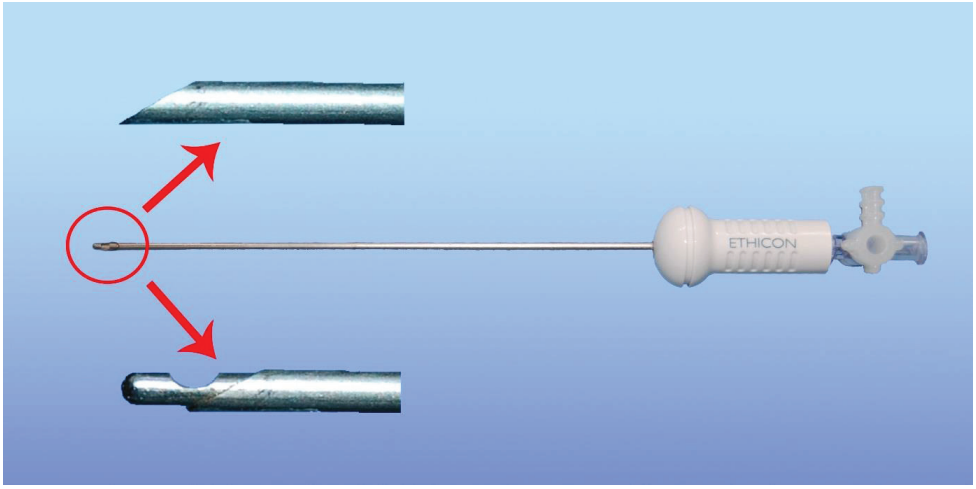

Figure 2.6 A present-day disposable type of Veress needle, as originally designed by Janos Veress, illustrating the sharp tip and spring-loaded blunt inner stylet.

as the pneumoperitoneum gas of choice because of the "Audible explosion and flashes of light produced by the combination of oxygen and a high frequency electrical current."[58] The use of monopolar electrocoagulation led to extensive morbidity and even death (intra-abdominal bleeding), and was abandoned in favor of bipolar electrocoagulation and mechanical means of achieving tubal ligation in later years.[58]

French gynecologist Raoul Palmer (1904-1985) performed laparoscopic sampling of ovocytes, puncture of cysts, adhesiolysis (1933), propagated monitoring the intra-abdominal pressure for anesthetic safety (1935), tubal sterilization (1936), uterine suspension (1942) and invented preoperative exploratory celioscopy (1943).[61,69] But although individual pioneers continued to explore the laparoscopic possibilities, it soon fell into oblivion in general surgery.[58]

French scientist Max Fourestier (1907-1986) discovered a method of transmitting an intense light beam from a source outside of the body's cavity along a quartz light rod to the distal end of the endoscope in 1952.[69,95-97] This 'cold light' illumination removed the dangers of intraperitoneal burns and electrical faults that occurred as a result of the intra-abdominal light source and was a major step forward.[60] But the quartz rod suffered from unfortunate limitations: it was high priced, fragile and the light needed to be positioned close to the external eyepiece.[61]

Another tremendous optical improvement was made in 1953 by British physicist Harold Hopkins (1918-1994) when he developed a fundamentally different lens system.[58,69,98-100] While conventional lens systems consisted of a series of glass lenses arranged one behind the other with large air gaps between them, the rod-lens system reverses this configuration (Fig 2.7). The rod-lenses occupy most of the telescope tube, while the relatively narrow air gaps act as air lenses. Since glass is a better light conductor than air, and fewer glass/air interfaces occur with this system, light ray scatter is reduced.[101] In combination with the larger aperture this gives a brighter image (an eight-fold improvement in light level), more realistic color reflection, a greater detail, and a larger field of view (70°).[99] Since light conduction was more efficient, the diameter of the endoscope could be made smaller. Because his first prototype was still inferior to the conventional lens systems of that time Hopkins struggled to get his invention commercialized.[101] German maker of precision medical instruments Karl

Storz recognized the potential of the rod-lens system and took the commercial risk to buy the patent and bring the endoscope in production.[101] Storz fabricated a superior light source for fiber illumination, used the light cables developed earlier by the American Cystoscope Makers Inc. (that had built the first cold light glass fiber endoscope in 1960) and combined this to the rod-lens system for a cold-light cystoscope in 1963.[96] Enhanced optics in combination with very bright cold light provided excellent visibility.[100,101] Innovative surgeons quickly recognized the potential of these inventions and revolutionized the concept of video-endoscopic surgery.

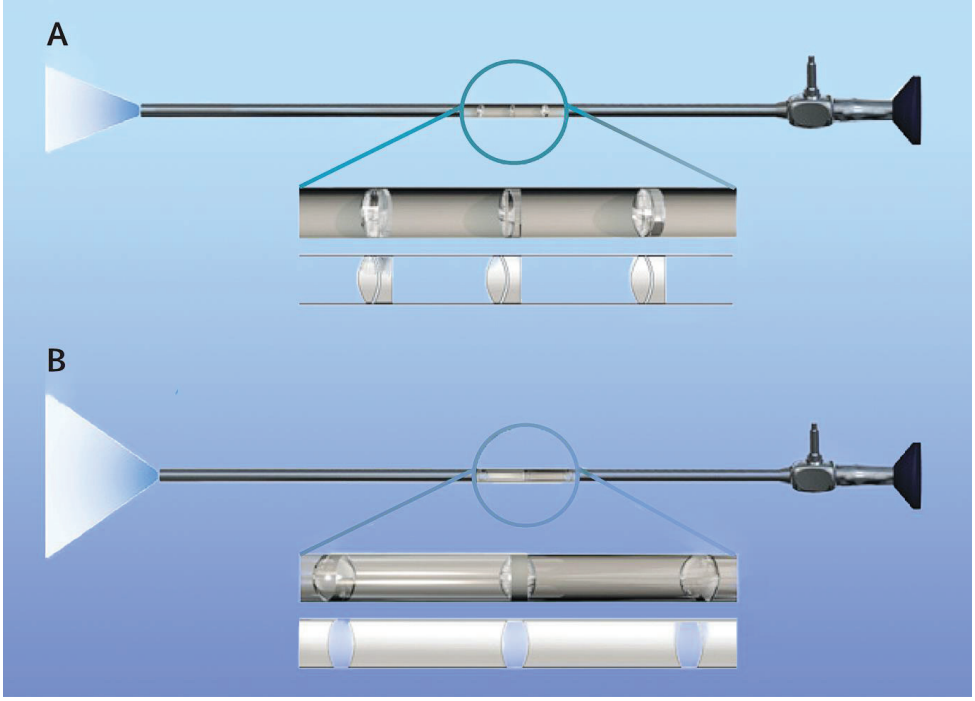

Figure 2.7 Conventional lens system (hollow endoscope with glass lenses) and the improved rod-lens system (glass endoscope with air lenses) developed by Harold Hopkins (adapted from Melzer, Lancet, 2012).

Throughout the 1960s and 1970s laparoscopy became a vital part of gynecologic practice.[60] It was gradually even becoming the procedure of preference for many gynecologic procedures: myomectomy, ovariectomy, ovarian cysts resection, adnexectomy, and

treatment of tubal pregnancy.[102,103] One of the leading pioneers in this period was German engineer and gynecologist Kurt Karl Stephan Semm (1927-2003).[104] Amongst his contributions was the introduction of an electronic carbon dioxide insufflator in 1960 that was further modified to automatically monitor intra-abdominal pressure and gas flow in 1966, thereby making laparoscopic procedures a lot safer.[105] Semm also designed an irrigation/aspiration device, a morcellator (to allow piecemeal removal of large neoplastic tissue), developed laparoscopic bipolar electrocoagulation, adapted the Roeder loop, and invented extra- and intracorporeal endoscopic knot tying techniques to achieve endoscopic hemostasis.[102,106,107] But Semm's technique was often criticized and insulted in public places: during a presentation on laparoscopic ovarian cyst treatment his slide projector was unplugged saying "That such unethical surgery should not be presented".[102,104]

The availability of intra-abdominal electrocoagulation was a major impetus to the development of operative laparoscopy, because more complicated surgery had not been possible without the ability to achieve hemostasis.[58] But laparoscopy, in contrast to its current prominence, did not find many advocates in general surgery.[108] Many surgeons considered it unethical (too dangerous) to make a surgical instrument out of a diagnostic tool.[102] Some accredited this mockingly to surgeons clinging to the dogma "The larger the cut, the better the surgeon".[60] But in truth the obstacle that prevented the more complicated general surgical procedures to be performed laparoscopically was that visualization was still limited to the person handling the endoscope, thereby prohibiting the efficient teamwork essential for more complicated procedures.

It has been found that almost 50% of the complications occurring during minimally invasive surgery are entry related.[109] Gastrointestinal internists (diagnostic laparoscopy) and gynecologists (diagnostic and therapeutic laparoscopy) were consistently using the Veress needle technique for abdominal entry (blind needle access to the peritoneal cavity, followed by pneumoperitoneum institution and trocar-cannula placement).[93,110] But Egyptian-American gynecologist Harrith M. Hasson (1931-2012) wanted to avoid the complications associated with blind percutaneous needle entry and developed an alternative trocar placement technique in 1971.[111] He used a mini-laparotomy technique for the direct visualization of the trocar entrance, placed the trocar and established pneumoperitoneum.[112] He also made some modifications to the cannula design, making them reusable, with an olive

shaped sleeve and a blunt obturator.[111] Dreaded entry complications were reduced to 0.5%.[113,114] But the merit of Hasson's entry technique is that it appealed to surgeons and helped gap the widely diverging attitudes which had formed between internists (urologists and gynecologists) and general surgeons in the late 1970s.[58,102,115]



Figure 2.8 Galloscope-laparoscope invented by Erich Mühe and used in the first laparoscopic cholecystectomy (adapted from Reynolds, JSLS, 2001).

Between 1975 and 1980 Semm tried to interest general surgeons in performing laparoscopic cholecystectomy.[104] But the surgical community saw no reason to change "A well-established working method into a complicated technical matter".[116] When Semm performed a fully laparoscopic appendectomy in 1980 he received harsh criticism from the established surgical society, orating that ''Only a person with brain damage would perform laparoscopic surgery''.[102,104,117,118] German surgeon Erich Mühe (1938-2005) accomplished the first laparoscopic cholecystectomy in 1983, but struggled heavily to have his findings published.[119] His technical presentation at the Congress of the German Surgical Society was met with considerable skepticism: the procedure was referred to as 'Mickey Mouse surgery' while others remarked "Small brain, small incision".[108] He performed 94 successful procedures

but when his 95th patient died, he was forced by the High Court to abandon his endoscopic work.[108,120]

Advances in anesthesia (analgesics) and the impressive results of intensive care medicine led to the development of more radical and extensive operations.[116] General surgical thinking was oriented to the concept that "Big problems required big incisions" and since "Incisions heal side to side, not end to end" there was little interest in wasting time changing the surgical management of an operation with a mortality rate as low as that of cholecystectomy.[108] Several French surgeons reported having performed successful laparoscopic cholecystectomies Philippe Mouret (1987), Francois Dubois (1988) and Jacques Perissat (1989).[108] Perissat presented his work at the Society of American Gastrointestinal Endoscopic Surgeons (SAGES) meeting in 1989, where the great surgical idea of minimally invasive surgery finally received the attention it disserved.[121] In 1992 Mühe was retrospectively acknowledged for his pioneering achievements and received the highest award from the German Surgical Society.[61,121]

Era of laparoscopic revolution

During the 1980s endoscopists attached heavy video-cameras to the eye piece of the endoscope.[116] Although it was easier to operate with an image projected on a monitor, these video-cameras unfortunately added weight to the endoscope, changing the balance and restricting movement. In 1986 a miniature electronic camera (4x4 mm) was developed that converted the incoming optical image into electronic impulses in a video computer chip (Charged-Coupled Device).[116] The ability to stand upright, and to look at a magnified projection of images onto television screens finally integrated laparoscopy into the discipline of general surgery.[60,102] The highest level of resolution in medical TV monitors by the late 1980s was still only around 275 - 450 lines. But the main advantage was that visualization was no longer limited to the individual directing the operative procedure, and active procedural participation from operative team members was now possible.[58,122] Video-imaging also facilitated education of other surgeons and house staff. Developments in the area of video-imaging have now resulted in higher resolution video-cameras (high definition 1080 lines) that afford greater clarity and definition as well as improved magnification of the operative field.[58]

The advent of laparoscopic cholecystectomy was the single most important stimulus to the development of operative laparoscopy.[58] It changed the field of general surgery more drastically and more rapidly than any other surgical milestone, including the introduction of anesthesia and the later introduction of antibiotics.[60] The rapid acceptance of laparoscopic surgery by the general population is unparalleled in surgical history. Based on obvious and compelling clinical experience, laparoscopic cholecystectomy became accepted by patients before randomized trials were even performed.[108] General surgeons, who had neglected operative laparoscopy before, were forced by the tremendous public interest to take notice. Within a short time various other operative procedures had been performed. By 1997 it was no longer necessary to ask if a certain procedure could be performed laparoscopically, but rather whether the patient benefitted from it.[58] In an era of obsession with cost-containment, early discharge from the hospital has provided considerable incentive for the rapid and widespread adoption of minimally invasive surgery as the technique of choice.[61] In a period of only 4 decades the entire field of operative urology changed from about 10% of endoscopic surgery to more than 80% of the procedures being performed by minimally invasive surgical techniques.[100,123] And while some endoscopic procedures might in fact represent a triumph of technology (or industry) over common sense, one cannot deny that a breakthrough in surgical thinking had been achieved: “We have a new hammer and are actively looking for something to pound”.[116]

Era of robotic surgery

Further technological improvements in the 1990s consisted of the introduction of robotic surgery in laparoscopy.[124,125] Since mid-1980 other surgical specialties had started using robotic devices.[126] Arthrobot was a name given to different robotic prototypes that could be used as a surgical scrub nurse robot, which handed operative instruments on voice command, as a medical laboratory robotic arm, as a positioning robot to bend the patient’s knee and for precise pre-operative planning in total hip arthroplasty.[127,128] Robotic surgical systems are divided in haptic and autonomous systems (Table 2.1). Haptic or tactile robotic systems allow the surgeon to use the robot to perform the operation. This technology requires constant input by the surgeon for the procedure to proceed.[129] Therefore they are also

referred to as computer-assisted systems (CAS) or Robot-Assisted Surgery (RAS).[130] The first systems were designated to work on bony structures, since it is much more difficult to engineer a system that is able to work successfully with soft tissues that are mobile, move and change shape during dissection and manipulation.

Table 2.1 Classification system of surgical robots

Categories	Definition	Examples
Supervisory	The surgeon preprograms the robot off-line first and the robot follows the specified motions autonomously, albeit under the supervision of the surgeon	Probot ROBODOC
Telesurgical	The robot is directly controlled by the surgeon via an online input device or surgical manipulator. The robot faithfully follows the motions of the input device simultaneously in a master-slave-like manner	Da Vinci ZEUS PARAMIS SPORT
Shared-control	The surgeon remains in control of the procedure and the robot offers some feedback or provides stability for the instrument being manipulated by the surgeon. The control is somewhat shared by both the surgeon and the robot	Da Vinci Eye Robot

In 1985 the PUMA 560 (Unimate) robotic surgical arm performed the first robot-assisted surgical procedure when it was used for a percutaneous CT-guided brain biopsy.[131] In orthopedic surgery haptic robots helped with unicompartimental knee replacement (Robotic Arm Interactive Orthopedic System, MAKO Surgical Corp., Fort Lauderdale, Florida and Acrobot, The Acrobot Company, London, United Kingdom). A more advanced type of surgical robots are autonomous robotic systems that still require the surgeon to perform the approach and set up the machine, but once engaged, complete the surgery, or part of the surgery, without the surgeon's help.[129] The first pure robotic surgery in the world took place in 1992



Figure 2.9 PUMA 560 has six degrees of freedom and was used to accurately place needles for CT-guided brain biopsy (Ryan, Essentials in Robotic Surgery, 2015).

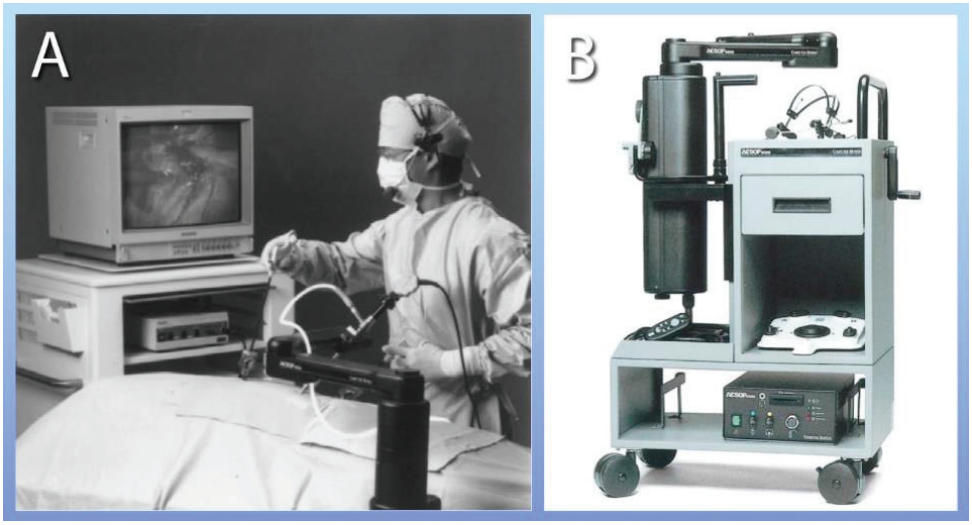

Figure 2.10 The voice-controlled optic holder AESOP for gynecologic endoscopic surgery (adapted from Allaf, Surg Endoscopy, 1998 and Mettler, Hum Reprod, 1998).

when PROBOT (Imperial College London) performed a transurethral prostatectomy.[132] After the surgeon specified a volume of prostate to be cut, it was designed to automatically cut this volume of tissue without further intervention from the surgeon.[133] Later that same year ROBODOC (Integrated Surgical Systems) was introduced to mill out precise fittings in the femur for hip replacement.[134]

Following the lead of laparoscopic surgery, after 1990 pulmonologists started to perform video-assisted thoracoscopic surgery to perform video-assisted interventions.[72] In minimally invasive surgery surgeons had reached a barrier. Fine detailed work in small confined spaces, such as that required in coronary artery bypass surgery, could not be performed because of the two-dimensional visibility and instruments limited to only two or three degrees of freedom (open-close, rotation and bending).[130] This resulted in a vast increase in major complications from diagnostic laparoscopic procedures to operative laparoscopies, respectively 0.6/1,000 and 10.1/1,000.[135] Robotic surgical devices that can act as extensions of the hands of the surgeon were assumed to offer a solution here. The first step was taken in 1993 when a robotic arm called AESOP or Automated Endoscopic System for Optimal Positioning (Computer Motion Inc.) was used to assist in laparoscopic camera holding and positioning for video-assisted thoracoscopic surgery.[136-138]

PARAMIS (Parallel Robot for Minimally Invasive Surgery) was developed for laparoscope camera positioning, but could be transformed into a rigid and stable multi-arm robot controlled from a console.[133] Advantages included: tremor reduction, enhanced precision of movement, utilization of both hands during the procedure, reduced eye strain, enhanced visibility or control of the surgical field, and elimination for a second surgeon.[139]

In 1998 the full advantage of robotic surgical devices could be exploited when the Zeus Robotic Surgical System (Computer Motion Inc.) was used to perform a robot-assisted fallopian tube re-anastomosis (Fig 2.11). In that same year the Da Vinci Robotic Surgery (Intuitive Surgical Inc.) performed a robot-assisted heart bypass procedure (Fig 2.12).[130] The Da Vinci and Zeus systems are similar in their capabilities: both systems are comprehensive master-slave haptic surgical robots with multiple arms operated remotely from a console with video-assisted visualization and computer enhancement.[140]

Figure 2.11 Zeus system set up (Lanfranco, Ann Surg, 2004).

Figure 2.12 The Da Vinci system set up (Lanfranco, Ann Surg, 2004).

The robotic system's extraordinary sensitivity and technical accuracy has facilitated the expertise of the operating surgeon by electronically and mechanically transferring wrist movement beyond the port site to the operative area (Fig 2.2).[61] Remote surgery, with the patient and surgeon in different locations was first achieved in 2001 using the Zeus system.[126] Although the telesurgical robot was originally intended to facilitate remotely performed surgery in battlefield and other remote environments, it turned out to be more useful for minimally invasive on-site surgery. The patents were sold to Intuitive Surgical Inc. and since 2003 the Da Vinci system is the only commercially available system and all contemporary robotic procedures and publications relate solely to the Da Vinci robot.[129,130]

Table 2.2 Advantages and disadvantages of robotic-assisted surgery versus conventional surgery.

Human strengths	Human limitations	Robot strengths	Robot limitations
strong hand-eye coordination dexterous flexible and adaptable can integrate extensive and diverse information rudimentary haptic abilities able to use qualitative information good judgement easy to instruct and debrief	limited dexterity outside natural scale prone to tremor and fatigue limited geometric accuracy limited ability to use quantitative information limited sterility susceptible to radiation and infection	good geometric accuracy stable and untiring scale motion can use diverse sensors in control may be sterilized resistant to radiation and infection	no judgement unable to use qualitative information absence of haptic sensation expensive technology in flux more studies needed

The advantages of robotic surgery are many because they overcome many of the obstacles of laparoscopic surgery: they increase dexterity, restore proper hand-eye coordination, offer an ergonomic position, and improve visualization (Table 2.3).[140] But there are also several disadvantages to these systems: as a new technology its uses and efficacy have not yet been well established (feasibility studies have been performed but long-term follow-up studies are lacking), many procedures will also have to be redesigned to optimize

the use of robotic arms and increase efficiency, and finally there is the cost (with a price tag of over a million euros, and a high yearly maintenance fee their cost is nearly prohibitive).[140] Nonetheless, the advantages outweigh the disadvantages and currently a new robotic system is in full development: SPORT or Single Port Orifice Robotic Technology (Titan Medical Inc., Canada).[133]

Table 2.3 Advantages and disadvantages of robotic-assisted surgery versus laparoscopic surgery

LS advantages	LS disadvantages	RAS advantages	RAS disadvantages
well-developed technology affordable and ubiquitous proven efficacy	loss of touch sensation loss of 3-d visualization compromised dexterity limited degrees of motion the fulcrum effect amplification of physiologic tremors	3-d visualization improved dexterity seven degrees of freedom elimination of fulcrum effect elimination of physiologic tremors ability to scale motions micro-anastomosis possible tele-surgery ergonomic position	absence of touch sensation very expensive high start-up cost may require extra staff to operate new technology unproven benefits

LS: laparoscopic surgery, RAS: robotic-assisted surgery

For innovative surgeons the sky is definitely not the limit. To be ready to perform laparoscopic surgery in space, parabolic flights that create weightlessness, were used to evaluate 'the physiologic tolerance of pigs for pneumoperitoneum during weightlessness'.[141]

Minimally invasive surgery in dogs

When George Kelling performed his first laparoscopy in a dog (1901), it acted as a model for future human procedures.[142] Many other researchers have also used dogs to design new instruments or develop new minimally invasive techniques. Still, it took 71 years before

videoendoscopic surgery was picked up in veterinary medicine to evaluate if dogs could benefit from it. From there on, minimally invasive surgery in dogs has followed a similar dynamic as previously in medicine: it started as a diagnostic tool for abdominal exploration and gastro-intestinal biopsies, next it was used for elective gynecological procedures, before it was finally picked up for general operative purposes.

In the 1970s, when medicine was just shifting from diagnostic to operative videoendoscopic procedures, veterinary pioneers introduced minimally invasive surgery in dogs. Dalton described a procedure for the laparoscopic exploration of the liver and pancreas in dogs (1972).[143] Geyer also used laparoscopy to evaluate the pancreas (1973) and Wildt published his work on using laparoscopy for the direct observation of internal organs in dogs and cats. In 1977 exploratory laparoscopy was described as a staging technique in dogs with a malignant tumor.[144,145] The logical next step was to describe laparoscopic biopsy techniques: laparoscopic renal biopsy (1983),[146] and laparoscopic hepatic biopsy (1985).[147]

In the 1980s and early 1990s the description of new laparoscopic techniques for gynecologic surgeries quickly followed: a sterilization technique in the male dog and cat (1981),[148] laparoscopic bitch sterilization by uterine horn occlusion (1985),[149] laparoscopic vas deferens occlusion (1993),[150] and laparoscopic cryptorchidectomy (1993).[151]

Similar to the evolution in medicine veterinary laparoscopy was also successfully used for urological procedures in the dog: percutaneous cystoscopy of the bladder and prostatic urethra (1995).[152] The first laparoscopic gastropexy procedure was described in 1996.[153]

Surfing on the popularity of minimally invasive procedures in medicine and benefitting from a multitude of research papers using dog models, pioneers started to introduce many different procedures in veterinary medicine. In 1999 the first detailed description of diagnostic thoracoscopy in dogs was published.[154] In 2001 biopsy techniques, but also therapeutic laparoscopic procedures such as ovariectomy and laparoscopic-assisted ovariohysterectomy were already advocated for routine use in dogs.[155] Introductory publications followed that described in detail the different authors' early experience with very useful and simple laparoscopic and laparoscopic-assisted procedures, such as gastropexy (2001),[156-158] laparoscopic organ biopsy (2002),[159,160] laparoscopic ovariectomy (2003),[161-166] laparoscopic-

assisted ovariohysterectomy (2003),[167-169] cystotomy (2003),[170] and cryptorchidectomy (2004).[171,172]

These techniques were widely adopted at many university teaching hospitals and referral centers. Increased confidence with minimally invasive techniques led to further investigation of more complex interventions such as splenectomy (2007),[173-175] adrenalectomy (2008),[176-179] cholecystectomy (2008), [180,181] and ureteronephrectomy (2013).[182]

The earlier evolution in medicine taught us that that once minimally invasive techniques were developed, they rapidly gained popularity with physicians as well as patients, even long before evidence-based studies were conducted to validate their efficacy. The same was true for veterinary diagnostic biopsy procedures. Only 20 years after the description of the first laparoscopic renal biopsy technique, and well after its routine use laparoscopic renal biopsies were shown to be superior to ultrasound guided needle biopsies (2003).[183,184] It took even 27 years before the safety and efficacy of laparoscopic hepatic biopsies was published in a large case series (80 dogs) in 2012.[185]

The introduction of laparoscopic gonadectomy techniques on the other hand generated a lot of debate in veterinary medicine.[186] The medical benefits where extensively documented in an attempt to convince the non-believers.[165,168,174,187-196] But despite the evidence and general acceptance that minimally invasive surgery minimizes tissue trauma and speeds up recovery, its uptake into veterinary clinical practice has been slow.[197] Many private practitioners refused the idea of turning “A well-established working method into a complicated technical matter”, thereby repeating mistakes earlier made in medicine. But veterinary medicine differs from medicine and has its own specific obstacles.

Equipment cost is the first obstacle to overcome. Fortunately, prices of minimally invasive surgical equipment have decreased over the past years due to several factors: technical advances in material, the availability of these instruments on second hand markets, and also because many suppliers previously dedicated on medicine now have focused their attention also to veterinary medicine. The investment cost threshold for veterinarians is now substantially lowered, making this no longer a limiting factor.

The second obstacle has to do with the technical challenges associated with this type of surgery. Skills required for laparoscopic surgery are not practiced in, nor transferred by, conventional surgery.[197] So, it is necessary to obtain training in these specialized skills before it is possible to successfully perform minimally invasive surgery. The organization of good laparoscopic training programs has been essential to instate confidence in the new technique.[198-200] Also, newer generations of veterinary students (also sometimes referred to as 'Nintendo surgeons') are known to embrace all kinds of new technologies.[201] Because of their video gaming background they pick up laparoscopic skills easily, since playing video games enhances visuospatial attention and improves eye-hand coordination.[202,203] This is nicely illustrated by a survey in 2010 amongst diplomates and residents of the American College of Veterinary Surgeons (ACVS) documenting that 86% of small animal diplomates and 98% of residents had performed minimally invasive surgery procedures.[204]

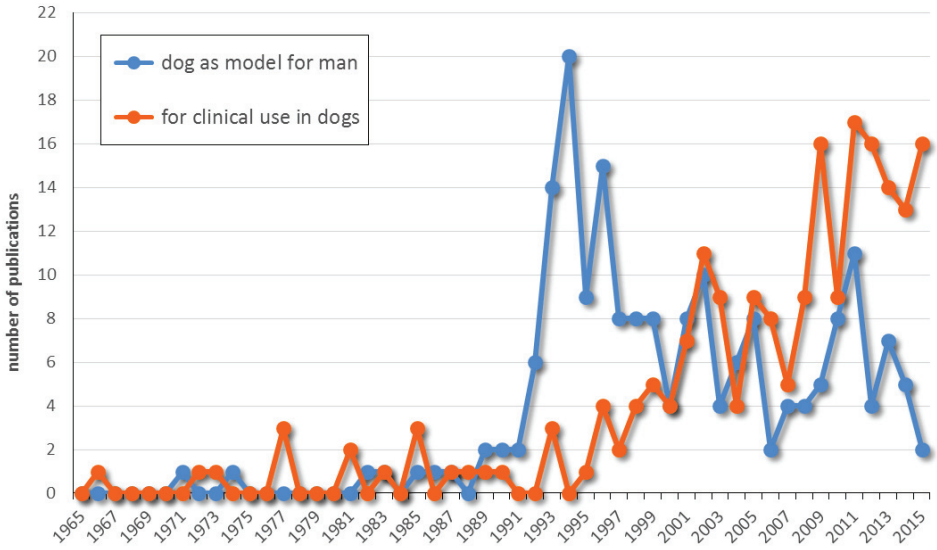

Figure 2.13 The annual number of publications on canine laparoscopy and thoracoscopy according to a search in PubMed and Web of Science. Dogs were first used as a model for medicine during the development of human minimally invasive procedures and the recent peak demonstrates the current popularity of minimally invasive surgery in veterinary medicine.

With the financial barrier and technical challenges removed, the medical argument gets priority and many veterinarians have begun to gladly embrace these technologies.[186,204,205] The annual increase in the number of research publications on laparoscopic and thoracoscopic procedures in dogs reflect the currently booming interest and popularity in veterinary minimally invasive surgery (Fig 2.13).

Creating a pneumoperitoneum for minimally invasive surgery

Since the abdominal wall is in close contact with the intra-abdominal organs, laparoscopic surgery is only possible when an artificial working space is created between these two. This can be achieved by instillation of an inert gas that pushes the abdominal wall away from the intra-abdominal organs, thereby creating a pneumoperitoneum (Fig 2.14). Carbon dioxide is favored because it is inexpensive, noninflammable, colorless, and rapidly excreted by the body.[206]

The pneumoperitoneum can be established through a closed- or an open-technique. The closed technique was the first one described: it uses a percutaneously placed needle to insufflate the abdominal cavity after which the trocar-cannula is placed.[92] The Veress needle, named after his inventor Janos Veress, consists of a blunt inner stylet connected by a spring mechanism to a sharp outer trocar. After making a skin incision the sharp trocar is use to perforate the abdominal wall musculature. As soon as the tip perforates the inner rectus sheath, the blunt stylet appears and prevents damage to intra-abdominal organs. Despite this protective mechanism, placement of the Veress needle is occasionally associated with direct intra-abdominal trauma (vascular injuries, bowel injuries, urological injuries).[207] Entry related complications in medicine occur in 3.3/1,000 procedures.[208] Life-threatening complications include injury to the bowel, bladder, major abdominal vessels, and an anterior abdominal-wall vessel; other less serious complications can also occur, such as post-operative infection, subcutaneous emphysema and extraperitoneal insufflation.[209] A large survey of nearly 37,000 human gynecologic laparoscopies in the United States of America revealed that vascular and intestinal entry injuries were caused by the Veress needle in 39.8%, by insertion of the primary

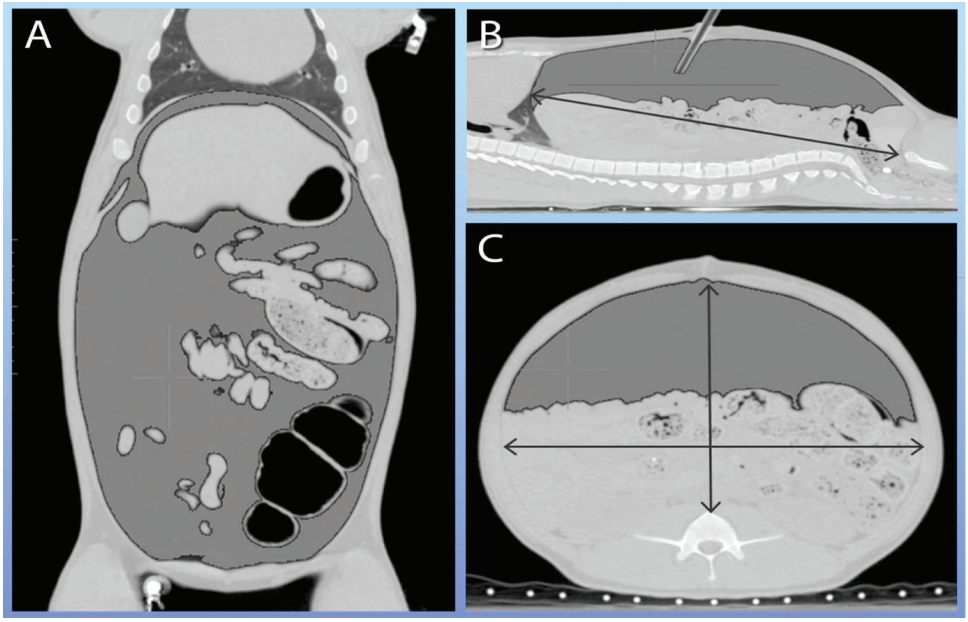

Figure 2.14 CT-images used to evaluate pneumoperitoneum in a pig. The CO_2 pneumoperitoneum is visible as the dark grey area (A). The actual surgical working space created can be measured using: the distance from diaphragm to symphysis (B), and the internal anteroposterior and transverse diameter (C) (adapted from Vlot, Surg Endosc, 2015).

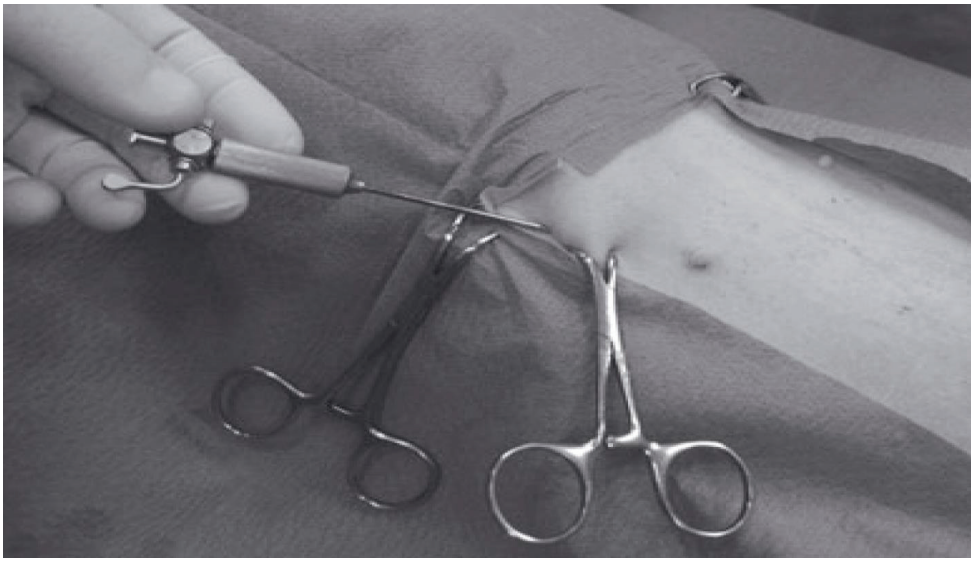

Figure 2.15 Intercostal Veress needle placement to decrease entry complications (Fiorbianco, Vet Surg, 2010).

trocar in 37.9% and by the insertion of the secondary trocar in 22%.[208] To prevent the occurrence of entry trauma in dogs the abdominal wall can be manually lifted, with traction sutures or towel clamps.[210]

An alternative is to place the Veress needle through one of the last right intercostal spaces (Fig 2.15).[211] With the dog in dorsal recumbency the costal arch will remain in more or less the same position, while gravity will flatten out the intra-abdominal organs (in this location more specifically the liver lobes) thereby creating a small virtual space between the liver lobes and the ventral abdominal wall.[212]

The intra-abdominal position is verified by moving the needle back and forth (dangerous for intra-abdominal lacerations), injecting a small amount of fluid, placing a fluid drop on the back of the needle and seeing it sucked inward when lifting the abdominal wall, and by aspiration of the needle (to rule out accidental perforation of spleen, bladder, or small intestine). After placement of the needle the insufflator is connected and gas flow permitted achieving pneumoperitoneum. Correct position of the Veress needle is essential since insufficiently deep placement will result in subcutaneous emphysema or pneumoretroperitoneum, and placing the needle too deep will result in insufflation under the omental leaf complicating visual orientation afterwards. Gas embolism is a rare but rapidly fatal consequence when the tip of the Veress needle is accidentally introduced in a parenchymal organ or blood vessel during laparoscopic access and insufflation gases are directly inoculated into vascular spaces.[213] Once the pneumoperitoneum is created full thickness stab incisions are made with a sharp-pointed surgical scalpel (Swann-Morton No. 11) and a sharp trocar-cannula is used to place the required number of cannulae.[214]

In an attempt to decrease the complications associated with blind percutaneous placement of the Veress needle, Hasson described an open approach for the placement of the cannulae.[111] In this technique a 4 cm ventral midline incision is made and the subcutaneous tissues dissected onto the outer fascia layer of the abdominal wall. Stay sutures or towel clamps are placed lateral to the linea alba and are used to lift the abdominal wall. A stab incision is made with a sharp-tipped scalpel blade through the abdominal wall. Actual opening of the internal fascia can be confirmed by bringing an instrument through the opening into the abdominal cavity (i.e. Mixter forceps). Holding the same amount of traction on the

abdominal wall a blunt-tipped trocar-cannula is inserted. The correct intra-abdominal position of the trocar-cannula is verified by freedom of motion of the trocar-cannula, by visual confirmation after inserting the endoscope in the cannula, or by use of the insufflator. When the insufflator is set to a low flow (1 L/min) presence of the tip of the cannula inside a large abdominal cavity will result in only a gradual increase in pressure. In contrast, when the tip of the cannula is still subcutaneous or even retroperitoneal, a sudden increase in pressure will be seen.[215] Advantages of the Hasson technique include less chance for insertional trauma and easier verification of the correct intra-abdominal position.[113] Disadvantages are the bigger skin incision and the possibility for insufflation gas leakage from the abdominal cavity, when the abdominal wall stab incision is erroneously made larger than the trocar-cannula device diameter.[216] After confirmation of the correct intra-abdominal position the insufflator is set to the normal high flow (3 - 6 L/min) and the pneumoperitoneum is created.

The modified Hasson's technique consists of a variation in which the skin incision is tailored to the cannula diameter (1 - 2 cm). The subcutaneous tissues are still dissected but to a lesser extent. And the abdominal wall is lifted by sutures or towel clamps placed in the surgical wound or percutaneously next to the incision site. Placement of the trocar-cannula is the same as for the Hasson technique. Therefore the modified Hasson's technique combines the advantage of decreased risk for insertional trauma without the disadvantage of a larger skin incision.[217,218] The use of the Ternamian Endo Tip screw-in cannula avoids sudden penetration of the abdominal wall and underlying organs and allows endoscopic verification of penetration level during placement.[219] Consequently this technique was selected as the method of choice for creating a pneumoperitoneum in all the studies in this thesis.

Having a pneumoperitoneum allows the laparoscopic surgeon to bring instruments into the artificial working space created in the abdominal cavity. A high intra-abdominal pressure during entry of the trocar-cannula was found to reduce the amount of entry complications that occured.[220] Also, the higher the pneumoperitoneum, the larger the working space available and thus the easier the manipulation of intra-abdominal organs will be (Fig 2.16).[221]

Historically Kelling (1901) used pressures of 50 - 100 mm Hg in dogs and reported no side effects.[142] But the insufflation of pressurized CO_2 gas into the abdominal cavity does cause

important physiological changes.[222-224] Firstly, rapid absorption of instilled CO_2 across the peritoneal membrane significantly increases plasma CO_2 concentrations, lowers plasma pH, and decreases the pH of peritoneal fluid in dogs.[225,226] Secondly, the positive intra-abdominal pressure will push the diaphragm more cranially. At positive intra-abdominal pressures of 12 mm Hg in dogs cranial advancement of the diaphragm decreases thoracic volume with 14%.[227] The result is a decrease in functional residual capacity of the lung, increased formation of atelectasis, occurrence of ventilation-perfusion mismatch in lung tissue and hypoventilation.[228,229] The resulting continued respiratory compromise will cause hypercapnia and hypoxemia.[206] The combination of CO_2 absorption and decreased ventilation can lead to excessively high $PaCO_2$ values that stimulate catecholamine release, which in turn increase heart rate, arterial blood pressure, and cardiac output, leading eventually to severe acidosis and possibly arrhythmias.[228,230] Thirdly, cardiovascular changes occur since positive intra-abdominal pressure causes caval compression, pooling of blood in the legs, and increased intra-abdominal venous resistance. Cardiovascular changes determined by decreased venous return and increased vascular resistance result in a decreased cardiac output.[231] One hour after the start of insufflation to an intra-abdominal pressure of 16 mm Hg, cardiac output was decreased and became progressively lower during the procedure, with portal venous and superior mesenteric arterial blood flows diminished, contrary no significant changes were observed in dogs at 8 or 12 mm Hg.[232,233] When the total oxidant and antioxidant status, a reflection of splanchnic ischemia, was investigated in dogs after 60 min at 7, 12 or 15 mm Hg capnoperitoneum significant changes were only observed at the higher pressures.[234]

The negative influence of high-pressure pneumoperitoneum on the microcirculation of intra-abdominal organs has also been documented with histopathology. In dogs, a 4 hour period of 20 mm Hg intra-abdominal pressure resulted in significant pathologic changes to the kidney, while the control group (12 mm Hg) did not have these alterations.[235] Guidelines in canine laparoscopy therefore advice to avoid using pressures higher than 15 mm Hg.[206]

Because the abdominal musculature is an elastic structure, insufflation of gas will at first result in a large increase in working space accompanied by only a small increase in pressure (Fig 2.17). Gradually the gain in working space will decrease, while pressure will rise more rapidly. This is documented in pigs, where the CT-measured volume increased by 93% when the intra-abdominal pressure rises from 5 to 10 mm Hg and only by 19% from 10 to 15

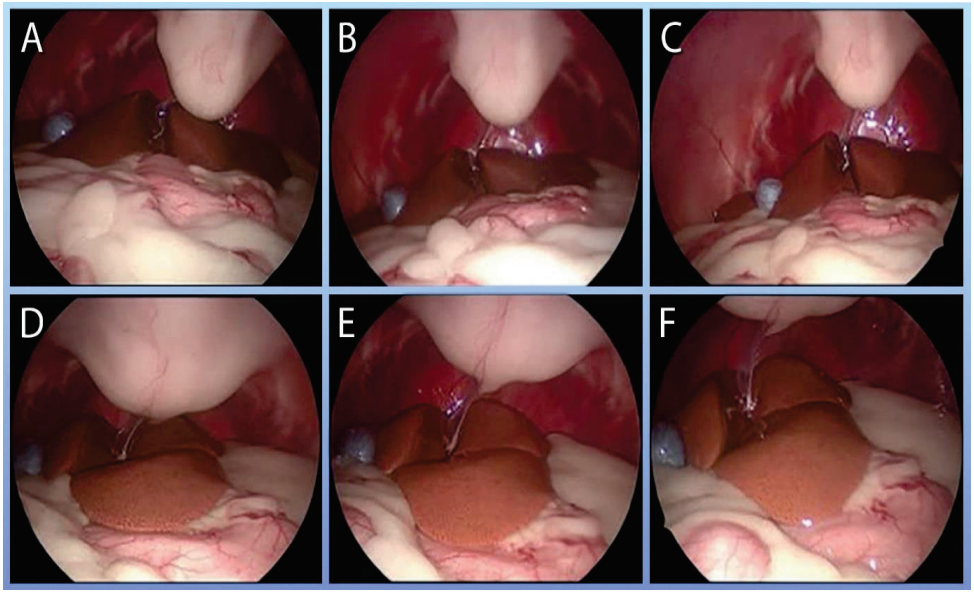

Figure 2.16 Cranial abdominal laparoscopy images of two healthy cats after induction of pneumoperitoneum at intra-abdominal pressures of 4 mm Hg (A and D), 8 mm Hg (B and E), and 15 mm Hg (C and F) (adapted from Mayhew, Am J Vet Res, 2013).

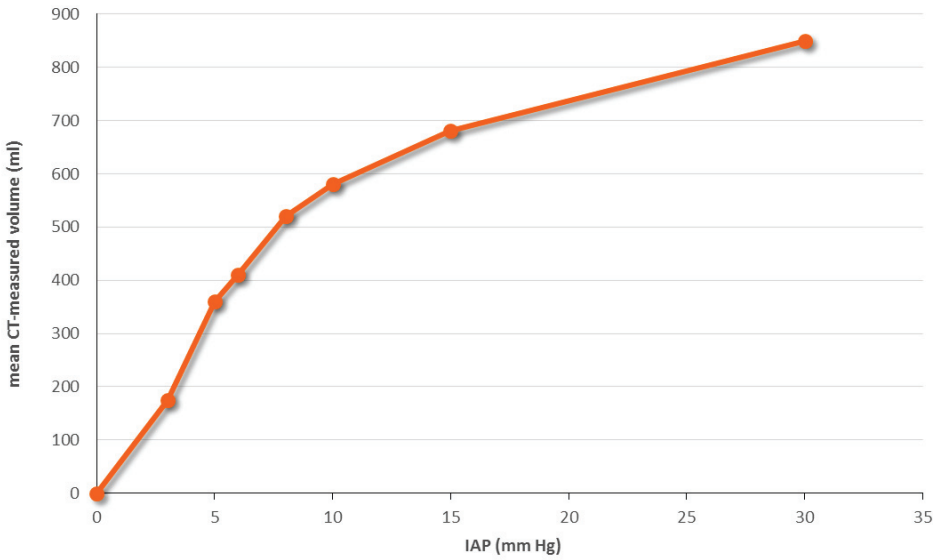

Figure 2.17 Effect of intra-abdominal pressure (IAP) on CO_2 pneumoperitoneum volume in pigs (adapted from Vlot, J Pediatr Surg, 2015).

mm Hg.[236] When the limit of expansion is achieved, any further insufflation will only result in pressure augmentation, not in increasing working space. Based on measured outside abdominal dimensions the cut off value beyond which no further increase in working space was found, but only a detrimental rise in pressure occurred, was determined at 8 mm Hg in cats.[237]

For dogs, it is more difficult to determine the optimal intra-abdominal pressure. Besides age (difference between juvenile versus mature dog) and body condition score (difference between non-obese versus obese dog) there is a tremendous impact of the breed. Determining one optimal value is complicated when dog weights vary from an 800 gram Chihuahua to an 80 kilogram Great Dane (100x heavier!), and when the thickness of the body wall musculature differs (sight hound versus brachycephalic breeds). Neuromuscular blocking agents cause full relaxation of body musculature (including the abdominal musculature).[238] This can potentially change the pressure/volume curve and allow for a larger working space without a deleterious increase of the intra-abdominal pressure (**Chapter 5**).

Hemostatic techniques in minimally invasive surgery

Maintenance of a bloodless surgical field is even more important in laparoscopic surgery than in conventional surgery, because of the relative inability to rapidly remove blood from the visual field.[169] To counter intraoperative bleeding a wide range of hemostatic techniques, suitable to deal with everything from capillary oozing to major arterial bleeding, is available to the laparoscopic surgeon.

Bleeding in conventional surgery is primarily dealt with by pressure on the vessel (digitally or by clamping it with forceps) followed by suture ligation of that same vessel. The principles of counter pressure and suture ligation are also applicable in minimally invasive surgery. Capillary oozing, as seen after biopsy procedures (hepatic) or from minor entry trauma to a parenchymal organ (spleen) is most often self-limiting.[185,239] The positive intra-abdominal pressure in laparoscopic surgery will actually accelerate hemostasis, since it acts as an indirect form of counter pressure. In experimentally created splenic capsule lacerations,

bleeding times were significantly decreased when the intra-abdominal pressure was increased (15.2 minutes at 0 mm Hg, 12.3 minutes at 5 mm Hg, 10.6 minutes at 15 mm Hg and 9.8 minutes at 25 mm Hg).[240] Working with an intra-abdominal pressure of 15 mm Hg thus results in a 30% decrease in capillary bleeding time compared to conventional surgery.

Another way to stimulate natural hemostasis is to bring hemostatic sponges (cellulose- or collagen-based) inside the abdomen and place them at the location of the bleeding.[239,241] Ligatures are often used in conventional surgery to eliminate active bleeding or prevent its occurrence by preplacing ligatures on tissue about to be transected. Intracorporeal suturing is possible with specific instruments for minimally invasive surgery. It is used to appose tissue (i.e. gastropexy procedures).[158,242] But generally this is considered too cumbersome, even for an experienced surgeon, to treat acute hemorrhaging tissue.[243] Instead, extracorporeally created slipknots brought at their desired location with a knot pusher, are a much faster technique.[244] Different knots have been tested and the 4S-modified Roeder knot consistently displays high ligation bursting strengths.[245,246] Ligatures are also commercially available as pre-tied loop ligatures.[247] These can certainly save time in emergency situations. The hemorrhaging vessel is grasped through the loop with a laparoscopic instrument, the loop is brought down on the vessel, tied snugly by pulling the suture and advancing the knot pusher, and finally the suture end is cut.[248]

Vascular staples are used in conventional surgery when it is necessary to transect numerous small to medium sized vessels.[249,250] They offer a reliable and fast technique, without collateral tissue damage and have very high bursting pressures.[251] These instruments have been modified to fit through a cannula, are loaded with multiple clips and are well suited for hemostasis of small and medium sized vessels. Unfortunately, because of the clip size they are not suited for transection of the ovarian pedicle in a dog. Even when using medium or large clips in a 10 mm laparoscopic stapler, a median of 31 clips (range, 19 to 40 clips) was necessary to achieve pedicle hemostasis.[169]

Electromagnetic energy-based hemostatic surgical devices generate heat in the hemorrhaging tissues to achieve hemostasis, just like heated rocks and metal did in prehistoric times.[252] Electrosurgical units used for hemostasis are currently the most common type of electrical equipment in the operating room.[253] The first report of using electromagnetic energy

sources in the early 19th century was by Antoine César Becqueral (1788-1878).[254] At that time it was common to use boiled oil to achieve hemostasis in surgery. But Becqueral preferred an even older technique of using hot iron to cauterize tissue (first described in the Egyptian era). He heated a wire with direct current (DC) to cauterized tissues upon contact and named this principle 'electrocautery'.[253] Current electrocautery instruments use direct current (from a battery) or low frequency, typically 50 or 60 cycles per second, alternating current (AC). The electric current never comes into contact with the patient, it is merely a means of generating heat in a metal wire. Temperatures as high as 400 to 1,200 °C are generated.[255] This is a distinctly different form of hemostasis than the later developed electrocoagulation, and although sometimes erroneously used in publications as a synonym, the term should be reserved for this specific technique.

In 1881 Jacques Arsene d'Arsonoval (1851-1940) discovered that high-frequency alternating current (AC) could pass through the human body without causing neuromuscular side effects that lead to death.[254] Because of the sudden increase in electrical resistance after leaving the metal hand instrument electrons will generate heat at the focal contact point of the metal instrument and the body (sparks).[253] The higher the tissue's resistance, the more tissue heating will occur (bone > fat > muscle > skin > blood). Electrocoagulation causes hemostasis through a coagulum created by the heat generated in the tissues: commonly temperatures ranging from 100 to 300 °C are generated (Table 2.4).[253]

The next decade different power setting were studied for their different tissue effects and a completely new terminology was created: diathermy (high frequency, low-density) causing mild tissue heat, fulguration (high-frequency, high-voltage) resulting in the destruction of superficial tissue, electrocoagulation (high-frequency, high-voltage used with a return electrode under the patient) was able to generated deeper penetration of heat in tissue, and desiccation (high-frequency, low-voltage with return electrode) the production of shorter sparks penetrating deeper in tissue and resulting in tissue dehydration.[256] Around 1920 instrument maker William T. Bovie (1882-1958) in collaboration with neurosurgeon Harvey Cushing (1869-1939) constructed the precursor of modern electrosurgery: an adjustable generator that could produce different waveforms, a hand instrument and a return electrode.[257]

Table 2.4 Principles of thermal tissue effect

temperature	biological tissue effect	hemostatic effect	visual change
40 - 48 °C	reversible inflammation and edema	none	erythema
50 - 70 °C	protein denaturation, coagulation and shrinking	coagulum	white / gray
70 - 90 °C	coagulation necrosis or tissue welding	vessel sealing	translucent / blanching
90 - 200 °C	tissue desiccation (slow) or evaporation (fast)	coagulum	puckering, white smoke
> 200 °C	carbonization of solid tissues	dry eschar	black, dark smoke plume

Combined information from[255,258]

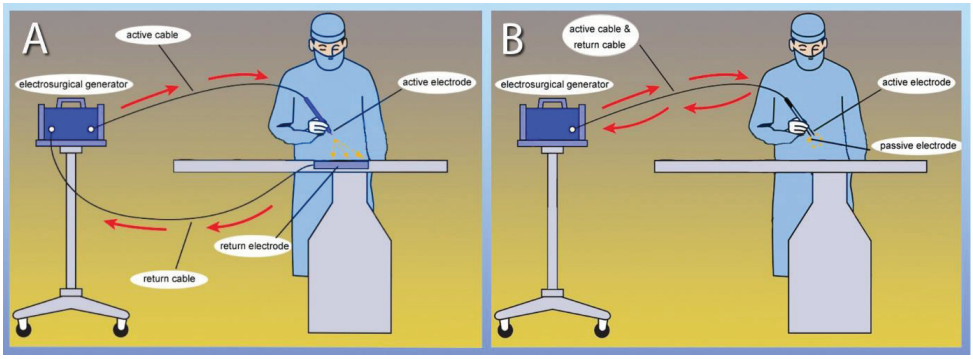

Figure 2.18 Illustration of the electrical pathway in monopolar (A) and bipolar (B) electrocoagulation (adapted from Van Goethem, The Cutting Edge, 2012).

In monopolar electrocoagulation the electrical charge runs from the electrosurgical generator to the hand instrument, is dispersed from a focal point into the patient's body, collected by the return electrode and drained back to the generator (Fig 2.18). Coagulation is achieved with an intermittent sine wave using a generator power setting in the range of 50 - 80 W.[256] Depending on the waveform used, the hand instrument can be used to make a

bloodless incision (low-voltage continuous wave form) or to coagulate blood vessels (high-voltage interrupted wave form). Vessel occlusion is dependent on both vessel crenation and coagulated thrombus within the vessel.[259] Monopolar electrocoagulation can effectively provide hemostasis for vessels ≤ 2 mm diameter (arteries < 1 mm, veins < 2 mm).[260] Collateral damage is seen to occur up to 2 cm away from the coagulation site.[261] In laparoscopic surgery the electrosurgical generator is connected to the laparoscopic instruments to achieve coagulation at the tip of the instrument. Used in contact mode current density is decreased leading to less heat production and drying of tissue with coagulum formation (desiccation coagulation).[256]

In bipolar electrocoagulation the electrical circuit is simplified to avoid alternate pathway burns (Fig 2.18).[253] Current flows from the electrosurgical generator to the hand instrument, reaches tissue from one tip of the instrument, is collected by the opposing tip and returned to the generator. Bipolar units use a lower voltage and power setting (30 - 50 W) compared to monopolar electrocoagulation.[253] The forceps and scissors commonly used in conventional surgery have been replaced by laparoscopic grasping instruments that can hold a significant amount of tissue. They are more effective on larger vessels because they hold the vessel in modest compression during desiccation.[259] Reliable hemostasis becomes possible on vessels up to 3 mm diameter. Lateral collateral damage occurs up to 8 mm from the point of application.[262,263]

The last decade some important instrument improvements have been made and new concepts of electrothermal hemostasis have been introduced, both revolutionizing minimally invasive surgery.[256] Some of these new instruments and hemostatic techniques are the subject of comparative studies in this thesis (**Chapters 6, 7 and 8**).

Hemostatic techniques in traditional gonadectomy

As a routine neutering technique in young and healthy dogs a mini-celiotomy incision can suffice since no abdominal exploration is required.[264] The abdominal wall is only opened

far enough to allow easy exteriorization of the ovary or in large dogs, visualization of the ovarian pedicle to allow safe ligation.

Suture ligation is the most commonly performed hemostatic technique.[265,266] Yet, some technical complications are associated with this suturing technique: placing ligatures around the ovarian pedicle requires the ovary to be brought extra-abdominal or have a large enough celiotomy incision to allow intra-abdominal placement, sutures placed on wet elastic tissue have a tendency to slip, pulling the ovary extra-abdominal will tension the ovarian pedicle generating a force counteracting the compressive force of the encircling ligature, and sutures can tear the fatty tissue of the ovarian pedicle thereby damaging ovarian vessels.

The result of failure of the suture to occlude the ovarian vasculature is life-threatening bleeding.[53] Technical difficulties can be overcome with experience, but in teaching hospitals total complications rates of 21 - 31% have been described.[35,52]

Because of these technical difficulties duration of surgery for ovariohysterectomy varies excessively between experienced (17 minutes for median weight 12.1 kg)[48] and inexperienced surgeons (75 minutes for mean weight 15 kg[35] and 90 minutes for median weight 16.53 kg[52]). Any modification of the ovarian pedicle's hemostatic technique that leads to a decrease in hemorrhagic complications, preferably without a learning curve, would be of great benefit to many veterinarians and animals. We therefore looked at the use of a vessel sealing instrument to perform pedicle hemostasis in midline celiotomy ovariectomy (**Chapter 9**).

Ovarian remnant syndrome

Ovarian remnant syndrome refers to the presence of functional ovarian tissue in a previously gonadectomized animal.[267,268] It is an infrequently encountered condition in dogs: 19 dogs were diagnosed during a 7 year period in one university teaching hospital,[269] a histology lab reported receiving samples from 17 dogs over a 4 year period,[270] and during the learning curve for laparoscopic ovariectomy 3/618 dogs (0.5%) were diagnosed with ovarian

remnant tissue.[271] Of dogs evaluated for complications after ovariohysterectomy at a university teaching hospital 17 - 43% had ovarian remnant tissue.[272]

Ovarian remnants are always found in the typical anatomical locations for ovaries: most occur at the right ovarian pedicle, less frequent the left ovarian pedicle and seldom the are still connected to the right or left uterine horn.[269,271] Because of these normal anatomical locations ovarian remnant tissue is no longer considered to result of congenital ectopic tissue.[269] Accessory ovarian tissue has been described in cats, cows and humans, but does not occur in dogs.[273] The cause of ovarian remnant tissue is therefore assumed to be a surgical error resulting in ovarian tissue remaining unintentionally in the bitch. Several causes have been suggested, including dropping of ovarian tissue, improper clamp placement, and a surgical incision that is too small.[268,270]

When ovarian tissue is left behind with an intact blood supply (i.e. connected to the ovarian pedicle or uterine horn) resumption of endocrine function is to be expected. But also ovarian tissue dropped in the abdomen can revascularize and become functional over time (autotransplantation). This was confirmed in an experimental study in 9 cats that had ovariectomy, but with one ovary, devoid of vasculature, intentionally left behind.[274] Repeat laparotomy six months later showed histological viable tissue and evidence of ovarian follicles or corpora lutea in 8 cats. Endocrine activity due to ovarian remnant syndrome can resume a few weeks to sometimes several years after the failed surgery.[269]

The most common clinical signs mimic those of proestrus or estrus and include vulvar swelling, serosanguineous vaginal discharge, and behavioral changes.[269,275] Uncommon signs including sharp, intermittent, abdominal pain, decreased appetite, dysuria, and frantic licking of the vulva, have also been described.[276] The continued secretion of reproductive hormones can result in ovarian, mammary gland or vaginal neoplasia and endometritis or stump pyometra.[269]

Diagnosis is usually straightforward. Clinical-gynecologic examination may reveal vaginal swelling and discharge during proestrus and estrus, and behavioral changes, mammary gland enlargement, and even milk production can be seen during diestrus.[277] Vaginal cytology showing cornified epithelial cells confirms estrus and thus hormonal activity.[278] Progesterone analysis can be performed when diagnosis is unclear: values higher than 2 ng/mL are indicative

for estrus.[278] The application of gonadotropin-releasing hormone (GnRH) stimulation test is advocated in bitches in which clinical signs are missing.[277] Ultrasound examination is performed to evaluate the entire genital tract in an attempt to locate the ovarian remnant tissue. One study described the correct ultrasonographic identification of the presence or absence of ovarian tissue in 9 of 12 animals.[269]

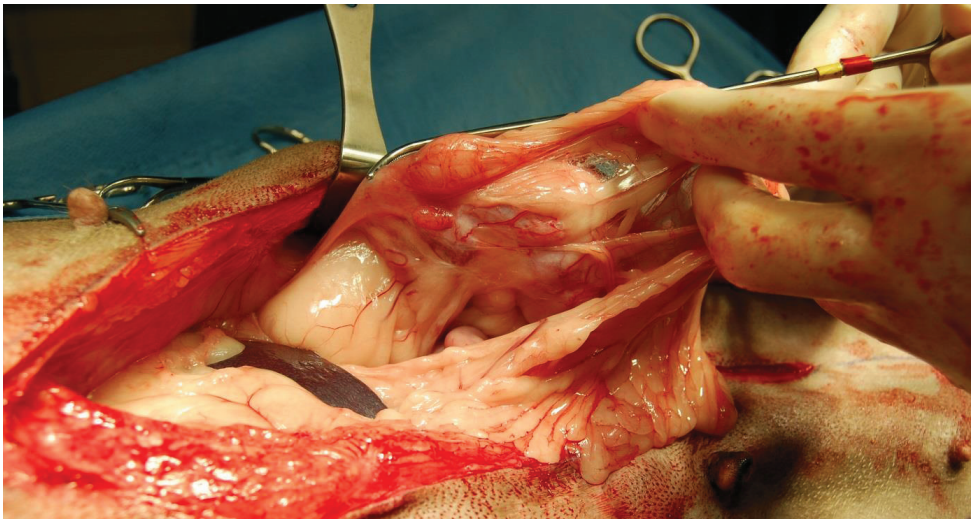

Figure 2.19 A large caudal midline celiotomy is required to identify the ovarian remnant tissue and deal with multiple omental adhesions.

The preferred treatment is surgical removal of the ovarian remnant tissue.[267] However, it can be difficult to identify residual ovarian tissue.[278] Surgical exploration of animals with suspected ovarian remnant tissue should therefore be performed when the animal is in proestrus, estrus, or diestrus because follicles or corpora lutea in the ovarian tissue and prominence of ovarian blood vessels at those times may make the ovarian remnant more readily identifiable.[269] When no macroscopic changes are seen, the ovarian pedicle and uterine horn are shortened, in an attempt to remove the tissue responsible.[278] Histological evaluation afterwards is hereby essential. Laparoscopic surgery is distinguished by a superior operative visualization due to the focused light source and magnification of camera and

monitor.[279] Combined with the minimally invasive nature of laparoscopic surgery these characteristics could make laparoscopic treatment a most efficient technique to treat ovarian remnant syndrome (**Chapter 10**).

References

1. Root Kustritz MV: Effects of surgical sterilization on canine and feline health and on society. Reprod Domest Anim 2012;47 Suppl 4:214-222.
2. Olson PN, Moulton C: Pet (dog and cat) overpopulation in the united states. J Reprod Fertil Suppl 1993;47:433-438.
3. New JC, Jr., Kelch WJ, Hutchison JM, Salman MD, King M, Scarlett JM, Kass PH: Birth and death rate estimates of cats and dogs in U.S. households and related factors. J Appl Anim Welf Sci 2004;7:229-241.
4. Griffiths AO, Silberberg A: Stray animals: Their impact on a community. Mod Vet Pract 1975;56:255-256.
5. Kutzler M, Wood A: Non-surgical methods of contraception and sterilization. Theriogenology 2006;66:514-525.
6. Artois M: Managing problem wildlife in the 'old world': A veterinary perspective. Reprod Fertil Dev 1997;9:17-25.
7. Uspensky I: Tick pests and vectors (Acari: Ixodoidea) in European towns: Introduction, persistence and management. Ticks Tick Borne Dis 2014;5:41-47.
8. Maenhoudt C, Santos NR, Fontbonne A: Suppression of fertility in adult dogs. Reprod Domest Anim 2014;49 Suppl 2:58-63.
9. Weikel JH, Jr., Nelson LW, Reno FE: A four-year evaluation of the chronic toxicity of megestrol acetate in dogs. Toxicol Appl Pharmacol 1975;33:414-426.
10. Trigg TE, Wright PJ, Armour AF, Williamson PE, Junaidi A, Martin GB, Doyle AG, Walsh J: Use of a GnRH analogue implant to produce reversible long-term suppression of reproductive function in male and female domestic dogs. J Reprod Fertil Suppl 2001;57:255-261.
11. Volpe P, Izzo B, Russo M, Iannetti L: Intrauterine device for contraception in dogs. Vet Rec 2001;149:77-79.
12. Salmeri KR, Olson PN, Bloomberg MS: Elective gonadectomy in dogs: A review. J Am Vet Med Assoc 1991;198:1183-1192.
13. Soto FR, Ferreira F, Pinheiro SR, Nogari F, Risseto MR, de Souza O, Amaku M: Adoption of shelter dogs in a Brazilian community: Assessing the caretaker profile. J Appl Anim Welf Sci 2005;8:105-116.
14. Looney AL, Bohling MW, Bushby PA, Howe LM, Griffin B, Levy JK, Eddlestone SM, Weedon JR, Appel LD, Rigdon-Brestle YK, Ferguson NJ, Sweeney DJ, Tyson KA, Voors AH, White SC, Wilford CL, Farrell KA, Jefferson EP, Moyer MR, Newbury SP, Saxton MA, Scarlett JM: The Association of Shelter Veterinarians veterinary medical care guidelines for spay-neuter programs. J Am Vet Med Assoc 2008;233:74-86.

15. Alexander SA, Shane SM: Characteristics of animals adopted from an animal control center whose owners complied with a spaying/neutering program. J Am Vet Med Assoc 1994;205:472-476.
16. Olson PN, Kustritz MVR, Johnston SD: Early-age neutering of dogs and cats in the united states (a review), in Concannon PW, England GCW, Farstad W, et al (eds): Advances in reproduction in dogs, cats and exotic carnivores, Cambridge, Journals Reproduction & Fertility Ltd, 2001, pp 223-232.
17. Root Kustritz MV: Pros, cons, and techniques of pediatric neutering. Vet Clin North Am Small Anim Pract 2014;44:221-233.
18. Porters N, Polis I, Moons C, Duchateau L, Goethals K, Huyghe S, de Rooster H: Prepubertal gonadectomy in cats: Different surgical techniques and comparison with gonadectomy at traditional age. Vet Rec 2014;175:223.
19. Porters N, de Rooster H, Moons CP, Duchateau L, Goethals K, Bosmans T, Polis I: Prepubertal gonadectomy in cats: Different injectable anaesthetic combinations and comparison with gonadectomy at traditional age. J Feline Med Surg 2015;17:458-467.
20. Anonymous: Database lists tests for hereditary diseases in dogs and cats. Vet Rec 2012;171:287.
21. Traas AM, Casal M, Haskins M, Henthorn P: Genetic counseling in the era of molecular diagnostics. Theriogenology 2006;66:599-605.
22. Kraft W: Geriatrics in canine and feline internal medicine. Eur J Med Res 1998;3:31-41.
23. Verstegen J, Dhaliwal G, Verstegen-Onclin K: Mucometra, cystic endometrial hyperplasia, and pyometra in the bitch: Advances in treatment and assessment of future reproductive success. Theriogenology 2008;70:364-374.
24. Sleeckx N, de Rooster H, Veldhuis Kroeze EJ, Van Ginneken C, Van Brantegem L: Canine mammary tumours, an overview. Reprod Domest Anim 2011;46:1112-1131.
25. Schneider R, Dorn CR, Taylor DO: Factors influencing canine mammary cancer development and postsurgical survival. J Natl Cancer Inst 1969;43:1249-1261.
26. Thacher C, Bradley RL: Vulvar and vaginal tumors in the dog: A retrospective study. J Am Vet Med Assoc 1983;183:690-692.
27. Howe LM: Surgical methods of contraception and sterilization. Theriogenology 2006;66:500-509.
28. Klinge U, Si ZY, Zheng H, Schumpelick V, Bhardwaj RS, Klosterhalfen B: Abnormal collagen I to III distribution in the skin of patients with incisional hernia. Eur Surg Res 2000;32:43-48.
29. van Ramshorst GH, Eker HH, Hop WCJ, Jeekel J, Lange JF: Impact of incisional hernia on health-related quality of life and body image: A prospective cohort study. Am J Surg 2012;204:144-150.
30. Gibson KT, Curtis CR, Turner AS, McIlwraith CW, Aanes WA, Stashak TS: Incisional hernias in the horse - incidence and predisposing factors. Vet Surg 1989;18:360-366.
31. Wilson DA, Baker GJ, Boero MJ: Complications of celiotomy incisions in horses. Vet Surg 1995;24:506-514.
32. Mair TS, Smith LJ: Survival and complication rates in 300 horses undergoing surgical treatment of colic. Part 3: Long-term complications and survival. Equine Vet J 2005;37:310-314.
33. Gower SB, Weisse CW, Brown DC: Major abdominal evisceration injuries in dogs and cats: 12 cases (1998-2008). J Am Vet Med Assoc 2009;234:1566-1572.
34. Boothe HW, Slater MR, Hobson HP, Fossum TW, Jung C: Exploratory celiotomy in 200 nontraumatized dogs and cats. Vet Surg 1992;21:452-457.

35. Burrow R, Batchelor D, Cripps P: Complications observed during and after ovariohysterectomy of 142 bitches at a veterinary teaching hospital. Vet Rec 2005;157:829-833.
36. Paul MD: Bidirectional barbed sutures for wound closure: Evolution and applications. J Am Col Certif Wound Spec 2009;1:51-57.
37. Murtha AP, Kaplan AL, Paglia MJ, Mills BB, Feldstein ML, Ruff GL: Evaluation of a novel technique for wound closure using a barbed suture. Plast Reconstr Surg 2006;117:1769-1780.
38. Rath AM, Chevrel JP: The healing of laparotomies: A bibliographic study. Hernia 2000;4:41-48.
39. Leung JC: Barbed bi-directional surgical sutures. Proceedings of the International Conference and Exibition on healthcare and medical textiles, Bolton, United Kingdom, 2003
40. Tera H, Aberg C: Strength of knots in surgery in relation to type of knot, type of suture material and dimension of suture thread. Acta Chir Scand 1977;143:75-83.
41. Kim JC, Lee YK, Lim BS, Rhee SH, Yang HC: Comparison of tensile and knot security properties of surgical sutures. J Mater Sci-Mater M 2007;18:2363-2369.
42. Miro D, Julia MV, Sitgesserra A: Wound breaking strength and healing after after suturing noninjured tissues. J Am Coll Surgeons 1995;180:659-665.
43. Bennett RG: Continuing medical education - selection of wound closure materials. J Am Acad Dermatol 1988;18:619-640.
44. Ruff GL: The history of barbed sutures. Aesthet Surg J 2013;33:12S-16S.
45. Grigoryants V, Baroni A: Effectiveness of wound closure with V-Loc 90 sutures in lipoabdominoplasty patients. Aesthet Surg J 2013;33:97-101.
46. McGrath H, Hardie RJ, Davis E: Lateral flank approach for ovariohysterectomy in small animals. Compend Cont Educ Vet 2004;26:922-930.
47. Reece JF, Nimesh MK, Wyllie RE, Jones AK, Dennison AW: Description and evaluation of a right flank, mini-laparotomy approach to canine ovariohysterectomy. Vet Rec 2012;171:248-253.
48. Michelsen J, Heller J, Wills F, Noble GK: Effect of surgeon experience on postoperative plasma cortisol and C-reactive protein concentrations after ovariohysterectomy in the dog: A randomised trial. Aust Vet J 2012;90:5.
49. Sangwan V: Right flank ovariohysterectomy in dogs. Indian Vet J 2005;82:1118-1119.
50. Janssens LAA, Janssens GH: Bilateral flank ovariectomy in the dog - surgical technique and sequelae in 72 animals. J Small Anim Pract 1991;32:249-252.
51. Dorn AS: Ovariohysterectomy by the flank approach. Vet Med Small Anim Clin 1975;70:569-573.
52. Harris KP, Adams VJ, Fordyce P, Ladlow J: Comparison of surgical duration of canine ovariectomy and ovariohysterectomy in a veterinary teaching hospital. J Small Anim Pract 2013;54:579-583.
53. Adin CA: Complications of ovariohysterectomy and orchiectomy in companion animals. Vet Clin North Am Small Anim Pract 2011;41:1023-1039.
54. Peeters ME, Kirpensteijn J: Comparison of surgical variables and short-term postoperative complications in healthy dogs undergoing ovariohysterectomy or ovariectomy. J Am Vet Med Assoc 2011;238:189-194.
55. Okkens AC, Kooistra HS, Nickel RF: Comparison of long-term effects of ovariectomy versus ovariohysterectomy in bitches. J Reprod Fertil 1997:227-231.
56. Okkens AC, Kooistra HS, Nickel RF: Comparison of long-term effects of ovariectomy versus ovariohysterectomy in bitches. Tijdschr Diergeneesk 2002;127:369-372.
57. Okkens AC, Kooistra HS, Nickel RF: Comparison of long-term effects of ovariectomy versus ovariohysterectomy in bitches. Prakt Tierarzt 2003;84:98-101.

58. Lau WY, Leow KC, Li AKC: History of endoscopic and laparoscopic surgery. World J Surg 1997;21:444-453.
59. Adler R: From hippocrates to the human genome, in Adler R (ed): Medical firsts, (ed 1st), Wiley, 2004, pp 7-12.
60. Spaner SJ, Warnock GL: A brief history of endoscopy, laparoscopy, and laparoscopic surgery. J Laparoendosc Adv Surg Tech A 1997;7:369-373.
61. Modlin IM, Kidd M, Lye KD: From the lumen to the laparoscope. Arch Surg 2004;139:1110-1126.
62. Nezhat C: Nezhat's history of endoscopy - a historical analysis of endoscopy's ascension since antiquity. Tuttlingen, Germany, Endo Press, 2012.
63. Buringh E, van Zanden JL: Charting the "rise of the west": Manuscripts and printed books in europe, a long-term perspective from the sixth through eighteenth centuries. J Econ Hist 2009;69:409-445.
64. Frerejean A: Gutenberg, the inventor of the printing press. Historia 2013:39-40.
65. Palmieri P: Experimental history: Swinging pendulums and melting shellac. Endeavour 2009;33:88-92.
66. Cantor GN: Newton on optics: The optical papers of isaac newton. Science 1984;224:724-725.
67. Anonymous: Surgical instruments in 1873. Br Med J 1873;1:732.
68. Rolls R: Archibald Cleland: c1700-71. Br Med J (Clin Res Ed) 1984;288:1132-1134.
69. Marlow J: History of laparoscopy, optics, fiberoptics, and instrumentation. Clin Obstet Gynecol 1976;19:261-275.
70. Simpson D: Simpson and the discovery of chloroform. Scot Med J 1990;35:149-153.
71. Gordon S: Clinical reports of rare cases, occuring in the hitworth and hardwicke hospitals: Most extensive pleuritic effusion rapidly becoming purulent, paracentesis, introduction of a drainage tube, recovery, examination of interior of pleura by the endoscope. Dublin Quarterly J Med Sci 1866;41:83-90.
72. Marchetti GP, Pinelli V, Tassi GF: 100 years of thoracoscopy: Historical notes. Respiration 2011;82:187-192.
73. Speiden NR: Thomas A. Edison: Sketch of activities, 1874-1881. Science 1947;105:137-141.
74. Hatzinger M, Fesenko A, Sohn M: The first human laparoscopy and notes operation: Dimitrij Oscarovic Ott (1855-1929). Urol Int 2014;92:387-391.
75. Schollmeyer T, Soyinka AS, Schollmeyer M, Meinhold-Heerlein I: Georg Kelling (1866-1945): The root of modern day minimal invasive surgery. A forgotten legend? Arch Gynecol Obstet 2007;276:505-509.
76. Kelling G: Die Tamponade der Bauchhöhle mit Luft zur Stillung Lebensgefährlicher Intestinalblutungen. Münch Med Wochenschr 1901;48:1480-1483;1535-1538.
77. Litynski GS, Paolucci V: Origin of laparoscopy: Coincidence or surgical interdisciplinary thought? World J Surg 1998;22:899-902.
78. Litynski GS: Laparoscopy - the early attempts: Spotlighting Georg Kelling and Hans Christian Jacobaeus. JSLS 1997;1:83-85.
79. Litynski G, Schaeff B, Paolucci V: From pneumoperitoneum to coelioscopy: Georg Kelling (1866-1945) - the pioneer of laparoscopy. Chirurg 1996;67:283-287.
80. Ohlgisser M, Sorokin Y, Heifetz M: Gynecologic laparoscopy. A review article. Obstet Gynecol Surv 1985;40:385-396.
81. Jacobaeus HC: Ueber die Möglichkeit die Zystokopie bei Untersuchung Seröser Höhlungen Anzuwenden. Münch Med Wochenschr 1910;57:2090-2092.

82. Jacobaeus HC: Kürze Übersight über meine Erfahrungen der Laparo-Thorakoskopie. Münch Med Wochenschr 1911;58:2017-2019.
83. Hatzinger M, Badawi JK, Hacker A, Langbein S, Honeck P, Alken P: Georg Kelling (1866-1945). The man who introduced modern laparoscopy into medicine. Urologe A 2006;45:868-870.
84. Jacobaeus HC: The practical importance of thoracoscopy in surgery of the chest. Surg Gynecol Obstetr 1922;34:289-296.
85. Salvadoretti G, Fantin I: [considerations on 550 cases of intrapleural pneumolysis according to jacobaeus]. Minerva Med 1952;43:88-89.
86. Morgenstern L: The first laparoscopist in the united states: Bertram M. Bernheim, md. Surg Innov 2007;14:241-242.
87. Fleming A: The development and use of penicillin. Chic Med Sch Q 1946;7:20-28.
88. Litynski G, Schaeff B, Paolucci V: 100th anniversary of Kalk, Heinz - the breakthrough of laparoscopy. Z Gastroenterol 1995;33:594-597.
89. Morgenstern L: No surgeon he - John C. Ruddock, md, facp, pioneer in laparoscopy. Surg Endosc-Ultras 1996;10:617-618.
90. Ruddock JC: Peritoneoscopy. Surg Gynecol Obstetr 1937;65:623-639.
91. Ruddock JC: Peritoneoscopy - a critical clinical review. Surg Clin N Am1957;37:1249-1260.
92. Veress J: Neues Instrument zur Ausfuhrung von Brust-oder Bauchpunktionen und Pneumothoraxbehandlung. Deut Med Wochenschr 1938;64:1480-1481.
93. Molloy D, Kaloo PD, Cooper M, Nguyen TV: Laparoscopic entry: A literature review and analysis of techniques and complications of primary port entry. Aust N Z J Obstet Gynaecol 2002;42:246-254.
94. Morgenstern L: From cardiology to laparoscopy: John Carroll Ruddock, md (1901-1964). Surg Innov 2005;12:185-186.
95. Fourestier M, Gladu A, Vulmiere J: [improvements in medical endoscopy with special reference to bronchoscopy]. Presse Med 1952;60:1292-1294.
96. Kieser CW: [introduction of cold light to endoscopy]. Aktuelle Urol 2008;39:130-134.
97. Fourestier M, Gladu A, Vulmiere J: Perfectionnements a l'endoscopie medical: Realization bronchoscopique. Presse Med 1952;60:1292.
98. Linder TE, Simmen D, Stool SE: Revolutionary inventions in the 20th century - the history of endoscopy. Arch Otolaryngol 1997;123:1161-1163.
99. Ellis H: The Hopkins rod-lens system. J Perioper Pract 2007;17:272, 274.
100. Fuchs GJ: Milestones in endoscope design for minimally invasive urologic surgery: The sentinel role of a pioneer. Surg Endosc 2006;20:493-499.
101. Cockett WS, Cockett ATK: The Hopkins rod-lens system and the Storz cold light illumination system. Urology 1998;51:1-2.
102. Litynski GS: Kurt Semm and the fight against skepticism: Endoscopic hemostasis, laparoscopic appendectomy, and Semm's impact on the "laparoscopic revolution". JSLS 1998;2:309-313.
103. Semm K: History of operative gynecologic endoscopy, in Sanfilippo JS, Levine RL (eds): Operative gynecologic endoscopy (2nd ed), Berlin, Springer-Verlag New York Inc, 1989, pp 3-17.
104. Bhattacharya K: Kurt Semm: A laparoscopic crusader. J Minim Access Surg 2007;3:35-36.
105. Litynski GS: Kurt Semm and an automatic insufflator. JSLS 1998;2:197-200.
106. Semm K: Tissue-pusher and loop-ligation - new aids for surgical-therapeutic pelviscopy (laparoscopy) = endoscopic intra-abdominal surgery. Endoscopy 1978;10:119-124.

107. Semm K: A new motorised macro-morcellator with horizontal introduction technique. Proceedings 6th World Congress of Endoscopic Surgery 1998, pp589-594.
108. Blum CA, Adams DB: Who did the first laparoscopic cholecystectomy. JMAS 2011;7:165-168.
109. Compeau C, McLeod NT, Ternamian A: Laparoscopic entry: A review of Canadian general surgical practice. Can J Surg 2011;54:315-320.
110. Semm K, Semm I: Safe insertion of trocars and the Veress needle using standard equipment and the 11 security steps. Gynaecol Endosc 1999;8:339-347.
111. Hasson HM: A modified instrument and method for laparoscopy. Am J Obstet Gynecol 1971;110:886-887.
112. Hasson HM: Open laparoscopy as a method of access in laparoscopic surgery. Gynaecol Endosc 1999;8:353-362.
113. Hasson HM: Open laparoscopy vs. closed laparoscopy: A comparison of complication rates. Adv Plan Parent 1978;13:41-50.
114. Hasson HM, Rotman C, Rana N, Kumari NA: Open laparoscopy: 29-year experience. Obstet Gynecol 2000;96:763-766.
115. Hasson HM: Challenges and rewards of a pioneer. JSLS 2007;11:399-402.
116. Litynski GS: Endoscopic surgery: The history, the pioneers. World J Surg 1999;23:745-753.
117. Strong VE, Forde KA, MacFadyen BV, Mellinger JD, Crookes PF, Sillin LF, Shadduck PP: Ethical considerations regarding the implementation of new technologies and techniques in surgery. Surg Endosc 2014;28:2272-2276.
118. Semm K: Endoscopic appendectomy. Endoscopy 1983;15:59-64.
119. Muhe E: Long-term follow-up after laparoscopic cholecystectomy. Endoscopy 1992;24:754-758.
120. Semm K: Robotics and the future of laparoscopy. JSLS 1999;3:87-88.
121. Reynolds W, Jr.: The first laparoscopic cholecystectomy. JSLS 2001;5:89-94.
122. Hanna GB, Shimi SM, Cuschieri A: Task performance in endoscopic surgery is influenced by location of the image display. Ann Surg 1998;227:481-484.
123. Marinakis CA, Fulmer BR: Out of the darkness and into the light: The history of laparoscopy in urology. J Urology 2002;167:185-185.
124. Sackier JM, Wang Y: Robotically assisted laparoscopic surgery. From concept to development. Surg Endosc 1994;8:63-66.
125. Moustris GP, Hiridis SC, Deliparaschos KM, Konstantinidis KM: Evolution of autonomous and semi-autonomous robotic surgical systems: A review of the literature. Int J Med Robot Comp 2011;7:375-392.
126. Yates DR, Vaessen C, Roupret M: From Leonardo to Da Vinci: The history of robot-assisted surgery in urology. BJU International 2011;108:1708-1713.
127. Kwon DS, Yoon YS, Lee JJ, Ko SY, Huh KH, Chung JH, Park YB, Won CH: Arthrobot: A new surgical robot system for total hip arthroplasty. Proceedings of the 2001 IEEE, pp 1123-1128.
128. Kwon DS, Lee JJ, Yoon YS, Ko SY, Kim J, Chung JH, Won CH, Kim JH: The mechanism and the registration method of a surgical robot for hip arthroplasty. Proceedings of the 2002 IEEE, pp 1889-1894.
129. Lang JE, Mannava S, Floyd AJ, Goddard MS, Smith BP, Mofidi A, Seyler TM, Jinnah RH: Robotic systems in orthopaedic surgery. J Bone Joint Surg Br 2011;93B:1296-1299.
130. Kernstine KH: Robotics in thoracic surgery. Am J Surg 2004;188:89S-97S.
131. Kwoh YS, Hou J, Jonckheere EA, Hayati S: A robot with improved absolute positioning accuracy for ct guided stereotactic brain surgery. IEEE Trans Biomed Eng 1988;35:153-160.

132. Mei Q, Harris SJ, ArambulaCosio F, Nathan MS, Hibberd RD, Wickham JEA, Davies BL: Probot - a computer integrated prostatectomy system, in Hohne KH, Kikinis R (eds): Visualization in biomedical computing, Berlin, Springer-Verlag Berlin, 1996, pp 581-590.
133. Ryan H, Tsuda S: History of and current systems in robotic surgery, in Kroh M, Chalikonda S (eds): Essentials in robotic surgery, Switzerland, Springer International, 2015, pp 1-12.
134. Kyberd P: Robodoc carves a place in medical history. New Sci 1992;136:17-17.
135. Härkki-Siren P, Kurki T: A nationwide analysis of laparoscopic complications. Obstet Gynecol 1997;89:108-112.
136. Kavoussi LR, Moore RG, Partin AW, Bender JS, Zenilman ME, Satava RM: Telerobotic assisted laparoscopic surgery: Initial laboratory and clinical experience. Urology 1994;44:15-19.
137. Allaf ME, Jackman SV, Schulam PG, Cadeddu JA, Lee BR, Moore RG, Kavoussi LR: Laparoscopic visual field - voice vs foot pedal interfaces for control of the aesop robot. Surg Endosc-Ultras 1998;12:1415-1418.
138. Mettler L, Ibrahim M, Jonat W: One year of experience working with the aid of a robotic assistant (the voice-controlled optic holder AESOP) in gynaecological endoscopic surgery. Hum Reprod 1998;13:2748-2750.
139. Pisla D, Plitea N, Vaida C, Hesselbach J, Raatz A, Vlad L, Graur F, Gyurka B, Gherman B, Suciu M: PARAMIS parallel robot for laparoscopic surgery. Chirurgia 2010;105:677-683.
140. Lanfranco AR, Castellanos AE, Desai JP, Meyers WC: Robotic surgery - a current perspective. Ann Surg 2004;239:14-21.
141. Kirkpatrick AW, Keaney M, Hemmelgarn B, Zhang JG, Ball CG, Groleau M, Tyssen M, Keyte J, Campbell MR, Kmet L, McBeth P, Broderick TJ: Intra-abdominal pressure effects on porcine thoracic compliance in weightlessness: Implications for physiologic tolerance of laparoscopic surgery in space. Crit Care Med 2009;37:591-597.
142. Kelling G: Über Oesophagoskopie, Gastroskopie und Koelioskopie. München Med Wochen 1901;49:21-31.
143. Dalton JR, Hill FW: A procedure for the examination of the liver and pancreas in dogs. J Small Anim Pract 1972;13:527-530.
144. Wildt DE, Kinney GM, Seager SW: Laparoscopy for direct observation of internal organs of the domestic cat and dog. Am J Vet Res 1977;38:1429-1432.
145. Johnson GF, Twedt DC: Endoscopy and laparoscopy in the diagnosis and management of neoplasia in small animals. Vet Clin North Am 1977;7:77-92.
146. Grauer GF, Twedt DC, Mero KN: Evaluation of laparoscopy for obtaining renal biopsy specimens from dogs and cats. J Am Vet Med Assoc 1983;183:677-679.
147. Jones BD, Hitt M, Hurst T: Hepatic biopsy. Vet Clin North Am Small Anim Pract 1985;15:39-65.
148. Wildt DE, Seager SWJ, Bridges CH: Sterilization of the male dog and cat by laparoscopic occlusion of the ductus deferens. Am J Vet Res 1981;42:1888-1897.
149. Wildt DE, Lawler DF: Laparoscopic sterilization of the bitch and queen by uterine horn occlusion. Am J Vet Res 1985;46:864-869.
150. Silva LD, Onclin K, Donnay I, Verstegen JP: Laparoscopic vasectomy in the male dog. J Reprod Fertil Suppl 1993;47:399-401.
151. Gimbo A, Catone G, Cristarella S, Scirpo A: A new, less invasive, laparoscopic-laparotomic technique for the cryptorchidectomy in the dog. Arch Ital Urol Androl 1993;65:277-281.

152. Van Lue SJ, Cowles RS, 3rd, Rawlings CA: Video-assisted percutaneous cystoscopy of the bladder and prostatic urethra in the dog: New approach for visual laser ablation of the prostate. J Endourol 1995;9:503-507.
153. Wilson ER, Henderson RA, Montgomery RD, Kincaid SA, Wright JC, Hanson RR: A comparison of laparoscopic and belt-loop gastropexy in dogs. Vet Surg 1996;25:221-227.
154. McCarthy TC: Diagnostic thoracoscopy. Clin Tech Small Anim Pract 1999;14:213-219.
155. Richter KP: Laparoscopy in dogs and cats. Vet Clin North Am Small Anim Pract 2001;31:707-727.
156. Rawlings CA, Foutz TL, Mahaffey MB, Howerth EW, Bement S, Canalis C: A rapid and strong laparoscopic-assisted gastropexy in dogs. Am J Vet Res 2001;62:871-875.
157. Runge JJ, Mayhew P, Rawlings CA: Laparoscopic-assisted and laparoscopic prophylactic gastropexy: Indications and techniques. Compend Cont Educ Vet 2009;31:58-65.
158. Mayhew PD, Brown DC: Prospective evaluation of two intracorporeally sutured prophylactic laparoscopic gastropexy techniques compared with laparoscopic-assisted gastropexy in dogs. Vet Surg 2009;38:738-746.
159. Rawlings CA, Howerth EW, Bement S, Canalis C: Laparoscopic-assisted enterostomy tube placement and full-thickness biopsy of the jejunum with serosal patching in dogs. Am J Vet Res 2002;63:1313-1319.
160. Mayhew P: Techniques for laparoscopic and laparoscopic-assisted biopsy of abdominal organs. Comp Cont Ed Vet 2009;31:170-177.
161. Van Goethem B, Rosenveldt KW, Kirpensteijn J: Monopolar versus bipolar electrocoagulation in canine laparoscopic ovariectomy: A nonrandomized, prospective, clinical trial. Vet Surg 2003;32:464-470.
162. van Nimwegen SA, Kirpensteijn J: Comparison of Nd:YAG surgical laser and Remorgida bipolar electrosurgery forceps for canine laparoscopic ovariectomy. Vet Surg 2007;36:533-540.
163. van Nimwegen SA, Van Swol CFP, Kirpensteijn J: Neodymium:Yttrium aluminum garnet surgical laser versus bipolar electrocoagulation for laparoscopic ovariectomy in dogs. Vet Surg 2005;34:353-357.
164. Dupre G, Fiorbianco V, Skalicky M, Gultiken N, Ay SS, Findik M: Laparoscopic ovariectomy in dogs: Comparison between single portal and two-portal access. Vet Surg 2009;38:818-824.
165. Culp WTN, Mayhew PD, Brown DC: The effect of laparoscopic versus open ovariectomy on postsurgical activity in small dogs. Vet Surg 2009;38:811-817.
166. Case JB, Marvel SJ, Boscan P, Monnet EL: Surgical time and severity of postoperative pain in dogs undergoing laparoscopic ovariectomy with one, two, or three instrument cannulas. J Am Vet Med Assoc 2011;239:203-208.
167. Austin B, Lanz OI, Hamilton SM, Broadstone RV, Martin RA: Laparoscopic ovariohysterectomy in nine dogs. J Am Anim Hosp Assoc 2003;39:391-396.
168. Devitt CM, Cox RE, Hailey JJ: Duration, complications, stress, and pain of open ovariohysterectomy versus a simple method of laparoscopic-assisted ovariohysterectomy in dogs. J Am Vet Med Assoc 2005;227:921-927.
169. Mayhew PD, Brown DC: Comparison of three techniques for ovarian pedicle hemostasis during laparoscopic-assisted ovariohysterectomy. Vet Surg 2007;36:541-547.
170. Rawlings CA, Mahaffey MB, Barsanti JA, Canalis C: Use of laparoscopic-assisted cystoscopy for removal of urinary calculi in dogs. J Am Vet Med Assoc 2003;222:759-761.
171. Miller NA, Van Lue SJ, Rawlings CA: Use of laparoscopic-assisted cryptorchidectomy in dogs and cats. J Am Vet Med Assoc 2004;224:875-878.

172. Runge JJ, Mayhew PD, Case JB, Singh A, Mayhew KN, Culp WTN: Single-port laparoscopic cryptorchidectomy in dogs and cats: 25 cases (2009-2014). J Am Vet Med Assoc 2014;245:1258-1265.
173. Oliveira ALA, Zorron R, Rios M, Antunes F, Pires MA, da Costa AC: Laparoscopic splenectomy in a canine: Technique and indications. Rev Bras Med Vet 2007;29:78-82.
174. Stedile R, Beck CAC, Schiochet F, Ferreira MP, Oliveira ST, Martens FB, Tessari JP, Bernades SBL, Oliveira CS, Santos AP, Mello FPS, Alievi MM, Muccillo MS: Laparoscopic versus open splenectomy in dogs. Pesquisa Vet Brasil 2009;29:653-660.
175. Shaver SL, Mayhew PD, Steffey MA, Hunt GB, Mayhew KN, Culp WTN: Short-term outcome of multiple port laparoscopic splenectomy in 10 dogs. Vet Surg 2015;44:71-75.
176. Pelaez MJ, Bouvy BM, Dupre GP: Laparoscopic adrenalectomy for treatment of unilateral adrenocortical carcinomas: Technique, complications, and results in seven dogs. Vet Surg 2008;37:444-453.
177. Smith RR, Mayhew PD, Berent AC: Laparoscopic adrenalectomy for management of a functional adrenal tumor in a cat. J Am Vet Med Assoc 2012;241:368-372.
178. Naan EC, Kirpensteijn J, Dupre GP, Galac S, Radlinsky MG: Innovative approach to laparoscopic adrenalectomy for treatment of unilateral adrenal gland tumors in dogs. Vet Surg 2013;42:710-715.
179. Mayhew PD, Culp WTN, Hunt GB, Steffey MA, Mayhew KN, Fuller M, Della-Maggiore A, Nelson RW: Comparison of perioperative morbidity and mortality rates in dogs with noninvasive adrenocortical masses undergoing laparoscopic versus open adrenalectomy. J Am Vet Med Assoc 2014;245:1028-1035.
180. Mayhew PD, Mehler SJ, Radhakrishnan A: Laparoscopic cholecystectomy for management of uncomplicated gall bladder mucocele in six dogs. Vet Surg 2008;37:625-630.
181. Mayhew PD: Advanced laparoscopic procedures (hepatobiliary, endocrine) in dogs and cats. Vet Clin N Am 2009;39:925-939.
182. Mayhew PD, Mehler SJ, Mayhew KN, Steffey MA, Culp WTN: Experimental and clinical evaluation of transperitoneal laparoscopic ureteronephrectomy in dogs. Vet Surg 2013;42:565-571.
183. Rawlings CA, Diamond H, Howerth EW, Neuwirth L, Canalis C: Diagnostic quality of percutaneous kidney biopsy specimens obtained with laparoscopy versus ultrasound guidance in dogs. J Am Vet Med Assoc 2003;223:317-321.
184. Rawlings CA, Howerth EW: Obtaining quality biopsies of the liver and kidney. J Am Anim Hosp Assoc 2004;40:352-358.
185. Petre SL, McClaran JK, Bergman PJ, Monette S: Safety and efficacy of laparoscopic hepatic biopsy in dogs: 80 cases (2004-2009). J Am Vet Med Assoc 2012;240:181-185.
186. Parkinson TJ: Progress towards less invasive Vet Surg. Vet Rec 2012;171:67-68.
187. Lee JY, Kim MC: Comparison of oxidative stress status in dogs undergoing laparoscopic and open ovariectomy. J Vet Med Sci 2014;76:273-276.
188. Freeman LJ, Rahmani EY, Al-Haddad M, Sherman S, Chiorean MV, Selzer DJ, Snyder PW, Constable PD: Comparison of pain and postoperative stress in dogs undergoing natural orifice transluminal endoscopic surgery, laparoscopic, and open oophorectomy. Gastrointest Endosc 2010;72:373-380.
189. Marcovich R, Williams AL, Seifman BD, Wolf JS: A canine model to assess the biochemical stress response to laparoscopic and open surgery. J Endourol 2001;15:1005-1008.

190. Bohm B, Milsom JW, Fazio VW: Postoperative intestinal motility following conventional and laparoscopic intestinal surgery. Arch Surg 1995;130:415-419.
191. Schippers E, Tittel A, Ottinger A, Schumpelick V: Laparoscopy versus laparotomy: Comparison of adhesion-formation after bowel resection in a canine model. Digest Surg 1998;15:145-147.
192. Hotokezaka M, Combs MJ, Schirmer BD: Recovery of gastrointestinal motility following open versus laparoscopic colon resection in dogs. Digest Dis Sci 1996;41:705-710.
193. Mochiki E, Nakabayashi T, Kamimura H, Haga N, Asao T, Kuwano H: Gastrointestinal recovery and outcome after laparoscopy-assisted versus conventional open distal gastrectomy for early gastric cancer. World J Surg 2002;26:1145-1149.
194. Szabo G, Miko I, Nagy P, Brath E, Peto K, Furka I, Gamal EM: Adhesion formation with open versus laparoscopic cholecystectomy: An immunologic and histologic study. Surg Endosc 2007;21:253-257.
195. Tittel A, Schippers E, Grablowitz V, Pollivoda M, Anurov M, Ottinger A, Schumpelick V: Intra-abdominal humidity and electromyographic activity of the gastrointestinal-tract - laparoscopy versus laparotomy. Surg Endosc-Ultras 1995;9:786-790.
196. Arulpragasam SP, Case JB, Ellison GW: Evaluation of costs and time required for laparoscopic-assisted versus open cystotomy for urinary cystolith removal in dogs: 43 cases (2009-2012). J Am Vet Med Assoc 2013;243:703-708.
197. Fransson B: The future taking veterinary laparoscopy to the next level. J Fel Med Surg 2014;16:42-50.
198. Fransson BA, Ragle CA: Assessment of laparoscopic skills before and after simulation training with a canine abdominal model. J Am Vet Med Assoc 2010;236:1079-1084.
199. Fransson BA, Ragle CA, Bryan ME: A laparoscopic surgical skills assessment tool for veterinarians. J Vet Med Educ 2010;37:304-313.
200. Uson-Gargallo J, Tapia-Araya AE, Martin-Portugues IDG, Sanchez-Margallo FM: Development and evaluation of a canine laparoscopic simulator for veterinary clinical training. J Vet Med Educ 2014;41:218-224.
201. Jalink MB, Goris J, Heineman E, Pierie J-PEN, Hoedemaker HOtC: The effects of video games on laparoscopic simulator skills. Am J Surg 2014;208:151-156.
202. Millard HAT, Millard RP, Constable PD, Freeman LJ: Relationships among video gaming proficiency and spatial orientation, laparoscopic, and traditional surgical skills of third-year veterinary students. J Am Vet Med Assoc 2014;244:357-362.
203. Jalink MB, Goris J, Heineman E, Pierie J, Hoedemaker HOT: The effects of video games on laparoscopic simulator skills. Am J Surg 2014;208:151-156.
204. Bleedorn JA, Dykema JL, Hardie RJ: Minimally invasive surgery in veterinary practice: A 2010 survey of diplomates and residents of the American College of Veterinary Surgeons. Vet Surg 2013;42:635-642.
205. Beierer LH, Burgess DM: Laparoscopy - a new and rapidly advancing field in veterinary science. Aust Vet Pract 2009;39:10-25.
206. Dorfelt R, Eberspacher E: Anaesthesia for laparoscopic surgery in small animal practice. Prakt Tierarzt 2010;91:640-647.
207. Kosuta M, Palmisano S, Piccinni G, Guerrini J, Giuricin M, Nagliati C, Casagranda B, de Manzini N: Safety of veress needle insertion in laparoscopic bariatric surgery. Surg Laparosc Endosc 2014;24:E1-E4.

208. Krishnakumar S, Tambe P: Entry complications in laparoscopic surgery. J Gynecol Endosc Surg 2009;1:4-11.
209. Ahmad G, O'Flynn H, Duffy JMN, Phillips K, Watson A: Laparoscopic entry techniques. Cochrane Database Syst Rev 2012:15;2:1-117.
210. Shamiyeh A, Glaser K, Kratochwill H, Hormandinger K, Fellner F, Wayand WU, Zehetner J: Lifting of the umbilicus for the installation of pneumoperitoneum with the veress needle increases the distance to the retroperitoneal and intraperitoneal structures. Surg Endosc 2009;23:313-317.
211. Doerner J, Fiorbianco V, Dupre G: Intercostal insertion of veress needle for canine laparoscopic procedures: A cadaver study. Vet Surg 2012;41:362-366.
212. Fiorbianco V, Skalicky M, Doerner J, Findik M, Dupre G: Right intercostal insertion of a veress needle for laparoscopy in dogs. Vet Surg 2012;41:367-373.
213. Gilroy BA, Anson LW: Fatal air-embolism during anesthesia for laparoscopy in a dog. J Am Vet Med Assoc 1987;190:552-554.
214. Tinelli A, Gasbarro N, Lupo P, Malvasi A, Tsin DA, Davila F, Dominguez G, Mettler L, Wetter PA: Safe introduction of ancillary trocars. JSLS 2012;16:276-279.
215. Vilos GA, Vilos AG: Safe laparoscopic entry guided by veress needle CO_2 insufflation pressure. J Am Assoc Gyn Lap 2003;10:415-420.
216. Vilos GA, Ternamian A, Dempster J, Laberge PY, The Society of O, Gynaecologists of C: Laparoscopic entry: A review of techniques, technologies, and complications. J Obstet Gynaecol Can 2007;29:433-465.
217. Angioli R, Terranova C, Nardone CDC, Cafa EV, Damiani P, Portuesi R, Muzii L, Plotti F, Zullo MA, Panici PB: A comparison of three different entry techniques in gynecological laparoscopic surgery: A randomized prospective trial. Eur J Obstet Gyn R B 2013;171:339-342.
218. Munro MG: Laparoscopic access: Complications, technologies, and techniques. Curr Opin Obstet Gynecol 2002;14:365-374.
219. Vilos GA: The ABCs of a safer laparoscopic entry. J Minim Invas Gyn 2006;13:249-251.
220. Reich H, Ribeiro SC, Rasmussen C, Rosenberg J, Vidali A: High-pressure trocar insertion technique. JSLS 1999;3:45-48.
221. Kanwer DB, Kaman L, Nedounsejiane M, Medhi B, Verma GR, Bala I: Comparative study of low-pressure versus standard-pressure pneumoperitoneum in laparoscopic cholecystectomy - a randomised controlled trial. Trop Gastroenterol 2009;30:171-174.
222. Boscan P, Cochran S, Monnet E, Webb C, Twedt D: Effect of prolonged general anesthesia with sevoflurane and laparoscopic surgery on gastric and small bowel propulsive motility and ph in dogs. Vet Anaesth Analg 2014;41:73-81.
223. Fukushima FB, Malm C, Andrade MEJ, Oliveira HP, Melo EG, Caldeira FMC, Gheller VA, Palhares MS, Macedo SP, Figueiredo MS, Silva MX: Cardiorespiratory and blood gas alterations during laparoscopic surgery for intra-uterine artificial insemination in dogs. Can Vet J 2011;52:77-79.
224. Weiland L, Polis I, de Rooster H, Gasthuys F: Laparoscopic interventions in dogs: Physiopathological changes and their impact on the patient. Vlaams Diergeneeskd Tijdsschr 2005;74:134-139.
225. Duerr FM, Twedt DC, Monnet E: Changes in pH of peritoneal fluid associated with carbon dioxide insufflation during laparoscopic surgery in dogs. Am J Vet Res 2008;69:298-301.

226. de Barros CJM, Sobrinho JA, Rapoport A, Novo NF, Azevedo J, Sorbello A: Comparative study of the changes in partial pressure of plasma carbon dioxide during carbon dioxide insufflation into the intraperitoneal and preperitoneal spaces. J Laparoendosc Adv S 2009;19:345-349.
227. Watkins C, Fransson BA, Ragle CA, Mattoon J, Gay JM: Comparison of thoracic and abdominal cavity volumes during abdominal CO_2 insufflation and abdominal wall lift. Vet Surg 2013;42:607-612.
228. Weil AB: Anesthesia for endoscopy in small animals. Vet Clin N Am 2009;39:839-48.
229. Gross ME, Dodam JR, Faunt KK: Anesthetic considerations for endoscopy, in McCarthy TC (ed): Veterinary endoscopy for the small animal practitioner, St. Louis, Missouri, Elsevier Saunders, 2005, pp 21-29.
230. Quandt JE: Anesthetic considerations for laser, laparoscopy, and thoracoscopy procedures. Clin Tech Small An P 1999;14:50-55.
231. Carsten EA, Gilson SD: Endoscopy in small animal medicine and surgery. Comp Cont Educ Pract 2000;22:321-324.
232. Ishizaki Y, Bandai Y, Shimomura K, Abe H, Ohtomo Y, Idezuki Y: Safe intra-abdominal pressure of carbon dioxide pneumoperitoneum during laparoscopic surgery. Surgery 1993;114:549-554.
233. Gross ME, Jones BD, Bergstresser DR, Rosenhauer RR: Effects of abdominal insufflation with nitrous-oxide on cardiorespiratory measurements in spontaneously breathing isoflurane-anesthetized dogs. Am J Vet Res 1993;54:1352-1358.
234. Lee JY, Choi SH: Evaluation of total oxidant and antioxidant status in dogs under different CO_2 pneumoperitoneum conditions. Acta Vet Scand 2015;57:6.
235. Hejazi M, Pedram MS, Ashegh H, Jafari N, Ghazisaeedi F, Abdi M: Evaluation of effects of intraperitoneal CO_2 pressure in laparoscopic operations on kidney, pancreas, liver and spleen in dogs. Iran Red Crescent Me 2013;15:809-812.
236. Vlot J, Wijnen R, Stolker RJ, Bax K: Optimizing working space in porcine laparoscopy: CT-measurement of the effects of intra-abdominal pressure. Surg Endosc 2013;27:1668-1673.
237. Mayhew PD, Pascoe PJ, Kass PH, Shilo-Benjamini Y: Effects of pneumoperitoneum induced at various pressures on cardiorespiratory function and working space during laparoscopy in cats. Am J Vet Res 2013;74:1340-1346.
238. Nagahama S, Nishimura R, Mochizuki M, Sasaki N: The effects of propofol, isoflurane and sevoflurane on vecuronium infusion rates for surgical muscle relaxation in dogs. Vet Anaesth Analg 2006;33:169-174.
239. Radhakrishnan A, Mayhew PD: Laparoscopic splenic biopsy in dogs and cats: 15 cases (2006-2008). J Am Anim Hosp Assoc 2013;49:41-45.
240. Papp A, Vereczkei, Lantos J, Horvath OP: The effect of different levels of peritoneal CO_2 pressure on bleeding time of spleen capsule injury. Surg Endosc 2003;17:1125-1128.
241. Rouach Y, Delongchamps NB, Patey N, Fontaine E, Timsit MO, Thiounn N, Mejean A: Suture or hemostatic agent during laparoscopic partial nephrectomy? A randomized study using a hypertensive porcine model. Urology 2009;73:172-177.
242. Spah CE, Wehrenberg A, Jaffe MH, Baird DK, Naughton JF, Payton ME: Evaluation of two novel self-anchoring barbed sutures in a prophylactic laparoscopic gastropexy compared with intracorporeal tied knots. Vet Surg 2013;42:932-942.
243. Jagad RB: A new technique for intracorporeal knot tying in laparoscopic surgery. J Laparoendosc Adv S 2008;18:626-628.

244. Nathanson LK, Nathanson PDK, Cuschieri A: Safety of vessel ligation in laparoscopic surgery. Endoscopy 1991;23:206-209.
245. Shettko DL, Frisbie DD, Hendrikson DA: A comparison of knot security of commonly used hand-tied laparoscopic slipknots. Vet Surg 2004;33:521-524.
246. Fugazzi RW, Fransson BA, Curran KM, Davis HM, Gay JM: A biomechanical study of laparoscopic 4S-modified Roeder and Weston knot strength in 3-0 polyglactin 910 and 3-0 polydioxanone. Vet Surg 2013;42:198-204.
247. Carpenter EM, Hendrickson DA, James S, Franke C, Frisbie D, Trostle S, Wilson D: A mechanical study of ligature security of commercially available pre-tied ligatures versus hand tied ligatures for use in equine laparoscopy. Vet Surg 2006;35:55-59.
248. Freeman LJ: Gastrointestinal laparoscopy in small animals. Vet Clin N Am 2009;39:903-924.
249. Massari F, Nicoli S, Romanelli G, Buracco P, Zini E: Adrenalectomy in dogs with adrenal gland tumors: 52 cases (2002-2008). J Am Vet Med Assoc 2011;239:216-221.
250. Monarski CJ, Jaffe MH, Kass PH: Decreased surgical time with a vessel sealing device versus a surgical stapler in performance of canine splenectomy. J Am Anim Hosp Assoc 2014;50:42-45.
251. Harold KL, Pollinger H, Matthews BD, Kercher KW, Sing RF, Heniford BT: Comparison of ultrasonic energy, bipolar thermal energy, and vascular clips for the hemostasis of small-, medium-, and large-sized arteries. Surg Endosc 2003;17:1228-1230.
252. Massarweh NN, Cosgriff N, Slakey DP: Electrosurgery: History, principles, and current and future uses. J Am Coll Surgeons 2006;202:520-530.
253. Alkatout I, Schollmeyer T, Hawaldar NA, Sharma N, Mettler L: Principles and safety measures of electrosurgery in laparoscopy. J S Laparoendosc Surg 2012;16:130-139.
254. Wang K, Advincula AP: "Current thoughts" in electrosurgery. Int J Gynecol Obstet 2007;97:245-250.
255. Van Goethem B, Schoemaker N, Ensink J: Electro-, cryo-, laser and endoscopic surgery, in Kirpensteijn J, Klein WR (eds): The cutting edge (2nd ed), London, UK, Roman House Publishers, 2012, pp 46-53.
256. Dubiel B, Shires PK, Korvick D, Chekan EG: Electromagnetic energy sources in surgery. Vet Surg 2010;39:909-924.
257. Oconnor JL, Bloom DA: William T. Bovie and electrosurgery. Surgery 1996;119:390-396.
258. Reyes DAG, Brown SI, Cochrane L, Motta LS, Cuschieri A: Thermal fusion: Effects and interactions of temperature, compression, and duration variables. Surg Endosc 2012;26:3626-3633.
259. Kennedy JS, Stranahan PL, Taylor KD, Chandler JG: High-burst-strength, feedback-controlled bipolar vessel sealing. Surg Endosc-Ultras 1998;12:876-878.
260. Toombs JP, Crowe DT: Operative techniques, in DH S (ed): Textbook of small animal surgery (ed 3), Vol 1. Philadelphia PA, W. B. Saunders, 1985, pp 310-334.
261. Hanrath M, Rodgerson DH: Laparoscopic cryptorchidectomy using electrosurgical instrumentation in standing horses. Vet Surg 2002;31:117-124.
262. Hruby GW, Marruffo FC, Durak E, Collins SM, Pierorazio P, Humphrey PA, Mansukhani MM, Landman J: Evaluation of surgical energy devices for vessel sealing and peripheral energy spread in a porcine model. J Urology 2007;178:2689-2693.
263. Phillips CK, Hruby GW, Duvak E, Lehman DS, Humphrey PA, Mansukhani MM, Landman J: Tissue response to surgical energy devices. Urology 2008;71:744-748.

264. Pukacz M, Kienzle B, Braun J: Simple, minimally invasive technique for ovariohysterectomy in the dog. Vet Rec 2009;165:688-690.
265. Okkens AC: Ovariohysterectomy in dogs. Tijdschr Diergeneesk 1981;106:1129-1141.
266. Rubin LD, Maplesden DC: Ovariohysterectomy in dogs and cats. Vet Med Sm Anim Clin 1978;73:467-471.
267. Wallace MS: The ovarian remnant syndrome in the bitch and queen. Vet Clin N Am 1991;21:501-507.
268. Pearson H: The complications of ovariohysterectomy in the bitch. J Small Anim Pract 1973;14:257-266.
269. Ball RL, Birchard SJ, May LR, Threlfall WR, Young GS: Ovarian remnant syndrome in dogs and cats: 21 cases (2000-2007). J Am Vet Med Assoc 2010;236:548-553.
270. Miller DM: Ovarian remnant syndrome in dogs and cats - 46 cases (1988-1992). J Vet Diagn Invest 1995;7:572-574.
271. Pope JF, Knowles TG: Retrospective analysis of the learning curve associated with laparoscopic ovariectomy in dogs and associated perioperative complication rates. Vet Surg 2014;43:668-677.
272. Okkens AC, Dieleman SJ: Gynecologic complications following ovariohysterectomy in dogs. Tijdschr Diergeneesk 1981;106:1142-1158.
273. McEntee K: The ovary, in: McEntee K (ed): Reproductive Pathology of domestic animals, San Diego, Academic Press Inc, 1990, pp 31-51.
274. DeNardo GA, Becker K, Brown NO, Dobbins S: Ovarian remnant syndrome: Revascularization of free-floating ovarian tissue in the feline abdominal cavity. J Am Anim Hosp Assoc 2001;37:290-296.
275. Sangster C: Ovarian remnant syndrome in a 5-year-old bitch. Can Vet J 2005;46:62-64.
276. Parker K, Snead E: Atypical presentation of ovarian remnant syndrome in a dog. J Am Anim Hosp Assoc 2014;50:E1-E5.
277. Gunzel-Apel AR, Buschhaus J, Urhausen C, Masal C, Wolf K, Meyer-Lindenberg A, Piechotta M, Beyerbach M, Schoon HA: [clinical signs, diagnostic approach and therapy for the so-called ovarian remnant syndrome in the bitch]. Tierarztl Prax K H 2012;40:35-42; quiz 43.
278. Van Soom A, Van Goethem B, Rijsselaere T: Diagnosestelling van ovarieel restsyndroom bij hond en kat. Vlaams Diergeneeskd Tijdschr 2008;77:435-441.
279. Van Goethem B, Bosch M, Stegen L: Laparoscopie in de gezelschapsdierenpraktijk. Deel 1: Instrumentarium en basisprincipes. Vlaams Diergeneeskd Tijdschr 2009;78:365-371.

3

Bidirectional barbed sutures for canine midline celiotomy closure

Van Goethem B,[1] van Nimwegen SA,[2] Baeumlin Y,[3]

Van der Vekens E,[3] Rubio-Guzman A,[1] Bosmans T,[1] de Rooster H[1]

submitted

[1]Department of Small Animal Medicine and Clinical Biology, Faculty of Veterinary Medicine, Ghent University, Salisburylaan 133, B-9820 Merelbeke, Belgium

[2]Department of Clinical Sciences of Companion Animals, Faculty of Veterinary Medicine, Utrecht University, Yalelaan 108, P.O. Box 80154, NL-3508 TD Utrecht, The Netherlands

[3]Department Of Medical Imaging of Domestic Animals, Faculty of Veterinary Medicine, Ghent University, Salisburylaan 133, B-9820 Merelbeke, Belgium

Abstract

Objectives: To evaluate the use of bidirectional barbed sutures for midline celiotomy closure (abdominal wall, subcutaneous tissues and dermis) in dogs.

Study Design: Randomized prospective study.

Animals: Nine healthy adult dogs admitted for elective ovariectomy.

Methods: In five dogs the midline celiotomy incision was closed using a commercially available bidirectional barbed suture for each of the three layers (abdominal wall, subcutaneous tissues and dermis). In four dogs, used as the control group, conventional suture material was used. Postoperatively dogs were evaluated for discomfort, wound healing complications, and the abdominal wall was ultrasonographically evaluated at predetermined times after the procedure.

Results: Celiotomy closure was easily achieved and no intraoperative or postoperative complications were encountered. Ultrasonographic evaluation noted that the abdominal wall thickness was increased for the barbed suture group (difference only significant at day 7). Abdominal wall layering and subcutaneous emphysema were not different between groups.

Conclusions: No wound healing complications occurred during abdominal wall closure with bidirectional barbed sutures and ultrasonographic characteristics were comparable to conventional sutures.

Clinical relevance: Bidirectional barbed sutures can be used for closing canine midline celiotomy incisions.

Introduction

Abdominal wall closure in quadrupeds is an essential part of any abdominal surgery. Guidelines for ventral midline closure are based on research as well as on common practical personal observations.[1] These guidelines may be altered following new developments in suture materials or knotting techniques.[2-4] Current guidelines for celiotomy closure in healthy dogs advocate the use of slowly absorbable monofilament material in a simple continuous suture pattern.[5] To achieve adequate knot security knots used in a simple continuous suture pattern require one additional throw at the start and even two or three extra throws at the end of the suture line.[4,6,7]

Figure 3.1 Bidirectional barbed suture material has tissue anchoring barbs in both directions from midway the suture and each end of the suture has a needle attached. (Picture reproduction with permission from Angiotech).

Barbed sutures have been developed as an alternative to conventional knotted sutures. A barbed suture consist of a monofilament suture with helicoidally distributed barbs cut in one direction (unidirectional) or from midway the suture towards both ends

(bidirectional).[8] The unidirectional barbed suture has a loop on one suture end and a needle on the other, allowing the suture to start with a locking loop and to be placed in a conventional manner (suturing from one end of the incision to the other).[9] The bidirectional suture is double armed (each suture end is attached to a needle), and has barbs that proceed in opposite directions from a small non-barbed segment (Fig 3.1). The suture is inserted midway the wound and runs in opposite directions.[10] After placement the barbs anchor firmly into tissues whenever a counterforce is applied, and therefore create secure wound apposition without the need for knots.[10]

In 2004, the United States of America Food and Drug Administration approval was received for use in approximating soft tissues in man.[11] Barbed sutures have progressively gained popularity for their superior tension dispersion.[12] The most common areas of use in medicine include plastic surgery (abdominoplasty, face lift, traumatic wound closure, tie-over dressings for skin grafts), gynecology (hysterectomy, myomectomy), orthopedics (tendon repair, fasciotomy closure) and endoscopic surgery (hernia repair, valvuloplasty, gastric bypass, urethrovesicular anastomosis).[13] In veterinary medicine, barbed sutures have been used in dogs for gastrocnemius tendon repair,[14] gastropexy,[9] laparoscopic gastropexy,[8] gastrotomy and enterotomy closure,[15] and laparoscopic enterotomy.[16]

The current study aimed to investigate whether bidirectional barbed sutures can be used for closing canine midline celiotomy incisions with specific interest to surgical site complications (e.g. herniation). Healing of the abdominal wall was investigated by serial ultrasound examinations.

Materials and methods

Patient selection and randomization

Nine healthy female intact adult Beagle dogs were used. Each had a complete physical examination before inclusion in the study and complete blood count and serum biochemical profile were performed. All dogs were kept at a university teaching hospital (Department of Small Animal Medicine and Clinical Biology, Ghent University, Salisburylaan 38A, 9280

Merelbeke, Belgium) and their history was known. The study was conducted at the dog's intended elective surgery time and was approved by the ethical committee.

Dogs were randomly assigned to one of two groups: midline celiotomy closure with bidirectional barbed suture (barbed suture group) or midline celiotomy closure with conventional monofilament suture (control group).

Power analysis

Considering that the main goal of the study was to test feasibility and safety of a bidirectional barbed suture for celiotomy closure, differences in wound parameters between groups of 30% were emphasized in a power analysis, using β=20%, α=5%, SD=15%. Such differences are detectable using 4 dogs per group.

Anesthetic protocol

A standardized anesthetic and analgesic management protocol was used. After placement of a 22 gauge catheter in the cephalic vein, dogs were intravenously (IV) premedicated with medetomidine (10 µg/kg). After 15 - 20 minutes all dogs were induced with propofol (1 - 2 mg/kg IV given to effect) and then maintained on isoflurane in a 50/50 mixture of oxygen and air (1 - 2 L/min total flow). Volume controlled intermittent positive pressure ventilation (IPPV) was started. Dogs received IV carprofen (4 mg/kg) at the time of induction and were later given oral carprofen (2 mg/kg twice daily) for an additional 3 days after the surgery. Intra-operative fluid therapy consisted of Hartmann's solution delivered at a rate of 5 mL/kg/hour. Cardiorespiratory variables were measured using a multiparameter monitor (Datex S3 monitor, Helsinki, Finland) during anesthesia.

Surgical technique

Centered over the mid-abdomen, a standardized 15 cm incision was made in the skin, subcutaneous layers and abdominal wall (Fig 3.2). After visual evaluation of the genital tract,

verifying the absence of macroscopic abnormalities, elective castration was performed by ovariectomy.[17]

In 5 dogs (barbed suture group), closure of the linea alba was performed using size 0 polydioxanone suture with bidirectional barbs (Quill SRS PDO, Angiotech, Pharmaceuticals, Vancouver, British Columbia, Canada) in a simple continuous appositional pattern. The double-armed suture was started at the midpoint of the wound, and proceeded outward in both directions. To allow the barbs to anchor in the tissue, 2 tissue bites were first taken in a cranial direction, before pulling the suture taut and closing the caudal aspect of the wound (Fig 3.3).

At the end of the celiotomy incision, the suture was passed back along the sutured incision (towards the starting point) for 3 additional tissue bites, according to the manufacturer's guidelines, before cutting the suture at the level of the abdominal wall. No knots were placed. For future identification of the exact suture site, 2 stainless steel staples were placed in the linea alba, one cm away from each end of the incision (Fig 3.4).

The subcutaneous tissues were closed using size 2-0 polyglecaprone suture with bidirectional barbs (Quill SRS Monoderm) starting also at the midpoint as described above. A simple continuous appositional suture pattern was used, with alternating tissue bites in the external fascia, to minimize dead space. At both ends of the incision, the suture was cut at the level of the subcutaneous tissues (without returning tissue bites). The skin was closed in a continuous intradermal pattern using size 3-0 polyglecaprone suture with bidirectional barbs. The suture line started midway the incision and at both ends of the incision the suture was made to exit 1 cm away from the end of the skin incision. This allowed some additional suture barb purchase before cutting the suture at the level of the skin.

In 4 dogs (control group), the midline celiotomy incision was closed using conventional simple continuous sutures of monofilament material similar to the barbed suture materials. The linea alba was closed using polydioxanone 2-0 (PDSII, Ethicon, Johnson & Johnson, Somerville, NJ) in a simple continuous appositional pattern. The knot at the beginning of the suture line consisted of 5 throws and the knot at the end of 6 throws.[4,5] Stainless steel staples were placed 1 cm from the end of the incision line. The subcutaneous tissues were closed using polyglecaprone 3-0 (Monocryl, Ethicon, Johnson & Johnson, Somerville, NJ) in a simple

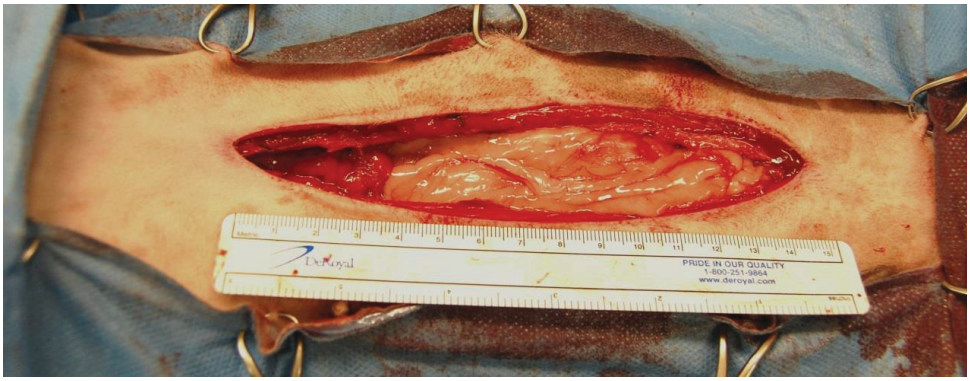

Figure 3.2 A standardized 15 cm midline celiotomy incision was made, centered over the mid-abdomen.

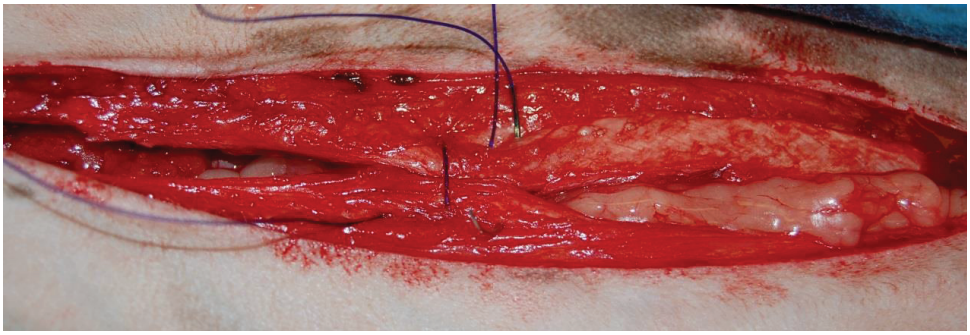

Figure 3.3 Two tissue bites in a cranial direction are necessary to anchor the barbs in the tissue before the caudal aspect can be closed in a simple continuous appositional pattern.

Figure 3.4 Knotless closure of the linea alba with barbed suture. Note the staples placed at both ends of the suture line for future ultrasonographic identification.

continuous subcuticular pattern with alternating tissue bites taken in the external fascial layer. The skin was closed using polyglecaprone 4-0 in a simple continuous intradermal pattern, with both knots buried in the subcutaneous layer.

Follow-up examination

Rescue analgesia was available when discomfort was present (graded 0 none, 1 mild, 2 moderate and 3 severe).

Patients were evaluated daily for the first 7 days and later at 14 and 28 days and at 6 months after the procedure. Wounds were inspected for swelling, erythema, dehiscence and discharge using a previously described scoring system for wound appearance.[18]

Each dog was scheduled to have follow-up abdominal ultrasonography at 1, 2, 3, and 7 days. Dogs from the barbed suture group received additional examinations at 6 months after surgery. The examination was performed with a multifrequency linear array probe of 7-14 MHz, using 12 MHz probe frequency (GE, Logiq 7, Minnesota, USA) with focus, depth and gain settings adapted to each dog in order to optimize the quality of the images. The celiotomy wound was divided in 3 zones from cranial to caudal and each zone was scanned in a transverse and in a longitudinal plane. Images were stored in DICOM format and were later randomly reviewed by two separate board certified radiologists, blinded for suture group, time point, and each other. Previously described specific criteria were used in order to evaluate the wounds: the thickness of the abdominal wall (measurement in mm), the abdominal wall layering (scored 0 normal, 1 mildly disturbed, 2 moderately disturbed and 3 absent), the presence of fluid or edema (scored 0 none, 1 mild, 2 moderate and 3 severe), and the presence of gas (scored 0 absent or 1 present) were evaluated and any other remarkable finding was noted.[19]

Statistics

Differences in test parameters are tested using Student's t-test for interval data, Mann-Whitney test for ordinal and not normally distributed data (normality was tested by Shapiro-

Wilk test), and Chi-square test for nominal data. Results are given as mean ± SD. A *P* value < .05 was considered significant.

Results

Population descriptives

Mean age for all dogs was 4.3 ± 2.8 years (range, 1.2 to 9.5 years) and mean bodyweight was 8.0 ± 1.4 kg (range, 6.3 to 10 kg). No significant differences were observed between the two groups regarding age (barbed suture 3.8 ± 1.2 years versus control group 4.9 ± 4.3 years) and body weight (barbed suture 8.0 ± 0.9 kg versus control group 9.0 ± 1.8 kg).

Results

No intraoperative complications occurred in any of the dogs in either group. The bidirectional barbed suture was easy to handle: traction on the suture during placement, essential for conventional sutures to avoid slacking of previous tissue bites, was found not to be necessary since the engaged barbs effectively locked the tissues in apposition and resisted counterforces trying to open the wound. Since the suture always started from midway of the incision towards both ends, the needle was pushed through the tissues with supination of the wrist on one side and pronation on the other side. Postoperatively, the suture material was well tolerated and no significant difference was seen with regard to postoperative wound characteristics. Rescue analgesia was not necessary for any of the dogs. No surgical site infections occurred in either group. Swelling and erythema of the wounds was comparable between groups and quickly resided within one to three days.

Ultrasound examinations

For both groups combined the thickness of the abdominal wall demonstrated a significant increase the first three days (10.8 ± 2.6 mm, 11.2 ± 2.2 mm, and 11.6 ± 1.7 mm respectively;

P = .046), followed by a not significant decrease at day seven (10.6 ± 1.7 mm). When abdominal wall thickness for the barbed suture group was compared to the control group, the barbed suture group had higher values at all times, but this difference was only significant for day 7 (barbed suture 11.5 ± 1.7 versus control 9.6 ± 0.9 mm; *P* = .002) (Fig 3.5).

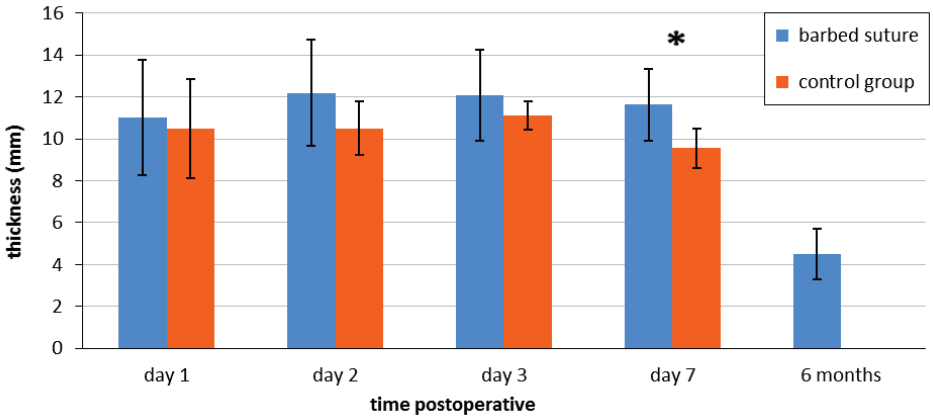

Figure 3.5 Comparison of abdominal wall thickness (SD depicted by error bar) between the barbed suture group and control group (* *P* < .05).

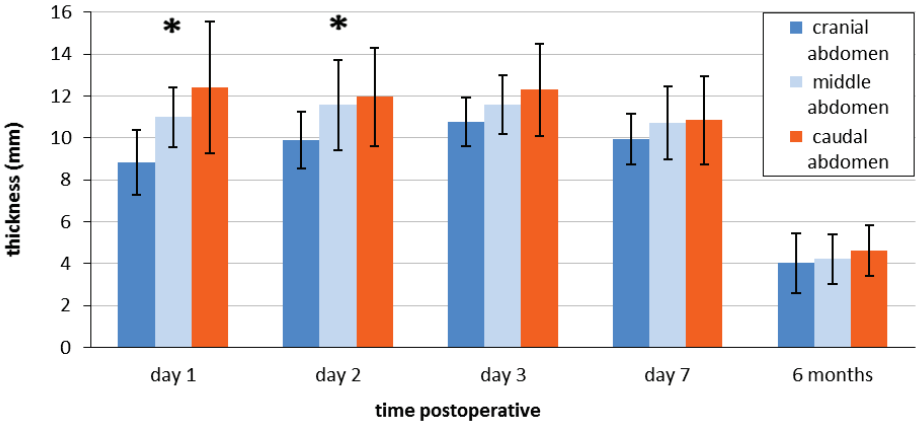

Figure 3.6 Abdominal wall thickness (SD depicted by error bar) for both groups noted a significant difference between the cranial and caudal location at the first and second postoperative day (* *P* < .05).

For both groups combined, the abdominal wall was thicker in the caudal region when compared to the cranial part of the midline celiotomy at day 1 (caudal 12.4 ± 3.1 mm versus cranial 8.8 ± 1.6 respectively; *P* = .011) and day 2 (caudal 12.0 ± 2.4 mm versus cranial 9.9 ± 1.3 respectively; *P* = .032). No significant differences were observed at any other time point (Fig 3.6).

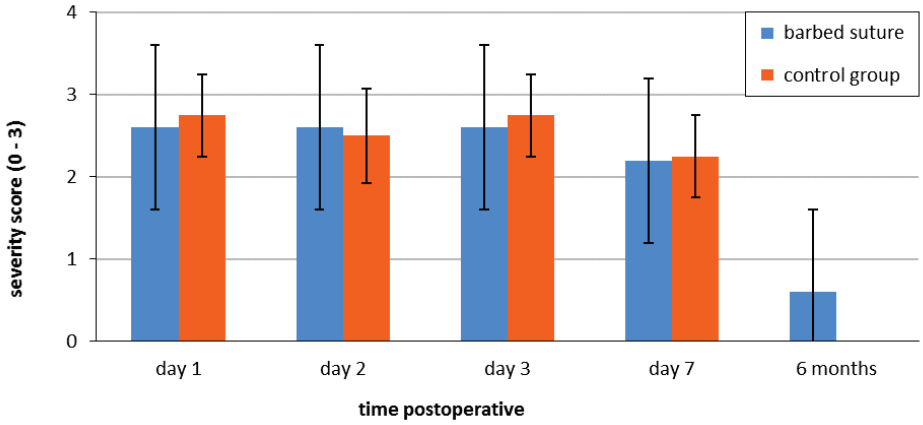

Figure 3.7 The appearance of postoperative abdominal wall layering (SD depicted by error bar) and its resolution was similar for barbed suture and conventional celiotomy closure (* *P* < .05).

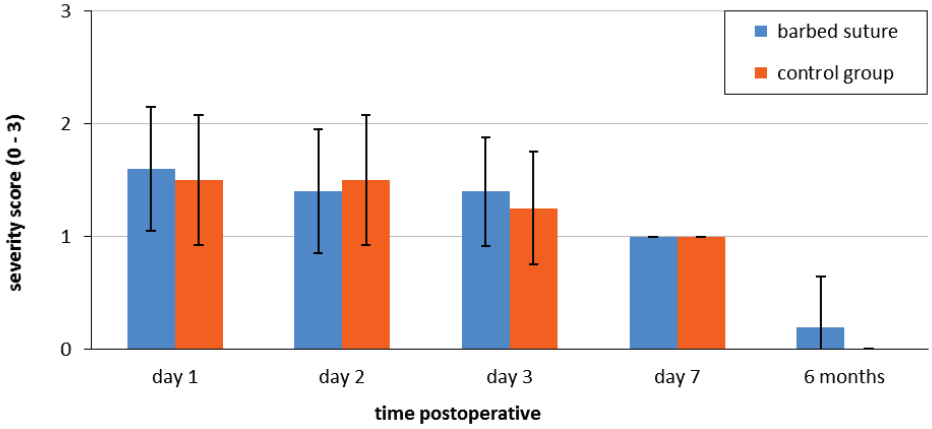

Figure 3.8 The development and resolution of subcutaneous edema (SD depicted by error bar) was similar for barbed suture and conventional celiotomy closure (* *P* < .05).

The abdominal wall layering was moderately disturbed to absent in all dogs during the first seven days after surgery, with a small improvement appearing on day 7 (Fig 3.7). Subcutaneous edema (mild to moderate) was present in all dogs and showed a gradual declined from day 2 on (Fig 3.8).

Pockets of anechoic fluid were visible in all dogs. These pockets were either located between the fascial planes, located around the suture material, or both. The fluid pockets disappeared at day 7 in all dogs. A small amount of gas was detected in the celiotomy wounds in all dogs at day 1. In one dog from the barbed suture group, a larger amount of gas was found at day 3 postoperatively in parallel with larger fluid pockets in the fascial planes and around the suture material. Except for this dog, no gas was seen in the wounds after day 1.

The control evaluation 6 months after surgery in the barbed suture group was characterized by a marked evolution of the ultrasonographic findings: the abdominal wall thickness was greatly diminished (from 11.5 ± 1.7 mm to 4.3 ± 1.2 mm; $P < .01$). In three dogs from the barbed suture group a minimal disturbance of the normal abdominal wall layering was still detected, with regularly spaced hypoechoic areas visible in the muscular layer along the length of the wound. No edema, fluid or gas was visible in any of the dogs at that time.

Discussion

Midline celiotomy closure in five dogs was successfully performed with bidirectional barbed sutures. Using an USP size 0 bidirectional suture for abdominal closure in medium sized dogs, no major complications, including herniation, occurred in any of the animals in this study.

The process of cutting barbs in a monofilament suture will effectively decrease the straight tensile strength by as much as 60%.[10] Thus the strength of a barbed suture will be equivalent to the strength of a monofilament suture that is one size smaller.[13,20] It is important to realize that, in contrast to the unidirectional product, the Quill SRS bidirectional sutures do not take this size differential into consideration in the labelling.[21] When Oni et al (2012) used

a 2-0 bidirectional barbed suture to close a midline celiotomy defect in a pilot study for porcine fascial closure, the animal developed an incisional hernia presumably due to insufficient suture strength.[22] Different size numbers were therefore used in this study: based on the dog's body weight a size 2-0 conventional suture was deemed appropriate for abdominal wall closure, and thus size 0 bidirectional suture was used. Since knot size and knot bulk are the actual limitations for the maximum suture diameter,[23] barbed sutures allow for the use of larger suture diameters when the expected tissue disruption forces necessitate this.

Claimed advantages of barbed sutures encompass knot elimination, improved healing, superior wound apposition and faster placement.[10] Improved healing due to superior wound apposition is currently only a hypothetical advantage.[24] Barbed sutures in movable places as the abdominal wall, could potentially also lead to tissue creep and progressive tensioning of tissue. Tightly approximated wounds and overly taut sutures have been shown to cause ischemia and scarring.[25] The latter will reduced wound strength, increase inflammation and even wound dehiscence can occur.[26-28] However, when wound strength between barbed sutures and conventional sutures was compared in several studies in dogs that evaluated the tissue tensile strength (for laparoscopic gastropexy)[8] and intestinal burst strength (for gastrotomy and enterotomy)[15,29,30] no differences were found. Also, during the 6 months of the current study, no suture extrusion or tissue distortion was observed and all wounds healed without major complications.

Ultrasonographic examination to evaluate abdominal wall healing has not been described in dogs. In cows, this imaging modality has been successfully used to characterize the normal body wall at the standard laparotomy site,[31] and the ultrasonographic assessment of wound healing 11 days after standing laparotomy.[19] In horses, staged ultrasonographic imaging of the ventral midline incision has been found to be an easy, reliable and objective method for the non-invasive monitoring of wound healing and detection of incisional complications such as wound drainage, suture sinus formation, suture abscess, superficial dehiscence or incisional hernia.[32] In the current study, thickness of the abdominal wall increased the first three days and then decreased. This increase is attributed to reflect inflammatory changes due to surgical tissue trauma and healing-induced inflammation[33] and was also evident in studies in cows (2.5 to 4 times)[19] and horses (1.25 to 4 times).[32] In our study abdominal wall layering was severely disturbed the first three days, moderately

disturbed on day 7 and normal-to-minor disturbed at 6 months. This coincides with described tissue resorption times for polydioxanone suture material.[34] When polydioxanone barbed suture material implanted in the abdominal wall in rabbits was histologically evaluated, it elicited a macrophage response that gradually diminished from 3 weeks to 6 months,[35] which may explain the findings of this study.

When bidirectional barbed sutures were used in 298 human plastic surgery procedures excessive erythema and increased wound dehiscence were observed.[36] These wound healing complications have been attributed to the larger cut angle of the barbs that result in a more flexible barb potentially allowing micromotion.[21] In pigs, a dermal wound healing study that compared bidirectional barbed sutures, unidirectional bared sutures and conventional sutures, considered bidirectional barbed sutures a safe and efficacious alternative for cosmetic skin closure.[37] Earlier work in dogs did not report any problems related to dermal wound healing.[10] The current study also did not detect any differences regarding wound healing of the different layers between the bidirectional barbed suture and conventional suture material. Swelling and erythema of the wounds was comparable between groups and quickly resided within one to three days as is common after intradermal closure.[18]

This study has several limitations. The small number of dogs did allow to evaluate the feasibility for using bidirectional barbed sutures for safe midline celiotomy closure. Still, much larger study groups are necessary to evaluate any potential benefit of barbed sutures on wound healing, since only 5.5% of clean surgical wounds develop complications.[38] Ultrasound investigation at 6 months follow-up was only performed in dogs from the barbed suture group so no comparison with the control group was available. Furthermore, the current study did not try to evaluate a possible time benefit for the barbed suture. The main reason being the expected bias caused by unfamiliarity with the suture material and the suturing technique in combination with the small study group. More recent descriptions using a modified suturing technique for bidirectional barbed sutures have found a positive influence on the duration of suturing.[39] Backhand suturing can be avoided by starting the non-barbed middle part as a matrass suture before suturing both ends with normal supination movements, suture backtracking is avoided by simply advancing the suture one or two throws beyond the incision length, and even more time saving is achieved by suturing with two surgeons from both sides of the patient.[13] Improved surgical efficiency is more notable in areas where tissue access is

limited, and when tissues need to be apposed under tension. Spah et al. (2013) determined surgical times for an intracorporeal sutured laparoscopic gastropexy in dogs and found a spectacular 54% decrease in duration for the barbed suture.[8] And two studies comparing surgical times between conventional and barbed suture enterotomy closure also found reduced time for the barbed suture.[15,30] Patients with large wounds or an abdominal incision that needs to be closed under tension could hypothetically benefit from barbed suture material.

Closure of the abdominal wall with bidirectional barbed suture has theoretical advantages over knotted sutures. This study, in a limited number of dogs, proved it to be a safe technique with ultrasonographic wound healing characteristics comparable to conventional sutures.

Disclosure

The bidirectional suture material used in this study was kindly supplied by Angiotech, Pharmaceuticals, Vancouver, British Columbia, Canada. No financial or other support was received.

References

1. Crowe DT: Closure of abdominal incisions using a continuous polypropylene suture: clinical experience in 550 dogs and cats. Vet Surg 1978;7:74-77.
2. Kirpensteijn J, Fingland RB, Boyer JE, Kennedy GA, Klemm RD, Debowes RM: Comparison of stainless-steel fascial staples and polypropylene suture material for closure of the linea-alba in dogs. Vet Surg 1993;22:464-472.
3. Kummeling A, van Sluijs FJ: Closure of the rectus sheath with a continuous looped suture and the skin with staples in dogs: Speed, safety, and costs compared to closure of the rectus sheath with interrupted sutures and the skin with a continuous subdermal suture. Vet Quart 1998;20:126-130.
4. Schaaf O, Glyde M, Day RE: In vitro comparison of secure Aberdeen and square knots with plasma- and fat-coated polydioxanone. Vet Surg 2010;39:553-560.

5. Bellenger CR: Abdominal wall, in Slatter DH (ed): Textbook of Small Animal Surgery (3rd ed), Philadelphia, W.B. Saunders, 2003, pp 405-413.
6. Rosin E, Robinson GM: Knot security of suture materials. Vet Surg 1989;18:269-273.
7. Annunziata CC, Drake DB, Woods JA, Gear AJ, Rodeheaver GT, Edlich RF: Technical considerations in knot construction. Part I. Continuous percutaneous and dermal suture closure. J Emerg Med 1997;15:351-356.
8. Spah CE, Wehrenberg A, Jaffe MH, Baird DK, Naughton JF, Payton ME: Evaluation of two novel self-anchoring barbed sutures in a prophylactic laparoscopic gastropexy compared with intracorporeal tied knots. Vet Surg 2013;42:932-942.
9. Arbaugh M, Case JB, Monnet E: Biomechanical comparison of Glycomer 631 and Glycomer 631 knotless for use in canine incisional gastropexy. Vet Surg 2013;42:205-209.
10. Leung JC, Ruff GL, Megaro MA: Barbed bi-directional medical sutures: Biomechanical properties and wound closure study, in Society for Biomaterials 28th annual meeting, 2002, p 724.
11. Paul MD: Barbed sutures in aesthetic plastic surgery: Evolution of thought and process. Aesthet Surg J 2013;33:17S-31S.
12. Matarasso A: Introduction to the barbed sutures supplement: the expanding applications of barbed sutures. Aesthet Surg J 2013;33:7S-11S.
13. Paul MD: Bidirectional barbed sutures for wound closure: evolution and applications. J Am Col Certif Wound Spec 2009;1:51-57.
14. Perry BS, Harper TA, Mitchell MA, McFadden MS, Perry BH: Barbed versus smooth polypropylene three-loop pulley sutures for repair of canine gastrocnemius tendon. Vet Comp Orthopaed 2014;27:436-440.
15. Ehrhart NP, Kaminskaya K, Miller JA, Zaruby JF: In vivo assessment of absorbable knotless barbed suture for single layer gastrotomy and enterotomy closure. Vet Surg 2013;42:210-216.
16. Omotosho P, Yurcisin B, Ceppa E, Miller J, Kirsch D, Portenier DD: In vivo assessment of an absorbable and non-absorbable knotless barbed suture for laparoscopic single-layer enterotomy closure: a clinical and biomechanical comparison against nonbarbed suture. J Laparoendosc Adv S 2011;21:893-897.
17. Van Goethem B, Schaefers-Okkens A, Kirpensteijn J: Making a rational choice between ovariectomy and ovariohysterectomy in the dog: a discussion of the benefits of either technique. Vet Surg 2006;35:136-143.
18. Sylvestre A, Wilson J, Hare J: A comparison of 2 different suture patterns for skin closure of canine ovariohysterectomy. Can Vet J 2002;43:699-702.
19. Buczinski S, Bourel C, Belanger AM: Ultrasonographic assessment of standing laparotomy wound healing in dairy cows. Res Vet Sci 2012;93:478-483.
20. Rashid R, Sartori M, White LE, Villa MT, Yoo SS, Alam M: Breaking strength of barbed polypropylene sutures - rater-blinded, controlled comparison with nonbarbed sutures of various calibers. Arch Dermatol 2007;143:869-872.
21. Gingras K, Zaruby J, Maul D: Comparison of V-Loc 180 wound closure device and Quill PDO knotless tissue-closure device for intradermal closure in a porcine in vivo model: evaluation of biomechanical wound strength. J Biomed Mater Res B 2012;100B:1053-1058.
22. Oni G, Brown SA, Kenkel JM: A comparison between barbed and nonbarbed absorbable suture for fascial closure in a porcine model. Plast Reconstr Surg 2012;130:536E-541E.
23. Vanrijssel EJC, Brand R, Admiraal C, Smit I, Trimbos JB: Tissue raction and surgical knots - the effect of suture size, knot configuration, and knot volume. Obstet Gynecol 1989;74:64-68.

24. Shah A, Rowlands M, Au A: Barbed sutures and tendon repair - a review. Hand (NY) 2015;10:6-15.
25. Bartlett LC: Pressure necrosis is the primary cause of wound dehiscence. Can J Surg 1985;28:27-30.
26. Nilsson T: Effect of increased and reduced tension on the mechanical properties of healing wound in the abdominal wall. Scand J Plast Recons 1982;16:101-105.
27. Hogstrom H, Haglund U, Zederfeldt B: Tension leads to increased neutrophil accumulation and decreased laparotomy wound strength. Surgery 1990;107:215-219.
28. Alexander HC, Prudden JF: The causes of abdominal wound disruption. Surg Gynecol Obstet 1966;122:1223-1229.
29. Hansen LA, Monnet EL: Evaluation of a novel suture material for closure of intestinal anastomoses in canine cadavers. Am J Vet Res2012;73:1819-1823.
30. Miller J, Zaruby J, Kaminskaya K: Evaluation of a barbed suture device versus conventional suture in a canine enterotomy model. J Invest Surg 2012;25:107-111.
31. Buczinski S, Bourel C, Belanger AM: Ultrasonographic determination of body wall thickness at standing left laparotomy site in dairy cows. Vet Rec 2010;166:204-205.
32. Wilson DA, Badertscher RR, 2nd, Boero MJ, Baker GJ, Foreman JH: Ultrasonographic evaluation of the healing of ventral midline abdominal incisions in the horse. Equine Vet J Suppl 1989:107-110.
33. Peterson SL, Stranahan PL, Schmaltz D, Mihaichuk C, Cosgriff N: Comparison of healing process following ligation with sutures and bipolar vessel sealing. Surg Technol Int 2002;10:55-60.
34. Molea G, Schonauer E, Bifulco G, D'Angelo D: Comparative study on biocompatibility and absorption times of three absorbable monofilament suture materials (Polydioxanone, Poliglecaprone 25, Glycomer 631). Brit J Plast Surg 2000;53:137-141.
35. Bellon JM, Perez-Lopez P, Simon-Allue R, Sotomayor S, Perez-Kohler B, Pena E, Pascual G, Calvo B: New suture materials for midline laparotomy closure: an experimental study. BMC Surg 2014;14:70.
36. Cortez R, Lazcano E, Miller T, Hein RE, Constantine RS, Anigian K, Davis KE, Kenkel JM: Barbed sutures and wound complications in plastic surgery: an analysis of outcomes. Aesthet Surg J 2015;35:178-188.
37. Zaruby J, Gingras K, Taylor J, Maul D: An in vivo comparison of barbed suture devices and conventional monofilament sutures for cosmetic skin closure: biomechanical wound strength and histology. Aesthet Surg J 2011;31:232-240.
38. Brunnberg L, Richter K, Kohn B, Hermanns W: Complications in wound healing in dogs and cats - A retrospective analysis (1990-1994). Kleintierpraxis 1997;42:535-553.
39. Rosen AD: Use of absorbable running barbed suture and progressive tension technique in abdominoplasty: a novel approach. Plast Reconstr Surg 2010;125:1024-1027.

4

Making a rational choice between ovariectomy and ovario-hysterectomy in the dog: a discussion of the benefits of either technique

Van Goethem B, Schaefers-Okkens A, Kirpensteijn J

Vet Surg 2006;35(2):136-143.

Department of Clinical Sciences of Companion Animals, Faculty of Veterinary Medicine, Utrecht University, Yalelaan 108, P.O. Box 80154, NL-3508 TD Utrecht, The Netherlands

Abstract

Objective: To determine if ovariectomy (OVE) is a safe alternative to ovariohysterectomy (OVH) for canine gonadectomy.

Study Design: Literature review.

Methods: An on-line bibliographic search in MEDLINE and PubMed was performed in December 2004, covering the period 1969-2004. Relevant studies were compared and evaluated with regard to study design, surgical technique, and both short-term and long-term follow-up.

Conclusions: OVH is technically more complicated, time consuming, and is probably associated with greater morbidity (larger incision, more intraoperative trauma, increased discomfort) compared to OVE. No significant differences between techniques were observed for incidence of long-term urogenital problems, including endometritis/pyometra and urinary incontinence, making OVE the preferred method of gonadectomy in the healthy bitch.

Clinical Relevance: Canine OVE can replace OVH as the procedure of choice for routine neutering of healthy female dogs.

Introduction

Gonadectomy is one of the most frequently performed surgical techniques in veterinary practice because it is the most reliable means of pet population control.[1] The importance of pet population control is underscored by the American Humane Association's Animal Shelter Reporting Study that between 3.9 and 5.9 million dogs are euthanatized annually in the United States of America.[2]

Gonadectomy can be performed by ovariectomy (OVE) or ovariohysterectomy (OVH), the latter being the preferred approach in the United States of America.[3-5] This preference is most likely based on the assumption that future uterine pathology is prevented by removing the uterus. In The Netherlands and some other European countries, OVE is routinely performed and has replaced OVH as the standard approach for gonadectomy; the uterus is only removed when uterine pathology is present. Despite long-term studies that compare risks and complications associated with these techniques, and favor OVE as the preferred technique, OVE is not generally accepted in the United States of America.[6-9]

Our aim was to evaluate and report possible differences in surgical complications between OVE and OVH. We reviewed the veterinary literature for evidence that would identify whether either technique could be considered superior for routine neutering of dogs.

Surgical technique

OVE is started by a median celiotomy extending from the umbilicus to approximately halfway between umbilicus and os pubis, depending on dog size. In deep-chested or obese dogs, it is sometimes necessary to enlarge the incision cranially to allow sufficient exposure of the ovarian pedicle.[4,10] The ovary is located, and retracted caudally to expose the suspensory ligament and ovarian pedicle. The suspensory ligament is stretched, broken, or transected by electrocoagulation or scissors, to improve manipulation and observation of the pedicle. The arteriovenous complex within the pedicle, arising from the ovarian artery and vein is ligated with 0 to 4-0 absorbable suture material, depending on pedicle size, after which it was

transected. The uterine artery and vein are ligated at the cranial tip of the uterine horn, 5 mm caudal to the proper ligament, using 2-0 to 4-0 absorbable suture material, and transected at the proper ligament.[11] After excision, the ovarian bursa is opened and the ovary inspected to confirm complete ovarian removal.[3,11]

OVH os also performed through a median celiotomy, although, based on the dog's size and body condition, the incision is lengthened in a caudal direction. After the ovarian pedicles are ligated and severed, the broad ligament was examined. If it is vascular, it is ligated with 1 or 2 ligatures using 2-0 to 4-0 absorbable suture material before it is cut or torn. A clamp is placed on the uterine body just cranial to, or on, the cervix. The uterine arteries are individually ligated proximal to the clamp using 2-0 to 4-0 absorbable suture material and the uterus, is ligated circumferentially in the crushing groove that remains after removal of the clamp using 0 to 4-0 absorbable suture material. After inspection for potential bleeding at the ligated pedicles, the celiotomy is closed in layers.[3,4,11-13]

From a technical perspective, OVE is less invasive and less time-consuming than OVH. Although it is possible to perform OVH through a small median celiotomy, atraumatic technique and correct placement of the uterine ligature near the cervix typically requires a larger celiotomy incision compared to OVE. Thus, the duration of surgery and anesthesia should be shorter for OVE, and because the celiotomy incision is shorter, the broad ligaments are not disrupted, and the uterine stump left intact, there is also less surgical trauma.

Indications for OVE and OVH

OVE is most commonly performed for elective neutering; however, it is also indicated for treatment of ovarian tumors, to promote involution of placental sites (non-responsive to medical treatment), to prevent recurrence of vaginal hyperplasia, to prevent hormonal changes that can interfere with medical therapy in patients with endocrine diseases (e.g., diabetes), and to eliminate the transfer of inherited diseases (e.g., generalized demodicosis).[3,11,14] OVE is also performed in young dogs (≤ 2.5 years) to decrease the incidence of mammary gland tumors. The relative risk for developing mammary gland tumors

decreases when neutering is performed before the first estrus (0.5%), between the first and second estrus (8%), and between the second estrus and 2.5 years of age (26%).[15] Despite one contrary opinion,[16] there is seemingly no benefit in performing OVH at the time of mammary tumor removal because neither tumor-related nor overall survival improve after OVH.[17-19]

OVH is the treatment of choice for most uterine diseases, including: congenital anomalies, pyometra, localized or diffuse cystic endometrial hyperplasia (CEH), uterine torsion, uterine prolapse, uterine rupture, and uterine neoplasia.[3,4,11,20] In a study of 1,712 canine OVHs, 1,409 (82%) were performed for elective sterilization, and only 313 (18%) for reproductive tract disease (as adjunctive therapy for mammary neoplasia, for treatment of pyometra, endometrial hyperplasia, vaginitis, and several miscellaneous genital tract diseases).[21] This and other reports clearly reflect textbook recommendations that the preferred technique for gonadectomy in dogs and cats is OVH.[3-5,11]

Surgery related complications

The primary rationale for selection of OVH or OVE is likely related to the expected frequency of short-term and long-term complications. In a retrospective study of 62 dogs that had OVH, 17.7% developed complications.[22]

Table 4.1 Surgery related complications after ovariohysterectomy

Group	Intra-abdominal bleeding			Vaginal bleeding		Ligation of the ureter			Ovarian remnant syndrome		Stump granuloma (suture reaction)		
OVH	< 25 kg:	2%	(7/290)[10]	2%	(2/8)[10]	OP:	*2%*	*(2/109)*[8]	*43%*	*(47/109)*[9]	OP:	*60%*	*(12/20)*[5]
									43%	(47/109)[9]		*1%*	*(1/109)*[8]
	> 25 kg:	79%	(69/87)[10]	*15%*	*(11/72)*[23]	US:	*3%*	*(3/109)*[8]	1%	(1/87)[10]	US:	*20%*	*(4/20)*[5]
									17%	*(12/72)*[23]		*5%*	*(5/109)*[8]
												7%	*(8/109)*[9]
												51%	*(37/72)*[23]

OVH, ovariohysterectomy; OP, ovarian pedicle; US, uterine stump. *Italic:* relative numbers, percentages based on dogs with complications.

Complications associated with OVE would be expected to be similar to those associated with the OVE component of OVH; however, other complications associated with removal of the uterus in OVH would not be expected with OVE. A review of reported complications after OVE and OVH is presented in Table 4.1.

Intra-abdominal bleeding

Bleeding was the most common complication (79%) in dogs >25 kg in a review of 853 OVHs.[10] Concurrently, bleeding has been determined to be the most common cause of death after OVH in large breed dogs.[5,20] Clinically important bleeding primarily occurs from the ovarian pedicles, the uterine vessels, or the uterine wall when ligatures are improperly placed,[23] and rarely occurs from vessels that accompany the suspensory ligament or within the broad ligament (Fig 4.1).[4] Thus, comparing OVE with OVH, the likelihood of clinically important bleeding from the ovarian pedicles should be similar.

Theoretically, OVH has additional risk for bleeding from vessels in the broad ligament and from uterine vessels near the cervix (where the uterine arteries are larger than at the tip of the uterine horn and bleeding can be more severe in comparison). Bleeding from uterine vessel rupture caused by excessive traction on the uterine body during OVH has been reported.[23]

Vaginal bleeding

Single non-absorbable multifilament ligatures around the uterine body can predispose to erosion of uterine vessels, resulting in intermittent vaginal bleeding (Fig 4.2). Pearson reported vaginal bleeding in 11 of 72 dogs (15%), 4 - 16 days after surgery.[23] Vaginal tamponade or exploratory celiotomy may be indicated, if the bleeding becomes severe. Vaginal bleeding may also be associated with infection caused by contamination during surgery, use of infected suture material, or from transfixation ligatures that enter the lumen of the uterus or cervix.[23]

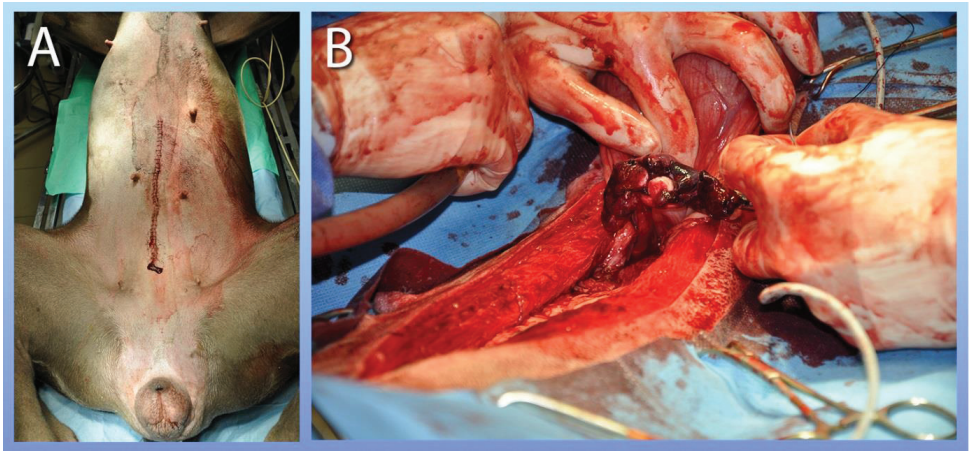

Figure 4.1 Hemorrhagic discharge from the suture line after ovariohysterectomy in a Great Dane warranted revision surgery (A). Bleeding uterine arteries where found and ligated (B).

Figure 4.2 Vaginal bleeding in a Golden Retriever after ovariohysterectomy.

The advantage of ligating the uterine vessels at the uterine horn tip and transection at the proper ligament is that the uterine horn lumen is not opened and the serosa remains intact. Bleeding from the vulva in the first week after surgery cannot occur. The only case in which one of the authors has observed a dog with vaginal bleeding after OVE was when the surgeon transected the uterine horn (and thus opened the lumen).

Ligation of the ureter

Direct obstruction of a ureter occurs when the ureter is accidentally included in a ligature (Fig 4.3). For instance, if the pedicle is ligated too close to its base at the abdominal wall, because of inadequate exposure of the caudal pole of the kidney, the proximal aspect of the ureter may be incorporated.[20] More often the distal part of the ureter is involved because of its close location to the uterine body. Inadvertent, suture-associated occlusion of the distal ureter is more common if a distended urinary bladder displaces the trigone cranially.[20] Okkens et al reported complications after OVH in 109 dogs, admitted over a 2-year-period (1977-1979) at Utrecht University, The Netherlands.[8] Among these dogs, 18 had signs related to the urinary system. Direct ligation of the ureter was observed at the ovarian pedicle in 2 dogs (11%) and at the distal ureter by uterine ligature in 3 dogs (17%). It is evident that the risk for ligation of the proximal ureter during OVE is identical to the OVH technique, but distal ureteral ligation is nonexistent during OVE.

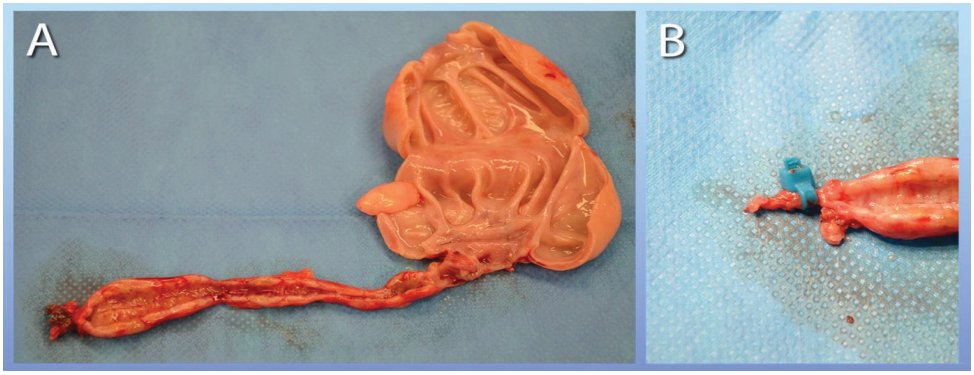

Figure 4.3 Hydroureter and hydronephros in a dog (A) due to inappropriate suture material (detail of the responsible cable tie - B) that was intended for uterine stump occlusion, but ended up incorporating the ureter.

Ovarian remnant syndrome

Recurrent estrus occurs after OVE or OVH when the ovaries are incompletely removed and residual ovarian tissue becomes functional (Fig 4.4). Collateral circulation to the ovarian tissue can develop even though the ovarian arteriovenous complex has been ligated and interrupted.[3] In dogs, neither ectopic ovaries (ovarian tissue in an abnormal location such as in the mesentery), nor accessory ovarian tissue extending into the ligament of the ovary have been reported, in contrast to their occurrence in cats, cows, and humans.[11,24]

Figure 4.4 A 9-year-old Pug with right-sided ovarian remnant tissue.

Pearson described 12 dogs with recurrent estrus in a group of 72 dogs with complications after OVH (17%).[23] Okkens et al reported 109 dogs with complications after OVH, of which 55 dogs had complications of a gynecologic nature; residual ovarian tissue was observed in 47 dogs (43%).[9] Of these dogs, 16 had bilateral, 25 right-sided, and 6 left-sided residual ovarian tissue. Ovarian remnants tend to be more commonly located on the right side. This higher frequency of right-sided ovarian remnants has been observed by others and is likely explained by a more cranial and deeper anatomic location of the right ovary, decreasing the ease of observation and removal.[23,25] When performing OVE, the surgeon is placing 2 cuts close to the ovary (ovarian pedicle and proper ligament). One could argue, but

this remains speculative, that there is an increased risk for ovarian remnants with OVE in comparison with OVH (where only 1 cut is made close to the ovary); however, this cannot be confirmed by literature review.

Most ovarian remnants occur after OVH.[8,9,23-25] This may be because OVH is the more commonly performed technique or because the celiotomy for OVH is located more caudally making observation of the (right) ovary more difficult. Decreased visualization enhances the risk for incorrect technique and the risk for ovarian remnants.[10] In OVE, the incision can be positioned more cranial, avoiding this problem. Ovarian remnant syndrome can be avoided by correct surgical technique regardless of the technique used. It is essential to have the incision cranial enough to allow complete visualization, especially of the right ovary. To achieve this with OVH a larger incision is necessary than for OVE.

Stump granuloma

Inflammation and granuloma formation can be caused by ligatures of non-absorbable suture material, poor aseptic technique, or excessive residual devitalized tissue (at the uterine body) (Fig 4.5). Braided non-absorbable suture materials, such as silk, nylon, or linen, and nonsurgical self-locking nylon bands (cable ties) have been implicated in most patients.[26] Okkens et al reported granulomas at the ovarian pedicle in 1 patient (6%) and at the uterine stump in 5 patients (28%).[8] In dogs with gynecologic complications after OVH, Okkens et al observed 8 dogs (15%) with stump granuloma.[9] The likelihood for development of a granuloma at the ovarian stump is not influenced by technique (OVE versus OVH), but the incidence of the more common granuloma at the uterine stump is eliminated with OVE. Granulomas at the uterine horn tip are possible, but to our knowledge, have not been described.

Fistulous tracts extending from the ligated ovarian pedicle can develop from inflammatory reaction to ligature material, primarily with braided non-absorbable suture material. Ovarian pedicle granulomas were associated with sublumbar sinuses.[20] Pearson described 72 dogs with complications resulting from OVH at a time when non-absorbable ligatures were routinely used, and reported 37 dogs with stump granuloma, of which 27 had

sinus formation (38%).[23] In a report of 20 OVH-related fistulous tracts, the origin of the tract was unilaterally from an ovarian ligature in 12 animals and from the uterine ligature in 4 animals.[5] Suture-associated fistulous tracts can easily be prevented by the use of synthetic absorbable suture materials but the surgical approach (OVE, OVH) should have no influence on the occurrence of fistulous tracts.[26]

Both OVE and OVH can result in fistulous tract formation from the ovarian stump. OVE technique might lead to formation of stump fistulas at the uterine horn tip; whereas, OVH technique has the additional risk for development of uterine stump fistulas. Both the uterine horn tip granuloma and the uterine horn tip fistula, however, can be prevented when correct OVE technique is used. Using correct technique, the uterine horn is not opened because transection is performed at the level of the proper ligament.

Figure 4.5 Granuloma formation at the uterine stump.

Miscellaneous

Many incidental complications after gonadectomy techniques including trauma to intestines or spleen, colonic incarceration,[23,27] failure to remove gauze sponges from the

abdomen before closure, endocrine alopecia, juvenile vulva formation, behavioral change, and eunuchoid syndrome have been reported.[5] It seems unlikely that either technique will significantly increase the risk for any of these complications. Because OVE results in a smaller incision, complications such as incisional swelling, seroma, infection, dehiscence, delayed healing, ventral body wall dehiscence, self-inflicted trauma, and pain are expected to be less.

Long-term complications and uterine pathologies

When considering changing the routine neutering procedure from OVH to OVE, the importance of future complications and uterine pathology needs to be considered (Table 4.2). In particular, development of endometritis/pyometra, occurrence of neoplastic uterine changes, incontinence, and obesity should be considered.

Table 4.2 Long-term development of complications and uterine pathology

Group	Endometritis/pyometra		Stump pyometra and CEH (ovarian remnant syndrome)			Uterine tumor formation	Urinary sphincter mechanism incontinence		
intact bitches	23% 15% 15%	(1800/200000)[28] (25/165)[29] (26/175)[30]	_			0.003%[33]		0.3% 0.2% 0.7% 1.3%	(7/2,434)[20] (10/5,315)[36] (29/4,382)[36] (34/2,614)[36]
							UD D		
ove	0% 0%	(0/69)[6] (0/72)[7]						9% 21%	(6/69)[6] (54/260)[45]
ovh	0%	(0/66)[6]	SP CEH	35% 43%	*(19/55)*[9] *(47/109)*[9]	_		14% 3% 18% 20% 19%	(9/66)[6] (53/1681)[36] (296/1,681)[36] (83/412)[38] (29/152)[45]

CEH: Cystic endometrial hyperplasia; UD: undocked; D: docked; OVE: ovariectomy; OVH: ovariohysterectomy; SP: stump pyometra. *Italic:* relative numbers, percentages based on dogs with complications.

Endometritis and pyometra

Epidemiologic data for ~ 200,000 dogs covered by insurance in Sweden revealed that 1,800 non-spayed bitches were treated for pyometra in 1996. The risk of an intact bitch developing pyometra before 10 years of age was 23 - 24%.[28] Other studies, albeit on a smaller scale, had similar findings. Fukuda reported a 15.2% chance for the development of pyometra in female dogs > 4 years (n = 165).[29] Von Berky reported a 14.9% chance for uterine disease (n = 175).[30]

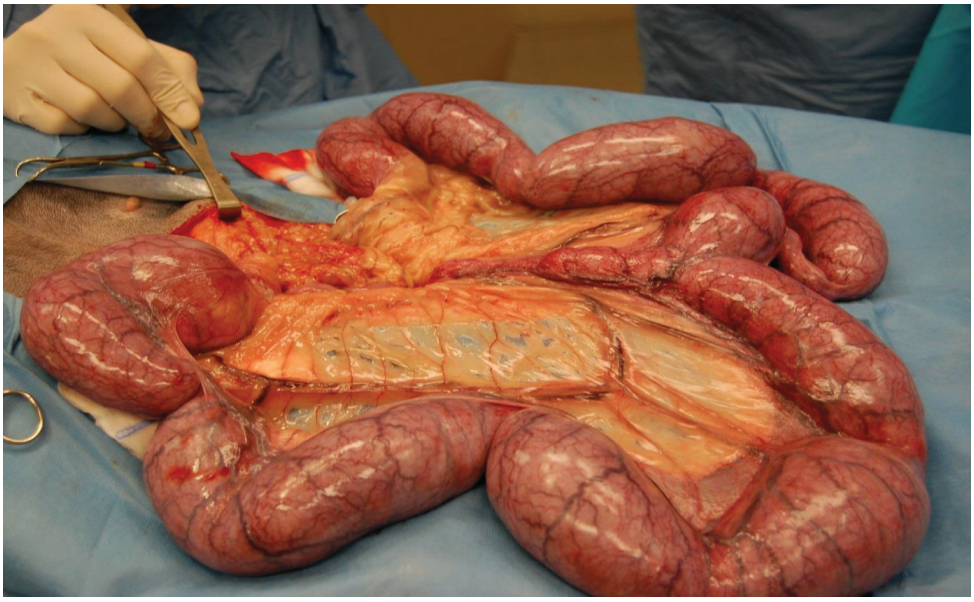

Figure 4.6 A 2.7 kg pyometra in a Bernese Mountain dog.

Thus, it is important to determine whether the uterus in ovariectomized dogs is predisposed to develop endometritis and pyometra (Fig 4.6). Pyometra has been defined as a hormonally mediated diastral disorder resulting from bacterial interaction with an abnormal uterine endometrial that has undergone pathologic changes assumed to be caused by an exaggerated response to progesterone stimulation.[31] Recently, the concept of considering CEH-pyometra as a complex has been questioned. It has been suggested that 2 different disorders: one where CEH-endometritis appears to have a strong hormonal component and the other where pyometra might be more influenced by the bacterial component.[28]

Nevertheless, both conditions are exclusively encountered in the luteal phase of the estrus cycle. Experimentally CEH or CEH-endometritis can be induced by administration of progesterone, even in ovariectomized bitches.[20] Withdrawal of progesterone treatment causes regression of the naturally occurring disease. Thus exposure to progestogens appears to be necessary for the development of CEH-endometritis.

A study by Okkens et al, comparing the long-term effects of OVE versus OVH, was conducted at Utrecht University in 1997.[6] Questionnaires were sent to 264 owners of bitches that had either OVE (n = 126) or OVH (n = 138) performed for routine neutering 8 - 11 years earlier. Complete data were obtained for 69 OVE bitches and 66 OVH bitches. None of the OVE bitches had signs consistent with having had endometritis. With the exception of urinary incontinence, no other problems related to surgical neutering were identified. These findings agree with those of Janssens who performed OVE on 72 bitches and after a 6 - 10 year follow-up, no pyometra was detected.[7] When OVE is correctly performed (all ovarian tissue removed), and in the absence of supplementation of exogenous progestogens, endometritis (CEH or pyometra) cannot occur.

Stump pyometra is uniquely associated with OVH, and can develop if endometrial tissue at the uterine stump is stimulated by either endogenous, because of incomplete ovarian tissue removal, or by exogenously administered progesterone.[20] In Okkens et al's report on 55 dogs with gynecologic complications after OVH, 19 dogs (35%) had stump pyometra associated with residual ovarian tissue.[9] In the same study 47 bitches had histologically confirmed CEH-endometritis during celiotomy; abdominal exploration revealed the presence of residual ovarian tissue in all of these dogs. Another 7 dogs had an enlarged and inflamed uterine stump, where no residual ovarian tissue was detected and on histology the inflammation was caused by an unabsorbed ligature (stump granuloma) without signs of CEH.[9]

These studies strongly suggest that progesterone is an essential factor in the occurrence of CEH-endometritis-pyometra. Ovariectomy will not increase the risk for the development of CEH-pyometra compared to OVH. When correctly performed, both OVH and OVE will prevent the development of CEH-pyometra in later life.

Uterine tumor formation

Uterine tumors are rare in the dog, with a reported rate of 0.4% of all canine tumors.[32] The University of Pennsylvania Veterinary Hospital examined 33,570 female dogs between 1952-1966, and 96 gynecologic neoplasms (uterus, n = 11; vagina or vulva, n = 85) were detected in 90 dogs (0.27%).[33] This brings the overall chance for a uterine tumor to 0.03% (11/33,570). Middle-aged and older animals were most commonly affected and most canine uterine tumors were mesenchymal in origin. Of the uterine tumors, 85 - 90% were benign leiomyomas and 10% leiomyosarcomas (Fig 4.7). The true risk for development of malignant tumoral disease of the uterus is therefore 0.003%. The prognosis associated with leiomyomas and other benign tumors is excellent, since surgery is nearly always curative. For leiomyosarcomas and other malignant tumors, the prognosis remains good if there is no evidence of metastatic disease at surgery and complete excision is possible.[32,34,35] When performing gonadectomy, the surgeon has to balance the risk for possible tumoral development in the uterus (in case of OVE), against the increase in surgery related complications (in case of OVH).

Figure 4.7 A leiomyosarcoma of the uterine body in a Jack Russel Terrier.

Urinary sphincter mechanism incontinence

Adhesions or granulomas of the uterine stump that interfere with urinary bladder sphincter function or development of a ureterovaginal fistula can occasionally cause incontinence. The most common cause of incontinence in spayed dogs, however, is urethral sphincter mechanism incompetence (USMI) (Fig 4.8). This is an uncommon disease in intact bitches with reported incidences of only 0.2% (10/5,315)[36] to 0.3% (7/2,434).[20] Because of the underlying hormonal cause, a significant increase of this pathology in spayed bitches has been hypothesized.[37,38] Nickel et al reported a significantly impaired urethral sphincter mechanism in gonadectomized dogs.[39] In their retrospective investigation, Holt and Thrusfield used data from a primary care and a referral practice in the United Kingdom, and reported that respectively 3% (53/1,681) and 17.7% (296/1,681) of dogs were considered incontinent after OVH.[36] In a study performed in Switzerland, up to 20% (83/412) of the spayed bitches developed signs suggestive of urinary incontinence postoperatively.[38]

Figure 4.8 Urinary incontinence, as evidenced by the discolored hair coat, in a spayed Maltese Dog.

Confounding factors in the development of incontinence include age of OVH, body weight, breed of dogs and tail-docking.[5,36,40-43] An increased risk in tail-docked bitches has been documented raising the incidence to 1.3 (34/2,614) compared to 0.7% (29/4,382) for undocked dogs.[36]

Long-term studies have been unable to detect a difference between the occurrences of incontinence in dogs after OVE compared to OVH. One of the initial reports concluded that there was no difference between OVE and OVH.[44] Another study found no statistical difference between OVE dogs that developed incontinence, namely 54/260 (20.8%) compared to OVH dogs that developed incontinence 29/152 (19.1%).[45] Okkens et al reported urinary incontinence in 15 dogs (11%) after long-term follow-up, but no significant difference in incidence between OVE and OVH neutered bitches.[6]

Body weight gain

Gonadectomy adversely affects the ability to regulate food intake and thus predisposes these animals to obesity.[20,46] Inactivity and increased food intake contributes to weight gains up to 38%. Edney and Smith observed that 21.4% of all dogs were overweight and spayed females were twice as likely to be obese compared to intact bitches.[47] In another study, where dogs were exercised regularly and their food intake was controlled, there was no significant increase in weight between spayed and intact females.[48] No significant difference in weight gain has been observed between dogs that had OVE versus OVH in other studies.[49,50]

Conclusion

The absence of randomized studies comparing complications after OVE and OVH in dogs forces us to interpret historical reviews of both techniques. The rational conclusion after review, when immediate postoperative complications are considered, is that either technique can be used for canine female gonadectomy. The surgeon has to choose the least invasive, fastest, and safest procedure. A major advantage of OVE is that it can be performed through

a smaller celiotomy incision and with less traction on the female genital tract. Technically, OVH is more complicated (more tissue is ligated and transected), time consuming (because a larger celiotomy is needed to expose the entire female tract) and is therefore expected to be associated with a greater short-term morbidity when compared to OVE. However, differences in short-term postoperative morbidity between the two techniques have not been published. Increased risk for surgery-related complications associated with OVH are suspected for: intra-abdominal and vaginal bleeding (because of the larger vessel diameter near the uterine body), ureteral ligation (because of the close proximity of the distal part of the ureter to the uterine body), ovarian remnants (because of the more caudally located celiotomy incision), uterine stump complications, and sinus tracts (because of mucosal exposure).

Since 1981, after introduction of OVE as the standard technique for canine neutering at Utrecht University, no increase in short-term complications has been observed. With respect to long-term urogenital problems, including endometritis/pyometra and urinary incontinence, it has been clearly established that they do not occur more frequently with either technique. The overall chance for development of malignant uterine tumors is very low (0.003%), and, in our opinion, does not warrant performing a potentially more traumatizing surgical procedure (OVH) that might be associated with more postoperative complications.

Without benefit of more prospective studies comparing surgical complications between OVE and OVH, most evidence extracted from the literature leads us to the conclusion that there is no benefit, and thus no indication, for removing the uterus during routine neutering in healthy bitches. Therefore we believe that OVE should be the procedure of choice for canine gonadectomy.

References

1. Stockner PK: The economics of spaying and neutering - market forces and owners values affecting pet population-control. J Am Vet Med Assoc 1991;198:1180-1182.
2. Nassar R, Fluke J: Pet population-dynamics and community-planning for animal-welfare and animal control. J Am Vet Med Assoc 1991;198:1160-1164.

3. Fingland RB: Ovariohysterectomy, in Current techniques in small animal surgery (4th ed), Baltimore, MD, Williams & Wilkins, 1998, pp 489-496.
4. Hedlund CS: Surgery of the reproductive and genital systems, in Fossum TW (ed): Small animal surgery (1st ed), Vol 1, St. Louis, MO, Mosby-Year Book Inc., 1997, pp 523-524, 536-537.
5. Stone AE, Cantrell CG, Sharp NJ: Ovary and uterus, in Slatter D (ed): Textbook of small animal surgery (2nd ed), Vol 2., Philadelphia, PA, Saunders, 1993, pp 1293-1308.
6. Okkens AC, Kooistra HS, Nickel RF: Comparison of long-term effects of ovariectomy versus ovariohysterectomy in bitches. J Reprod Fertil 1997:227-231.
7. Janssens LAA, Janssens GH: Bilateral flank ovariectomy in the dog - surgical technique and sequelae in 72 animals. J Small Anim Pract 1991;32:249-252.
8. Okkens AC, vd Gaag I, Biewenga WJ, Rothuizen J, Voorhout G: Urological complications following ovariohysterectomy in dogs. Tijdschr Diergeneeskd 1981;106:1189-1198.
9. Okkens AC, Dieleman SJ: Gynecologic complications following ovariohysterectomy in dogs, due 1. partial removal of the ovaries, 2. inflammation of the uterocervical stump. Tijdschr Diergeneesk 1981;106:1142-1158.
10. Berzon JL: Complications of elective ovariohysterectomies in the dog and the cat at a teaching institution: clinical review of 853 cases. Vet Surg 1979;8:89-91.
11. Stone AE: Ovary and uterus, in Slatter D (ed): Textbook of small animal surgery, Vol 2, Philadelphia, PA, Saunders, 2003, pp 1495-1499.
12. Van Sluijs FJ: Ovariohysterectomy, in Van Sluijs FJ (ed): Atlas of small animal surgery, Vol 1, Utrecht, The Netherlands, Wetenschappelijke uitgeverij Bunge, 1992, pp 82-84.
13. Toombs JP, Clarke KM: Basic operative techniques, in Slatter D (ed): Textbook of small animal surgery, Vol 1., Philadelphia, PA, Saunders, 2003, pp 208-212.
14. Wheeler SL, Magne ML, Kaufmann J: Postpartum disorders in the bitch: a review. Compend Cont Educ Vet 1984;6:493.
15. Schneider R, Dorn CR, Taylor DO: Factors influencing canine mammary cancer development and postsurgical survival. J Natl Cancer Inst 1969;43:1249-1261.
16. Sorenmo KU, Shofer FS, Goldschmidt MH: Effect of spaying and timing of spaying on survival of dogs with mammary carcinoma. J Vet Intern Med 2000;14:266-270.
17. Philibert JC, Snyder PW, Glickman N, Glickman LT, Knapp DW, Waters DJ: Influence of host factors on survival in dogs with malignant mammary gland tumors. J Vet Intern Med 2003;17:102-106.
18. Morris JS, Dobson JM, Bostock DE, O'Farrell E: Effect of ovariohysterectomy in bitches with mammary neoplasms. Vet Rec 1998;142:656-658.
19. Yamagami T, Kobayashi T, Takahashi K, Sugiyama M: Prognosis for canine malignant mammary tumors based on TNM and histologic classification. J Vet Med Sci 1996;58:1079-1083.
20. Kyles AE, Aronsohn M, Stone EA: Urogenital surgery, in Lipowitz AJ (ed): Complications in small animal surgery, Baltimore, MD, Williams & Wilkins, 1996, pp 496-503.
21. Wilson GP, Hayes HM: Ovariohysterectomy in the dog and cat, in Bojrab MJ (ed): Current techniques in small animal surgery, Philadelphia, PA, Lea & Febinger, 1983, pp 334-338.
22. Pollari FL, Bonnett BN, Bamsey SC, Meek AH, Allen DG: Postoperative complications of elective surgeries in dogs and cats determined by examining electronic and paper medical records. J Am Vet Med Assoc 1996;208:1882-1886.
23. Pearson H: The complications of ovariohysterectomy in the bitch. J Small Anim Pract 1973;14:257-266.

24. Miller DM: Ovarian remnant syndrome in dogs and cats - 46 cases (1988-1992). J Vet Diagn Invest 1995;7:572-574.
25. Wallace MS: The ovarian remnant syndrome in the bitch and queen. Vet Clin North Am Small Anim Pract 1991;21:501-507.
26. Werner RE, Straughan AJ, Vezin D: Nylon cable band reactions in ovariohysterectomized bitches. J Am Vet Med Assoc 1992;200:64-66.
27. Coolman BR, Marretta SM, Dudley MB, Averill SM: Partial colonic obstruction following ovariohysterectomy: a report of three cases. J Am Anim Hosp Assoc 1999;35:169-172.
28. Fransson BA, Ragle CA: Canine pyometra: an update on pathogenesis and treatment. Compend Cont Educ Vet 2003;25:602-611.
29. Fukuda S: Incidence of pyometra in colony-raised beagle dogs. Exp Anim 2001;50:325-329.
30. Von Berky AG, Townsend WL: The relationship between the prevalence of uterine lesions and the use of medroxyprogesterone acetate for canine population-control. Aust Vet J 1993;70:249-250.
31. Nelson RW, Feldman EC: Pyometra. Vet Clin North Am Small Anim Pract 1986;16:561-576.
32. Klein MK: Tumors of the female reproductive system, in Withrow SJ, Vail DM (eds): Small animal clinical oncology, Saunders, St. Louis, 2007, pp 610-618.
33. Brodey RS, Roszel JF: Neoplasms of the canine uterus, vagina, and vulva: a clinicopathologic survey of 90 cases. J Am Vet Med Assoc 1967;151:1294-1307.
34. Vos JH: Uterine and cervical carcinomas in five dogs. J Vet Med 1980;35:385-390.
35. Ogilvie GK, Moore AS: Tumors of the reproductive system, in Managing the Veterinary Care Patient, New Jersey, Veterinary Learning Systems Co., Inc., 1995, pp 419-420.
36. Holt PE, Thrusfield MV: Association in bitches between breed, size, neutering and docking, and acquired urinary-incontinence due to incompetence of the urethral sphincter mechanism. Vet Rec 1993;133:177-180.
37. Thrusfield MV: Association between urinary-incontinence and spaying in bitches. Vet Rec 1985;116:695-695.
38. Arnold S: Harninkontinenz bei kastrierten Hundinnen. Teil 1: Bedeutung, Klinik und Atiopathogenese. Schweiz Arch Tierh 1997;139:271-276.
39. Nickel RF, van Wees AM, van den Brom WE: Studies on the function of the urethra and bladder in continent and incontinent female dogs. Chapter 7: Changes in urethral closure and bladder storage function in young female dogs caused by prepubertal events, the estrous cycle, and neutering. Utrecht University, 1998.
40. Janssens LAA, Peeters S: Comparisons between stress incontinence in women and sphincter mechanism incompetence in the female dog. Vet Rec 1997;141:620-625.
41. White RN: Urethropexy for the management of urethral sphincter mechanism incompetence in the bitch. J Small Anim Pract 2001;42:481-486.
42. Blendinger C, Blendinger K, Bostedt H: Die Harninkontinenz nach Kastration bei der Hundin. 1. Mitteilung: entstehung, Haufigkeit und Disposition. Tierarztl Prax K H 1995;23:291-299.
43. Spain CV, Scarlett JM, Houpt KA: Long-term risks and benefits of early-age gonadectomy in dogs. J Am Vet Med Assoc 2004;224:380-387.
44. Ruckstuhl B: Die Incontinentia Urinae bei der Hundin als Spatfolge der Kastration. Schweiz Arch Tierh 1978;120:143-148.
45. Arnold S, Arnold P, Hubler M: Die Incontinentia Urinae bei der Hundin als Spatfolge der Kastration. Schweiz Arch Tierh 1989;120:143-148.

46. Salmeri KR, Olson PN, Bloomberg MS: Elective gonadectomy in dogs: a review. J Am Vet Med Assoc 1991;198:1183-1192.
47. Edney ATB, Smith PM: Study of obesity in dogs visiting veterinary practices in the united-kingdom. Vet Rec 1986;118:391-396.
48. Le Roux PH: Thyroid status, oestradiol level, work performance and body mass of ovariectomised bitches and bitches bearing ovarian autotransplants in the stomach wall. J S Afr Vet Assoc 1983;54:115-117.
49. Houpt KA, Hintz HF: Obesity in dogs. Canine Pract 1978;5:54-58.
50. Houpt KA, Coren B, Hintz HF, Hilderbrant JE: Effect of sex and reproductive status on sucrose preference, food-intake, and body-weight of dogs. J Am Vet Med Assoc 1979;174:1083-1085.

5

The effect of neuromuscular blockade on canine laparoscopic ovariectomy: a double-blinded, prospective clinical trial

Van Goethem B, van Nimwegen SA, Akkerdaas I, Murrell JC, Kirpensteijn J

Vet Surg 2012;41(3):374-380.

Department of Clinical Sciences of Companion Animals, Faculty of Veterinary Medicine, Utrecht University, Yalelaan 108, P.O. Box 80154, NL-3508 TD Utrecht, The Netherlands

Abstract

Objective: To evaluate the effect of neuromuscular blockade (NMB) on surgical time and various anesthetic variables during laparoscopic ovariectomy in dogs.

Study Design: Prospective, double-blinded, randomized clinical trial.

Animals: Female dogs (n = 40).

Methods: Laparoscopic ovariectomy using bipolar electrocoagulation was performed by 1 surgeon using a standardized protocol, where 1 ovary was removed under NMB, and the other without NMB. Surgical and anesthetic (respiratory and circulatory) variables were recorded for predetermined procedural stages and were statistically evaluated.

Results: Mean total surgical time was 25.1 ± 6.3 minutes (range, 16 to 47 minutes). With NMB, mean duration of surgical excision of the ovary was not significantly changed compared to ovariectomy without NMB (NMB 5.7 ± 2.3 minutes versus no NMB 5.9 ± 1.9 minutes). Arterial blood pressure was the only recorded anesthetic variable that significantly changed under NMB (5% decrease). Occurrence of intraoperative complications did not differ. In obese dogs, total surgical time was increased by 22%. Other variables, including the occurrence of intraoperative mesovarial bleeding did not influence surgical duration.

Conclusions: NMB did not significantly improve laparoscopic ovariectomy times and except for a 5% decrease in arterial blood pressure did not change any of the evaluated anesthetic and surgical variables.

Introduction

The effects of abdominal insufflation with carbon dioxide and the Trendelenburg position (head down tilt) on cardiovascular and respiratory variables during anesthesia have been reported in dogs.[1] Detrimental effects elicited by pneumoperitoneum (e.g., decreased cardiac output, increased abdominal vascular resistance, increased intra-thoracic pressure and impaired organ perfusion) are typically evident at intra-abdominal pressures of 16 mm Hg in healthy dogs, but are not apparent at 8 or 12 mm Hg.[2] High peritoneal CO_2 pressures (15 and 25 mm Hg) in dogs should therefore be avoided.[3,4] Ozmen et al have also noted an increased proinflammatory cytokine and free radical production in rabbits with increased abdominal pressure during laparoscopy.[5] The only possible temporary clinical application of high abdominal pressure in dogs is to promote spontaneous hemostasis in splenic capsule lacerations.[6] In human laparoscopy, low-pressure pneumoperitoneum is considered to be advantageous in terms of postoperative pain, use of analgesics, preservation of pulmonary function, and hospital stay; nevertheless surgeons experience more difficulty when working in a low-pressure abdomen.[7] Veterinary laparoscopy is currently carried out using a balance between these factors between 4 - 12 mm Hg.[2,8]

Trendelenburg position, aiming to improve surgical field by cranial displacement of abdominal organs, further increases intra-thoracic pressure by weight on the diaphragm (impairs tidal volume, pulmonary compliance and minute volume of ventilation) and governs cardiovascular effects by activation of baroreceptor reflexes (vasodilatation, reduced heart rate, cardiac output, stroke volume, contractility, arterial blood pressure and perfusion).[3]

Neuromuscular blocking drugs are commonly used in human laparoscopic surgery because muscle relaxation causes a more flaccid and stretchable abdominal wall.[9] This eliminates the need for high pneumoperitoneum pressures to improve surgical conditions. Although the concern exists that muscle flaccidity under neuromuscular blockade (NMB) would potentially make trocar placement more difficult, data suggests that the adequacy of the pneumoperitoneum for trocar placement is better in people receiving NMB therefore necessitating less trocar placement attempts.[10] A study in pigs however questions the efficacy of NMB and suggest that it does not significantly affects laparoscopic procedures.[11]

Our objective was to examine the effect of NMB on surgery time in dogs. We hypothesized that keeping the abdominal pressure at a fixed level, surgical duration would be shorter because of improved ease in searching the ovaries and performing the ovariectomy because of the larger working space induced by the flaccid abdominal wall. Additionally, the effect of NMB on certain cardiovascular and respiratory variables was evaluated for potential changes. Other variables previously reported to possibly influence surgical time, such as age, weight and obesity, estrus or pseudopregnancy, ovarian accessibility and mesovarial bleeding were evaluated.[12,13]

Materials and methods

Groups

Before recruitment of dogs (n = 40) they were randomly assigned to 1 of 2 groups. We used female dogs admitted for elective ovariectomy and weighing 10 - 40 kg. All owners signed an informed consent before study entry. Only dogs with normal anatomy of the uterus and ovaries during laparoscopic evaluation remained in the study. No dogs were excluded. As this was a routine surgical procedure on normal dogs, no selection bias was present. In group 1, the left ovary was removed under NMB, and the right ovary removed in the absence of NMB. In group 2, the left ovary was removed in the absence of NMB and the right ovary removed under NMB. With this experimental design possible differences in surgery time because of the position of the ovary and order of excision were randomized and each dog acted as its own control when comparing surgical and anesthetic variables for NMB.

A standard questionnaire was completed before surgery. Questions included dog age, number of estrus cycles, date of last estrus, presence of pseudo-pregnancy, general health and vaccination status. A body condition scoring system, ranging from 1 (thin) to 5 (obese) was used to objectively differentiate obese from non-obese dogs.[14]

Surgical technique

All surgeries were performed by the same surgeon (JK) who was blinded to the administration of NMB. Dogs were positioned in 10° Trendelenburg and the table was laterally tilted depending on the side of interest. A standard midline laparoscopic approach was performed using 3 portals.[12] Abdominal insufflation pressure was maintained at 8 - 10 mm Hg. Two 5 mm trocar-cannulae and one 10 mm trocar-cannula device (Surgiport disposable trocar, Auto Suture, United States Surgical Corporation, Norwalk, CT) were placed. A 5 mm 0° telescope (Hopkins II, Karl Storz-Endoscopy, the Netherlands) was introduced and the abdomen was inspected. Two grasping forceps (Endo dissect 5 mm and Endo Clinch II 5 mm, United States Surgical Corporation) were used to locate and mobilize the ovarian bursa. Both ovaries were removed with a bipolar technique as described in earlier reports.[8] After ovariectomy, the left ovary was placed next to the bladder (for easy retrieval later) and the procedure was repeated for the right ovary. In between transection of the left and right ovary a 10-minute break was held to allow for NMB reversal or induction.[15] During this time the surgeon left the room to remain blinded for presence of NMB. After the 2nd ovariectomy, both ovaries were gently removed through the caudal portal. Carbon dioxide was evacuated from the abdomen and the portal incisions were closed routinely.

Anesthetic technique

All dogs were anesthetized using a standard protocol. After premedication with medetomidine (1.5 mg/m^2 intravenously [IV]), anesthesia was induced with propofol (1 - 2 mg/kg IV to effect) and maintained with isoflurane vaporized in a 50/50 mixture of oxygen and air (1 - 2 L/min). After connection to a circle breathing system, volume controlled automatic intermittent positive pressure ventilation (IPPV) was started. An initial tidal volume of 10 mL/kg was chosen and a respiratory rate of 12 breaths/min. The tidal volume or respiratory rate were manually adjusted to maintain an end-tidal carbon dioxide concentration ($ETCO_2$) between 5.2 - 5.7 kPa, while airway pressure remained < 20 cm H_2O. Once $ETCO_2$ was stabilized the ventilation variables were not adjusted further. An 18 or 20 gauge cannula was placed in the right femoral artery and connected to a pressure transducer (Gabarith PMSET 1 DT-XX ROSE; Becton Dickinson Critical Care Systems, Singapore) for arterial blood pressure

monitoring. Arterial blood pressure measurement, electrocardiography (lead II) (S/5 ECG Module; Datex Ohmeda Division Instrumentarium Corporation, Helsinki, Finland), and esophageal temperature measurement (Datex central temperature probe; Datex Ohmeda) were carried out continuously during the procedure. Body temperature was supported using a circulating warm waterbed and a heat-and-moisture exchanger (Humid-Vent, Gibeck, Teleflex Medical BV, Hilversum, the Netherlands) placed between the anesthesia breathing system and endotracheal tube.

Airway gases were sampled continuously from the circuit end of the endotracheal tube. Isoflurane, oxygen and carbon dioxide were measured using an infrared monitor (S/5 Compact Airway modules, Datex-Ohmeda). End tidal isoflurane concentration (ETiso) was adjusted according to clinical assessment of anesthetic depth. ETiso was stabilized during the surgical approach to the ovary, the concentration was maintained constant during removal of both ovaries. IV fluid therapy was provided throughout anesthesia with Ringer's lactate solution (5 mL/kg/hr). According to standard anesthetic protocols at Utrecht University, medetomidine 0.75 mg/m^2 IV was repeated 1 hour after premedication.

On the completion of surgery carprofen (4 mg/kg IV) and buprenorphine (10 µg/kg intramuscularly [IM]) were administered for postoperative analgesia. IPPV was discontinued and ventilation supported until spontaneous breathing resumed. Administration of isoflurane was continued until the dog breathed spontaneously. Atipamezole (3.75 mg/m2 IM; Antisedan, Pfizer Animal Health BV, Capelle aan de IJssel, the Netherlands) was administered at the start of the recovery period.

Neuromuscular blockade

The effect of the NMB was monitored using the train-of-four (TOF) technique.[16] The needle electrodes of a peripheral nerve stimulator (TOF-Guard, Oreganon Teknika, Turnhout, Belgium) placed subcutaneously over the left ulnar nerve were used to generate a stimulus in the flexor carpi ulnaris muscle. Four supramaximal stimuli of 10 mA and 0.2 seconds duration were delivered at 2 Hz over 2 s. Each TOF was repeated every 12 s. Disappearance of the twitch response to all 4 stimuli was considered to be complete NMB.

Group 1 dogs after abdominal insufflation had NMB induced with vecuronium-bromide (0.1 mg/kg IV, diluted to 5 mL with 0.9% NaCl). If complete NMB was not achieved with the initial dose a second dose of 0.05 mg/kg was supplemented. Before starting surgery on the second ovary, NMB was reversed with neostigmine (0.04 mg/kg IV) and atropine (0.02 mg/kg IV) combined in the same syringe and administered slowly. One twitch response to the TOF stimulator had to be present before pharmacological reversal was attempted. Return of neuromuscular function was defined as visual observation of 4 equal muscle twitches. After return of TOF response, at the end of the 10 minute break, 5 mL 0.9% NaCl IV (placebo vecuronium) was administered. TOF response was continually monitored during removal of the second ovary to ensure no recurrence of NMB occurred.

Group 2 dogs received placebo NMB (5 mL IV 0.9% NaCl) after abdominal insufflation. After removal of the first ovary a 10 minute break (placebo NMB reversal) was allowed before NMB was induced with vecuronium-bromide for surgery on the second ovary. Dose of vecuronium, definition of NMB, and conditions for start of surgery were as for group 1 dogs. NMB was reversed after removal of the second ovary. Protocol for reversal was identical to group 1 dogs.

Test variables

Procedure time was recorded using a stopwatch. Incision time was 00.00 and the following time points were recorded: insertion of the first trocar, start of searching for the left ovary (directly after insertion of all instruments), start excision of the left ovary, end excision of left ovary, start searching right ovary, start excision right ovary, end excision right ovary, start removal ovaries from abdomen, end removal ovaries from abdomen. Between the ‘end of excision of the left ovary’ and ‘start searching the right ovary’ a 10-minute standardized waiting period was introduced to eliminate NMB (group 1) or induce NMB (group 2).

The following anesthetic variables were monitored and recorded every 3 minutes during searching and excision of both ovaries: heart rate, respiratory rate, tidal volume, mean airway pressure, $ETCO_2$, ETiso, TOF response, ECG, arterial blood pressure (mean [MAP], systolic [SAP] and diastolic [DAP]) and body temperature. During surgery, the ease of access

to the ovaries, the amount of fat in the ovarian ligament (0 = none; 1 = minimal amount of fat; 2 = moderate amount of fat; and 3 = large amounts of fat),[17] and the occurrence of bleeding from the ovarian pedicle were recorded.

Follow-up

Dogs were sent home after recovery from anesthesia with instructions for postoperative care and administration of carprofen (2 mg/kg orally twice daily) for 3 days. The owner was contacted 10 days later and asked about outcome with a specific interest about wound healing. Questions pertained to signs of marked swelling, infection and slight wound dehiscence and were considered wound complications. Further questions concerned the number of days until complete recovery, activity and appetite.

Statistical analysis

To estimate the number of dogs needed, power analysis was carried out based on data from a previous study.[12] With an assumed mean difference between the 2 techniques of 1.5 minutes/ovary and a SD of 2.5 minutes/procedure, an α of 0.05 and a β of 0.15, 40 dogs were necessary. Differences in anesthetic variables as well as duration of searching and excision of the ovary under NMB versus no NMB and surgery duration for left and right ovary were evaluated using Student's t-test for paired samples. Differences between groups were evaluated by the χ^2 test for ordinal or ratio data and by Student's t-test for independent samples or 1 way ANOVA for interval data. Data are reported as mean ± SD, and $P < .05$ (2-tailed) was considered significant. Statistical analysis of data was performed with software (SPSS 11.5 for Windows, SPSS, Chicago, IL).

Results

Forty dogs were enrolled; consisting of 20 different breeds and 5 mixed breed dogs. Mean ± SD age was 2.3 ± 2.1 years (range, 7 months to 8.6 years). Mean bodyweight was 26.2 ± 6.8 kg (range, 10 to 40 kg). Fourteen dogs were considered to be obese. The 2 groups (NMB left and NMB right) did not differ for any of the following variables: age, bodyweight, number of estrus cycles, time since last estrus, pseudo-pregnancy, obesity score, fat score of the ovarian ligament, accessibility of the ovaries, occurrence of bleeding from the ovaries, and duration of the predetermined surgical intervals.

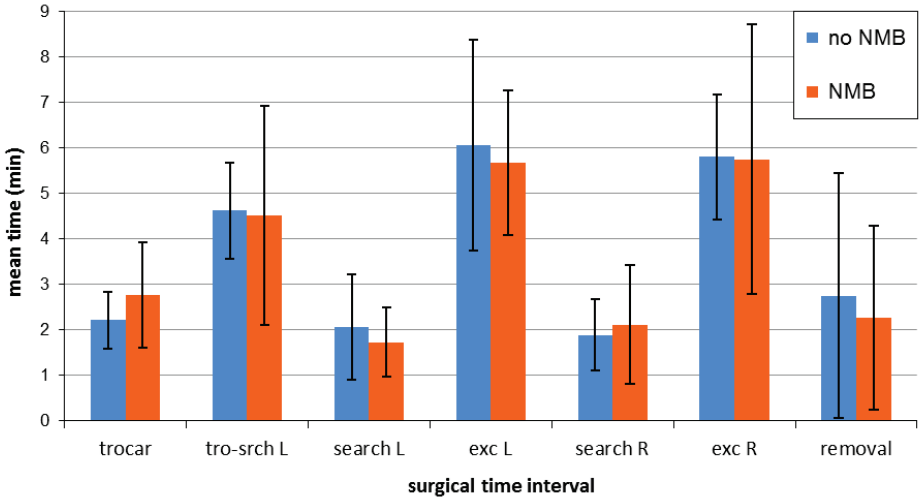

Figure 5.1 Duration of predetermined surgical time intervals (SD depicted by error bar) with neuromuscular blockade (NMB) and without (no NMB). Trocar: from skin incision to placement of first trocar. Tro-srch: from insertion of first trocar to the start of searching for the ovary. Search L: time from searching to grasping of the left ovary. Exc L: duration of excision of the left ovary. Search R: time from searching to grasping of the right ovary. Exc R: duration of excision of the right ovary. Removal: duration of removal of both ovaries from the abdomen (* *P* < .05).

Surgical times

NMB did not significantly affect any of the recorded surgery intervals (Figs. 5.1, 5.2). Procedural times to search the ovary with and without NMB was not significantly different (NMB 1.8 ± 1.0 minutes versus no NMB 2.1 ± 1.0 minutes). Times for excision of the ovary with and without NMB was also not significantly different (NMB 5.7 ± 2.3 minutes versus no NMB 5.9 ± 1.9 minutes). Total surgery time including the 10-minute break was 40 ± 8 minutes (range, 28 to 67 minutes). Exact surgery time (sum of all recorded surgery intervals) was 25.1 ± 6.3 minutes (range, 16 to 47 minutes). The latter was used for evaluation of the effect of intraoperative variables on surgical duration.

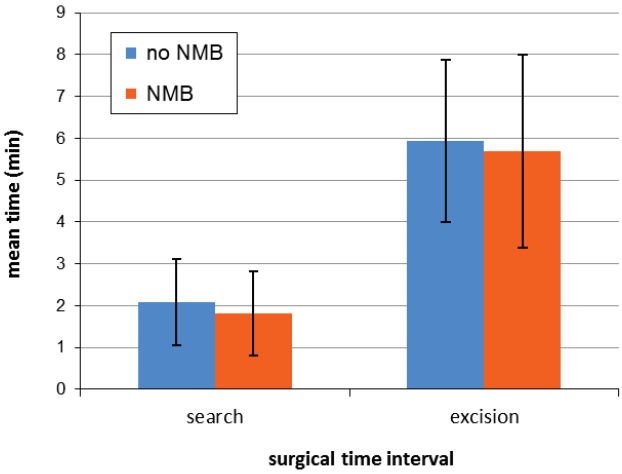

Figure 5.2 Surgical time intervals (SD depicted by error bar) for searching and excision of the ovary (combined data for left and right) with and without neuromuscular blockade (NMB) (* *P* < .05).

Anesthetic variables

Mean arterial pressure (MAP) showed a ~5% decrease during surgery under NMB (NMB 117.4 ± 12.3 mm Hg versus no NMB 123.8 ± 18.3 mm; *P* = .027; pooled values from Fig 5.3). Mean diastolic arterial pressure (DAP) showed the same ~5% decrease during surgery under NMB (NMB 105.3 ± 11.3 mm Hg versus no NMB 110.7 ± 17.2 mm Hg; *P* = .048; pooled values from Fig 5.4.). Systolic arterial pressure (SAP) was not significantly different with NMB versus without NMB (NMB 157.6 ± 17.3 mm Hg versus no NMB 161.0 ± 19.6 mm Hg; pooled values).

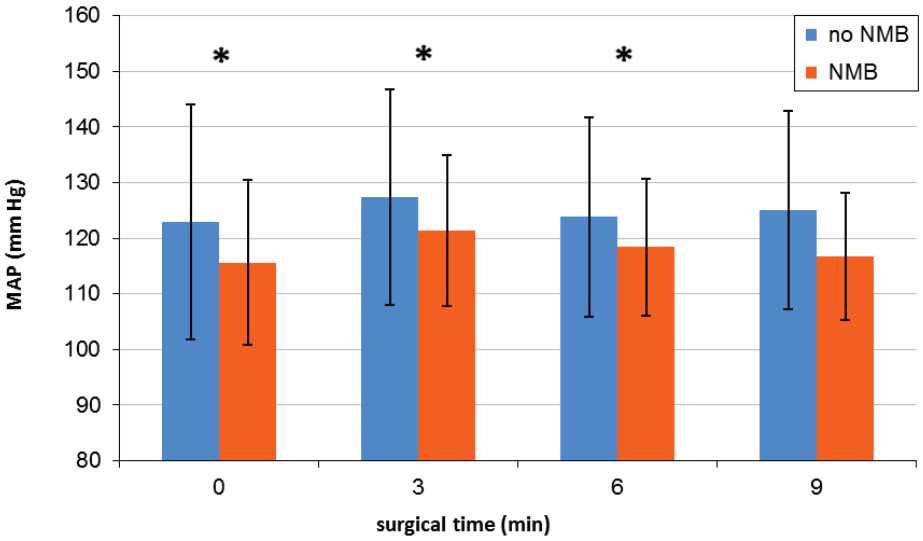

Figure 5.3 Mean arterial blood pressure (MAP) with neuromuscular blockade (NMB) compared to surgery without NMB (no NMB), measured every 3 minutes during searching and excision of the ovary (* $P < .05$).

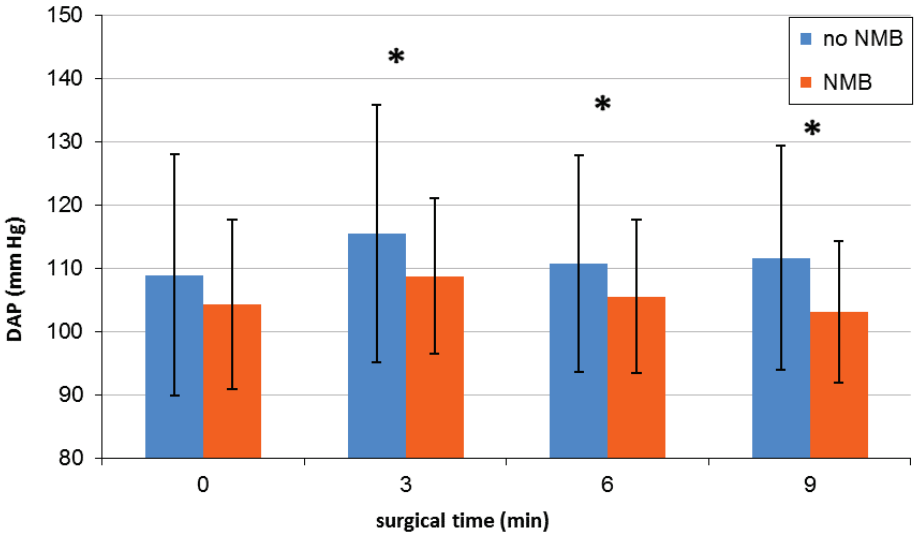

Figure 5.4 Diastolic arterial blood pressure (DAP) during surgery with neuromuscular blockade (NMB) compared to surgery without NMB (no NMB), measured every 3 minutes during searching and excision of the ovary (* $P < .05$).

None of the other anesthetic variables were significantly altered during NMB compared to anesthesia without NMB.

Intraoperative bleeding from the ovarian pedicle

Arterial bleeding from the mesovarial pedicle occurred in 10 instances (9 dogs), 5 of which occurred under NMB and 5 without NMB. The dog with 2 bleeding pedicles developed 1 with and 1 without NMB. The occurrence of mesovarial bleeding was not affected by NMB and did not increase total surgical time. Bleeding from the ovarian pedicle was usually easily manageable using the bipolar forceps.

Access to the ovaries, obesity, estrus and pseudo-pregnancy

Duration of surgery, calculated with exact surgical time, was ~19% longer when ovaries were difficult to access (n = 12 dogs) compared to easy access (difficult access 28.9 ± 8.1 minutes versus easy access 23.5 ± 4.7 minutes; $P = .01$). Difficulty of access to the ovaries was not related to the use of NMB or to obesity.

Surgical time was significantly longer (22%) in obese dogs (n = 14) compared to dogs with normal body condition (obese 29.2 ± 7.7 minutes versus normal 22.9 ± 4.2 minutes; $P = .002$).

Estrus (n = 2) and pseudopregnancy (n = 15) did not significantly influence surgical time.

Postoperative variables

Minimal wound swelling that resolved without medical or surgical intervention occurred in 4 dogs (4 of 120 wounds). Recovery time was 1.3 ± 0.3 days. All dogs had normal activity and appetite 1 week postoperatively. Dogs were administered carprofen for 2.65 ± 0.9 days.

Discussion

Neuromuscular blocking agents have been advocated as an anesthetic adjunct for human laparoscopic procedures to provide muscle relaxation to improve surgical accessibility.[9] We hypothesized that keeping the abdominal pressure at a fixed level, surgical convenience would be improved by NMB and surgical duration would be shorter (improved ease at searching ovaries and performing ovariectomy). NMB did, however, not affect surgery duration in laparoscopic ovariectomy, nor did it affect the accessibility of the ovaries or the occurrence of complications at equal insufflation pressures of 8 - 10 mm Hg. These results correspond to the study of Williams and colleagues (2003) where 2 different anesthetic regimes in people (spontaneous breathing without NMB versus artificial respiration with NMB) were compared. They concluded that trocar placement was more safely performed in the NMB group, but that no difference in the quality of surgical view or complications could be found.[10]

Neuromuscular blocking drugs will prevent high intra-abdominal and airway pressures induced by the pneumoperitoneum in people.[9] This is especially important when the intra-abdominal insufflation pressure is not preset as it was in our study. When the abdomen is primarily insufflated to a level necessary to achieve enough surgical working space, relaxing the abdominal wall by means of NMB might help to avoid intra-abdominal or intra-thoracic pressures above the general accepted levels (> 12 mm Hg). However, surgical working space already being adequate at 8 - 10 mm Hg is probably the main reason that we did not find any differences in surgical time with NMB.

Vecuronium-bromide was chosen for NMB because of its rapid onset and short duration of action since the study design necessitated reversal of NMB in the 10 minute break between ovariectomy 1 and 2 in group 1 dogs.[15] Vecuronium is metabolized in the liver and excreted in bile, therefore, liver dysfunction can lead to a more prolonged duration of action and delay pharmacological reversal.[18,19] All dogs were healthy based on clinical examination; therefore this should not have influenced the duration of NMB. Reversal of NMB with neostigmine and atropine within the 10-minute break was feasible in all dogs and was not associated with complications.

With the exception of blood pressure, all other monitored anesthetic variables were not significantly different with or without NMB. Because insufflation pressure is unchanged under NMB, intra-abdominal pressure cannot be held responsible for changes in arterial blood pressure. The reduction in MAP and DAP pressures during NMB was small and all recorded blood pressure values were within normal physiologic limits for all dogs during anesthesia.[20] Although vecuronium has been reported to deliver cardiovascular stable NMB compared to other NMB drugs,[21-25] some experiments have found vecuronium to cause cardiovascular changes.[26-30] It is therefore possible that the observed change in blood pressure during NMB in this study can be directly attributed to vecuronium. Other drugs administered during anesthesia also influence blood pressure and may have contributed to this finding. Isoflurane is known for its dose dependent depression of the blood pressure; therefore ETiso was kept unchanged during ovariectomy 1 and 2.[31] Medetomidine causes an initial hypertension in dogs followed by a return to approximately normal values.[32] Medetomidine was redosed during anesthesia 1 hour after premedication and this dose will have influenced blood pressure values. Although the protocol was standardized between dogs it is possible that this may have been a confounding factor.

NMB was monitored using a peripheral nerve stimulator to stimulate the ulnar nerve. No scientific evidence exists to justify the use of a particular nerve,[33] nevertheless the ulnar nerve is most frequently used in people.[34] Correct placement of the stimulating electrodes was verified before administration of NMB using TOF stimulation. TOF stimulation pattern is commonly used to monitor NMB in dogs and is accepted to be adequately sensitive.[35,36] Double burst stimulation is recognized to be a more sensitive technique to measure NMB in people,[34] but this technique has not been evaluated in dogs. The TOF ratio (TOFR; ratio of the height of the 4th twitch to the 1st twitch) was measured by observation rather than by accelerography. Residual NMB with intermediate acting NMB such as vecuronium bromide is relatively common in people, even when the block is reversed using an anticholinesterase.[37] However monitoring TOFR with accelerography has not been shown to significantly improve the detection of residual blockade.[38] Greer and colleagues compared tactile assessment of TOF count and TOF ratio by an accelomyographic monitor by nursing staff in people and found that they tended to overestimate the degree of block using tactile assessment.[39] Therefore

despite the use of tactile monitoring in our study it is unlikely that there was residual blockade between ovariectomy 1 and 2 in group 1 dogs.

Intraoperative bleeding did not influence surgical time, which is consistent with the results of bipolar electrocoagulation in laparoscopic ovariectomy in a previous study.[13] Although the bipolar electrocoagulation forceps is inferior to more modern methods of coagulation (vessel sealing, laser, harmonic scalpel),[40,41] it is very efficient in conducting hemostasis in laparoscopic ovariectomy and handling possible mesovarial bleeding.[12] Effects on surgical duration of difficult access to the ovary, obesity, estrus and pseudopregnancy were similar to previous studies.[12,13] The same applies for postoperative variables.

Use of NMB in laparoscopic procedures in dogs with no abnormalities of the ovaries and uterus, is a safe technique only associated with a slight (5%) decrease in MAP (as a result of a decreased DAP). When safe intra-abdominal pressures (8 - 10 mm Hg) are used, no beneficial effect on laparoscopic ovariectomy times or other surgical variables could be detected. This study could not detect any benefit from the addition of NMB to the standard anesthetic protocol in canine laparoscopic ovariectomy.

References

1. Bailey JE, Pablo LS: Anesthetic and physiologic considerations for veterinary endosurgery, in Freeman LJ (ed): Veterinary Endosurgery, St. Louis, MO, Mosby, 1999, pp 24-43.
2. Ishizaki Y, Bandai Y, Shimomura K, Abe H, Ohtomo Y, Idezuki Y: Safe intra-abdominal pressure of carbon dioxide pneumoperitoneum during laparoscopic surgery. Surgery 1993;114:549-554.
3. Williams MD, Murr PC: Laparoscopic insufflation of the abdomen depresses cardiopulmonary function. Surg Endosc-Ultras 1993;7:12-16.
4. Duke T, Steinacher SL, Remedios AM: Cardiopulmonary effects of using carbon dioxide for laparoscopic surgery in dogs. Vet Surg 1996;25:77-82.
5. Ozmen MM, Zulfikaroglu B, Col C, Cinel I, Isman FK, Cinel L, Besler TH: Effect of increased abdominal pressure on cytokines (IL1 beta, IL6, TNFalpha), C-reactive protein (CRP), free radicals (NO, MDA), and histology. Surg Laparosc Endosc Percutan Tech 2009;19:142-147.
6. Papp A, Vereczkei, Lantos J, Horvath OP: The effect of different levels of peritoneal CO_2 pressure on bleeding time of spleen capsule injury. Surg Endosc 2003;17:1125-1128.
7. Joshipura VP, Haribhakti SP, Patel NR, Naik RP, Soni HN, Patel B, Bhavsar MS, Narwaria MB, Thakker R: A prospective randomized, controlled study comparing low-pressure versus high-

pressure pneumoperitoneum during laparoscopic cholecystectomy. Surg Laparosc Endosc Percutan Tech 2009;19:234-240.
8. van Nimwegen SA, Kirpensteijn J: Laparoscopic ovariectomy in cats: comparison of laser and bipolar electrocoagulation. J Feline Med Surg 2007;9:397-403.
9. Hanley E: Anesthesia for laparoscopic surgery. Surg Clin North Am 1992;72:1013-1019.
10. Williams MT, Rice I, Ewen SP, Elliott SM: A comparison of the effect of two anaesthetic techniques on surgical conditions during gynaecological laparoscopy. Anaesthesia 2003;58:574-578.
11. Chassard D, Berrada K, Tournadre JP, Bouletreau P: The effects of neuromuscular block on peak airway pressure and abdominal elastance during pneumoperitoneum. Vet Anesth Analg 1996;82:525-527.
12. Van Goethem B, Rosenveldt KW, Kirpensteijn J: Monopolar versus bipolar electrocoagulation in canine laparoscopic ovariectomy: a nonrandomized, prospective, clinical trial. Vet Surg 2003;32:464-470.
13. van Nimwegen SA, Van Swol CFP, Kirpensteijn J: Neodymium:Yttrium aluminum garnet surgical laser versus bipolar electrocoagulation for laparoscopic ovariectomy in dogs. Vet Surg 2005;34:353-357.
14. Impellizeri JA, Tetrick MA, Muir P: Effect of weight reduction on clinical signs of lameness in dogs with hip osteoarthritis. J Am Vet Med Assoc 2000;216:1089-1091.
15. Jones RS: Neuromuscular blocking action of vecuronium in the dog and its reversal by neostigmine. Res Vet Sci 1985;38:193-196.
16. Cullen LK, Jones RS: Recording of train-of-four evoked muscle responses from the nose and foreleg in the intact dog. Res Vet Sci 1980;29:277-280.
17. van Nimwegen SA, Kirpensteijn J: Comparison of Nd:YAG surgical laser and Remorgida bipolar electrosurgery forceps for canine laparoscopic ovariectomy. Vet Surg 2007;36:533-540.
18. Craig RG, Hunter JM: Neuromuscular blocking drugs and their antagonists in patients with organ disease. Anaesthesia 2009;64:55-65.
19. Khuenl-Brady K, Castagnoli KP, Canfell PC, Caldwell JE, Agoston S, Miller RD: The neuromuscular blocking effects and pharmacokinetics of ORG 9426 and ORG 9616 in the cat. Anesthesiology 1990;72:669-674.
20. Kuusela E, Raekallio M, Vaisanen M, Mykkanen K, Ropponen H, Vainio O: Comparison of medetomidine and dexmedetomidine as premedicants in dogs undergoing propofol-isoflurane anesthesia. Am J Vet Res 2001;62:1073-1080.
21. Morris RB, Cahalan MK, Miller RD, Wilkinson PL, Quasha AL, Robinson SL: The cardiovascular effects of vecuronium (ORG NC45) and pancuronium in patients undergoing coronary-artery bypass-grafting. Anesthesiology 1983;58:438-440.
22. Vettermann J, Beck KC, Lindahl SGE, Brichant JF, Rehder K: Actions of enflurane, isoflurane, vecuronium, atracurium, and pancuronium on pulmonary resistance in dogs. Anesthesiology 1988;69:688-695.
23. Schmeling WT, Kampine JP, Warltier DC: Negative chronotropic actions of sufentanil and vecuronium in chronically instrumented dogs pretreated with propranolol and/or diltiazem. Anesth Analg 1989;69:4-14.
24. Larijani GE, Gratz I, Minassian SS, Hughes DL, Afshar M, Karayannis BN: Comparative evaluation of the neuromuscular and cardiovascular effects of pipecuronium, pancuronium, atracurium, and vecuronium under isoflurane anesthesia. Pharmacotherapy 1992;12:278-282.

25. Husby P, Gramstad L, Rosland JH, Vamnes JS, Segadal L: Haemodynamic effects of high-dose vecuronium compared with pancuronium in beta-blocked patients with coronary artery disease during fentanyl-diazepam-nitrous oxide anaesthesia. Acta Anaesthesiol Scand 1996;40:26-31.
26. Robertson EN, Booij L, Fragen RJ, Crul JF: Clinical comparison of atracurium and vecuronium (org-nc-45). Br J Anaesth 1983;55:125-129.
27. Lavery GG, Mirakhur RK, Clarke RSJ, Gibson FM: The effect of atracurium, vecuronium and pancuronium on heart-rate and arterial-pressure in normal individuals. Eur J Anaesthesiol 1986;3:459-467.
28. Hackett GH, Jantzen J, Earnshaw G: Cardiovascular effects of vecuronium, atracurium, pancuronium, metocurine and RGH-4201 in dogs. Acta Anaesthesiol Scand 1989;33:298-303.
29. Narita M, Furukawa Y, Ren LM, Karasawa Y, Takei M, Murakami M, Takayama S, Chiba S: Cardiac effects of vecuronium and its interaction with autonomic nervous-system in isolated perfused canine hearts. J Cardiovasc Pharmacol 1992;19:1000-1008.
30. Stevens JB, Hecker RB, Talbot JC, Walker SC: The haemodynamic effects of rocuronium and vecuronium are different under balanced anaesthesia. Acta Anaesthesiol Scand 1997;41:502-505.
31. Merin RG, Bernard JM, Doursout MF, Cohen M, Chelly JE: Comparison of the effects of isoflurane and desflurane on cardiovascular dynamics and regional blood-flow in the chronically instrumented dog. Anesthesiology 1991;74:568-574.
32. Murrell JC, Hellebrekers LJ: Medetomidine and dexmedetomidine: a review of cardiovascular effects and antinociceptive properties in the dog. Vet Anaesth Analg 2005;32:117-127.
33. Davidson JE: Neuromuscular blockade: indications, peripheral nerve stimulation, and other concurrent interventions. New Horiz 1994;2:75-84.
34. Rowlee SC: Monitoring neuromuscular blockade in the intensive care unit: the peripheral nerve stimulator. Heart Lung 1999;28:352-362.
35. Kastrup MR, Marsico F, Ascoli FO, Becker T, Soares JHN, de Segura IAG: Neuromuscular blocking properties of atracurium during sevoflurane or propofol anaesthesia in dogs. Vet Anaesth Analg 2005;32:222-227.
36. Adams WA, Mark Senior J, Jones RS, Williams JM, Gleed RD: cis-Atracurium in dogs with and without porto-systemic shunts. Vet Anaesth Analg 2006;33:17-23.
37. Hayes AH, Mirakhur RK, Breslin DS, Reid JE, McCourt KC: Postoperative residual block after intermediate-acting neuromuscular blocking drugs. Anaesthesia 2001;56:312-318.
38. Suzuki T, Fukano N, Kitajima O, Saeki S, Ogawa S: Normalization of acceleromyographic train-of-four ratio by baseline value for detecting residual neuromuscular block. Br J Anaesth 2006;96:44-47.
39. Greer R, Harper NJN, Pearson AJ: Neuromuscular monitoring by intensive care nurses: comparison of acceleromyography and tactile assessment. Br J Anaesth 1998;80:384-385.
40. Lamberton GR, Hsi RS, Jin DH, Lindler TU, Jellison FC, Baldwin DD: Prospective comparison of four laparoscopic vessel ligation devices. J Endourol 2008;22:2307-2312.
41. Newcomb WL, Hope WW, Schmelzer TM, Heath JJ, Norton HJ, Lincourt A, Heniford BT, Iannitti DA: Comparison of blood vessel sealing among new electrosurgical and ultrasonic devices. Surg Endosc 2009;23:90-96.

6

Monopolar versus bipolar electrocoagulation in canine laparoscopic ovariectomy: a nonrandomized, prospective, clinical trial

Van Goethem B, Rosenveldt KW, Kirpensteijn J

Vet Surg 2003;32(5):464-470.

Department of Clinical Sciences of Companion Animals, Faculty of Veterinary Medicine, Utrecht University, Yalelaan 108, P.O. Box 80154, NL-3508 TD Utrecht, The Netherlands

Abstract

Objective: To compare the effect of using monopolar (MEC) or bipolar electrocoagulation (BEC) on surgical time for laparoscopic ovariectomy in dogs, and to evaluate the influence of age, weight and obesity, and estrus or pseudopregnancy on surgical time.

Study design: Prospective, nonrandomized, clinical trial.

Animals: One hundred three female dogs.

Methods: Laparoscopic ovariectomy was performed with MEC or BEC by 1 surgeon using a standard protocol. Surgical time was recorded for the different procedural stages and was statistically evaluated for differences between MEC and BEC (chi-square, Student's t- test, and ANOVA). The influence of significant variables was analyzed using multiple linear regression analysis.

Results: Mean surgical time was 47 minutes (range, 27 to 110 minutes). Surgical time was significantly shorter with BEC (BEC 41 minutes versus BEC 53 minutes; $P < .001$). Obesity (obesity 56 minutes versus no obesity 42 minutes; $P < .001$) and intraoperative mesovarial bleeding (bleeding 56 minutes versus no bleeding 46 minutes; $P = .03$) increased surgical time. Dog age, estrus, and pseudopregnancy did not significantly influence surgical time.

Conclusions: BEC decreased laparoscopic ovariectomy time, decreased the occurrence of intraoperative bleeding, and, with the technique used, facilitated exteriorization of the ovaries.

Clinical relevance: Laparoscopic ovariectomy can be performed more rapidly when using BEC instead of MEC and with less risk of mesovarial bleeding.

Introduction

Laparoscopic sterilization of bitches was first reported in 1985.[1] Oviducts or uterine horns were clipped or cauterized. These techniques are no longer recommended in dogs, because three of six dogs subsequently developed pyometra. Coagulation of the uterine horns at the uterotubal junction near the ovarian bursa appeared to be a safer technique.[2] However, although conception was prevented, sexual behavior was not eliminated. Because sexual behavior is frequently the reason for requesting sterilization, the preferred sterilization technique is gonadectomy.[3]

Although it is possible to perform a laparoscopic ovariohysterectomy, long-term research of the conventional technique has shown that ovariohysterectomy offers no advantage over an ovariectomy in routine neutering of healthy postpuberal bitches.[4] Therefore, ovariectomy is the standard method of sterilization in the Netherlands. Because ovariectomy is faster, easier, and does not require the caudal portal to be enlarged for removal of the uterus this technique was chosen.

Laparoscopic ovariectomy is a relatively rapid technique that is minimally invasive and allows excellent observation of the genitourinary tract and other viscera.[5-7] Laparoscopy is also useful for diagnosis and treatment of ovarian remnants, uterine stump pyometra, and fistulous tracts from inflammatory reaction to suture materials.[8,9]

Electrocoagulation, either monopolar (MEC) or bipolar (BEC), can be used for hemostasis when cutting tissue during laparoscopy. MEC is more commonly used and involves current flow from the hand piece (active electrode) through the patient's body to the return dispersive electrode (neutral pad) before returning to the electrosurgical generator.[10,11] Endoscopic use of MEC is by means of scissors that act as the active hand piece and releases current (Fig 6.1). This allows a slow cutting movement that coagulates both cut ends. Although MEC is effective when applied correctly, its use has been discouraged, because of concerns about alternate site burns related to capacitive coupling, direct coupling, insulation failure, or unintended burns along the monopolar current path.[11,12]

With BEC, the bipolar forceps are coupled and current passes from one tip of the hand

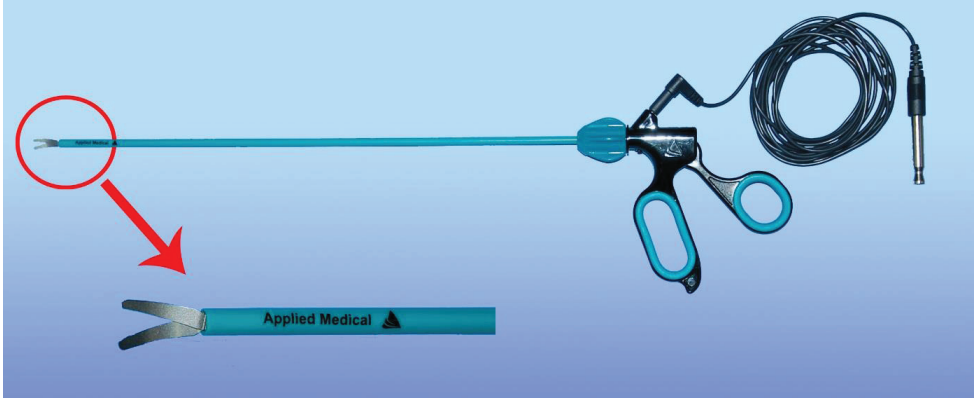

Figure 6.1 Laparoscopic scissors (Endo Mini-Shears Short 5 mm) were connected to a monopolar electrocoagulation generator to coagulate the tissues it contacts and generate a vascular seal before cutting.



Figure 6.2 Bipolar electrocoagulation forceps (Take-Apart Bipolar Grasping Forceps) can grasp and coagulate a large amount of tissue in a single action. Cutting the coagulated tissue, however, requires a second instrument.

piece (active electrode) to the contralateral tip (neutral electrode) (Fig 6.2). Only tissue grasped between the jaws will be coagulated.[11,13] Advantages of BEC include less current required for the same hemostatic effect, and less risk of unintentional injury to surrounding tissues, because direct coupling and capacitive coupling cannot occur. Further, effective coagulation can be obtained even in a wet surgical field.[11,13,14] A disadvantage of the BEC

technique compared to MEC, in laparoscopic procedures, is the need to use two instruments: the electrocoagulation forceps for hemostasis and the scissors for tissue transection. This increases the number of surgical movements and theoretically may slow the procedure.[15,16]

Our objective was to compare surgical times for bilateral ovariectomy with MEC and BEC techniques. We also evaluated other variables previously reported to influence surgical time, such as age, weight and obesity, estrus or pseudopregnancy, bleeding at the ovarian pedicle and ovarian accessibility.[17,18]

Materials and methods

Criteria for inclusion

Client-owned bitches (n = 103) admitted for elective ovariectomy between December 1997 and December 2000 were entered in the study. Dogs were assigned to MEC or BEC in a nonrandomized manner because of the limited availability of the new bipolar laparoscopic instrument. Thus, dogs 1 to 30, 79 to 82 and 84 to 103 were entered in the MEC group (n = 54) and dogs 31 to 78, and dog 83 were entered in the BEC group (n = 49). Only dogs that had normal anatomy of the uterus and ovaries identified during laparoscopy were included in this study. Because this was a routine surgical procedure on normal dogs, no selection bias was present.

Before surgery, a standard questionnaire was completed by the surgeon. Questions included dog age, number of estrus cycles, date of last estrus, body weight, and obesity based on a body condition score system, ranging from 1 (thin) to 5 (obese).[19] Based on this body condition score a subjective differentiation of obese or not obese was made.

Surgical technique

We used a variation of the classic laparoscopic approach for dogs, where there is one median portal at the umbilicus and two lateral portals, each on one side of the mammary

glands.[9,16,20-22] Instead, we used three median portals: the caudal portal (10 mm) was located halfway between the umbilicus and the os pubis; the middle portal (10 mm) was located 1 cm caudal to the umbilicus; and the cranial portal (5 mm) just 1 cm cranial to the umbilicus and slightly paramedian to avoid trauma to veins located on the midline.

We used an modified Hasson's technique at the caudal portal.[16] After trocar-cannula insertion (Surgiport 10 mm disposable trocar with 100-mm sleeve; Auto Suture, US Surgical Corp., Norwalk, CT), the correct location of the cannula was checked by inflation of a small amount of CO_2 (1 L/min). When no pressure build up was noted it was concluded that the cannula entered the abdominal cavity and the abdomen was insufflated with CO_2 (6 L/min) to an intra-abdominal pressure of 8 to 12 mm Hg. A 10-mm zero degree telescope (Hopkins II, Karl Storz-Endoscopy, the Netherlands) was inserted in the caudal portal. The two other trocar-cannulae (Surgiport 10 mm in the middle position and Surgiport 5 mm disposable trocar with 100 mm sleeve in the cranial location; Auto Suture, US Surgical Corp.) were inserted under endoscopic guidance to avoid contact with the falciform ligament. After placement of the cranial and middle portal, the telescope was relocated to the middle portal and the abdomen was inspected. Two grasping forceps (Endo dissect 5 mm and Endo Clinch II 5 mm; US Surgical Corp) were used to locate and mobilize the left ovarian bursa. The dog was placed in a Trendelenburg position and, if necessary, the surgical table was tilted to the surgeon's side to improve access to the ovaries.

MEC was performed by an open bursa technique. The ovarian bursa was sharply incised through the bursal opening (Endo Mini-Shears Short 5 mm; US Surgical Corporation, Norwalk, CT) to expose the ovary. The ovary was clamped on one side with self-retaining forceps (Endo Clinch II 5 mm, US Surgical Corp.). Then, the uterine horn and ovarian pedicle were coagulated and cut with endoscopic scissors (Endo Mini-Shears Short 5 mm; US Surgical Corp.) within the bursa.

With BEC, the ovarian bursa remained intact and the bursal opening was entered with one tip of the self-retaining forceps (Endo Clinch II 5 mm; US Surgical Corp.), and the bursal tissue grasped. Then, the proper and suspensory ligaments of the ovary were coagulated using an endoscopic cautery (Take-Apart Bipolar Grasping Forceps 5 mm; Karl Storz-Endoscopy, The Netherlands) and sharply dissected using endoscopic scissors (Endo Mini-Shears Short 5 mm).

The ovarian pedicle was coagulated and cut similarly. Each ovarian pedicle was carefully evaluated for bleeding. If ovarian pedicle bleeding could not be controlled using electrocoagulation (MEC or BEC), it was ligated using size 0 polyglactin 910 (Vicryl Endoloop ligature EJ10; Ethicon, Somerville, NJ).

The left ovary was placed to the right side of the bladder (for easy retrieval later) and the procedure was repeated for the right ovary. Both ovaries were gently removed through the caudal portal. CO_2 was evacuated from the abdomen and the portal incisions closed.

The surgical procedure was divided into 4 different stages and the time for each stage recorded. Stage I: from skin incision to observation of the left ovary; stage II: left ovarian resection; stage III: right ovarian resection; and stage IV: removal of both ovaries from the abdominal cavity. The surgeon also recorded intraoperative bleeding from the ovarian pedicle and the ease of access to the ovaries. All surgeries were performed by the same surgeon (JK).

Follow-up

The owner was contacted by telephone and asked about outcome with specific interest on wound healing. Signs of slight wound dehiscence, infection, and even marked swelling were considered wound complications.

Statistical analysis

Data are reported as mean ± SD. Differences between groups were evaluated by the chi-square test for ordinal or ratio data and by 2-tailed, non-paired, Student's t-test or 1-way parametric ANOVA for interval data. The significant variables were entered into the multiple linear regression equation. A P value < .05 was considered significant. Statistical analysis of data was performed with computer software (SPSS Windows 9.0, SPSS, Chicago, IL).

Results

Forty-two different breeds were represented. Mean age was 2.8 ± 2 years (range, 6 months to 10 years). Mean bodyweight was 25.6 ± 10 kg (range, 5 to 53 kg). Based on body condition scores, 38 dogs were considered obese and 65 dogs not obese.

Effect of electrocoagulation method: MEC versus BEC

For the combined techniques, mean surgical time (incision to closure) was 47 minutes (range, 27 to 110 minutes). Surgical time with BEC was 23% shorter than with MEC (BEC 40.8 ± 10 minutes versus MEC 52.7 ± 14 minutes; $P < .001$). When procedural stages were evaluated, operative times with BEC were significantly shorter in stage II (BEC 9.0 ± 6 minutes versus MEC 13.5 ± 6 minutes; $P = .001$), stage III (BEC 13.4 ± 4 minutes versus MEC 17.0 ± 4 minutes; $P = .002$), and stage IV (BEC 5.0 ± 3 minutes versus MEC 9.2 ± 7 minutes; $P = .001$; Fig 6.3).

Intraoperative bleeding from the ovarian pedicle

Arterial bleeding at the pedicle stump occurred in 11 dogs, 7 dogs (13%) from the MEC group and 4 dogs (8%) from the BEC group. Total surgical time was significantly increased with 22% in case of bleeding (bleeding 56 minutes versus no bleeding 46 minutes; $P = .03$). The predominant time increase occurred in stage II (bleeding 12.3 ± 3 minutes versus no bleeding 8.7 ± 3 minutes; $P = .02$; Fig 6.4) and stage III (bleeding 18.0 ± 5 minutes versus no bleeding 14.2 ± 4 minutes). The time increase in stage III proved not to be significant, however. We also noted that the efficacy of MEC decreased in the presence of bleeding. Ligatures were needed more often with MEC than BEC (MEC 24 dogs versus BEC 1 dog; $P < .001$). Bilateral ligatures were used in 20 dogs. Unilateral Endoloop ligatures were used on the left ovarian pedicle stump in 1 dog and on the right in 4 dogs.

The frequency of intraoperative bleeding increased with age, and consequently with the number of estral cycles. The mean age of dogs with bleeding of the ovarian pedicle stump was

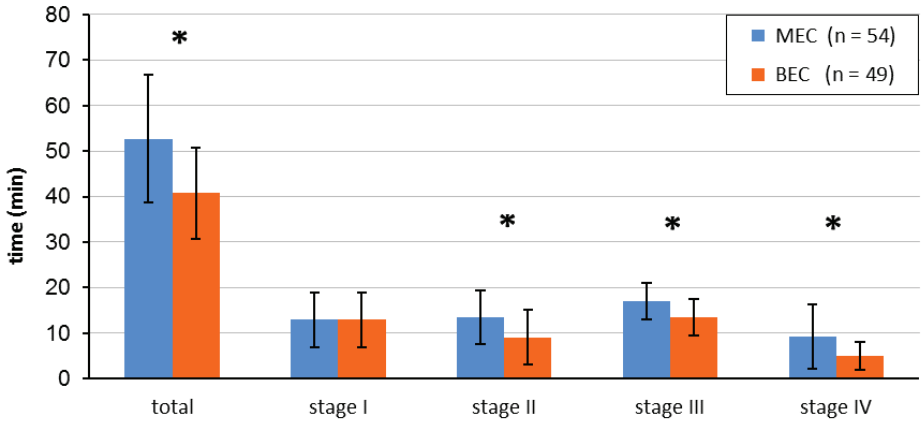

Figure 6.3 Comparison between MEC and BEC at the different procedural stages. Stage I: incision to observation of the left ovary, stage II: left ovarian resection, stage III: right ovarian resection and stage IV: removal of ovaries (* *P* < .05).

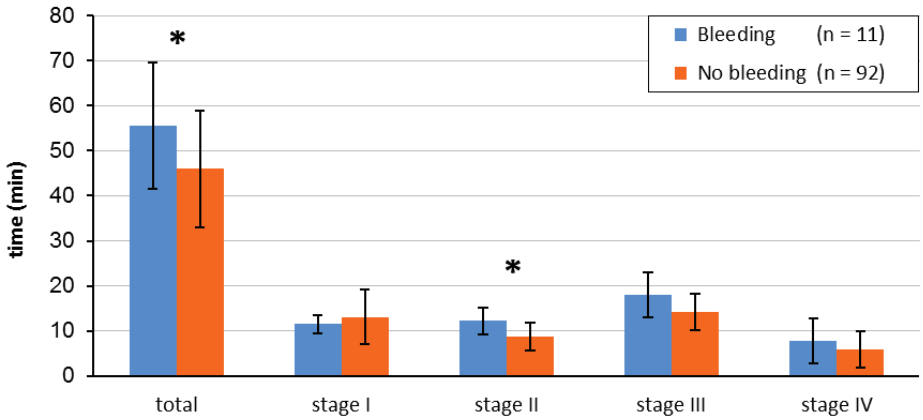

Figure 6.4 The effect of intraoperative bleeding on the different procedural stages. Stage I: incision - visualization left ovary, stage II: left ovariectomy, stage III: right ovariectomy and stage IV: removal of ovaries (* *P* < .05).

significantly different from dogs with no bleeding (bleeding 4.4 ± 3 years versus no bleeding 2.6 ± 2 years; *P* = .001). The mean number of estral cycles in dogs with bleeding was

significantly higher compared to dogs with no bleeding (bleeding 6.7 ± 6 cycles versus no bleeding 3.1 ± 3 cycles; *P* = .001). The effect of obesity on bleeding was not significant.

Access to the ovaries

Surgical times were significantly longer (19%) when ovaries were difficult to access (difficult access 54.2 ± 15 minutes versus easy access 45.5 ± 13 minutes; *P* = .01). Increased time occurred predominantly in stage II (difficult 12.0 ± 3 minutes versus easy 8.7 ± 3 minutes; *P* = .02) and stage III (difficult 17.7 ± 5 minutes versus easy 13.8 ± 4 minutes; *P* = .01).

There was a close relationship between access to the ovaries and obesity (*P* = .003). The left ovary was more difficult to access in obese dogs (obese 9/29 dogs or 31% versus normal 5/60 dogs or 8%; *P* = .03). Also the right ovary was more difficult to access in obese dogs (obese 9/29 dogs or 31% versus normal 4/61 dogs or 7%; *P* = .01).

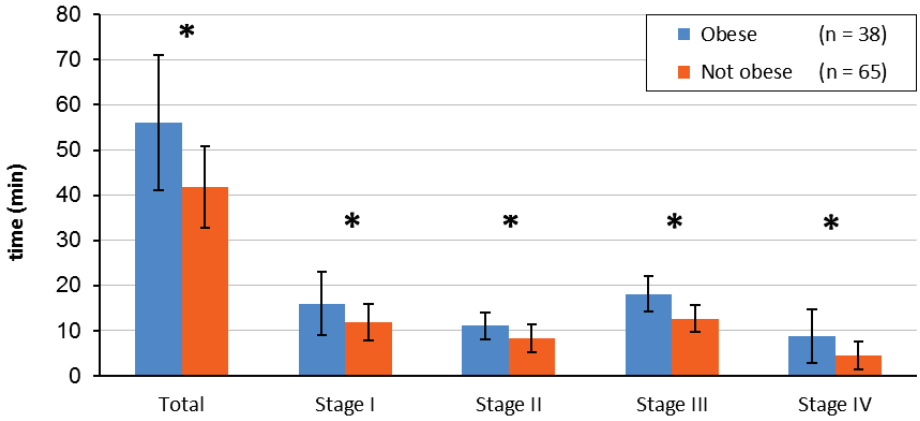

Figure 6.5 The effect of obesity on the different procedural stages. Stage I: incision - observation of the left ovary, stage II: left ovariectomy, stage III: right ovariectomy and stage IV: removal of ovaries (* *P* < .05).

Obesity

Surgical time was significantly longer (34%) in obese dogs compared to dogs with normal body condition (obese 56.1 ± 15 minutes versus normal 41.8 ± 9 minutes; $P < .001$; Fig 6.5). All surgical stages were affected: stage I (obese 15.9 ± 7 minutes versus normal 11.8 ± 4 minutes; $P = .02$), stage II (obese 11.1 ± 3 minutes versus normal 8.3 ± 3 minutes; $P = .003$), stage III (obese 18.1 ± 4 minutes versus normal 12.6 ± 3 minutes; $P < .001$), and stage IV (obese 8.7 ± 6 minutes versus normal 4.5 ± 3 minutes; $P < .001$).

Dogs with obesity were older than dogs with normal body condition scores (obesity mean age 3.5 ± 2 years versus normal 2.3 ± 2 years; $P = .003$). Obesity proved to be significantly related to the age of the dog, with increasing risk for obesity for dogs > 3 years. Since age and number of estral cycles are closely related, this variable was also significantly different (obese 4.9 ± 5 cycles versus normal 2.6 ± 2 cycles; $P = .002$).

Estrus cycle

Estrus (n = 7) and pseudopregnancy (n = 15) did not significantly influence the surgical time. Increasing number of estral cycles were related to the occurrence of intraoperative bleeding and the development of obesity.

Wound healing

Minor wound complications that resolved without medical or surgical intervention occurred in 3.9% of the dogs (12 of 309 wounds). These ranged from swelling and redness to dehiscence and discharge. Complications occurred in the cranial portal (2 dogs), the middle portal (7), and in the caudal portal (3).

Multivariate regression analysis

Surgical technique (MEC versus BEC: $P < .001$), mesovarial bleeding ($P = .033$) and obesity ($P < .001$) independently had a significant effect on total surgical time. Surgical time

related to ovarian accessibility was no longer significant when the factor weight (obesity) was corrected for.

Discussion

With experience, laparoscopic ovariectomy can be accomplished relatively quickly. In contrast to some previous authors, who rejected the laparoscopic technique because of its prolonged duration when compared to the conventional technique,[23] we agree with those who observed surgical times to be compatible.[20] All surgeries were performed by the same surgeon (JK), who had already performed more than 150 laparoscopic ovariectomies before this study, thus minimizing temporal bias associated with learning.

Methods for hemostasis include vascular staples, clips, sutures, and coagulation.[12,15,16,24] Cost often limits the use of endoscopic vascular staples in veterinary surgery. When endoscopic vascular clips are used, the ovarian pedicle must be divided into smaller segments to fit the aperture of the ligating clip to prevent bleeding. The large amount of fat in the ovarian pedicle, especially in obese dogs, makes this procedure difficult to perform without causing bleeding.[1,7,24] Suture ligation of the ovarian pedicle is used when the pedicle is too large for staples or clips, or when there is intraoperative bleeding. However, the tissue has to be able to withstand stretching and the manipulation involved with suture passage and knotting. Use of endoscopic loop sutures increases surgical cost and the risk for intraoperative complications, including trauma to friable adipose tissue, tearing of the vascular pedicle, and accidental ligation of the ureter.[9] Considering the higher surgical cost of these procedures and their potential risks, we chose to investigate the efficacy of two methods of laparoscopic electrocoagulation. Electrocoagulation is preferred when the pedicle is friable or vascular, because compared to the above-mentioned techniques; it reduces the risk of damage to these structures.[9,12]

In our experience, MEC was associated with an increased risk of intraoperative bleeding. Although there was no significant difference in incidence of arterial ovarian pedicle bleeders between MEC and BEC, BEC was more successful in coagulating active arterial or

venous bleeding. This is reflected in the number of ligatures placed. Unsatisfactory hemostasis necessitated ligation of the ovarian pedicle in 24 dogs (44%) with MEC compared to 1 dog (2%) when BEC was used. One possible explanation may be that the typical small bleeders at the ovarian pedicle are easier to grasp and to coagulate using BEC.

Based on previous reports, we anticipated a longer surgical time with BEC.[25] At the time of this study, available bipolar scissors were equipped with jaws too small for grasping the broad ovarian pedicle in dogs. This required the use of two instruments: the electrocoagulation forceps and the scissors. Although this increase in number of surgical movements could negatively influence BEC surgical times, this proved negligible compared to the benefits. Instead, BEC resulted in a significantly shorter surgical time (23% reduction) that was attributed foremost to the faster resection of both ovaries and to a lesser degree to their faster removal from the abdomen. The time from incision to the start of the first ovariectomy did not differ significantly between the 2 techniques, as had been expected. The increase in time to remove the right versus the left ovary was attributed to moving the surgeon and the endoscopy equipment to the opposite side. BEC also allowed coagulation of the ovarian pedicle over a 1-cm area by applying the forceps below the first line of coagulation. A wider coagulated ovarian pedicle is easier to cut.

An unanticipated advantage of the BEC technique was the relative ease of grasping and exteriorizing the ovarian tissue after ovariectomy. With the MEC technique the ovary was prolapsed from the bursa whereas with the BEC technique the ovary remained within the bursal tissue. The fatty bursal tissue was easier to manipulate than the ovary and also seemed to facilitate passage of the ovarian tissue through the abdominal wall.

Obesity was significantly related to the age of the dog, with increasing risk for obesity for dogs > 3 years. Concurrently it was also related to the number of estrus cycles. Obesity increased the duration, as expected, of every single stage of the procedure. Laparoscopic ovariectomy is easier in non-obese dogs, but the procedure also allows excellent observation of the ovarian pedicles in obese dogs. The necessity of a large incision to observe or exteriorize the ovaries during incisional ovariectomy in obese dogs makes laparoscopic ovariectomy a suitable alternative.

Wound complications were uncommon (3.9%) and were lower when compared to a retrospective analysis (1990-1994) of 8,724 dogs where the general complication rate for outpatient or inpatient treatment in a university setting was 11.8% and 5.5%, respectively, for clean, elective procedures.[26] Wound complications in laparoscopic ovariectomy could be lowered even further by meticulous surgical suturing technique. We speculate that wound complications occurring at the middle portal may have resulted from failure to completely remove anticondensing fluid from the endoscope. Because total surgical time is directly related to wound infection, with rates varying from 2.5 to 4.7 % for clean procedures as reported respectively by Romatowski[27] and by Brown et al,[28] it is also important to maintain strict aseptic surgical technique, especially in dogs with longer surgical times (the range for both BEC and MEC was 27 to 110 minutes).

We conclude that, if electrocoagulation is to be used in laparoscopic ovariectomy, BEC is preferred because it decreases the overall surgical time even further and, more specifically, the time to remove the individual ovaries. The incidence of intraoperative bleeding is decreased by use of BEC, and, when bleeding does occur, coagulation is facilitated by BEC.

References

1. Wildt DE, Lawler DF: Laparoscopic sterilization of the bitch and queen by uterine horn occlusion. Am J Vet Res1985;46:864-869.
2. Dukelow WR: Laparoscopy in small animals and ancillary techniques, in Harrison RM, Wildt DE (eds): Animal Laparoscopy, Baltimore, MD, Williams & Wilkins, 1980, pp 95-105.
3. Uson J, Tejedo V, Vives MA, Ezquerra LJ, Jimenez J: Thérapeutique laparoscopie (L'ovariectomie et la ligature des cornes utérines chez la chienne). Rec Méd Vét 1992;168:237-241.
4. Okkens AC, Kooistra HS, Nickel RF: Comparison of long-term effects of ovariectomy versus ovariohysterectomy in bitches. J Reprod Fertil 1997:227-231.
5. Wildt DE, Kinney GM, Seager SW: Laparoscopy for direct observation of internal organs of the domestic cat and dog. Am J Vet Res 1977;38:1429-1432.
6. Thiele S, Kelch G, Gerlach K: Kastration der Hündin durch laparoskopische Ovarektomie. Kleintierpraxis 1993;38:463-466.
7. Thiele S, Kelch G, Frank KG: Endoscopy of body cavities and minimally invasive surgery in small animals - review. Berl Munch Tierarztl Wochenschr 1996;109:288-291.
8. Minami S, Okamoto Y, Eguchi H, Kato K: Successful laparoscopy assisted ovariohysterectomy in two dogs with pyometra. J Vet Med Sci 1997;59:845-847.

9. Freeman LJ, Hendrickson DA: Minimally invasive surgery of the reproductive system, in Freeman LJ (ed): Veterinary Endosurgery, St. Louis, MO, Mosby, 1998, pp 205-217.
10. Baldwin CJ, Cowell RL, Kostolich M: Hemostasis: physiology, diagnosis, and treatment of bleeding disorders in surgical patients, in Slatter D (ed): Textbook of Small Animal Surgery, Vol 1., Philadelphia, PA, Saunders, 1993, pp 29-51.
11. Toombs JP, Clarke KM: Basic operative techniques, in Slatter D (ed): Textbook of small animal surgery, Vol 1., Philadelphia, PA, Saunders, 2003, pp 208-212.
12. Hulka JF, Thweatt D, Ulberg LC: Contained cautery: studies toward safer laparoscopic sterilization technics. Fertil Steril 1973;24:912-920.
13. Wildt DE: Laparoscopy in the dog and cat, in Harrison RM, Wildt DE (eds): Animal Laparoscopy, Baltimore, MD, Williams & Wilkins, 1980, pp 31-72.
14. Baggish MS, Tucker RD: Tissue actions of bipolar scissors compared with monopolar devices. Fertil Steril 1995;63:422-426.
15. Edelman DS, Unger SW: Bipolar versus monopolar cautery scissors for laparoscopic cholecystectomy - a randomized, prospective-study. Surg Laparosc Endosc 1995;5:459-462.
16. Magne ML, Tams TR: Laparoscopy: instrumentation and technique, in Tams TR (ed): Small Animal Endoscopy, St Louis, MO, Mosby, 1999, pp 615, 630-631.
17. Hedlund CS: Surgery of the reproductive and genital systems, in Fossum TW (ed): Small animal surgery (1st ed), Vol 1., St. Louis, MO, Mosby-Year Book Inc., 1997, pp 523-524, 536-537.
18. Kyles AE, Aronsohn M, Stone EA: Urogenital surgery, in Lipowitz AJ (ed): Complications in small animal surgery, Baltimore, MD, Williams & Wilkins, 1996, pp 496-503.
19. Impellizeri JA, Tetrick MA, Muir P: Effect of weight reduction on clinical signs of lameness in dogs with hip osteoarthritis. J Am Vet Med Assoc 2000;216:1089-1091.
20. Brugmans F, Thiele S, Koehler L: Minimaal invasieve chirurgie door middel van laparoscopische en thoracoscopische technieken. Vlaams Diergeneeskd Tijdschr 1996:72-81.
21. Rothuizen J: Laparoscopy in small animal medicine. Vet Quart 1985;7:225-228.
22. Brearly MJ, Cooper JE, Sullivan M: A colour atlas of small animal endoscopy. London, UK, Wolfe Publishing Ltd, 1991, pp 77-86.
23. Remedios AM, Ferguson NJ, Walker DD, Walsh PJ: Laparoscopic versus open ovariohysterectomy in dogs: a comparison of postoperative pain and morbidity. Vet Surg 1997;26:425.
24. Brenner WE, Edelman DA, Black JF, Goldsmith A: Laparoscopic sterilization with electrocautery, spring-loaded clips, and silastic bands - technical problems and early complications. Fertil Steril 1976;27:256-266.
25. Lantis JC, Durville FM, Connolly R, Schwaitzberg SD: Comparison of coagulation modalities in surgery. J Laparoendosc Adv S-Part A 1998;8:381-394.
26. Brunnberg L, Richter K, Kohn B: Wundheilungsstörungen bei Hund und Katze: Retrospektive Analyse 1990-1994. Kleintierpraxis 1997;42:535-553.
27. Romatowski J: Prevention and control of surgical wound-infection. J Am Vet Med Assoc 1989;194:107-114.
28. Brown DC, Conzemius MG, Shofer F, Swann H: Epidemiologic evaluation of postoperative wound infections in dogs and cats. J Am Vet Med Assoc 1997;210:1302-1306.

7

Comparison of the efficacy of a bipolar vessel sealing device and a bipolar electrocoagulation forceps in canine laparoscopic ovariectomy

Van Goethem B,[1] Wagner F, [1] van Nimwegen SA,[1]
Kik M,[2] Kirpensteijn J[1,3]

submitted

[1]Department of Clinical Sciences of Companion Animals, Faculty of Veterinary Medicine, Utrecht University, Utrecht, The Netherlands

[2]Department of Pathology, Faculty of Veterinary Medicine, Utrecht University, Utrecht, The Netherlands

[3]Current position: Hill's Pet Nutrition, 400 SW Topeka Ave, Topeka, KS 66047, USA

Abstract

Objectives: To compare a standard bipolar vessel sealing device (LigaSure - LS) with a dedicated bipolar electrocoagulation forceps (Take Apart Grasping Forceps - TA) for canine laparoscopic ovariectomy (lap OVE).

Study Design: Prospective, randomized clinical trial.

Animals: 40 client-owned dogs admitted for elective lap OVE.

Methods: The standard lap OVE technique was adapted to randomly assign each ovary to removal by LS or TA. Each technique was alternately used on the left and right side, comparing surgery duration, bleeding, and the extent of thermal tissue damage. The effect of variables, such as age, weight and obesity, estrus or pseudopregnancy, on lap OVE surgical times were evaluated.

Results: Mean total surgical time was 34.3 ± 10.5 minutes. Resection of the ovary was significantly faster with LS versus TA (LS 3.5 ± 2.7 minutes versus TA 8.1 ± 4.2 minutes; $P < .001$). Intraoperative bleeding occurred in 4 dogs (10%), and all bleeding occurred with TA ($P = .044$). Mean depth of electrothermal coagulation damage was 1.7 ± 0.9 mm, and this was not significantly different for LS versus TA. The histological scoring system did find significantly lower scores for LS versus TA at the level of the ovarian pedicle ($P = .007$), and the proper ligament ($P = .025$). Surgical times were influenced by surgeon experience, and ovarian pedicle fat scores. Both hemostatic instruments benefitted from surgical experience (shorter ovarian excision times).

Conclusions: Lap OVE can be performed more rapidly with LS, with less chance of bleeding at the ovarian pedicle and with less thermal coagulation damage to the cut surfaces when compared to TA. Despite feedback control ovariectomy with LS is operator dependent.

Clinical relevance: This study shows that LS has several advantages over TA in canine lap OVE and needs some practice.

Introduction

Laparoscopic ovariectomy (lap OVE) has gained importance as an elective gonadectomy technique because of obvious advantages over traditional ovariectomy: it is less invasive,[1] it is associated with less postoperative pain and stress,[2-5] there is less postoperative adhesion formation,[6,7] it has a shorter convalescence[8] and earlier discharge from the hospital.[9] To achieve hemostasis during transection of the ovarian pedicle, an extensive range of techniques has been used: intracorporeal or extracorporeal tied ligatures,[2,10] metallic or resorbable vascular clips,[10] monopolar electrocoagulation (MEC),[11,12] a bipolar electrocoagulation (BEC) forceps,[11-13] a combined BEC and cutting forceps,[14-16] bipolar vessel sealing devices (VSD),[10,12,16-18] ultrasonic vessel sealing devices [12,18] and Nd-YAG surgical lasers.[13,15]

Newer energy-based hemostatic surgical devices with tissue sensing technology can seal blood vessels with burst pressures higher than those of former BEC devices and equaling the supraphysiologic pressures obtained with surgical clips or ligatures.[19-21] Still, BEC forceps are widely distributed and used.[22] A survey in 2008 on 110 ACVS diplomats found that the most commonly used energy-based hemostatic surgical devices were: MEC (88%), BEC (76%), CO_2 laser (49%) and VSD (42%).[23] BEC forceps have proven more efficient than MEC for laparoscopic ovariectomy, resulting in decreased surgical times and less intraoperative bleeding.[11] Even when compared to the technically more advanced Nd:YAG laser, BEC forceps turned out to be equally efficient.[13] Because BEC forceps have a large grasping surface that is resistant to tissue slippage, allow to be steam autoclaved (reusable), and are relatively inexpensive compared to more advanced energy-based hemostatic surgical devices, this type of forceps is propagated as a dedicated forceps for laparoscopic ovariectomy, and as such considered by many practitioners to be the hemostatic technique of choice.[24]

The objective of this study was to compare a standard bipolar VSD (LigaSure – LS; Fig 7.1) with a dedicated BEC forceps (Take Apart Grasping forceps – TA; Fig 7.2) and laparoscopic scissors during canine ovariectomy. Specific interest was on operating time, the amount of thermal tissue damage, the effect of surgical experience (instrument expertise) and possible dog-related influential variables (obesity, estrus, etc.).

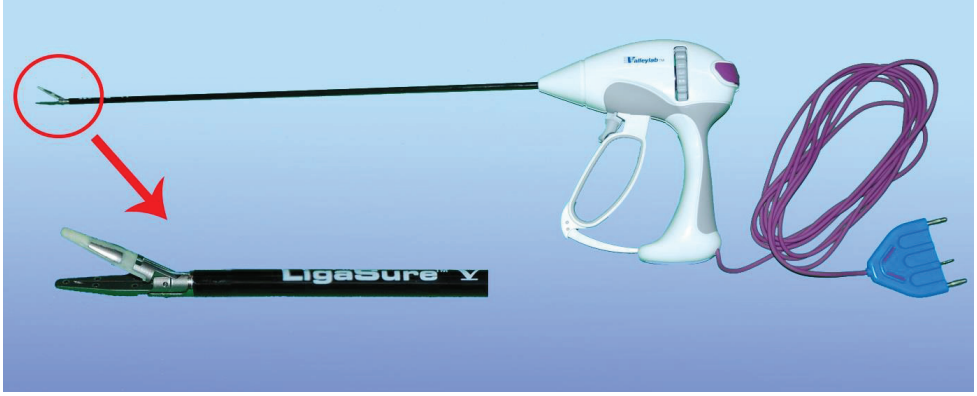

Figure 7.1 The 5 mm bipolar vessel sealing device (LigaSure V with Dolphin tip).



Figure 7.2 The 5 mm bipolar electrocoagulation grasping forceps (Take-Apart Grasping forceps).

Materials and methods

Study design

This study was a single-center, randomized, controlled clinical trial with client consent obtained for all dogs. The two different lap OVE techniques were performed in each animal based on previous randomization: the left ovarian pedicle was transected using LS or TA and

laparoscopic scissors, upon which the right pedicle was transected with the alternate technique. A standardized surgery and anesthesia protocol was used.[15]

Patient selection and randomization

Forty client-owned dogs admitted for elective lap OVE, between September 2006 and September 2007, were included. All dogs were healthy and classified as ASA 1 based on physical examination.[25] Data about breed, age, bodyweight, and obesity were obtained. A standard questionnaire about the dog (number of heat cycles, date of last heat, presence of pseudopregnancy, general health, diet, vaccination status) was completed before surgery. Obesity scores were based on a published scoring system.[26] The randomization process was performed before the trial and prewritten notes were drawn immediately preceding surgery.

Surgical technique

To evaluate the effect of surgical experience the procedure was performed by either an experienced laparoscopic surgeon (JK) or a novice laparoscopic surgeon (FW). Video-assisted lap OVE was performed through 3 median portals with the dogs positioned in dorsal recumbency in a 10° Trendelenburg position. A modified Hasson's approach was used at the caudal portal for insertion of an 11 mm threaded cannula (Ternamian EndoTIP cannula; Karl Storz Endoscopy, Tuttlingen, Germany). The insufflator, first set at 1 L/minute and only after verification of proper abdominal cannula placement switched to 6 L/minute, kept the intra-abdominal pressure at 8 mm Hg. A 5 mm zero degree telescope (Hopkins II, Karl Storz Endoscopy, Tuttlingen, Germany) was inserted through the cannula and two 6 mm threaded cannulas (Ternamian EndoTIP cannula) were inserted under laparoscopic guidance, 2 cm caudal and 2 cm cranial to the umbilicus. After cannulae insertion, the telescope was redirected to the middle portal.

In all dogs, the left ovary was excised first with the surgeon standing on the right side of the dog and the laparoscopic unit at the left side. The surgeon and the unit changed sides for excision of the right ovary. The ovarian bursa was located by identifying the round ligament of the uterus at the inguinal ring and following it cranially using two endoscopic grasping

forceps (Endo Dissect 5 mm and Endo Clinch II 5 mm; US Surgical Corporation, Norwalk, CT, USA). The bursa was grasped in the bursal opening with the self-retaining forceps (Endo Clinch) inserted through the cranial portal. For ovariectomy the energy-based hemostatic surgical hemostatic device was consecutively applied across the proper ligament, ovarian pedicle, and suspensory ligament. When the ovary was freed from its pedicle the stump was checked for bleeding. The ovarian bursa containing the ovary was extracted from the abdomen using the (larger) caudal portal. All ovaries were checked for completeness after removal. Closure of the abdomen was performed in a routine fashion.

Postoperative care

Dogs were released from the hospital immediately after full recovery from anesthesia. Carprofen (2 mg/kg orally twice daily) was prescribed for pain management for 3 days postoperatively.

Recorded surgical variables

Total surgical time (incision to final closure) and separate procedural times (including time from skin incision to placement of cannulae, time from start of searching for left ovary to placement of forceps in the ovarian bursa, time for left ovarian resection, time for turning of surgeon and equipment to other side, time from start of searching for right ovary to placement of forceps in the ovarian bursa, time for right ovarian resection, time for removing the resected right ovary from the abdomen, and time for removing the resected left ovary from the abdomen) were noted. Occurrence of intraoperative bleeding was recorded, the fat content of the ovarian pedicle was scored (FS: 0 = no fat, 1 = minimal fat, 2 = moderate fat, 3 = abundant fat), and patients were evaluated for obesity.

Histological examination

The resected ovaries were fixed in 10% neutral buffered formalin. All ovaries were longitudinally sectioned and the surrounding zone of coagulation was first evaluated under a dissecting microscope with 10 - 40x magnification and measured in mm. After embedding and

processing, the ovaries were stained with H&E and then analyzed by one pathologist (MK) in three locations: suspensory ligament, ovarian pedicle and proper ligament. A qualitative scoring system for electrothermal damage was used, taking into account the degree of coagulation necrosis, and the presence of gas formation caused by tissue boiling (0 = no damage, 1 = minimal damage, 2 = moderate damage, 3 = severe damage).

Statistical analysis

A power analysis was performed ($\beta = 0.90$; $\alpha = 0.05$, SD = 20%; estimated difference of 15%, based on a previous study)[15] and the number of dogs needed was determined to be 40 per test group. A minimum of 40 dogs (80 ovaries) was therefore necessary.

A paired sample t-test was used to test for differences in duration of defined surgical stages of left versus right, LS versus TA, and differences in histological parameters between groups. Nonparametric testing (Mann-Whitney U test and Kruskal Wallis analysis) was performed for non-uniformly distributed data. An independent samples t-test and one-way ANOVA were used to test for other (unpaired) variables (occurrence of intraoperative bleeding, effect of fat score) between groups. $P < .05$ (2-tailed) were considered significant. Results are reported as mean ± SD unless stated otherwise.

Results

Population descriptives

Mean age for all dogs was 2.6 ± 1.9 years (range, 0.5 to 8.4 years) and mean bodyweight was 21.8 ± 9.3 kg (range, 6.0 to 43.0 kg). Because both techniques were always tested on the same dog (left and right) there was no difference between groups with regard to the tested variables.

Surgery time intervals

Mean total surgical time was 34.3 ± 10.5 minutes (range, 17.0 to 61.6 minutes). Searching the right ovary took significantly longer than the left ovary (right 3.5 ± 1.8 minutes versus left 2.6 ± 1.8 minutes; *P* = .007). Ovarian resection was significantly faster with LS versus TA (LS 3.5 ± 2.7 minutes versus TA 8.1 ± 4.2 minutes; *P* < .001; Fig 7.3).

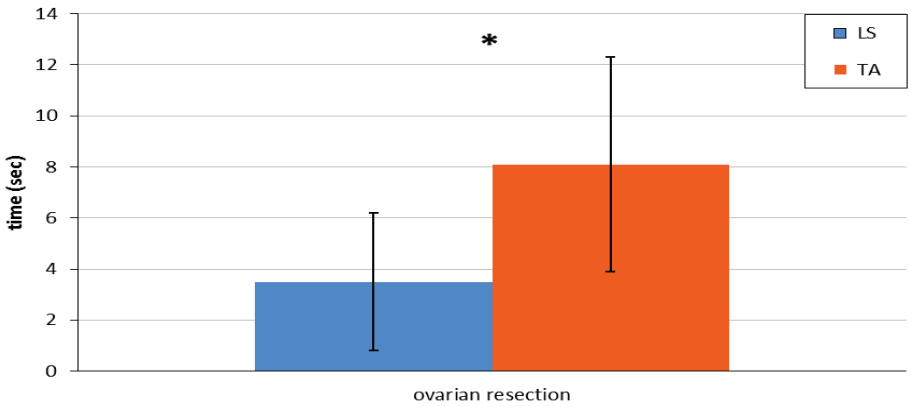

Figure 7.3 Ovarian resection times (SD depicted by error bar) were significantly different between LS and TA (data for left and right ovary combined) (* *P* < .05).

Intraoperative bleeding

Intraoperative bleeding occurred in 4 dogs (10%), equally distributed amongst the left and right ovarian pedicle. There was a significant difference between techniques, since all bleeding occurred when the BEC forceps was used (*P* = .044). Bleeding was easily controlled by reapplying the BEC forceps, but this resulted in a significantly longer ovarian resection time (bleeding 14.7 ± 6.0 minutes versus no bleeding 7.3 ± 3.4 minutes; *P* = .005). Total surgical time was, therefore, also significantly longer (bleeding 46.4 ± 9.9 minutes versus no bleeding 33.3 ± 9.9 minutes; *P* = .016; Fig 7.4).

Surgeon experience

The novice laparoscopic surgeon had significantly longer ovarian resection times compared to the experienced laparoscopic surgeon. This was both the case for LS (novice 4.7

± 3.3 minutes versus experienced 2.4 ± 1.0 minutes; *P* = .002), and TA (novice 9.9 ± 4.4 minutes versus experienced 6.3 ± 3.2 minutes; *P* = .002). Also, changing sides and moving the laparoscopy trolley after left ovarian resection, took significantly longer for the novice surgeon (novice 4.4 ± 2.9 minutes versus experienced 1.9 ± 0.7 minutes; *P* < .001). This resulted in 24% longer total surgical times for the novice surgeon (novice 38.7 ± 11.4 minutes versus experienced 30.5 ± 7.7 minutes; P = .028).

One incidence of intraoperative bleeding occurred with the experienced surgeon and 3 incidences occurred with the novice surgeon, but this difference was not significantly different.

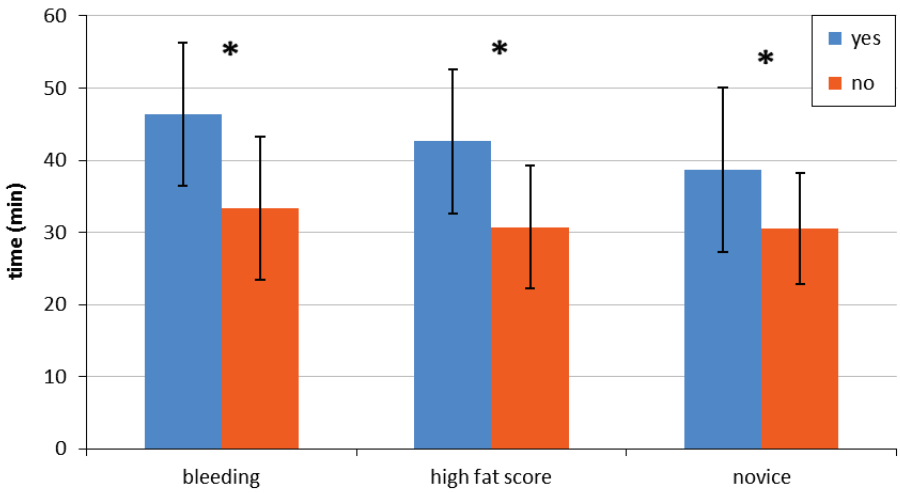

Figure 7.4 Total surgery time (SD depicted by error bar) was significantly different in case of intra-operative ovarian pedicle stump bleeding, obesity and laparoscopic surgical experience (* *P* < .05).

Obesity and fat score

Total surgery time was significantly increased with increasing fat score of the ovarian pedicle (FS 1 30.7 ± 8.5 minutes versus FS3 42.6 ± 10.0 minutes; *P* = .027). Fat scores also had an effect on the efficiency of both energy-based hemostatic surgical devices. Ovarian resection times were significantly increased with higher fat scores for LS (FS 1 2.8 ± 1.4 minutes versus FS 3 5.4 ± 4.2 minutes; *P* = .031) and for TA (FS 1 6.1 ± 2.9 minutes versus FS 3 10.5 ±

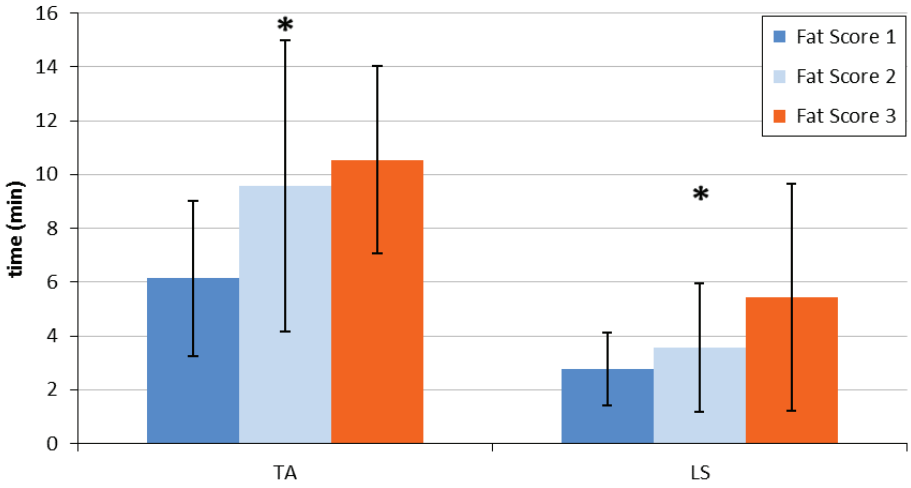

Figure 7.5 Ovarian excision times (SD depicted by error bar) significantly increased with higher Fat Scores of the ovarian pedicle for both the bipolar electrocoagulation grasping forceps (TA) and vessel sealing device (LS) (* *P* < .05).

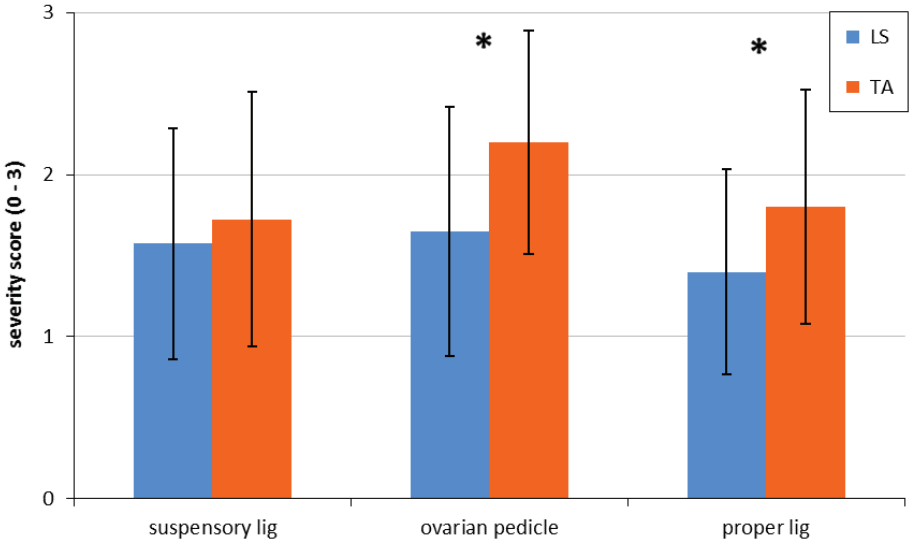

Figure 7.6 Electrothermal damage as evaluated by the histological severity score (SD depicted by error bar) was significantly different at the ovarian pedicle and the proper ligament (* *P* < .05).

3.5 minutes; *P* = .013; Fig 7.5). Time to remove the left ovary from the abdominal cavity was significantly increased with higher fat scores (FS 1 1.8 ± 1.2 minutes versus FS 3 0.9 ± 0.9 minutes; *P* = .029). The difference in removal of the right ovary from the abdomen was not significant. Electrothermal tissue damage was not affected by fat score. External obesity score did not significantly influence any of the investigated parameters, but was significantly related to the fat score of the ovarian pedicle (*P* = .006).

Histological examination

Mean depth of electrothermal coagulation damage was 1.7 ± 0.9 mm (range, 0.5 to 4.0 mm), and this was not significantly different for LS versus TA. The histological scoring system did find significantly lower electrothermal damage scores for LS versus TA at the level of the ovarian pedicle (LS 1.7 ± 0.8 versus TA 2.2 ± 0.7; *P* = .007), and the proper ligament (LS 1.4 ± 0.6 versus TA 1.8 ± 0.7; *P* = .025) (Fig 7.6).

Discussion

In this study on canine lap OVE, the vessel sealing device (LS) was 26% faster for the ovarian resection compared to a bipolar electrocoagulation grasping forceps combined with laparoscopic scissors. Canine *in vivo* studies comparing the efficiency of energy-based hemostatic surgical devices are scarce in veterinary medicine.[11,13,15,27,28] Mayhew and Brown (2007) compared a VSD with suture and clip ligation of the ovarian pedicle during laparoscopic-assisted ovariohysterectomy, and found the VSD to significantly shorten surgical time.[10] But for a comparison between vessel sealing and bipolar electrocoagulation we have to turn to human medicine, where a meta-analysis based on 29 prospective randomized trials, found a mean operative time reduction of 28% was found.[29] This number is comparable to our findings.

The reduction of operative time with VSDs seen in this study may have several reasons. Whilst both instruments provide hemostasis through electrothermal tissue effects from bipolar energy, their hemostatic action is quite different. The BEC forceps induces vessel

crenation and the development of a proximal intravascular thrombus leading to vascular occlusion.[19] VSDs, on the other hand, use energy and pressure to induce protein denaturing leading to the fusion of collagen and elastin from the vessel wall and surrounding connective tissue.[30] The energy activation times to achieve their respective hemostatic effect will therefore vary. Moreover, the vessel sealing generator is feedback-controlled, giving the operator an audible signal when a vascular seal is created.[19] In contrast, the BEC forceps has to be manually deactivated when the operator is satisfied with visual changes suggesting the formation of a vascular seal. The latter can also explain the differences in surgical times between the experienced and novice surgeon. But the most obvious difference between these two instruments is that the used VSD is an all-in-one instrument that is able to separate tissues after sealing, by using the incorporated blade.[19] The BEC forceps only coagulates tissue, and relies on the introduction of separate laparoscopic scissors for tissue transection. These multiple actions, coagulating interspersed with cutting, decrease surgical efficiency (surgical time benefit) and increase the risk for complications (inadvertent cannula pull out, abdominal organ damage by repeated introduction of instruments, etc.).[11]

Although both energy-based hemostatic surgical devices achieved successful ovarian pedicle hemostasis, nevertheless intraoperative bleeding was observed with the BEC instrument (in 10% of the cases). All complications were quickly resolved using the same instrument on the tissue and coagulating the area of bleeding. Diamantis et al (2006) compared BEC and VSD on the short gastric arteries in rabbits, and noted complete hemostasis without any complication with VSD, but BEC often resulted in failed coagulation.[12] Both instruments have been shown to reliably create a vascular seal on harvested tissues with BEC creating adequate bursting pressure up to 3 mm arteries and for VSD even up to 7 mm arteries.[20] Bleeding with the BEC instrument is therefore not caused by exceeding the instruments capabilities regarding vascular diameter.[13] We rather assume that bleeding in this study was partly related to the two-instrument-approach during BEC. With LS, the combined sealing and cutting instrument places the cut precisely in the middle of the coagulated or sealed tissue.[19] In a two-instrument-approach the grasped tissues are flattened between the instruments jaws during coagulation, but will expend back to their original three-dimensional configuration as soon as released thereby distorting the original seal line. This may lead to inaccurate assessment of the correct cutting angle with scissors and a higher risk for bleeding.

One incidence of intraoperative bleeding occurred with the experienced laparoscopic surgeon and 3 incidences occurred with the novice laparoscopic surgeon. We believe this reflects the operator dependent nature of the BEC technique, which relies on visual interpretation of the coagulated tissue to assume a vascular seal, something that can easily lead to underestimating the correct amount of energy needed to achieve vascular hemostasis. Also, for the VSD significantly longer surgical times were seen for the novice surgeon. the existence of a learning curve has not been previously described for a VSD. The feedback-controlled function of the VSD would actually eliminate a learning curve.[19] Mayhew et al (2007) detected a learning curve for the laparoscopic application of vascular clips and suture ligation, but not for the VSD instrument.[10] Yet, all three-dimensional manipulation during laparoscopic surgery has inherent difficulties because of the spatial interpretation based on the two-dimensional monitor.[31] And apart from orienting the instrument, figuring out the maximum amount of tissue that can be grasped to form a successful seal, also requires the necessary experience with a specific instrument. Both of these situations are not encountered in experimental *ex vivo* research and have therefore not been addressed earlier. Guizzo et al (2015) observed two cases of bleeding from the ovarian pedicle in dogs and did relate this to instrument inexperience (too short an exposure of the grasped tissue to ultrasonic energy or exaggerated traction on the pedicle during coagulation).[28]

An important aspect of energy-based hemostatic surgical devices is the development of thermal coagulation damage to the surrounding tissues.[32] This undesirable result of the coagulation process can be evaluated and measured by histological examination.[30] Collateral tissue damage extending 1 - 3 mm for VSD and 1 - 6 mm for BEC was previously described.[22] The values found in this study (1.7 ± 0.9 mm) are well within these limits. Mean depth of electrothermal coagulation damage was not significantly different between the two investigated instruments. But the histologic scoring system noted significantly less damage with LS compared to TA at the ovarian pedicle and the proper ligament. An earlier *in vivo* comparison between VSD and BEC also found more thermal injury with BEC.[12] Pressurization of the tissue in the locked VSD instrument and applying the pulsed energy needed for hemostasis based on real-time measurement of tissue impedance optimizes the coagulation process to produce a translucent seal of partially denatured protein.[19,33] Not surprisingly, the resulting lower collateral histological damage score is most prominent at the ovarian pedicle.

Since multiple activation cycles are required before final transection of this broad structure a cumulative thermal effect will be more pronounced at this location. Minimization of thermal spread is important in lap OVE due to the presence of important structures adjacent to the ovarian pedicle (ureters).[10]

The presence of obesity, in this study evaluated based on the external appearance of the dog, had no significant influence on measured parameters (no effect on surgical times nor electrothermal damage). Fat scores, based on intra-abdominal observation during surgery, were a more reliable factor affecting total surgical time, ovarian resection times for both instruments, and removal time for the left ovary. Other researchers have previously also established that fat scores affect procedural times during laparoscopic ovariectomy.[15,27]

The amount of energy needed to create a vascular seal increases with increasing amounts of tissue.[20,34] When tissue is thick (> 5 mm) and has a deeply located vessel, as with the ovarian pedicle in obese dogs, some have advocated to use multiple coagulation applications with TA.[14] Consequently, the amount of thermal coagulation damage will increase.[35] Novice surgeons, realizing that this is the location most often responsible for postoperative bleeding, may be tempted to apply more energy since visual confirmation of a vascular seal in this location is sometimes difficult. However, we did not find a significant difference in electrothermal damage based on surgical experience. And the increase in surgical ovarian resection time for TA with higher fat scores, was also seen with LS.

The use of multiple overlapping seals to achieve a more secure hemostatic effect has also been described for the VSD.[36] Still, others have expressed concerns that the repeated application of a VSD may actually negatively influence the strength of the seal because of local heat production.[37] Therefore, separating the broad ovarian pedicle in appropriate chunks of tissue suitable for a single seal resulted in the best combination of vascular seal reliability with the least thermal damage.[35] This was also the technique applied in this study.

The TA forceps is able to grasp more tissue in a single action compared to the LS forceps because the jaws open up wider and the jaw length is longer which results in a larger contact surface (TA 125 mm^2 versus LS 58 mm^2). Furthermore, the structured contact surface of the TA forceps offers a better grip on grasped tissues and allows for better energy dispersal.[38] For obese dogs with broad ovarian pedicles (associated with high fat scores in this study) this could

have resulted in an advantage for the TA forceps. Still, both instruments experienced a significant increase in ovarian excision duration for high fat scores: a 72% increase for TA and 100% increase for LS (the difference between the two instruments was not statistically different).

We conclude that the new VSD LS was superior to the BEC TA forceps for canine lap OVE: excision of the ovaries was faster, no bleeding of the ovarian pedicle occurred and electrothermal damage to surrounding tissues was less. Despite the feedback-controlled function this instrument, just like other electrosurgical devices, has a learning curve.

References

1. Hoglund OV, Olsson K, Hagman R, Ohlund M, Olsson U, Lagerstedt AS: Comparison of haemodynamic changes during two surgical methods for neutering female dogs. Res Vet Sci 2011;91(1):159-163.
2. Davidson EB, Moll HD, Payton ME: Comparison of laparoscopic ovariohysterectomy and ovariohysterectomy in dogs. Vet Surg 2004;33(1):62-69.
3. Hancock RB, Lanz OI, Waldron DR, Duncan RB, Broadstone RV, Hendrix PK: Comparison of postoperative pain after ovariohysterectomy by harmonic scalpel-assisted laparoscopy compared with median celiotomy and ligation in dogs. Vet Surg 2005;34(3):273-282.
4. Marcovich R, Williams AL, Seifman BD, Wolf JS: A canine model to assess the biochemical stress response to laparoscopic and open surgery. J Endourol 2001;15(10):1005-1008.
5. Lee JY, Kim MC: Comparison of oxidative stress status in dogs undergoing laparoscopic and open ovariectomy. J Vet Med Sci 2014;76(2):273-276.
6. Schippers E, Tittel A, Ottinger A, Schumpelick V: Laparoscopy versus laparotomy: comparison of adhesion-formation after bowel resection in a canine model. Dig Surg 1998;15(2):145-147.
7. Gamal EM, Metzger P, Szabo GY, Brath E, Peto K, Olah A, Kiss J, Furka I, Miko I: The influence of intraoperative complications on adhesion formation during laparoscopic and conventional cholecystectomy in an animal model. Surg Endosc-Ultras 2001;15(8):873-877.
8. Culp WTN, Mayhew PD, Brown DC: The effect of laparoscopic versus open ovariectomy on postsurgical activity in small dogs. Vet Surg 2009;38(7):811-817.
9. Devitt CM, Cox RE, Hailey JJ: Duration, complications, stress, and pain of open ovariohysterectomy versus a simple method of laparoscopic-assisted ovariohysterectomy in dogs. J Am Vet Med Assoc 2005;227(6):921-927.
10. Mayhew PD, Brown DC: Comparison of three techniques for ovarian pedicle hemostasis during laparoscopic-assisted ovariohysterectomy. Vet Surg 2007;36(6):541-547.

11. Van Goethem B, Rosenveldt KW, Kirpensteijn J: Monopolar versus bipolar electrocoagulation in canine laparoscopic ovariectomy: a nonrandomized, prospective, clinical trial. Vet Surg 2003;32(5):464-470.
12. Diamantis T, Kontos M, Arvelakis A, Syroukis S, Koronarchis D, Papalois A, Agapitos E, Bastounis E, Lazaris AC: Comparison of monopolar electrocoagulation, bipolar electrocoagulation, ultracision, and LigaSure. Surg Today 2006;36(10):908-913.
13. van Nimwegen SA, Van Swol CFP, Kirpensteijn J: Neodymium:Yttrium aluminum garnet surgical laser versus bipolar electrocoagulation for laparoscopic ovariectomy in dogs. Vet Surg 2005;34(4):353-357.
14. Remorgida V: A new instrument for advanced laparoscopic surgery: a reusable bipolar forceps with grasping and cutting capacity. Minim Invasive Ther Allied Technol 1997;6(2):132-134.
15. van Nimwegen SA, Kirpensteijn J: Comparison of Nd:YAG surgical laser and Remorgida bipolar electrosurgery forceps for canine laparoscopic ovariectomy. Vet Surg 2007;36(6):533-540.
16. Turi A, Nemeth T: Comparison of two different electrosurgical haemostatic devices for laparoscopic surgery in small animals. Magy Allatorvosok Lapja 2015;137(5):293-304.
17. Wenkel R, Ziemann U, Thielebein J, Prange H: Laparoskopische Kastration der Hündin: Darstellung neuer Verfahren zur minimal invasieven Ovariohysterektomie. Tierarztl Prax 2005;33(177-188.
18. Ohlund M, Hoglund O, Olsson U, Lagerstedt AS: Laparoscopic ovariectomy in dogs: a comparison of the LigaSure and the SonoSurg systems. J Small Anim Pract 2011;52(6):290-294.
19. Kennedy JS, Stranahan PL, Taylor KD, Chandler JG: High-burst-strength, feedback-controlled bipolar vessel sealing. Surg Endosc-Ultras 1998;12(6):876-878.
20. Harold KL, Pollinger H, Matthews BD, Kercher KW, Sing RF, Heniford BT: Comparison of ultrasonic energy, bipolar thermal energy, and vascular clips for the hemostasis of small-, medium-, and large-sized arteries. Surg Endosc 2003;17(8):1228-1230.
21. Newcomb WL, Hope WW, Schmelzer TM, Heath JJ, Norton HJ, Lincourt A, Heniford BT, Iannitti DA: Comparison of blood vessel sealing among new electrosurgical and ultrasonic devices. Surg Endosc 2009;23(1):90-96.
22. Landman J, Kerbl K, Rehman J, Andreoni C, Humphrey PA, Collyer W, Olweny E, Sundaram C, Clayman RV: Evaluation of a vessel sealing system, bipolar electrosurgery, harmonic scalpel, titanium clips, endoscopic gastrointestinal anastomosis vascular staples and sutures for arterial and venous ligation in a porcine model. J Urology 2003;169(2):697-700.
23. Dubiel B, Shires PK, Korvick D, Chekan EG: Electromagnetic energy sources in surgery. Vet Surg 2010;39(8):909-924.
24. Van Goethem B, Bosch M, Stegen L: Laparoscopie in de gezelschapsdierenpraktijk. Deel 1: instrumentarium en basisprincipes. Vlaams Diergeneeskd Tijdschr 2009;78:365-371.
25. Gross ME, Dodam JR, Faunt KK: Anesthetic considerations for endoscopy, in McCarthy TC (ed): Veterinary endoscopy for the small animal practitioner, St. Louis, Missouri, Elsevier Saunders, 2005, pp 21-29.
26. Impellizeri JA, Tetrick MA, Muir P: Effect of weight reduction on clinical signs of lameness in dogs with hip osteoarthritis. J Am Vet Med Assoc 2000;216(7):1089-1091.
27. Dupre G, Fiorbianco V, Skalicky M, Gultiken N, Ay SS, Findik M: Laparoscopic ovariectomy in dogs: comparison between single portal and two-portal access. Vet Surg 2009;38(7):818-824.
28. Guizzo N, Feranti JPS, Bairros MC, Bortoluzzi M, Motta AC, Sartori LW, Santos FR, Tomazzoni FV, Brambatti G, Guedes RL, Silva MAM, Brun MV: Ultrasonic shears and bipolar vessel-sealing

system for three-port laparoscopic ovariohysterectomy in dogs. Arq Bras Med Vet Zootec 2015;67(1):55-61.
29. Macario A, Dexter F, Sypal J, Cosgriff N, Heniford BT: Operative time and other outcomes of the electrothermal bipolar vessel sealing system (LigaSure) versus other methods for surgical hemostasis: a meta-analysis. Surg Innov 2008;15(4):284-291.
30. Sahin DA, Kusaslan R, Sahin O, Akbulut G, Bas O, Dilek ON: Histopathological effects of bipolar vessel sealing devices on liver parenchyma and comparison with suture method: an experimental study. Eur Surg Res 2007;39(2):111-117.
31. Mayhew PD: Complications of minimally invasive surgery in companion animals. Vet Clin North Am Small Anim Pract 2011;41(5):1007-1021.
32. Phillips CK, Hruby GW, Duvak E, Lehman DS, Humphrey PA, Mansukhani MM, Landman J: Tissue response to surgical energy devices. Urology 2008;71(4):744-748.
33. Peycke LE: Facilitation of soft tissue surgery surgical staplers and vessel sealing devices. Vet Clin North Am Small Anim Pract 2015;45(3):451-461.
34. Carbonell AM, Joels CS, Kercher KW, Matthews BD, Sing RF, Heniford BT: A comparison of laparoscopic bipolar vessel sealing devices in the hemostasis of small-, medium-, and large-sized arteries. J Laparoendosc Adv S-Part A 2003;13(6):377-380.
35. Matz BM, Tillson DM, Boothe HW, Dillon RA, Cattley RC: Effect of vascular seal configuration using the LigaSure on arterial challenge pressure, time for seal creation, and histologic features. Vet Surg 2014;43(6):761-764.
36. Rivier P, Monnet E: Use of a vessel sealant device for splenectomy in dogs. Vet Surg 2011;40(1):102-105.
37. Barrera JS, Monnet E: Effectiveness of a bipolar vessel sealant device for sealing uterine horns and bodies from dogs. Am J Vet Res 2012;73(2):302-305.
38. Richter S, Kollmar O, Schilling MK, Pistorius GA, Menger MD: Efficacy and quality of vessel sealing - Comparison of a reusable with a disposable device and effects of clamp surface geometry and structure. Surg Endosc 2006;20(6):890-894.

8

Comparison of the efficacy of a bipolar vessel sealing device and a bipolar electrocoagulation cutting forceps in canine laparoscopic ovariectomy

Van Goethem B,[1] van Nimwegen SA,[1] Chiers K,[2] Kirpensteijn J[1,3]

submitted

[1]Department of Clinical Sciences of Companion Animals, Faculty of Veterinary Medicine, Utrecht University, Utrecht, the Netherlands.

[2]Department of Pathology, Bacteriology and Poultry Diseases, Faculty of Veterinary Medicine, Ghent University, Ghent, Belgium

[3]Current position: Hill's Pet Nutrition, 400 SW Topeka Ave, Topeka, KS 66047, USA

Abstract

Objective: To compare two commonly used laparoscopic energy-based hemostatic surgical devices: a bipolar vessel sealing device (LigaSure - LS) and a bipolar electrocoagulation cutting forceps (HotBlade - HB) during laparoscopic ovariectomy (lap OVE).

Study design: Prospective, randomized clinical trial.

Animals: Female dogs (n = 21) admitted for elective lap OVE.

Methods: The standard lap OVE technique was adapted to randomly assign one ovary to removal by LS and the contralateral by HB. Duration of predetermined surgery intervals and complications were compared between techniques. Additionally, the effects of several intraoperative variables on surgical time were evaluated and the resected ovary was histologically examined.

Results: Excision of the ovaries was significantly faster for LS (LS 2.5 ± 1.2 minutes versus HB 4.8 ± 1.8 minutes; $P < .001$). Intraoperative pedicle stump bleeding occurred in 29% of dogs, but only with HB. With either technique excision of the ovaries took significantly longer in obese animals. Mean depth of thermal coagulation was significantly less for LS (LS 93.4 ± 85.8 µm versus HB 130.9 ± 101.2 µm; $P < .001$). This difference was most clearly observed at the ovarian pedicle ($P = .003$) and the proper ligament ($P = .03$).

Conclusions: Lap OVE can be performed more rapidly with LS, with less chance of bleeding at the ovarian pedicle and with less thermal coagulation damage when compared to HB.

Clinical relevance: This study shows that LS has several advantages over HB in canine lap OVE.

Introduction

Maintenance of a bloodless surgical field is even more important in laparoscopic surgery than in conventional surgery, because of the relative inability to rapidly remove blood from the visual field.[1] The introduction of energy-based hemostatic surgical devices has expanded the arsenal of potential techniques available for hemostasis during laparoscopic surgery. These devices allow for rapid sequential tissue and vessel sealing, coagulation, and even transection. By reducing the need for earlier clamp-cut-and-tie methods, they have enabled remarkable progress in minimally invasive surgery.[2]

Energy-based hemostatic surgical devices achieve hemostasis by generating heat for protein denaturation, intraluminal thrombosis, and vessel sealing or coagulation.[3] Seal success is determined by the total amount of energy applied to the tissue, the maximum temperature reached, and the duration of coagulation.[4] Therefore, minimizing the amount of thermal damage to the surrounding tissues and improving the speed without compromising seal integrity are current paradigms in research on laparoscopic energy-based hemostatic surgical devices.[5]

LigaSure (LS; Covidien, Valleylab, Boulder, CO, USA; Fig 8.1) has been developed as a large-vessel sealing device and can also be used to grasp, seal, coagulate and cut soft tissues.[6] It was first described in 2005 for canine laparoscopic ovariohysterectomy.[7] HotBlade (HB; Patton Surgical, Austin, Tex, USA; Fig 8.2) is a 5 mm all-in-one laparoscopic instrument designed for grasping, dissecting, coagulating and cutting soft tissues.[8] This instrument is popular with general practitioners for economic reasons (the price of the hand instrument is lower compared to the vessel sealing device and it works with a standard bipolar energy generator).[9]

The objective of this study was to compare a bipolar vessel sealing device (LigaSure - LS) and a bipolar electrocoagulation cutting forceps (HotBlade - HB) during canine laparoscopic ovariectomy (lap OVE). Specific interest was on operating time differences, the amount of collateral thermal tissue damage, and possible dog-related influential variables (obesity, etc.).

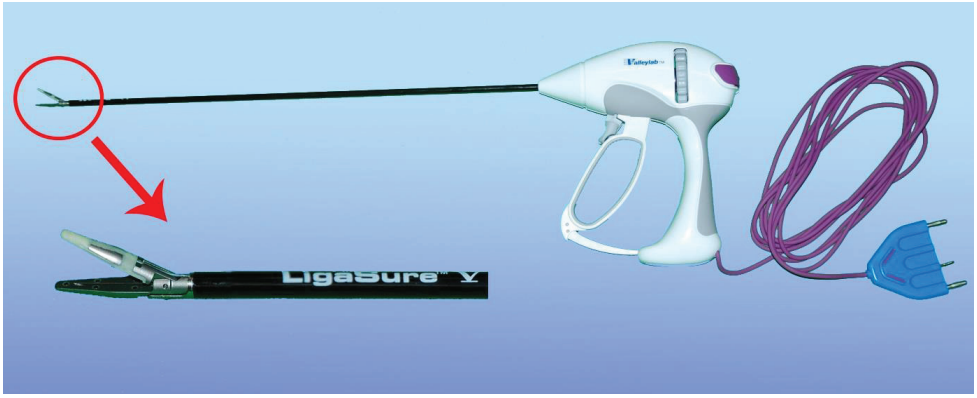

Figure 8.1 A 5 mm bipolar vessel sealing device (Dolphin-tipped LigaSure V, Covidien, Valleylab, Boulder, CO) was used for bipolar vessel sealing and dividing.

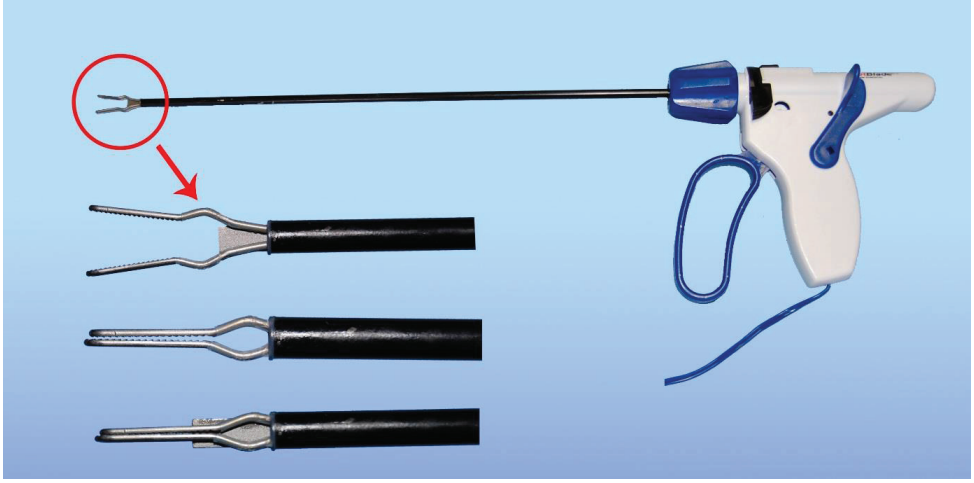

Figure 8.2 A 5 mm bipolar electrocoagulation cutting forceps (HotBlade, Patton Surgical, Austin, Tex) was used for tissue grasping, coagulating and cutting.

Materials and methods

Study Design

This study was a single-center, randomized, controlled, clinical trial with client consent obtained for all dogs. The two different lap OVE techniques were performed in each animal

based on previous randomization: the left ovarian pedicle was transected using LS or HB, upon which the right pedicle was transected with the alternate technique. A standardized surgery and anesthesia protocol was used.[10]

Patient Selection and randomization

Twenty-one client-owned dogs admitted for elective lap OVE, between September 2010 and August 2011, were included. Breed, age, bodyweight, and obesity scores[11] were recorded on admission. Randomization was performed preceding the study, and order of instruments was enclosed in an enveloped for each dog, to be opened by the surgeon at the start of surgery.

Surgical technique

All surgical procedures were performed by a single, experienced laparoscopic surgeon (JK). Video-assisted lap OVE was performed through 3 median portals. Dogs were positioned in dorsal recumbency in a 10° Trendelenburg position. A modified Hasson's approach was used at the caudal portal followed by insertion of an 11 mm threaded cannula (Ternamian EndoTIP cannula; Karl Storz Endoscopy, Tuttlingen, Germany). CO_2-flow was first set at 1 L/minutes to verify proper abdominal placement of the cannula, after which the abdomen was insufflated at 6 L/minutes and the intra-abdominal pressure was kept at 8 mm Hg. A 5 mm zero degree telescope (Hopkins II, Karl Storz Endoscopy, Tuttlingen, Germany) was inserted through the cannula and two 6 mm threaded cannulae (Ternamian EndoTIP cannula size 6 mm; Karl Storz Endoscopy, Tuttlingen, Germany) were inserted under laparoscopic guidance, 2 cm caudal and 2 cm cranial to the umbilicus. After cannulae insertion, the endoscope was redirected to the middle portal.

In all dogs, the left ovary was resected first with the surgeon standing on the right side of the dog and changing sides for resection of the right ovary. The ovarian bursa was located by identifying the round ligament of the uterus at the inguinal ring and following it cranially using two endoscopic grasping forceps (Endo Dissect 5 mm and Endo Clinch II 5 mm; US Surgical Corporation, Norwalk, CT, USA). The bursa was grasped in the bursal opening with the

self-retaining forceps (Endo Clinch) inserted through the cranial portal. For ovarian resection, the energy-based hemostatic surgical device was consecutively applied across the proper ligament, ovarian pedicle, and suspensory ligament. For the LS technique a 5 mm Dolphin-tipped LigaSure V was used with the generator set at 3 bars (81 - 115 volts). For the HB technique a 5 mm HotBlade was used with the generator set at 25 - 35 watts.

When the ovary was freed from its pedicle the stump was checked for bleeding. The ovarian bursa containing the ovary was extracted from the abdomen using the (larger) caudal portal. All ovaries were checked for completeness after removal. Closure of the abdomen was performed in a routine fashion.

Postoperative care

Dogs were released from the hospital immediately after full recovery from anesthesia. Carprofen (2 mg/kg orally twice daily) was prescribed for pain management for 3 days postoperatively.

Recorded surgical variables

Total time of surgery (incision to final closure); separate time intervals of the procedure (including time from skin-incision to placement of trocars, from the start of searching for the left ovary to the placement of a forceps in the ovarian bursa, left ovarian resection, for turning of the surgeon and the equipment to the other side, time from the start of searching for the right ovary to the placement of a forceps in the ovarian bursa, right ovarian resection, time for removing the resected right ovary from the abdomen, and time for removing the resected left ovary from the abdomen). Additionally, the fat content of the ovarian pedicle was scored (fat score – FS: 0 = no fat, 1 = minimal fat, 2 = moderate fat, 3 = abundant fat), occurrence of intraoperative bleeding, and abnormalities of the ovaries or uterus were recorded.

Histological examination

The resected ovaries were fixed in 10% neutral buffered formalin, embedded in paraffin blocks according to their anatomic location (suspensory ligament, ovarian pedicle,

and proper ligament) and sectioned longitudinally. Hematoxylin and eosin staining of 5 µm sections was performed. Step segments were obtained through each specimen. An experienced pathologist (KC) reviewed each specimen and measured the depth of thermal damage (in µm), defined as microscopic areas of lost cellular borders and nuclear destruction.[12]

Statistical analysis

A power analysis was performed ($\beta = 0.90$; $\alpha = 0.05$, SD = 20%; estimated difference of 20%, based on previous studies)[10,13] and the number of samples needed was determined to be 20 per test group. A minimum of 20 dogs (40 ovaries) was therefore necessary.

A paired sample t-test was used to test for differences in duration of defined surgical stages of left versus right, LS versus HB and differences in histological parameters between groups. Nonparametric testing was performed for non-uniformly distributed data. An independent samples t-test and ANOVA were used to test for other (unpaired) variables such as occurrence of intraoperative bleeding between groups. $P < .05$ (2-tailed) were considered significant. Results are reported as mean ± SD unless stated otherwise.

Results

Population descriptives

Twenty-one dogs of various breeds (12 different dog breeds and 5 mixed breed dogs) were used. Mean age for all dogs was 2.6 ± 3.0 years (range, 0.5 to 13.0 years) and mean bodyweight was 24.4 ± 15.5 kg (range, 5.0 to 73.0 kg). Because both techniques were always tested on the same dog (left and right) there was no difference between groups with regard to the tested variables.

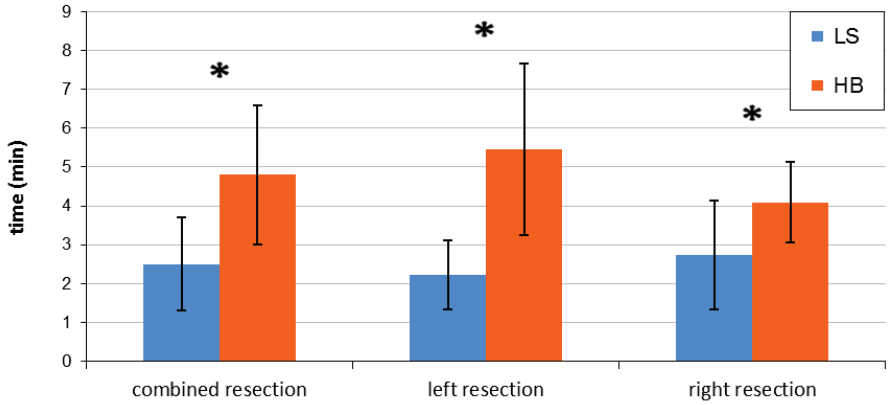

Figure 8.3 Ovarian excision times (SD depicted by error bar) were significantly different between LS and HB for excision of the left ovary, the right ovary, and combined data (independent of side) (* *P* < .05).

Surgical time intervals

Total surgical time was 32.0 ± 5.9 minutes (range, 23.3 to 44.1 minutes). Excising the ovaries was significantly faster with LS (LS 2.5 ± 1.2 minutes versus HB 4.8 ± 1.8 minutes; *P* < .001; Fig 8.3). This time difference was also significant for each side separately (left: LS 2.2 ± 0.9 minutes versus HB 5.5 ± 2.2 minutes; *P* = .001 and right: LS 2.7 ± 1.4 minutes versus HB 4.1 ± 1.0 minutes; *P* = .02; Figure 8.3). Removal of the left ovary from the abdomen was significantly faster than the right ovary (1.7 ± 0.4 minutes versus 2.0 ± 0.3 minutes; *P* = .048). Other procedural times were not significantly different between left versus right side.

Intraoperative bleeding

Intraoperative bleeding occurred in 6/42 ovaries (14%). There was a significant difference since all bleeding occurred with HB (*P* = .01). Bleeding was however easily controlled by reapplying the HB forceps and did not affect total surgery time or ovary resection time. Bleeding occurred at the left ovarian pedicle in 2 dogs and in 4 dogs at the right ovarian pedicle.

Histological coagulation damage

Depth of thermal coagulation was significantly different between the techniques for the ovarian pedicle (LS 40.5 ± 25.0 µm versus HB 66.0 ± 38.6 µm; P = .003), but was not significantly different for the suspensory ligament (LS 74.4 ± 47.3 µm versus HB 90.5 ± 41.6 µm) and the proper ligament (LS 163.5 ± 104.8 µm versus HB 232.3 ± 104.4 µm). Combined data for all locations showed that coagulation depth was significantly less for LS versus HB (LS 93.4 ± 85.8 µm versus HB 130.9 ± 101.2 µm; P < .001) (Fig 8.4).

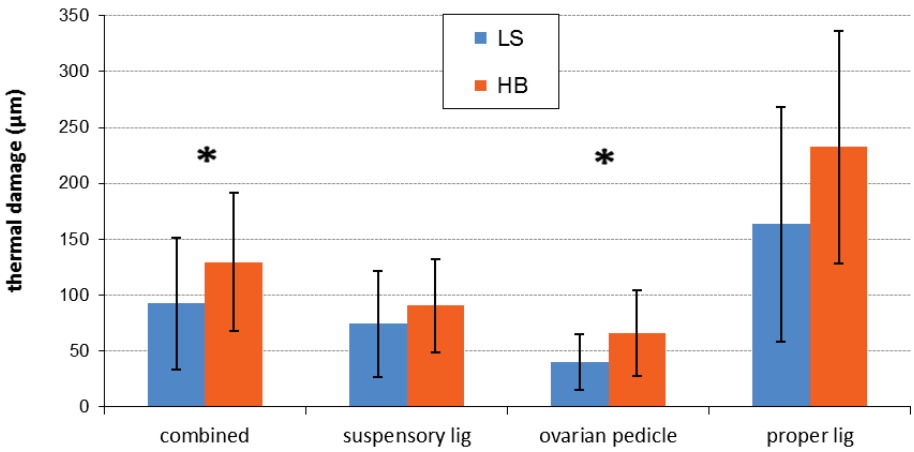

Figure 8.4 Depth of thermal coagulation damage (SD depicted by error bar) was significantly different between LS and HB for the ovarian pedicle, and for combined data (independent of location) (* P < .05).

Other variables

The fat score of the ovarian ligament had a significant effect on total surgical time (P = .018). Both LS and HB were significantly faster with a lower fat score (respectively P = .019 and P < .001).

Discussion

The introduction energy-based hemostatic surgical devices has resulted in more efficient and cost-efficient surgery by limiting the application of mechanical devices such as clips and staples to larger vessels and more vascular tissues.[14] The presence of objective data comparing the safety and efficacy of these devices is, however, limited. Many publications describe vascular seals with supraphysiologic bursting pressures in blood vessels harvested from dogs,[15,16] pigs,[5,17-19] and cows.[20] But the true merits of laparoscopic energy-based hemostatic surgical devices have been poorly characterized in *in vivo* studies. Only a few reports actually compare the efficacy of different energy-based hemostatic surgical devices during canine gonadectomy.[1,10,13,21,22]

This study suggests that LS is more efficient and safer than HB during canine lap OVE. Resection of the ovaries was significantly faster for LS versus HB. This time difference is the result of the dissimilar working mechanism of these two bipolar energy-based hemostatic surgical devices. The VSD generator measures the electrical impedance of the tissue at the seal site and the amount of energy delivered is modified accordingly until a permanent seal is created by fusing collagen and elastin from the vessel wall.[15] When the tissue impedance measurement indicates that an acceptable seal is created, the cycle is terminated by the generator and the operator is signaled by an audible tone. With an activation time of approximately 2 - 6 seconds this vascular seal is quickly achieved.[6,19] Bipolar electrocoagulation (BEC) on the other hand causes hemostasis by both vessel desiccation and crenation, together with the generation of a proximal intravascular thrombus.[6,23] This coagulation seal takes longer when compared to bipolar vessel sealing.[5,20] Additionally, the BEC generator has no feedback function and so deactivation of the hand instrument relies on operator experience to determine when a proper vascular seal has been created.[21] Since visual changes, compatible with the formation of a vascular coagulation seal (discoloration, shrinking), are often difficult to accurately assess before actual vessel division, careful laparoscopic surgeons will use longer activation times than strictly necessary.[19]

Monopolar electrosurgery has thermal damage reported to spread out as far as 10 - 20 mm from the point of application.[2] BEC is historically associated with up to 8 mm of

surrounding thermal damage.[14,24] But technological improvements have managed to decreased surrounding thermal damage for newer bipolar forceps, resulting in 2 - 6 mm for Klepinger (Karl Storz, Culver City, California) and 1 - 5 mm for Trimax (United States Surgical).[19] The described surrounding thermal spread for LS is 1.2 - 6.0 mm, depending on the amount of tissue grasped.[14,17-19,24-26] But since all of these studies are performed on non-perfused cadaver tissue samples, they might not reflect the true situation *in vivo*. In our study the measured thermal damage depths were 33% less for LS compared to HB. Again, this reflects the difference in working mechanism between VSD and BEC. Vessel sealing uses temperatures below 100 °C to melt and fuse the vessel wall.[6] Measured temperatures at the tip of the 5 mm LS instrument are between 39.5 - 96.4 °C,[14,24,27-29] and tissue temperatures 2 mm away from the LS instrument are 56 °C.[20] BEC devices use higher amounts of energy, resulting in temperatures well above 100 °C at the tip of the BEC forceps.[30]

Apart from the instrument temperature also the time of exposure to this temperature is a critical factor in inducing thermal damage.[14] Ovarian resection time in this study was determined by the instrument's hemostatic cycle time and the number of activations. Because ovarian resection time was longer for HB than for LS, instrument contact time was longer, and more thermal damage was observed in the resected tissues.

The HB forceps does have articulated jaws, due to specific electric transmission, and thus differs from standard grasping forceps. Tissue compression in the HB instrument is limited by the spring tension and therefore less than in VSD.[4,8] The two nearby points of the electrical system are consequently further apart, resulting in a larger amount of energy passing through the surrounding tissues.[28] Regardless of the energy-based hemostatic surgical device used, the amount of thermal injury increases with the amount of tissue grasped.[17]

Other factors such as chemical composition and vascularity of the tissues being resected are also likely to be important in establishing the amount of peripheral damage associated with different energy-based hemostatic surgical devices.[14,31] Therefore, differences were observed between the different locations: decreased depth of thermal damage with LS for the ovarian pedicle, but not for the suspensory and proper ligament). The presence of multiple vessels in the ovarian pedicle act as a heat sink and decrease the thermal effect on the surrounding tissues. Even when vessels are clamped, the proximal arterial pressure causes

flow turbulence and fluid turnover with concomitant dissipation of energy at the ligated edge.[14] Another possible explanation for the time difference at the ovarian pedicle, as well as the thermal depth difference between LS and HB at the ovarian pedicle, is that concerns about potential bleeding from this highly vascular structure may have the surgeon activating the non-feedback HB instrument for a longer time.

There is no question that on occasion, energy-based hemostatic surgical devices fail to obtain hemostasis, and thus manufacturers have focused a considerable amount of time and energy on improving their devices to optimize their function.[31] These improvements have led to HB, a bipolar electrocoagulation device where the cutting blade becomes part of the electrical circuit during cutting, thereby creating coagulation along the surface of the cutting blade to ensure a reduction in bleeding compared to conventional knife blade instruments. Still, intraoperative pedicle stump bleeding only occurred with HB (in 29%). This can be explained since VSD create seals that resist dislodgement because they are intrinsic to the vessel wall structure.[6] Experimental contamination of the instrument tip with coagulated tissue or blood *ex vivo*, had no significant impact on seal success and only a limited effect on seal stability.[4] But BEC relies on vessel desiccation and intravascular thrombosis formation and because HB is not feedback controlled, it is subject to operator error: too little energy application results in an insufficient coagulum, resulting in failed hemostasis.[8,19]

With both techniques excision of the ovaries took longer in obese animals, which is consistent with earlier reports.[10,13,21] The longer surgical times are explained by the increased number of sequential actions (grasping, coagulation/vessel sealing, and transection) required in a larger ovarian pedicle.

HB has great utility for the economy-minded surgeon, and is effective with sufficient experience. LS was, however, more efficient than HB during canine lap OVE: it decreased surgical time for ovarian excision, consistently created a vascular seal (no intraoperative bleeding), and produced less surrounding thermal damage.

References

1. Mayhew PD, Brown DC: Comparison of three techniques for ovarian pedicle hemostasis during laparoscopic-assisted ovariohysterectomy. Vet Surg 2007;36:541-547.
2. Dubiel B, Shires PK, Korvick D, Chekan EG: Electromagnetic energy sources in surgery. Vet Surg 2010;39:909-924.
3. Diamantis T, Kontos M, Arvelakis A, Syroukis S, Koronarchis D, Papalois A, Agapitos E, Bastounis E, Lazaris AC: Comparison of monopolar electrocoagulation, bipolar electrocoagulation, ultracision, and LigaSure. Surg Today 2006;36:908-913.
4. Wallwiener CW, Junginger SH, Zubke W, Brucker SY, Enderle MD, Neugebauer A, Schonfisch B, Wallwiener M: Bipolar vessel sealing: instrument contamination and wear have little effect on seal quality and success in a porcine in vitro model. Langenbecks Arch Surg 2014;399:863-871.
5. Newcomb WL, Hope WW, Schmelzer TM, Heath JJ, Norton HJ, Lincourt A, Heniford BT, Iannitti DA: Comparison of blood vessel sealing among new electrosurgical and ultrasonic devices. Surg Endosc 2009;23:90-96.
6. Kennedy JS, Stranahan PL, Taylor KD, Chandler JG: High-burst-strength, feedback-controlled bipolar vessel sealing. Surg Endosc-Ultras 1998;12:876-878.
7. Wenkel R, Ziemann U, Thielebein J, Prange H: Laparoskopische Kastration der Hündin: Darstellung neuer Verfahren zur minimal invasieven Ovariohysterektomie. Tierarztl Prax 2005;33:177-188.
8. Huhn JC: Stapling and energy devices for endoscopic surgery, in Tams TR, Rawlings CA (eds): Small Animal Endoscopy (3rd ed), St. Louis, Missouri, Mosby, 2011, pp 363-370.
9. Van Goethem B, Bosch M, Stegen L: Laparoscopie in de gezelschapsdierenpraktijk. Deel 1: instrumentarium en basisprincipes. Vlaams Diergeneeskd Tijdschr 2009;78:365-371.
10. van Nimwegen SA, Kirpensteijn J: Comparison of Nd:YAG surgical laser and Remorgida bipolar electrosurgery forceps for canine laparoscopic ovariectomy. Vet Surg 2007;36:533-540.
11. Impellizeri JA, Tetrick MA, Muir P: Effect of weight reduction on clinical signs of lameness in dogs with hip osteoarthritis. J Am Vet Med Assoc 2000;216:1089-1091.
12. Klar M, Haberstroh J, Timme S, Fritzsch G, Gitsch G, Denschlag D: Comparison of a reusable with a disposable vessel-sealing device in a sheep model: efficacy and costs. Fertil Steril 2011;95:795-798.
13. van Nimwegen SA, Van Swol CFP, Kirpensteijn J: Neodymium:Yttrium aluminum garnet surgical laser versus bipolar electrocoagulation for laparoscopic ovariectomy in dogs. Vet Surg 2005;34:353-357.
14. Phillips CK, Hruby GW, Duvak E, Lehman DS, Humphrey PA, Mansukhani MM, Landman J: Tissue response to surgical energy devices. Urology 2008;71:744-748.
15. Matz BM, Tillson DM, Boothe HW, Dillon RA, Cattley RC: Effect of vascular seal configuration using the LigaSure on arterial challenge pressure, time for seal creation, and histologic features. Vet Surg 2014;43:761-764.
16. Bubenik LJ, Hosgood G, Vasanjee SC: Bursting tension of medium and large canine arteries sealed with ultrasonic energy or suture ligation. Vet Surg 2005;34:289-293.
17. Carbonell AM, Joels CS, Kercher KW, Matthews BD, Sing RF, Heniford BT: A comparison of laparoscopic bipolar vessel sealing devices in the hemostasis of small-, medium-, and large-sized arteries. J Laparoendosc Adv S-Part A 2003;13:377-380.

18. Harold KL, Pollinger H, Matthews BD, Kercher KW, Sing RF, Heniford BT: Comparison of ultrasonic energy, bipolar thermal energy, and vascular clips for the hemostasis of small-, medium-, and large-sized arteries. Surg Endosc 2003;17:1228-1230.
19. Landman J, Kerbl K, Rehman J, Andreoni C, Humphrey PA, Collyer W, Olweny E, Sundaram C, Clayman RV: Evaluation of a vessel sealing system, bipolar electrosurgery, harmonic scalpel, titanium clips, endoscopic gastrointestinal anastomosis vascular staples and sutures for arterial and venous ligation in a porcine model. J Urology 2003;169:697-700.
20. Lamberton GR, Hsi RS, Jin DH, Lindler TU, Jellison FC, Baldwin DD: Prospective comparison of four laparoscopic vessel ligation devices. J Endourol 2008;22:2307-2312.
21. Van Goethem B, Rosenveldt KW, Kirpensteijn J: Monopolar versus bipolar electrocoagulation in canine laparoscopic ovariectomy: a nonrandomized, prospective, clinical trial. Vet Surg 2003;32:464-470.
22. Guizzo N, Feranti JPS, Bairros MC, Bortoluzzi M, Motta AC, Sartori LW, Santos FR, Tomazzoni FV, Brambatti G, Guedes RL, Silva MAM, Brun MV: Ultrasonic shears and bipolar vessel-sealing system for three-port laparoscopic ovariohysterectomy in dogs. Arq Bras Med Vet Zootec 2015;67:55-61.
23. Alkatout I, Schollmeyer T, Hawaldar NA, Sharma N, Mettler L: Principles and safety measures of electrosurgery in laparoscopy. JSLS 2012;16:130-139.
24. Hruby GI, Marruffo F, Durak E, Collins SM, Pierorazio PM, Humphrey PA, Mansukhani MM, Landman J: Evaluation of surgical energy-devices for vessel sealing and peripheral energy spread in a porcine model: Harmonic ACE, harmonic LCS-C5, LigaSure V, and Trisector. J Urology 2007;177:318-318.
25. Prokopakis EP, Lachanas VA, Vardouniotis AS, Velegrakis GA: The use of the LigaSure vessel sealing system in head and neck surgery: a report on six years of experience and a review of the literature. B-Ent 2010;6:19-25.
26. Sahin DA, Kusaslan R, Sahin O, Akbulut G, Bas O, Dilek ON: Histopathological effects of bipolar vessel sealing devices on liver parenchyma and comparison with suture method: an experimental study. Eur Surg Res 2007;39:111-117.
27. Kim FJ, Chammas MF, Gewehr E, Morihisa M, Caldas F, Hayacibara E, Baptistussi M, Meyer F, Martins AC: Temperature safety profile of laparoscopic devices: Harmonic ACE (ACE), LigaSure V (LV), and plasma trisector (PT). Surg Endosc 2008;22:1464-1469.
28. Eto K, Omura N, Haruki K, Uno Y, Ohkuma M, Nakajima S, Anan T, Kosuge M, Fujita T, Yanaga K: A comparison of laparoscopic energy devices on charges in thermal power after application to porcine mesentery. Surg Laparosc Endosc Percutan Tech 2015;25:E37-E41.
29. Seehofer D, Mogl M, Boas-Knoop S, Unger J, Schirmeier A, Chopra S, Eurich D: Safety and efficacy of new integrated bipolar and ultrasonic scissors compared to conventional laparoscopic 5-mm sealing and cutting instruments. Surg Endosc 2012;26:2541-2549.
30. Ahmad G, O'Flynn H, Duffy JMN, Phillips K, Watson A: Laparoscopic entry techniques. Cochrane Database Syst Rev 2012:15;2:1-117.
31. Phillips CK, Hruby GW, Mirabile G, Motamedinia P, Durak E, Lehman DS, Hong PW, Landman J: The effect of intraluminal content on the bursting strength of vessels ligated with the Harmonic ACE and LigaSure V. J Endourol 2008;22:1383-1387.

9

A vessel sealing device versus suture ligation for canine ovarian pedicle hemostasis: a randomized clinical trial

Schwarzkopf I,[1,2] Van Goethem B,[1] Vandekerckhove PM,[2] de Rooster H[1]

Vet Record 2015;176(5):125-128.

[1]Department of Small Animal Medicine and Clinical Biology, Faculty of Veterinary Medicine, Ghent University, Salisburylaan 133, B-9820 Merelbeke, Belgium

[2]Dierenartsencentrum Malpertuus, Leenstraat 2a, Heusden, B-9070, Belgium

Abstract

Vessel sealing devices (VSD) are well established in laparoscopic ovariectomy (OVE) in dogs. The objective of this study was to evaluate the efficacy of ovarian pedicle hemostasis by vessel sealing using a commercially available VSD for conventional OVE (LigaSure) and compare it with manual suture ligation (SL). A prospective, randomized clinical trial including 20 female dogs was designed. Conventional OVE was performed via a standard midline celiotomy by a single surgeon using a standardized protocol. At random, the right ovarian pedicle was sealed or ligated, whereas the left pedicle was treated by the alternative technique. Surgical times for procedural stages and intraoperative complications were recorded and statistically evaluated. Mean total surgical time was 29.28 ± 11.13 minutes (range, 12.50 to 62.13 minutes). Time for ovarian resection was significantly reduced with VSD (VSD 2.22 ± 0.58 minutes versus SL 4.10 ± 1.13 minutes; P = .0001). Intraoperative complications were rare for both techniques (failure of the electrode of the VSD [n=3]; pedicle stump bleeding due to ligature slippage [n = 1]). The results of the current study indicate that ovarian pedicle hemostasis achieved by VSD is significantly faster than by SL without appearing to compromise safety.

Introduction

Gonadectomy of healthy female dogs is a routine and frequently performed procedure in small animal veterinary practice.[1,2] Neutering is the most reliable method of pet population control and also has advantages for the dog's health.[3] Although other approaches have been described,[2] the most widely performed technique is midline celiotomy for either ovariectomy (OVE) or ovariohysterectomy (OVH).[4] In European countries, other than the UK, OVE is preferred to OVH for elective cases, and the uterus is only removed if uterine pathology is present.[2,5-7]

Throughout the years, adaptations to the standard OVE technique have been proposed, offering benefits to the surgeon (faster procedure) and to the animal (decreased morbidity). Limiting the length of the celiotomy incision will decrease visualization and can thus result in longer, rather than shorter surgical times.[8] Laparoscopic OVE combines a small incision with good visualization, and although surgical times decrease rapidly once experience is gained, total procedural time will be longer compared to conventional OVE in the hands of novice laparoscopic surgeons.[9]

In laparoscopic OVE, different techniques for ovarian pedicle hemostasis have been evaluated and compared: extracorporeal or intracorporeal suture ligation (SL), vascular clips, monopolar and bipolar electrocoagulation, laser energy and VSDs.[9-13] VSDs use high-current and low-voltage bipolar radiofrequency energy to desiccate collagen and elastin in the vessel wall and surrounding connective tissue interposed between the jaws of the device.[14,15] This results in the safe sealing of vessels up to and including 7 mm in diameter during a two to four seconds seal cycle.[16,17]

Laparoscopic VSDs consist of a 20 - 45 cm hand instrument with integrated cutting mechanism, while devices used in conventional surgery have shorter hand pieces, often without an integrated knife. VSDs provide excellent ovarian pedicle hemostasis in addition to a fast surgical time during laparoscopic OVE and laparoscopic-assisted OVH in dogs.[9] The authors, therefore, hypothesize that conventional OVE in dogs using a VSD would result in shorter procedural times compared to SL, without increasing the risk of surgical complications (bleeding).

The aim of the current study was to compare, in terms of safety and surgical time, ovarian pedicle hemostasis during conventional OVE in dogs performed with a VSD (LigaSure) and with the conventional SL technique. Furthermore, the time needed for ovarian pedicle hemostasis of the right versus the left side was measured for both techniques (VSD and SL).

Materials and methods

The study protocol was approved by the Ethical Committee (Faculty of Veterinary Medicine, Ghent University, Belgium); legal and ethical requirements have been met with regard to the humane treatment of animals described in the study.

Groups

Healthy female dogs presented for elective OVE were admitted in the study. Dogs that presented with abnormal anatomy of the uterus or ovaries during celiotomy were subsequently excluded. A total of 20 bitches were included. The dogs were randomly divided into two treatment groups by following a list created by an online random number generator. One group had VSD performed on the right ovary, followed by SL on the left ovary; the other group had SL performed on the right ovary, followed by VSD on the left ovary. In this way, each dog also served as its own control.

A questionnaire was completed before surgery to obtain information on age, general health, number of estrous cycles, date of last estrous and occurrence of pseudopregnancy. The body condition was scored by one observer (IS) (body condition score - BCS 1: cachectic, 2: thin, 3: normal, 4: overweight, and 5: obese).[18]

Anaesthetic technique

All dogs were classified as American Society of Anesthesiologists class I patients, meaning a patient with no systemic disease (http://www.asahq.org 2014). They were preme-

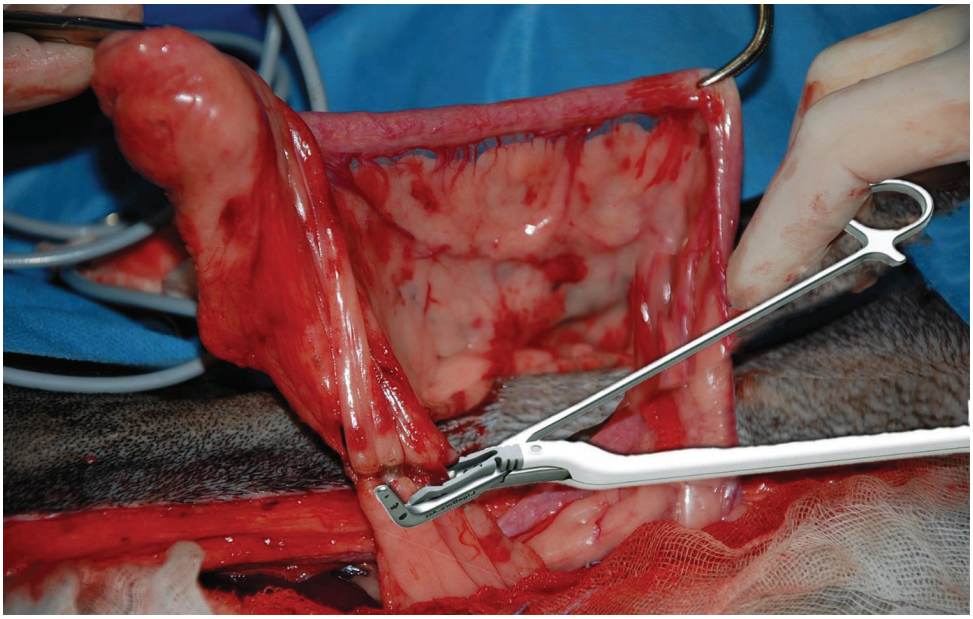

Figure 9.1 The vessel sealing device for conventional surgery consisted of a reusable metal forceps with disposable plastic snap-in bipolar vessel sealing electrode.

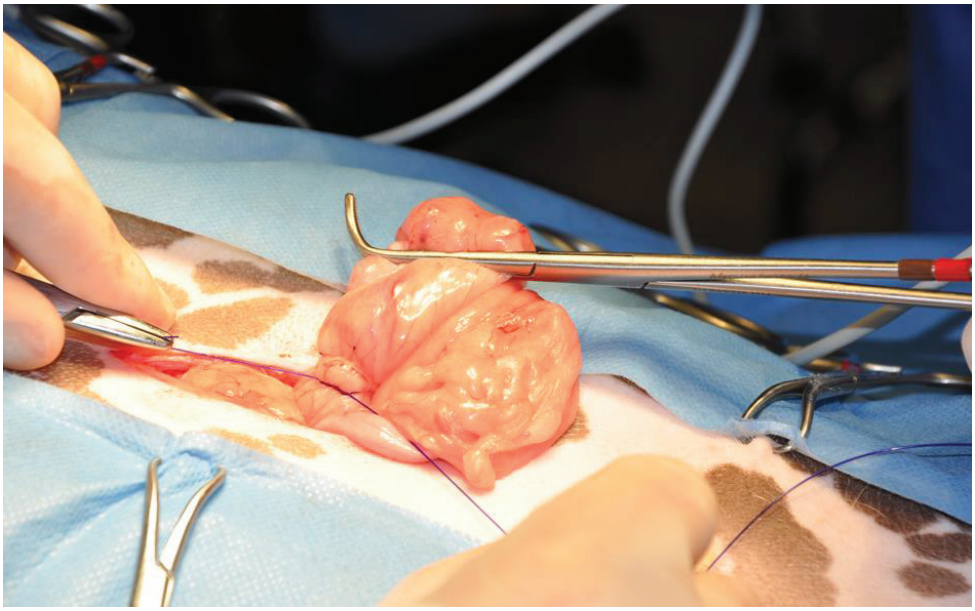

Figure 9.2 Suture ligation of the ovarian pedicle (double) and uterine horn tip (single ligation).

dicated with 0.01 mg/kg IM medetomidine (Dorbene vet, Pfizer) and 0.1 mg/kg IM methadone (Mephenon, Oterop). Induction was performed with 0.5 mg/kg IV diazepam (Valium, Roche), immediately followed by 5 mg/kg IV ketamine (Anesketin, EuroVet). Twenty-two mg/kg IV cefazoline (Cefazolin Sandoz, Sandoz) was administered at the time of induction as was 4 mg/kg IV carprofen (Rimadyl, Pfizer) or 0.2 mg/kg IV meloxicam (Metacam, Boehringer Ingelheim).

Dogs were intubated and after clipping, prepping and transfer to the surgical theatre, they were positioned in dorsal recumbency on a heating pad. Anesthesia was maintained by isoflurane in oxygen. Ten ml/kg/hour IV lactated Ringer's solution (Hartmann's Lactated Ringers, B. Braun) was infused during surgery. Twenty µg/kg IV buprenorphine (Vetergesic Multidose, Ecuphar nv) was administered at the end of surgery. The dogs were placed in a cage with soft padding until full recovery from anesthesia and discharge home.

Surgical technique

All surgeries were performed by the same surgeon (IS), assisted by one of two experienced technicians. A standard midline celiotomy approach was used. The celiotomy incision was made just cranial to the umbilicus until halfway the distance between umbilicus and pubis. The procedure started with identification of the right ovary. A hemostat was placed on the proper ligament and held under mild caudomedial traction by the technician. The suspensory ligament was left intact since all ovaries could be retracted extra-abdominal. With a closed hemostat, a window was created in the broad ligament just caudal to the ovarian pedicle. In group 1, the right ovarian pedicle was sealed with a VSD. A Pean-styled, 18 cm long reusable instrument with 30° curved jaws (LS 2070, Valleylab/Covidien) was used with a snap-in electrode (LS 2071, Valleylab/Covidien) connected to a generator (LigaSure, Valleylab/Covidien) (Fig 9.1). The electrodes are available in sterile packages for single use, but were reused multiple times after cold sterilization with paraformaldehyde (Asphalin B, Becht). The left ovary was removed after double ligation of the ovarian pedicle and single ligation of the tip of the uterine horn with polydioxanone (USP 3-0 to 0 according to the body weight) (SL; Fig 9.2). In both groups, Mayo scissors were used to transect the tissues cranial and caudal to the ovary. In group 2, the order of the hemostatic techniques was reversed.

After removal of both ovaries and inspection of the pedicle stumps for bleeding, the abdomen was closed in a routine fashion: the linea alba in a continuous pattern using polydioxanone, the subcutaneous tissues with a continuous mattress suture using poliglecaprone and the skin with an intradermal suture using poliglecaprone). An adhesive bandage (Hypafix, BSN Medical) was used for wound coverage.

Test variables

The length of the procedure was recorded using a stopwatch. Recording started at the time of first incision and the following time points were recorded: identification of the right ovary, start of pedicle hemostasis of the right ovary, removal of the right ovary, identification of the left ovary, start of pedicle hemostasis of the left ovary, removal of the left ovary and end of the surgery. Any intraoperative problems encountered were recorded. When instrument failure of the VSD occurred, the stopwatch was paused and restarted when adaptive changes were made.

Follow-up

Dogs were sent home the same day with instructions for postoperative care: postoperative analgesia was provided by 2 mg/kg carprofen (Rimadyl, Pfizer) orally every 12 hours or 0.2 mg/kg meloxicam (Metacam, Boehringer Ingelheim) orally every 24 hours, for five days. The owner was contacted 10 days after the surgery and was asked about the recovery of the dog.

Statistical analysis

For the statistical evaluation, SPSS V.21 (IBM, USA) was used. The surgical time from identification of the ovary to its removal with the use of VSD or SL was compared in each dog, using a paired t test (two-tailed). Because the data were not normally distributed, a Mann-Whitney U test was performed to compare the surgical time needed for identification with

removal of the right versus left ovaries for each of the VSD and SL techniques. The significance level for all statistical tests was set at $P < .05$.

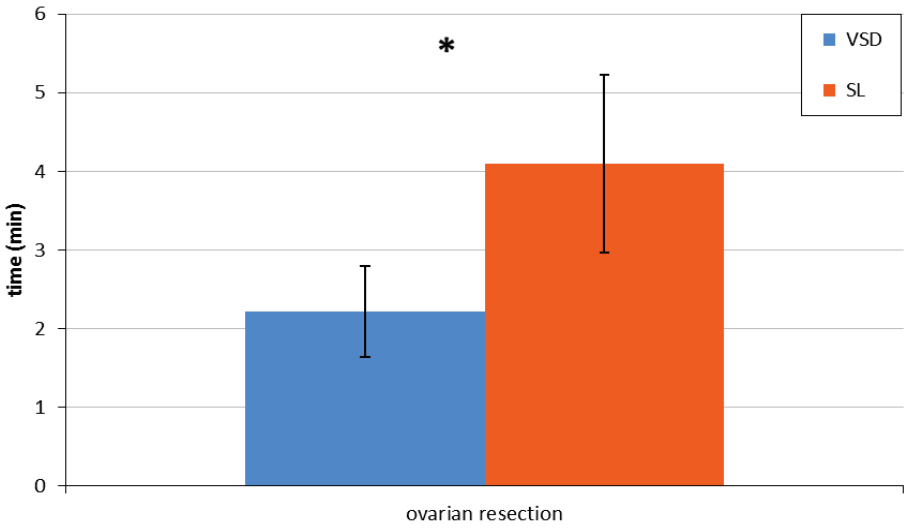

Figure 9.3 Ovarian resection times (SD depicted by error bar) were significantly different between the vessel sealing device (VSD) and suture ligation (SL) (* *P* < .05).

Results

Twenty dogs of various breeds (12 different dog breeds and 1 mixed breed dog) were used. Mean age was 29 months (range, 5 to 121 months). Mean bodyweight was 15.7 kg (range, 1.8 to 52.9 kg), whereas the median BCS was 3 (range, 2 to 5). Eleven dogs were prepubertal, one dog had only had one estrous cycle and eight dogs had had multiple estrous cycles before being presented for gonadectomy. At presentation, 10 dogs were two to three months after their last estrous cycle, whereas the stage of the cycle was unknown to the owner in the remaining dogs.

Intraoperative complications were rare. One dog developed bleeding at the left ovarian pedicle after SL. An extra ligature was placed to ensure hemostasis. In three cases VSD malfunctioning occurred. Replacement of the re-used electrode by a new one immediately solved the problem in all cases.

Mean duration of the complete surgical procedure was 29.28 ± 11.30 minutes (range, 12.50 to 62.13 minutes). Time from identification to removal of the ovary was significantly faster when the VSD was used (VSD 2.22 ± 0.58 minutes versus SL 4.10 ± 1.13 minutes; $P < .001$; Fig 9.3).

Statistical analyses failed to identify a difference between the time from isolation to removal of right versus left ovaries with VS as well as with SL.

No postoperative complications were reported by the owners when they were contacted 10 days after the surgery.

Discussion

This study on conventional OVE in healthy dogs demonstrated that the use of a VSD significantly shortened the procedural time for ovarian pedicle hemostasis. Meanwhile, its use was found to be similarly safe and efficient as the conventional SL in terms of achieved hemostasis and intraoperative and short-term complications.

Previous studies that evaluated different techniques for ovarian pedicle hemostasis in laparoscopic OVE in dogs, found VSDs to be very successful.[9,11-13] Not only do they reliably seal large vessels (up to and including 7 mm), but they offer a feedback-controlled response system that automatically discontinues the electrocoagulation process when the tissue is adequately sealed.[19] This technology reduces thermal necrosis and collateral damage when compared to traditional systems in which the amount of energy is subjectively dictated by the surgeon.[20,21] The LigaSure system demonstrated histologically milder surrounding thermal injury than conventional monopolar and bipolar electrocoagulation.[22] The seal created by the LigaSure is an intrinsic part of the vessel wall, which cannot be dislodged.[23]

Effective ligation is essential to assure adequate hemostasis, avoiding subsequent bleeding. Bleeding has been reported the most common complication of conventional OVE/OVH and can potentially be fatal.[24-27] Identified causes of pedicle stump bleeding are vessel rupture due to strumming of the suspensory ligament, due to pedicle handling and manipulations, due to improper knot tying technique (e.g. placement, spacing, tightness of the knot) in combination with excessive amount of fat in the ovarian pedicle.[1,28] Observations suggest that many seasoned veterinarians are still anxious about their ligation technique in bitch spays, especially in overweight dogs with bulky pedicles.[29] Bleeding of the pedicle stump occurred in one dog after SL (the largest dog of the case series) and necessitated placement of an additional ligature. The authors hypothesize that the use of a VSD will reduce the risk of pedicle stump bleeding in conventional OVE in dogs compared to SL, especially in the hands of novice surgeons.

Notwithstanding the higher cost associated with a VSD compared to the use of suture material, the authors believe that the VSD offers an attractive method for neutering bitches. It is a safe technique, avoids postoperative suture complications, is easy to apply, is not operator dependent, and is very time-efficient. Furthermore, the VSD will prove beneficial for many other surgical procedures (e.g. splenectomy, tumor resection). Although not studied specifically in this study, it can also be argued that some of the complications observed after OVE/OVH are less likely to occur when a VSD is used compared to SL.[1] Long-term studies including large case numbers are needed to demonstrate whether a VSD indeed would result in lower complication rates.

The advantage of the LigaSure instrument used in this study was the relatively large size of the electrodes (18 mm) allowing large tissue bites. Therefore, the number of seal cycles needed to bridge the ovarian pedicle was limited. The fact that there was no built-in divider, however, necessitated alternation between the VSD instrument and surgical scissors. An additional disadvantage was that the single use electrodes that needed to be mounted on to the reusable hand piece, were very pliable and prone to twisting. If not assembled with care, an electrical contact failure would occur, as was encountered in 3 out of 20 cases. Another potential issue after repeated re-sterilization of the electrodes is the increase in stickiness to the tissues after sealing.[30] However, this issue was not observed in the current study.

Because of its more cranial location and its relatively shorter suspensory ligament, the right ovary is more tightly fixed in the abdomen.[31] It was therefore hypothesized that, irrespective of the technique used, less time would be needed for ovarian pedicle hemostasis of left ovaries compared to right ovaries. Yet this study failed to identify any time difference between sides. Potentially, the sample size was too limited to provide enough power to detect smaller time differences.

This study showed that, in the hands of the first author, SL took approximately twice as long as the VSD. It is obvious that the surgeon is likely to have the biggest impact on the time to achieve hemostasis and efficacy of ligation. Therefore, the data obtained in this study can only be applied to the conditions in this study. Nevertheless, the first author is a seasoned surgeon and therefore it is expected that time differences between the VSD and SL would even be more pronounced if both procedures were to be performed by novice surgeons.

Prophylactic antibiotic use is not necessary for clean elective surgeries. However, at the time of conduction, at the first author's institution, antibiotic prophylaxis was routinely given irrespective of the type of surgery. This method is now changed.

A limitation of this study included the reuse of the single use LigaSure electrodes. The time lost by replacing the reused electrode in cases of technical failure, was not taken into account when calculating the surgical times since single use of the disposable electrodes would most likely have prevented this issue. Furthermore, the single use electrodes are likely to be reused when this technique is picked up in veterinary practice.

Finally, the sample size of the current study was rather small. The last is less relevant for the comparison of the procedural time required for VSD versus SL because the paired study design allowed for a detailed comparison within the same animal. Nevertheless, it is plausible that differences in the isolation times for right versus left ovaries would have been observed if the study would have had more statistical power. Since surgical site complications might be expected to occur with a frequency of less than 1:20, any difference between the two techniques with regard to complications could not be evaluated.

In summary, it can be said that OVE using a VSD allows pedicle hemostasis with great ease. It simplifies OVE by negating the need for ligations and is safe and reliable. The results

of the current study on conventional OVE in dogs indicate that ovarian pedicle hemostasis achieved by a VSD was significantly faster than by SL. The clinical implication of the current study may be a more widespread use of VSDs for routine surgeries such as conventional OVE/OVH amongst practitioners. This may decrease the reluctance amongst (inexperienced) surgeons to neuter obese bitches.

References

1. Adin CA: Complications of ovariohysterectomy and orchiectomy in companion animals. Vet Clin North Am Small Anim Pract 2011;41:1023-1039.
2. Howe LM: Surgical methods of contraception and sterilization. Theriogenology 2006;66:500-509.
3. Kustritz MVR: Effects of surgical sterilization on canine and feline health and on society. Reprod in Domest Anim 2012;47:214-222.
4. Van Goethem B, Schaefers-Okkens A, Kirpensteijn J: Making a rational choice between ovariectomy and ovariohysterectomy in the dog: a discussion of the benefits of either technique. Vet Surg 2006;35:136-143.
5. Okkens AC, Kooistra HS: Reproductive problems in the bitch and the queen. Vet Quart 1997;19:S36-S37.
6. DeTora M, McCarthy R: Ovariohysterectomy versus ovariectomy for elective sterilization of female dogs and cats: is removal of the uterus necessary? J Am Vet Med Assoc 2011;239:1409-1412.
7. Peeters ME, Kirpensteijn J: Comparison of surgical variables and short-term postoperative complications in healthy dogs undergoing ovariohysterectomy or ovariectomy. J Am Vet Med Assoc 2011;238:189-194.
8. Pukacz M, Kienzle B, Braun J: Simple, minimally invasive technique for ovariohysterectomy in the dog. Vet Rec 2009;165:688-690.
9. Mayhew PD, Brown DC: Comparison of three techniques for ovarian pedicle hemostasis during laparoscopic-assisted ovariohysterectomy. Vet Surg 2007;36:541-547.
10. Harold KL, Pollinger H, Matthews BD, Kercher KW, Sing RF, Heniford BT: Comparison of ultrasonic energy, bipolar thermal energy, and vascular clips for the hemostasis of small-, medium-, and large-sized arteries. Surg Endosc 2003;17:1228-1230.
11. van Nimwegen SA, Van Swol CFP, Kirpensteijn J: Neodymium:Yttrium aluminum garnet surgical laser versus bipolar electrocoagulation for laparoscopic ovariectomy in dogs. Vet Surg 2005;34:353-357.
12. van Nimwegen SA, Kirpensteijn J: Comparison of Nd:YAG surgical laser and Remorgida bipolar electrosurgery forceps for canine laparoscopic ovariectomy. Vet Surg 2007;36:533-540.
13. Öhlund M, Höglund O, Olsson U, Lagerstedt AS: Laparoscopic ovariectomy in dogs: a comparison of the LigaSure and the SonoSurg systems. J Small Anim Pract 2011;52:290-294.

14. Heniford BT, Matthews BD, Sing RF, Backus C, Pratt B, Greene FL: Initial results with an electrothermal bipolar vessel sealer. Surg Endosc-Ultras 2001;15:799-801.
15. Carbonell AM, Joels CS, Kercher KW, Matthews BD, Sing RF, Heniford BT: A comparison of laparoscopic bipolar vessel sealing devices in the hemostasis of small-, medium-, and large-sized arteries. J Laparoendosc Adv S-Part A 2003;13:377-380.
16. Landman J, Kerbl K, Rehman J, Andreoni C, Humphrey PA, Collyer W, Olweny E, Sundaram C, Clayman RV: Evaluation of a vessel sealing system, bipolar electrosurgery, harmonic scalpel, titanium clips, endoscopic gastrointestinal anastomosis vascular staples and sutures for arterial and venous ligation in a porcine model. J Urology 2003;169:697-700.
17. Person B, Vivas DA, Ruiz D, Talcott M, Coad JE, Wexner SD: Comparison of four energy-based vascular sealing and cutting instruments: a porcine model. Surg Endosc 2008;22:534-538.
18. Baldwin K, Bartges J, Buffington T, Freeman LM, Grabow M, Legred J, Ostwald D: AAHA nutritional assessment guidelines for dogs and cats. J Am Anim Hosp Assoc 2010;46:285-296.
19. Richter S, Kollmar O, Schilling MK, Pistorius GA, Menger MD: Efficacy and quality of vessel sealing - comparison of a reusable with a disposable device and effects of clamp surface geometry and structure. Surg Endosc 2006;20:890-894.
20. Santini M, Vicidomini G, Baldi A, Gallo G, Laperuta P, Busiello L, Di Marino MP, Pastore V: Use of an electrothermal bipolar tissue sealing system in lung surgery. Eur J Cardiothorac Surg 2006;29:226-230.
21. Pastore AL, Palleschi G, Silvestri L, Leto A, Sacchi K, Pacini L, Petrozza V, Carbone A: Prospective randomized study of radiofrequency versus ultrasound scalpels on functional outcomes of laparoscopic radical prostatectomy. J Endourol 2013;27:989-993.
22. Diamantis T, Kontos M, Arvelakis A, Syroukis S, Koronarchis D, Papalois A, Agapitos E, Bastounis E, Lazaris AC: Comparison of monopolar electrocoagulation, bipolar electrocoagulation, ultracision, and LigaSure. Surg Today 2006;36:908-913.
23. Kennedy JS, Stranahan PL, Taylor KD, Chandler JG: High-burst-strength, feedback-controlled bipolar vessel sealing. Surg Endosc-Ultras 1998;12:876-878.
24. Pearson H: The complications of ovariohysterectomy in the bitch. J Small Anim Pract 1973;14:257-266.
25. Berzon JL: Complications of elective ovariohysterectomies in the dog and the cat at a teaching institution: clinical review of 853 cases. Vet Surg 1979;8:89-91.
26. Pollari FL, Bonnett BN, Bamsey SC, Meek AH, Allen DG: Postoperative complications of elective surgeries in dogs and cats determined by examining electronic and paper medical records. J Am Vet Med Assoc 1996;208:1882-1886.
27. Kyles AE, Aronsohn M, Stone EA: Urogenital surgery, in Lipowitz AJ (ed): Complications in small animal surgery, Baltimore, MD, Williams & Wilkins, 1996, pp 496-503.
28. Burrow R, Batchelor D, Cripps P: Complications observed during and after ovariohysterectomy of 142 bitches at a veterinary teaching hospital. Vet Rec 2005;157:829-833.
29. Leitch BJ, Bray JP, Kim NJG, Cann B, Lopez-Vilalobos N: Pedicle ligation in ovariohysterectomy: an in vitro study of ligation techniques. J Small Anim Pract 2012;53:592-598.
30. Gracia-Calvo LA, Martin-Cuervo M, Jimenez J, Vieitez V, Duran ME, Arguelles D, Ezquerra LJ: Intra and postoperative assessment of re-sterilised LigaSure Atlas for orchidectomies in horses: clinical study. Vet Rec 2012;171:5.
31. Wildt DE, Levinson CJ, Seager SW: Laparoscopic exposure and sequential observation of the ovary of the cycling bitch. Anat Rec 1977;189:443-449.

10

A laparoscopic approach for removal of ovarian remnant tissue in 32 dogs

van Nimwegen SA,[1] Van Goethem B,[2] de Gier J,[1] Kirpensteijn J[1,3]

submitted

[1]Department of Clinical Sciences of Companion Animals, Faculty of Veterinary Medicine, Utrecht University, Yalelaan 108, P.O. Box 80154, NL-3508 TD Utrecht, The Netherlands

[2]Department of Small Animal Medicine and Clinical Biology, Faculty of Veterinary Medicine, Ghent University, Salisburylaan 133, B-9820 Merelbeke, Belgium

[3]Current position: Hill's Pet Nutrition, 400 SW Topeka Ave, Topeka, KS 66047, USA

Abstract

Background: Surgical treatment of ovarian remnant syndrome (ORS) in dogs usually necessitates large celiotomy incisions and considerable manipulation of organs because of the relatively deep position of ovarian remnant tissue, the large size of the patient, and the frequent presence of adhesions. When considering that conventional exploratory surgery for ORS is much more invasive compared to conventional elective ovariectomy, the rationale for a laparoscopic approach of canine ORS is evident. In women, laparoscopic treatment of ORS is successful and has significant advantages over laparotomy. Feasibility and efficacy of a laparoscopic approach for the treatment of ORS in dogs was prospectively evaluated using a standardized protocol for diagnosis, treatment, and follow-up. Treatment success was evaluated by histological analysis of removed tissues, postoperative hormone testing, and long-term clinical follow-up.

Results: Thirty-two client-owned dogs diagnosed with ORS underwent abdominal ultrasound for ovarian remnant localization prior to laparoscopic surgery for removal of ovarian remnants. Tissue dissection and excision was performed using a vessel sealing device. Laparoscopy enabled detailed visibility and facilitated detection and removal of suspected ovarian tissue in all cases. Histology confirmed the ovarian origin of removed tissue in all dogs. In addition, a GnRH stimulation test was performed in 14 dogs after a median follow-up of 10.5 months and verified the absence of residual functional ovarian remnant tissue in 100%. Mean surgery duration was 107 ± 33 minutes. Mean convalescence duration was 1.5 ± 0.7 days. No major complications occurred. Adhesions were observed in 79% of the dogs and significantly affected surgery duration. Extensive adhesions complicated the surgical approach. Minor bleeding occurred in 12% and also caused an increase in surgery duration. Trendelenburg position and lateral tilting of the patient were essential for proper access to ovarian remnants. Absence of clinical signs confirmed treatment efficacy after a median follow-up period of 22.5 months.

Conclusion: Laparoscopic surgery for ORS in dogs is 100% effective with minimal complications and rapid convalescence, and can successfully replace an otherwise invasive surgical procedure.

Introduction

Ovarian remnant syndrome (ORS) can occur as a complication after ovariectomy (OVE) or ovariohysterectomy (OVH). The syndrome is defined by clinical signs caused by hormone production by ovarian remnant tissue. The reported incidence of ORS in dogs is 0.1% (2/1,880) to 0.5% (3/618).[1,2] Patients referred for ORS to a veterinary specialist are seen approximately 3 to 12 times/year.[3-7] Despite proclaimed causes of ovarian remnant tissue, such as accessory or ectopic ovarian tissue, the only proven cause for dogs with ORS is iatrogenic, i.e. not removing all ovarian tissue during OVE/OVH.[5,8] Possible risk factors for ORS in dogs are associated with difficult accessibility of the ovaries during surgery, corresponding to the higher incidence of right-sided remnant ovarian tissue, and include large, deep-chested dogs, obesity, and a celiotomy incision that is too small or located too caudal for proper ovarian access.[4-9] Clinical signs from ovarian hormone production usually occur within several months after the initial procedure,[7] although they can arise from as early as 1 week to as late as 11 years after the initial surgery.[9] Clinical signs of ORS can include symptoms associated with (pro)estrus, such as behavioral changes, attractiveness for male dogs, swelling of the vulva and/or mammary glands, serosanguineous vaginal discharge and receptivity to mating. Additionally, cystic endometrial hyperplasia, endometritis, (stump) pyometra, pseudopregnancy, vaginitis, and ovarian neoplasia are described,[5,7,8] and less commonly vaginal or uterine tumors,[10,11] diabetes mellitus,[12] and abdominal pain[13] are described. In contrast, ORS in humans is mainly associated with chronic inflammatory processes causing abdominal pain.[14]

Diagnosis of ORS can be reliably made using a combination of history, clinical signs, vaginoscopic findings and vaginal cytology during (pro)estrus, and measurement of the plasma progesterone concentration (> 3.36 nmol/L) during luteal phase.[7,15] Median normal basal progesterone concentration in ovariectomized bitches is 0.63 nmol/L (range, < 0.15 - 2.2 nmol/L).[16] In cases in which results of these tests are not diagnostic but a suspicion of ORS still remains, a gonadotrophin-releasing hormone (GnRH) stimulation test can be used to rule out the presence of an ovarian remnant.[9]

Treatment of ORS consists of surgical resection of the ovarian remnant(s). The common approach is a midline celiotomy for abdominal exploration with excision of all suspect tissues near the site of the original OVE/OVH, because macroscopic distinction between ovarian remnant and fibrous scar tissue can be difficult. Because of the dorsal location of the ovarian pedicle and adhesions induced by the previous surgery, care has to be taken to avoid damaging the ureters and other closely associated tissues. Performing surgery during estrus, when vascularization of ovarian remnants is augmented and size is often increased by follicles, aids in the discovery of very small remnants or remnants covered by adhesions.[8,9,17] Consequently, a large celiotomy incision and manipulation of organs are usually required for thorough exploration of the ovarian pedicle and uterine horn locations. In case of cystic abnormalities or granulomatous changes of uterine remnants or cervical stump these are also excised. Recurrence of ORS after surgical intervention is not uncommon[18] and referral to a surgical specialist has been advised.[19,20]

Considering that surgery for ORS is accompanied by a larger celiotomy and considerably more manipulation of abdominal tissues than elective ovariectomy or ovariohysterectomy, the rationale for developing a minimally invasive approach is logical. Laparoscopic ovariectomy has become a routine procedure in dogs and cats with multiple studies showing reduced peri- and post-operative pain and faster convalescence compared to a celiotomy approach.[21-26] In women, laparoscopic treatment of ORS is successful.[14,27] It has a 0 - 7% recurrence rate.[28-30] Advantages are decreased blood loss and shortened hospital stay with less postoperative complications compared to celiotomy.[31] Only sparse retrospective case series exist on laparoscopic surgery for ORS in dogs and cats.[18,32,33] A laparoscopic approach for removal of ovarian remnant tissue was prospectively investigated in dogs diagnosed with ORS, using a standardized protocol for diagnosis, treatment, and follow-up. We hypothesized that a laparoscopic approach for removal of ovarian remnant tissue would be feasible in dogs, without the need for conversion to celiotomy, with a high success rate, and short convalescence period. Additionally, the absence of any ovarian tissue was confirmed postoperatively in a subset of the first 13 dogs using a GnRH stimulation test.

Materials and methods

Inclusion criteria

All dogs diagnosed with ORS, between July 2009 and February 2014, at the Department of Clinical Sciences of Companion Animals, Utrecht University and the Department of Small Animal Medicine, Ghent University were offered a laparoscopic surgical approach for the same costs as a laparoscopic ovariectomy. A research grant by the Dutch Society for Veterinary Research in Companion Animals (Stichting Diergeneeskundig Onderzoek Gezelschapsdieren, D.O.G.) enabled follow-up GnRH-testing in the first 13 dogs without additional costs for the owners.

Diagnostic protocol

For inclusion in the study, ORS had to be proven by a combination of clinical history and physical examination. When signs of (pro)estrus, caused by an increased plasma estradiol concentration, were evident this was confirmed using vaginoscopy and vaginal cytology. When a late follicular phase or luteal phase was suspected based on the history, measurement of plasma progesterone concentration was performed. In cases in which these tests were negative, but suspicion of ORS remained, a GnRH stimulation test was performed.

Additionally, abdominal ultrasound was performed in all dogs to search for abnormalities that could be related to ORS and to evaluate the ability to predict the location of ovarian remnant tissue by ultrasound. Initial diagnosis, ultrasound-predicted location, and treatment success were ultimately confirmed by histological examination of all excised tissues, labeled according to their location in the abdomen.

Anesthetic protocol

Two different anesthetic protocols were used. Healthy ASA 1 and 2 patients received anesthesia according to a routine protocol consisting of: premedication by 10 - 15 µg/kg IV dexmedetomidine (Dexdomitor, Orion Corporation, Finland), induction by 1 - 2 mg/kg IV

propofol to effect (PropoFlo Plus, Abbott Logistics B.V., the Netherlands), and maintenance by isoflurane (Isoflo, Abbott Laboratories, United Kingdom) in 50% O_2 - 50% air mixture. Dogs were mechanically ventilated (IPPV) during surgery. Dexmedetomidine was routinely redosed at 5 - 7.5 µg/kg IV after 60 minutes of anesthesia. Additional analgesia consisted of 4 mg/kg IV carprofen (Rimadyl, Zoetis, Belgium) and 10 - 15 µg/kg IV buprenorphine (Buprecare, Animalcare ltd, United Kingdom). After surgery, 50 - 75 µg/kg IM atipamezole (Antisedan, Orion Corporation, Finland) was administered to reverse dexmedetomidine effects. Routine anesthetic monitoring consisted of esophageal temperature probe, capnography, pulse oximetry, end-tidal O_2, end-tidal CO_2, end-tidal isoflurane, ECG, heart rate, respiratory rate, tidal volume, airway pressure, non-invasive blood pressure.

Dogs older than 7 years, or with increased risk of circulatory compromise received a different anesthetic protocol consisting of: premedication by 0.05 mg/kg IV methadone (Comfortan, Eurovet Animal Health B.V., the Netherlands) and 0.4 mg/kg IV midazolam (Dormicum, Roche B.V., the Netherlands), followed by induction with 2 - 4 mg/kg IV propofol to effect and maintenance by isoflurane in 50% O_2 – 50% air mixture. Additional analgesia consisted of constant rate infusion of 10 - 20 µg/kg/hr fentanyl (Bipharma, the Netherlands) during maintenance of anesthesia, which is partially reversed during recovery by administering 10 - 15 µg/kg IV buprenorphine while maintaining adequate postoperative analgesia. Postoperative analgesia consisted of 3 days of 2 mg/kg 2dd oral carprofen.

Surgery protocol

Time of surgery was not necessarily planned to coincide with estrus for improved visualization of remnants. On the contrary, surgery was often postponed until anestrus for dogs presented with overt estrus and a history of regular estrous cyclicity, to decrease the chance of postoperative pseudopregnancy. For dogs that did not present with signs of regular estrous cyclicity, surgery was usually planned shortly after diagnosis.

All surgeries were performed by three experienced laparoscopic surgeons with ECVS board certification (SvN, JK, BVG). The dogs were placed in 10 - 15° Trendelenburg position with alternate 20 - 30° lateral tilting. Surgery was performed through a standard 3-portal

midline laparoscopic approach; using a modified Hasson's approach with 6 mm outer diameter blunt tip threaded screw-in cannulae (Ternamian EndoTIP, Karl Storz Endoscopy, Germany). The first portal was placed in the abdominal midline, midway between umbilicus and pubis. A 10 mm skin incision was made, followed by blunt dissection of subcutaneous tissue, revealing the linea alba. Two stay sutures were placed in the external abdominal fascia, bilaterally at 2 mm from the linea alba. The stay sutures were pulled up and a 4 - 5 mm stab incision was made in the linea alba. A 6 mm outer diameter blunt screw-in cannula was placed under visual guidance of a 5 mm 0° or 30° telescope (Hopkins II, Karl Storz Endoscopy, Tuttlingen, Germany) inserted in the cannula.[35] After visual confirmation of proper abdominal entry, the abdomen was insufflated with CO_2 gas to an intra-abdominal pressure of 8 mm Hg (Endo-Arthroflator-VET, Karl Storz Endoscopy, Tutlingen, Germany). Two additional 6 mm cannulae were placed 1 - 2 cm caudal and 1 - 2 cm cranial to the umbilicus. The telescope was then inserted through the middle portal and a routine inspection of the abdomen was performed.

Surgery was commenced according to a preplanned routine: inspection of the left ovarian pedicle location and uterine remnant (if present) with the dog tilted to the right side; inspection of the right ovarian pedicle location and uterine remnant (if present) with the dog tilted to the left side; inspection of the cervical stump (if present). As a rule, adequate access to the ovarian pedicle area included at least proper visualization of both kidneys. Furthermore, any abnormalities and omental adhesions were inspected. In cases where remnants were hard to find, any possible omental adhesions were carefully identified and followed towards any attachment site. Likewise, the round ligament of the uterus was identified at the inguinal ring and followed cranially. Any suspect looking tissues, adhesions, or ligature scars were excised from the pedicle region and any cystic or inflammatory changes of the uterine remnant or locations of omental adhesions to the uterine remnant were also excised. A fourth cannula for extra tissue manipulation was placed if required. Manipulation of tissues was routinely performed using 5 mm diameter endoscopic instruments, including a Kelly dissection forceps and a self-retaining blunt grasping forceps. Additional instruments for tissue manipulation were optional, including fan retractors, Babcock forceps, endoscopic suction/irrigation device, and endoscopic scissors. All tissue dissection and excision was performed using a vessel sealing device (VSD; LigaSure, Covidien, Boulder, CO). Excised tissue was removed from the

abdominal cavity either through a 10 mm cannula that was exchanged for the 6 mm cannula in the caudal portal, or through an enlarged caudal portal. Larger tissue specimens or fragments were removed using a specimen retrieval bag. Uterine remnants with hormone-induced changes within the normal range were not excised. In cases of abnormal uterine changes, such as overt cystic endometrial hyperplasia or pyometra, the uterine remnants were excised or laparoscopic-assisted hysterectomy was performed with removal of the uterus through an enlarged caudal portal. Isolated uterine abnormalities, such as (para-)uterine cysts or adhesions were treated by local excision of the abnormal tissue.

Closure of portals larger than 6 mm was done in 3 layers (external abdominal fascia, subcutis, and skin) using absorbable monofilament suture material. In portals < 6 mm where the external abdominal fascia was not easily accessible, only subcutaneous tissues and skin were closed. Dogs were released from the hospital directly after recovery from anesthesia and owners were instructed the keep their dog on a leash with restricted exercise for 3 - 5 days.

Follow-up protocol

Owners were routinely contacted by telephone after 2 - 3 weeks when a standardized questionnaire was used to obtain information on: the duration of convalescence (how long it took for the dog to act as before the operation, seemingly unaffected by the surgery or anesthesia), the occurrence of pseudopregnancy, the occurrence of wound complications, the appetite, changes in behavior, the activity level of the dog, and owner satisfaction with the treatment and outcome. For the first 13 dogs, a routine control visit was planned, preferably more than 3 months post-operatively, during which a GnRH stimulation test was performed in order to evaluate if all ovarian remnant tissue was removed during surgery. After the initial 13 cases, post-operative GnRH testing was only performed if clinical signs suggested possible recurrence of ORS.

Long term follow-up consisted of several contact moments with the owners by telephone throughout the duration of the study: information regarding any behavioral or clinical signs suggestive for ORS, and changes in appetite and activity level were monitored.

GnRH stimulation test

Blood samples were collected by venipuncture at different time points (−40, 0, 10, 60, and 120 minutes). At t = 0, immediately after collecting the second blood sample, a GnRH analogue, 10 µg/kg IV gonadorelin (Fertagyl, Intervet/Schering-Plough Animal Health, Boxmeer, the Netherlands) was administered. Plasma hormone concentrations were measured as previously described: oestradiol-17β (at −40, 0, 60, and 120 min), LH and FSH (both at −40, 0, 10, and 60 min).[9] Previously established cut-off values were used to differentiate between dogs with and without residual ovarian tissue (Table 10.1).[9,36]

Table 10.1 Reference values used for interpretation of the GnRH stimulation test results.

Plasma parameter	Time point	Cut-off value (ovariectomized)
LH	basal	> 3.4 µg/L
FSH	basal	> 11.0 µg/L
FSH / estradiol-17β ratio	basal	> 0.66
estradiol-17β	120 min after GnRH	< 21.3 pmol/L
estradiol-17β	basal	< 7 pmol/L → no ORS 7 - 21.3 pmol/L → not diagnostic

Time point is relative to the administration of GnRH during a GnRH stimulation test. An animal was considered ovariectomized if the measured parameters were > or < the presented cut-off values as specified.

Statistical analysis

Statistical analysis of the data was performed using IBM SPSS 23 data analysis software. Apart from general descriptive statistics, differences between sub-groups were evaluated using Student's t-test and statistical relations or trends were evaluated using ANOVA and linear regression tests. Non-parametric tests were used if data was not normally distributed, including Mann-Whitney U and Kruskall Wallis test. Statistical significance was assumed when $P < .05$. Results are reported as means ± SD or median (range).

Results

Patient population

Thirty-two dogs of various breeds (10 different dog breeds and 13 mixed breed dogs) were used. Mixed breed dogs (42%) and Labrador retrievers (8%) were the most common dogs. Mean age was 4.5 ± 2.7 years; mean body weight was 26.7 ± 12.4 kg. Seventy-five percent of the patients had initially been spayed in the Netherlands and Belgium (countries in which the study was performed), 25% of the dogs were previously operated abroad, including Bulgaria, Greece, Turkey, Spain, and the USA. According to the clinical history, the initial surgery consisted of ovariectomy in 59%, ovariohysterectomy in 31%, and was unknown for 10% of the dogs.

The date of initial surgery was known for 18 animals and the median interval between initial surgery and clinical signs of ORS was 8.5 months, (range, 0.5 to 96 months). Clinical signs that were most frequently reported by the owners were: attractiveness to male dogs (96%), vulvar discharge (83%), and vulvar swelling (57%). Less frequently, swelling of mammary glands, occurrence of pseudopregnancy, decreased appetite, frequent urination, and weight loss were reported. Two dogs suffered from increased stress/anxiety that the owners attributed to the ORS. Abdominal pain was present in one dog, pain during defecating in one dog, occasional abdominal discomfort ('prayer position') and vomiting in one dog, and a mammary tumor in another. In 20% of the dogs, treatment of the ORS by exploratory celiotomy had already been attempted by the referring veterinary practitioner. Diagnosis was confirmed by clinical presentation and measurement of plasma progesterone level > 3.36 nmol/l in 38% of the patients. Presence of overt clinical estrus, as confirmed by vaginoscopy and vaginal cytology or distinct endometritis confirmed the existence of residual ovarian tissue in 56% of dogs. The remaining 6% could only be diagnosed after a GnRH stimulation test.

Preoperative ultrasound findings

Ultrasound imaging indicated a possible ovarian remnant located at the left ovarian pedicle area in 45%, and at the right ovarian pedicle area in 84% of dogs. Uterine tissue was

identified in 84% of the patients, and showed cystic changes, was enlarged, or fluid-filled in 54%. One coincidental finding was the absence of a left kidney, in the presence of a left ovarian remnant, in a mixed breed dog spayed at the age of 7 weeks.

Surgical findings

All dogs successfully underwent laparoscopic surgery for ORS without the need for conversion to a conventional approach. Duration of surgery, from skin incision to completion of wound closure, was 107 ± 33 minutes. Adequate exposure of ovarian remnants sometimes necessitated tilting the dog > 30° laterally or up to 20° in Trendelenburg position. All suspect or abnormal looking tissue, even if only very small, was excised: ligature scar tissue, any adhesions, apparent vasculature, or cyst-like changes. Ligature scars with only minimal fibrotic changes without apparent vasculature or other changes were not excised (Fig 10.1).

Suspect tissue was removed from the left pedicle area in 69%, from the right pedicle area in 91%, from the tip of the left uterine horn in 50%, and from the tip of the right uterine horn in 47% of dogs. Removal of the uterine body was performed in 9% of the dogs. The mean number of excised tissue specimens per dog was 2.5 ± 0.9. The size of excised tissues varied from < 1 cm to cystic structures of 5 - 6 cm in diameter.

Adhesions were found in 79% of the dogs (Fig 10.2). Adhesions were located at the left pedicle in 41%, at the right pedicle in 67%, at the uterus in 48%, and to the mesoduodenum in 25% of the cases. Surgery duration was significantly faster in dogs without adhesions (no adhesions 85 ± 21 minutes versus adhesions 119 ± 33 minutes; $P = .03$). A fourth, paramedian, cannula was placed in 2 dogs for improved access to the surgical area.

Complications

No major complications occurred. Minor complications consisting of intraoperative bleeding occurred in 4 dogs (12%). In one dog, bleeding originated from an abdominal vessel damaged by the paramedian abdominal wall cannula and was eventually controlled placing a full-thickness abdominal wall suture. In another dog, minor bleeding occurred from splenic

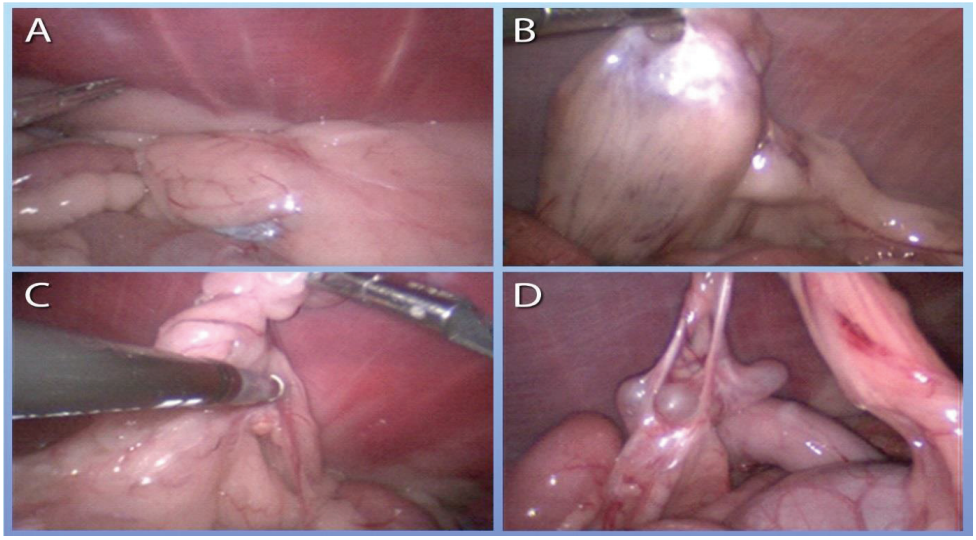

Figure 10.1 Laparoscopic images of a normal left ovarian pedicle scar (A) and several examples of ovarian remnants: large left-sided ovarian remnant with forceps in ovarian bursal opening (B), small right-sided ovarian remnant covered by fat and omental adhesions (C), and right-sided ovarian remnant with omental adhesions and multiple cystic structures (D).

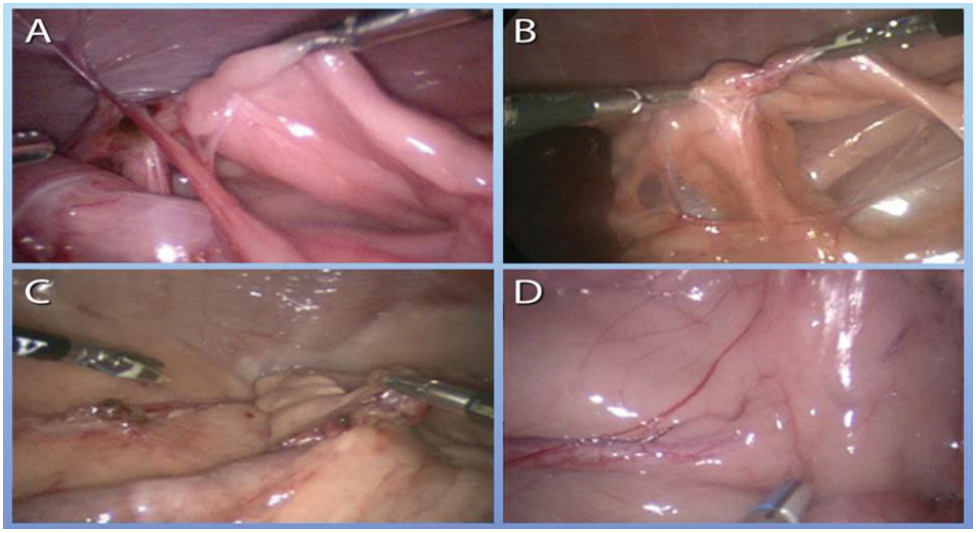

Figure 10.2 Examples of adhesions in the ovarian pedicle area: left-sided scar tissue with multiple adhesions, including to the abdominal wall (A), left-sided scar tissue with multiple adhesions (B), dissection of a small ovarian remnant adhered to the mesoduodenum and the pancreas (C), and visualization of the right ureter close to the ovarian pedicle area (D).

puncture with an instrument. Two dog developed small bleedings from dissection in the right and left pedicle area, respectively, when extensive adhesions made access to these areas difficult. All bleedings were successfully controlled laparoscopically. Visualization was retained using either a suction/irrigation instrument or the application of surgical gauze through a 10 mm cannula. The splenic puncture site was plugged with a hemostatic gelatin sponge (Spongostan, Ethicon Inc., Somerville, NJ), and bleeding ruptured adhesions were stopped with a vessel sealing device. Total blood loss was considered minimal, but the extra effort of evaluation and intervention caused a significant increase in surgery duration (bleeding 143 ± 42 minutes versus no bleeding 101 ± 28 minutes; $P = .02$).

Additional surgical procedures were performed in three dogs. One dog had a laparoscopic liver biopsy because of an increased level of circulating bile acids. Another dog had a partial mastectomy because of a concurrent mammary tumor. This turned out to be mammary carcinoma with lymph node metastasis and this dog died 3 months later because of generalized metastasis. A third dog turned out to have a subclinical gastric volvulus of 270° with moderate dilation which became apparent during routine inspection of the abdomen. This condition was corrected by deflating the stomach through gastric intubation and laparoscopic correction of the stomach position, followed by a laparoscopic-assisted gastropexy.

Histology results

Histological evaluation identified the effective removal of ovarian remnant tissue in all dogs. Remnants were removed from the left ovarian pedicle in 8 dogs (25%), from the right ovarian pedicle in 28 dogs (88%), and on both sides in 5 dogs (16%). Right-sided remnants were significantly overrepresented ($P = .01$). One dog (3%) had an ovarian remnant attached to the uterine horn without involvement of a pedicle area. In this dog, both pedicle areas looked normal macroscopically with only minimal scar tissue at the left side. The tips of the uterine horns were adhered to each other and to omentum with a small ovarian remnant within the adhesions.

Several ovarian remnants contained small to large (up to 3 cm) cysts and/or areas representing corpora lutea. In two dogs the ovarian remnant contained a granulosa cell tumor. Uterine abnormalities consisted of cystic endometrial hyperplasia, endometritis, or localized large cysts (up to 6 cm).

When combining the results of preoperative ultrasound evaluation with the results of histology of excised tissues, the accuracy of abdominal ultrasound to predict the location of an ovarian remnant has a sensitivity of 94% and a specificity of 74%. Sensitivity and specificity were higher for right-sided remnants than left-sided remnants (Table 10.2).

Table 10.2 Diagnostic accuracy of abdominal ultrasound to locate ovarian remnants in dogs.

Ultrasound diagnosis	Sensitivity	Specificity
Left pedicle	88%	70%
Right pedicle	96%	100%
Left + right	94%	74%

Short-term follow-up

Mean duration of recovery, as concluded from the telephone questionnaire with the owners, was 1.5 ± 0.7 days. Recovery duration significantly increased with increased surgery duration (linear regression, $P < .01$, Fig 10.3). Pseudopregnancy was noted postoperatively by the owner in 4 dogs (12.5%) and resolved without medical intervention. Mild wound healing complications (minor swelling and serous discharge) were seen in 4% of the cases, without requiring medical attention. In the short-term follow-up (during the first 2 months postoperatively) 3 dogs (10%), one of which was also pseudopregnant, still showed increased attractiveness for male dogs. Another 3 dogs (10%) had an episode of minor vaginal discharge ranging from a white to bloody aspect.

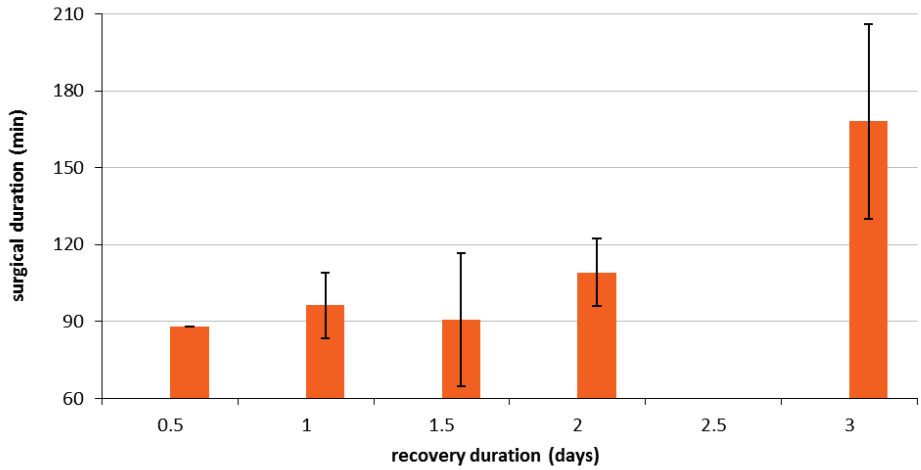

Figure 10.3 Relation between recovery and surgery duration (SD depicted by error bars) as subjectively scored by owners. Longer surgery duration was significantly related to an increased recovery duration.

Hormone stimulation testing

GnRH stimulation testing was performed in 14 dogs. One additional dog (nr. 8) was tested for ORS because of the occurrence of mild vaginal bleeding 11 months after surgery. No other clinical signs were apparent and the only abnormality found during clinical evaluation was a small vaginal septum remnant on vaginoscopy.

Median time interval between ORS surgery and GnRH stimulation tests for the 14 dogs was 10.5 months (range, 1 to 25 months). Results of these tests confirmed that ovarian remnant tissue was no longer present. Moreover, none of the measured blood plasma hormone levels could indicate the presence of ovarian tissue, while at least 2 measurements (median 4, range 2 to 5) per dog indicated the absence of functional ovarian tissue (Table 10.3).

Long-term follow-up

Median duration between ORS surgery and last telephone follow-up was 22.5 months (range, 6 to 53 months). Despite having a negative GnRH stimulation test at 16 months postoperative

one dog remained to show increased attractiveness to male dogs according to the owners after a follow-up period of 51 months. None of the other dogs, including the ones that were attractive to male dogs or had vaginal discharge at the short-term follow-up, had any remaining signs fitting with ORS. Two dogs with reported stress/anxiety, one with abdominal pain, and one with pain during defecation preoperatively had all markedly improved. In one dog, signs of occasional abdominal discomfort ('prayer position') and vomiting did not improve after ORS surgery, although the dog did become more active and had a better appetite. In general all clinical signs of ORS disappeared completely after surgery. Overall activity level was subjectively increased in 16% of the dogs, appetite had increased in 16% and was reduced in 1 dog compared to the preoperative situation.

Table 10.3 Results of GnRH stimulation tests.

Dog Nr.	Post-op GnRH stim test	interval OR-GnRH stim test (months)	Mean basal E_2 (pmol/L)	E_2 t=60	E_2 t=120	Mean basal LH (µg/L)	LH t=10	LH t=60	Mean basal FSH (µg/L)	FSH t=10	FSH t=60	Basal FSH/E_2
4	28.1.2011	16.5	9.8	9.2	11.2	11.3	26.7	13.9	15.1	14.3	15.6	1.54
3	2.2.2011	17.5	19.4	8.8	8.6	29.8	30.8	25.4	31.0	21.6	32.1	1.60
5	22.2.2011	16	16.5	14.0	17.6	10.1	26.5	15.1	11.3	8.2	13.2	0.68
2	11.3.2011	20	18.4	18.0	16.5	25.3	38.1	22.2	24.2	19.0	24.8	1.31
6	3.5.2011	18	17.1	12.5	14.3	16.6	29.0	20.5	20.6	21.3	24.0	1.20
14	12.8.2011	1.5	<7	<7	<7	14.7	33.2	15.6	14.4	16.3	17.7	3.88
17	24.10.2011	1	<7	<7	<7	11.6	27.8	12.4	7.1*	7.9	8.1	2.95
16	5.12.2011	3	<7	<7	<7	10.4	31.6	8.2	13.2	10.8	13.3	3.56
12	9.12.2011	6.3	<7	<7	17.3	5.9	10.7	6.6	13.7	12.7	15.1	3.52
15	26.4.12	8.5	<7	<7	<7	20.8	43.9	26.6	20.0	21.4	20.5	11.08
11	11.5.2012	12	<7	<7	<7	15.7	22.2	12.2	18.1	18.3	17.5	7.22
8	25.5.2012	25	<7		<7							
21	27.2.2013	7	<7	<7	<7	4.9	13.1	7.2				
13	6.3.13	9	<7	<7	<7	19.3	36.0	15.4				

Mean basal plasma values of estradiol (E_2), LH and FSH are the average of two separate basal measurements at t=-40 and t=0. All measured plasma values that indicate absence of functional ovarian tissue are marked in red, based on previously published cut-off values (see Table 1).[9,36] None of the values are consistent with the existence of functional ovarian tissue. *The basal FSH of dog nr. 17 could in theory fit with an intact dog or a short time interval after OVE/OVH (see discussion section). The absence of an increase after GnRH is consistent with absence of ovarian tissue. Dog number is based on surgical order (date).

Discussion

Ovarian remnants were successfully removed by laparoscopic surgery in 32 dogs diagnosed with ORS. All had histologically confirmed ovarian tissue excised. All follow-up GnRH stimulation test results were consistent with the absence of ovarian tissue and all but one dog were completely free of clinical signs associated with ORS in the long-term follow-up. This one dog continued to show increased attractiveness to male dogs according to the owners. However, the dog was tested negative by GnRH stimulation test 16 months postoperative, was herself not interested in male dogs, and was free of any other sign of ORS after a follow-up period of 51 months. Therefore, attractiveness to male dogs, if truly present in this animal, is most probably caused by another reason (vestibulitis).

The laparoscopic approach was very effective for abdominal exploration and detection of ovarian remnants or suspect tissues. Being able to get a detailed and magnified close-up image of selected tissues was considered advantageous over conventional surgery for ORS, in which detection and surgical access to an ovarian remnant can be very demanding. Access to the pedicle area was usually considered sufficient. Proper visualization, including visual access to the caudoventral aspect of the kidney, was in most cases achieved using the standard 20 - 30° lateral tilting and 10 - 15° Trendelenburg positioning of the patient. This also facilitated identification of the caudal part of the ipsilateral ureter in most dogs, which was helpful during dissection of remnants located in this area. Difficult access to the pedicle was mainly caused by the existence of adhesions that would sometimes prevent the intestines, pancreas or spleen to be teased away from the area of interest. These cases were managed by increasing the Trendelenburg angle (up to 20°) and careful dissection of adhesions. In two cases an extra instrument portal was needed for additional retraction of organs to increase visibility of the area of interest. Most of the ovarian remnants could be revealed by locating, grabbing and lifting up the adhered ligaments and omentum. In that way, many of the remnants were also lifted up to some extent and could be recognized by their increased vasculature, bulky or cystic appearance. Gently lifting the remnant allowed dissecting it from all surrounding attachments (ligaments, omentum, and subperitoneal fat dorsally). The greatest difficulty was experienced with small ovarian remnants extensively covered by adhesions. In a few cases, the remnant was located in a very dorsal, almost subperitoneal position. In those cases, the remnant would

be covered by subperitoneal fat and did not move up by lifting adhered tissues but would be buried beneath them. Careful probe palpation and dissection was then applied to reveal and remove the remnant without leaving parts behind or damaging the ureter which runs close to it. Adhesions to the mesoduodenum, which were observed in 25% of the cases, could also be challenging because of the close proximity of the pancreas and the pancreaticoduodenal blood vessels. While the endoscopic technique was, at first, met with skepticism to be able to find the responsible remnant tissue in cases of ORS in challenging locations, it proved to be 100% successful in finding and removing all remnant tissue in each dog.

The incidence of referral and type of dogs with ORS in the present study is comparable to previous studies where large dogs were overrepresented.[7,9] In a study by Okkens et al (1981) 76% of dogs weighed more than 20 kg, which is similar to 75% weighing over 20 kg in the present study.[7] Likewise, the significant overrepresentation of right-sided remnants in the present study population, is also consistent with previous reports: it is related to the deeper and more cranial position of the right ovary making it more difficult to access during a standard laparotomy approach, thereby increasing the risk for ORS.[5-8] Ovarian remnants were found at the ovarian pedicle in 97% of the dogs which supports the cause as being a surgical error. There might, theoretically, be an increased risk for ORS after OVE compared to OVH because OVE necessitates 2 incisions near the ovary versus only one incision for OVH.[34] The majority of dogs (59%) in the present study were ovariectomized. However, only one dog (3%) had an ovarian remnant attached to a uterine horn. And so, with most of the remnant tissue (97%) being located at the ovarian pedicle, this argument is negligible. An improper surgical technique to remove ovaria in general bears a heavier influence than the discussion surrounding removal of the uterus or not as a reason for ORS.

A relatively high percentage of dogs (25%) was imported from other countries where they were originally spayed. Although this has not been mentioned in other studies, the occurrence of ORS in dogs imported from less developed regions might be higher. The fact that 20% of the dogs already underwent surgery by a general practitioner in an unsuccessful attempt to remove ovarian remnant tissue, stresses that surgery for ORS can be a challenge, especially in less experienced hands.[19,20] The absence of a left kidney in the presence of a left-sided ovarian remnant in the present study may indicate a grave surgical error: the accidental removal of a kidney during initial gonadectomy in this dog. However, the presence of a solitary

kidney or kidney agenesis cannot be ruled out. The absence of a kidney in a dog with ORS has been reported previously.[5]

The amount of adhesions generally observed in these patients was subjectively considered to be more extensive than would be expected after a properly performed OVE/OVH. Considering that 20% of the dogs already had a second surgery will certainly have contributed. And although the contralateral scar and uterine remnants were equally affected, it was noticed that the most severe adhesions were associated with the ovarian remnant. It is known that ORS may cause or promote chronic inflammatory lesions of the female canine reproductive tract, such as stump pyometra, cystic endometrial hyperplasia, and cystic changes in the ovarian remnant itself, which may all contribute to the formation of adhesions.[5,7,8] ORS in humans is usually associated with extensive adhesions.[14] But the situation differs from dogs, since the abdominal inflammatory lesions (endometriosis) are present before the ovariectomy, and recurrence of these lesions is associated with ovarian remnant tissue.

The recovery duration in this study was short and comparable to that of laparoscopic ovariectomy: discharge on the same day of surgery and full return of function after 1.5 days.[37,38] The significant relation apparent between minimally invasive surgery duration and postoperative convalescence length has not been described before. In humans, postoperative convalescence length is mainly affected by postoperative pain, as a result of high pneumoperitoneum pressures stretching the peritoneum and diaphragm or possibly a chemical irritation of CO_2 gas.[35,36] Dogs, on the other hand, only undergo low pneumoperitoneum pressures. But since surgical duration was prolonged in case of extensive adhesions, the increased recovery period most probably reflect the amount of peritoneal disruption during surgical dissection.

Using a vessel-sealing device (VSD) for dissection of adhesions and excision of tissues was very effective. The VSD was often also used as a mechanical dissecting forceps for dissecting and sealing of tissues with only minimal bleeding. All abnormal looking tissues were excised, including many ligature scars. In the authors' opinion all abnormal tissue that has some noticeable vasculature, small cyst-like changes, clear discoloration, or adhesions should be excised because ovarian remnants may be just a few millimeters in size.

The diagnostic value of preoperative ultrasound was higher in the present study than previously reported.[5,9] However, ultrasound cannot be used to prove or rule out the existence of functional ovarian tissue. The relatively low values for specificity (74%) of ultrasound diagnosis of the position of an ovarian remnant is largely explained by the high numbers of false positive diagnoses for the left ovarian pedicle. This may be due to a much lower incidence of an ovarian remnant on this side making the chance of false positive diagnosis higher for the left side than for the right side. On the other hand, false positive diagnosis is also affected by detection of scar tissue because ultrasound may not be able to reliably differentiate between scar tissue and an actual ovarian remnant in all cases. Since scar tissue can often not be reliably differentiated from small ovarian remnants by the naked eye and is therefore removed during surgery, the detection of a pedicle scar with ultrasound is considered helpful for ORS surgery. Knowing the location and approximate size of abnormalities seen with ultrasound may help deciding when to stop or go on with searching for abnormalities, especially in patients with extensive adhesions or obesity where only a small remnant was found during surgery. In such circumstances it can be helpful to know if more or larger abnormalities were found on ultrasound evaluation.

Histology proved that all the suspected material resected in the 32 dogs actually contained ovarian remnants. Sizes of remnants varied from several millimeters up to complete ovaries and cystic changes of several centimeters. Occasionally, large uterine cysts (up to 6 cm) were encountered, possibly caused by retention of fluid in the uterine lumen cranial to the site of ligation of the uterine horn. Two ovarian remnants turned out to contain a granulosa cell tumor. Formation of granulosa cell tumors in ovarian remnants is relatively common. In humans, it has been suggested that increased gonadotropin levels may increase the risk of ovarian tumor formation. The same may be true in dogs.[16] The incidence in the present study (6%) is lower than the previously reported incidence of 21 - 25%.[5,9] However, the true incidence and/or cause of tumor formation in ovarian remnants is unknown.

All results of follow-up GnRH stimulation tests were consistent with absence of ovarian tissue. These findings were confirmed clinically by the absence of clinical signs of ORS after a median follow-up period of 22.5 months. There was an apparent trend of higher mean basal estradiol values in the early cases (Table 10.2). These cases also had a longer interval between surgery and GnRH stimulation test. A certain low basal plasma estradiol concentration is

normally seen in dogs after gonadectomy, which might be a consequence of endogenous estradiol from conversion of androstenediol from the adrenal cortex. Although not reported before, this process may change in time after surgery, as is the case for LH and FSH plasma levels.[39,40] Nonetheless, estradiol did not increase after GnRH administration and was below the cut-off value at all times as expected after OVE/OVH (Table 2). The basal FSH of dog Nr. 17 could in theory fit with an intact dog (< 11.0 µg/L).[39] However, FSH did not increase after GnRH administration, which is consistent with absence of ovarian tissue. It has been described that gonadotrophic hormones are decreased between 4 to 10 weeks after OVE/OVH, after which they steadily increase until week 42.[40] This is one of the reasons that we preferably performed GnRH stimulation tests after a longer time interval and may explain the low basal plasma FSH in this dog, since it was tested only 1 month after surgery.

Findings in the present study support the theory that ORS is caused by surgical error with an important risk factor being difficult access during surgery (considering the large size of the dogs and the significant overrepresentation of right-sided ovarian remnants).

A laparoscopic approach for the removal of ovarian remnants in dogs was feasible and effective. The ability to change the position of the patient during the procedure, tilting sideways and in steep Trendelenburg position, is a requirement for proper access to both pedicles. A VSD facilitated good tissue dissecting and excision ability. The 100% success rate of this approach makes laparoscopic treatment of ORS a valid and more appealing alternative to laparotomy. Furthermore, recovery duration was short and subjective observations were indicative of similar advantages of laparoscopy compared to celiotomy for ORS as there are for other surgical procedures, including increased and detailed visibility of abdominal tissues. This leads us to conclude that a laparoscopic approach for ORS is not only successful but is also associated with the advantages of minimally invasive surgery in an otherwise invasive surgical procedure.

References

1. Pope JF, Knowles TG: Retrospective analysis of the learning curve associated with laparoscopic ovariectomy in dogs and associated perioperative complication rates. Vet Surg 2014;43:668-677.
2. Muraro L, White RS: Complications of ovariohysterectomy procedures performed in 1880 dogs. Tierarztl Prax Ausg K Kleintiere Heimtiere 2014;42:297-302.
3. Gunzel-Apel AR, Buschhaus J, Urhausen C, Masal C, Wolf K, Meyer-Lindenberg A, Piechotta M, Beyerbach M, Schoon HA: [Clinical signs, diagnostic approach and therapy for the so-called ovarian remnant syndrome in the bitch]. Tierarztl Prax Ausg K Kleintiere Heimtiere 2012;40:35-42; quiz 43.
4. Miller DM: Ovarian remnant syndrome in dogs and cats - 46 cases (1988-1992). J Vet Diagn Invest 1995;7:572-574.
5. Ball RL, Birchard SJ, May LR, Threlfall WR, Young GS: Ovarian remnant syndrome in dogs and cats: 21 cases (2000-2007). J Am Vet Med Assoc 2010;236:548-553.
6. Pearson H: The complications of ovariohysterectomy in the bitch. J Small Anim Pract 1973;14:257-266.
7. Okkens AC, Dieleman SJ: Gynecologic complications following ovariohysterectomy in dogs, due 1. partial removal of the ovaries, 2. inflammation of the uterocervical stump. Tijdschr Diergeneesk 1981;106:1142-1158.
8. Wallace MS: The ovarian remnant syndrome in the bitch and queen. Vet Clin North Am Small Anim Pract 1991;21:501-507.
9. Buijtels J, de Gier J, Kooistra HS, Naan EC, Oei CHY, Okkens AC: The pituitary-ovarian axis in dogs with remnant ovarian tissue. Theriogenology 2011;75:742-751.
10. Sontas BH, Ozyogurtcu H, Turna O, Arun S, Ekici H: Uterine leiomyoma in a spayed poodle bitch: a case report. Reprod in Domest Anim 2010;45:550-554.
11. Sontas BH, Altun ED, Guvenc K, Arun SS, Ekici H: Vaginal neurofibroma in a hysterectomized poodle dog. Reprod in Domest Anim 2010;45:1130-1133.
12. Poppl AG, Mottin TS, Gonzalez FHD: Diabetes mellitus remission after resolution of inflammatory and progesterone-related conditions in bitches. Res Vet Sci 2013;94:471-473.
13. Parker K, Snead E: Atypical presentation of ovarian remnant syndrome in a dog. J Am Anim Hosp Assoc 2014;50:E1-E5.
14. Kho RM, Abrao MS: Ovarian remnant syndrome: etiology, diagnosis, treatment and impact of endometriosis. Curr Opin Obstet Gynecol 2012;24:210-214.
15. Post K: Canine vaginal cytology during the estrous-cycle. Can Vet J 1985;26:101-104.
16. Buijtels J, de Gier J, Kooistra HS, Kroeze E, Okkens AC: Alterations of the pituitary-ovarian axis in dogs with a functional granulosa cell tumor. Theriogenology 2010;73:11-19.
17. Howe LM: Surgical methods of contraception and sterilization. Theriogenology 2006;66:500-509.
18. Naiman JH, Mayhew PD, Steffey MA, Culp WTN, Runge JJ, Singh A: Laparoscopic treatment of ovarian remnant syndrome in dogs and cats: 7 cases (2010-2013). J Am Vet Med Assoc 2014;245:1251-1257.
19. Fransson B: Ovaries and Uterus, in Tobias KM, Johnston SD (eds): Vet Surg: Small Animal, St. Louis, MO, Elsevier Saunders, 2012, pp 1871-1891.

20. Feldman EC, Nelson RW: Fertility, associated breeding disorders and disorders of sexual development, in Feldman EC, Nelson RW (eds): Canine and Feline Endocrinology and Reproduction, St. Louis, MO, Saunders, 2004, p 868.
21. Culp WTN, Mayhew PD, Brown DC: The effect of laparoscopic versus open ovariectomy on postsurgical activity in small dogs. Vet Surg 2009;38:811-817.
22. Davidson EB, Moll HD, Payton ME: Comparison of laparoscopic ovariohysterectomy and ovariohysterectomy in dogs. Vet Surg 2004;33:62-69.
23. Hancock RB, Lanz OI, Waldron DR, Duncan RB, Broadstone RV, Hendrix PK: Comparison of postoperative pain after ovariohysterectomy by harmonic scalpel-assisted laparoscopy compared with median celiotomy and ligation in dogs. Vet Surg 2005;34:273-282.
24. Devitt CM, Cox RE, Hailey JJ: Duration, complications, stress, and pain of open ovariohysterectomy versus a simple method of laparoscopic-assisted ovariohysterectomy in dogs. J Am Vet Med Assoc 2005;227:921-927.
25. Case JB, Boscan PL, Monnet EL, Niyom SR, Imhoff DJ, Wallace ML, Smeak DD: Comparison of surgical variables and pain in cats undergoing ovariohysterectomy, laparoscopic-assisted ovariohysterectomy, and laparoscopic ovariectomy. J Am Anim Hosp Assoc 2015;51:1-7.
26. Nickel RF: Postoperative Rekonvaleszenz nach Laparoskopischer und Konventioneller Ovariektomie: eine Vergleichende Studie. Kleintierpraxis 2007;52:413-424.
27. Nezhat F, Nezhat C: Operative laparoscopy for the treatment of ovarian remnant syndrome. Fertil Steril 1992;57:1003-1007.
28. Nezhat C, Kearney S, Malik S, Nezhat C, Nezhat F: Laparoscopic management of ovarian remnant. Fertil Steril 2005;83:973-978.
29. Abu-Rafeh B, Vilos GA, Misra M: Frequency and laparoscopic management ovarian remnant syndrome. J Am Assoc Gynecol Laparosc 2003;10:33-37.
30. Kho RM, Magrina JF, Magtibay PM: Pathologic findings and outcomes of a minimally invasive approach to ovarian remnant syndrome. Fertil Steril 2007;87:1005-1009.
31. Zapardiel I, Zanagnolo V, Kho RM, Magrina JF, Magtibay PM: Ovarian remnant syndrome: comparison of laparotomy, laparoscopy and robotic surgery. Acta Obstet Gynecol Scand 2012;91:965-969.
32. Krauss Z, Krauss M: Magnetic resonance imaging and laparoscopic management of an ovarian remnant in a bitch. Tierarztl Prax Ausg K Kleintiere Heimtiere 2015;43:111-114.
33. Finger BL, Brun MV, Colome LM, Pimentel RO, Feranti JPS: Videolaparoscopic surgery in the diagnosis and treatment of remaining ovary in a cat. Cienc Rural 2009;39:2539-2541.
34. Van Goethem B, Schaefers-Okkens A, Kirpensteijn J: Making a rational choice between ovariectomy and ovariohysterectomy in the dog: A discussion of the benefits of either technique. Vet Surg 2006;35:136-143.
35. Bisgaard T, Kehlet H, Rosenberg J: Pain and convalescence after laparoscopic cholecystectomy. Eur J Surg 2001;167:84-96.
36. Donatsky AM, Bjerrum F, Gogenur I: Surgical techniques to minimize shoulder pain after laparoscopic cholecystectomy. A systematic review. Surg Endosc 2013;27:2275-2282.
37. van Nimwegen SA, Kirpensteijn J: Comparison of Nd:YAG surgical laser and Remorgida bipolar electrosurgery forceps for canine laparoscopic ovariectomy. Vet Surg 2007;36:533-540.
38. van Nimwegen SA, Van Swol CFP, Kirpensteijn J: Neodymium:Yttrium aluminum garnet surgical laser versus bipolar electrocoagulation for laparoscopic ovariectomy in dogs. Vet Surg 2005;34:353-357.

39. de Gier J, Buijtels J, Albers-Wolthers CHJ, Oei CHY, Kooistra HS, Okkens AC: Effects of gonadotropin-releasing hormone administration on the pituitary-gonadal axis in male and female dogs before and after gonadectomy. Theriogenology 2012;77:967-978.
40. Reichler IM, Pfeiffer E, Piche CA, Jochle W, Roos M, Hubler M, Arnold S: Changes in plasma gonadotropin concentrations and urethral closure pressure in the bitch during the 12 months following ovariectomy. Theriogenology 2004;62:1391-1402.

11

Summarizing discussion and finalizing conclusion

Aim of this thesis

In **Chapter 1** the general aim and specific objectives of this thesis are presented. The rational was to review some recent technological developments in human surgery and evaluate their potential as a surgical innovation for canine gonadectomy. Driven by some of the technological advances described in this thesis, the past decade has truly confronted veterinarians with some important changes on veterinary elective gonadectomy, not only in current thinking but also in surgical techniques.

General introduction

In **Chapter 2** a literature review is provided covering relevant knowledge on gonadectomy as a method of contraception, the traditional surgical techniques for gonadectomy, the history of minimally invasive surgery in medicine and veterinary medicine, the creation of a pneumoperitoneum, the different hemostatic techniques available in minimally invasive surgery, hemostatic techniques available in traditional gonadectomy, and ovarian remnant syndrome in dogs.

Innovation is crucial for progress in surgery. However, experimental research can be harmful to patients since it is accompanied not only by successes but also by failures.[1] To limit the occurrence of failures, discussion with peers, openness to criticism, and being mindful of the patient's well-being while innovating remains essential.[2] Bearing this in mind, the studies in this thesis were only conducted when there was reasonable proof the innovating technique would not harm the patient.

Ethical issues can arise when surgical innovations result from new products that have been developed as collaborative efforts between surgical device companies and surgeons. This collaboration involves a risk of conflict of interest.[3] Since the innovations used in this thesis are all primarily developed for human surgery, no conflict of interests exists towards its use in dogs.

New surgical techniques often depend on new technology that can be significantly more expensive than traditional techniques. The introduction of robot-assisted surgery in medicine for example, and specifically the Da Vinci Surgical System, is considered by some "To be one of the biggest breakthroughs in surgery since the introduction of anesthesia, and represents the most significant advancement in minimally invasive surgery of this decade".[4,5] But despite the increasing popularity of robotic surgery, except in robot-assisted radical prostatectomy, there is yet no unequivocal evidence to show its superiority over traditional laparoscopic surgery in other surgical procedures.[5,6] Often there are no clear criteria to decide what new innovative techniques are going to turn out to be truly beneficial to patients, before actually implementing these techniques.[3] For robot-assisted surgery the take-up and use of the Da Vinci robot only becomes perfectly rational when the wider context is considered: smart nomenclature and novelty signify high-tech clinical excellence for the institution, the acquired device will result in research-related excellence, having access to robot-assisted surgery is performing better-than-the-competition, the robot's liberalized provision reduces financial risks, and finally having a robot will shape patients' choices and the public's expectations towards it.[7] Even more then in human medicine, affordability of innovative techniques is an important issue in veterinary medicine. And although innovative techniques may be expensive at first, economic principles dictate that when patent protection is lost and different competitors increase competition on the marketplace, prices will drop. This principle is nicely illustrated when looking at the decline of the price of vessel sealing devices since their introduction. And for robot-assisted surgery a similar evolution is expected to happen in the next five years.[8] Because veterinary medicine lags somewhat behind major innovations in human medicine, this price drop is often already the case by the time innovative techniques from human medicine are being picked up in veterinary medicine. Thus making these techniques immediately available also for use in general practice.

Since the risks of a novel operation may not be fully known, informed consent prior to surgery is a difficult requirement. In addition, even if the risks of a minimally invasive surgery are known in the hands of the innovator, the actual risks to patients when surgeons are learning the new technique are unknown.[3] Laparoscopic surgery is certainly associated with a learning curve.[9] Laparoscopic simulator training is therefore necessary before embarking on life minimally invasive surgery.[10,11] The studies in this thesis were always performed by

experienced (laparoscopic) surgeons. Nevertheless, for every laparoscopic procedure the surgeon is advised to inform the pet owner that laparoscopic treatment is intended, but conversion might become necessary at a given moment.[12] True conversion rates for therapeutic laparoscopic procedures have not been determined, but conversion rate in a cohort of diagnostic laparoscopy procedures performed at a single institution in 94 dogs and cats was 21%.[13]

Canine midline celiotomy closure

In **Chapter 3** the feasibility to use bidirectional barbed sutures for the closure of midline celiotomy incisions was evaluated. This novel suture material easily achieved three-layer closure in all dogs. It had good handling characteristics, avoided suture slacking and resulted in good cosmetic results with no wound healing complications. This descriptive study therefore concluded that it is safe to use this type of suture material for midline celiotomy closure. Prospective research in a much larger cohort of dogs is necessary to evaluate any potential benefit knotless suture material for celiotomy closure might have with regard to surgical time, impaired wound healing and cosmetics.

Ultrasound has not previously been reported in dogs for verification of abdominal wound healing. But it was found to be a valuable tool. When blinded ultrasonographic evaluation was used to compare healing of the celiotomy wall with a control group this study found similar ultrasonographic characteristics (disruption of abdominal wall layering, subcutaneous edema and gas) between the two methods evaluated.

Ovariectomy versus ovariohysterectomy

Strong personal opinions exists amongst veterinarians towards performing either ovariectomy or ovariohysterectomy for elective gonadectomy in dogs, and these are passed

on to future generations. In **Chapter 4,** the available literature of that time (till 2005) was reviewed to compare complications associated with ovariectomy and ovariohysterectomy. No scientific evidence to favor any technique was found: the incidence of long-term urogenital problems, including endometritis/pyometra and urinary incontinence did not differ amongst these two techniques. But because ovariohysterectomy is technically more complicated (important for inexperienced surgeons), time consuming, and is probably associated with greater morbidity compared to ovariectomy (larger incision, more intraoperative trauma, increased discomfort) we concluded that ovariectomy would be the preferred method of gonadectomy. At that time ovariectomy had slowly become the standard of care in many European countries thanks to the efforts of some visionary colleagues expressing their views about the unnecessary morbidity associated with OVH in all journals willing to accept this message.[14-16]

But it would take more to convince schools and colleges in the United States of America and Canada to change teaching solely ovariohysterectomy in surgical laboratories and start rewriting surgical textbooks. In an attempt to provide the veterinary community with the required evidence randomized prospective clinical trials were performed in different centers. A study in 2011 found that skin and fascia incision lengths were indeed significantly greater in dogs that underwent ovariohysterectomy, compared to those that underwent ovariectomy. Due to the small number of groups, however, no difference in short-term postoperative complications (pain scores and wound healing) was detected.[17]

In fact, by this time it was the client-driven popularity of minimally invasive surgery that started to change the unconvinced veterinarians' minds.[18] While laparoscopic and laparoscopic-assisted ovariohysterectomy are both possible, it is technically far easier to perform a laparoscopic ovariectomy.[19-21] And so the main driving force away from ovariohysterectomy as the routine gonadectomy technique has been the spreading popularity of laparoscopic ovariectomy. This is very similar to the way laparoscopic cholecystectomy in human medicine suddenly became the standard surgical technique, with over one-half million laparoscopic cholecystectomies performed in 1992, while scientific evidence about its superiority over traditional cholecystectomy only started to appear the following years.[22-27]

The veterinary community was therefore forced to look again at the available scientific evidence, searching for confirmation to validate ovariectomy as the standard technique. Using the same methodology as in our earlier study another review of the available literature in 2011 reached similar conclusions: stating that the potential advantages of ovariectomy were to include a smaller incision, better viewing of the ovarian pedicle, and possibly less risk of complications associated with surgical manipulation of the uterus.[28] In 2012, the hemostatic response to surgical neutering was compared between ovariectomy and ovariohysterectomy, where the first was expected to give less stimulation, but both groups had substantial hemostatic and fibrinolytic activation.[29] A study in 2013, looked at surgical duration in a veterinary teaching hospital in a large cohort of dogs (n = 108).[30] But since no clear guidelines where given to the inexperienced surgeons performing the actual surgery all dogs ended up with a sizeable incision length (9.2 cm length for 16.5 kg dogs) and a relatively long duration of surgery in both procedures (mean 90.3 min). Nevertheless, the authors of that study kept on supporting ovariectomy as an acceptable alternative to ovariohysterectomy in their conclusion. The first study to clearly report a statistically significant advantage for ovariectomy was published in Korea in 2013.[31] The authors extensively compared 6 ovariectomized dogs with 7 ovariohysterectomized dogs looking at: postoperative pain scores; plasma glucose, creatinine kinase, and cortisol; surgical time; duration of anesthesia; and incision length. The authors found ovariectomy the superior choice since compared to ovariohysterectomy dogs had shorter incision length, shorter surgical duration, shorter duration of anesthesia, lower pain scores, and lower surgical stress response.

Neuromuscular blocking agents during laparoscopy

Because prolonged capnoperitoneum has negative effects on the cardiorespiratory system, there is a delicate balance between achieving a large enough space to allow safe performance of laparoscopic surgery, and a low enough pressure not to compromise the patient’s health.

Surgical adaptations that can avoid prolonged high pressures are sought after by many minimally invasive surgeons. Simply working at low-pressure pneumoperitoneum would be an obvious solution. But a randomized controlled trial in human cholecystectomy working at low (7 - 10 mm Hg) versus standard (12 - 14 mm Hg) intra-abdominal pressures found that surgical times were increased because of the decreased working space at low pressures (low 49.07 ± 5.72 minutes versus high 46.43 ± 6.92 minutes).[32] And for laparoscopic nephrectomy with low-pressure pneumoperitoneum in humans even more pronounced differences were found (low 147 ± 86 minutes versus high 111 ± 19 minutes; $P < .04$).[33] When low pressure results in inferior operating conditions not only surgical duration will be prolonged but this may also lead to an increased incidence of surgical complications. Not surprisingly, one author reported a 40% failure rate in human laparoscopic cholecystectomy when intra-abdominal pressures of 8 mm Hg were used.[34]

In **Chapter 5** we evaluated the effect of neuromuscular blockade on working space, assuming that with a constant intra-abdominal pressure, relaxation of the abdominal muscles would allow for an increased working space. However, no differences in surgical times were found when the effect of neuromuscular blockade was evaluated during canine laparoscopic ovariectomy.[35]

An alternative, and possibly more accurate method of verifying an increase in working space is to use computed tomography scanning.[36,37] CT measurements allow for precise calculation of the actual pneumoperitoneum volume, whereas the volume of CO_2 gas released by the insufflator does not. When the increase in abdominal volume in pigs was measured with CT, volume increased 93% when the pressure rose from 5 to 10 mm Hg and with an additional 19% when pressure increased to 15 mm Hg.[38] But when the same group (Vlot et al) evaluated the effect of neuromuscular blockade on working space in pigs, they could not detect an difference based on CT measurements.[39] Although this study was performed in a different species, pigs are a good model for dogs since pigs also have an established pneumoperitoneum pressure threshold value of 15 mm Hg and are consequently very similar to dogs.[38] Therefore, we feel this study supports our earlier findings in dogs.

In human medicine, neuromuscular blockade is a common component of clinical anesthetic practice during laparoscopic surgery. Since low-pressure pneumoperitoneum in

humans is associated with less postoperative referral shoulder pain, neuromuscular blockade is added to the anesthetic protocol for low-pressure pneumoperitoneum in an attempt to improve surgical conditions.[40] But there is no strong evidence yet that moderate neuromuscular blockade (TOF counts of 1 - 3) is beneficial to a working space at fixed intra-abdominal pressure levels.[34] Current human research is therefore focused on the potential beneficial effects of deep neuromuscular blocks (TOF 0).[41-43] This type of blockade has been found to marginally improve surgical conditions in laparoscopic cholecystectomy, nephrectomy and prostatectomy.[44] Yet, even when neuromuscular block is effective in creating more working space, it does not necessarily entail that surgeons will automatically use lower inflation pressures.[34] And thus, the current advice in human laparoscopic procedures is to start with either moderate or deep neuromuscular block in combination with low-pressure pneumoperitoneum, and only increase the intra-abdominal pressure when surgical conditions require this (necessary in up to 50% of the patients).[44]

But the situation in dogs is different from the human situation. For most abdominal procedures in dogs optimal surgical working space conditions are already met at 8 - 12 mm Hg.[45] This would already be considered low-pressure pneumoperitoneum in humans.[32] Also these values are well below the cardiovascular deleterious threshold of 15 mm Hg. More importantly no complications regarding referral shoulder pain have been described in dogs.[46] And so, without a pressing need to lower the pneumoperitoneum pressures, there would hardly be any added benefit for neuromuscular blockade. Furthermore the economic repercussions of deep neuromuscular blockage (investment in monitors and cost of reversal products) would, in our opinion, prevent it from becoming a standard part of veterinary clinical anesthetic practice.

Rising intra-abdominal pressures will stretch the elastic abdominal wall muscles until their limit is reached.[38] This results in a typical pressure-volume curve where most increase in working space is achieved at low intra-abdominal pressures and only small improvements are evident at high intra-abdominal pressures.[47] Interestingly, when intra-abdominal pressures are lowered after first stretching the abdominal wall muscles for a certain time at high pressures, larger working spaces will be achieved at low intra-abdominal pressures due to this pre-stretching. Previous stepwise insufflation of the abdominal cavity in pigs increased subsequent working space volume by 21% at a repeat intra-abdominal pressure of 5 mm Hg,

7% at 10 mm Hg and 3% at 15 mm Hg.[48] This effect was even more pronounced in pigs with a smaller body size (6 versus 20 kg).[49] This phenomenon of muscle pre-stretching is often used in canine laparoscopy, sometimes even without the surgeon actually realizing it. When a Veress needle is used, one way to avoid laparoscopic entry complications, is to increase intra-abdominal pressure briefly to 12 – 15 mm Hg during entry of the trocar-cannula.[46] Also, after the first trocar-cannula is placed using the modified Hasson's technique, higher-end insufflation pressures are instilled for the placement of additional trocar-cannulae. Once all cannulae are in place, the intra-abdominal pressure is lowered to 6 - 8 mm Hg, thereby benefitting from the pre-stretched abdominal wall musculature and achieving a relatively larger working space for this set intra-abdominal pressure.

Another way of increasing the working space without having to increase the intra-abdominal pressure is to decrease intestinal content. Mechanical bowel preparation in pigs was found to result in a 43% relative increase at 5 mm Hg, 21% increase at 10 mm Hg, and 18% increase at 15 mm Hg.[50] Since dogs are carnivorous, as opposed to the omnivorous pig, and thus have less intestinal volume in the abdominal cavity the potential effect of mechanical bowel preparation would probably be less.

Drugs that potentially increase intra-abdominal pressures should be avoided during laparoscopic procedures. Intravenous administration of fentanyl in humans is known to increase the intra-abdominal pressure by stimulating the active contribution of abdominal muscles during expiration.[51] A study in 16 dogs, however, could not establish any effect of fentanyl on intra-abdominal pressures.[52]

On a side note, intra-abdominal pressure measurements based on the insufflator should always be interpreted carefully. Some researchers have found the cyclic mechanism of the insufflator to result in a variability that correlated poorly with the actual intra-abdominal pressure when measured with a separate intra-abdominal catheter connected to a pressure monitor.[53]

In an attempt to avoid a positive-pressure capnoperitoneum altogether, pediatric and geriatric human surgeons have investigated a lift device to pull the abdominal wall away from the intra-abdominal organs using an outside pulling force.[54] This creates an isobaric pneumoperitoneum in contrast to the positive pressure pneumoperitoneum created by the

laparoscopic insufflator. Despite the claimed advantages, meta-analysis of lift laparoscopy versus capnoperitoneum laparoscopy in human medicine have found no advantages of either technique with regard to intraoperative heart rate, intraoperative complications, duration of hospital stay, shoulder pain, blood pH or serum IL-6.[55] Lift laparoscopy was associated with shorter times to activity, lower postoperative $PaCO_2$ levels, and lower postoperative nausea and vomiting occurrences, while capnoperitoneum required a shorter surgical time.[55]

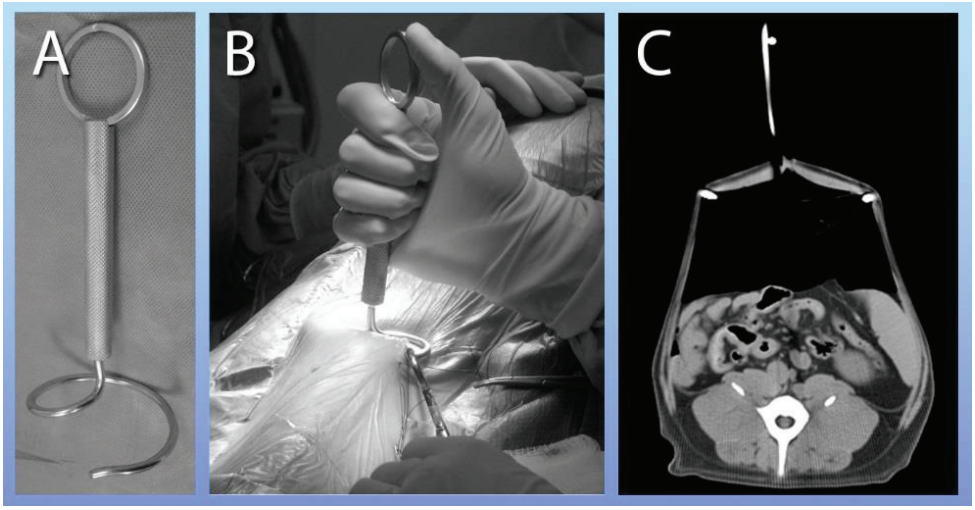

Figure 11.1 Lift laparoscopy (adapted from Fransson, Vet Surg, 2013 and Kennedy, Vet Surg, 2014).

The lift laparoscopy technique was picked up in veterinary medicine in 2011 and successfully used in dogs (Fig 11.1).[56] It was found that, in contrast to the positive pressure pneumoperitoneum, the isobaric pneumoperitoneum did not affect thoracic volume.[57] But evaluation of serum acute phase proteins (C-reactive protein) and interleukine-6, thought to play a role in the pathogenesis of surgical trauma, between lift laparoscopy and capnoperitoneum laparoscopy in dogs actually found higher levels of IL-6 in lift laparoscopy.[58] Other studies in healthy dogs showed that lift laparoscopy was associated with less frequency of hypercapnia, required less anesthetic gas, and was not more time-consuming or painful than capnoperitoneum laparoscopy.[59]

A potential reason why lift laparoscopy has not gained widespread use to date is that the amount of working space created by the lift laparoscopy approach differs from the traditional capnoperitoneum laparoscopy.[46] With a 12 mm Hg capnoperitoneum, the multidirectional centrifugal forces on the abdominal wall resulted in an 80% increase of abdominal volume, while the unidirectional tensile forces on the abdominal wall generated by the lift laparoscopy device only resulted in a 25% increase in abdominal volume.[57] Larger isobaric pneumoperitoneum volumes can be produced with increased tensile force, or with dual lifting at lower force.[60] This technique is however still in its infancy, having been reported in small numbers and without establishing the learning curve. Further evidence-based studies focusing on larger patient cohorts should be evaluated prospectively so that a potential benefit of this procedure becomes evident and that case selection criteria can be established.

Hemostatic techniques for ovariectomy

New drugs intended for human use require two separate double-blinded randomized clinical trials performed for approval by the United States of America Food and Drug Administration.[61] New surgical devices are not held to this same standard, therefore often resulting in a lack of randomized clinical trial data for specific surgical devices. Furthermore, many of the studies available around 2005, evaluated the efficacy of energy-based hemostatic surgical devices on vascular tissues (arteries and veins) harvested from pigs. There were no *in vivo* studies published on the efficacy and tissue interaction on life vascularized tissues. It is in this context that we developed several studies, described in this manuscript, with the intention to increase evidence-based knowledge of these vastly popular new surgical devices.

New energy-based hemostatic surgical devices are evaluated based on 5 criteria: efficiency, safety, reliability, consistency and utility.[62] When the new energy-based hemostatic surgical device is more efficient, it will result in a shorter surgical duration. Safety includes minimal electrothermal coagulation damage. Reliability refers to the new instrument achieving hemostasis for the designed procedure (vessel size). Consistency means the

hemostatic effect is independent of the user. And lastly utility refers to the ability to use the new instrument multiple times.

In **Chapter 6** (study performed in 2002-2003) we compared the current standard for laparoscopic hemostasis in veterinary medicine monopolar electrocoagulation over laparoscopic scissors (Endo Mini-Shears Short 5 mm; US Surgical Corporation, Norwalk, CT MEC), with a newly developed Take-Apart Bipolar Grasping forceps (Karl Storz-Endoscopy, The Netherlands). The Take-Apart Bipolar Grasping forceps has a structured surface that increases surface contact area of the instrument and the tissue and, therefore, may improve energy transmission during the electrocoagulation process.[63] Bearing the five evaluation criteria in mind we compared surgical time, the occurrence of intraoperative bleeding, and potential patient-related factors as age, weight, obesity, estrus, and pseudopregnancy. This prospective clinical trial consisted of 103 female dogs, a rather large number for comparative studies in veterinary medicine, and certainly a comfortable size for statistical evaluation. Unfortunately, because the newly developed hemostatic instrument was not always available, the study could not be randomized. The Take-Apart Bipolar Grasping forceps proved more efficient since it decreased surgical time compared to monopolar electrocoagulation (bipolar 40.8 $\pm$ 10 minutes versus monopolar 52.7 $\pm$ 14 minutes; $P < .001$). The instrument was also reliable and decreased the occurrence of intraoperative arterial pedicle bleeding (bipolar 4 dogs or 8% versus monopolar 7 dogs or 13%). Obesity (obesity 56 minutes versus normal 42 minutes; $P < .001$) and intraoperative mesovarial bleeding (bleeding 56 minutes versus no bleeding 46 minutes; $P = .03$) both increased surgical time. Dog age, estrus, and pseudopregnancy did not significantly influence surgical time.

Other studies compared the same grasping forceps (in 2005),[64] and later an improved model (in 2007),[65] versus laparoscopic laser hemostasis and found that the bipolar grasping forceps reduced surgical time and intraoperative ovarian pedicle bleeding. The Take-Apart Bipolar Grasping forceps was intended for multi-use (could be steam autoclaved) and can be connected to a standard electrosurgical generator. The efficiency of the instrument coupled with a low-investment cost made this instrument popular, not only in academia, but also in general practices performing minimally invasive surgery.[66] A drawback of the instrument, however, was that it did not divide tissue. And so multiple actions, coagulating interspersed with cutting, remained necessary. Further technological improvement of the hemostatic

instrument that avoided this switching of instruments could result in further surgical efficiency (surgical time benefit).

By 2006 an improved bipolar electrocoagulation instrument that seals and divides tissue started to emerge in veterinary medicine.[67,68] A meta-analysis in human medicine, based on 29 prospective randomized trials, found a mean operative time reduction of 28% for this vessel sealing device compared to monopolar electrocoagulation.[61] In **Chapter 7** (study performed in 2006-2007) the efficacy of the Take-Apart Bipolar Grasping forceps was compared to this new vessel sealing device (LigaSure, Covidien, Valleylab, Boulder, CO, USA) during canine laparoscopic ovariectomy. The LigaSure instrument has a smooth surface that is ideal to minimize direct physical injury to the tissue compared to the grooved surface from the Take-Apart Bipolar Grasping forceps, which may reduce the sticking of the instrument after the sealing process, but possibly does not guarantee appropriate thermal spread for a reliable vascular seal.[63] However, the new energy-based hemostatic surgical device was more efficient (surgical time for ovarian resection was decreased), safe (same depth of electrothermal coagulation damage but lower histological damage scores). In this study the effect of surgical experience was also evaluated. Not surprisingly, total surgical time and ovarian resection time with the Take-Apart Bipolar Grasping forceps (multiple-action procedure) was longer for the novice laparoscopic surgeon. But also ovarian resection time with LigaSure, despite being fitted with a feedback-equipped generator signaling the end of the sealing action, was longer for the novice surgeon. The reason for this is that ovarian resection requires three-dimensional maneuverability: the transection plane for the proper ligament is vertical, while it is horizontal for the ovarian pedicle and suspensory ligament. This is where a known learning curve exists for laparoscopic surgeons.[9,10,69] Furthermore, every energy-based hemostatic surgical device itself comes with a learning curve: the amount of tissue that can be grasped and successfully sealed will vary between instruments but also between tissue types. Drawbacks for the vessel sealing instrument are that it is designed to be a single-use instrument, and it requires a dedicated electrosurgical generator (impedance-controlled feedback software system). This prohibited LigaSure from becoming the standard laparoscopic hemostatic technique anywhere but in specific minimally invasive surgical centers (academia and referral practices).[70]

In **Chapter 8** (study performed in 2010-2011) a similar comparative study was performed during canine laparoscopic ovariectomy, now between the vessel sealing device (LigaSure) and an all-in-one bipolar electrocoagulation forceps (HotBlade, Patton Surgical, Austin, Tex, USA) with built-in cutting function. Since the combined coagulating-cutting bipolar forceps is a more economical alternative compared to the vessel sealing device this information would have practical implications for general practices that wanted to add minimally invasive procedures to their surgical repertoire. We concluded that HotBlade has great utility for the economy-minded surgeon, and is effective with sufficient instrument experience. But the LigaSure device was more efficient (shorter surgical times), safer (less thermal coagulation), and more reliable (intraoperative bleeding was only seen associated with HotBlade).

The same findings have been reproduced in a later study evaluating the feasibility for reduced port laparoscopic ovariectomy with an operating laparoscope. Dupré et al (2009) utilized two different vessel sealing devices and concluded that surgical times were significantly affected by body condition scores, ovarian ligament fat scores, ovarian bleeding, and surgeon expertise.[71] Both the single-portal and two-portal surgery proved later to be less painful compared to the standard three-portal surgery.[72] This first work could therefore be considered the stimulus to the further development of single-port-multi-access cannulae in dogs and allowing the propagation of single incision laparoscopic surgery (SILS).[69,73,74]

Values for thermal spread (electrocoagulation damage) found for LigaSure vary between our two studies. This is partly explained by the longer fixation period before processing (3.5 years) for samples in the second study. Formalin fixation is known to shrink tissue, which might also result in a decreased zone of thermal spread.[75-77] More importantly, the evaluation of thermal spread in these two studies was performed in two different institutions (Pathology lab Utrecht University and Ghent University). Different methods for sample processing and evaluation by different pathologists account for the differences. The first study used macroscopic evaluation under a stereo-microscope (30x magnification) using visual changes, while the second study evaluated histologic changes under a microscope (1000x magnification). Although the absolute numbers of thermal depth between the two studies vary, the results are, however, similar with regard to the distribution of thermal damage per location and per technique.

Thermal damage is determined by the degree of temperature and the exposure time.[78] Both will depend on the specific energy-based hemostatic surgical device used. The 10 mm LigaSure Atlas, for example, has lower instrument tip temperatures compared to the 5 mm instrument (Atlas 58.4 ± 3.0 °C versus 5-mm instrument 86.5 ± 5.1 °C) and also its cooling time is significantly shorter (Atlas 6.3 ± 0.6 °C versus 5-mm instrument 37.9 ± 4.8 °C) resulting, contrary to what intuitively is expected, in less thermal damage for the larger instrument.[79] When instrument tip temperatures are known to rise high, proper pauses can be inserted when working near temperature-sensitive areas to allow cooling of the instrument. But also the cooling time properties of the energy-based hemostatic surgical device will differ between instruments.[80] Mastery of energy-based hemostatic surgical devices is therefore considered a fundamental skill in the repertoire of the accomplished surgeon.[81]

. The clamp pressure originating from the articulated jaws of the 10 mm LigaSure Atlas is 0.72 N/mm^2.[82] Because the HotBlade instrument lacks articulated jaws, and compressive forces are generated by a spring mechanism, the pressure at the tip of the instrument is much lower. This lack of grip often resulted in tissue being pushed out from between the jaws when the cutting blade was advanced. This particularly happened when too much tissue was grasped with the instruments jaws adding another factor to the learning curve of the instrument. It also partly explains the longer surgical times and more thermal damage observed with this instrument compared to LigaSure. Another drawback for this device is that it was also designed for single-use thereby increasing surgical costs.[82]

A challenge we encountered during our evaluation of the available energy-based hemostatic surgical devices is the rapid evolution of devices. This makes it difficult to determine the optimal time for a clinical study, because by the time the study is completed, the device's features have already improved.[61] Currently, HotBlade is no longer commercially available. But very similar instruments like LiNA PowerBlade (LiNA Medical, Glostrup, Denmark) are still used in human medicine (Fig 11.2). An improved bipolar electrocoagulation forceps RoBi plus (Storz, Germany) became available in 2015 (Fig 11.3). It has articulated jaws and is designed for multi-use. Evidence of its efficiency from randomized clinical trials is currently lacking.

Figure 11.2 **LiNa PowerBlade is a disposable all-in-one bipolar electrocoagulation cutting forceps available in a 5 mm and 10 mm instrument.**

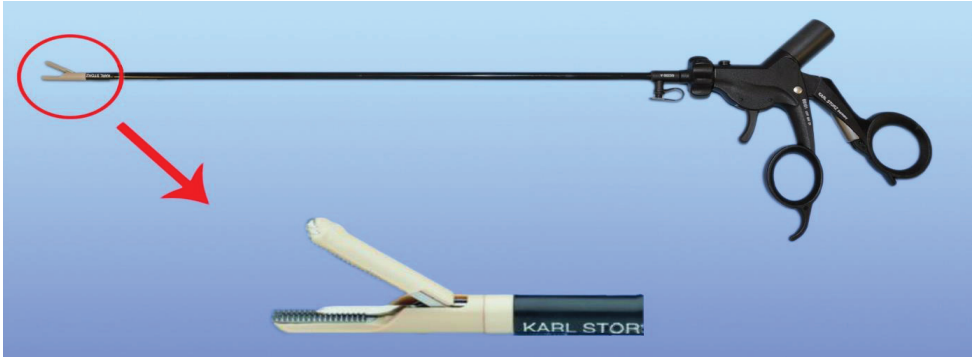

Figure 11.3 **RoBi plus is an autoclavable bipolar electrocoagulation cutting forceps.**

Figure 11.4 **MarSeal is an autoclavable bipolar energy-based hemostatic surgical device capable of vessel sealing and tissue dividing.**

Vessel sealant device in traditional ovariectomy

By this time, other researchers had also recognized that surgical efficiency during laparoscopic ovariectomy was increased using LigaSure for hemostasis.[83] With new and improved hemostatic technologies available for minimally invasive surgery, we wondered if it was time to reconsider the conventional suture ligation in conventional ovariectomy in dogs. Vessel sealing devices were certainly much faster compared to laparoscopic suture ligation.[84] But we were interested if this would also remain true for suture ligation during midline celiotomy approach.

In **Chapter 9** we compared a reusable vessel sealing device (LigaSure Std Reusable Instrument, Valleylab/Covidien) with suture ligation of the ovarian pedicle during traditional midline celiotomy approach for canine ovariectomy. Time to remove the ovary was decreased with almost 50% when the vessel sealing device was used (vessel sealing device 2.22 ± 0.58 minutes versus suture ligation 4.10 ± 1.13 minutes; $P < .001$). The results of our study clearly indicate that ovarian pedicle hemostasis achieved by a vessel sealing device is significantly faster than by placement of ligatures and this without appearing to compromise safety. Although not investigated in this study, the absence of foreign suture material and the decrease in the amount of devitalized tissue (the pedicle stump distal to the ligature) could potentially lead to a decrease in postoperative pain and/or adhesions. A meta-analysis in human medicine based on 29 prospective randomized trials concluded that vessel sealing devices not only reduced mean operative time with 28%, but was also associated with a mean 43 mL less blood loss, showed fewer complications, and reduced mean postoperative pain.[61]

In addition to the LigaSure device used in these studies, there are other vessel sealing devices available. Enseal (SurgRx, Ethicon, Cincinnati, OH) claims to offer improved efficacy by utilizing a temperature-sensitive matrix, consisting of nanopolar thermostats embedded within the jaws of the device, that controls the energy delivered to the electrode-tissue interface.[85] Radiofrequency energy travels in the jaws from external to internal, causing less thermal spread compared to LigaSure where the energy travels back and forth between the two jaws.[86] Caiman (Aragon, Palo Alto, CA) has an articulated head to create more uniform tissue compression and uses an algorithm based on a pulse waveform modulation that

monitors and delivers current in relation to power, voltage and resistance. This results in virtually no tissue charring or tissue adhesion. Gyrus (Gyrus Medical, Maple Grove, Minnesota) is a bipolar electrosurgical device that uses plasma kinetic technology to deliver a high current and very low voltage to the tissue.[87,93] Using electrothermal energy in a series of rapid pulses allows coagulation interspersed with a cooling phase, thereby decreasing lateral thermal spread.[94] Many studies comparing Enseal and/or Gyrus to LigaSure concluded the latter has the highest bursting pressures and fastest sealing time overall.[78,85,88,95-98] Some have, however, stated that mean bursting pressure values cannot be used to select the superior hemostatic instrument since all vessel sealing instruments' bursting pressures are well beyond normal physiologic levels.[95] So, the clinical significance of these comparative findings is unknown.[99]

Vessel sealing devices have been successfully used in dogs for partial liver lobectomies,[100] partial lung lobectomies,[101] splenectomy,[102] partial pancreatectomy,[103] and uterine horn and body occlusion.[104] With the all-round usefulness of these vessel sealing devices in conventional surgical procedures their usage in general surgical practice is predictable.[105] The last obstacle that remained, the disposable instruments resulting in increased surgical cost, has been removed now that reusable vessel sealing devices have been developed (Fig 11.4). *In vivo* testing of the reusable MarSeal (KLS Martin, Tuttlingen, Germany) on sheep arteries demonstrated similar bursting strengths compared to LigaSure and even shorter sealing times.[82] Another vessel sealing device, BiClamp (ERBE, Tübingen, Germany) has been used extensively in conventional surgery (human thyroidectomy)[106] and minimally invasive surgery.[107]

Technological progress did not stop with the development of electrothermal bipolar vessel sealing devices (Table 11.1). Surgical hemostasis can also be achieve with a mechanical induced thermal seal.[78,108,109] Ultrasonic systems, like the Harmonic ACE (Ethicon Endo-surgery, Cincinnati, OH), or Sonosurg (Olympus Medical Systems Corp, Tokyo, Japan) deliver high frequency ultrasonic waves, at about 55,000 vibrations per second, that generate high temperatures to seal and divide vessels up to 5 mm in diameter.[79,92,95,110] This system reaches very high instrument temperatures (195.9 ± 14.5 °C), so particular care should be taken when it is used during laparoscopy.[79,87,97,98] But, proper use of the instrument produces the least thermal damage when compared to electrothermal vessel sealing.[78,111] A earlier prototype of

Table 11.1 Comparison of characteristics of 4 energy-based hemostatic surgical devices.

	Monopolar	Bipolar	Vessel sealing device	Ultrasonic
Method of hemostasis	Coagulation	Coagulation	Vessel sealing	Vessel sealing
Build-in cutting function	no	some all-in-one	laparoscopy devices	yes
Power setting	50 - 80 W	30 - 50 W	2-3 bars	55.000 Hz
Instrument temperature	70 °C	62 °C	40 - 96 °C	125 - 300 °C
Tissue temperature	400 °C	>100 °C	56 - 100 °C	80 - 227 °C
Vessel diameter	1 - 2 mm	< 3 mm	≤ 7 mm	≤ 5 mm
Thermal spread	10 - 20 mm	2 - 6 mm	1 - 4 mm	1 - 4 mm
Cooling time (to 50 °C)	17 sec	11 sec	20 - 40 sec	27 - 45 sec

Combined information.[78,79,88,90,104-107]

this instrument, Ultracision (Ethicon Endo-Surgery Inc., Cincinnati, OH) was the first in 2003 to describe an ultrasonic energy-based hemostatic surgical device for laparoscopic ovariohysterectomy in 9 dogs.[112] More recently, Autosonix (Covidien Surgical Inc, Sao Paulo, SP, Brazil) was successfully used for canine ovariohysterectomy.[70] The Sonicision Cordless Ultrasonic Dissector (Covidien, Medtronic, France) is assembled with a reusable battery and generator on a base hand-piece (Fig 11.5).[91] In 2012 this instrument was used for the first time in a clinical setting (for a radical nephrectomy and a pelvic lymphadenectomy in man).[113]

THUNDERBEAT (Olympus Medical Systems Corp, Tokyo, Japan) is a prototype that combines the best of both technologies: ultrasonically generated frictional heat energy and bipolar heat energy simultaneously (Fig 11.6).[114] Preliminary research concluded that it has the potential the potential to surpass the dissection speed of ultrasonic devices with the sealing efficacy of bipolar clamps.[115,116]



Figure 11.5 Sonicision is a cordless energy-based hemostatic surgical device that uses ultrasonic energy to achieve vessel sealing and tissue division. The reusable generator is located on the tip of the instrument, powered by a battery case in the handhold.

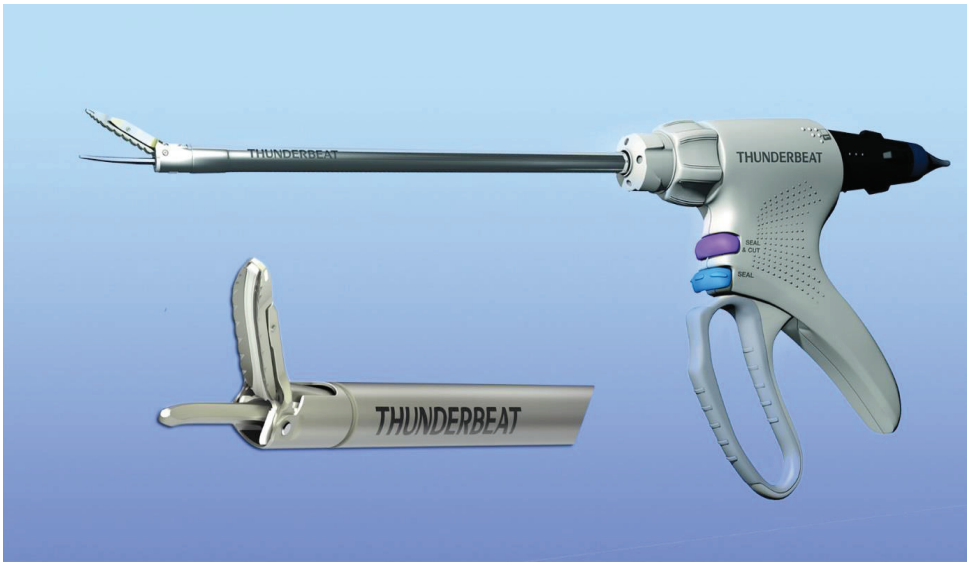

Figure 11.6 THUNDERBEAT is an energy-based hemostatic surgical device that combines bipolar and ultrasonic energy to achieve vessel sealing and tissue division.

Laparoscopy for ovarian remnant syndrome treatment

Surgical treatment of ovarian remnant syndrome in dogs usually necessitates large celiotomy incisions and considerable manipulation of organs because of the relatively deep position of ovarian remnant tissue and the likely presence of adhesions. The rationale for a laparoscopic approach of canine ovarian remnant syndrome is logical when considering that conventional surgery for ovarian remnant syndrome is much more invasive compared to conventional elective ovariectomy.

In **Chapter 10,** thirty-two client-owned dogs diagnosed with ovarian remnant syndrome underwent laparoscopic surgery for removal of ovarian remnants. Adhesions were observed in 79% of the dogs and extensive adhesions certainly complicated the surgical approach. Tissue dissection and resection was performed using a 5 mm vessel sealant device (LigaSure). Electrothermal bipolar vessel sealing devices are designed to do just that, sealing arteries and veins.[67] But, they have been found to be much more versatile since the instrument can be used to seal and transect most soft tissues. The standard straight Dolphin Tip instrument was successfully used in this study to dissect tissues. This feature has been recognized by the company, and tip adaptations of the LigaSure have now resulted in hand instruments more adapted to the dissection of delicate tissues, like the curved tip Maryland Jaw.[117,118] The LigaSure Advance even has a monopolar tip for cutting less vascularized tissue during dissection.[119] Both these variations of the hand instrument could have facilitated dissection of ovarian remnants in the presence of severe adhesions.

As expected, laparoscopy enabled detailed visibility and facilitated detection of suspected ovarian tissue. Laparoscopic removal was 100% successful with a mean surgery duration of 107 ± 33 minutes. And especially the rapid convalescence duration (1.5 ± 0.7 days) should be a stimulus for veterinarians to replace an otherwise invasive surgical procedure by this minimally invasive variation.

Figure 11.7 Different tip constructions for the 5 mm LigaSure vessel sealer (from left to right): Dolphin tip, Maryland tip, Pistol tip, and Blunt tip compared to the 10 mm LigaSure Atlas.

General conclusion

The fact that many routine surgical procedures such as elective gonadectomy lend themselves so well to a minimally invasive approach is a strong driving force behind the increasing use of minimally invasive surgery in veterinary practice.[8] When laparoscopic ovariectomy is compared to traditional ovariectomy the first is found to be less invasive,[120] associated with less postoperative pain and stress,[121-124] less postoperative adhesion formation,[125,126] a shorter convalescence[127] and earlier discharge from the hospital.[20] It is therefore no surprise that veterinary minimally invasive surgery is advancing rapidly to allow our small animal patients to benefit from all these documented advantages.

For hemostasis during minimally invasive surgery different energy-based hemostatic surgical devices are available. And although they all have their specific advantages and disadvantages, the vessel sealing device LigaSure was superior to the alternatives used in our studies. Innovative surgeons are invited to embrace these new technologies. For it is an

exciting concept to be able to offer our small animal patients many of the advantages that have been realized in human medicine before.

However, we should avoid blindly relying on new and unproven technologies. Surgeons should be well informed from evidence-based research on the instrument's capabilities, and have appropriate hemostatic instrument and procedural training.[119] For, in the words of Andrew Brill (past president of the American Association of Gynecologic Laparoscopists): "In the end it's not the wand, but the magician (that makes the difference)."

References

1. Strong VE, Forde KA, MacFadyen BV, Mellinger JD, Crookes PF, Sillin LF, Shadduck PP: Ethical considerations regarding the implementation of new technologies and techniques in surgery. Surg Endosc 2014;28:2272-2276.
2. Shivaprakasha K: Innovations - not crossing the red line. Indian J Med Ethics 2013;10:121-123.
3. Angelos P: Ethics and Surg Innov: Challenges to the professionalism of surgeons. Int J Surg 2013;11 Suppl 1:S2-5.
4. Wilson TG: Advancement of technology and its impact on urologists: release of the Da Vinci Xi, a new surgical robot. Eur Urol 2014;66:793-794.
5. Ng AT, Tam PC: Current status of robot-assisted surgery. Hong Kong Med J 2014;20:241-250.
6. Brody F, Richards NG: Review of robotic versus conventional laparoscopic surgery. Surg Endosc 2014;28:1413-1424.
7. Abrishami P, Boer A, Horstman K: Understanding the adoption dynamics of medical innovations: affordances of the Da Vinci robot in the Netherlands. Soc Sci Med 2014;117:125-133.
8. Mayhew PD: Recent advances in soft tissue minimally invasive surgery. J Small Anim Pract 2014;55:75-83.
9. Pope JF, Knowles TG: Retrospective analysis of the learning curve associated with laparoscopic ovariectomy in dogs and associated perioperative complication rates. Vet Surg 2014;43:668-677.
10. Uson-Gargallo J, Tapia-Araya AE, Martin-Portugues IDG, Sanchez-Margallo FM: Development and evaluation of a canine laparoscopic simulator for veterinary clinical training. J Vet Med Educ 2014;41:218-224.
11. Dauster B, Steinberg AP, Vassiliou MC, Bergman S, Stanbridge DD, Feldman LS, Fried GM: Validity of the mistels simulator for laparoscopy training in urology. J Endourol 2005;19:541-545.
12. McClaran JK, Buote NJ: Complications and need for conversion to laparotomy in small animals. Vet Clin North Am Small Anim Pract 2009;39:941-951.
13. Buote NJ, Kovak-McClaran JR, Schold JD: Conversion from diagnostic laparoscopy to laparotomy: risk factors and occurrence. Vet Surg 2011;40:106-114.

14. Okkens AC, Kooistra HS, Nickel RF: Comparison of long-term effects of ovariectomy versus ovariohysterectomy in bitches. J Reprod Fertil 1997:227-231.
15. Okkens AC, Kooistra HS, Nickel RF: Comparison of long-term effects of ovariectomy versus ovariohysterectomy in bitches. Tijdschr Diergeneesk 2002;127:369-372.
16. Okkens AC, Kooistra HS, Nickel RF: Comparison of long-term effects of ovariectomy versus ovariohysterectomy in bitches. Prakt Tierarzt 2003;84:98-101.
17. Peeters ME, Kirpensteijn J: Comparison of surgical variables and short-term postoperative complications in healthy dogs undergoing ovariohysterectomy or ovariectomy. J Am Vet Med Assoc 2011;238:189-194.
18. Parkinson TJ: Progress towards less invasive veterinary surgery. Vet Rec 2012;171:67-68.
19. Gower S, Mayhew P: Canine laparoscopic and laparoscopic-assisted ovariohysterectomy and ovariectomy. Compend Cont Educ Vet 2008;30:430-440.
20. Devitt CM, Cox RE, Hailey JJ: Duration, complications, stress, and pain of open ovariohysterectomy versus a simple method of laparoscopic-assisted ovariohysterectomy in dogs. J Am Vet Med Assoc 2005;227:921-927.
21. Case JB, Boscan PL, Monnet EL, Niyom SR, Imhoff DJ, Wallace ML, Smeak DD: Comparison of surgical variables and pain in cats undergoing ovariohysterectomy, laparoscopic-assisted ovariohysterectomy, and laparoscopic ovariectomy. J Am Anim Hosp Assoc 2015;51:1-7.
22. Perissat J: Laparoscopic cholecystectomy - the European experience. Am J Surg 1993;165:444-449.
23. Barkun JS, Barkun AN, Sampalis JS, Fried G, Taylor B, Wexler MJ, Goresky CA, Meakins JL: Randomized controlled trial of laparoscopic versus mini-cholecystectomy. Lancet 1992;340:1116-1119.
24. Barkun AN, Barkun JS, Sampalis JS, Fried GM, Meakins JL, Goresky CA: A randomized clinical-trial comparing gallbladder stone shock-wave lithotripsy to laparoscopic cholecystectomy. Gastroenterology 1993;104:A2-A2.
25. Barkun JS, Barkun AN, Meakins JL, Bailar J, Battista RN, Brassard R, Bret PM, Fried G, Garzon J, Hinchey EJ, Joseph L, Mamazza J, Sigman H, Stein L, Sampalis J, Szego PL, Taylor B, Wexler MJ: Laparoscopic versus open cholecystectomy - the Canadian experience. Am J Surg 1993;165:455-458.
26. Barkun AN, Barkun JS, Sampalis JS, Caro J, Fried GM, Meakins JL, Joseph L, Goresky CA, McGill Gallstone Treatment Group: Costs and effectiveness of extracorporeal gallbladder stone shock wave lithotripsy versus laparoscopic cholecystectomy - a randomized clinical trial. Int J Technol Assess Health Care 1997;13:589-601.
27. Spaner SJ, Warnock GL: A brief history of endoscopy, laparoscopy, and laparoscopic surgery. J Laparoendosc Adv Surg Tech A 1997;7:369-373.
28. DeTora M, McCarthy R: Ovariohysterectomy versus ovariectomy for elective sterilization of female dogs and cats: is removal of the uterus necessary? J Am Vet Med Assoc 2011;239:1409-1412.
29. Moldal ER, Kristensen AT, Peeters ME, Nodtvedt A, Kirpensteijn J: Hemostatic response to surgical neutering via ovariectomy and ovariohysterectomy in dogs. Am J Vet Res 2012;73:1469-1476.
30. Harris KP, Adams VJ, Fordyce P, Ladlow J: Comparison of surgical duration of canine ovariectomy and ovariohysterectomy in a veterinary teaching hospital. J Small Anim Pract 2013;54:579-583.

31. Lee S-S: Comparison of ovariectomy and ovariohysterectomy in terms of postoperative pain behavior and surgical stress in dogs. J Vet Clinics 2013;30:166-171.
32. Kanwer DB, Kaman L, Nedounsejiane M, Medhi B, Verma GR, Bala I: Comparative study of low-pressure versus standard-pressure pneumoperitoneum in laparoscopic cholecystectomy - a randomised controlled trial. Trop Gastroenterol 2009;30:171-174.
33. Warle MC, Berkers AW, Langenhuijsen JF, van der Jagt MF, Dooper PM, Kloke HJ, Pilzecker D, Renes SH, Wever KE, Hoitsma AJ, van der Vliet JA, D'Ancona FCH: Low-pressure pneumoperitoneum during laparoscopic donor nephrectomy to optimize live donors' comfort. Clin Transplant 2013;27:E478-E483.
34. Kopman AF, Naguib M: Laparoscopic surgery and muscle relaxants: is deep block helpful? Anesth Analg 2015;120:51-58.
35. Van Goethem B, van Nimwegen SA, Akkerdaas I, Murrell JC, Kirpensteijn J: The effect of neuromuscular blockade on canine laparoscopic ovariectomy: a double-blinded, prospective clinical trial. Vet Surg 2012;41:374-380.
36. Elliott RC, Kirberger RM: Computed tomography determined changes in position of the urogenital system after CO_2 insufflation to determine optimal positioning for abdominal laparoscopy. Vet Surg 2015;44:91-99.
37. Elliott RC, Kirberger RM, Joubert KE: Computed tomography determined changes in position of the hepatobiliary and gastrointestinal systems after CO_2 insufflation to determine optimal positioning for abdominal laparoscopy. Vet Surg 2015;44:100-112.
38. Vlot J, Wijnen R, Stolker RJ, Bax K: Optimizing working space in porcine laparoscopy: CT measurement of the effects of intra-abdominal pressure. Surg Endosc 2013;27:1668-1673.
39. Vlot J, Specht PA, Wijnen RMH, van Rosmalen J, Mik EG, Bax KMA: Optimizing working space in laparoscopy: CT-measurement of the effect of neuromuscular blockade and its reversal in a porcine model. Surg Endosc 2015;29:2210-2216.
40. Hua J, Gong J, Yao L, Zhou B, Song ZS: Low-pressure versus standard-pressure pneumoperitoneum for laparoscopic cholecystectomy: A systematic review and meta-analysis. Am J Surg 2014;208:143-150.
41. Van Wijk RM, Watts RW, Ledowski T, Trochsler M, Moran JL, Arenas GWN: Deep neuromuscular block reduces intra-abdominal pressure requirements during laparoscopic cholecystectomy: a prospective observational study. Acta Anaesthesiol Scand 2015;59:434-440.
42. Madsen MV, Gatke MR, Springborg HH, Rosenberg J, Lund J, Istre O: Optimising abdominal space with deep neuromuscular blockade in gynaecologic laparoscopy - a randomised, blinded crossover study. Acta Anaesthesiol Scand 2015;59:441-447.
43. Staehr-Rye AK, Rasmussen LS, Rosenberg J, Juul P, Lindekaer AL, Riber C, Gatke MR: Surgical space conditions during low-pressure laparoscopic cholecystectomy with deep versus moderate neuromuscular blockade: a randomized clinical study. Anesth Analg 2014;119:1084-1092.
44. Madsen MV, Staehr-Rye AK, Gatke MR, Claudius C: Neuromuscular blockade for optimising surgical conditions during abdominal and gynaecological surgery: a systematic review. Acta Anaesthesiol Scand 2015;59:1-16.
45. Milovancev M, Townsend KL: Current concepts in minimally invasive surgery of the abdomen. Vet Clin North Am Small Anim Pract 2015;45:507-+.
46. Mayhew PD: Complications of minimally invasive surgery in companion animals. Vet Clin North Am Small Anim Pract 2011;41:1007-21.

47. Mayhew PD, Pascoe PJ, Kass PH, Shilo-Benjamini Y: Effects of pneumoperitoneum induced at various pressures on cardiorespiratory function and working space during laparoscopy in cats. Am J Vet Res2013;74:1340-1346.
48. Vlot J, Wijnen R, Stolker RJ, Bax K: Optimizing working space in laparoscopy: CT measurement of the effect of pre-stretching of the abdominal wall in a porcine model. Surg Endosc 2014;28:841-846.
49. Vlot J, Staals LME, Wijnen RMH, Stolker RJ, Bax KMA: Optimizing working space in laparoscopy: CT measurement of the influence of small body size in a porcine model. J Pediatr Surg 2015;50:465-471.
50. Vlot J, Slieker JC, Wijnen R, Lange JF, Bax KMA: Optimizing working-space in laparoscopy: Measuring the effect of mechanical bowel preparation in a porcine model. Surg Endosc 2013;27:1980-1985.
51. Drummond GB, Duncan NK: Abdominal pressure during laparoscopy: effects of fentanyl. Br J Anaesth 2002;88:384-388.
52. Dorfelt R, Ambrisko TD, Moens Y: Influence of fentanyl on intra-abdominal pressure during laparoscopy in dogs. Vet Anaesth Analg 2012;39:390-397.
53. Iorio B, de Barros RF, Miranda ML, de Oliveira AG, Bustorff-Silva JM: Evaluation of a simple valve mechanism used to stabilize intra-abdominal pressure during surgically induced pneumoperitoneum in small animals. Surg Endosc 2012;26:528-532.
54. Bossotti M, Bona A, Borroni R, Mattio R, Coda A, Ferri F, Martino F, Dellepiane M: Gasless laparoscopic-assisted ileostomy or colostomy closure using an abdominal wall-lifting device. Surg Endosc-Ultras 2001;15:597-599.
55. Ren H, Tong Y, Ding XB, Wang X, Jin SQ, Niu XY, Zhao X, Li Q: Abdominal wall-lifting versus CO_2 pneumoperitoneum in laparoscopy: A review and meta-analysis. Int J Clin Exp Med 2014;7:1558-1568.
56. Fransson BA, Ragle CA: Lift laparoscopy in dogs and cats: 12 cases (2008-2009). J Am Vet Med Assoc 2011;239:1574-1579.
57. Watkins C, Fransson BA, Ragle CA, Mattoon J, Gay JM: Comparison of thoracic and abdominal cavity volumes during abdominal CO_2 insufflation and abdominal wall lift. Vet Surg 2013;42:607-612.
58. Zhang JT, Shao JT, Liu YF, Wang HB: Gasless laparoscopic ovariohysterectomy and comparison of serum levels of interleukin-6 and C-reactive protein after LOHE and traditional laparoscopic ovariohysterectomy in bitches. Bull Vet Inst Pulawy 2013;57:127-130.
59. Fransson BA, Grubb TL, Perez TE, Flores K, Gay JM: Cardiorespiratory changes and pain response of lift laparoscopy compared to capnoperitoneum laparoscopy in dogs. Vet Surg 2015;44:7-14.
60. Kennedy KC, Fransson BA, Gay JM, Roberts GD: Comparison of pneumoperitoneum volumes in lift laparoscopy with variable lift locations and tensile forces. Vet Surg 2015;44:83-90.
61. Macario A, Dexter F, Sypal J, Cosgriff N, Heniford BT: Operative time and other outcomes of the electrothermal bipolar vessel sealing system (LigaSure) versus other methods for surgical hemostasis: a meta-analysis. Surg Innov 2008;15:284-291.
62. Rasche A, Hanisch S, Eick S, Hegemann O, Kraft M: The choice of surgical techniques for dissecting tissue. An evaluation software. Biomed Tech (Berl) 2014;59:S398-S400.

63. Richter S, Kollmar O, Schilling MK, Pistorius GA, Menger MD: Efficacy and quality of vessel sealing - comparison of a reusable with a disposable device and effects of clamp surface geometry and structure. Surg Endosc 2006;20:890-894.
64. van Nimwegen SA, Van Swol CFP, Kirpensteijn J: Neodymium:Yttrium aluminum garnet surgical laser versus bipolar electrocoagulation for laparoscopic ovariectomy in dogs. Vet Surg 2005;34:353-357.
65. van Nimwegen SA, Kirpensteijn J: Comparison of Nd:YAG surgical laser and Remorgida bipolar electrosurgery forceps for canine laparoscopic ovariectomy. Vet Surg 2007;36:533-540.
66. Van Goethem B, Bosch M, Stegen L: Laparoscopie in de gezelschapsdierenpraktijk. Deel 1: instrumentarium en basisprincipes. Vlaams Diergeneeskd Tijdschr 2009;78:365-371.
67. Kennedy JS, Stranahan PL, Taylor KD, Chandler JG: High-burst-strength, feedback-controlled bipolar vessel sealing. Surg Endosc-Ultras 1998;12:876-878.
68. Heniford BT, Matthews BD, Sing RF, Backus C, Pratt B, Greene FL: Initial results with an electrothermal bipolar vessel sealer. Surg Endosc-Ultras 2001;15:799-801.
69. Runge JJ, Boston RC, Ross SB, Brown DC: Evaluation of the learning curve for a board-certified veterinary surgeon performing laparoendoscopic single-site ovariectomy in dogs. J Am Vet Med Assoc 2014;245:828-835.
70. Guizzo N, Feranti JPS, Bairros MC, Bortoluzzi M, Motta AC, Sartori LW, Santos FR, Tomazzoni FV, Brambatti G, Guedes RL, Silva MAM, Brun MV: Ultrasonic shears and bipolar vessel-sealing system for three-port laparoscopic ovariohysterectomy in dogs. Arq Bras Med Vet Zootec 2015;67:55-61.
71. Dupre G, Fiorbianco V, Skalicky M, Gultiken N, Ay SS, Findik M: Laparoscopic ovariectomy in dogs: comparison between single portal and two-portal access. Vet Surg 2009;38:818-824.
72. Case JB, Marvel SJ, Boscan P, Monnet EL: Surgical time and severity of postoperative pain in dogs undergoing laparoscopic ovariectomy with one, two, or three instrument cannulas. J Am Vet Med Assoc 2011;239:203-208.
73. Runge JJ, Curcillo PG, King SA, Podolsky ER, Holt DE, Davidson J, Agnello KA: Initial application of reduced port surgery using the single port access technique for laparoscopic canine ovariectomy. Vet Surg 2012;41:803-806.
74. Runge JJ, Mayhew PD: Evaluation of single port access gastropexy and ovariectomy using articulating instruments and angled telescopes in dogs. Vet Surg 2013;42:807-813.
75. Clarke BS, Banks TA, Findji L: Quantification of tissue shrinkage in canine small intestinal specimens after resection and fixation. Can J Vet Res 2014;78:46-49.
76. Reimer SB, Seguin B, DeCock HE, Walsh PJ, Kass PH: Evaluation of the effect of routine histologic processing on the size of skin samples obtained from dogs. Am J Vet Res 2005;66:500-505.
77. Johnson RE, Sigman JD, Funk GF, Robinson RA, Hoffman HT: Quantification of surgical margin shrinkage in the oral cavity. Head Neck 1997;19:281-286.
78. Phillips CK, Hruby GW, Duvak E, Lehman DS, Humphrey PA, Mansukhani MM, Landman J: Tissue response to surgical energy devices. Urology 2008;71:744-748.
79. Eto K, Omura N, Haruki K, Uno Y, Ohkuma M, Nakajima S, Anan T, Kosuge M, Fujita T, Yanaga K: A comparison of laparoscopic energy devices on charges in thermal power after application to porcine mesentery. Surg Laparosc Endosc Percutan Tech 2015;25:E37-E41.
80. Campbell PA, Cresswell AB, Frank TG, Cuschieri A: Real-time thermography during energized vessel sealing and dissection. Surg Endosc 2003;17:1640-1645.

81. Massarweh NN, Cosgriff N, Slakey DP: Electrosurgery: History, principles, and current and future uses. J Am Coll Surgeons 2006;202:520-530.
82. Klar M, Haberstroh J, Timme S, Fritzsch G, Gitsch G, Denschlag D: Comparison of a reusable with a disposable vessel-sealing device in a sheep model: Efficacy and costs. Fertil Steril 2011;95:795-798.
83. Wenkel R, Ziemann U, Thielebein J, Prange H: Laparoskopische Kastration der Hündin: Darstellung neuer verfahren zur Minimal Invasieven Ovariohysterektomie. Tierarztl Prax 2005;33:177-188.
84. Mayhew PD, Brown DC: Comparison of three techniques for ovarian pedicle hemostasis during laparoscopic-assisted ovariohysterectomy. Vet Surg 2007;36:541-547.
85. Smaldone MC, Gibbons EP, Jackman SV: Laparoscopic nephrectomy using the enseal tissue seating and hemostasis system: Successful therapeutic application of nanotechnology. JSLS 2008;12:213-216.
86. Sahin DA, Kusaslan R, Sahin O, Akbulut G, Bas O, Dilek ON: Histopathological effects of bipolar vessel sealing devices on liver parenchyma and comparison with suture method: an experimental study. Eur Surg Res 2007;39:111-117.
87. Kim FJ, Chammas MF, Gewehr E, Morihisa M, Caldas F, Hayacibara E, Baptistussi M, Meyer F, Martins AC: Temperature safety profile of laparoscopic devices: Harmonic ACE (ACE), LigaSure V (LV), and Plasma Trisector (PT). Surg Endosc 2008;22:1464-1469.
88. Lamberton GR, Hsi RS, Jin DH, Lindler TU, Jellison FC, Baldwin DD: Prospective comparison of four laparoscopic vessel ligation devices. J Endourol 2008;22:2307-2312.
89. Dubiel B, Shires PK, Korvick D, Chekan EG: Electromagnetic energy sources in surgery. Vet Surg 2010;39:909-924.
90. Van Goethem B, Schoemaker N, Ensink J: Electro-, cryo-, laser and endoscopic surgery, in Kirpensteijn J, Klein WR (eds): The cutting edge (2nd ed), London, UK, Roman House Publishers, 2012, pp 46-53.
91. Tsirline VB, Lau KN, Swan RZ, Montero PN, Sindram D, Martinie JB, Iannitti DA: Evaluation of an innovative, cordless ultrasonic dissector. Surg Innov 2013;20:524-529.
92. Kim FJ, Sehrt D, da Silva RD, Gustafson D, Nogueira L, Molina WR: Evaluation of emissivity and temperature profile of laparoscopic ultrasonic devices (blades and passive jaws). Surg Endosc 2015;29:1179-1184.
93. Gozen AS, Teber D, Rassweiler JJ: Principles and initial experience of a new device for dissection and hemostasis. Minim Invasive Ther Allied Technol 2007;16:58-65.
94. Santa-Cruz RW, Auge BK, Lallas CD, Preminger GM, Polascik TJ: Use of bipolar laparoscopic forceps to occlude and transect the retroperitoneal vasculature: a porcine model. J Endourol 2003;17:181-185.
95. Box GN, Lee HJ, Abraham JB, Deane LA, Elchico ER, Abdelshehid CA, Alipanah R, Taylor MB, Andrade L, Edwards RA, Borin JF, McDougall EM, Clayman RV: Comparative study of in vivo lymphatic sealing capability of the porcine thoracic duct using laparoscopic dissection devices. J Urology 2009;181:387-391.
96. Carbonell AM, Joels CS, Kercher KW, Matthews BD, Sing RF, Heniford BT: A comparison of laparoscopic bipolar vessel sealing devices in the hemostasis of small-, medium-, and large-sized arteries. J Laparoendosc Adv S-Part A 2003;13:377-380.

97. Diamantis T, Kontos M, Arvelakis A, Syroukis S, Koronarchis D, Papalois A, Agapitos E, Bastounis E, Lazaris AC: Comparison of monopolar electrocoagulation, bipolar electrocoagulation, ultracision, and LigaSure. Surg Today 2006;36:908-913.
98. Diamantis T, Gialikaris S, Kontos M, Gakiopoulou C, Felekouras E, Papalois A, Agrogiannis G, Patsouris E, Bastounis E: Comparison of safety and efficacy of ultrasonic and bipolar thermal energy - an experimental study. Surg Laparosc Endosc Percutan Tech 2008;18:384-390.
99. Person B, Vivas DA, Ruiz D, Talcott M, Coad JE, Wexner SD: Comparison of four energy-based vascular sealing and cutting instruments: a porcine model. Surg Endosc 2008;22:534-538.
100. Risselada M, Ellison GW, Bacon NJ, Polyak MMR, van Gilder J, Kirkby K, Kim SE: Comparison of 5 surgical techniques for partial liver lobectomy in the dog for intraoperative blood loss and surgical time. Vet Surg 2010;39:856-862.
101. Mayhew PD, Culp WTN, Pascoe PJ, Arzi NV: Use of the LigaSure vessel-sealing device for thoracoscopic peripheral lung biopsy in healthy dogs. Vet Surg 2012;41:523-528.
102. Monarski CJ, Jaffe MH, Kass PH: Decreased surgical time with a vessel sealing device versus a surgical stapler in performance of canine splenectomy. J Am Anim Hosp Assoc 2014;50:42-45.
103. Wouters EGH, Buishand FO, Kik M, Kirpensteijn J: Use of a bipolar vessel-sealing device in resection of canine insulinoma. J Small Anim Pract 2011;52:139-145.
104. Matz BM, Tillson DM, Boothe HW, Dillon RA, Cattley RC: Effect of vascular seal configuration using the LigaSure on arterial challenge pressure, time for seal creation, and histologic features. Vet Surg 2014;43:761-764.
105. Barrera JS, Monnet E: Effectiveness of a bipolar vessel sealant device for sealing uterine horns and bodies from dogs. Am J Vet Res 2012;73:302-305.
106. Pniak T, Formanek M, Matousek P, Zelenik K, Kominek P: Bipolar thermofusion BiClamp 150 in thyroidectomy: a review of 1156 operations. Biomed Res Int 2014;2014:1-4.
107. Uchiyama H, Itoh S, Higashi T, Korenaga D, Takenaka K: Pure laparoscopic partial hepatectomy using a newly developed vessel sealing device, BiClamp. Surg Laparosc Endosc Percutan Tech 2013;23:E116-E118.
108. Bubenik LJ, Hosgood G, Vasanjee SC: Bursting tension of medium and large canine arteries sealed with ultrasonic energy or suture ligation. Vet Surg 2005;34:289-293.
109. Harold KL, Pollinger H, Matthews BD, Kercher KW, Sing RF, Heniford BT: Comparison of ultrasonic energy, bipolar thermal energy, and vascular clips for the hemostasis of small-, medium-, and large-sized arteries. Surg Endosc 2003;17:1228-1230.
110. Matthews BD, Pratt BL, Backus CL, Kercher KW, Mostafa G, Lentzner A, Lipford EH, Sing RF, Heniford BT: Effectiveness of the ultrasonic coagulating shears, LigaSure vessel sealer, and surgical clip application in biliary surgery: a comparative analysis. Am Surg 2001;67:901-906.
111. Landman J, Kerbl K, Rehman J, Andreoni C, Humphrey PA, Collyer W, Olweny E, Sundaram C, Clayman RV: Evaluation of a vessel sealing system, bipolar electrosurgery, harmonic scalpel, titanium clips, endoscopic gastrointestinal anastomosis vascular staples and sutures for arterial and venous ligation in a porcine model. J Urology 2003;169:697-700.
112. Austin B, Lanz OI, Hamilton SM, Broadstone RV, Martin RA: Laparoscopic ovariohysterectomy in nine dogs. J Am Anim Hosp Assoc 2003;39:391-396.
113. Kim FJ, Sehrt D, Molina WR, Pompeo A: Clinical use of a cordless laparoscopic ultrasonic device. JSLS 2014;18:5.

114. Milsom J, Trencheva K, Monette S, Pavoor R, Shukla P, Ma JJ, Sonoda T: Evaluation of the safety, efficacy, and versatility of a new surgical energy device (THUNDERBEAT) in comparison with harmonic ACE, LigaSure V, and Enseal devices in a porcine model. J Laparoendosc Adv S 2012;22:378-386.
115. Seehofer D, Mogl M, Boas-Knoop S, Unger J, Schirmeier A, Chopra S, Eurich D: Safety and efficacy of new integrated bipolar and ultrasonic scissors compared to conventional laparoscopic 5-mm sealing and cutting instruments. Surg Endosc 2012;26:2541-2549.
116. Tanaka R, Gitelis M, Meiselman D, Abar B, Zapf M, Carbray J, Vigneswaran Y, Zhao JC, Ujiki M: Evaluation of vessel sealing performance among ultrasonic devices in a porcine model. Surg Innov 2015;22:338-343.
117. Petrucci F, Antoniazzi G, Valerio S: Use of the LigaSure Maryland Jaw in radical prostatectomy: our experience. Anticancer Research 2015;35:3637-3638.
118. Zaidi N, Glover AR, Sidhu SB: The Covidien LigaSure Maryland Jaw device. Expert Rev Med Devices 2015;12:151-155.
119. Peycke LE: Facilitation of soft tissue surgery surgical staplers and vessel sealing devices. Vet Clin North Am Small Anim Pract 2015;45:451-461.
120. Hoglund OV, Olsson K, Hagman R, Ohlund M, Olsson U, Lagerstedt AS: Comparison of haemodynamic changes during two surgical methods for neutering female dogs. Res Vet Sci 2011;91:159-163.
121. Davidson EB, Moll HD, Payton ME: Comparison of laparoscopic ovariohysterectomy and ovariohysterectomy in dogs. Vet Surg 2004;33:62-69.
122. Hancock RB, Lanz OI, Waldron DR, Duncan RB, Broadstone RV, Hendrix PK: Comparison of postoperative pain after ovariohysterectomy by Harmonic Scalpel-assisted laparoscopy compared with median celiotomy and ligation in dogs. Vet Surg 2005;34:273-282.
123. Marcovich R, Williams AL, Seifman BD, Wolf JS: A canine model to assess the biochemical stress response to laparoscopic and open surgery. J Endourol 2001;15:1005-1008.
124. Lee JY, Kim MC: Comparison of oxidative stress status in dogs undergoing laparoscopic and open ovariectomy. J Vet Med Sci 2014;76:273-276.
125. Schippers E, Tittel A, Ottinger A, Schumpelick V: Laparoscopy versus laparotomy: comparison of adhesion-formation after bowel resection in a canine model. Dig Surg 1998;15:145-147.
126. Gamal EM, Metzger P, Szabo GY, Brath E, Peto K, Olah A, Kiss J, Furka I, Miko I: The influence of intraoperative complications on adhesion formation during laparoscopic and conventional cholecystectomy in an animal model. Surg Endosc-Ultras 2001;15:873-877.
127. Culp WTN, Mayhew PD, Brown DC: The effect of laparoscopic versus open ovariectomy on postsurgical activity in small dogs. Vet Surg 2009;38:811-817.

12

Samenvattende bespreking en eindconclusie

Doel van dit proefschrift

In **Hoofdstuk 1** wordt het algemene doel en de specifieke doelstellingen van dit proefschrift voorgesteld. Het algemene doel is om enkele recente technologische ontwikkelingen in de humane geneeskunde te beoordelen op hun potentiële gebruik als een nieuwe chirurgische ontwikkeling voor gonadectomie bij de teef. In het voorbije decennium werden dierenartsen geconfronteerd met enkele belangwekkende veranderingen op het vlak van de preventieve gonadectomie. Het gaan hier niet alleen on de keuze van de ingreep (ovariëctomie versus ovariohysterectomie), maar ook in de toegepaste chirurgische techniek (middenlijn versus flank benadering, laparoscopische versus conventionele techniek, keuze van de hemostatische techniek). De specifieke doelstellingen van dit proefschrift focussen op onderzoek naar de best mogelijke keuze inzake ingreep en techniek.

Algemene inleiding

In **Hoofdstuk 2** wordt op basis van een intensief literatuuronderzoek een overzicht gegeven van de hedendaagse kennis met betrekking tot:

- gonadectomie als methode van contraceptie bij de hond,
- de geschiedenis van minimaal invasieve chirurgie in de humane geneeskunde,
- de geschiedenis van minimaal invasieve chirurgie bij de hond,
- het aanleggen van een pneumoperitoneum aan de start van een laparoscopische ingreep,
- de verschillende beschikbare hemostatische technieken tijdens traditionele gonadectomie,
- het ovarieel rest syndroom bij de hond.

Innovatie is essentieel voor vooruitgang in de chirurgie. Experimenteel onderzoek kan echter ook nadelig zijn voor patiënten, aangezien zulk onderzoek niet automatisch leidt tot succes, maar ook kan mislukken.[1] Om de kans op mislukking te verkleinen is het essentieel om overleg te plegen met andere onderzoekers, open te staan voor suggesties en kritiek, en het

welzijn van de patiënt steeds voorop te stellen.[2] Met dit in het achterhoofd, werden de studies voor dit proefschrift enkel uitgevoerd wanneer er een redelijk bewijs was dat de innovatieve techniek de patiënt niet zou schaden.

Er kunnen problemen ontstaan wanneer chirurgische innovaties voortkomen uit nieuwe producten die zijn ontwikkeld vanuit een gezamenlijke inspanning van commerciële bedrijven en chirurgen. Deze samenwerking houdt namelijk het risico in van een belangenconflict.[3] Aangezien de technologische ontwikkelingen gebruikt in dit proefschrift allemaal in de eerste plaats werden ontwikkeld voor gebruik in de humane geneeskunde, en de diergeneeskunde ten opzichte hiervan slechts een erg beperkte afzetmarkt biedt, treedt er bij de in dit proefschrift gebruikte technologieën geen belangenconflict op.

Nieuwe chirurgische technieken zijn vaak gebaseerd op nieuwe technologieën die opvallend duurder zijn dan de traditionele technieken. De introductie van robot-geassisteerde chirurgie in de humane geneeskunde bijvoorbeeld, en meer in het bijzonder het Da Vinci Surgical System, wordt door sommigen beschouwd als 'één van de grootste doorbraken in chirurgie sinds de ontwikkeling van anesthesie, en vertegenwoordigt de meest significante vooruitgang in minimaal invasieve chirurgie dit decennium.'[4,5] Maar ondanks de toenemende populariteit van robotchirurgie is er, op robot-geassisteerde radicale prostatectomie na, geen eenduidig bewijs van enige superioriteit ten opzichte van traditionele laparoscopische chirurgie.[5,6] Vaak zijn er geen duidelijke criteria om te bepalen welke nieuwe innovatieve technieken echt gunstig gaan zijn voor de patiënten, alvorens deze technieken daadwerkelijk uit te voeren.[3] Voor robot-geassisteerde chirurgie is het gebruik van het Da Vinci Surgical System enkel te verantwoorden wanneer wordt gekeken naar de ruimere context:

- slimme naamgeving en nieuwigheid genereert hightech faam voor een instelling, wat op zijn beurt klinische uitmuntendheid suggereert,
- het verworven apparaat kan worden gebruikt voor gespecialiseerd onderzoek (onontgonnen publicatie terrein),
- robot-geassisteerde chirurgie kunnen uitvoeren betekent beter presteren dan competitieve instellingen die niet over robots beschikken,
- de vrijstelling van erelonen wanneer gebruik wordt gemaakt van robotchirurgie dekt het financiële risico van de aanschaf ervan,

- en ten slotte zal de aanwezigheid van een robot de verwachtingen van patiënten en het publiek vormen.[7]

Nog meer dan in de humane geneeskunde zal de betaalbaarheid van innovatieve technieken een belangrijk onderwerp zijn in de diergeneeskunde. En hoewel innovatieve technieken in het begin duur kunnen zijn, zullen economische principes dicteren dat wanneer de octrooibescherming vervalt en er verschillende firma's robots aanbieden, deze concurrentie op de markt de prijzen zal doen dalen. Dit principe wordt mooi geïllustreerd als we kijken naar de daling van de prijs van *vessel sealing* apparaten sinds hun introductie. En voor robotchirurgie wordt een gelijkaardige evolutie verwacht de komende vijf jaar.[8] Omdat diergeneeskunde enigszins achterloopt op belangrijke innovaties in de geneeskunde, is deze economisch-gedicteerde prijsdaling vaak al het geval op het moment dat innovatieve technieken uit de humane geneeskunde worden opgepikt in de diergeneeskunde. Hierdoor zijn deze technieken dan ook vrij snel beschikbaar voor gebruik in de algemene praktijk.

Aangezien het risico van een nieuwe operatietechniek niet volledig is bekend, is het opstellen van een geïnformeerd toestemmingsdocument, voorafgaand aan de eigenlijke chirurgie, moeilijk. Zelfs wanneer de risico's van een minimaal invasieve chirurgische procedure in handen van de innovator bekend zijn, dan nog is het daadwerkelijke risico voor de patiënt, indien een arts de techniek pas aanleerde, niet bekend.[3] Laparoscopische chirurgie is omwille van de specifieke motorische vaardigheden geassocieerd met een leercurve.[9] Laparoscopische simulator training is daarom noodzakelijk vooraleer minimaal invasieve chirurgische procedures bij patiënten uit te voeren.[10,11] De studies vervat in dit proefschrift werden daarom altijd uitgevoerd door ervaren (laparoscopische) chirurgen. Niettemin werd, voorafgaand aan de ingreep, de eigenaar telkens gewezen op de intentie de ingreep laparoscopisch tot een goed einde te brengen, maar dat, wanneer conversie in het belang van het dier noodzakelijk was, dit zonder aarzelen zou worden uitgevoerd.[10] De werkelijke frequentie van conversie in geval van therapeutische laparoscopische procedures is nog niet bekend, maar conversie naar een traditionele benadering in een cohort van diagnostische laparoscopische procedures uitgevoerd in één enkele instelling bij 94 honden en katten bleek 21%.[11]

Hechtmateriaal met weerhaken voor het sluiten van de buikwand

In **Hoofdstuk 3** wordt de haalbaarheid geëvalueerd om voor het sluiten van middellijn celiotomie incisies bidirectioneel hechtmateriaal met weerhaken te gebruiken. Met dit nieuw ontwikkelde hechtmateriaal was het gemakkelijk om bij alle honden de drie verschillende weefsellagen (buikwand, subcutis en huid) te sluiten. Het hechtmateriaal had daarnaast een zeer goede hanteerbaarheid, het progressieve verankeren van de weerhaken op het hechtmateriaal zorgde voor een perfecte weefselappositie, zonder de noodzaak om voortdurende spanning op de draad te houden, er traden geen wondhelingscomplicaties op, en het cosmetische eindresultaat was goed. Deze beschrijvende studie concludeert dat het veilig is om voor het sluiten van een middellijn celiotomie dit hechtmateriaal met weerhaken te gebruiken. Prospectief onderzoek bij een veel groter aantal honden is nodig om eventuele voordelen van hechtmateriaal met weerhaken op het vlak van de operatietijd, snelheid van wondgenezing en cosmetisch aspect te bepalen.

In deze studie werd voor het eerst gebruik gemaakt van echografisch onderzoek voor het opvolgen van de abdominale wondgenezing. Dit werd eerder al bij andere diersoorten gebruikt, maar bleek nu ook bij de hond een waardevol instrument. Vergelijkend onderzoek tussen de studiepopulatie en de controlegroep, door een onderzoeker die niet op de hoogte was van het gebruikte hechtmateriaal, bracht vergelijkbare echografische kenmerken aan het licht met betrekking tot de verstoring van de weefsellagen, de aanwezigheid van subcutaan oedeem en gas.

Ovariëctomie versus ovariohysterectomie

Vele dierenartsen hebben sterke persoonlijke overtuigingen wat betreft het uitvoeren van een ovariëctomie of een ovariohysterectomie voor electieve gonadectomie bij honden. Deze overtuigingen worden vooral op basis van persoonlijke voorkeur doorgegeven aan volgende generaties. In **Hoofdstuk 4** wordt de, tot 2005 beschikbare, literatuur kritisch doorgenomen op zoek naar wetenschappelijke argumenten om een voorkeur voor een

bepaalde techniek te vinden. Op basis van de beschreven complicaties geassocieerd met ovariëctomie en ovariohysterectomie kon geen verschil worden vastgesteld: het voorkomen van urogenitale problemen op de lange termijn, zoals cysteuze endometrium hyperplasie of pyometra en urine-incontinentie verschilde niet bij deze twee technieken. Wel werd vastgesteld dat ovariohysterectomie technisch meer ingewikkeld is, meer tijdrovend is (omdat er meer structuren dienen te worden afgebonden en omdat er een grotere incisie moet worden gesloten), en naar alle waarschijnlijkheid geassocieerd is met een grotere morbiditeit (grotere incisie, meer intra-operatieve trauma, verhoogde pijn). Deze elementen zouden meer uitgesproken zijn wanneer onervaren chirurgen de ingreep uitvoeren. Vandaar dat wordt geconcludeerd dat ovariëctomie de voorkeurstechniek is voor een electieve gonadectomie, in het bijzonder wanneer uitgevoerd door onervaren chirurgen. Op het tijdstip van dit reviewartikel was gonadectomie dan ook reeds langzaam uitgegroeid tot de standaardoperatie in vele Europese landen. Dit dankzij de inspanningen van enkele visionaire collega's die bezorgd waren over de onnodige morbiditeit geassocieerd met ovariohysterectomie en elke kans grepen om de voorkeur voor ovariëctomie te verspreiden onder dierenartsen.[12-14]

Maar het zou meer vragen om ook scholen en universiteiten in de Verenigde Staten van Amerika en Canada te overtuigen uitsluitend ovariohysterectomie te onderwijzen in wet-lab trainingen en chirurgische tekstboeken te herschrijven. In een poging de diergeneeskundige gemeenschap het vereiste bewijs te bezorgen werden gerandomiseerde prospectieve klinische studies uitgevoerd in verschillende centra. Uit een studie in 2011 bleek dat de incisielengtes in de huid en buikwand inderdaad significant groter waren bij honden die ovariohysterectomie ondergingen, vergeleken met de andere die ovariëctomie onderging.[15] Vanwege het kleine aantal honden in elke groep kon echter geen verschil worden opgemerkt met betrekking tot postoperatieve complicaties (pijnscores en wondheling).

Eigenlijk was het meer de opkomende populariteit van minimaal invasieve chirurgie en de vraag van eigenaars naar deze technieken die de overstap van ovariohysterectomie naar ovariëctomie bewerkstelligden.[16] Terwijl zowel laparoscopische als laparoscopisch-geassisteerde ovariohysterectomie mogelijk zijn, is het technisch veel gemakkelijker om een laparoscopische ovariëctomie uit te voeren.[17-19] En dus werd de belangrijkste drijvende kracht om af te stappen van ovariohysterectomie als de routine gonadectomie techniek, de

toenemende populariteit van laparoscopische ovariëctomie. Dit is zeer vergelijkbaar met de manier waarop enkele jaren eerder laparoscopische cholecystectomie in de humane geneeskunde plotseling de standaard chirurgische techniek werd op basis van de vraag van de patiënten. Zo werden in 1992 meer dan een half miljoen laparoscopische cholecystectomieën uitgevoerd, terwijl wetenschappelijk bewijs van de superioriteit van deze techniek ten opzichte van de traditionele cholecystectomie pas de jaren erna begon op te duiken.[20-25]

Geconfronteerd met een verschuiving richting ovariëctomie, ging de diergeneeskundige gemeenschap opnieuw kijken naar het beschikbare wetenschappelijke bewijs om ovariëctomie te valideren als de standaard techniek. Met behulp van dezelfde methode als in onze review studie zes jaar eerder, werd in 2011 de beschikbare literatuur opnieuw doorgenomen.[26] De auteurs kwamen tot gelijkaardige conclusies en identificeerden potentiële voordelen van ovariëctomie over ovariohysterectomie als daar zijn: een kleinere incisielengte, een betere zichtbaarheid van de ovariële ophangband (door de meer craniale incisie), en minder kans op complicaties te wijten aan chirurgische manipulatie van de uterus. Wanneer in 2012 de hemostatische reactie werd vergeleken tussen ovariëctomie en ovariohysterectomie, met als hypothese dat bij de eerste minder reactie zou worden gezien door minder trauma, werden de onderzoekers teleurgesteld omdat bij beide groepen een aanzienlijk hemostatische en fibrinolytische activatie werd gevonden.[27] Een studie in 2013 keek naar de chirurgische duur van beide ingrepen in een diergeneeskundig academisch ziekenhuis bij een grote groep honden (n = 108).[28] Maar aangezien er geen duidelijke richtlijnen met betrekking tot de incisieplaats waren, en de eigenlijke operatie door onervaren chirurgen werd uitgevoerd, resulteerde dit in een relatief grote incisielengte (een gemiddelde lengte van 9,2 cm voor honden met een gemiddeld gewicht van 16,5 kg) en een in verhouding weinig realistische operatieduur (gemiddeld 90,3 minuten). De auteurs van deze studie steunden in hun conclusie het uitvoeren van ovariëctomie als een aanvaardbaar alternatief voor ovariohysterectomie. De eerste prospectieve studie die eindelijk bevestigde wat reeds lang werd verwacht, en die een duidelijk statistisch significant voordeel voor ovariëctomie terugvond, werd gepubliceerd in Korea in 2013.[29] Deze auteurs vergeleken 6 ovariëctomie honden met 7 ovariohysterectomie honden en keken naar postoperatieve pijn scores, plasma glucose, creatinine kinase, cortisol, chirurgische tijd, de duur van de anesthesie en de incisie lengte. De auteurs besloten dat ovariëctomie de superieure keuze was omwille van de kortere

incisie lengte, de kortere chirurgische tijd, de kortere duur van de anesthesie, samen met lagere pijn- en chirurgische stress respons in vergelijking met ovariohysterectomie.

Het gebruik van spierverslappers tijdens laparoscopie

Omdat de langdurige aanwezigheid van een pneumoperitoneum resulteert in een negatieve invloed op het cardiorespiratoire systeem, bestaat er een delicaat evenwicht tussen het bereiken van een voldoende grote ruimte om een laparoscopische ingreep veilig uit te voeren, en een pneumoperitoneum druk die laag genoeg blijft om de gezondheid van de patiënt niet in gevaar te brengen.

Vele minimaal invasieve chirurgen zoeken dan ook naar modificaties die toelaten om laparoscopische operatietechnieken uit te voeren zonder langdurig hoge pneumoperitoneum druk. Simpelweg werken met een lage druk pneumoperitoneum ligt erg voor de hand. Maar een gerandomiseerde gecontroleerde studie waarbij bij mensen cholecystectomie werd uitgevoerd met een lage druk pneumoperitoneum (7 - 10 mm Hg) versus een standaard intra-abdominale druk (12 - 14 mm Hg) stelde vast dat de operatietijden verhoogden als gevolg van de verminderde werkruimte bij lage drukken (respectievelijk 49,07 ± 5,72 minuten versus 46,43 ± 6,92 minuten).[30] En voor laparoscopische nefrectomie bij de mens uitgevoerd bij lage druk pneumoperitoneum werden zelfs meer uitgesproken verschillen gevonden (147 ± 86 minuten versus 111 ± 19 minuten; $P < .04$).[31] Wanneer werken met een lage pneumoperitoneum druk resulteert in inferieure operatie-omstandigheden dan zal dit niet alleen de operatieduur negatief beïnvloeden, maar kan dit ook leiden tot het voorkomen van meer chirurgische complicaties. Het is daarom ook niet verrassend vast te stellen dat een auteur een falingspercentage weergeeft van 40% voor humane laparoscopische cholecystectomie uitgevoerd met een intra-abdominale druk van 8 mm Hg.[32]

In **Hoofdstuk 5** wordt het effect van neuromusculaire blokkade (spierverslapping) op de beschikbare intra-abdominale werkruimte geëvalueerd, ervan uitgaande dat relaxatie van de buikspieren het mogelijk maakt om bij dezelfde intra-abdominale druk een grotere werkruimte te verkrijgen. Onze prospectieve, vergelijkende studie die werd uitgevoerd bij

honden die een laparoscopische ovariëctomie ondergingen, kon echter geen verschil in operatietijd aantonen.[33]

In de studie werd er vanuit gegaan dat een grotere intra-abdominale operatieruimte automatisch zou resulteren in een kortere operatietijd. Een alternatieve, en mogelijk meer nauwkeurige methode om een toename van de werkruimte vast te stellen, is computertomografie.[36] Dit is zelfs meer correct dan het schatten van de werkruimte op basis van het verbruikte volume CO_2 afgelezen op de insufflator, omdat computertomografie het mogelijk maakt om het werkelijke capnoperitoneum volume nauwkeurig te berekenen.[37] Het pneumoperitoneum volume bij varkens, gemeten via computertomografie steeg met 93% vanaf 5 - 10 mm Hg en met een extra 19% vanaf 10 - 15 mm Hg.[34] Wanneer Vlot en medewerkers het effect van neuromusculaire blokkade evalueerden op de werkruimte bij varkens, kon geen toename worden vastgesteld op basis van computertomografie metingen.[35] Hoewel deze studie werd uitgevoerd bij een andere diersoort, zijn varkens een goed model voor honden, omdat ze over een gelijkwaardige pneumoperitoneum drempelwaarde van 15 mm Hg beschikken, waarboven negatieve cardiorespiratoire gevolgen merkbaar worden.[34] Deze studie bij varkens, met een betere detectietechniek voor toegenomen intra-abdominaal volume, steunt dus onze eerdere bevindingen bij honden.

In de humane geneeskunde is neuromusculaire blokkade een veelgebruikt onderdeel van een gebalanceerd anesthesieprotocol voor een laparoscopische ingreep. Omdat lage druk pneumoperitoneum bij mensen wordt geassocieerd met minder postoperatieve uitstralingspijn naar de schouder, wordt neuromusculaire blokkade toegevoegd aan het narcose protocol voor lage druk pneumoperitoneum in een poging de operatieve omstandigheden te verbeteren.[36] Desondanks is er op dit ogenblik geen sterk bewijs dat matige neuromusculaire blokkade (TOF tellingen van 1 - 3) resulteert in een toename van de werkruimte wanneer de intra-abdominale druk continu wordt gehouden.[32] Lopend onderzoek is nu gericht op de potentieel gunstige effecten van diepe neuromusculaire blokken (TOF 0).[37-39] Bij dit type blokkade werd een kleine verbetering van de operatieve omstandigheden vastgesteld voor laparoscopische cholecystectomie, nefrectomie en prostatectomie.[40] Maar, zelfs wanneer diepe neuromusculaire blokkade effectief meer werkruimte kan creëren, betekent dit niet noodzakelijkerwijs dat chirurgen ook automatisch gebruik zullen maken van lagere insufflatie drukken.[32] Vandaar het huidige advies bij humane laparoscopische ingrepen

om te beginnen met matige of diepe neuromusculaire blokkade in combinatie met een lage druk pneumoperitoneum, en de intra-abdominale druk enkel te verhogen wanneer de specifieke operatie-omstandigheden dit vereisen (vereist bij 50% van de patiënten).[40]

De situatie bij honden verschilt echter grondig van de situatie bij mensen. Voor de meeste abdominale procedures bij honden wordt reeds een optimale operatieve werkruimte bereikt bij een pneumoperitoneum druk van 8 - 12 mm Hg.[41] Een druk die bij mensen als laag wordt beschouwd, en ruim onder de schadelijke cardiorespiratoire drempelwaarde bij honden (15 mm Hg). Tevens werd tot op heden niet aangetoond dat honden druk-gerelateerde uitstralingspijnen in de schouder zouden hebben.[42] Zonder een dringende behoefte om de pneumoperitoneum druk verder te verlagen, is er dan ook geen voordeel te verwachten van neuromusculaire blokkade bij honden. Verder zijn de economische gevolgen van diepe neuromusculaire blokkade (investering in monitoring en de kosten van antagonerende producten) zodanig dat, naar onze mening, neuromusculaire blokkade naar alle waarschijnlijkheid geen onderdeel zal worden van de diergeneeskundige klinische anesthesie.

Een stijgende intra-abdominale druk zal de buikwandspieren uitrekken tot hun elastische limiet is bereikt.[34] Dit resulteert in een typische druk-volume curve waar de meeste toename in werkruimte wordt bereikt bij lagere intra-abdominale druk en er nog slechts kleine verbeteringen waarneembaar zijn bij hogere intra-abdominale druk.[43] Een interessante vaststelling is, dat wanneer de intra-abdominale druk wordt verlaagd, na eerst de buikwandspieren gedurende een bepaalde tijd te hebben uitgerekt bij een hoge druk, er een grotere chirurgische werkruimte wordt gecreëerd, dan wanneer van in het begin deze lagere druk wordt gebruikt. Dit is het principe van pre-stretching. Wanneer bij varkens de buikwandspieren op deze manier eerst werden uitgerekt, werd bij een intra-abdominale druk van 5 mm Hg een toename van wel 21% vastgesteld, bij 10 mm Hg een toename van 7% en bij 15 mm Hg een toename van 3%.[44] Dit effect was zelfs meer uitgesproken aanwezig bij varkens met een kleiner lichaamsgewicht (6 versus 20 kg).[45] Het fenomeen van spier *pre-stretching* wordt bij honden ook vaak toegepast tijdens laparoscopische ingrepen, maar vaak zonder dat de chirurg zich hier specifiek van bewust is. Zodra het capnoperitoneum met een Veress naald wordt aangelegd, wordt de intra-abdominale druk verhoogt tot 12 mm Hg, om tijdens het inbrengen van de trocart-canule combinaties intrede complicaties te voorkomen.[42] Ook wanneer de eerste trocart-canule combinatie via de gemodificeerde Hasson techniek wordt

geplaatst, wordt tijdelijk een hogere intra-abdominale druk gebruikt bij het plaatsen van de bijkomende trocart-canule combinaties. Zodra alle canules correct in de buikwand verankerd zijn, wordt de intra-abdominale druk verlaagd tot een procedurele druk van 6 - 8 mm Hg. Hierbij wordt dus geprofiteerd van de uitgerekte buikspieren en wordt een relatief grotere werkruimte verkregen dan wanneer van in het begin met 6 - 8 mm Hg zou worden gewerkt.

Bij varkens bestaat een andere manier om de intra-abdominale werkruimte te vergroten, zonder de intra-abdominale druk te verhogen, door de darminhoud te verminderen. Zo bleek darmvoorbereiding met laxatieven te resulteren in een relatieve toename van de intra-abdominale ruimte met 43% bij 5 mm Hg, een toename van 21% bij 10 mm Hg en een toename van 18% bij 15 mm Hg.[46] Aangezien honden carnivoor zijn, in tegenstelling tot het omnivore varken, en het aandeel van het intestinaal volume in de buikholte geringer is, zal het potentiële effect van darmvoorbereiding bij honden een veel kleinere rol spelen en waarschijnlijk geen klinische toepassingen hebben.

Tijdens laparoscopische procedures dienen geneesmiddelen, die de intra-abdominale druk verhogen, te worden vermeden. Intraveneuze toediening van fentanyl bij de mens staat erom bekend dat het de intra-abdominale druk verhoogt, door het stimuleren van de actieve bijdrage van de buikspieren bij de expiratie.[47] Een onderzoek bij 16 honden kon echter geen enkel effect van fentanyl op de intra-abdominale druk tijdens een laparoscopische ingreep vaststellen.[48]

Terzijde dient hierbij opgemerkt te worden dat intra-abdominale drukmetingen op basis van de insufflator altijd met voorzichtigheid dienen te worden geïnterpreteerd. Sommige onderzoekers hebben vastgesteld dat het cyclische mechanisme van de insufflator resulteert in een variabiliteit die slecht gecorreleerd is met de werkelijke intra-abdominale druk, wanneer die gemeten wordt met een aparte intra-abdominale katheter verbonden met een druk monitor.[49]

In een poging om een positieve druk capnoperitoneum helemaal te vermijden, hebben pediatrische en geriatrische humane chirurgen onderzoek gedaan naar een hefinstrument dat de buikwand wegtrekt van de intra-abdominale organen via een trekkracht van buitenaf (Fig 12.1).[50] Hierdoor ontstaat een isobaar capnoperitoneum, in tegenstelling tot het positieve druk pneumoperitoneum gecreëerd door de laparoscopische insufflator. Ondanks de beweer-

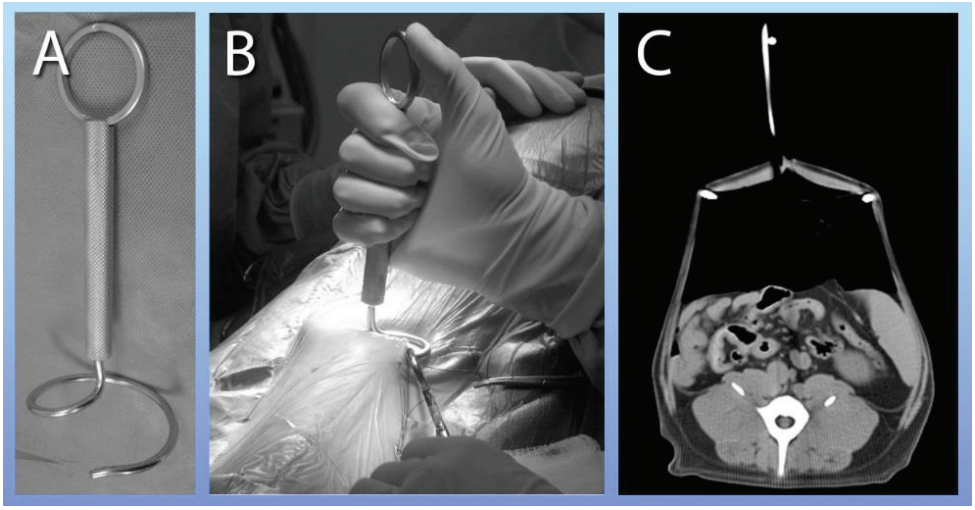

Figuur 12.1 Bij lift laparoscopie wordt een hef instrument (A) in de ventrale buikwand verankerd en opgespannen (B). Computertomografie (C) toont het isobaar pneumoperitoneum dat hierbij wordt gecreëerd (aangepast uit Fransson, Vet Surg, 2013 en Kennedy, Vet Surg, 2014).

de voordelen, kon een meta-analyse van de lift laparoscopie versus positieve druk capnoperitoneum in de humane geneeskunde geen voordeel in de richting van één van beide technieken vinden, met betrekking tot: de intra-operatieve hartfrequentie, de intra-operatieve complicaties, de duur van verblijf in het ziekenhuis, de pijn in de schouder, de pH van het bloed, het gehalte aan serum interleukine-6 (dat geacht wordt een rol te spelen bij de pathogenese van chirurgisch trauma).[51] Wel was volgens datzelfde onderzoek lift laparoscopie geassocieerd met kortere hersteltijd, lagere postoperatieve $PaCO_2$ niveaus, en geassocieerd met minder postoperatieve misselijkheid en braken, terwijl capnoperitoneum dan weer resulteerde in een kortere operatieduur. De lift laparoscopie techniek werd opgepikt in de diergeneeskunde in 2011 en reeds met succes uitgevoerd bij honden.[52] In tegenstelling tot het positieve druk capnoperitoneum had het isobaar pneumoperitoneum geen negatieve invloed op het thoracale volume.[53] Maar, uit een vergelijking van serum acute fase-eiwitten (C-reactief proteïne) en interleukine-6 bij lift laparoscopie en positieve druk capnoperitoneum laparoscopie bij honden bleken juist hogere niveaus van interleukine-6 in lift laparoscopie voor te komen.[54] In andere studies, bij gezonde honden, werd vastgesteld dat lift laparoscopie gepaard gaat met een lagere frequentie van hypercapnia, dat het minder anesthesiegas

vereist en dat lift laparoscopie niet meer tijdrovend of pijnlijk was dan positieve druk capnoperitoneum.[55]

Een mogelijke reden waarom lift laparoscopie tot op heden niet wijdverspreid geraakt, heeft ermee te maken dat de hoeveelheid werkruimte die door de lift laparoscopie benadering wordt verkregen, verschilt van de werkruimte bekomen met traditionele capnoperitoneum laparoscopie.[42] Bij een 12 mm Hg capnoperitoneum, zullen de multidirectionele centrifugale krachten op de buikwand leiden tot een toename van het abdominale volume met 80% (zowel in laterale als ventrale richting), terwijl de unidirectionele trekkrachten op de buikwand die door de lift laparoscopie worden uitgeoefend slechts resulteerden in een verhoging van het abdominale volume met 25% (enkel in ventrale richting).[53] Het is mogelijk om een groter abdominaal volume te verkrijgen door gebruik te maken van grotere trekkrachten, of wanneer een dubbel hefinstrument wordt gebruikt.[56] Lift laparoscopie in de diergeneeskunde staat nog in de kinderschoenen, met slechts een beperkt aantal publicaties en de vaststelling van een duidelijke leercurve. Verdere *evidence-based* studies gericht op een groter aantal patiënten moeten prospectief worden geëvalueerd om een eventueel voordeel van deze procedure duidelijk te maken en welbepaalde selectiecriteria te bepalen.

Hemostatische technieken tijdens ovariëctomie

Wanneer nieuwe geneesmiddelen voor menselijk gebruik op de markt worden gebracht, moeten twee afzonderlijke dubbel-geblindeerde en gerandomiseerde klinische studies worden uitgevoerd om goedkeuring te verkrijgen bij de Amerikaanse *Food and Drug Administration*.[57] Nieuwe chirurgische apparaten worden niet gehouden aan dezelfde norm, wat voor een aantal instrumenten resulteert in een gebrek aan gegevens gebaseerd op gerandomiseerde klinische studies. Bovendien beschrijven veel van de, in 2005, beschikbare studies de effectiviteit van elektrische hemostatische apparaten op vaatweefsel (slagaders en aders) geoogst uit varkens. Er waren toen nog geen *in vivo* studies gepubliceerd over de werkzaamheid en weefsel interactie op levend gevascularisseerd weefsel. Het is in deze

context dat we verschillende studies uitvoerden, in dit manuscript gebundeld, om zo de *evidence-based* kennis rond deze nieuwe en snel populair geworden elektrische hemostatische apparaten te verhogen.

Nieuwe elektrische hemostatische apparaten worden geëvalueerd op basis van vijf criteria: efficiëntie, veiligheid, betrouwbaarheid, consistentie en gebruik.[58] Wanneer een nieuw instrument efficiënter is, zal dit resulteren in een kortere operatieduur. Veiligheid omvat de aanwezigheid van minimale elektrothermische coagulatieschade. Betrouwbaarheid verwijst naar de mogelijkheid van het nieuwe instrument om hemostase te bereiken in de procedure waarvoor het werd ontworpen (grootte van het bloedvat). Consistentie betekent dat het hemostatische effect onafhankelijk is van de gebruiker. En ten slotte verwijst gebruik naar het vermogen om het nieuwe instrument meermalig te gebruiken.

In **Hoofdstuk 6** (studie uitgevoerd in 2002-2003) vergelijken we de toenmalige diergeneeskundige standaard voor hemostase tijdens laparoscopische ingrepen, de monopolaire elektrocoagulatie via een laparoscopische schaar (Endo Mini-Shears Short 5 mm; US Surgical Corporation, Norwalk, CT), met een nieuw ontwikkeld bipolair grijpinstrument (Take-Apart Bipolar Grasping forceps; Karl Storz-Endoscopy, Nederland). Het bipolaire grijpinstrument heeft een gegolfde bek zodat het contactoppervlak van het instrument met het weefsel verhoogt, waardoor de transmissie van elektrische energie tijdens het elektrocoagulatie proces verbetert.[59] Met de vijf evaluatiecriteria in gedachten werd in onze studie gekeken naar de operatietijd, het optreden van intra-operatieve bloedingen, en potentiële patiëntgebonden factoren zoals leeftijd, gewicht en obesitas, oestrus of schijndracht. Deze prospectieve klinische studie onderzocht 103 vrouwelijke honden, wat in de diergeneeskunde een behoorlijk groot aantal is voor een vergelijkende studie, en zeker een comfortabele grootte voor statistische evaluatie. Helaas kon het onderzoek niet worden gerandomiseerd, gezien het nieuw ontwikkelde hemostatische instrument niet steeds beschikbaar was. Het bipolaire grijpinstrument bleek efficiënter, gezien het vergeleken met monopolaire elektrocoagulatie de operatieduur verminderde (40.8 $\pm$ 10 minuten tegenover 52,7 $\pm$ 14 minuten; $P < .001$). Het instrument was betrouwbaar want het verminderde het optreden van intra-operatieve bloedingen van het mesovarium (7 honden of 13% in de monopolaire elektrocoagulatie groep en 4 honden of 8% in de bipolaire coagulatie groep). De aanwezigheid van obesitas en intraoperatieve mesovarial bloedingen verlengden de

operatieduur (respectievelijk 56 minuten tegenover 42 minuten; $P < .001$ en 56 minuten tegenover 46 minuten; $P = .03$). De leeftijd, de aanwezigheid van oestrus of schijnzwangerschap hadden geen significante invloed op de operatieduur.

Andere studies vergeleken hetzelfde grijpinstrument (in 2005),[60] en later een verbeterd model (in 2007),[61] met laparoscopische laser hemostase en vonden dat het bipolaire grijpinstrument gepaard ging met kortere operatieduur en het minder voorkomen van intra-operatieve bloedingen van het mesovarium. Het bipolaire grijpinstrument is bestemd voor hergebruik (is stoom autoclaveerbaar) en wordt verbonden met een standaard elektrochirurgische generator. De efficiëntie van het instrument, gekoppeld aan een lage investeringskost, maakte dit hemostatische instrument dan ook onmiddellijk populair, niet alleen in de academische wereld, maar ook in algemeen praktijken waar minimaal invasieve chirurgie werd uitgevoerd.[62] Een groot nadeel van het instrument was echter dat het niet beschikt over een snijfunctie. En dus zijn er meerdere handelingen en instrumenten nodig: elektrocoagulatie voor hemostase gevolgd door het inbrengen van een schaar om het weefsel door te knippen. Verdere technologische aanpassingen aan dit hemostatische instrument, zodat het afwisselend inbrengen van instrumenten kan worden vermeden, zou ontegensprekelijk leiden tot verdere chirurgische efficiëntie (kortere operatieduur).

Tegen 2006 verscheen in de diergeneeskunde een verbeterd bipolair elektrocoagulatie instrument dat zowel coaguleerde als sneed.[67,68] Een meta-analyse in de geneeskunde, gebaseerd op 29 prospectieve gerandomiseerde studies, vond dat dit hemostatische instrument, wanneer vergeleken met monopolaire elektrocoagulatie, de gemiddelde operatieduur verkortte met 28%.[57] In **Hoofdstuk 7** wordt de doeltreffendheid van het klassieke bipolaire grijpinstrument vergeleken met een nieuw hemostatische instrument dat gebruik maakt van *vessel sealing* (LigaSure), tijdens laparoscopische ovariëctomie van honden (studie uitgevoerd tussen 2006-2007). Het *vessel sealing* instrument heeft een glad contactoppervlak dat, in vergelijking met het gegroefde oppervlak van het bipolaire grijpinstrument, directe fysieke schade aan het weefsel voorkomt, zodat het vastkleven van het instrument aan het einde van het coagulatieproces wordt voorkomen, maar waardoor de elektrische stroom mogelijk niet optimaal door het weefsel loopt.[59]

Echter, het nieuwe elektrische hemostase apparaat was efficiënter (de operatieduur voor het losmaken van het ovarium was korter), en veiliger (dezelfde diepte van elektrothermische coagulatieschade werd teruggevonden, maar met lagere histologische schade scores). In deze studie werd ook het effect van de chirurgische ervaring geëvalueerd. Zoals verwacht, was de totale operatieduur en de operatieduur om het ovarium los te maken met het bipolaire grijpinstrument, langer voor de onervaren laparoscopische chirurg. Maar ook de tijdsduur voor het losmaken van het ovarium met het *vessel sealing* instrument, nochtans uitgerust met een generator die de gebruiker feedback bezorgt over het einde van het hemostatische proces, duurde langer voor de beginnende chirurg. De vermoedelijke reden hiervoor is dat losmaken van het ovarium uit zijn ophangbanden een specifieke driedimensionale wendbaarheid vereist: het doorsnijden van het ligamentum proprium gebeurt verticaal, waarna het mesovarium en het ligamentum suspensorium horizontaal worden doorgesneden. Voor dit soort specifieke manipulaties tijdens laparoscopische ingrepen bestaat een behoorlijke leercurve.[9,10,69] Bovendien heeft het gebruik van elk elektrisch hemostatisch apparaat ook een weliswaar beperkte eigen leercurve: de hoeveelheid weefsel die kan worden vastgegrepen en met succes gecoaguleerd zal variëren tussen verschillende types instrumenten, maar ook tussen weefseltypes. Nadelen van het *vessel sealing* instrument zijn: het instrument is ontworpen voor eenmalig gebruik, en het instrument vereist een specifieke elektrochirurgische generator (impedantie-gecontroleerd feedback softwaresysteem). De investerings- en gebruikskost weerhield *vessel sealing* instrumenten ervan om de nieuwe standaard hemostatische techniek in laparoscopische chirurgie te worden. Enkel centra specifiek toegewijd aan minimaal invasieve chirurgie (de academische wereld en chirurgische verwijspraktijken) konden zich dit instrument veroorloven.[63]

In **Hoofdstuk 8** wordt een gelijkaardige vergelijkende studie, uitgevoerd tijdens laparoscopische ovariëctomie bij honden weergegeven (studie uitgevoerd tussen 2010 - 2011). Deze keer werd het *vessel sealing* instrument vergeleken met een bipolair elektrocoagulatie instrument met ingebouwde snijfunctie (HotBlade; Patton Surgical, Austin, Tex, USA). Aangezien het bipolaire combinatie instrument (coagulatie en snijfunctie) een goedkoper alternatief biedt ten opzichte van het *vessel sealing* instrument is het belangrijk de functie van beide instrumenten in een grondig onderzoek te vergelijken. We concludeerden

dat het bipolaire combinatie instrument van groot belang is voor de economisch-ingestelde chirurg en effectief is met de nodige laparoscopische ervaring. Maar het *vessel sealing* instrument is efficiënter (kortere operatieduur), veiliger (minder thermische coagulatie schade), en betrouwbaarder (alleen intraoperatieve bloeding geassocieerd met het bipolaire combinatie instrument).

Dezelfde bevindingen werden teruggevonden in een latere studie waar de haalbaarheid van laparoscopische ovariëctomie werd geëvalueerd, gebruikmakend van slechts één canule en een operatieve laparoscoop (een 10 mm endoscoop met een 5 mm werkkanaal ingebouwd), twee canules en een transcutane fixatiehechting of van de conventionele drie-canule-techniek. Dupré en medewerkers (2009) gebruikten hierbij twee verschillende elektrische hemostase apparaten en concludeerde dat de operatieduur aanzienlijk werd beïnvloed door de lichamelijke conditie score, de vetscore van het mesovarium, het optreden van bloedingen van de ovariële ophangbanden, en de ervaring van de laparoscopische chirurg.[64] Zowel de operatie met slechts één canule als die met twee canules bleken minder pijnlijk te zijn in vergelijking met de standaard drie-canule-techniek.[65] Dit werk is tevens erg belangrijk te noemen aangezien het de stimulans is geweest voor de verdere ontwikkeling van de single-port-multi-toegang canules waaruit single incision laparoscopische chirurgie (SILS) is ontstaan.[66-68]

De afstanden voor thermische schade van het *vessel sealing* instrument die werden teruggevonden in beide studies varieerde behoorlijk (factor 10 verschil). Dit wordt voor een beperkt deel verklaard door de langere fixatieperiode voor de verwerking van de stalen in de tweede studie (3,5 jaar). Formalinefixatie staat erom bekend dat het weefsel doet krimpen, wat dus ook kan resulteren in een verkleinen van de zone van thermische schade.[69-71] Voorts werd de evaluatie van thermische schade uitgevoerd in twee verschillende instellingen (Histopathologisch laboratorium van de Universiteit Utrecht en dat van de Universiteit Gent). Dit kan leiden tot een andere methode om het staal te verwerken, bijvoorbeeld met betrekking tot de oriëntatie van het snijvlak ten opzichte van het *vessel seal*. Daarnaast werd met een verschillende microscoop gekeken (stereomicroscoop x30 versus zoommicroscoop x1000). En dat de evaluatie gebeurde door verschillende pathologen zou ok een deel van deze verschillen kunnen verklaren. Hoewel het absolute getal dat de diepte weergeeft van de

thermische schade bij de twee studies verschilt, is het belangrijker dat de resultaten volledig vergelijkbaar zijn wat betreft de verdeling van thermische schade per locatie en per techniek.

Thermische schade wordt bepaald door de hoogte van de temperatuur en de duur van de inwerktijd.[72] Beide worden bepaald door het specifieke elektrisch hemostatisch apparaat dat wordt gebruikt. Zo wordt, in tegenstelling tot wat intuïtief wordt verwacht, minder thermische schade vastgesteld bij het gebruik van een 10 mm LigaSure Atlas instrument vergeleken met een 5 mm LigaSure instrument, omdat: de temperatuur gemeten aan de tip van een 10 mm LigaSure Atlas instrument lager is vergeleken met het 5 mm instrument (58,4 ± 3,0 °C tegenover 86,5 ± 5,1 °C), en bovendien is de afkoeltijd ook aanzienlijk korter (6,3 ± 0,6 seconden tegenover 37,9 ± 4,8 seconden).[73] Wanneer de temperatuur aan de tip van een instrument behoorlijk oploopt, kan het verstandig zijn om tijdens het gebruik van het instrument in temperatuurgevoelige zones een korte pauze in te lassen om de temperatuur van het instrument te laten dalen. De specifieke eigenschappen met betrekking tot het afkoelen verschillen ook tussen elektrische hemostatische apparaten en hun instrumenten.[74] Het beheersen van de eigenschappen van elektrische hemostatische apparaten wordt daarom ook gezien als een fundamentele vaardigheid in het repertoire van de ervaren chirurg.[75]

De druk uitgeoefend door de scharnierende delen van de tip van de 10 mm LigaSure Atlas is 0,72 N/mm^2.[76] Omdat het HotBlade instrument geen scharnierende tip heeft en de samendrukkende krachten ontstaan door een veermechanisme, is de druk aan het uiteinde van het instrument veel lager. Dit gebrek aan grip resulteert er vaak in dat het vastgegrepen weefsel simpelweg uit de tip van het instrument glijdt wanneer het mes wordt geactiveerd. Dit gebeurt in het bijzonder wanneer relatief veel weefsel wordt vastgegrepen. Hierdoor wordt een bijkomende factor toegevoegd aan de specifieke leercurve van dit instrument. Het verklaart ook deels de langere operatieduur en het waarnemen van meer thermische schade (doordat na het wegglijden het weefsel opnieuw dient te worden vastgegrepen en gecoaguleerd) in vergelijking met het *vessel sealing* instrument. Een ander nadeel van dit instrument is ook dat het is ontworpen voor eenmalig gebruik, waardoor de procedurele kost toeneemt.[76]



Figuur 12.2 **LiNa Powerblade is een all-in-one bipolair elektrocoagulatie instrument met ingebouwde snijfunctie dat beschikbaar is als een 5 mm en een 10 mm instrument voor eenmalig gebruik.**



Figuur 12.3 **RoBi plus is een autoclaveerbaar bipolair elektrocoagulatie instrument met articulerende tip en ingebouwde snijfunctie.**

Tijdens onze evaluatie van de beschikbare elektrische hemostatische apparaten bleek de snelle evolutie van de apparaten een behoorlijke uitdaging te zijn. Deze evolutie zorgde ervoor dat tegen de tijd dat er voldoende patiënten waren verzameld voor een klinische studie, er reeds een nieuwe variant van het instrument beschikbaar was.[57] Zo is het bipolaire HotBlade instrument op dit ogenblik niet meer commercieel verkrijgbaar. Maar, instrumenten zoals Lina PowerBlade (Lina Medical, Glostrup, Denemarken) die vergelijkbaar zijn, zowel wat hun bouw betreft als de gebruikte hemostatische technologie, worden nog steeds volop gebruikt in de geneeskunde (Fig 12.2).

In 2015 kwam een verbeterd bipolair elektrocoagulatie instrument op de markt genaamd Robi plus (Storz, Duitsland) (Fig 12.3). Dit instrument heeft een articulerende tip (waardoor een betere grip op het weefsel wordt verkregen) en het instrument is ontworpen voor hergebruik (autoclaveerbaar). Het bewijs van de efficiëntie van dit instrument, op basis van gerandomiseerde klinische studies, ontbreekt echter op dit ogenblik.

Vessel sealing in conventionele ovariëctomie

Nu er, dankzij de ontwikkelingen op het vlak van de minimaal invasieve chirurgie, nieuwe en verbeterde hemostatische technieken beschikbaar zijn, vroegen we ons af of het niet eens tijd werd om het conventionele ligeren van de ovariumstomp met hechtdraad tijdens conventionele ovariëctomie bij honden te heroverwegen. Andere onderzoekers hadden zich ook reeds gerealiseerd dat het gebruik van LigaSure hemostase tijdens laparoscopische ovariëctomie resulteerde in een verhoogde efficiëntie in vergelijking met de klassieke laparotomie.[77] Zonder enige twijfel is *vessel sealing* tijdens laparoscopische operaties veel sneller dan het, intra- of extracorporaal plaatsen van hechtdraad.[78] Het doel was na te gaan of dit ook geldt tijdens een middellijn celiotomie benadering met een *vessel sealing* instrument voor conventionele chirurgie.

In **Hoofdstuk 9** vergelijken we een herbruikbaar *vessel sealing* instrument voor conventionele chirurgie (LigaSure Std Reusable Instrument, Valleylab/Covidien) met hechtdraad ligatie van de ovariële ophangband tijdens conventionele middellijn celiotomie

ovariëctomie bij honden. De tijd nodig voor het losmaken van het ovarium werd verlaagd met bijna 50% (*vessel sealing* 2,22 ± 0,58 minuten tegenover hechtdraad 4,10 ± 1,13 minuten; $P < .001$). De resultaten van deze studie gaven aan dat ovariële hemostase door middel van een *vessel sealing* instrument aanzienlijk sneller was dan het plaatsen van ligaturen, en dit zonder in te boeten op veiligheid (er trad namelijk enkel bloeding op bij hechtdraad ligatie, niet bij *vessel sealing*).

Hoewel niet specifiek onderzocht in deze studie, is het mogelijk dat de afwezigheid van hechtmateriaal (wat tot een vreemd voorwerp reactie leidt) en een afname van de hoeveelheid necrotisch weefsel (het mesovarium distaal van de ligatuur noodzakelijk om afglijden van de hechting te vermijden) zou kunnen leiden tot minder postoperatieve pijn en/of adhesies. Een meta-analyse in de geneeskunde, op basis van 29 prospectieve gerandomiseerde studies, concludeerde dat *vessel sealing* niet alleen de gemiddelde operatieduur vermindert met 28%, maar ook gemiddeld zorgde voor 43 ml minder bloedverlies, minder complicaties en gemiddeld minder postoperatieve pijn.[57]

Er zijn andere *vessel sealing* instrumenten op de markt, naast het LigaSure instrument dat werd onderzocht in verschillende studies. Enseal (SurgRx, Ethicon, Cincinnati, OH) beweert een betere werkzaamheid te bieden door gebruik te maken van een temperatuurgevoelige matrix, bestaande uit nanopolaire thermostaten, ingebed in de tip van het instrument en zo de energie bepaalt die geleverd dient te worden aan de overgang elektrode-weefsel.[79] Daarnaast is de richting van de radiofrequente energie van extern naar intern in de tip van het instrument, waardoor minder warmte wordt verspreid ten opzichte van LigaSure waar de energie zich heen en weer verplaatst tussen beide tippen van het instrument.[80] Caiman (Aragon, Palo Alto, CA) heeft een gelede kop (een bijkomend scharnier in de onderste tip) en gebruikt een algoritme, gebaseerd op een pulserende golfvorm modulatie, dat erover waakt bijkomende stroom te leveren in relatie tot het ontwikkelde vermogen, de spanning en de weerstand in het instrument. Dit resulteert in de afwezigheid van weefsel carbonisatie of weefseladhesie aan het instrument. Gyrus (ACMI Corporation, Southborough, MA) is een bipolair elektrocoagulatie instrument dat plasma kinetische technologie gebruikt om een hoge stroom en zeer lage spanning te leveren aan de weefsels.[87,88] Door een reeks snelle pulsen af te vuren wordt tijdens de coagulatie zelf een afkoelfase ingebouwd waardoor er minder zijdelingse thermische schade is.[81] In diverse studies wordt de efficiëntie van Enseal en Gyrus

ten opzichte van LigaSure vergeleken en er werd geconcludeerd dat deze laatste de hoogste sealdruk haalt alvorens te barsten en tevens de snelste sealtijd.[78,85,90-94] De klinische betekenis van deze bevindingen is echter moeilijk op hun waarde in te schatten.[82] Tegenstanders hebben zelfs aangehaald dat de gemiddelde druk waaraan een seal barst niet van betekenis is om het beste instrument te bepalen, aangezien al deze drukken ver boven de normale fysiologische niveaus lagen.[83]

Doordat *vessel sealing* instrumenten gemakkelijk all-round inzetbaar zijn, is het voor de hand liggend dat ze steeds vaker worden gebruikt voor conventionele chirurgische procedures.[84] *Vessel sealing* instrumenten zijn reeds met succes gebruikt bij honden voor een partiële lever lobectomie,[85] partiële long lobectomie,[86] splenectomie,[87] partiële pancreatectomie,[88] en uterushoorn en uterus occlusie.[89] De laatste hindernis die overbleef, was dat het wegwerpinstrument resulteerde in verhoogde verbruikskosten tijdens de chirurgische ingreep. Maar ook deze hindernis werd uiteindelijk weggewerkt. BiClamp (ERBE, Tübingen, Duitsland) is een autoclaveerbaar *vessel sealing* instrument dat veelvuldig wordt gebruikt in zowel conventionele chirurgie (human thyroïdectomie),[90] als voor minimaal invasieve chirurgie.[91] Een nadeel van dit toestel is evenwel dat het niet beschikt over een ingebouwde snijfunctie. Een instrument dat zowel herbruikbaar is, als beschikt over ingebouwde snijfunctie is MarSeal (KLS Martin, Tuttlingen, Duitsland) (Fig 12.4). *In vivo* studies op arteries in schapen vonden afdichtingsdrukken terug die vergelijkbaar waren met LigaSure en afdichtingstijden die zelfs nog korter waren.[76]

De technologische vooruitgang stopte niet na de ontwikkeling van elektrothermische (bipolaire) *vessel sealing* apparaten (Tabel 12.1). Chirurgische hemostase kan nu ook worden bereikt met een mechanisch geïnduceerd thermisch coagulum.[78,108,109] Ultrasone systemen, zoals de Harmonische ACE (Ethicon Endo-chirurgie, Cincinnati, OH), of Sonosurg (Olympos) produceren hoogfrequente ultrasone golven, ongeveer 55.000 trillingen per seconde, die door wrijving hoge temperaturen genereren om zo bloedvaten af te dichten met een diameter tot 5 mm.[79,91,107,110] Met ultrasone energie bereiken de instrumenten echter erg hoge temperaturen (195,9 ± 14,5 °C), waar tijdens het gebruik bij laparoscopische ingrepen zeker de nodige aandacht aan dient te worden besteed.[73,92,98,99] Anderzijds, produceert het juiste gebruik van het instrument minder thermische schade in vergelijking met elektrothermische *vessel sealing*.[78,111] Het eerste prototype van dit instrument, Ultracision (Ethicon Endo-Surgery

Figuur 12.4 MarSeal is een autoclaveerbaar *vessel sealing* instrument met ingebouwde snijfunctie.

Tabel 12.1 Een vergelijking van de eigenschappen van vier elektrische hemostase apparaten.

	Monopolair	Bipolair	*Vessel sealing*	Ultrasoon
Methode van hemostase	coagulatie	coagulatie	vessel sealing	vessel sealing
Ingebouwde snijfunctie	nee	sommige	laparoscopische	ja
Vermogen	50 - 80 W	30 - 50 W	40-60 %	55.000 Hz
Instrument temperatuur	70 °C	62 °C	40 - 96 °C	125 - 300 °C
Weefsel temperatuur	400 °C	> 100 °C	56 - 100 °C	80 - 227 °C
Bloedvat diameter	1 - 2 mm	< 3 mm	≤ 7 mm	≤ 5 mm
Thermische schade	10 - 20 mm	2 - 6 mm	1 - 4 mm	1 - 4 mm
Afkoeltijd (tot 50 °C)	17 sec	11 sec	20 - 40 sec	27 - 45 sec

Gecombineerde informatie uit[78,79,88,90,104-107]

Inc., Cincinnati, OH) beschreef in 2003 reeds het gebruik van ultrasone energie hemostase tijdens laparoscopische ovariohysterectomie bij negen honden.[100] Recenter werd Autosonix (Covidien Surgical Inc, Sao Paulo, SP, Brazil) even efficiënt bevonden als LigaSure voor het gebruikt tijdens laparoscopische ovariohysterectomy bij honden.[63] The Sonicision Cordless



Figuur 12.5 Sonicision Cordless Ultrasonic Dissector is het eerste draadloze hemostase toestel. Het werkt op ultrasone energie geproduceerd door de generator bovenaan in het handinstrument en de accu in de handgreep.

Figuur 12.6 THUNDERBEAT is een elektrisch hemostase apparaat dat elektrothermische en ultrasone energie combineert om tot *vessel sealing* te komen.

Ultrasonic Dissector (Covidien, Elancourt, Frankrijk) bestaat uit een herbruikbare (plasma- of gassterilisatie) generator en batterij, die beide op het handinstrument worden gemonteerd voor gebruik (Fig 12.5).[96] In 2012 werd dit instrument voor de eerste keer in een humaan ziekenhuis gebruikt (voor een radicale nefrectomie en een bekken lymfadenectomie).[101]

THUNDERBEAT (Olympus Medical Systems Corp., Tokyo, Japan) is een prototype dat het beste van beide technologieën combineert: bloedvat coagulatie door middel van simultane ultrasoon-opgewekte wrijvingsenergie in combinatie met bipolaire elektrothermische energie (Fig 12.6).[102] Voorlopig onderzoek concludeerde dat deze techniek potentieel de dissectiesnelheid van ultrasone apparaten kan overtreffen terwijl het de *vessel sealing* eigenschappen van bipolaire apparaten behoudt.[115,116]

Laparoscopie in de behandeling van ovarieel restsyndroom

Chirurgische behandeling van ovarieel rest syndroom (ORS) bij honden vereist meestal een lange celiotomie incisie en aanzienlijke manipulatie van intra-abdominale organen vanwege de relatief diepe positie van het ovarieel restweefsel en de vaak aanwezige verklevingen. Een laparoscopische benadering van honden met ORS is logisch, aangezien hiermee een minimaal invasieve exploratie van het abdomen mogelijk is, en net zoals bij een electieve ovariëctomie resterend weefsel kan worden weggenomen.

In **Hoofstuk 10** wordt via een laparoscopische benadering ovarieel restweefsel verwijderd bij 32 honden met een diagnose van ORS. Verklevingen werden waargenomen bij 79% van de honden en uitgebreide adhesies bemoeilijkten de chirurgische benadering. Weefseldissectie en -excisie werden uitgevoerd met een 5 mm *vessel sealing* apparaat (LigaSure). Elektrothermische bipolaire vaatcoagulatie-apparaten werden initieel ontworpen om zo efficiënt mogelijk arteries en venen af te dichten en door te snijden.[103] Maar deze instrumenten zijn eigenlijk veel veelzijdiger aangezien het instrument kan worden gebruikt om de meeste zachte weefsels af te dichten en door te snijden. Daarnaast werd het standaard, rechte Dolphin Tip instrument succesvol toegepast voor het vrijprepareren van weefsels. Deze eigenschap werd erkend door de fabrikant, en verdere aanpassingen aan de tip van LigaSure

instrumenten hebben geresulteerd in handinstrumenten die meer toegespitst zijn op de dissectie van gevoelige weefsels, zoals de gebogen tip Maryland Jaw (Fig 12.7).[104,105] De LigaSure Advance heeft zelfs een bijkomende monopolaire extensie op de tip die het elektrisch doorsnijden van minder sterk doorbloed weefsel tijdens dissectie toelaat.[106] Beide varianten van het LigaSure handinstrument hadden de dissectie van ovarieel restweefsel in de aanwezigheid van ernstige verklevingen kunnen vergemakkelijken.

Figuur 12.7 Verschillende *vessel sealing* instrumenten voor de 5 mm LigaSure (van links naar rechts): Dolphin tip, Maryland tip, Pistol tip, en Blunt tip, vergeleken met de 10 mm LigaSure Atlas.

Zoals verwacht, resulteerde de laparoscopische benadering in een gedetailleerde inkijk op de intra-abdominale organen, wat de detectie van verdacht ovarieel restweefsel vergemakkelijkte. Daarnaast was het laparoscopisch verwijderen in 100% van de honden succesvol, met een gemiddelde operatieduur van 107 ± 33 minuten. Het bijzonder snelle herstel (gemiddelde duur 1,5 ± 0,7 dagen) zou een stimulans moeten zijn voor dierenartsen om een invasieve chirurgische procedure (conventionele celiotomie) te vervangen door deze minimaal invasieve variatie.

Eindconclusie

Het feit dat veel routinematig uitgevoerde chirurgische procedures, zoals electieve gonadectomie, zich lenen voor een minimaal invasieve benadering is een sterke drijvende kracht achter het toenemende gebruik van minimaal invasieve chirurgie in de dierenartsenpraktijk.[8] Wanneer laparoscopische ovariëctomie wordt vergeleken met conventionele ovariëctomie, dan blijkt de eerste minder invasief te zijn,[107] geassocieerd te zijn met minder postoperatieve pijn en stress,[108-111] minder aanleiding te geven tot postoperatieve adhesie vorming,[125,126] gepaard te gaan met een kortere hertelperiode[112] en een sneller ontslag uit de dierenkliniek.[18] Het is dan ook geen verrassing dat de diergeneeskundige chirurgie snel evolueert richting minimaal invasieve procedures om zo onze kleine huisdieren patiënten te laten profiteren van de vele gedocumenteerde voordelen.

Bij laparoscopische ingrepen kunnen er verschillende soorten elektrische hemostase apparaten worden gebruikt. En hoewel ze allemaal hun specifieke voor- en nadelen hebben, bleek het *vessel sealing* apparaat, gebruikt in onze studies (LigaSure), superieur te zijn aan de oudere methoden (monopolaire elektrocoagulatie) of meer economische apparaten (bipolaire all-in-one instrumenten). Innovatieve chirurgen worden uitgenodigd om deze nieuwe technologieën te omarmen. Want het is een spannend concept om onze kleine huisdieren patiënten de voordelen, die oorspronkelijk werden ontwikkeld voor gebruik bij de mens, aan te bieden. Echter, we moeten opletten niet blindelings te vertrouwen op nieuwe en onbewezen technologieën. Het is daarom belangrijk dat chirurgen op basis van *evidence based* onderzoek worden geïnformeerd over de eigenschappen en mogelijkheden van hemostatische apparaten, en hun procedurele training.[106] Of, om het met de woorden van Andrew Brill (ex-voorzitter van de Amerikaanse Vereniging van Gynaecologische Laparoscopisten) te zeggen: ‘It’s not the wand, but the magician (that makes the difference).'

Referenties

1. Strong VE, Forde KA, MacFadyen BV, Mellinger JD, Crookes PF, Sillin LF, Shadduck PP: Ethical considerations regarding the implementation of new technologies and techniques in surgery. Surg Endosc 2014;28:2272-2276.
2. Shivaprakasha K: Innovations - not crossing the red line. Indian J Med Ethics 2013;10:121-123.
3. Angelos P: Ethics and Surg Innov: Challenges to the professionalism of surgeons. Int J Surg 2013;11 Suppl 1:S2-5.
4. Wilson TG: Advancement of technology and its impact on urologists: release of the Da Vinci Xi, a new surgical robot. Eur Urol 2014;66:793-794.
5. Ng AT, Tam PC: Current status of robot-assisted surgery. Hong Kong Med J 2014;20:241-250.
6. Brody F, Richards NG: Review of robotic versus conventional laparoscopic surgery. Surg Endosc 2014;28:1413-1424.
7. Abrishami P, Boer A, Horstman K: Understanding the adoption dynamics of medical innovations: affordances of the Da Vinci robot in the netherlands. Soc Sci Med 2014;117:125-133.
8. Mayhew PD: Recent advances in soft tissue minimally invasive surgery. J Small Anim Pract 2014;55:75-83.
9. Pope JF, Knowles TG: Retrospective analysis of the learning curve associated with laparoscopic ovariectomy in dogs and associated perioperative complication rates. Vet Surg 2014;43:668-677.
10. Uson-Gargallo J, Tapia-Araya AE, Martin-Portugues IDG, Sanchez-Margallo FM: Development and evaluation of a canine laparoscopic simulator for veterinary clinical training. J Vet Med Educ 2014;41:218-224.
11. Dauster B, Steinberg AP, Vassiliou MC, Bergman S, Stanbridge DD, Feldman LS, Fried GM: Validity of the mistels simulator for laparoscopy training in urology. J Endourol 2005;19:541-545.
12. McClaran JK, Buote NJ: Complications and need for conversion to laparotomy in small animals. Vet Clin North Am Small Anim Pract 2009;39:941-951.
13. Buote NJ, Kovak-McClaran JR, Schold JD: Conversion from diagnostic laparoscopy to laparotomy: risk factors and occurrence. Vet Surg 2011;40:106-114.
14. Okkens AC, Kooistra HS, Nickel RF: Comparison of long-term effects of ovariectomy versus ovariohysterectomy in bitches. J Reprod Fertil 1997:227-231.
15. Okkens AC, Kooistra HS, Nickel RF: Comparison of long-term effects of ovariectomy versus ovariohysterectomy in bitches. Tijdschr Diergeneesk 2002;127:369-372.
16. Okkens AC, Kooistra HS, Nickel RF: Comparison of long-term effects of ovariectomy versus ovariohysterectomy in bitches. Prakt Tierarzt 2003;84:98-101.
17. Peeters ME, Kirpensteijn J: Comparison of surgical variables and short-term postoperative complications in healthy dogs undergoing ovariohysterectomy or ovariectomy. J Am Vet Med Assoc 2011;238:189-194.
18. Parkinson TJ: Progress towards less invasive Vet Surg. Vet Rec 2012;171:67-68.
19. Gower S, Mayhew P: Canine laparoscopic and laparoscopic-assisted ovariohysterectomy and ovariectomy. Compend Cont Educ Vet 2008;30:430-440.
20. Devitt CM, Cox RE, Hailey JJ: Duration, complications, stress, and pain of open ovariohysterectomy versus a simple method of laparoscopic-assisted ovariohysterectomy in dogs. J Am Vet Med Assoc 2005;227:921-927.

21. Case JB, Boscan PL, Monnet EL, Niyom SR, Imhoff DJ, Wallace ML, Smeak DD: Comparison of surgical variables and pain in cats undergoing ovariohysterectomy, laparoscopic-assisted ovariohysterectomy, and laparoscopic ovariectomy. J Am Anim Hosp Assoc 2015;51:1-7.
22. Perissat J: Laparoscopic cholecystectomy - the European experience. Am J Surg 1993;165:444-449.
23. Barkun JS, Barkun AN, Sampalis JS, Fried G, Taylor B, Wexler MJ, Goresky CA, Meakins JL: Randomized controlled trial of laparoscopic versus mini-cholecystectomy. Lancet 1992;340:1116-1119.
24. Barkun AN, Barkun JS, Sampalis JS, Fried GM, Meakins JL, Goresky CA: A randomized clinical-trial comparing gallbladder stone shock-wave lithotripsy to laparoscopic cholecystectomy. Gastroenterology 1993;104:A2-A2.
25. Barkun JS, Barkun AN, Meakins JL, Bailar J, Battista RN, Brassard R, Bret PM, Fried G, Garzon J, Hinchey EJ, Joseph L, Mamazza J, Sigman H, Stein L, Sampalis J, Szego PL, Taylor B, Wexler MJ: Laparoscopic versus open cholecystectomy - the Canadian experience. Am J Surg 1993;165:455-458.
26. Barkun AN, Barkun JS, Sampalis JS, Caro J, Fried GM, Meakins JL, Joseph L, Goresky CA, McGill Gallstone Treatment Group: Costs and effectiveness of extracorporeal gallbladder stone shock wave lithotripsy versus laparoscopic cholecystectomy - a randomized clinical trial. Int J Technol Assess Health Care 1997;13:589-601.
27. Spaner SJ, Warnock GL: A brief history of endoscopy, laparoscopy, and laparoscopic surgery. J Laparoendosc Adv Surg Tech A 1997;7:369-373.
28. DeTora M, McCarthy R: Ovariohysterectomy versus ovariectomy for elective sterilization of female dogs and cats: is removal of the uterus necessary? J Am Vet Med Assoc 2011;239:1409-1412.
29. Moldal ER, Kristensen AT, Peeters ME, Nodtvedt A, Kirpensteijn J: Hemostatic response to surgical neutering via ovariectomy and ovariohysterectomy in dogs. Am J Vet Res2012;73:1469-1476.
30. Harris KP, Adams VJ, Fordyce P, Ladlow J: Comparison of surgical duration of canine ovariectomy and ovariohysterectomy in a veterinary teaching hospital. J Small Anim Pract 2013;54:579-583.
31. Lee S-S: Comparison of ovariectomy and ovariohysterectomy in terms of postoperative pain behavior and surgical stress in dogs. J Vet Clinics 2013;30:166-171.
32. Kanwer DB, Kaman L, Nedounsejiane M, Medhi B, Verma GR, Bala I: Comparative study of low-pressure versus standard-pressure pneumoperitoneum in laparoscopic cholecystectomy - a randomised controlled trial. Trop Gastroenterol 2009;30:171-174.
33. Warle MC, Berkers AW, Langenhuijsen JF, van der Jagt MF, Dooper PM, Kloke HJ, Pilzecker D, Renes SH, Wever KE, Hoitsma AJ, van der Vliet JA, D'Ancona FCH: Low-pressure pneumoperitoneum during laparoscopic donor nephrectomy to optimize live donors' comfort. Clin Transplant 2013;27:E478-E483.
34. Kopman AF, Naguib M: Laparoscopic surgery and muscle relaxants: is deep block helpful? Anesth Analg 2015;120:51-58.
35. Van Goethem B, van Nimwegen SA, Akkerdaas I, Murrell JC, Kirpensteijn J: The effect of neuromuscular blockade on canine laparoscopic ovariectomy: a double-blinded, prospective clinical trial. Vet Surg 2012;41:374-380.

36. Elliott RC, Kirberger RM: Computed tomography determined changes in position of the urogenital system after CO_2 insufflation to determine optimal positioning for abdominal laparoscopy. Vet Surg 2015;44:91-99.
37. Elliott RC, Kirberger RM, Joubert KE: Computed tomography determined changes in position of the hepatobiliary and gastrointestinal systems after CO_2 insufflation to determine optimal positioning for abdominal laparoscopy. Vet Surg 2015;44:100-112.
38. Vlot J, Wijnen R, Stolker RJ, Bax K: Optimizing working space in porcine laparoscopy: CT measurement of the effects of intra-abdominal pressure. Surg Endosc 2013;27:1668-1673.
39. Vlot J, Specht PA, Wijnen RMH, van Rosmalen J, Mik EG, Bax KMA: Optimizing working space in laparoscopy: CT-measurement of the effect of neuromuscular blockade and its reversal in a porcine model. Surg Endosc 2015;29:2210-2216.
40. Hua J, Gong J, Yao L, Zhou B, Song ZS: Low-pressure versus standard-pressure pneumoperitoneum for laparoscopic cholecystectomy: a systematic review and meta-analysis. Am J Surg 2014;208:143-150.
41. Van Wijk RM, Watts RW, Ledowski T, Trochsler M, Moran JL, Arenas GWN: Deep neuromuscular block reduces intra-abdominal pressure requirements during laparoscopic cholecystectomy: A prospective observational study. Acta Anaesthesiol Scand 2015;59:434-440.
42. Madsen MV, Gatke MR, Springborg HH, Rosenberg J, Lund J, Istre O: Optimising abdominal space with deep neuromuscular blockade in gynaecologic laparoscopy - a randomised, blinded crossover study. Acta Anaesthesiol Scand 2015;59:441-447.
43. Staehr-Rye AK, Rasmussen LS, Rosenberg J, Juul P, Lindekaer AL, Riber C, Gatke MR: Surgical space conditions during low-pressure laparoscopic cholecystectomy with deep versus moderate neuromuscular blockade: a randomized clinical study. Anesth Analg 2014;119:1084-1092.
44. Madsen MV, Staehr-Rye AK, Gatke MR, Claudius C: Neuromuscular blockade for optimising surgical conditions during abdominal and gynaecological surgery: a systematic review. Acta Anaesthesiol Scand 2015;59:1-16.
45. Milovancev M, Townsend KL: Current concepts in minimally invasive surgery of the abdomen. Vet Clin North Am Small Anim Pract 2015;45:507-+.
46. Mayhew PD: Complications of minimally invasive surgery in companion animals. Vet Clin North Am Small Anim Pract 2011;41:1007-21.
47. Mayhew PD, Pascoe PJ, Kass PH, Shilo-Benjamini Y: Effects of pneumoperitoneum induced at various pressures on cardiorespiratory function and working space during laparoscopy in cats. Am J Vet Res 2013;74:1340-1346.
48. Vlot J, Wijnen R, Stolker RJ, Bax K: Optimizing working space in laparoscopy: CT measurement of the effect of pre-stretching of the abdominal wall in a porcine model. Surg Endosc 2014;28:841-846.
49. Vlot J, Staals LME, Wijnen RMH, Stolker RJ, Bax KMA: Optimizing working space in laparoscopy: CT measurement of the influence of small body size in a porcine model. J Pediatr Surg 2015;50:465-471.
50. Vlot J, Slieker JC, Wijnen R, Lange JF, Bax KMA: Optimizing working-space in laparoscopy: measuring the effect of mechanical bowel preparation in a porcine model. Surg Endosc 2013;27:1980-1985.
51. Drummond GB, Duncan NK: Abdominal pressure during laparoscopy: effects of fentanyl. Br J Anaesth 2002;88:384-388.

52. Dorfelt R, Ambrisko TD, Moens Y: Influence of fentanyl on intra-abdominal pressure during laparoscopy in dogs. Vet Anaesth Analg 2012;39:390-397.
53. Iorio B, de Barros RF, Miranda ML, de Oliveira AG, Bustorff-Silva JM: Evaluation of a simple valve mechanism used to stabilize intra-abdominal pressure during surgically induced pneumoperitoneum in small animals. Surg Endosc 2012;26:528-532.
54. Bossotti M, Bona A, Borroni R, Mattio R, Coda A, Ferri F, Martino F, Dellepiane M: Gasless laparoscopic-assisted ileostomy or colostomy closure using an abdominal wall-lifting device. Surg Endosc-Ultras 2001;15:597-599.
55. Ren H, Tong Y, Ding XB, Wang X, Jin SQ, Niu XY, Zhao X, Li Q: Abdominal wall-lifting versus CO_2 pneumoperitoneum in laparoscopy: a review and meta-analysis. Int J Clin Exp Med 2014;7:1558-1568.
56. Fransson BA, Ragle CA: Lift laparoscopy in dogs and cats: 12 cases (2008-2009). J Am Vet Med Assoc 2011;239:1574-1579.
57. Watkins C, Fransson BA, Ragle CA, Mattoon J, Gay JM: Comparison of thoracic and abdominal cavity volumes during abdominal CO_2 insufflation and abdominal wall lift. Vet Surg 2013;42:607-612.
58. Zhang JT, Shao JT, Liu YF, Wang HB: Gasless laparoscopic ovariohysterectomy and comparison of serum levels of interleukin-6 and C-reactive protein after LOHE and traditional laparoscopic ovariohysterectomy in bitches. Bull Vet Inst Pulawy 2013;57:127-130.
59. Fransson BA, Grubb TL, Perez TE, Flores K, Gay JM: Cardiorespiratory changes and pain response of lift laparoscopy compared to capnoperitoneum laparoscopy in dogs. Vet Surg 2015;44:7-14.
60. Kennedy KC, Fransson BA, Gay JM, Roberts GD: Comparison of pneumoperitoneum volumes in lift laparoscopy with variable lift locations and tensile forces. Vet Surg 2015;44:83-90.
61. Macario A, Dexter F, Sypal J, Cosgriff N, Heniford BT: Operative time and other outcomes of the electrothermal bipolar vessel sealing system (LigaSure) versus other methods for surgical hemostasis: a meta-analysis. Surg Innov 2008;15:284-291.
62. Rasche A, Hanisch S, Eick S, Hegemann O, Kraft M: The choice of surgical techniques for dissecting tissue. An evaluation software. Biomed Tech (Berl) 2014;59:S398-S400.
63. Richter S, Kollmar O, Schilling MK, Pistorius GA, Menger MD: Efficacy and quality of vessel sealing - comparison of a reusable with a disposable device and effects of clamp surface geometry and structure. Surg Endosc 2006;20:890-894.
64. van Nimwegen SA, Van Swol CFP, Kirpensteijn J: Neodymium:Yttrium aluminum garnet surgical laser versus bipolar electrocoagulation for laparoscopic ovariectomy in dogs. Vet Surg 2005;34:353-357.
65. van Nimwegen SA, Kirpensteijn J: Comparison of Nd:YAG surgical laser and remorgida bipolar electrosurgery forceps for canine laparoscopic ovariectomy. Vet Surg 2007;36:533-540.
66. Van Goethem B, Bosch M, Stegen L: Laparoscopie in de gezelschapsdierenpraktijk. Deel 1: instrumentarium en basisprincipes. Vlaams Diergeneeskd Tijdschr 2009;78:365-371.
67. Kennedy JS, Stranahan PL, Taylor KD, Chandler JG: High-burst-strength, feedback-controlled bipolar vessel sealing. Surg Endosc-Ultras 1998;12:876-878.
68. Heniford BT, Matthews BD, Sing RF, Backus C, Pratt B, Greene FL: Initial results with an electrothermal bipolar vessel sealer. Surg Endosc-Ultras 2001;15:799-801.

69. Runge JJ, Boston RC, Ross SB, Brown DC: Evaluation of the learning curve for a board-certified veterinary surgeon performing laparoendoscopic single-site ovariectomy in dogs. J Am Vet Med Assoc 2014;245:828-835.
70. Guizzo N, Feranti JPS, Bairros MC, Bortoluzzi M, Motta AC, Sartori LW, Santos FR, Tomazzoni FV, Brambatti G, Guedes RL, Silva MAM, Brun MV: Ultrasonic shears and bipolar vessel-sealing system for three-port laparoscopic ovariohysterectomy in dogs. Arq Bras Med Vet Zootec 2015;67:55-61.
71. Dupre G, Fiorbianco V, Skalicky M, Gultiken N, Ay SS, Findik M: Laparoscopic ovariectomy in dogs: comparison between single portal and two-portal access. Vet Surg 2009;38:818-824.
72. Case JB, Marvel SJ, Boscan P, Monnet EL: Surgical time and severity of postoperative pain in dogs undergoing laparoscopic ovariectomy with one, two, or three instrument cannulas. J Am Vet Med Assoc 2011;239:203-208.
73. Runge JJ, Curcillo PG, King SA, Podolsky ER, Holt DE, Davidson J, Agnello KA: Initial application of reduced port surgery using the single port access technique for laparoscopic canine ovariectomy. Vet Surg 2012;41:803-806.
74. Runge JJ, Mayhew PD: Evaluation of single port access gastropexy and ovariectomy using articulating instruments and angled telescopes in dogs. Vet Surg 2013;42:807-813.
75. Clarke BS, Banks TA, Findji L: Quantification of tissue shrinkage in canine small intestinal specimens after resection and fixation. Can J Vet Res 2014;78:46-49.
76. Reimer SB, Seguin B, DeCock HE, Walsh PJ, Kass PH: Evaluation of the effect of routine histologic processing on the size of skin samples obtained from dogs. Am J Vet Res 2005;66:500-505.
77. Johnson RE, Sigman JD, Funk GF, Robinson RA, Hoffman HT: Quantification of surgical margin shrinkage in the oral cavity. Head Neck 1997;19:281-286.
78. Phillips CK, Hruby GW, Duvak E, Lehman DS, Humphrey PA, Mansukhani MM, Landman J: Tissue response to surgical energy devices. Urology 2008;71:744-748.
79. Eto K, Omura N, Haruki K, Uno Y, Ohkuma M, Nakajima S, Anan T, Kosuge M, Fujita T, Yanaga K: A comparison of laparoscopic energy devices on charges in thermal power after application to porcine mesentery. Surg Laparosc Endosc Percutan Tech 2015;25:E37-E41.
80. Campbell PA, Cresswell AB, Frank TG, Cuschieri A: Real-time thermography during energized vessel sealing and dissection. Surg Endosc 2003;17:1640-1645.
81. Massarweh NN, Cosgriff N, Slakey DP: Electrosurgery: History, principles, and current and future uses. J Am Coll Surgeons 2006;202:520-530.
82. Klar M, Haberstroh J, Timme S, Fritzsch G, Gitsch G, Denschlag D: Comparison of a reusable with a disposable vessel-sealing device in a sheep model: efficacy and costs. Fertil Steril 2011;95:795-798.
83. Wenkel R, Ziemann U, Thielebein J, Prange H: Laparoskopische Kastration der Hündin: Darstellung neuer verfahren zur Minimal Invasieven Ovariohysterektomie. Tierarztl Prax 2005;33:177-188.
84. Mayhew PD, Brown DC: Comparison of three techniques for ovarian pedicle hemostasis during laparoscopic-assisted ovariohysterectomy. Vet Surg 2007;36:541-547.
85. Smaldone MC, Gibbons EP, Jackman SV: Laparoscopic nephrectomy using the enseal tissue seating and hemostasis system: successful therapeutic application of nanotechnology. JSLS 2008;12:213-216.

86. Sahin DA, Kusaslan R, Sahin O, Akbulut G, Bas O, Dilek ON: Histopathological effects of bipolar vessel sealing devices on liver parenchyma and comparison with suture method: an experimental study. Eur Surg Res 2007;39:111-117.
87. Kim FJ, Chammas MF, Gewehr E, Morihisa M, Caldas F, Hayacibara E, Baptistussi M, Meyer F, Martins AC: Temperature safety profile of laparoscopic devices: Harmonic ACE (ACE), LigaSure V (LV), and Plasma Trisector (PT). Surg Endosc 2008;22:1464-1469.
88. Lamberton GR, Hsi RS, Jin DH, Lindler TU, Jellison FC, Baldwin DD: Prospective comparison of four laparoscopic vessel ligation devices. J Endourol 2008;22:2307-2312.
89. Dubiel B, Shires PK, Korvick D, Chekan EG: Electromagnetic energy sources in surgery. Vet Surg 2010;39:909-924.
90. Van Goethem B, Schoemaker N, Ensink J: Electro-, cryo-, laser and endoscopic surgery, in Kirpensteijn J, Klein WR (eds): The cutting edge (2nd ed), London, UK, Roman House Publishers, 2012, pp 46-53.
91. Tsirline VB, Lau KN, Swan RZ, Montero PN, Sindram D, Martinie JB, Iannitti DA: Evaluation of an innovative, cordless ultrasonic dissector. Surg Innov 2013;20:524-529.
92. Kim FJ, Sehrt D, da Silva RD, Gustafson D, Nogueira L, Molina WR: Evaluation of emissivity and temperature profile of laparoscopic ultrasonic devices (blades and passive jaws). Surg Endosc 2015;29:1179-1184.
93. Gozen AS, Teber D, Rassweiler JJ: Principles and initial experience of a new device for dissection and hemostasis. Minim Invasive Ther Allied Technol 2007;16:58-65.
94. Santa-Cruz RW, Auge BK, Lallas CD, Preminger GM, Polascik TJ: Use of bipolar laparoscopic forceps to occlude and transect the retroperitoneal vasculature: a porcine model. J Endourol 2003;17:181-185.
95. Box GN, Lee HJ, Abraham JB, Deane LA, Elchico ER, Abdelshehid CA, Alipanah R, Taylor MB, Andrade L, Edwards RA, Borin JF, McDougall EM, Clayman RV: Comparative study of in vivo lymphatic sealing capability of the porcine thoracic duct using laparoscopic dissection devices. J Urology 2009;181:387-391.
96. Carbonell AM, Joels CS, Kercher KW, Matthews BD, Sing RF, Heniford BT: A comparison of laparoscopic bipolar vessel sealing devices in the hemostasis of small-, medium-, and large-sized arteries. J Laparoendosc Adv S-Part A 2003;13:377-380.
97. Diamantis T, Kontos M, Arvelakis A, Syroukis S, Koronarchis D, Papalois A, Agapitos E, Bastounis E, Lazaris AC: Comparison of monopolar electrocoagulation, bipolar electrocoagulation, ultracision, and LigaSure. Surg Today 2006;36:908-913.
98. Diamantis T, Gialikaris S, Kontos M, Gakiopoulou C, Felekouras E, Papalois A, Agrogiannis G, Patsouris E, Bastounis E: Comparison of safety and efficacy of ultrasonic and bipolar thermal energy - an experimental study. Surg Laparosc Endosc Percutan Tech 2008;18:384-390.
99. Person B, Vivas DA, Ruiz D, Talcott M, Coad JE, Wexner SD: Comparison of four energy-based vascular sealing and cutting instruments: a porcine model. Surg Endosc 2008;22:534-538.
100. Matz BM, Tillson DM, Boothe HW, Dillon RA, Cattley RC: Effect of vascular seal configuration using the LigaSure on arterial challenge pressure, time for seal creation, and histologic features. Vet Surg 2014;43:761-764.
101. Risselada M, Ellison GW, Bacon NJ, Polyak MMR, van Gilder J, Kirkby K, Kim SE: Comparison of 5 surgical techniques for partial liver lobectomy in the dog for intraoperative blood loss and surgical time. Vet Surg 2010;39:856-862.

102. Mayhew PD, Culp WTN, Pascoe PJ, Arzi NV: Use of the LigaSure vessel-sealing device for thoracoscopic peripheral lung biopsy in healthy dogs. Vet Surg 2012;41:523-528.
103. Monarski CJ, Jaffe MH, Kass PH: Decreased surgical time with a vessel sealing device versus a surgical stapler in performance of canine splenectomy. J Am Anim Hosp Assoc 2014;50:42-45.
104. Wouters EGH, Buishand FO, Kik M, Kirpensteijn J: Use of a bipolar vessel-sealing device in resection of canine insulinoma. J Small Anim Pract 2011;52:139-145.
105. Barrera JS, Monnet E: Effectiveness of a bipolar vessel sealant device for sealing uterine horns and bodies from dogs. Am J Vet Res 2012;73:302-305.
106. Pniak T, Formanek M, Matousek P, Zelenik K, Kominek P: Bipolar thermofusion BiClamp 150 in thyroidectomy: a review of 1156 operations. Biomed Res Int 2014;2014:1-4.
107. Uchiyama H, Itoh S, Higashi T, Korenaga D, Takenaka K: Pure laparoscopic partial hepatectomy using a newly developed vessel sealing device, BiClamp. Surg Laparosc Endosc Percutan Tech 2013;23:E116-E118.
108. Bubenik LJ, Hosgood G, Vasanjee SC: Bursting tension of medium and large canine arteries sealed with ultrasonic energy or suture ligation. Vet Surg 2005;34:289-293.
109. Harold KL, Pollinger H, Matthews BD, Kercher KW, Sing RF, Heniford BT: Comparison of ultrasonic energy, bipolar thermal energy, and vascular clips for the hemostasis of small-, medium-, and large-sized arteries. Surg Endosc 2003;17:1228-1230.
110. Matthews BD, Pratt BL, Backus CL, Kercher KW, Mostafa G, Lentzner A, Lipford EH, Sing RF, Heniford BT: Effectiveness of the ultrasonic coagulating shears, LigaSure vessel sealer, and surgical clip application in biliary surgery: a comparative analysis. Am Surg 2001;67:901-906.
111. Landman J, Kerbl K, Rehman J, Andreoni C, Humphrey PA, Collyer W, Olweny E, Sundaram C, Clayman RV: Evaluation of a vessel sealing system, bipolar electrosurgery, harmonic scalpel, titanium clips, endoscopic gastrointestinal anastomosis vascular staples and sutures for arterial and venous ligation in a porcine model. J Urology 2003;169:697-700.
112. Austin B, Lanz OI, Hamilton SM, Broadstone RV, Martin RA: Laparoscopic ovariohysterectomy in nine dogs. J Am Anim Hosp Assoc 2003;39:391-396.
113. Kim FJ, Sehrt D, Molina WR, Pompeo A: Clinical use of a cordless laparoscopic ultrasonic device. JSLS 2014;18:5.
114. Milsom J, Trencheva K, Monette S, Pavoor R, Shukla P, Ma JJ, Sonoda T: Evaluation of the safety, efficacy, and versatility of a new surgical energy device (THUNDERBEAT) in comparison with harmonic ACE, LigaSure V, and Enseal devices in a porcine model. J Laparoendosc Adv S 2012;22:378-386.
115. Seehofer D, Mogl M, Boas-Knoop S, Unger J, Schirmeier A, Chopra S, Eurich D: Safety and efficacy of new integrated bipolar and ultrasonic scissors compared to conventional laparoscopic 5-mm sealing and cutting instruments. Surg Endosc 2012;26:2541-2549.
116. Tanaka R, Gitelis M, Meiselman D, Abar B, Zapf M, Carbray J, Vigneswaran Y, Zhao JC, Ujiki M: Evaluation of vessel sealing performance among ultrasonic devices in a porcine model. Surg Innov 2015;22:338-343.
117. Petrucci F, Antoniazzi G, Valerio S: Use of the LigaSure Maryland Jaw in radical prostatectomy: our experience. Anticancer Research 2015;35:3637-3638.
118. Zaidi N, Glover AR, Sidhu SB: The Covidien LigaSure Maryland Jaw device. Expert Rev Med Devices 2015;12:151-155.

119. Peycke LE: Facilitation of soft tissue surgery surgical staplers and vessel sealing devices. Vet Clin North Am Small Anim Pract 2015;45:451-461.
120. Hoglund OV, Olsson K, Hagman R, Ohlund M, Olsson U, Lagerstedt AS: Comparison of haemodynamic changes during two surgical methods for neutering female dogs. Res Vet Sci 2011;91:159-163.
121. Davidson EB, Moll HD, Payton ME: Comparison of laparoscopic ovariohysterectomy and ovariohysterectomy in dogs. Vet Surg 2004;33:62-69.
122. Hancock RB, Lanz OI, Waldron DR, Duncan RB, Broadstone RV, Hendrix PK: Comparison of postoperative pain after ovariohysterectomy by Harmonic Scalpel-assisted laparoscopy compared to median celiotomy and ligation in dogs. Vet Surg 2005;34:273-282.
123. Marcovich R, Williams AL, Seifman BD, Wolf JS: A canine model to assess the biochemical stress response to laparoscopic and open surgery. J Endourol 2001;15:1005-1008.
124. Lee JY, Kim MC: Comparison of oxidative stress status in dogs undergoing laparoscopic and open ovariectomy. J Vet Med Sci 2014;76:273-276.
125. Schippers E, Tittel A, Ottinger A, Schumpelick V: Laparoscopy versus laparotomy: Comparison of adhesion-formation after bowel resection in a canine model. Dig Surg 1998;15:145-147.
126. Gamal EM, Metzger P, Szabo GY, Brath E, Peto K, Olah A, Kiss J, Furka I, Miko I: The influence of intraoperative complications on adhesion formation during laparoscopic and conventional cholecystectomy in an animal model. Surg Endosc-Ultras 2001;15:873-877.
127. Culp WTN, Mayhew PD, Brown DC: The effect of laparoscopic versus open ovariectomy on postsurgical activity in small dogs. Vet Surg 2009;38:811-817.

13

List of publications

Peer reviewed journal publications

1. S. Bhatti, L. Van Ham, I. Putcuyps, H. De Bosschere, I. Polis, B. Van Goethem: Atlantoaxial cartilaginous exostosis causing spinal cord compression in a mature Bernese mountain dog. J Small Anim Pract 2001;42(2):79-81.

2. B. Van Goethem, K. Rosenveldt, J. Kirpensteijn: Monopolar Versus Bipolar Electrocoagulation In Canine Celioscopic Ovariectomy. A non-randomized prospective clinical tral. Vet Surg 2003;32(5):464-470.

3. Van Goethem B, Schaefers-Okkens A, Kirpensteijn J: Making A Rational Choice between Ovariectomy and Ovariohysterectomy in Canine Gonadectomy. A discussion of benefits of either technique. Vet Surg 2006;35(2):136-143.

4. Van Soom A, Van Goethem B, Rijsselaere T: Diagnosestelling van ovarieel restsyndroom bij hond en kat. Vlaams Diergeneeskd Tijdschr 2008;77(6):435-441.

5. Maes S, Van Goethem B, Saunders J, Binst D, Chiers K, Ducatelle R: Pneumomediastinum and subcutaneous emphysema in a cat associated with necrotizing bronchopneumonia caused by feline herpesvirus-1. Journal of Comparative Pathology 2009;141(4):283-283

6. Van Goethem B, Bosch M, Stegen L: Laparoscopie in de gezelschapsdierenpraktijk, Deel 1: instrumentarium en basisprincipes, Vlaams Diergeneeskd Tijdschr 2009;78:365-371.

7. Van Goethem B, Bosch M, StegenL: Laparoscopie in de gezelschapsdierenpraktijk Deel 2: bioptname en chirurgische ingrepen, Vlaams Diergeneeskd Tijdschr 2009;78:443-449.

8. Van Goethem B, Bosmans T, Chiers K: Surgical resection of a mature teratoma on the head of a young cat. J Am Anim Hosp Assoc 2010;46(2):121-126.

9. Van den Berghe F, Cornillie P, Stegen L, Van Goethem B, Simoens P: Palatoschisis in the Dog: Developmental Mechanisms and Etiology. Vlaams Diergeneeskd Tijdschr 2010;79(2):117-123.

10. Van den Bossche I, Paepe D, Saunders J, Verbrugghe A, Vandenabeele S, Van Goethem B, Daminet S: Acute pancreatitis in two dogs. Vlaams Diergeneeskd Tijdschr 2010;79(3):163-168.

11. Van Goethem B, Sansen S, Tshamala M, de Rooster H: The teratoma in companion animals. Vlaams Diergeneeskd Tijdschr 2010;79(3):227-234.

12. van der Sloot M, Stegen L, Binst D, Piron K, Haers H, Van Goethem B: Intraluminal stents for the treatment of tracheal collapse in the dog. Vlaams Diergeneeskd Tijdschr 2010;79(4):275-283.

13. Vandenabeele S, Van Goethem B, de Rooster H: Pattern alopecia due to cystic ovaries in a Flemish cattle dog. Vlaams Diergeneeskd Tijdschr 2010;79(5):389-393.

14. Rubio-Guzman A, Van Goethem B, Verhaert L: Tongue entrapment in two dogs. J Small Anim Pract 2010;51(10):558-560.

15. Ghys L, Herbelet S, Meulemans G, Van Goethem B, Bosmans T, Van Caelenberg A, Van Der Vekens E, Kalmar I, Hermans K: Hyperadrenocorticism in the ferret: an overview of the current knowledge based on two clinical cases. Vlaams Diergeneeskd Tijdschr 2011;80(2):137-146.

16. Mees G, Vangestel C, Dierckx R, Loomans S, Van Damme N, Peremans K, de Rooster H, Van Goethem B, Pauwels P, Ducatelle R, Van de Wiele C: Metabolic correlates of tumour hypoxia in malignant canine mammary carcinoma. Res Vet Sci. 2011;91(3):e125-128.

17. Guisado V, Bavegems V, Vercauteren G, Waelbers T, Pey P, Rubio-Guzman A, Van Goethem B, de Rooster H: Two cases of peritoneopericardial diaphragmatic hernia in the cat. Vlaams Diergeneeskd Tijdschr 2011;80(6):395-402.

18. Maes S, Van Goethem B, Saunders J, Binst D, Chiers K, Ducatelle R: Pneumomediastinum and subcutaneous emphysema in a cat associated with necrotizing bronchopneumonia caused by feline herpesvirus-1. The Canadian Veterinary Journal 2011;52:1119-1122.

19. Van Meervenne S, Declercq J, Van Soens I, Van Goethem B, Van Ham L: Tongue and tail necrosis in an atypical case of acute steroid responsive meningitis-arteritis in a dog. Vlaams Diergeneeskd Tijdschr 2012;81:93-97.

20. Van Goethem B, van Nimwegen S, Akkerdaas I, Murrell J, Kirpensteijn J: The effect of neuromuscular blockade on canine laparoscopic ovariectomy: A double-blinded, prospective clinical trial. Vet Surg 2012;41:374-380.

21. David S, Van Goethem B, Rubio-Guzman A, de Rooster H: Profylactische gastropexie bij de hond: een overzicht van de chirurgische technieken. Vlaams Diergeneeskd Tijdschr 2012;81:174-183.

22. Verbeke F, Binst D, Stegen L, Waelbers T, de Rooster H, Van Goethem B: Total venous inflow occlusion and pericardial auto-graft reconstruction for right atrial hemangiosarcoma resection in a dog. Canadian Veterinary Journal 2012;53(10):1114-1118.

23. Spillebeen A, Or M, Van Goethem B, de Rooster H: Negative pressure wound therapy to promote wound healing in companion animals. Vlaams Diergeneeskd Tijdschr 2013;82:191-200.

24. Kitshoff AM, Van Goethem B, Stegen L, Vandekerckhove P, de Rooster H: Laryngeal paralysis in dogs: an update on recent knowledge. Journal of the South African Veterinary Association 2013;84(1):E1-9.

25. Bosmans T, Melis S, de Rooster H, Van Goethem B, Defauw P, Van Soens I, Polis I: Anaphylaxis after intravenous administration of amoxicilline/clavulanic acid in two dogs under general anesthesia. Vlaams Diergeneeskd Tijdschr 2014;83:14-19.

26. Debever S, Van de Maele I, De Ridder M, Waelbers T, Gielen I, de Rooster H, Van Goethem B: Treatment of a large thoracic wall tumour in a dog. Vlaams Diergeneeskd Tijdschr 2014;83(2):66-72.

27. Koenraadt A, Stegen L, Bosmans T, Van Goethem B: Laparoscopic treatment of persistent inguinal haemorrhage after prescrotal orchiectomy in a dog. J Small Anim Pract 2014;55(8):427-430.

28. Rubio A, Boyen F, Tas O, Kitshoff A, Polis I, Van Goethem B, de Rooster H: Bacterial colonization of the ovarian bursa in dogs with clinically suspected pyometra and in controls. Theriogenology 2014;82(7):966-971.

29. Or M, Van Goethem B, Polis I, Spillebeen A, Vandekerckhove P, Saunders J, de Rooster H: Pedicle digital pad transfer and negative pressure wound therapy for reconstruction of the weight-bearing surface after complete digital loss in a dog. Vet Comp Orthopaed 2015;28(2):140-144.

30. Stegen L, Van Goethem B, Beerden C, Grussendorf C, de Rooster H: Use of greater omentum in the surgical treatment of a synovial cyst in a cat. Tierarztl Prax 2015;43(2):115-119.

31. Schwarzkopf I, Van Goethem B, Vandekerckhove PM, de Rooster H: Vessel sealing versus suture ligation for canine ovarian pedicle haemostasis: a randomised clinical trial. Vet Rec 2015;176(5):125-128.

32. Devriendt N, Van Goethem B, Kitshoff A, Furcas A, Van der Vekens E, de Rooster: Oropharyngeal stick injury in the dog. Vlaams Diergeneeskd Tijdschr 2015;84(3): 162-168.

33. Crha M, Van Goethem B, Dvorak M., Necois A: Emergency laparoscopic cryptorchidectomy for acute abdomen due to testicular torsion in a dog. Acta Veterinaria Brno 2015;84(2):167-171.

34. Stegen L, Van Goethem B, Beerden C, Grussendorf C, de Rooster H: Use of greater omentum in the surgical treatment of a synovial cyst in a cat. Tierarztl Prax Ausg K Kleintiere Heimtiere 2015;43(2):115-119.

35. Stegen L, Kitshoff A Van Goethem B, Vandekerckhove P, de Rooster H: Intralaryngeal thyroarythenoid lateralisation using Fast-Fix 360 study: a canine cadaveric study. Vet Rec Open 2015;2:e000125:1-4.

36. Kitshoff A, Van Goethem B, Boyen F, Tas O, Polis I, de Rooster H: Clinical parameters as predictors of bacterial isolation in the uterine content of dogs suspected of pyometra. Vlaams Diergeneeskd Tijdschr 2015;84(4):188-196.

37. Buijtels D, Van Goethem B, De Cock H, de Rooster H, Vandenabeele S: Multipele dermoïd sinuscysten op de kop van een dwergschnauzer. Vlaams Diergeneeskd Tijdschr 2015;84:326-332.

38. Geerickx L, Van der Vekens E, Van Goethem B, Saunders J: Een atypisch geval van traumatische hernia diafragmatica bij de hond. Vlaams Diergeneeskd Tijdschr 2015 in press

39. Lippens S, Van Goethem B, Gielen I, de Rooster H: Cosmetische rostrale neusreconstructie na plaveiselcelcarcinoom resectie bij twee honden. Vlaams Diergeneeskd Tijdschr 2015 in press

40. Lippens S, Furcas A, Or M, Van Goethem B, de Rooster H: Behandeling van een chronische huidwonde bij een hond via negatieve druktherapie. Vlaams Diergeneeskd Tijdschr 2015 in press

Book chapters

1. Klein WR, Tryphonidou M, Van Goethem B: Electro/cryo/laser and endoscopic surgery. In: Kirpensteijn J en Klein WR (Ed.): The Cutting Edge, Basic operating skills for the veterinary surgeon, 2nd ed, Roman House Publishers Ltd, Allowgate, United Kingdom.

2. Van Goethem B: Minimaal invasieve chirurgie: laparoscopie en thoracoscopie bij de hond en de kat. Diergeneeskundig Memorandum 2011;58(3):1-112.

3. Van Goethem B: Cesarean Section. In: Griffon D and Hamaide A (Ed.): Complications in Small Animal Surgery. Wiley-Blackwell UK p522-527. in press

4. Van Goethem B: Orchidectomy. In: Griffon D and Hamaide A (Ed.): Complications in Small Animal Surgery. Wiley-Blackwell UK p528-533. in press

5. Van Goethem B, Schoemaker N, Ensink J: Electro-, cryo-, laser and endoscopic surgery. In: Kirpensteijn J. en Klein W.R. (Ed.): The Cutting Edge, Basic operating skills for the

veterinary surgeon, 3rd ed, Roman House Publishers Ltd, Allowgate, United Kingdom in press

Posters

1. Van Goethem B, Rosenveldt K, Kirpensteijn J: Comparison of two surgical techniques in canine laparoscopic ovariectomy. Voorjaarsdagen Congress Proceedings 2001.

2. Van Goethem B, Rosenveldt K, Kirpensteijn J: Monopolar Versus Bipolar Electrocoagulation In Canine Celioscopic Ovariectomy. A non-randomized prospective clinical trial. 11th Annual ECVS Congress Proceedings 2002.

3. Rubio-Guzman A, Van Goethem B, Verhaert L: Tongue entrapment in two dogs. ECVS congress 2010 Helsinki.

4. Van Goethem B: Het plaatsen van een slokdarmsonde bij een kat. In: Multidisciplinaire aanpak van chronische nierinsufficiëntie bij de kat. Matido publishing, Everdinge, Belgium, 2011 (ISBN 9789082016208).

5. Rubio-Guzman A, Pil S, Stegen L, de Rooster H, Van Goethem B: Prevalence of malignant and non-malignant diseases in splenectomized dogs: A retrospective analysis of 105 cases (2001-2011). SEVC Conference Poster 2011.

6. Stegen L, Kreb A, Van Goethem B, Rubio-Guzman A, de Rooster H: Comparison of lateral thoracotomy and median sternotomy in dogs and cats. SEVC Conference Poster 2011.

14

Curriculum vitae

Bart Van Goethem was born on the 19th of March 1971 in Dendermonde, in the Dutch-speaking part of Belgium. He followed a classical (Latin) and later scientific secondary education. He first followed two years of Pharmaceutical Sciences at Antwerp University (Belgium) before reorienting himself to Veterinary Medicine. During his studentship he actively participated in Student Associations and held different positions (scripter, vice-president, and president). Despite his active social life, he managed to graduate with honors at Ghent University (Belgium) in 1996.

He completed an internship at Ghent University's Small Animal Clinic (1996-1997) and was later offered a part-time position as surgical assistant by Prof. J. De Schepper when the soft tissue surgeon suddenly left. This position was held for three years. To fill up his free time he obtained a small animal practice in Opwijk (Belgium). Although the successful primary care practice gave much satisfaction, a sincere passion for surgery was gradually developing. This led to the practice being sold and the position at Ghent University terminated, for new horizons were calling.

In 2000 he started an ECVS residency training at Utrecht University (the Netherlands) under the supervision of Prof. J. Kirpensteijn. After finalizing the residency in 2003, it was difficult to turn his back on a place with such a wealth of surgical knowledge (Prof. van Sluijs, Prof. H. Hazewinkel, and many others) not to forget all the friends made. But having a wife and three kids in Belgium made daily travelling to Utrecht no longer desirable. It was time to take full parenthood responsibilities and return.

Back in Belgium he associated with three referral clinics (De Bosdreef, Anubis and Vandecan) and was responsible between 2004-2005 for a nice big caseload of orthopedic referrals and some advanced soft tissue cases. In 2005 he accepted a full-time position as soft tissue surgeon at Ghent University's Small Animal Clinic by Prof. L. Van Ham and was back where he started. In 2007 he became diplomate of the European College of Veterinary Surgeons, and in 2009 he obtained the position of head of clinics of the soft tissue surgery department.

Currently he is an enthusiast propagator of minimally invasive surgery, actively participates in resident training, lectures national and international, has written journal articles and book chapters and acts as a reviewer for some national and international journals.

15

Acknowledgements

A researcher is supposed to be nothing less than omnipotent. No seriously, let me explain myself. First the researcher needs to identify a soft spot in current medical knowledge. This requires wisdom and in-depth knowledge of the literature, achieved only by years of reading journals, preferentially also on not immediately related topics or even on completely different two-legged creatures. The next step is to set up a study whose results will incontestably fill up this knowledge vacuum. This requires strategic planning, creative out-of-the-box thinking, administrative skills (for study funding, ethical committee approval, planning in surgical procedures) and people skills (amongst others to persuade owners to participate in the study). Than the researcher needs to be able to tame uncooperative animals and wield knifes and other sharp surgical instruments without harming the animals to acquire his data. Computer skills are required to enter all data, select some bizarre-named statistical tests and then determine whether the numbers the computer spits out are due to an internal malfunction or the result of the performed statistical test. Next, the researcher needs to write up the results of the study and needs to get everything published. This involves writing skills, knowledge of foreign languages, more computer skills to keep track of references, adjust pictures or make awesome graphs. Mental stability and more people skills are required to deal with the editor's and reviewers' remarks during the reviewing process. You see? Omnipotent it is.

Luckily the researcher can count on friends and colleagues to help him during his endeavor. For after all, research just like surgery is a team effort. This thesis can therefore only exist thanks to the help of many people, some of whom I insist on mentioning specifically.

Jan Willem Hesselink accepted to become promotor of this thesis without knowing me or even having met me. Without his brave decision my thesis would have died prematurely. Jan Willem, I admire your considerate people skills, and thank you for trusting in my abilities.

Jolle Kirpensteijn has been a strong driving force behind my specialist career, first as my residency supervisor and later as my PhD promotor. When I left Utrecht his relentless insistence to continue the ongoing research projects, by friendly and sometime less friendly insinuations every time we met, have proven indispensable for the final result. Thanks Jolle, I owe you a lot!

Sebastiaan van Nimwegen has collaborated on many of the studies in this thesis and guided me along the PhD path. He even managed to make me understand the statistical tests involved in our studies. An accomplishment which should not be underestimated. I am confident we will keep on nurturing this professional and social friendship on future projects.

Next there are the many co-authors of these studies, who each attributed from their personal viewpoint. Foremost I was lucky to benefit from the experiences of reproductive specialists Auke Schaefers-Okkens, Ann Van Soom, Jeffrey de Gier, and Tom Rijsselaere. Well aware of the fact that, in human medicine, minimally invasive surgery was picked up by gynecologists before surgeons did, they have wholeheartedly supported the early adoption of these techniques in the veterinary field. Allowing dogs to benefit as soon as possible from the advantages of innovative techniques. Picking on anesthetists has become second nature to many university-grounded surgeons. Nevertheless, I have utmost respect for Jo Murrell, Ies Akkerdaas, and Tim Bosmans for their knowledge, professionalism, and critical attitude whenever a surgeon wants to try out something new. Pathologists Maja Kik and Koen Chiers, not only analyzed my samples, but also gave me a cardiac workout when I found out their results on very similar studies differed by a factor x25. As I experienced first-handed during the evaluation of formalin-fixed tissue cuts, pathologists have the same problem as laparoscopic surgeons: both being limited by the two-dimensional representation of the three-dimensional reality. Diagnostic imaginers Elke Van der Vekens and Yseult Baeumlin did some groundbreaking work evaluating the abdominal wall healing of the dog ultrasonographically. Thanks for going back to the original dataset every time I thought of something else to analyze. Frank Wagner, fellow surgeon, gave me a much appreciated language lesson when he supplied me with the statistical prints for our study performed by a German company. Margot Bosch and Karin Rosenveldt, primary care veterinarians with a passion for minimally invasive surgery, thanks for your help.

Despite the annoying yearly confrontation with your own age when you see new students arriving (no, they are not getting younger), working at a university has the advantage of introducing you regularly to keen fresh minds. I am lucky to have worked with residents, from many different countries in and outside Europe, that have enriched my life on a personal and professional level and have resulted in long-lasting friendships. Ilona Schwarzkopf, amongst others I admire your capacity to face setbacks (yes, a stopwatch is more accurate than a clock with hands) and am grateful to use your results in this thesis. Ludo Stegen taught me the value of photo editing software (he developed the picture background I have been consistently using the last ten years) and also that not everyone is a morning person (aka the relativity of punctuality). Alejandro Rubio-Guzman has the typical Latin American temperament lurking beneath a surface of humor, professionalism and benevolent family man.

Hilde de Rooster and Peter Vandekerckhove, fellow surgeons, I would like to thank you for your analytical minds, in-depth knowledge and general support.

A special word of appreciation and gratitude goes out to Elien Taffin and Liesbeth Ghijs, office associates and former PhD students, for introducing me to reference tracking software. You made me see that time spend away from clinics is not necessarily lost time. Given the right environment, people can actually get all excited about the ideal graph layout and before I knew it I found myself caught up in a thrilling competition on having the highest number of references in my reference tracking software (purely by coincidence I ended at 666).

To my former and current colleagues, the residents, interns, and students I have all worked with, thanks for sharing your knowledge, your enthusiasm, your warm friendship, your company on skiing trips, your gastronomic experiences, and foremost for keeping my feet firmly on the ground.

This project is done … time for a new undertaking.