

## First confirmed case of bovine besnoitiosis in an imported bull in Belgium

### *Eerste bevestigd geval van boviene besnoitiose in België bij een ingevoerde stier*

<sup>1,2</sup>A. Vanhoudt, <sup>1</sup>B. Pardon, <sup>1</sup>P. De Schutter, <sup>3</sup>L. Bosseler, <sup>4</sup>C. Sarre, <sup>4</sup>J. Vercruyse, <sup>1</sup>P. Deprez

<sup>1</sup> Department of Internal Medicine and Clinical Biology of Large Animals, Faculty of Veterinary Medicine, Ghent University, Salisburylaan 133, B-9820 Merelbeke, Belgium

<sup>2</sup> Utrecht University, Veterinary Faculty, Department of Farm Animal Health, Yalelaan 7, NL-3584-CL Utrecht, the Netherlands

<sup>3</sup> Department of Pathology, Bacteriology and Poultry Diseases, Faculty of Veterinary Medicine, Ghent University, Salisburylaan 133, B-9820 Merelbeke, Belgium

<sup>4</sup> Department of Virology, Parasitology and Immunology, Faculty of Veterinary Medicine, Ghent University, Salisburylaan 133, B-9820 Merelbeke, Belgium

A.Vanhoudt@uu.nl

## ABSTRACT

*Besnoitia besnoiti* is a protozoan parasite known to cause important economic losses in the cattle industry in Africa, Asia and the Mediterranean area. In the last years, (re-) emergence of the parasite has been reported in France, Germany, Hungary and Italy with in some cases, establishment of an endemic infection. In this article, the first case of besnoitiosis in Belgium in a Blonde d'Aquitaine bull imported from the south of France is described. Additionally, a brief overview of the epidemiology of the disease is provided.

## SAMENVATTING

Het protozoön *Besnoitia besnoiti* is verantwoordelijk voor belangrijke economische verliezen in de rundvee-industrie in Afrika, Azië en het Middellandse Zeegebied. Tijdens de voorbije decennia zijn er verscheidene meldingen gedaan van deze ziekte in Europa. In dit artikel wordt het eerste bevestigde geval beschreven van besnoitiose in België bij een blonde d'aquitainestier geïmporteerd uit Zuid-Frankrijk. Daarnaast wordt de epidemiologie van besnoitiose beknopt toegelicht.

## INTRODUCTION

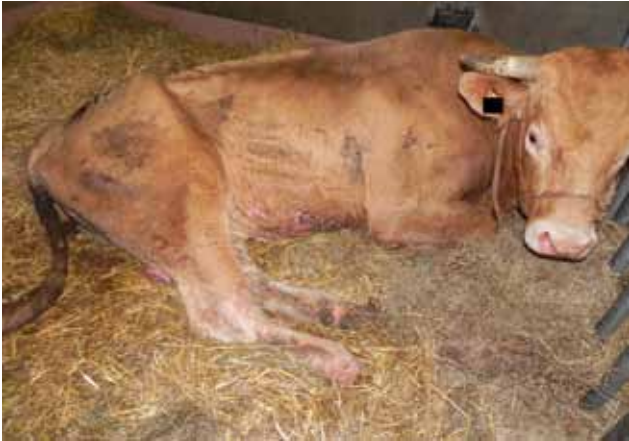The European Food Safety Agency has recently declared bovine besnoitiosis an emerging disease in Europe (Anonymous, 2010). This disease in cattle is caused by *Besnoitia besnoiti*, an obligate intracellular protozoan parasite (genus *Besnoitia*, family Sarcocystidae, phylum Apicomplexa) (Cortes et al., 2014). Sub-Saharan Africa and Asia together with the Pyrenean area of France and Spain and southern Portugal in Europe are long-time endemic regions (Irigoiien et al., 2000; Cortes et al., 2005; Jacquet et al., 2010; Olias et al., 2011). Whilst sporadic, non-endemic, imported cases of bovine besnoitiosis have been reported in France, Germany, Hungary and Italy (Mehlhorn et al., 2009; Jacquet et al., 2010; Mutinelli et al., 2011; Hornok et al., 2014), more recently, epizootic outbreaks of the disease have been reported in these countries (Jacquet et al., 2010; Rostaher et al., 2010; Gentile et al., 2012; Hornok et al., 2014). In this case

report, the first imported, non-endemic case of bovine besnoitiosis in Belgium is described.

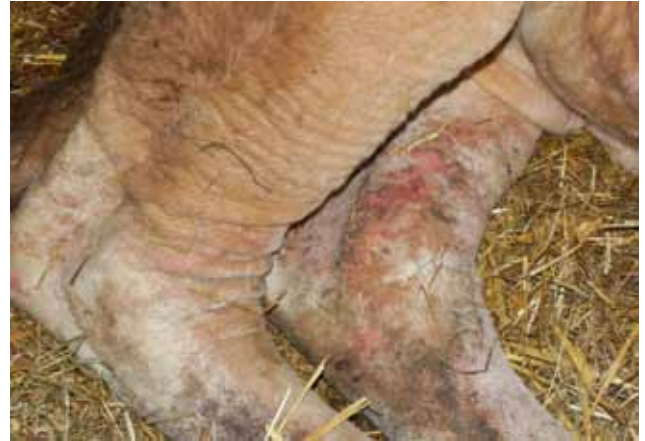## CASE DESCRIPTION

### Case history

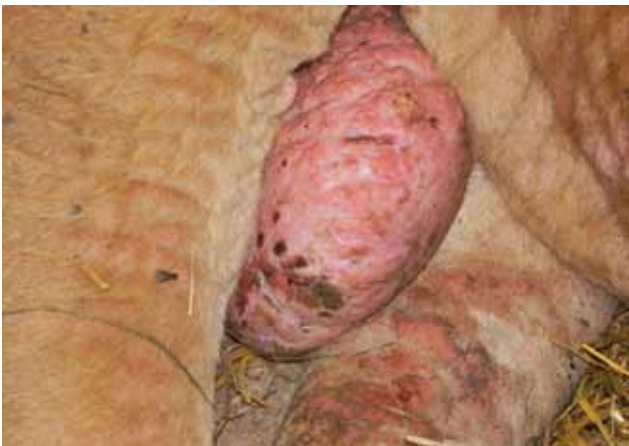On October 22<sup>nd</sup>, 2012, a six-year-old Blonde d'Aquitaine bull was presented to the Veterinary Clinic of Large Animal Internal Medicine, Faculty of Veterinary Medicine, Ghent University (Belgium) with a history of lameness, constipation followed by diarrhea, weight loss and intermittent conjunctivitis. The farm of origin was situated in the northern part of the province of West-Flanders (Belgium). On the farm of origin, the bull had been treated with moxidectin (Cydectin pour-on, Pfizer Animal Health, Belgium) and albendazole (Valbazen, Pfizer Animal Health, Belgium) and had been given a vitamin and minerals sup-



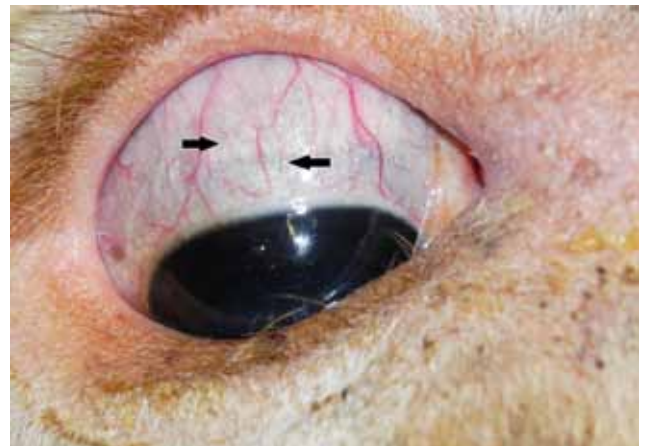
**Figure 1.** Thickening and wrinkling of the skin of the ventral abdomen and distal limbs of a six-year-old Blonde d'Aquitaine bull with bovine besnoitiosis in poor body condition.



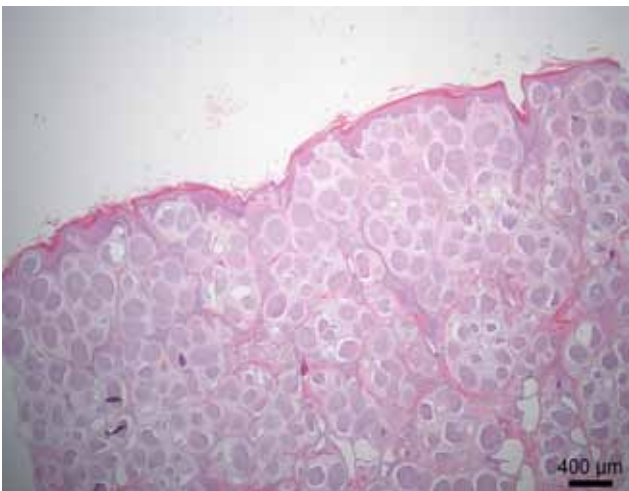
**Figure 2.** Detail of the thickening and wrinkling with patchy alopecia of the skin of the tarsal region of the hind limbs of a six-year-old Blonde d'Aquitaine bull with bovine besnoitiosis.



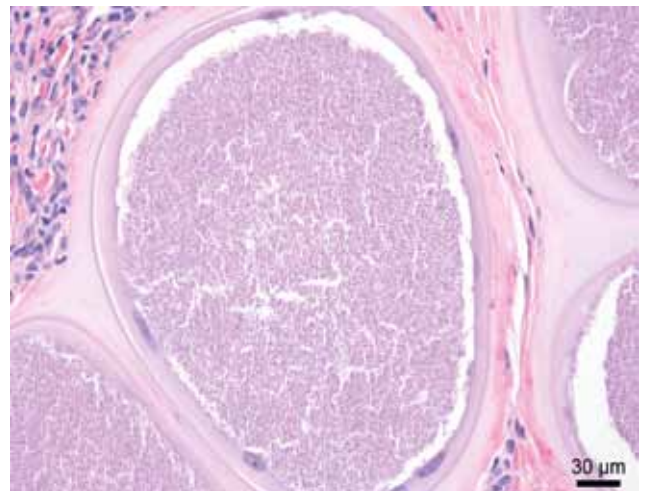
**Figure 3.** Detail of the thickening and wrinkling with patchy alopecia of the skin of the scrotum of a six-year-old Blonde d'Aquitaine bull with bovine besnoitiosis.



**Figure 4.** Detail of the pathognomonic tissue cysts (black arrows) in the scleral conjunctiva of a six-year-old Blonde d'Aquitaine bull with bovine besnoitiosis.



**Figure 5.** Skin of a six-year-old Blonde d'Aquitaine bull. A large number of tissue cysts are present in the dermis. The epidermis is diffusely hyperplastic and hyperkeratotic.



**Figure 6.** Close-up of an intracellular tissue cyst. Centrally, numerous crescent-shaped, 3-5 µm bradyzoites are seen. These are surrounded by several enlarged and peripheralized fibroblast nuclei and a thick hyaline capsule that consists of several layers.

**Table 1. Results from venous blood gas analysis and biochemistry<sup>a</sup>.**

	Result	Reference
pH	7.48	7.35 – 7.45
pCO <sub>2</sub> (mm Hg)	41.5	35.0 – 45.0
HCO <sub>3</sub> (mmol/L)	30.1	24 – 34 <sup>b</sup>
B.E. (mEq/L)	6.1	-5 to +5
HCT (%)	42	25 – 35
Serum total protein (g/L)	87	60 – 80
Total bilirubin (µmol/L)	12	2.5 – 6
Urea (mmol/L)	5.7	3 – 8
Creatinine (µmol/L)	62	88 – 172
GPT (mU/ml)	49	< 10
AST (mU/ml)	231	24 – 142
LDH (mU/ml)	5350	692 – 1450
CPK (mU/ml)	101	150 – 200
ALP (mU/ml)	76	150 – 200
γ-GT (mU/ml)	65	< 30
Na (mEq/L)	131.6	134 – 145 <sup>b</sup>
K (mEq/L)	4.95	3.9 – 5.3 <sup>b</sup>
Ca <sup>2+</sup> (mmol/L)	1.06	≥ 1.0 <sup>b</sup>
Cl (mEq/L)	97	94 – 105 <sup>b</sup>

<sup>a</sup>. Laboratory of Internal Medicine, Department of Internal Medicine and Clinical Biology of Large Animals, Faculty of Veterinary Medicine, Ghent University, Belgium.

<sup>b</sup>. Divers T.J. and Peek S.F. (2008). The clinical examination. In: Divers T.J. and Peek S.F. (editors). *Rebhun's Diseases of Dairy Cattle*. 2de Ed., Saunders Elsevier, Missouri, p. 14.

plement. The bull had been imported from the Pyrenees Mountain region in southern France on October 2<sup>nd</sup>, 2012 for fattening. On the farm in France, the bull had been used for breeding.

### Clinical examination

The bull was found to be in poor body condition (760 kg). On clinical examination, diarrhea was noted and the skin of the ventral part of the abdomen, hind legs and scrotum showed thickening, wrinkling and patchy alopecia (Figures 1, 2, 3). A close visual inspection of the eyes revealed translucent cysts of approximately 0.5 mm in diameter on the scleral conjunctiva of both eyes (Figure 4). During transport, the bull had incurred a lesion on its sacrum. Ultrasound examination of the abdomen and thorax was normal. No further abnormalities were detected.

### Blood and serological examinations

Jugular blood samples (heparin and ethylenediaminetetraacetic acid (EDTA)) were taken for blood gas analysis, standard biochemistry (Laboratory of Internal Medicine, Department of Internal Medicine and Clinical Biology of Large Animals, Faculty of Veterinary Medicine, Ghent University, Belgium) and serology for *B. besnoiti* diagnosis by western blot (Cortes et al., 2006a) (Laboratory of Parasitology, École Nationale Vétérinaire de Toulouse, France). The results of the blood gas analysis and standard biochemistry were generally indicative of mild liver damage, mild to moderate hemoconcentration, mild metabolic alkalosis and a moderate increase of muscle enzymes due

to muscle crush following recumbency (Table 1). The result of the western blot showed the typical besnoitiosis profile with three major antigenic areas of reactivity (Cortes et al., 2006a).

### Necropsy

Following the diagnosis of *B. besnoiti* by western blot serology, the bull was euthanized due to the poor prognosis in the chronic stage of the disease.

Post-mortem examination revealed a hyperkeratotic dermatitis of the scrotum, ventral abdomen and distal parts of the limbs. Furthermore, serous atrophy of the cardiac fat tissue, endocarditis of the tricuspid valve, a focal cyst in the right kidney, multifocal abscessation and interstitial emphysema of the lungs, multifocal ulcerative colitis, fasciolosis and paramphistomosis were noted. On histological examination, several tissue cysts containing numerous bradyzoites of *B. besnoiti* were found in tissue samples from the testis, planum nasale, sclera, skeletal and cardiac muscle, esophagus and skin from the scrotum, dorsal and ventral abdomen, distal limb, sternum and head (Figures 5 and 6).

## DISCUSSION

### Biological features

Bovine besnoitiosis is a disease in cattle caused by the obligate intracellular protozoan parasite *B. besnoiti* (Cortes et al., 2014). The species of the genus *Besnoitia* are closely related to *Neospora caninum* and

*Toxoplasma gondii* (Schaes et al., 2011a). The life cycle of *B. besnoiti* remains largely unknown (Olias et al., 2011; Cortes et al., 2014). In similarity to other cyst-forming coccidians, the presence of a definitive host, probably carnivore, in the close environment of cattle has been suggested for *B. besnoiti* (Tenter and Johnson, 1997). Several studies have attempted to generate *B. besnoiti* oocysts in cats. A Russian study by Peteshev et al. (1974, cited in Cortes et al., 2014) has confirmed the formation of oocysts in cats being fed with tissues from cattle supposedly infected with *B. besnoiti*. However, no other study has been able to reproduce these results (Diesing et al., 1988; Ng'ang'a and Kasigazi, 1994; Ayroud et al., 1995; Basso et al., 2011; Cortes et al., 2014). Therefore, the oral route of infection in cattle by ingestion of oocysts that have been shed by a definitive host has not yet been identified (Cortes et al., 2014). Evidence of infections in wild ruminants (caribou, impala, kudu, mule deer, musk ox, red deer, reindeer, roe deer and wildebeest) with *B. besnoiti* in South Africa (Basson et al., 1970), Canada (Gutiérrez-Expósito et al., 2012) and Spain (Gutiérrez-Expósito et al., 2013) suggest the existence of a sylvatic cycle. Consequently, infective oocysts could be produced by a definitive wildlife host (Cortes et al., 2014). Bigalke et al. (1967) however, concluded that the isolates from impala, wildebeest and cattle should be regarded as distinct strains or biologically different isolates of *B. besnoiti*. In general, the meaning of the evidence of infections with *B. besnoiti* in wild ruminants needs further investigation to explain their possible role in the transmission of bovine besnoitiosis (Cortes et al., 2014). On the other hand, it is known that blood feeding insects, horse flies and the stable fly, *Stomoxys calcitrans*, do play a role in the transmission of bovine besnoitiosis (Bigalke, 1968; Liénard et al., 2013; Cortes et al., 2014). By transmission via these vectors, *B. besnoiti* is able to bypass the sexual reproduction part of its life cycle. Other potential routes of transmission are via non-biting flies (*Musca* spp.) that have access to *B. besnoiti* in lacrimal fluid, iatrogenic transmission and direct contact of an infected animal with uninfected animals (Bigalke, 1968; Cortes et al., 2014). The role of these routes in the transmission of bovine besnoitiosis and the likelihood of occurrence under field conditions need further investigation. To date, no reports have been made of vertical transmission of bovine besnoitiosis or infections in humans with a species of the *Besnoitia* genus (Cortes et al., 2014).

### Epidemiology and clinical signs

In endemic areas, infection of a herd with *B. besnoiti* results in a subclinical seroconversion of the majority of the animals, whilst only a few develop clinical signs (Bigalke, 1968; Álvarez-García et al., 2013; Jacquiet et al., 2010). Introduction of the disease in herds in a non-endemic area on the other hand, of-

ten results in a higher number of animals developing clinical signs (Jacquiet et al., 2010; Álvarez-García et al., 2013). Infection with *B. besnoiti* can occur in animals of any age and in both sexes from all cattle breeds (Bigalke, 1968; Cortes et al., 2014). Clinical disease however, rarely occurs in calves younger than six months old (Bigalke, 1968; Cortes et al., 2014). This is likely to be a consequence of the presence of passively transferred maternal antibodies against *B. besnoiti* via the colostrum of the dams (Shkap et al., 1994). Mortality due to bovine besnoitiosis is expected to be less than 1% during the acute stage of the disease; however, this is higher in bulls, which seem to be more susceptible to clinical disease (Jacquiet et al., 2010; Álvarez-García et al., 2013). During the chronic stage of the disease, a case fatality rate of around 10% is to be expected (Pols, 1960).

An infection with bovine besnoitiosis may result in three different clinical manifestations (Jacquiet et al., 2010): an acute, febrile stage, which in general lasts between six and ten days and is characterized by typical clinical signs resulting from a generalized vasculitis and thrombosis caused by the rapid tachyzoite proliferation (Basson et al., 1970); followed by a life-long chronic, cyst-forming stage characterized by dermal lesions (Pols, 1960; Bigalke, 1968; Cortes et al., 2014) and the pathognomic thick-walled tissue cysts in the scleral conjunctiva and vaginal mucosa as the only clinical sign (Álvarez-García et al., 2013) (Figure 6); and seroconverted animals that remain asymptomatic. In general, the asymptomatic seroconverted animals form the largest proportion in the population following an infection with *B. besnoiti* (Jacquiet et al., 2010).

Clinical signs during the acute stage of the disease consist of fever (above 40°C), increased heart rate, intensive respiratory disorder, serous nasal and ocular discharge, loss of milk production, swelling of superficial lymph nodes, acute orchitis, generalized edema of the skin and sometimes anasarca, anorexia, generalized weakness and reluctance to move resulting in rapid weight loss and declining body condition (Schulz, 1960; Basson et al., 1970; Cortes et al., 2005; Jacquiet et al., 2010; Cortes et al., 2014). The formation of the pathognomic thick-walled tissue cysts in the scleral conjunctiva and vaginal mucosa starts one to two weeks after the onset of the acute stage (Basson et al., 1970; Álvarez-García et al., 2013; Cortes et al., 2014). These cysts have a high tropism for cutaneous and subcutaneous tissues and for the intermuscular fascia (Basson et al., 1970). During the chronic stage of the disease, the dermal lesions consist of a marked thickening, hardening and wrinkling of the skin due to scleroderma (Basson et al., 1970). This is predominantly seen on the skin of the neck, shoulders and rump. Hyperkeratosis, hyperpigmentation and alopecia are always present with dermal lesions (Pols, 1960).

In pregnant animals, abortion can occur in the

acute stage of the disease (Pols, 1960; Cortes et al., 2014). Cows remain fertile during the chronic stage of the disease (Cortes et al., 2014). In contrast, affected bulls often become infertile due to irreversible testicular lesions of vasculitis, focal necrosis, sclerosis and atrophy (Kumi-Diaka et al., 1981).

### Differential diagnosis and diagnosis

Based on the clinical signs, bovine besnoitiosis is often mistaken for blue tongue virus infection, malignant catarrhal fever, photosensitization or rinderpest (acute phase of bovine besnoitiosis) or dermatophytosis, fungal infection, mange or mineral deficiency (chronic phase of bovine besnoitiosis) (Jacquiet et al., 2010; Cortes et al., 2014). Therefore, clinical suspicion of an infection with *B. besnoiti* following observation of the thick-walled tissue cysts in scleral conjunctiva or vaginal mucosa or both on close visual inspection should always be confirmed using another diagnostic test. A range of direct and indirect diagnostic tests are available for the detection of bovine besnoitiosis. Which diagnostic approach should be used depends on the clinical status of the animal and the status of the herd it comes from (Cortes et al., 2014).

The detection of *B. besnoiti* DNA in a tissue sample (8 mm biopsy punch of the skin or a scrape of the vaginal mucosa) using PCR (Schaes et al., 2011b) or detection of antibodies against *B. besnoiti* using an avidity enzyme-linked immunosorbent assay (ELISA, APure-BbELISA) (Schaes et al., 2013) have been found appropriate diagnostic techniques in the acute, clinical stage of the disease.

In subclinically infected animals, detection of bovine besnoitiosis is best done using a highly sensitive method, such as PCR (Schaes et al., 2011b) or by serology. An indirect fluorescence antibody test (IFAT) (Shkap et al., 2002) is considered the gold standard for serology. Alternatively, a modified direct agglutination test developed by Waap et al. (2011) or western blotting (Schaes et al., 2010) can be used. Western blotting has been recommended as a confirmation test in combination with other methods (García-Lunar et al., 2013). When handling a larger number of samples, an ELISA, which is commercially available (PrioCHECK Besnoitia Ab, Prionics AG, Schlieren, Switzerland), is more appropriate (Schaes et al., 2011a). The diagnosis of individual cases should however be confirmed using at least one other test, IFAT or western blotting (García-Lunar et al., 2013). Care should be taken for false positive results due to cross-reactions in several tests with related apicomplexans (Nasir et al., 2012).

Chronic infections with *B. besnoiti* can be detected by histopathology of skin biopsies (8 mm biopsy punch) from sites with dermal lesions associated with bovine besnoitiosis (Cortes et al. 2006b) or the other diagnostic tests available for the acute and subclinical stage of the disease.

### Therapy

Several attempts for the treatment of bovine besnoitiosis have been made. Unfortunately, to date, none has been found to be successful. Further details on these attempts are beyond the scope of this case report. The authors refer to the review by Cortes et al. (2014) for more information.

### Control

In South Africa and Israel, live vaccines have been used in order to control bovine besnoitiosis. As live-attenuated vaccines pose the risk of introducing the parasite into uninfected areas, their use is geographically limited. The use of live-attenuated vaccines also poses the risk of creating carrier animals amongst the vaccinated animals which is of particular concern in the case of *B. besnoiti* because knowledge of the biology, transmission and life cycle is limited (Cortes et al., 2014).

In their review, Álvarez-García et al. (2013) have suggested control of bovine besnoitiosis based on management measures coupled to diagnosis. This approach has two objectives. First, to avoid entrance of the disease into a naïve herd by rigorous testing of any animal entering the herd and biosecurity measures. Secondly, to avoid spread of the disease within infected herds by gradually decreasing the prevalence in the herd. This is best done by a long-term, step-by-step, selective culling strategy based on a cost-benefit balance together with biosecurity measurements.

Results of a pilot study by Jacquiet et al. (2013) indicated that in herds with low prevalence of the disease (less than 6%), exhaustive culling of seropositive animals has proven an efficient control strategy for bovine besnoitiosis even if the prevalence is higher (between 10 and 60%) and infection is active in neighbouring herds.

This strategy of exhaustive culling was applied in this case in Belgium as the farm of origin was a fattening unit with all animals leaving the farm for slaughter. Up to date, no further reports of animals suspected of infection with *B. besnoiti* have been made by the farmer and local veterinary surgeon. Therefore, it is likely that this infection with bovine besnoitiosis was an isolated, imported case.

### CONCLUSION

Bovine besnoitiosis has recently been declared an emerging disease in Europe (Anonymous, 2010). In non-endemic areas, the diagnosis of bovine besnoitiosis most commonly coincides with a recent introduction of animals on the farm (Cortes et al., 2014). The majority of infections with *B. besnoiti* are subclinical. The detection of the pathognomic, thick-walled tissue cysts in scleral conjunctiva and vaginal mucosa in

those animals that do develop clinical signs should be confirmed by at least one other diagnostic test (Álvarez-García et al., 2013). As no effective treatments or vaccines are available, exhaustive culling of seropositive animals together with biosecurity measurements, for example fly control, seem to be the most effective control strategy on farms with a low prevalence of the disease.

## ACKNOWLEDGEMENTS

The authors would like to thank Prof. Dr. Philippe Jacquet of the Laboratory of Parasitology, École Nationale Vétérinaire de Toulouse (France) for the western blot serology, Mr. James Adams of the Farm Animal Clinical Centre, The Royal Veterinary College, University of London (United Kingdom) for his critical linguistic review of the manuscript and Dr. Alexandre Leitão of the Instituto de Investigação Científica Tropical, CVZ, CIISA Faculdade de Medicina Veterinária, Universidade de Lisboa (Portugal) for his help in getting access to several references.

## CONFLICT OF INTEREST

The authors declare that they have no conflict of interest with the contents of this paper in any respect.

## REFERENCES

- Álvarez-García G., Frey C.F., Ortega-Mora L.M., Schares G. (2013). A century of bovine besnoitiosis: an unknown disease re-emerging in Europe. *Trends in Parasitology* 29, 407-415.
- Anonymous (2010). Scientific statement on Bovine besnoitiosis. *EFSA Journal* 8, 1499.
- Ayroud M., Leighton F.A., Tessaro S.V. (1995). The morphology and pathology of *Besnoitia* sp. in reindeer (*Rangifer tarandus tarandus*). *Journal of Wildlife Diseases* 31, 319-326.
- Basso W., Schares G., Gollnick N.S., Rütten M., Deplazes P. (2011). Exploring the life cycle of *Besnoitia besnoiti* experimental infection of putative definitive and intermediate host species. *Veterinary Parasitology* 178, 223-234.
- Basson P.A., McCully R.M., Bigalke R.D. (1970). Observations on the pathogenesis of bovine and antelope strains of *Besnoitia besnoiti* (Marotel, 1912) infection in cattle and rabbits. *Onderstepoort Journal of Veterinary Research* 37, 105-126.
- Bigalke R.D. (1968). New concepts on the epidemiological features of bovine besnoitiosis as determined by laboratory and field investigations. *Onderstepoort Journal of Veterinary Research* 35, 3-138.
- Bigalke R.D., van Niekerk J.W., Basson P.A., McCully R.M. (1967). Studies on the relationship between *Besnoitia* of blue wildebeest and impala, and *Besnoitia besnoiti* of cattle. *Onderstepoort Journal of Veterinary Research* 34, 7-28.
- Cortes H., Leitão A., Gottstein B., Hemphill A. (2014). A review on bovine besnoitiosis: a disease with economic impact in herd health management, caused by *Besnoitia besnoiti* (Franco and Borges, 1916). *Parasitology* 141, 1406-1417.
- Cortes H., Leitão A., Vidal R., Vila-Viçosa M.J., Ferreira M.L., Caeiro V., Hjerpe C.A. (2005). Besnoitiosis in bulls in Portugal. *Veterinary Record* 157, 263-264.
- Cortes H.C.E., Nunes S., Reis Y., Staubli D., Vidal R., Sager H., Leitão A., Gottstein B. (2006a). Immunodiagnosis of *Besnoitia besnoiti* infection by ELISA and Western blot. *Veterinary Parasitology* 141, 216-225.
- Cortes H.C.E., Reis Y., Waap H., Vidal R., Soares H., Marques I., da Pereira F., Fazendeiro I., Ferreira M.L., Caeiro V., Shkap V., Hemphill A., Leitão A. (2006b). Isolation of *Besnoitia besnoiti* from infected cattle in Portugal. *Veterinary Parasitology* 141, 226-233.
- Diesing L., Heydorn A.O., Matuschka F.R., Bauer C., Pipano E., de Waal D.T., Potgieter F.T. (1988). *Besnoitia besnoiti*: Studies on the definitive host and experimental infections in cattle. *Parasitology Research* 75, 114-117.
- García-Lunar P., Ortega-Mora L.M., Schares G., Gollnick N.S., Jacquet P., Grisez C., Prevot F., Frey C.F., Gottstein B., Álvarez-García G. (2013). An Inter-Laboratory Comparative Study of Serological Tools Employed in the Diagnosis of *Besnoitia besnoiti* Infection in Bovines. *Transboundary and Emerging Diseases* 60, 59-68.
- Gentile A., Militerno G., Schares G., Nanni A., Testoni S., Bassi P., Gollnick N.S. (2012). Evidence for bovine besnoitiosis being endemic in Italy—First *in vitro* isolation of *Besnoitia besnoiti* from cattle born in Italy. *Veterinary Parasitology* 184, 108-115.
- Gutiérrez-Expósito D., Ortega-Mora L.M., Gajadhar A.A., García-Lunar P., Dubey J.P., Álvarez-García G. (2012). Serological evidence of *Besnoitia* spp. infection in Canadian wild ruminants and strong cross-reaction between *Besnoitia besnoiti* and *Besnoitia tarandi*. *Veterinary Parasitology* 190, 19-28.
- Gutiérrez-Expósito D., Ortega-Mora L.M., Marco I., Boadella M., Gortázar C., San Miguel-Ayaz J.M., García-Lunar P., Lavín S., Álvarez-García G. (2013). First serosurvey of *Besnoitia* spp. infection in wild European ruminants in Spain. *Veterinary Parasitology* 197, 557-564.
- Hornok S., Fedák A., Baska F., Hofmann-Lehmann R., Basso W. (2014). Bovine besnoitiosis emerging in Central-Eastern Europe, Hungary. *Parasites & Vectors* 7, 20.
- Irigoien M., Del Cacho E., Gallego M., López-Bernad F., Quílez J., Sánchez-Acedo C. (2000). Immunohistochemical study of the cyst of *Besnoitia bensoiti*. *Veterinary Parasitology* 91, 1-6.
- Jacquet P., Liénard E., Franc M. (2010). Bovine besnoitiosis: Epidemiological and clinical aspects. *Veterinary Parasitology* 174, 30-36.
- Jacquet P., Prévot F., Grisez C., Liénard E., Bouhsira E., Franc M., Alzieu J.P., Desclaux X., Rameil M., Malavieille R., Boulon C., Mejean F. (2013). Emergence of bovine besnoitiosis in Europe: how to stop the spread? In: *Proceedings of the European Buiatrics Forum*. Marseille, 63.
- Kumi-Diaka J., Wilson S., Sannusi A., Njoku C.E., Osoru D.I.K. (1981). Bovine besnoitiosis and its effect on the male reproductive system. *Theriogenology* 16, 523-530.
- Liénard E., Salem A., Jacquet P., Grisez C., Prévot F., Blanchard B., Bohsira E., Franc M. (2013). Development of a protocol testing the ability of *Stomoxys calcitrans*

- (Linnaeus, 1758) (Diptera: Muscidae) to transmit *Besnoitia besnoiti* (Henry, 1913) (Apicomplexa: Sarcocystidae). *Parasitology Research* 112, 479-486.
- Mehlhorn H., Klimpel S., Schein E., Heydorn A.O., Al-Quraishy S., Selmair J. (2009). Another African disease in Central Europa: Besnoitiosis of cattle. I. Light and electron microscopical study. *Parasitology Research* 104, 861-868.
- Mutinelli F., Schiavon E., Ceglie L., Fasolato M., Natale A., Rampin F., Carminato A. (2011). Bovine besnoitiosis in imported cattle in Italy. *Veterinary Parasitology* 178, 198.
- Nasir A., Lanyon S.R., Schares G., Anderson M.L., Reichel M.P. (2012). Sero-prevalence of *Neospora caninum* and *Besnoitia besnoiti* in South Australian beef and dairy cattle. *Veterinary Parasitology* 186, 480-485.
- Ng'ang'a C.J. and Kasigazi S. (1994). Caprine besnoitiosis: studies on the experimental intermediate hosts and the role of the domestic cat in transmission. *Veterinary Parasitology* 52, 207-210.
- Olias P., Schade B., Mehlhorn H. (2011). Molecular pathology, taxonomy and epidemiology of *Besnoitia* species (Protozoa: Sarcocystidae). *Infection, Genetics and Evolution* 11, 1564-1576.
- Peteshev V.M., Galuzo I.G. Polomoshov A.P. (1974). Cats – definitive hosts *Besnoitia* (*Besnoitia besnoiti*) (in Russian). *Izvestia Akademii Nauk Kazakheskan SSR B*, 33-38, cited in Cortes et al., 2014.
- Pols J.W. (1960). Studies on bovine besnoitiosis with special reference to the aetiology. *Onderstepoort Journal of Veterinary Research* 28, 265-356.
- Rostaher A., Mueller R.S., Majzoub M., Schares G., Gollnick N.S. (2010). Bovine besnoitiosis in Germany. *Veterinary Dermatology* 21, 329-334.
- Schares G., Basso W., Majzoub M., Rostaher A., Scharr J.C., Langenmayer M.C., Selmair J., Dubey J.P., Cortes H.C., Conraths F.J., Gollnick N.S. (2010). Comparative evaluation of immunofluorescent antibody and new immunoblot tests for the specific detection of antibodies against *Besnoitia besnoiti* tachyzoites and bradyzoites in bovine sera. *Veterinary Parasitology* 171, 32-40.
- Schares G., Basso W., Majzoub M., Rostaher A., Scharr J.C., Langenmayer M.C., Selmair J., Dubey J.P., Cortes H.C., Conraths F.J., Haupt T., Pürro M., Raeber A., Buholzer P., Gollnick N.S. (2011a). Evaluation of a commercial ELISA for the specific detection of antibodies against *Besnoitia besnoiti*. *Veterinary Parasitology* 175, 52-59.
- Schares G., Langenmayer M.C., Scharr J.C., Minke L., Maksimov P., Maksimov A., Schares S., Bärwald A., Basso W., Dubey J.P., Conraths F.J., Gollnick N.S. (2013). Novel tools for the diagnosis and differentiation of acute and chronic bovine besnoitiosis. *International Journal for Parasitology* 43, 143-154.
- Schares G., Maksimov A., Basso W., Moré G., Dubey J.P., Rosenthal B., Majzoub M., Selmair J., Langenmayer M.C., Scharr J.C., Conraths F.J., Gollnick N.S. (2011b). Quantitative real time polymerase chain reaction assays for the sensitive detection of *Besnoitia besnoiti* infection in cattle. *Veterinary Parasitology* 178, 208-216.
- Schulz K.C.A. (1960). A report on naturally acquired besnoitiosis in bovines with special reference to its pathology. *Journal of the South African Veterinary Medical Association* 31, 21-35.
- Shkap V., Pipano E., Marcus S., Krigel Y. (1994). Bovine besnoitiosis: transfer of colostrum antibodies with observations possibly relating to natural transmission of the infection. *Onderstepoort Journal of Veterinary Research* 61, 273-275.
- Shkap V., Reske A., Pipano E., Fish L., Baszler T. (2002). Immunological relationship between *Neospora caninum* and *Besnoitia besnoiti*. *Veterinary Parasitology* 106, 35-43.
- Tenter A.M. and Johnson A.M. (1997). Phylogeny of the tissue cyst-forming coccidia. *Advances in Parasitology* 39, 69-139.
- Wap H., Cardoso R., Marcelino E., Malta J., Cortes H., Leitão A. (2011). A modified agglutination test for the diagnosis of *Besnoitia* infection. *Veterinary Parasitology* 178, 217-222.