


Quantitative histo-morphometric analysis of heat-stress-related damage in the small intestines of broiler chickens

Regiane R. Santos, Ajay Awati, Petra J. Roubos-van den Hil, Monique H. G. Tersteeg-Zijderveld, Peter A. Koolmees & Johanna Fink-Gremmels


To cite this article: Regiane R. Santos, Ajay Awati, Petra J. Roubos-van den Hil, Monique H. G. Tersteeg-Zijderveld, Peter A. Koolmees & Johanna Fink-Gremmels (2015) Quantitative histo-morphometric analysis of heat-stress-related damage in the small intestines of broiler chickens, *Avian Pathology*, 44:1, 19-22, DOI: [10.1080/03079457.2014.988122](https://doi.org/10.1080/03079457.2014.988122)

To link to this article: <http://dx.doi.org/10.1080/03079457.2014.988122>

 View supplementary material 

 Accepted author version posted online: 20 Nov 2014.
Published online: 23 Dec 2014.

 Submit your article to this journal 

 Article views: 222

 View related articles 

 View Crossmark data 

ORIGINAL ARTICLE

Quantitative histo-morphometric analysis of heat-stress-related damage in the small intestines of broiler chickens

Regiane R. Santos^{1*}, Ajay Awati², Petra J. Roubos-van den Hil²,
Monique H. G. Tersteeg-Zijdeveld¹, Peter A. Koolmees¹, and Johanna Fink-Gremmels¹

¹Faculty of Veterinary Medicine, Utrecht University, Utrecht, the Netherlands, and ²Nutreco R&D, Boxmeer, the Netherlands

The aim of the current research was to present a methodological approach allowing reproducible morphometric and morphological (Chiu/Park scale) analyses of the alterations in the intestines of broilers exposed to heat stress. Ross broilers were exposed over four consecutive days to a high-temperature regime in controlled climate rooms, with a day temperature of 39°C (±1°C) and a night temperature of 25°C (±1°C), respectively. A control group was kept at an ambient temperature of 25°C (±1°C) during the entire experimental period. At the end of the exposure period, the birds were sacrificed and specimens were taken of the duodenum, jejunum and ileum for histology. Blood was collected for oxidative stress analysis. Histo-morphological and morphometric analyses of the intestines indicated that the duodenum and jejunum showed more damage than the ileum. The major alterations in the control intestines were limited to the villus tips, while heat stress led to villus denudation and crypt damage. When compared with morphologically normal villi, heat-stress-associated alterations were also observed in villus height (decreased), villus breadth at base (increased) and epithelial cell area (decreased). Birds exposed to heat stress presented with an increase in glutathione peroxidase activity and a decreased antioxidant capacity. It can be concluded that the chosen model allows a reproducible quantification of heat stress effects, which is suitable for the evaluation of dietary intervention strategies to combat heat stress conditions.

Introduction

Heat stress severely affects the production performance of broilers, not only by decreasing feed intake but also by the typical mechanisms used to dissipate body heat, such as panting because a large proportion of heat loss in the bird is via evaporative cooling from the respiratory tract (Marder & Arad, 1989). This can lead to dehydration stress and subsequent gut damage, as the intestines seem to be the tissue most vulnerable to heat stress (Quinteiro-Filho *et al.*, 2010). A healthy intestinal epithelium is characterized by a rapid rate of cell turnover, whereby epithelial cells are continuously replaced by new cells derived from crypt stem cells. The integrity of the small intestine has been evaluated by measuring villus height and crypt depth (Hao *et al.*, 2012; Ashraf *et al.*, 2013; Song *et al.*, 2014), villus width (Ashraf *et al.*, 2013), villus:crypt ratio (Burkholder *et al.*, 2008; Hao *et al.*, 2012) and villus surface (Ashraf *et al.*, 2013). Histopathological scoring of lesions has been limited to semi-quantitative scores such as mild, moderate and severe alterations (Quinteiro-Filho *et al.*, 2010). A combination of detailed morphometric analyses with a transparent morphological evaluation using the Chiu/Park scale for grading intestinal damage (Quaedackers *et al.*, 2000) may be superior to these individual approaches. The aim of the current study was to validate the combination of the Chiu/Park model with morphometric analysis to address intestinal villus damage in broilers under the condition of heat stress.

Materials and Methods

Twenty 17-day-old Ross Broilers (10 males and 10 females), which had been brooded in the same environment (on litter at a stocking density of 10 birds/m²) and were from the same source, were housed in special bird units with a lighting programme of 16 h light (04:00 to 20:00) per 24 h. All birds used in the present study were vaccinated and had received an anti-coccidial. Feed (Supplemental Table 1) and water were given *ad libitum*. After a 6-day acclimatization period, birds were allocated at random to two groups: a control group, maintained at an ambient temperature of 25°C (±1°C); or a heat stress group with a room temperature of 39°C (±1°C) for 8 h during the daylight period for a period of 4 consecutive days. On the last day of heat stress, the birds were sacrificed for sampling. The experimental protocol was established in line with the prerequisites of the use of animals in research (DIRECTIVE 2010/63/EU) and had been approved prior to the onset of the experimental trials by the local committee on the uses of animals in research according to BGBI. I S. 1105.

Feed consumption and body weight of the birds were recorded at the beginning and at the end of the experimental period. Plasma was derived from blood (~10 ml collected per bird at slaughter), harvested by centrifugation (15 min at 1500 × *g*) and stored at -20°C. Oxidative stress was measured by the activity (nmol nicotinamide adenine dinucleotide phosphate/min/ml) of glutathione-peroxidase (GSH-Px) using a commercial kit (number 353919; Merck KGaA, Darmstadt, Germany), and the Trolox equivalent antioxidant capacity (TEAC, mM) was measured using an assay kit (number CS0790; Sigma, Saint Louis, MO, USA).

Small intestinal samples were taken from three different locations—2 cm after the gizzard (duodenum), just before Meckel's diverticulum (jejunum); and 2 cm before the ileo-caecal transition (ileum)— and fixed in 4% paraformaldehyde for histological analysis. Using light microscopy, morphometric and morphological analyses were performed. Villus height, top

*To whom correspondence should be addressed: Tel: +31 30 2531078. Fax: +31 30 2534125. E-mail: R.Rodriguesdossantos@pq.cnpq.br

(Received 20 June 2014; accepted 9 November 2014)

© 2014 Houghton Trust Ltd

and basal width, crypt depth, as well as epithelial cell and total villus areas (at least 10 villi per intestinal segment) from each individual bird were measured with an Olympus Camera coupled to a computer-assisted digital image analysis system Cell D 3.8. The villus height: crypt depth ratio and the villus area: epithelial area ratio were also quantified. Only intact villi were measured.

To evaluate the degree of mucosal damage, the Chiu/Park scale was applied (Quaedackers *et al.*, 2000). In brief, the mucosa was classified as normal if presenting with an intact structure and no visible damage (degree 0). Damage, in turn, was classified according to the degree of cell injury; that is, damage in the sub-epithelial space at the villus tips (degree 1), extension of the sub-epithelial space with moderate lifting (degree 2), massive lifting down sides of the villus with some denudation of the villus (degree 3), denuded villi with dilated capillaries (degree 4), disintegration of the lamina propria (degree 5), crypt injury (degree 6), trans-mucosal infarction (degree 7) and trans-mural infarction (degree 8).

Data were analysed with Prism 6.04 software (GraphPad, La Jolla, CA, USA) using one-way analysis of variance.

Results and Discussion

No mortality occurred and there was no significant ($P < 0.08$) difference in the body weight between the control birds (2372.2 ± 225.7 g) and heat-stressed birds (mean 2207.2 ± 182.2 g), although panting, wing spreading and squatting close to the ground was common in the birds

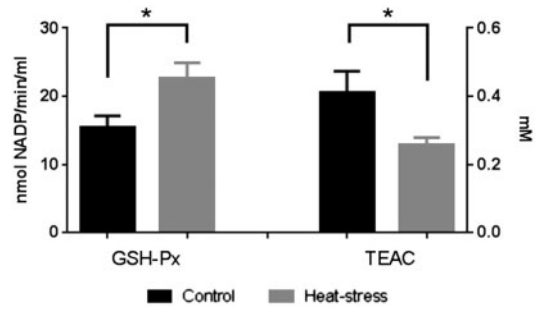


Figure 1. GSH-Px activity (nmol nicotinamide adenine dinucleotide phosphate/min/ml) and TEAC (mM). *Statistically significant differences between control and heat stress groups.

exposed to the high-temperature programme. The absence of mortality and no effect on body weight was unexpected, as on chicken farms birds seem to be more sensitive to heat stress, with even fatal outcomes under comparable climatic conditions in some cases (McDougald & McQuiston, 1980; Vale *et al.*, 2008). The most likely reason for this discrepancy is the fact that, in this study, the birds were kept in an experimental unit with more than sufficient space, under perfect hygienic conditions and free of any

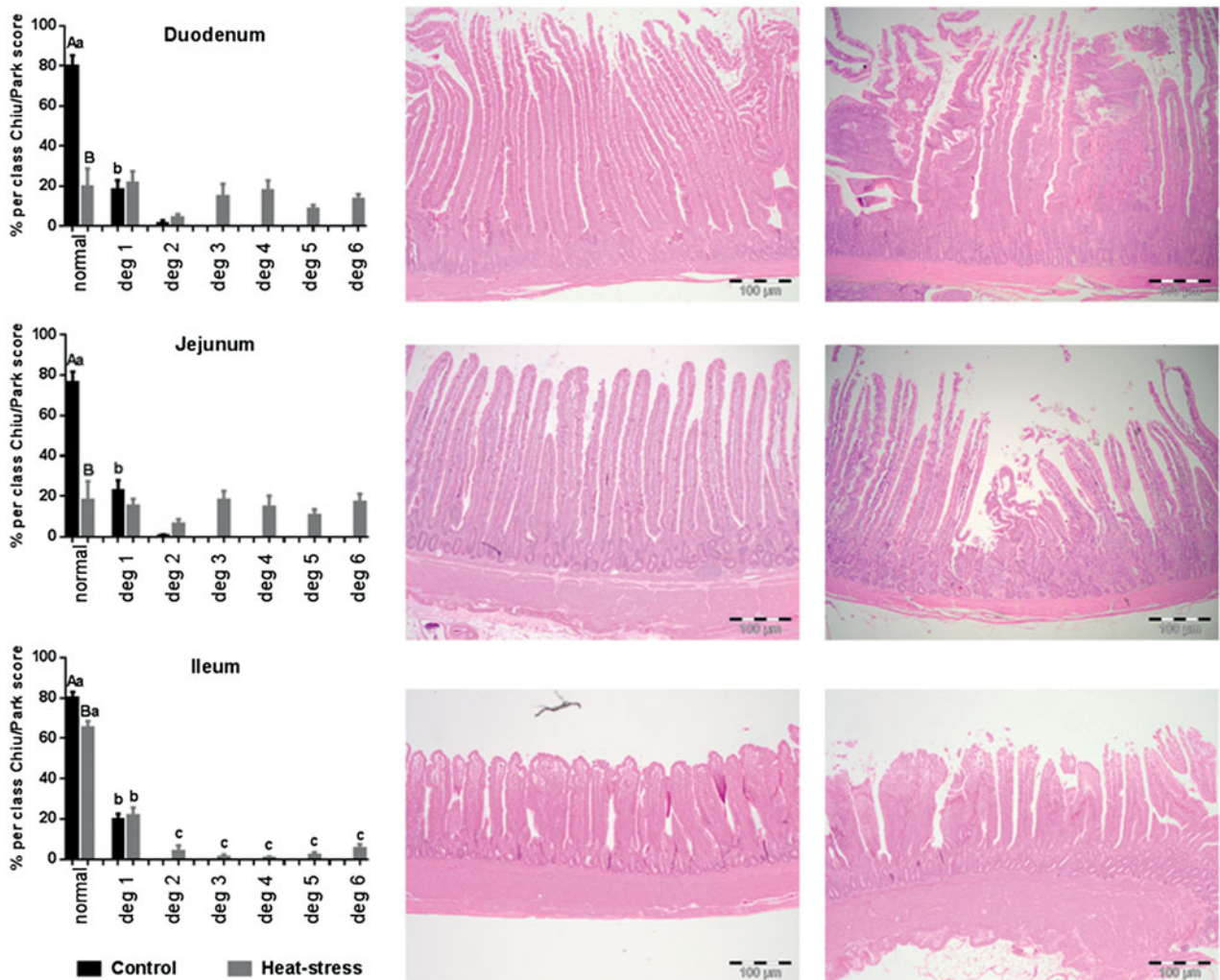


Figure 2. Percentages of normal features and lesion degrees (1 to 6) in the duodenum, jejunum and ileum from control and heat-stressed birds. Different lowercase letters differ between normal features and lesion degrees ($P < 0.05$); different uppercase letters differ between control and heat-stress poultry within the same lesion degree ($P < 0.05$). Illustrative images of haematoxylin and eosin-stained sections of normal small intestine (duodenum, jejunum and ileum) from control and heat-stress-treated birds. Scale bars = 100 μ m

Table 1. Influence of heat stress on morphological parameters of the duodenal, jejunal and ileal mucosa.

Parameter	Control	Heat stress
Villus height (μm)		
Duodenum	1524.00 \pm 45.38 ^A	1244.00 \pm 59.14 ^B
Jejunum	1429.00 \pm 91.98 ^A	1178.00 \pm 73.08 ^B
Ileum	657.70 \pm 33.56 ^A	525.30 \pm 12.58 ^B
Villus breadth apex (μm)		
Duodenum	49.02 \pm 04.16	44.31 \pm 05.11
Jejunum	69.52 \pm 06.09 ^A	45.17 \pm 04.77 ^B
Ileum	44.09 \pm 02.70	46.67 \pm 03.03
Villus breadth base (μm)		
Duodenum	58.10 \pm 05.38 ^A	89.46 \pm 07.23 ^B
Jejunum	109.80 \pm 13.48	84.96 \pm 08.92
Ileum	94.43 \pm 06.94	83.91 \pm 04.23
Villus width (μm)		
Duodenum	144.10 \pm 07.93 ^A	210.50 \pm 14.95 ^B
Jejunum	223.50 \pm 20.20	218.00 \pm 20.24
Ileum	172.40 \pm 12.52	179.30 \pm 08.48
Villus area (μm^2)		
Duodenum	182.34 \pm 08.18 ^A	251.00 \pm 18.26 ^B
Jejunum	337.34 \pm 33.33 ^A	254.07 \pm 24.10 ^B
Ileum	114.99 \pm 09.15 ^A	92.64 \pm 05.55 ^B
Crypt depth (μm)		
Duodenum	256.20 \pm 19.65	300.30 \pm 21.37
Jejunum	312.00 \pm 10.96 ^A	364.90 \pm 22.04 ^B
Ileum	189.60 \pm 06.60	191.90 \pm 06.35
Epithelial cell area (μm^2)		
Duodenum	144.67 \pm 04.83 ^A	108.61 \pm 08.23 ^B
Jejunum	197.99 \pm 25.14 ^A	122.02 \pm 09.17 ^B
Ileum	62.80 \pm 03.84 ^A	47.94 \pm 02.86 ^B
Villus height: crypt depth ratio		
Duodenum	09.70 \pm 00.54 ^A	0.4.82 \pm 00.33 ^B
Jejunum	04.65 \pm 00.57	03.99 \pm 00.44
Ileum	04.02 \pm 00.21 ^A	02.39 \pm 00.24 ^B
Villus area: epithelial cell area ratio		
Duodenum	01.27 \pm 00.05 ^A	02.42 \pm 00.16 ^B
Jejunum	01.77 \pm 00.09 ^A	02.31 \pm 00.19 ^B
Ileum	01.81 \pm 00.08 ^A	01.99 \pm 00.05 ^B

Data presented as mean \pm standard error of the mean. Different uppercase superscript letters indicate significant differences between control and heat stress groups within each intestinal segment (i.e. duodenum, jejunum or ileum).

other stressors. While the birds rested during the entire heat period (albeit with spread wings and panting), they rapidly compensated for this by rapid feed intake during the remaining light period. Such behaviour might have influenced the gut mucosal damage; Burkholder *et al.* (2008) showed that intestinal damage occurs due to heat stress and feed withdrawal. Therefore, while the gut was not empty at necropsy, we cannot exclude a degree of mucosal damage due to feed deprivation caused by heat stress.

Together with the typical adaptive behaviour to high-temperatures alterations, the biochemical parameters of oxidative stress were also altered, showing increased ($P < 0.05$) plasma GSH-Px activity accompanied by decreased ($P < 0.05$) TEAC values in heat-stressed birds when compared with control birds (Figure 1). The increased GSH-Px activity can be interpreted as an adaptive response of the cellular antioxidant defence system to remove reactive oxygen species (Yang *et al.*, 2010; Gu *et al.*, 2012), and is supported by the TEAC measurements.

Intestinal segments from control birds were normal and, if present, damage was limited to minor injury in the sub-epithelial space at the villus tips (Figure 2). A morphological analysis was conducted according to the Chiu/Park scale (Quaedackers *et al.*, 2000). Intestines from heat-stress-exposed birds showed alterations predominantly in the duodenal and jejunal villi and crypts, while the ileal morphology was unaffected. The duodenum and jejunum of heat-stressed birds presented with a decreased percentage ($P < 0.01$) of morphologically normal villi (presenting with damage type 1), together with an increase ($P < 0.01$) in villi damage types 2 to 6. Trans-mucosal and trans-mural infarctions were not observed. Representative images of villi from birds with and without heat stress are presented in Figure 2.

A full morphometric analysis of intestinal segments from control birds and from those challenged with high temperature was undertaken (Table 1). Villus height, epithelial and total villus areas, together with the villus:epithelial cell area ratio, were decreased ($P < 0.05$) in all the small intestine segments of the heat-stressed birds. The jejunum from the heat-stressed birds was also characterized by a decreased ($P < 0.01$) villus breadth at the apex and increased ($P < 0.01$) crypt depth. The duodenum from heat-stressed birds showed an increased villus breadth ($P < 0.01$). The ratio villus height: crypt depth was decreased in villi from the duodenum and ileum ($P < 0.01$). When the crypt depth was evaluated, only those from the jejunum were increased due to heat stress. This might be considered an adaptive response to villus damage in the jejunum, where hyperplasia of the crypt epithelium was induced to increase the absorptive area. Although the villus area from the jejunum and ileum were decreased when compared with control birds, the duodenal villus width as well as the breadth at the base and the villus area were increased in birds challenged by heat stress. This might be interpreted as a compensatory mechanism increasing the absorption of nutrients to more proximal sites, and in turn may explain why heat stress did not significantly affect body weight gain. Hao *et al.* (2012) showed that in the first 10 h of heat stress, no intestinal damage was observed in broilers. Intestinal injury related to heat stress was reported after 24 h by Burkholder *et al.* (2008), however, which is in line with our study, where birds were exposed for 4 days and each day for 8 h, a total of 32 h of heat stress. Quinteiro-Filho *et al.* (2010, 2012) did not find differences in villus height and crypt depth in the intestines from chickens subjected to heat stress for 6 days, which may indicate that the birds have the capacity to adapt to this condition. However, when birds are subjected to long-term heat stress such compensatory mechanisms are not sufficient to maintain intestinal integrity. Recently, Ashraf *et al.* (2013) showed that broilers exposed to high temperatures (35°C) for 21 days presented with damage to the intestines, including the ileum.

In conclusion, we have characterized the intestinal responses to repeated heat stress as a function of oxidative stress and the combination of villi morphology and morphometry alterations. The combination of morphological and morphometric analyses can be recommended as a reliable and objective parameter to evaluate subtle differences in intestinal morphology. This method can be applied to experiments assessing the benefits of special diets designed to reduce the adverse effects of stress in birds.

Acknowledgements

The authors thank the technical team of Nutreco N.V., the Netherlands for their valuable discussions. Some of the data presented in this manuscript were presented at the XXIV World Poultry Congress in 2012.

Supplemental Data

Supplemental data for this article can be accessed [here](#).

References

- Ashraf, S., Zaneb, H., Yousaf, M.S., Ijaz, A., Sohail, M.U., Muti, S., Usman, M.M., Ijaz, S. & Rehman H. (2013). Effect of dietary supplementation of prebiotics and probiotics on intestinal microarchitecture in broilers reared under cyclic heat stress. *Journal of Animal Physiology and Animal Nutrition*, 97, 68–73.
- Burkholder, K.M., Thompson, K.L., Einstein, M.E., Applegate, T.J. & Patterson, J.A. (2008). Influence of stressors on normal intestinal microbiota, intestinal morphology, and susceptibility to *Salmonella* Enteritidis colonization in broilers. *Poultry Science*, 87, 1734–1741.
- Gu, X.H., Hao, Y. & Wang, X.L. (2012). Overexpression of heat shock protein 70 and its relationship to intestine under acute heat stress in broilers: intestinal oxidative stress. *Poultry Science*, 91, 790–799.
- Hao, Y., Gu, X.H. & Wang, X.L. (2012). Overexpression of heat shock protein 70 and its relationship to intestine under acute heat stress in broilers: intestinal structure and digestive function. *Poultry Science*, 91, 781–789.
- Marder, J. & Arad, Z. (1989). Panting and acid-base regulation in heat stressed birds. *Comparative Biochemistry and Physiology Part A: Physiology*, 94, 395–400.
- McDougald, L.R. & McQuiston, T.E. (1980). Mortality from heat stress in broiler chickens influenced by anticoccidial drugs. *Poultry Science*, 59, 2421–2423.
- Quaedackers, J.S.L.T., Beuk, R.J., Bennet, L., Charlton, A., Oude Egbrink, M.G.A., Gunn, A.J. & Heineman, E. (2000). An evaluation of methods for grading histologic injury following ischemia/reperfusion of the small bowel. *Transplantation Proceedings*, 32, 1307–1310.
- Quinteiro-Filho, W.M., Gomes, A.V.S., Pinheiro, M.L., Ribeiro, A., Ferraz-de-Paula, V., Astolfi-Ferreira, C.S., Ferreira, A.J.P. & Palermo-Neto, J. (2012). Heat stress impairs performance and induces intestinal inflammation in broiler chickens infected with *Salmonella* Enteritidis. *Avian Pathology*, 41, 421–427.
- Quinteiro-Filho, W.M., Ribeiro, A., Ferraz-de-Paula, V., Pinheiro, M.L., Sakai, M., Sa, L.R.M., Ferreira, A.J.P. & Palermo-Neto, J. (2010). Heat stress impairs performance parameters, induces intestinal injury, and decreases macrophage activity in broiler chickens. *Poultry Science*, 89, 1905–1914.
- Song, J., Xiao, K., Ke, Y.L., Jiao, L.F., Hu, C.H., Diao, Q.Y., Shi, B. & Zou, X.T. (2014). Effect of a probiotic mixture on intestinal microflora, morphology, and barrier integrity of broilers subjected to heat stress. *Poultry Science*, 93, 581–588.
- Vale, M.M., de Moura, D.J., Nääs, I.A., Oliveira, S.R.M. & Rodrigues, L.H. A. (2008). Data mining to estimate broiler mortality when exposed to heat wave. *Scientia Agricola*, 65, 223–229.
- Yang, L., Tan, G.-Y., Fu, Y.-Q., Feng, J.-H. & Zhang, M.-H. (2010). Effects of acute heat stress and subsequent stress removal on function of hepatic mitochondrial respiration, ROS production and lipid peroxidation in broiler chickens. *Comparative Biochemistry and Physiology Part C: Toxicology & Pharmacology*, 151, 204–208.