

Strategies to improve the outcome of esophagectomy for esophageal cancer

Judith Boone

Strategies to improve the outcome of esophagectomy for esophageal cancer -
Judith Boone. Thesis, Utrecht University, Faculty of Medicine, the Netherlands

ISBN: 978-90-393-4976-2
Printed by: Gildeprint Drukkerijen - Enschede
Lay-out: Gildeprint Drukkerijen - Enschede
Illustrations: Ingrid Janssen, UMC Utrecht
Cover: Robot-assisted thoracoscopic esophagectomy, Raymond Toelanie,
UMC Utrecht

Copyright © 2008 Judith Boone, Utrecht, the Netherlands

No part of this thesis may be reproduced, stored in a database or retrieval system, or transmitted in any form or by any means without prior written permission of the author, or when appropriate, the publishers of the published papers.

Financial support for the printing of this thesis was generously provided by:

Stichting Rigter!, Haarlem; Tilman Rosens Van der Corput (TRC) Advocaten, Veldhoven; Straalbedrijf Boone B.V., Middelburg; Storm Industriediensten B.V., Rhoon; Intuitive Surgical, Aubonne, Zwitserland; Kenneth Smith Training, Eindhoven; Dhr. Vorspaget, Waalre; Supermarkt Heijmans B.V., Malden; Wicro Plastics B.V., Kessel; Caleidoscoop Leertrajecten B.V., Veghel; Siemens Nederland N.V. Medical Solutions, Den Haag; Novartis Oncology, Arnhem; Covidien, Zaltbommel; EuroTec, Roosendaal; AstraZeneca Gastroenterology, Zoetermeer; Bayer HealthCare, Mijdrecht; Janssen-Cilag B.V., Tilburg; Medical Measurement Systems B.V., Enschede; Roche Nederland B.V., Woerden; Sanofi-Aventis Nederland B.V., Gouda; Chirurgisch Fonds UMC Utrecht; Stichting Nationaal Fonds Tegen Kanker, voor *onderzoek naar reguliere en aanvullende therapieën*, Amsterdam; GlaxoSmithKline, Zeist; Welmed B.V., Hardenberg; J.E. Jurriaanse Stichting, Rotterdam; PinkRoccade Healthcare, 's Hertogenbosch;

Strategies to improve the outcome of esophagectomy for esophageal cancer

Strategieën om de uitkomst van slokdarmkankeroperaties te verbeteren

(met een samenvatting in het Nederlands)

Proefschrift

ter verkrijging van de graad van doctor aan de Universiteit Utrecht
op gezag van de rector magnificus, prof. dr. J.C. Stoof,
ingevolge het besluit van het college voor promoties
in het openbaar te verdedigen op

donderdag 29 januari 2009 des middags om 2.30 uur

door

Judith Boone

geboren op 29 augustus 1982 te Middelburg

Promotoren: Prof.dr. R. van Hillegersberg
Prof.dr. I.H.M. Borel Rinkes
Prof.dr. F.J.W. ten Kate

Aan mijn ouders

CONTENTS

Chapter 1	General introduction and outline of the thesis	9
Part I:	Surgical strategies	21
Chapter 2	International survey on esophageal cancer: Part I Surgical techniques	23
Chapter 3	First experience with robot-assisted thoracoscopic esophagolymphadenectomy for esophageal cancer	43
Chapter 4	Gastric conduit staple line: to oversee or not?	59
Chapter 5	The effect of azygos vein preservation on mediastinal lymph node harvesting in thoracic esophagolymphadenectomy	67
Chapter 6	Robot-assisted thoracoscopic esophagectomy for esophageal cancer: short- and mid-term results	79
Chapter 7	Robot-assisted thoracoscopic esophagectomy for a giant upper esophageal leiomyoma	101
Part II:	Molecular biological strategies	113
Chapter 8	Validation of tissue microarray technology in squamous cell carcinoma of the esophagus	115
Chapter 9	Targets for molecular therapy in esophageal squamous cell carcinoma: an immunohistochemical analysis	133
Chapter 10	mTOR in esophageal squamous cell carcinoma: A potential target for molecular therapy?	153

Part III: Diagnostic imaging strategies	169
Chapter 11 International survey on esophageal cancer: Part II Staging and neoadjuvant therapy	171
Chapter 12 Sentinel node biopsy in esophageal cancer: Results of a Western European feasibility study	191
Chapter 13 Diagnostic value of routine aqueous contrast swallow examination after esophagectomy for detecting leakage of the cervical esophagogastric anastomosis	211
Chapter 14 Summary	229
Chapter 15 General discussion and conclusions	237
Chapter 16 Samenvatting in het Nederlands voor niet-ingewijden	249
Chapter 17 Addenda	265
I - Robot-assisted thoracoscopic esophagolymphadenectomy for esophageal cancer	267
II - Transhiatal robot-assisted esophagectomy	271
III - The azygos vein: to resect or not?	275
Chapter 18 List of abbreviations	280
List of publications	282
Review committee	284
Dankwoord	285
Curriculum vitae	291
Color figures	292

1

**General introduction and
outline of the thesis**

1

Esophageal cancer

Esophageal cancer is the 8th most common type of malignancy and the 6th most common cause of cancer mortality in the world.¹ In 2002, the amount of newly diagnosed patients worldwide was approximately 462,000.¹ The two most common histologic subtypes are esophageal squamous cell carcinoma (ESCC), arising from dysplastic squamous epithelium of the esophagus and esophageal adenocarcinoma (EAC), originating from dysplasia in columnar-lined esophagus with intestinal metaplasia (i.e. Barrett's esophagus).^{2,3} For the past decades the incidence of esophageal cancer has rapidly increased, particularly due to a rise in adenocarcinoma of the esophagus.⁴ Yet, worldwide the incidence of ESCC is highest.¹

For patients diagnosed with locally advanced esophageal cancer, the best chance of cure is offered by radical surgical resection.⁵ As symptoms, such as dysphagia and retrosternal discomfort, arise only when the tumor is large enough to obstruct the esophageal lumen, patients are frequently diagnosed at an advanced stage. Consequently, less than half of patients are eligible for surgery due to tumor ingrowth into adjacent structures or due to the presence of distant metastases.^{6,7}

Surgical treatment of esophageal cancer

As the esophagus has a unique longitudinal lymphatic drainage system in the submucosal layer, lymph node metastases of esophageal cancer can occur along the entire esophagus from the cervical to the abdominal part.⁸⁻¹¹ The optimal treatment for esophageal cancer, therefore, consists of transthoracic en bloc esophagectomy (TTE) with an extensive mediastinal and abdominal lymph node dissection (LND).⁵ This approach through thoracotomy is accompanied by significant morbidity, which is predominantly due to cardiopulmonary complications.^{12,13}

To reduce the surgical trauma and thus the morbidity of open TTE, less invasive surgical techniques such as transhiatal esophagectomy (THE) and minimally invasive esophagectomy (MIE) have been introduced.^{14,15} A randomized controlled trial on TTE versus THE has shown the latter to carry a lower complication rate.¹² However, since with THE the esophagus is stripped out of the mediastinum, only a limited LND can be carried out without dissection of the upper mediastinal lymph nodes.^{14,16} Consequently, a

trend towards a better survival for TTE over THE was detected.^{12,17} Statistical significance was not reached, but this was most probably a result of the fact that the study was underpowered.

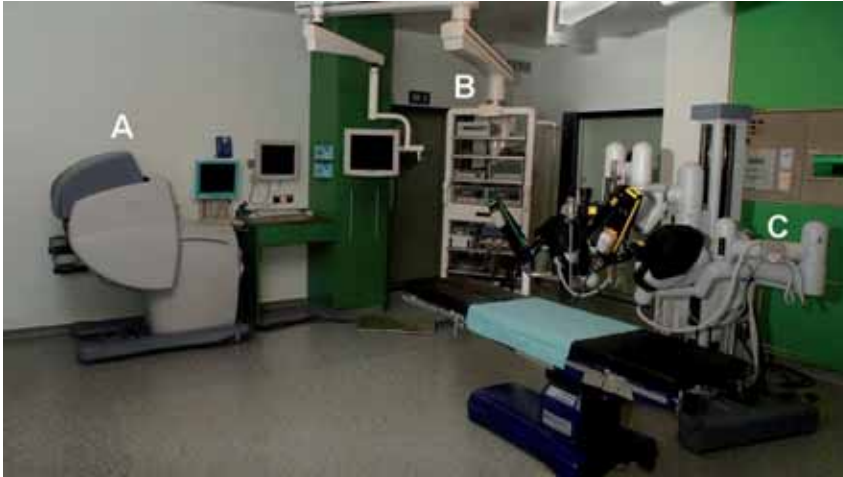
With regard to MIE, the world’s largest series on thoracoscopic esophagectomy has shown a significantly lower blood loss and morbidity compared to open TTE.¹⁸ However, the survival after this procedure was worse than after open TTE (3-year overall survival rate for stage II patients of 20%¹⁸ vs. 50%^{5,19}, respectively). This could be explained by the fact that the disadvantages of “conventional” scopic surgery, such as a 2-dimensional vision, disturbed eye-hand coordination and fewer degrees of freedom,²⁰ hamper the surgeon in performing a proper mediastinal LND, thereby increasing the risk of regional tumor recurrence.

Robotic systems have been developed to overcome the limitations of conventional scopic surgery.²⁰ The Da Vinci® robotic system consists of 3 parts (Figure 1): I) the 3-armed robotic system which is positioned next to the operating table; II) the console of the robotic system with joystick-like hand controls and with foot pedals through which the surgeon can control the arms of the robotic system and III) the accessories cart which holds e.g. the insufflator, light sources and focus control. The Da Vinci® robotic system offers the surgeon a tenfold magnified, 3-dimensional view on the surgical field.²¹ The surgeon’s tremor is filtered and the articulated surgical instruments allow for more degrees of freedom. These advantages facilitate a precise dissection in a confined operating space. Robotic surgical systems have successfully been applied in various specialities such as urology,^{22,23} gynaecology,²⁴ cardiothoracic surgery^{25,26} and general surgery²⁷. For radical prostatectomy the robot-assisted approach has shown to be superior to the conventional laparoscopic approach²² and has therefore become the treatment of choice in many centers. Robotic systems may also be of added value in thoracoscopic esophagectomy, by facilitating a more accurate mediastinal dissection of the esophagus with the surrounding lymph nodes when compared to conventional thoracoscopic esophagectomy.

1	1
	2
	3
	4
	5
	6
	7
	8
	9
	10
	11
	12
	13
	14
	15
	16
	17
	18
	19
	20
	21
	22
	23
	24
	25
	26
	27
	28
	29
	30
	31
	32

1

Figure 1 - The Da Vinci® surgical system consisting of the surgeon's console (A), the accessory cart (B) and the robotic surgical system (C) (see page 292 for color figure).



Neoadjuvant therapy

Due to the frequent occurrence of recurrent disease, the survival after esophagectomy is relatively poor. The overall 5-year survival rate after open TTE is around 35%.¹⁷ Tumor recurrence can be locally (i.e. at the anastomosis), regionally (i.e. the mediastinal lymph nodes) or systemically (i.e. organ metastases or distant lymph nodes). Locoregional recurrence is due to an incomplete tumor resection and, thus, to inadequate surgery, whereas the latter is predominantly a consequence of early metastatic spread.

A recent meta-analysis has revealed that neoadjuvant chemoradiotherapy (CRTx)

improves the two-year survival rate of esophageal cancer patients with approximately 10% by downstaging of the tumor and by early opposing metastatic spread.²⁸ Yet, it is unknown at what frequency neoadjuvant therapy is nowadays incorporated in the work-up of esophageal cancer patients.

A disadvantage of chemotherapy is that it destructs all proliferating cells, including normal healthy cells leading to toxicity.^{29,30} Hence, therapy has been developed that selectively acts on tumor cells by aiming at molecular characteristics of a tumor.³¹ Although various targets for molecular therapy have been identified in cancer^{32,33} and although some clinical studies with targeted therapy have been performed in esophageal carcinoma,^{34,35} it remains to be further elucidated which particular molecular markers to target in esophageal cancer.

The presence of molecular markers in tissues can be assessed by means of immunohistochemical analysis of formalin-fixed, paraffin-embedded tissues. The tissue microarray (TMA) technology has been developed to facilitate high-throughput immunohistochemical and in situ hybridization analysis of tissues.³⁶ By inserting small (diameter 0.6mm) donor biopsy cores into a single recipient paraffin block (Figure 2), these tissues can be analyzed under identical laboratory and evaluation conditions, without significantly damaging the patient's tissue.³⁶ Moreover, it leads to a reduction of the amount of consumables used and time needed for interpretation.

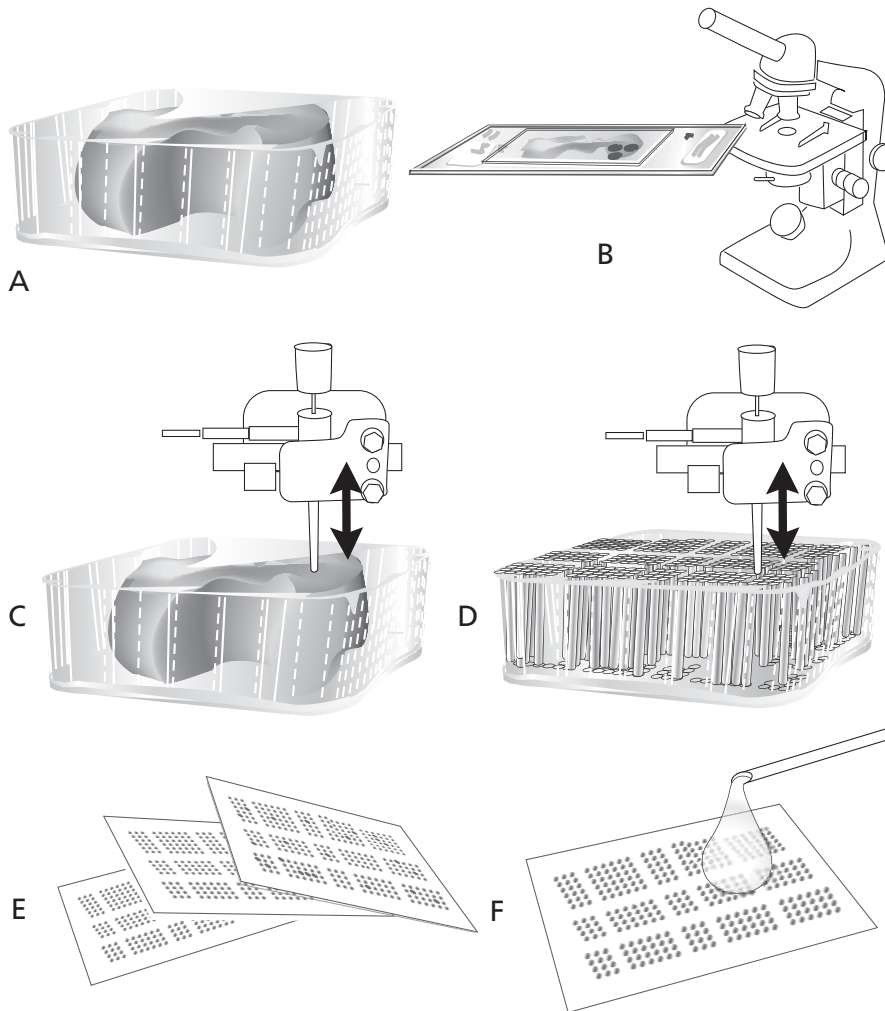
Diagnostic imaging

Staging of esophageal cancer can be done with diagnostic modalities such as endoscopic ultrasonography (EUS), computed tomography (CT) scanning and ultrasonography (US) of the neck.^{37,38} EUS has proven to be the most accurate tool for assessing the depth of tumor infiltration into the esophageal wall.³⁹ Organ metastases can accurately be identified by CT-scanning, whereas US of the neck is the preferred diagnostic modality for the detection of supraclavicular lymph node metastases.³⁸ It is, however, unknown in what frequency these different diagnostic modalities are currently being applied worldwide in the work-up of esophageal cancer patients.

1	1
	2
	3
	4
	5
	6
	7
	8
	9
	10
	11
	12
	13
	14
	15
	16
	17
	18
	19
	20
	21
	22
	23
	24
	25
	26
	27
	28
	29
	30
	31
	32

1

Figure 2 - Simplified schematic overview of the construction of a tissue microarray (TMA). A: donor paraffin block containing tissue (dark); B: microscopical selection of 3 representative tissue regions on a haematoxylin & eosin section of the donor paraffin block; C: from each representative tissue region a biopsy core (diameter 0.6 mm) is punched out of the corresponding donor paraffin block; D: biopsy cores are transferred to the recipient TMA paraffin block. E: multiple sections can be cut from the TMA paraffin block; F: immunohistochemical analysis performed on a single TMA-slide provides information on hundreds of tissues.

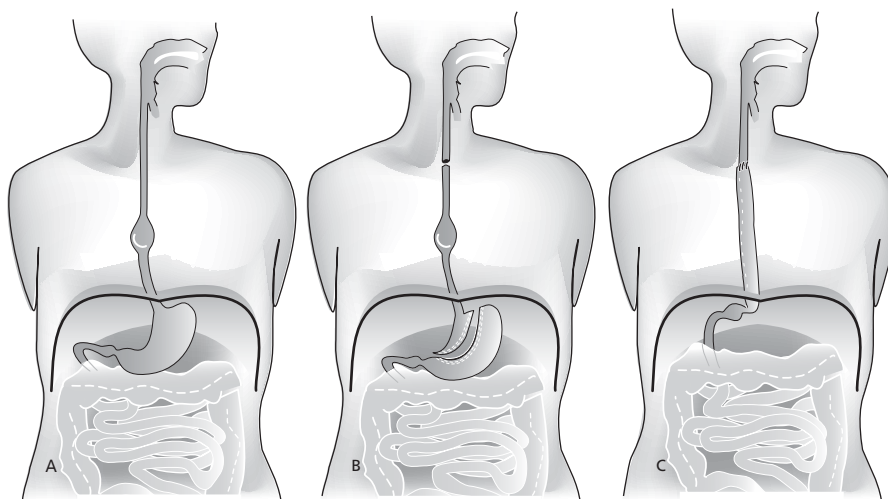


For patients without lymph node metastases in the resected specimen (pN0), the extensive LND turned out to be abundant. In these patients, the morbidity of esophagectomy could be improved by tailoring the extent of LND. This might be achieved by introducing the sentinel node (SN) concept in esophageal cancer surgery. A sentinel node (SN) is

a lymph node that receives lymphatic flow directly from the primary tumor, being the first site of metastatic spread.⁴⁰ The SN concept states that when pathologic analysis of SNs shows no evidence of tumor, a LND of the draining lymph nodes may be omitted.⁴¹ This technique is nowadays widely accepted as an alternative for the standard axillary lymphadenectomy in breast carcinoma patients.⁴²

After resection of the esophagus and cardia, the digestive tract is generally reconstructed with a gastric conduit (Figure 3).⁴³ This conduit is created by means of linear staplers and is anastomosed in the neck or intrathoracically. An important cause of morbidity and mortality after esophagectomy is anastomotic leakage.⁴⁴ The reported incidence of cervical anastomotic leakage ranges from 0%-25%.⁴⁴ To assess the anastomotic integrity before oral intake is resumed, an aqueous contrast swallow examination is routinely performed around the 7th postoperative day in many centers.⁴⁵ In case no radiological leakage is noticed, diet is gradually resumed; when a radiological leakage is detected, oral intake is prohibited for another week. Yet, the value of this routine radiological examination is controversial.

Figure 3 - Schematic overview on esophagectomy with gastric conduit formation. A: Tumor in the middle part of the esophagus B: Resection includes the thoracoabdominal part of the esophagus, the cardia and mediastinal and abdominal lymph nodes (not shown). To reconstruct the digestive tract, from the stomach a conduit is constructed. C: The gastric conduit is pulled through the posterior mediastinum to the neck. A handsewn or stapled anastomosis is made between the conduit and the cervical part of the esophagus



1
2
3
4
5
6
7
8
9
10
11
12
13
14
15
16
17
18
19
20
21
22
23
24
25
26
27
28
29
30
31
32

1

OUTLINE AND CENTRAL QUESTIONS OF THIS THESIS

The general aim of this thesis is to investigate strategies in the field of surgery (**Part I**), molecular biology (**Part II**) and diagnostic imaging (**Part III**) through which the outcome of patients that undergo esophagectomy for esophageal cancer could be improved.

The studies presented in this thesis are guided by the following research questions:

- What is the current worldwide practice in surgical techniques, preoperative staging and neoadjuvant therapy as applied in esophageal cancer? (**Chapters 2 and 11**)
- Could the application of minimally invasive robotic systems reduce the morbidity of transthoracic esophagectomy without compromising oncologic outcome? (**Chapters 3-7**)
- Which markers are potential targets for neoadjuvant molecular therapy in squamous cell carcinoma of the esophagus? (**Chapters 8-10**)
- Is there a justification for sentinel node biopsy or routine post-esophagectomy aqueous contrast swallow examination in esophageal cancer? (**Chapters 12 and 13**)


REFERENCES

1	1
	2
	3
	4
	5
	6
	7
	8
	9
	10
	11
	12
	13
	14
	15
	16
	17
	18
	19
	20
	21
	22
	23
	24
	25
	26
	27
	28
	29
	30
	31
	32

1. Kamangar F, Dores GM, Anderson WF. Patterns of cancer incidence, mortality, and prevalence across five continents: defining priorities to reduce cancer disparities in different geographic regions of the world. *J Clin Oncol* 2006; 24:2137-2150.
2. Stoner GD and Gupta A. Etiology and chemoprevention of esophageal squamous cell carcinoma. *Carcinogenesis* 2001; 22:1737-1746.
3. Marsman WA, Tytgat GN, ten Kate FJ, van Lanschot JJ. Differences and similarities of adenocarcinomas of the esophagus and esophagogastric junction. *J Surg Oncol* 2005; 92:160-168.
4. Holmes RS and Vaughan TL. Epidemiology and pathogenesis of esophageal cancer. *Semin Radiat Oncol* 2007; 17:2-9.
5. Mariette C, Piessen G, Triboulet JP. Therapeutic strategies in oesophageal carcinoma: role of surgery and other modalities. *Lancet Oncol* 2007; 8:545-553.
6. Koshy M, Esiashvili N, Landry JC, Thomas CR Jr., Matthews RH. Multiple management modalities in esophageal cancer: epidemiology, presentation and progression, work-up, and surgical approaches. *Oncologist* 2004; 9:137-146.
7. Enzinger PC and Mayer RJ. Esophageal cancer. *N Engl J Med* 2003; 349:2241-2252.
8. Zuidema GD. Shackelford's surgery of the alimentary tract. W.B.Saunders Company; 2002.
9. van Sandick JW, van Lanschot JJ, ten Kate FJ et al. Pathology of early invasive adenocarcinoma of the esophagus or esophagogastric junction: implications for therapeutic decision making. *Cancer* 2000; 88:2429-2437.
10. Li H, Zhang Y, Cai H, Xiang J. Pattern of lymph node metastases in patients with squamous cell carcinoma of the thoracic esophagus who underwent three-field lymphadenectomy. *Eur Surg Res* 2007; 39:1-6.
11. Stein HJ, Feith M, Bruecher BL, Naehrig J, Sarbia M, Siewert JR. Early esophageal cancer: pattern of lymphatic spread and prognostic factors for long-term survival after surgical resection. *Ann Surg* 2005; 242:566-573.
12. Hulscher JB, van Sandick JW, de Boer AG et al. Extended transthoracic resection compared with limited transhiatal resection for adenocarcinoma of the esophagus. *N Engl J Med* 2002; 347:1662-1669.
13. Griffin SM, Shaw IH, Dresner SM. Early complications after Ivor Lewis subtotal esophagectomy with two-field lymphadenectomy: risk factors and management. *J Am Coll Surg* 2002; 194:285-297.
14. Orringer MB, Marshall B, Chang AC, Lee J, Pickens A, Lau CL. Two thousand transhiatal esophagectomies: changing trends, lessons learned. *Ann Surg* 2007; 246:363-372.

15. Espat NJ, Jacobsen G, Horgan S, Donahue P. Minimally invasive treatment of esophageal cancer: laparoscopic staging to robotic esophagectomy. *Cancer J* 2005; 11:10-17.
16. Orringer MB. Transhiatal esophagectomy without thoracotomy for carcinoma of the thoracic esophagus. *Ann Surg* 1984; 200:282-288.
17. Omloo JM, Lagarde SM, Hulscher JB et al. Extended transthoracic resection compared with limited transhiatal resection for adenocarcinoma of the mid/distal esophagus: five-year survival of a randomized clinical trial. *Ann Surg* 2007; 246:992-1000.
18. Luketich JD, Alvelo-Rivera M, Buenaventura PO et al. Minimally invasive esophagectomy: outcomes in 222 patients. *Ann Surg* 2003; 238:486-494.
19. Mariette C, Piessen G, Balon JM, Van S, I, Triboulet JP. Surgery alone in the curative treatment of localised oesophageal carcinoma. *Eur J Surg Oncol* 2004; 30:869-876.
20. Ruurda JP, van Vroonhoven TJ, Broeders IA. Robot-assisted surgical systems: a new era in laparoscopic surgery. *Ann R Coll Surg Engl* 2002; 84:223-226.
21. Hanly EJ and Talamini MA. Robotic abdominal surgery. *Am J Surg* 2004; 188:19-26.
22. Menon M, Shrivastava A, Tewari A. Laparoscopic radical prostatectomy: Conventional and robotic. *Urology* 2005; 66:101-104.
23. Yanke BV, Lallas CD, Pagnani C, Bagley DH. Robot-assisted laparoscopic pyeloplasty: technical considerations and outcomes. *J Endourol* 2008; 22:1291-1296.
24. Advincula AP and Song A. The role of robotic surgery in gynecology. *Curr Opin Obstet Gynecol* 2007; 19:331-336.
25. Bolotin G, Kypson AP, Nifong LW, Chitwood WR, Jr. Robotically-assisted left atrial fibrillation ablation and mitral valve repair through a right mini-thoracotomy. *Ann Thorac Surg* 2004; 78:e63-e64.
26. Felger JE, Nifong LW, Chitwood WR. The evolution and early experience with robot-assisted mitral valve surgery. *Curr Surg* 2001; 58:570-575.
27. Gutt CN, Oniu T, Mehrabi A, Kashfi A, Schemmer P, Buchler MW. Robot-assisted abdominal surgery. *Br J Surg* 2004; 91:1390-1397.
28. Gebski V, Burmeister B, Smithers BM, Foo K, Zalberg J, Simes J. Survival benefits from neoadjuvant chemoradiotherapy or chemotherapy in oesophageal carcinoma: a meta-analysis. *Lancet Oncol* 2007; 8:226-234.
29. Cavaletti G and Marmiroli P. Chemotherapy-induced peripheral neurotoxicity. *Expert Opin Drug Saf* 2004; 3:535-546.
30. Zuppinger C, Timolati F, Suter TM. Pathophysiology and diagnosis of cancer drug induced cardiomyopathy. *Cardiovasc Toxicol* 2007; 7:61-66.

31.	Tew WP, Kelsen DP, Ilson DH. Targeted therapies for esophageal cancer. <i>Oncologist</i> 2005; 10:590-601.	1	1
32.	Mendelsohn J and Baselga J. Epidermal growth factor receptor targeting in cancer. <i>Semin Oncol</i> 2006; 33:369-385.		2
33.	Press MF and Lenz HJ. EGFR, HER2 and VEGF pathways: validated targets for cancer treatment. <i>Drugs</i> 2007; 67:2045-2075.		3
34.	Safran H, Dipetrillo T, Akerman P et al. Phase I/II study of trastuzumab, paclitaxel, cisplatin and radiation for locally advanced, HER2 overexpressing, esophageal adenocarcinoma. <i>Int J Radiat Oncol Biol Phys</i> 2007; 67:405-409.		4
35.	Janmaat ML, Gallegos-Ruiz MI, Rodriguez JA et al. Predictive factors for outcome in a phase II study of gefitinib in second-line treatment of advanced esophageal cancer patients. <i>J Clin Oncol</i> 2006; 24:1612-1619.		5
36.	Kononen J, Bubendorf L, Kallioniemi A et al. Tissue microarrays for high-throughput molecular profiling of tumor specimens. <i>Nat Med</i> 1998; 4:844-847.		6
37.	van Vliet EP, Heijnenbroek-Kal MH, Hunink MG, Kuipers EJ, Siersema PD. Staging investigations for oesophageal cancer: a meta-analysis. <i>Br J Cancer</i> 2008; 98:547-557.		7
38.	van Vliet EP, van der LA, Kuipers EJ et al. Ultrasound, computed tomography, or the combination for the detection of supraclavicular lymph nodes in patients with esophageal or gastric cardia cancer: a comparative study. <i>J Surg Oncol</i> 2007; 96:200-206.		8
39.	Lightdale CJ and Kulkarni KG. Role of endoscopic ultrasonography in the staging and follow-up of esophageal cancer. <i>J Clin Oncol</i> 2005; 23:4483-4489.		9
40.	Nieweg OE, Tanis PJ, Kroon BB. The definition of a sentinel node. <i>Ann Surg Oncol</i> 2001; 8:538-541.		10
41.	Amersi F and Morton DL. The role of sentinel lymph node biopsy in the management of melanoma. <i>Adv Surg</i> 2007; 41:241-56:241-256.		11
42.	Kim T, Giuliano AE, Lyman GH. Lymphatic mapping and sentinel lymph node biopsy in early-stage breast carcinoma: a metaanalysis. <i>Cancer</i> 2006; 106:4-16.		12
43.	Urschel JD. Does the interponat affect outcome after esophagectomy for cancer? <i>Dis Esophagus</i> 2001; 14:124-130.		13
44.	Urschel JD. Esophagogastrostomy anastomotic leaks complicating esophagectomy: a review. <i>Am J Surg</i> 1995; 169:634-640.		14
45.	Upponi S, Ganeshan A, Slater A et al. Imaging following surgery for oesophageal cancer. <i>Clinical Radiology</i> 2007; 62:724-731.		15
			16
			17
			18
			19
			20
			21
			22
			23
			24
			25
			26
			27
			28
			29
			30
			31
			32



PART I
SURGICAL STRATEGIES

2

Diseases of the Esophagus; accepted for publication

International survey on esophageal cancer: Part I Surgical techniques

Judith Boone¹

Daan P. Livestro¹

Sjoerd G. Elias²

Inne H.M. Borel Rinkes¹

Richard van Hillegersberg¹

¹ Department of Surgery

² Julius Center for Health Sciences and Primary Care,
University Medical Center Utrecht

ABSTRACT**Background**

In patients with esophageal cancer, radical surgical resection of the esophagus and surrounding lymph nodes is the only curative treatment option. Nevertheless, no standard surgical procedure exists. The aims of the present study were to gain insight into the frequencies of the various surgical techniques in esophageal cancer surgery as applied by surgeons throughout the world and to identify intercontinental differences regarding surgical techniques.

Methods

Surgeons with particular interest in esophageal surgery, including members of the International Society for Diseases of the Esophagus (ISDE), the European Society of Esophagology Group d'Etude Européen des Maladies de l'Oesophage (ESE-GEEMO) and the OESO, were invited to participate in an online questionnaire. Questions were asked regarding approach to esophagectomy, extent of lymphadenectomy (LND), type of reconstruction and anastomotic techniques. Subanalyses were performed for surgeon's case volume per year, years of experience in esophageal cancer surgery and continent.

Results

Of 567 invited surgeons, 269 participated resulting in an overall response rate of 47%. The responders currently performing esophagectomies (n=250; 44%), represented 41 countries across the 6 continents. Fifty-two percent of responders favor open transthoracic esophagectomy (TTE) over transhiatal esophagectomy (THE) or minimally invasive esophagectomy (MIE). THE is preferred by 26%, whereas MIE is favored by 14%. Eight percent have no preference for one approach to esophagectomy over the other. The extent of LND is most frequently the 2-field, routinely performed by 73% of surgeons. The continuity of the digestive tract is most frequently restored with a gastric conduit (85%). In open TTE, the anastomosis is routinely created in the neck by 56% of responders and in the chest by 40%. Cervical anastomoses are routinely fashioned by means of a handsewn technique by 65% of responders, while 35% favor the stapled

technique. The cervical incision is predominantly performed vertically on the left side of the neck (routinely by 66%). A horizontal neck incision is routinely carried out by 19% of responders and a vertical right-sided incision by 11%. Significant differences in surgical techniques could be detected between low- and high-volume surgeons, between surgeons with ≤ 10 vs. ≥ 21 years of experience and between surgeons from different continents.

Conclusions

Currently, the most commonly applied surgical procedure is the open right-sided transthoracic approach with a two-field lymphadenectomy, using a gastric tube anastomosed at the left side of the neck by means of a handsewn, end-to-side technique. The results of this survey provide baseline data for future research and for the development of international guidelines.

_____	1
_____	2
2 _____	3
_____	4
_____	5
_____	6
_____	7
_____	8
_____	9
_____	10
_____	11
_____	12
_____	13
_____	14
_____	15
_____	16
_____	17
_____	18
_____	19
_____	20
_____	21
_____	22
_____	23
_____	24
_____	25
_____	26
_____	27
_____	28
_____	29
_____	30
_____	31
_____	32

INTRODUCTION

For patients with locoregional esophageal cancer there is general consensus that the best chance of cure is offered by radical resection of the esophagus and surrounding lymph nodes.^{1,2} Nevertheless, no standard surgical procedure exists for the type of approach, the extent of lymphadenectomy or the anastomotic technique.

Transthoracic esophagectomy (TTE) allows for en bloc resection of the esophagus and surrounding tissues such as the mediastinal lymph nodes, aiming at a radical resection to increase survival.^{3,4} Transhiatal esophagectomy (THE) is less extensive and therefore has the benefits of a relatively low blood loss, short surgery time and low complication rates.⁵ Controversy persists over which surgical approach is best as neither a randomized controlled trial nor a meta-analysis could detect a significant difference in overall survival between both procedures.^{3,6,7} To reduce postoperative morbidity, minimally invasive esophagectomy (MIE) using thoracoscopy and laparoscopy has been introduced.⁸⁻¹⁰ Long-term results of these techniques have to be awaited.

Due to the unique submucosal lymphatic drainage system of the esophagus,¹¹ lymph node metastases may be located in the abdominal, mediastinal or cervical region.^{12,13} Several studies have shown a significant survival benefit for patients having undergone a 3-field lymph node dissection (LND) compared to 2-field LND.¹⁴⁻¹⁸ However, these studies are non-randomized and therefore benefit of 3-field LND may be attributed to stage-migration.¹⁹ The optimal extent of LND still remains a matter of international debate.

The anastomosis between the substitute for the esophagus and the remaining esophageal segment can be created intrathoracically or in the neck.²⁰⁻²² Two recent randomized controlled trials have shown both procedures to be equally safe with comparable leakage and mortality rates.^{20,21} In addition, both the cervical and the intrathoracic anastomosis can be fashioned using a handsewn or a stapled technique in an "end-to-end", "end-to-side" or "side-to-side" manner,²³⁻²⁸ depending on the surgeon's experience and preference.

The objectives of the present study were to gain insight into the frequencies of the various surgical techniques applied in esophageal cancer surgery and to identify intercontinental differences. Since there has been a lot of interest recently in the effect of operation volume on the outcome of esophageal cancer surgery,²⁹⁻³² we have tried

to detect differences in surgical techniques between surgeons with different levels of experience in esophageal cancer surgery. This is the first survey on this topic published so far.

MATERIALS AND METHODS

Questionnaire

A web-based questionnaire (<http://www.esophagussurvey.com>) was designed in 2007 that addressed: (I) demographic data and surgical experience in esophageal cancer surgery; (II) pre-operative work-up of esophageal cancer patients; (III) techniques of esophageal cancer surgery; (IV) postoperative management and (V) additional commentaries. In this manuscript the results of parts I, III and IV will be presented. Answers to most questions could be given on a 3-point-scale: 'never-occasionally-routinely'. Sporadically, responders were asked to reply to questions by choosing from a multiple-choice list or by giving percentages. The answers from returned questionnaires were directly entered into an online database.

Invited physicians

Surgical members of the International Society for Diseases of the Esophagus (ISDE), the European Society of Esophagology - Group d'Etude Européen des Maladies de l'Oesophage (ESE-GEEMO) and the OESO were invited by electronic mail (e-mail) to participate in the questionnaire and received a link to the website, a personal login name and a password. Written permission was obtained from the Presidents of these societies in order to gain access to their membership databases and to contact their members. In addition, surgeons known from personal networks were requested to participate in the survey and responders were able to recommend colleagues in the field.

The first invitation was sent on July 23, 2007. Reminder e-mail notices were sent every 2 weeks to those who had not responded to the initial request. The survey was closed on October 23, 2007. A recipient was considered a 'non-responder' if no reply was received on this day. If the responder did not perform esophageal cancer surgery (by replying 'no' to the corresponding question), the questionnaire would end and no

1
2
3
4
5
6
7
8
9
10
11
12
13
14
15
16
17
18
19
20
21
22
23
24
25
26
27
28
29
30
31
32

- 1 —
- 2 —
- 3 —
- 4 —
- 5 —
- 6 —
- 7 —
- 8 —
- 9 —
- 10 —
- 11 —
- 12 —
- 13 —
- 14 —
- 15 —
- 16 —
- 17 —
- 18 —
- 19 —
- 20 —
- 21 —
- 22 —
- 23 —
- 24 —
- 25 —
- 26 —
- 27 —
- 28 —
- 29 —
- 30 —
- 31 —
- 32 —

2

further data were collected.

For comparing the surgical techniques of low-volume and high-volume surgeons, we defined low-volume surgeons as surgeons who performed ≤ 10 esophagectomies per year, medium-volume surgeons as surgeons who carried out 11-20 esophagectomies, and high-volume surgeons ≥ 21 . In addition, to reveal differences in surgical techniques between regular and senior surgeons, responders were divided into 3 groups according to the years of experience in esophageal cancer surgery: surgeons having performed esophagectomy for ≤ 10 years, 11-20 years or ≥ 21 years.

Statistical analysis

All data were analyzed anonymously. Statistical analysis was performed when appropriate, using SPSS (Version 12.0, for Windows). Surgical approaches, extent of lymphadenectomy, anastomotic techniques and other elements of esophageal cancer surgery were compared with regard to surgeon's case volume, years of experience and continent. Percentages were rounded to the nearest integer and as a consequence the sum of percentages may not equal 100%. For comparison of data between continents, the continents South-America, Oceania and Africa were excluded since they each had less than 5% (n=13) of the total amount of responders.

RESULTS

Characteristics of Responders

Of 567 invited physicians, 269 participated in the questionnaire resulting in an overall response rate of 47%. Nineteen (7%) responders indicated not to actively practice esophageal cancer surgery. The remaining 250 responders (specific response rate 44%) formed the basis for all further analysis. They represented 41 countries across the 6 continents (Table 1). Due to a technical failure of the website, 5 of 250 responders were not able to answer all questions of part II. Consequently, the total amount of responders to those questions could vary between 245 -250.

Of the 250 responders, 159 (64%) were member of the ISDE, 36 (14%) were member of more than 1 esophageal society, 21 (8%) were ESE member, 33 (13%) were known from

personal networks and 1 was referred by a colleague. An overview of the responders' function, case volume per year and years of experience is given in Table 2. Twenty-four percent of responders were low-volume, 31% medium-volume and 45% high-volume esophageal cancer surgeons.

North-American responders were mainly medium- (36%) and high-volume (55%) surgeons, while Asian responders were predominantly high-volume (65%). European responders were equally distributed over the 3 categories. Surgeons with ≥ 11 years of experience were predominantly high-volume surgeons (48%), whereas surgeons with ≤ 10 years of experience were equally distributed over the 3 categories.

Table 1 - Specific response rates per continent and country

Country	Invited, n	Participated*, n	Specific Response Rate, %
Europe:	253	125	49
The Netherlands	34	31	91
Italy	50	21	42
Spain	23	12	52
United Kingdom	21	10	48
Germany	18	6	33
Belgium	11	5	45
France	20	5	25
Greece	10	4	40
Sweden	7	4	57
Finland	5	4	80
Asia:	181	51	28
Japan	134	30	22
Korea	10	6	60
India	8	5	63
China	12	4	33
North America:	73	42	58
USA	63	37	59
Canada	10	5	50
South America:	36	18	50
Brazil	20	11	55
Oceania:	21	12	57
Australia	20	12	60
Africa	3	2	67
Overall	567	250	44

*Countries with 3 or less responders include: Portugal (3), Austria (3), Hungary (3), Czech Republic (2), Poland (2), Serbia (2), Turkey (2), Israel (2), Taiwan (2), Mexico (2), Argentina (2), Chile (2), Ireland (1), Slovenia (1), Romania (1), Croatia (1), Norway (1), Switzerland (1), Saudi Arabia (1), Thailand (1), Uruguay (1), Sudan (1), South Africa (1)

Table 2 - Overview of the function, personal esophagectomy case volume per year and years of experience in esophageal cancer surgery of the 250 surgical responders.

	n	%
Function		
Fellow	10	4
Senior staff	49	20
Regular staff	188	75
Other	3	1
Personal case volume/year		
<11	59	24
11 – 20	79	32
21 – 30	53	21
31 – 40	27	11
41 – 50	10	4
51 – 60	4	2
>60	18	7
Years of experience		
<6	30	12
6 – 10	49	20
11 – 15	49	20
16 – 20	51	20
21 – 25	41	16
26 – 30	18	7
>30	12	5
Overall	250	44

Surgical approaches

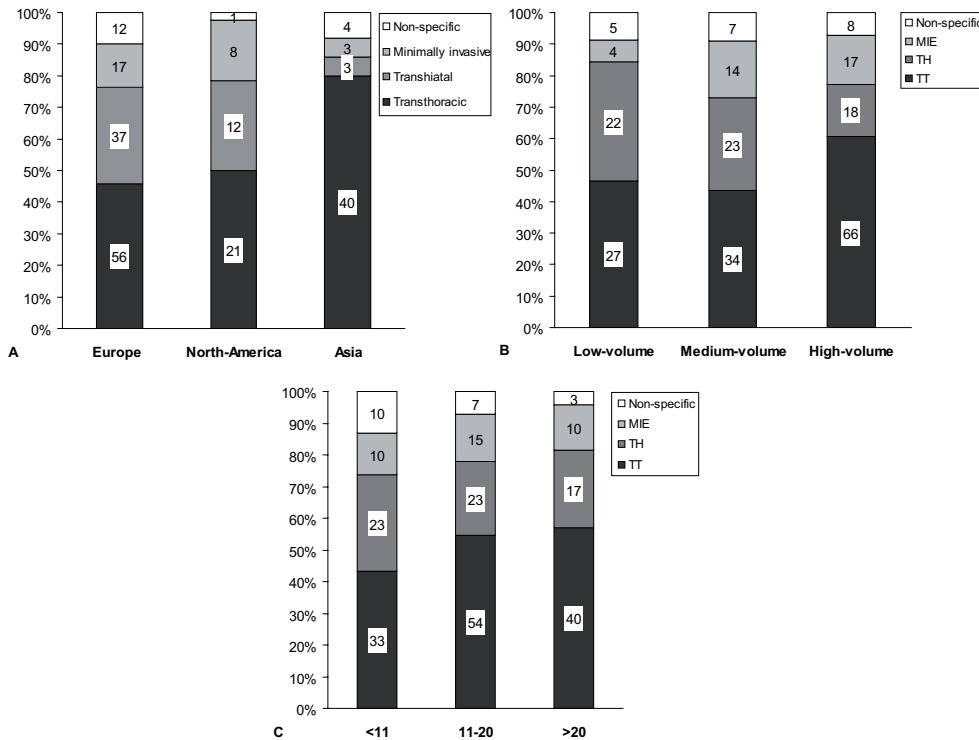
Fifty-two percent (n=127) of responders predominantly use open TTE. THE is preferred by 26% (n=63) of responders, while MIE is favored by 14% (n=35). Eight percent (n=20) have no preference for one approach over the other. TTE is the most commonly applied procedure in all 3 continents (Figure 1a). With increasing experience, the routine use of TTE rises and that of THE declines (Figure 1b and 1c). Twenty responders (8%) indicated never to perform TTE. The transhiatal approach is never used by 25% of responders, while 60% never treat their patients by MIE. In case of open transthoracic esophagectomy, a right-sided thoracotomy is routinely performed by 91% of surgeons, while 8% routinely perform a left-sided thoracotomy.

Forty percent of responders apply minimally invasive techniques in esophageal cancer surgery. In Figure 2, an overview is given of the application of MIE with regard to surgeon's experience and continent. When performing MIE, 34% of surgeons routinely use laparoscopy. The thoracoscopic and thoracolaparoscopic approaches are both routinely applied by 26% of surgeons. Low-volume surgeons performing MIE favor the

laparoscopic approach (routinely done by 43%), whereas high-volume surgeons use the thoracoscopic, laparoscopic and thoracoscopic approaches in equal frequency (routinely performed by 30%).

- 1
- 2
- 3
- 4
- 5
- 6
- 7
- 8
- 9
- 10
- 11
- 12
- 13
- 14
- 15
- 16
- 17
- 18
- 19
- 20
- 21
- 22
- 23
- 24
- 25
- 26
- 27
- 28
- 29
- 30
- 31
- 32

Figure 1 - Favored approach to esophagectomy according to (A) continent, (B) case volume per year and (C) years of esophageal cancer surgery experience. Values within bars represent number of responders.



TH: transhiatal esophagectomy; TT: transthoracic esophagectomy; MIE: minimally invasive esophagectomy

Lymphadenectomy

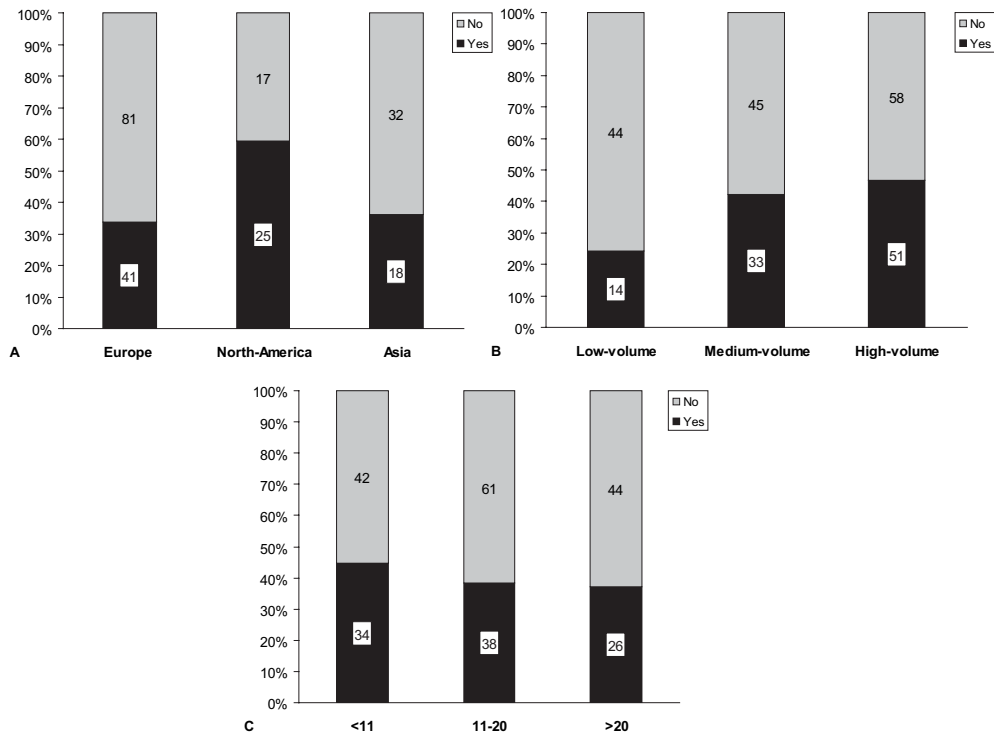
The extent of LND is most frequently the 2-field LND (Figure 3). Low-, medium- and high-volume surgeons all perform the 2-field LND most (routinely applied by 66%, 77% and 73%, respectively). Three-field LND was routinely carried out more by high-volume surgeons than low-volume surgeons (21% and 9% respectively). Comparably, surgeons with ≥ 21 years of experience are more likely to routinely execute the 3-field

- 1
- 2
- 3
- 4
- 5
- 6
- 7
- 8
- 9
- 10
- 11
- 12
- 13
- 14
- 15
- 16
- 17
- 18
- 19
- 20
- 21
- 22
- 23
- 24
- 25
- 26
- 27
- 28
- 29
- 30
- 31
- 32

2

LND than surgeons with ≤ 10 years of experience (17% and 9% respectively). North-American and European responders favor the 2-field LND (routinely performed by 86% and 79%), while Asian responders carry out the 2-field and the 3-field LND in equal frequency (both routinely performed by 49%).

Figure 2 - Overview of the application of minimally invasive esophagectomy, according to (A) continent, (B) case volume per year and (C) years of esophageal cancer surgery experience.

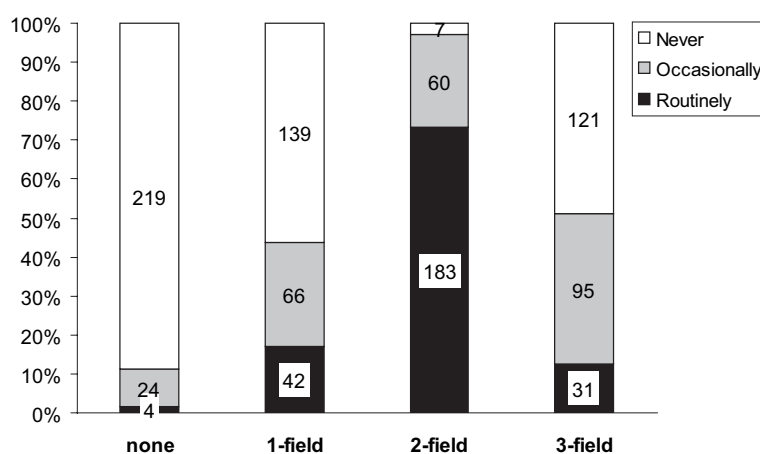


Type of reconstruction

The preferred type of reconstruction is shown in Figure 4. The gastric tube is routinely applied by 90% of European, 80% of Asian and 79% of North-American surgeons. Asian and North-American responders routinely perform a whole stomach reconstruction more often than European responders (22% and 21% vs. 11%, respectively). Surgeons with ≥ 21 years of experience routinely use the whole stomach more often than surgeons with ≤ 10 years of experience (21% vs. 10% respectively).

The gastric conduit's linear staple line is routinely oversewn by 77% of responders, occasionally by 11% and never by 13%. Of surgeons with ≥ 21 years of experience 66% routinely oversew the staple line, compared to 81% of surgeons with ≤ 10 years of experience. In addition, 62% of North-American responders routinely oversew compared to 79% of European and 82% of Asian responders.

Figure 3 - Extent of lymph node dissection as currently applied by the responders. Values within bars represent number of responders.



Anastomotic techniques

In open TTE, the anastomosis is routinely created in the neck by 56% of responders and in the chest by 40%. In the thoracoscopic approach the cervical anastomosis is favored over the intrathoracic anastomosis (routinely performed by 87% and 8%, respectively). During open TTE, Asian responders routinely perform a cervical anastomosis more routinely than an intrathoracic anastomosis (Figure 5), while no preference for either was seen among European responders. No substantial differences could be detected between more experienced and less experienced surgeons.

During TTE the cervical incision is predominantly performed vertically on the left side of the neck (routinely by 66%). A horizontal neck incision is routinely carried out by 19% and a vertical right-sided incision by 11%. Half of Asian responders routinely perform a horizontal incision and 39% a vertical left-sided incision. On the contrary, the European

- 1
- 2
- 3
- 4
- 5
- 6
- 7
- 8
- 9
- 10
- 11
- 12
- 13
- 14
- 15
- 16
- 17
- 18
- 19
- 20
- 21
- 22
- 23
- 24
- 25
- 26
- 27
- 28
- 29
- 30
- 31
- 32

and North-American responders predominantly use the left-sided approach (routinely performed by 76% and 75%, respectively).

Cervical anastomoses are more frequently fashioned by means of a handsewn technique than by a stapled technique (routinely performed by 65% vs. 35%, respectively). In Europe, the handsewn method (routinely used by 77%) is preferred, whereas in North-America the stapled method is favored (routinely used by 69%). Asian responders routinely perform both techniques in equal frequencies (50%). Low-volume surgeons routinely use the stapled method less often than do high-volume surgeons (26% vs. 42%, respectively).

Conversely, in case of intrathoracic anastomoses the stapled technique is favored over the handsewn method (routinely applied by 62% and 34%, respectively). Asian surgeons routinely perform the stapled technique more often than North-American and European (79% vs. 69% and 54%, respectively). High-volume surgeons routinely apply the stapled method more often than low-volume surgeons (75% vs. 55%, respectively).

In both cervical and intrathoracic anastomoses the end-to-side anastomotic technique is applied most often (routinely used by 50% and 64% respectively), followed by the end-to-end (33% and 24%, respectively) and the side-to-side (14% and 8%, respectively) techniques. In Asia and Europe, the cervical anastomosis is most frequently performed in an end-to-side manner (52% and 51%, respectively), whereas in North-America the side-to-side and end-to-side methods are preferred (both routinely used by 43% of responders). In intrathoracic anastomoses, all continents routinely use the end-to-side technique most often (Asia 69%, Europe 63% and North-America 57%).

Other elements of esophageal cancer surgery

A pyloroplasty is routinely performed by 40% of responders, whereas it is never done by 38%. Sixty-two percent of North-American responders routinely perform a pyloroplasty, compared to 34% of European and 24% of Asian. Surgeons having performed esophagectomy for ≥ 21 years routinely perform a pyloroplasty more often than surgeons with ≤ 10 years of experience (47% and 32%, respectively).

Clinical presence of tumor invasion into the pleurae or the crurae of the diaphragm is a contraindication for esophagectomy for 21% of responders, while 26% routinely

surgically treat these patients. High-volume surgeons (32%) routinely treat these patients more often than low-volume surgeons (17%). Asian responders (39%) routinely operate these patients more often than North-American (26%) or European (24%) responders. Patients with clinical evidence of M1a lymph node metastases are not surgically treated by 28% of responders. In contrast, 51% of responders occasionally operate these patients, while 21% do so routinely. High-volume surgeons (29%) routinely operate on these patients more often than low- (15%) and medium-volume (14%) surgeons.

- 1
- 2
- 3
- 4
- 5
- 6
- 7
- 8
- 9
- 10
- 11
- 12
- 13
- 14
- 15
- 16
- 17
- 18
- 19
- 20
- 21
- 22
- 23
- 24
- 25
- 26
- 27
- 28
- 29
- 30
- 31
- 32

Figure 4 - Type of reconstruction used after esophagectomy. Values within bars represent number of responders.

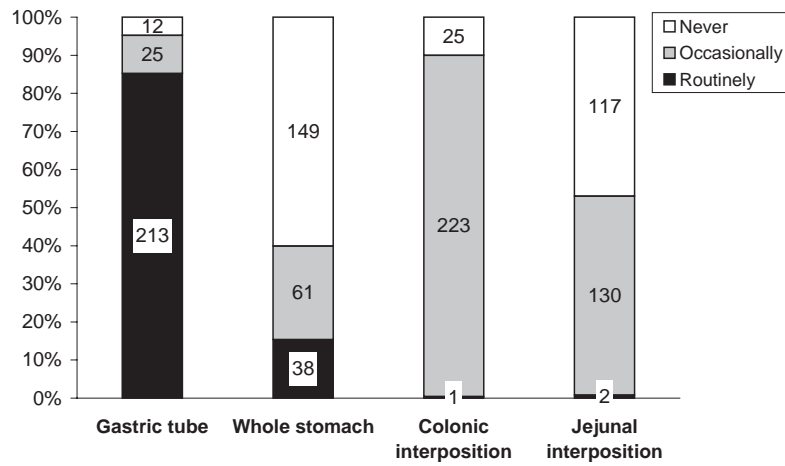
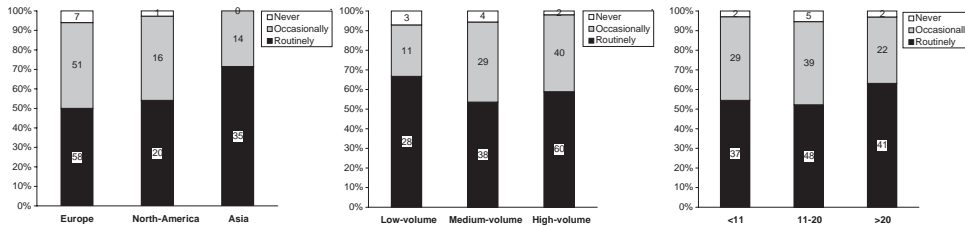
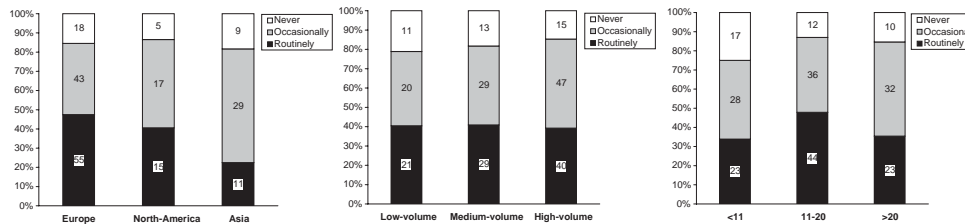


Figure 5 - Frequency of the application of cervical and intrathoracic anastomoses with regard to surgeons' experience in esophageal cancer surgery and nationality. Values within bars represent number of responders.

Cervical Anastomosis



Intrathoracic Anastomosis



DISCUSSION

In esophageal cancer surgery various techniques are being used for esophagectomy, lymphadenectomy and for constructing the anastomosis.^{2,19,33} The findings of this survey provide a comprehensive insight into the frequencies of these techniques as applied in esophageal cancer surgery by surgeons worldwide.

Extended TTE is the most commonly used approach in all continents, particularly in Asia. The higher application of TTE in Asia may be a reflection of this continent's higher incidence rate of esophageal squamous cell carcinomas, which are often located in the mid/upper part of the esophagus.^{34,35} With growing experience the use of TTE increases while that of THE decreases, even when excluding the Asian responders (data not shown). This may indicate that patients with advanced or mid/upper esophageal tumors requiring TTE are being referred to surgeons in tertiary referral centers with particular experience in esophageal cancer surgery. In addition, it may reflect that surgeons having performed esophagectomy for ≥ 21 years were taught TTE in the time THE was just in early development and they nowadays still associate most with the extended TTE.

Consistent with the preference for TTE, the results of this survey show that 2-field LND is nowadays the most commonly applied extent of LND. This is in line with the long-term results of a randomized study on TTE and THE in which a trend towards an overall survival benefit was noticed in patients having undergone TTE.⁶ A 3-field LND was routinely performed by only 13% of responders, predominantly Asian.

Minimally invasive techniques have emerged to reduce the morbidity associated with esophagectomy.^{8-10,36} Various studies on MIE have shown a substantial lower blood loss, pulmonary complication rate and hospital stay compared to open approaches.^{8-10,36} Our survey reveals that MIE is now applied by 40% of responders.

The anastomosis between the substitute of the esophagus and the remaining proximal esophagus can be located in the neck or in the chest.^{21,22} Several randomized trials have shown both techniques to be equally safe with comparable morbidity.²⁰⁻²² The results of this survey show that during open TTE a cervical anastomosis is applied more often than an intrathoracic anastomosis, except for European responders, who have no clear preference. Both cervical and intrathoracic anastomoses can be made using a stapler instrument or by hand.^{26,28} A meta-analysis could not detect a significant difference in the incidence of anastomotic stenosis or leakage between both techniques.²⁸ The responders to our survey prefer the handsewn technique for cervical anastomoses and the stapled technique for intrathoracic anastomoses.

As with all questionnaires, the answers of the responders of our survey may not reflect the views of all surgeons.³⁷ However, with a specific response rate of 44%, predominantly from members of prominent esophageal societies from various countries, our results are likely to be representative for the current practice of esophageal cancer surgery. Compared to the response rate of North-America (58%) and Europe (49%), that of Japan was relatively low (22%). Nevertheless, 20% of the total amount of responders was Asian which provides an acceptable impression of the techniques applied in this continent.

In our subanalyses it was noted that the surgeon's case volume is related to the continent the surgeon is from, reflecting the global differences in incidence rates of esophageal cancer and in organization of medical care.³⁸ These geographical disparities in experience may have influenced the comparison of the surgical techniques of high- and low-volume surgeons. Although in the present literature esophageal surgeons are

1
2
3
4
5
6
7
8
9
10
11
12
13
14
15
16
17
18
19
20
21
22
23
24
25
26
27
28
29
30
31
32

considered high-volume surgeons when they perform more than 5 cases annually,^{39,40} we have chosen to use higher cut-off values, since our baseline table showed that 76% of responders perform even more than 10 esophagectomies yearly.

In conclusion, this international survey among surgeons with particular interest in esophageal cancer surgery reveals that the most frequently used technique is open TTE with a 2-field LND and a handsewn, end-to-side anastomosis located on the left side of the neck. Moreover, the techniques applied in esophageal cancer surgery have shown to depend on the surgeon's experience and nationality. This data may be used as a basis for future trials comparing the various techniques, aiming to identify the most optimal combination for surgical treatment. In addition, the results of this study may help to formulate guidelines on these subjects. It should be worthwhile to repeat this survey within several years to detect possible changes in techniques over time.

ACKNOWLEDGEMENTS

The authors would like to thank all responders for their appreciated participation in the survey and for sharing their expertise in the field of esophageal cancer treatment. We would like to express special gratitude to Professor Kahrilas and Professor DeMeester from the International Society for Diseases of the Esophagus (ISDE), Professor Lundell and Professor Zaninotto from the European Society of Esophagology - Group d'Etude Européen des Maladies de l'Oesophage (ESE-GEEMO) and Professor Giuli from the OESO for providing access to their membership databases.

REFERENCES

1. Mariette C, Piessen G, Triboulet JP. Therapeutic strategies in oesophageal carcinoma: role of surgery and other modalities. *Lancet Oncol* 2007; 8:545-553.
2. DeMeester SR. Adenocarcinoma of the Esophagus and Cardia: A Review of the Disease and Its Treatment. *Ann Surg Oncol* 2006; 13:12-30.
3. Hulscher JBF, van Sandick JW, de Boer AGEM et al. Extended Transthoracic Resection Compared with Limited Transhiatal Resection for Adenocarcinoma of the Esophagus. *N Engl J Med* 2002; 347:1662-1669.
4. Skinner DB. Esophageal malignancies. Experience with 110 cases. *Surg Clin North Am* 1976; 56:137-147.
5. Orringer MB, Marshall B, Chang AC, Lee J, Pickens A, Lau CL. Two thousand transhiatal esophagectomies: changing trends, lessons learned. *Ann Surg* 2007; 246:363-372.
6. Omloo JM, Lagarde SM, Hulscher JB et al. Extended Transthoracic Resection Compared With Limited Transhiatal Resection for Adenocarcinoma of the Mid/Distal Esophagus: Five-Year Survival of a Randomized Clinical Trial. *Ann Surg* 2007; 246:992-1001.
7. Hulscher JB, Tijssen JG, Obertop H, van Lanschot JJ. Transthoracic versus transhiatal resection for carcinoma of the esophagus: a meta-analysis. *Ann Thorac Surg* 2001; 72:306-313.
8. Luketich JD, Alvelo-Rivera M, Buenaventura PO et al. Minimally invasive esophagectomy: outcomes in 222 patients. *Ann Surg* 2003; 238:486-494.
9. Gemmill EH and McCulloch P. Systematic review of minimally invasive resection for gastro-oesophageal cancer. *Br J Surg* 2007; 94:1461-1467.
10. Law S. Minimally invasive techniques for oesophageal cancer surgery. *Best Pract Res Clin Gastroenterol* 2006; 20:925-940.
11. Zuidema GD, Yeo CJ. *Surgery of the Alimentary Tract*, fifth Edition. Philadelphia: W.B. Saunders, 2002.
12. Li H, Zhang Y, Cai H, Xiang J. Pattern of lymph node metastases in patients with squamous cell carcinoma of the thoracic esophagus who underwent three-field lymphadenectomy. *Eur Surg Res* 2007; 39:1-6.
13. van de Ven C, De Leyn P, Coosemans W, Van Raemdonck D, Lerut T. Three-field lymphadenectomy and pattern of lymph node spread in T3 adenocarcinoma of the distal esophagus and the gastro-esophageal junction. *Eur J Cardiothorac Surg* 1999; 15:769-773.
14. Isono K, Sato H, Nakayama K. Results of a nationwide study on the three-field lymph node dissection of esophageal cancer. *Oncology* 1991; 48:411-420.

15. Kato H, Watanabe H, Tachimori Y, Iizuka T. Evaluation of neck lymph node dissection for thoracic esophageal carcinoma. *Ann Thorac Surg* 1991; 51:931-935.
16. Lerut T, Naftoux P, Moons J et al. Three-field lymphadenectomy for carcinoma of the esophagus and gastroesophageal junction in 174 R0 resections: impact on staging, disease-free survival, and outcome: a plea for adaptation of TNM classification in upper-half esophageal carcinoma. *Ann Surg* 2004; 240:962-972.
17. Altorki N, Kent M, Ferrara C, Port J. Three-field lymph node dissection for squamous cell and adenocarcinoma of the esophagus. *Ann Surg* 2002; 236:177-183.
18. Baba M, Aikou T, Yoshinaka H et al. Long-term results of subtotal esophagectomy with three-field lymphadenectomy for carcinoma of the thoracic esophagus. *Ann Surg* 1994; 219:310-316.
19. Law S and Wong J. Current management of esophageal cancer. *J Gastrointest Surg* 2005; 9:291-310.
20. Okuyama M, Motoyama S, Suzuki H, Saito R, Maruyama K, Ogawa J. Hand-sewn cervical anastomosis versus stapled intrathoracic anastomosis after esophagectomy for middle or lower thoracic esophageal cancer: a prospective randomized controlled study. *Surg Today* 2007; 37:947-952.
21. Walther B, Johansson J, Johnsson F, Von Holstein CS, Zilling T. Cervical or thoracic anastomosis after esophageal resection and gastric tube reconstruction: a prospective randomized trial comparing sutured neck anastomosis with stapled intrathoracic anastomosis. *Ann Surg* 2003; 238:803-812.
22. Blewett CJ, Miller JD, Young JE, Bennett WF, Urschel JD. Anastomotic leaks after esophagectomy for esophageal cancer: a comparison of thoracic and cervical anastomoses. *Ann Thorac Cardiovasc Surg* 2001; 7:75-78.
23. Raz DJ, Tedesco P, Herbella FA, Nipomnick I, Way LW, Patti MG. Side-to-side stapled intra-thoracic esophagogastric anastomosis reduces the incidence of leaks and stenosis. *Dis Esophagus* 2008; 21:69-72.
24. Behzadi A, Nichols FC, Cassivi SD, Deschamps C, Allen MS, Pairolero PC. Esophagogastrectomy: the influence of stapled versus hand-sewn anastomosis on outcome. *J Gastrointest Surg* 2005; 9:1031-1040.
25. Hsu HH, Chen JS, Huang PM, Lee JM, Lee YC. Comparison of manual and mechanical cervical esophagogastric anastomosis after esophageal resection for squamous cell carcinoma: a prospective randomized controlled trial. *Eur J Cardiothorac Surg* 2004; 25:1097-1101.
26. Laterza E, de Manzoni G, Veraldi GF, Guglielmi A, Tedesco P, Cordiano C. Manual compared with mechanical cervical oesophagogastric anastomosis: a randomised trial. *Eur J Surg* 1999; 165:1051-1054.

- | | | |
|-----|---|----|
| 27. | Singh D, Maley RH, Santucci T et al. Experience and technique of stapled mechanical cervical esophagogastric anastomosis. <i>Ann Thorac Surg</i> 2001; 71:419-424. | 1 |
| 28. | Urschel JD, Blewett CJ, Bennett WF, Miller JD, Young JE. Handsewn or stapled esophagogastric anastomoses after esophagectomy for cancer: meta-analysis of randomized controlled trials. <i>Dis Esophagus</i> 2001; 14:212-217. | 2 |
| 29. | Swisher SG, Deford L, Merriman KW et al. Effect of operative volume on morbidity, mortality, and hospital use after esophagectomy for cancer. <i>J Thorac Cardiovasc Surg</i> 2000; 119:1126-1132. | 3 |
| 30. | Wouters MW, Wijnhoven BP, Karim-Kos HE et al. High-volume versus low-volume for esophageal resections for cancer: the essential role of case-mix adjustments based on clinical data. <i>Ann Surg Oncol</i> 2008; 15:80-87. | 4 |
| 31. | van Lanschot JJ, Hulscher JB, Buskens CJ, Tilanus HW, ten Kate FJ, Obertop H. Hospital volume and hospital mortality for esophagectomy. <i>Cancer</i> 2001; 91:1574-1578. | 5 |
| 32. | Dimick JB, Cattaneo SM, Lipsett PA, Pronovost PJ, Heitmiller RF. Hospital volume is related to clinical and economic outcomes of esophageal resection in Maryland. <i>Ann Thorac Surg</i> 2001; 72:334-339. | 6 |
| 33. | Tytgat GN, Bartelink H, Bernards R et al. Cancer of the esophagus and gastric cardia: recent advances. <i>Dis Esophagus</i> 2004; 17:10-26. | 7 |
| 34. | Shigeoka H and Shiozaki H. Surgery for resectable esophageal cancer in Japan. <i>Ann Thorac Cardiovasc Surg</i> 2004; 10:69-70. | 8 |
| 35. | Pera M, Manterola C, Vidal O, Grande L. Epidemiology of esophageal adenocarcinoma. <i>J Surg Oncol</i> 2005; 92:151-159. | 9 |
| 36. | Nguyen NT, Gelfand D, Stevens CM et al. Current status of minimally invasive esophagectomy. <i>Minerva Chir</i> 2004; 59:437-446. | 10 |
| 37. | Couper M. Web surveys: a review of issues and approaches. <i>Public Opin Q</i> 2000; 64:464-494. | 11 |
| 38. | Kamangar F, Dores GM, Anderson WF. Patterns of cancer incidence, mortality, and prevalence across five continents: defining priorities to reduce cancer disparities in different geographic regions of the world. <i>J Clin Oncol</i> 2006; 24:2137-2150. | 12 |
| 39. | Migliore M, Choong CK, Lim E, Goldsmith KA, Ritchie A, Wells FC. A surgeon's case volume of oesophagectomy for cancer strongly influences the operative mortality rate. <i>Eur J Cardiothorac Surg</i> 2007; 32:375-380. | 13 |
| 40. | Dimick JB, Goodney PP, Orringer MB, Birkmeyer JD. Specialty training and mortality after esophageal cancer resection. <i>Ann Thorac Surg</i> 2005; 80:282-286. | 14 |
| | | 15 |
| | | 16 |
| | | 17 |
| | | 18 |
| | | 19 |
| | | 20 |
| | | 21 |
| | | 22 |
| | | 23 |
| | | 24 |
| | | 25 |
| | | 26 |
| | | 27 |
| | | 28 |
| | | 29 |
| | | 30 |
| | | 31 |
| | | 32 |

3

Surgical Endoscopy 2006; 20:1435-9

**First experience with robot-assisted
thoracoscopic esophagolymphadenectomy
for esophageal cancer**

Richard van Hillegersberg¹
Judith Boone¹
Werner A. Draaisma¹
Ivo A.M.J. Broeders¹
Maurice J.M.M. Giezeman²
Inne H.M. Borel Rinkes¹

Departments of ¹Surgery and ²Anaesthesiology,
University Medical Center Utrecht

ABSTRACT

Background

Transthoracic esophagectomy with extended lymph node dissection is associated with higher morbidity rates than transhiatal esophagectomy. This morbidity rate could be reduced by the use of minimally invasive techniques. The feasibility of robot-assisted thoracoscopic esophagectomy (RTE) with mediastinal lymphadenectomy was assessed prospectively.

Methods

This study investigated 21 consecutive patients with esophageal cancer who underwent RTE using the Da Vinci® robotic system. Continuity was restored with a gastric conduit and a cervical anastomosis.

Results

A total of 18 (86%) procedures were completed thoracoscopically. The operating time for the thoracoscopic phase was 180 min (range, 120–240 min), and the median blood loss was 400 ml (range, 150–700 ml). A median of 20 (range, 9–30) lymph nodes were retrieved. The median intensive care unit stay was 4 days (range, 1–129 days), and the hospital stay was 18 days (range, 11–182 days). Pulmonary complications occurred in 10 patients (48%), and one patient (5%) died of a tracheo-neo-esophageal fistula.

Conclusions

In this initial experience, robot-assisted thoracoscopic esophagectomy was found to be feasible, providing an effective lymphadenectomy with low blood loss. Standardization of the technique and increased experience should reduce the complication rate, which is in the range of the rate for open transthoracic dissection.

INTRODUCTION

In esophageal cancer, extended transthoracic resection offers the best chance for complete tumor clearance and long-term survival.¹ A trend towards a 5-year survival benefit (37% vs 27%) has been demonstrated for the transthoracic approach compared to the transhiatal technique.² However, morbidity associated with the open transthoracic esophago-lymphadenectomy is considerably higher. This is mainly caused by a higher number of pulmonary complications (57 vs 27%), reflected by a longer duration of mechanical ventilation and longer ICU and hospital stay.²

Since minimally invasive surgery induces less surgical trauma and immunological stress, it may potentially reduce the postoperative complication rate.³ Various approaches have been investigated, each with their specific technical advantages and difficulties.⁴⁻⁶ In general, minimally invasive esophagectomy is a feasible, but technically demanding procedure.⁷ The advantages reported so far are a substantially reduced blood loss, and shorter ICU and hospital stays.⁸

Robot-assisted minimally invasive surgery allows for precise dissection and manipulation in a confined operating space.^{9,10} As a result, this technology may aid to perform a thoroscopic extended mediastinal lymphadenectomy. In this study we describe the first series of robot-assisted thoroscopic esophago-lymphadenectomy.

MATERIALS AND METHODS

Patients

Between October 2003 and January 2005, patients with esophageal cancer, potentially resectable at diagnostic work-up, were included to undergo robot-assisted thoroscopic esophago-lymphadenectomy. Patients with significant pulmonary comorbidity were excluded from this study and underwent conventional transhiatal esophageal resection. The preoperative diagnostic work-up consisted of endoscopy with biopsy and histological examination, endoscopic ultrasonography (EUS) (with indicated fine needle aspiration (FNA)), computed tomography of thorax and abdomen, ultrasonography of the neck (with indicated FNA) to preclude M1b metastases, bronchoscopy in case of suspected

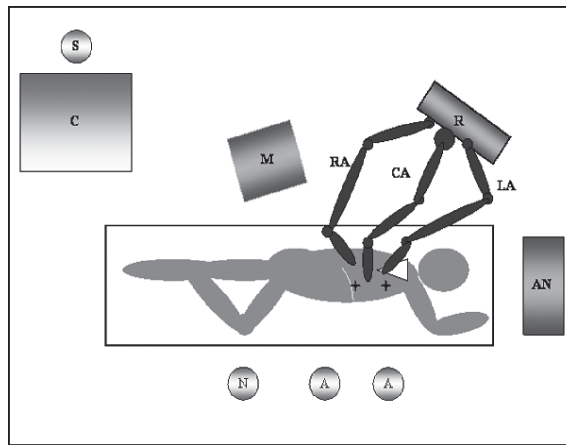
1
2
3
4
5
6
7
8
9
10
11
12
13
14
15
16
17
18
19
20
21
22
23
24
25
26
27
28
29
30
31
32

ingrowth in the upper airway determined by computed tomography of thorax or by endosonography and pulmonary function test. Indications for operation were similar as those for open surgery. Neoadjuvant chemotherapy (5-FU, cisplatin) was given in case of endoscopically and cytologically proven M1a lymph node metastases around the celiac axis to enhance the probability of curative resection. All patients were followed in the outpatient clinic at 3-4 months intervals.

Operative technique

The optimal thoracic port positions were first tested in a laboratory setting on human cadavers. To reach the entire mediastinum from diaphragm to thoracic aperture, a cranial position of the robot was found to be optimal, with ports in triangular formation (Figure 1).

Figure 1 - Set-up and positioning of the operating team in robot-assisted thoracoscopic esophago-lymphadenectomy.



R: robotic cart; RA: right robotic instrument arm in the 8th intercostal space; LA: left robotic instrument arm in the 4th intercostal space anterior to the scapular rim; CA: camera arm in the 6th intercostal space; Asterix: thoracic assisting ports in the 5th and 7th intercostal spaces; M: video cart (with monitor, insufflator, ultrasonic generator, light source, camera unit and focus control and synchronizer); AN: anaesthetic equipment; A: assistant; N: scrub nurse; C: robotic console; S: surgeon.

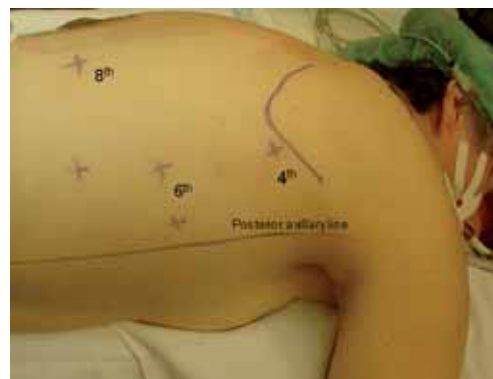The newly developed thoracoscopic procedure was initially combined with open abdominal dissection of the stomach to create the gastric conduit and to perform a celiac lymph node dissection. After the first 16 cases, the learning curve for this

procedure had stabilised and it was decided to perform a complete minimally invasive procedure. The laparoscopic abdominal phase was performed without robot assistance as initial experimental studies revealed that large ranges of the robotic arms would limit the use of the robotic system in this part of the procedure.

All minimally invasive parts of the surgical procedure were performed by the same experienced laparoscopic surgeon (RvH). There were 2 surgical assistants. General anaesthesia was combined with thoracic epidural anaesthesia to minimize intra-operative and postoperative pain.

The patient was intubated with a left-sided double-lumen tube and positioned in the left lateral decubitus position, 45° tilted towards prone position. In this position, the right lung is out of the operating field without retraction following desufflation. The robot was positioned on the dorso-cranial side and 2 assistants were on the anterior side. Three robotic ports were placed identically in all patients. A 10 mm camera port was placed at the 6th intercostal space, posterior to the posterior axillary line. Two 8 mm ports were placed just anteriorly to the scapular rim in the 4th intercostal space and more posteriorly in the 8th intercostal space. Two thoracoscopic ports were used in the 5th and 7th intercostal spaces, just posterior to the posterior axillary line. These ports were used for conventional thoracoscopic assistance, such as suction, traction and clipping (Figure 2).

Figure 2 - Thoracoscopic port placement in a patient positioned in the left lateral decubitus position, 45° tilted towards prone position. The 12 mm camera trocar is in the 6th intercostal space, the right robotic 8 mm trocar in the 8th intercostal space, the left robotic 8 mm trocar in the 4th intercostal space anterior to the scapular rim. The two thoracic assisting ports in the 5th and 7th intercostal spaces are also indicated. (see page 293 for color figure)



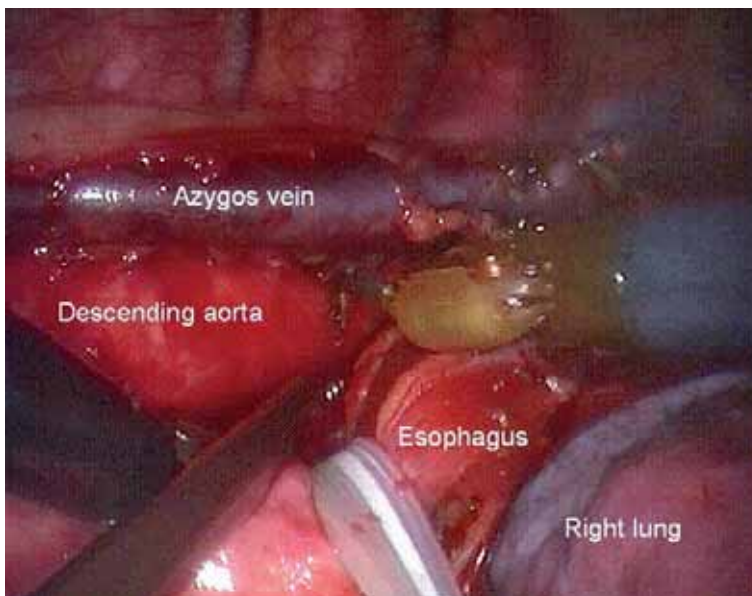
- 1
- 2
- 3
- 4
- 5
- 6
- 7
- 8
- 9
- 10
- 11
- 12
- 13
- 14
- 15
- 16
- 17
- 18
- 19
- 20
- 21
- 22
- 23
- 24
- 25
- 26
- 27
- 28
- 29
- 30
- 31
- 32

3

After division of the pulmonary ligament, the parietal pleura was divided at the anterior side up to the level of the azygos vein. The azygos vein was ligated with sutures and clips. The mediastinal pleura above the azygos vein was preserved and lifted upwards for the paratracheal lymph node dissection.

Then the parietal pleura was divided at the posterior side along the azygos vein and thoracic duct. The thoracic duct was clipped at the level of the diaphragm to prevent leakage. The tumor and adjacent lymph nodes were dissected en bloc, with clipping of the aorto-esophageal vessels. The right vagal nerve was identified and dissected below the level of the carina. A penrose drain was placed around the esophagus to facilitate traction (Figure 3).

Figure 3 - Thoracoscopic monitor view halfway the mediastinal dissection. A penrose drain around the esophagus is used to retract the esophagus anteriorly. The cautery hook instrument is held between aorta and esophagus; the suction device at the left. The descending aorta, just after the aortic arch, has been cleared from the adjacent lymphatic tissue en bloc with the esophagus (see page 293 for color figure).



In this way the entire thoracic esophagus was mobilized from the thoracic inlet to the diaphragmatic reflections. Finally, a subcarinal lymph node dissection was performed. The specimen included the lower and middle mediastinal, subcarinal and right-sided paratracheal nodes. The aortopulmonary window nodes were dissected separately. A

24-F chest tube was placed and the lung insufflated under direct vision. The patient was then put in supine position.

Through a midline laparotomy, the greater and lesser curvature were dissected and a 3-4 cm wide gastric tube was constructed with staplers. The left gastric artery and vein were then transected at its origin, with concomitant resection of local lymph nodes. A feeding jejunostomy was installed in first jejunal loop after Treitz ligament. The cervical esophagus was mobilized through a right-sided longitudinal neck incision. A hand sewn end-to-side esophagogastrostomy was performed in the neck using one layer PDS 3/0 running sutures.

In case of laparoscopic abdominal phase, the cervical esophageal transection was performed first. Five abdominal ports were used. An 11 mm camera port was introduced supra-umbilical, an 11 mm working port was placed at the left midclavicular line at the umbilical level. A 5 mm working port was placed more cranially at the right midclavicular line. A 5 mm assisting port was placed in the left subcostal area. A 12 mm port was placed pararectal right for the liver retractor. The abdomen was insufflated to a carbon dioxide pressure level of 15 mm Hg. The greater and lesser curvature were dissected with ultrasonic coagulating shears. The left gastric artery and vein were then transected at their origin, with resection of local lymph nodes. The hiatus was opened and the distal esophagus dissected from the right and left crus. Carbon dioxide pressure level was then reduced to 5 mm Hg to avoid a high intrathoracic pressure. The first jejunal loop after Treitz ligament was identified and marked with an instrument for the creation of a feeding jejunostomy. The esophagus and surrounding lymph nodes were pulled into the abdomen under laparoscopic vision. A 7 cm transverse incision was made at the level of the left para-umbilical port to extract the specimen and stomach using a wound protector. Outside the abdomen, a 3-4 cm wide gastric tube was then constructed with GIA staplers and suturing of the stapled line with PDS 3/0. After pulling the gastric tube to the neck, a feeding jejunostomy was placed at the level of the transverse incision. An esophagogastrostomy was performed in the neck.

Statistical analysis

All patient data were collected prospectively and analyses were made using SPSS (version 12.0 for Windows). Data are presented as median and range.

- _____ 1
- _____ 2
- _____ 3
- _____ 4
- _____ 5
- _____ 6
- _____ 7
- _____ 8
- _____ 9
- _____ 10
- _____ 11
- _____ 12
- _____ 13
- _____ 14
- _____ 15
- _____ 16
- _____ 17
- _____ 18
- _____ 19
- _____ 20
- _____ 21
- _____ 22
- _____ 23
- _____ 24
- _____ 25
- _____ 26
- _____ 27
- _____ 28
- _____ 29
- _____ 30
- _____ 31
- _____ 32

RESULTS

Twenty-one consecutive patients were included to undergo robot-assisted (Da Vinci®, Intuitive Surgical, Inc, Sunnyvale, California, USA) thoracoscopic esophagectomy. Patient characteristics are described in Table 1. Indications for surgery were adenocarcinoma in 10 (48%) cases or squamous cell carcinoma in 11 (52%), located in the mid esophagus in 8 (38%) or lower esophagus in 13 (62%) cases. Three (14%) patients received neoadjuvant chemotherapy since M1a lymph nodes were detected by EUS and confirmed by preoperative FNA or CT-scan.

Table 1 - Patient characteristics of 21 patients who underwent robot-assisted thoracoscopic esophagectomy

Gender – no. (%)	
Male	15 (71)
Female	6 (29)
Age – median (range)	62 (47-78)
ASA-classification – no. (%)	
1	6 (29)
2	11 (52)
3	4 (19)
Body mass index – median (range)	26 (19-36)
Smokers – median (%)	10 (48%)

Eighteen (86%) procedures were completed thoracoscopically. Conversion to thoracotomy was due to either extensive pulmonary adhesions (n=1), a bulky adhesive tumour (n=1) or bleeding from an aorto-esophageal artery at the level of the aortic arch (n=1).

Median robotic set-up time was 7 (4-15) min. Median operating time for the thoracoscopic phase was 180 (120-240) min and 450 (370-550) min for the complete procedure. With growing experience, median operating time for the thoracoscopic phase reduced from 228 in the first 10 cases to 168 min in the last 11 cases. The median blood loss was 400 (150-700) ml for the robot-assisted thoracoscopic phase and 950 (250-5300) ml for the complete procedure. The upper value represents the blood loss in the patient with bleeding from an aorto-esophageal artery that required conversion.

Table 2 - Characteristics of surgery and early postoperative course in 21 patients who underwent robot-assisted thoracoscopic esophagectomy

Duration of surgery – minutes (range)	450 (370-550)
Robot-assisted thoracic	180 (120-240)
Blood loss - ml (range)	950 (250-5300)
Robot-assisted thoracic	400 (150-700)
Postoperative complications - no. (%)	
Pulmonary complications	10 (48)
Cardiac complications	3 (14)
Anastomotic leakage	3 (14)
Vocal-cord paralysis	3 (14)
Chylous leakage	3 (14)
Wound infection	3 (14)
Tracheo-neo-esophageal fistula	1 (5)
Gastrostomy leakage	1 (5)
Ventilation time – days	
Median	2
Range	0 –126
ICU stay – days	
Median	4
Range	1 – 129
Hospital stay – days	
Median	18
Range	11 –182
In-hospital mortality - no. (%)	1 (5)

Postoperative complications are listed in Table 2. One patient died due to a tracheo-neo-esophageal fistula that was treated by pneumonectomy (5%). Another patient developed leakage due to an ischemic lesion of the distal neo-esophagus, which could be managed by relaparotomy. Pulmonary complication rate reduced from 60% in the first 10 cases to 32% in the last 11 cases. In the first 10 cases, pulmonary complications were mainly caused by left sided pneumonia and associated ARDS in 3 (33%) patients. In those 3 patients long ICU and ventilation times were recorded, representing the upper values of these parameters.

A median of 20 (9-30) lymph nodes were retrieved. Tumor free resection margins (R0) were obtained in 16 (76%) patients, microscopic residual tumor (R1) circumferential

_____	1
_____	2
_____	3
_____	4
3 _____	5
_____	6
_____	7
_____	8
_____	9
_____	10
_____	11
_____	12
_____	13
_____	14
_____	15
_____	16
_____	17
_____	18
_____	19
_____	20
_____	21
_____	22
_____	23
_____	24
_____	25
_____	26
_____	27
_____	28
_____	29
_____	30
_____	31
_____	32

resection margins in 5 (24%). No macroscopic residual tumor (R2) margins occurred. Stage grouping and tumor characteristics are shown in Table 3.

Table 3 - Characteristics of the resected tumor in patients who underwent robot-assisted thoracoscopic esophagectomy

Histologic type – no. (%)	
Adenocarcinoma	10 (48)
Squamous cell carcinoma	11 (52)
Location esophagus – no. (%)	
Mid	8 (38)
Low	13 (62)
TNM stage – no. (%)	
I	1 (5)
Ila	4 (19)
III	5 (24)
IVa	11 (52)
Radicality of surgery – no. (%)	
R0	16 (76)
R1	5 (24)
R2	0
Number of lymph nodes dissected –median (range)	
	20 (9-30)

Tumor free resection margins (R0), microscopic residual tumor (R1), macroscopic residual tumor (R2)

DISCUSSION

This is the first reported series of robot-assisted thoracoscopic esophago-lymphadenectomy. We demonstrated that, with proper placement of the robotic ports, this procedure can be performed safely. In conventional thoracoscopic procedures, mediastinal lymphadenectomy is technically hindered by working in a three-dimensional field through a two-dimensional view with rigid instruments. The robot offers a three-dimensional magnified vision and articulating instruments, allowing a precise dissection of the peri-esophageal tissue along all the vital structures, such as pulmonary vein, trachea, aorta and recurrent nerves.

The first case of a robot-assisted thoracoscopic esophagectomy was recently published.¹¹ In that report a complete robot-assisted approach was used in the thoracic and abdominal

phase. The set-up used in this study was developed and extensively tested in our laboratory on human cadavers. We experienced this set-up to be beneficial as the entire mediastinum from diaphragm to thoracic aperture could be reached. Furthermore, we found that the abdominal phase is less suitable for the robotic approach, as manoeuvres with large amplitude are necessary to dissect the entire greater curvature.

Local tumor recurrence is a main cause of treatment failure in esophageal cancer. In a retrospective analysis of 149 patients who underwent open transhiatal resection, disease recurred in 52% (median follow up 24 months) within a median time of 11 months. In these patients, 23% recurred only locally, whereas 14% recurred systemically.¹² Thus, in a substantial number of patients (23%), recurrence is probably due to either an incomplete positive lymph node dissection or an incomplete circumferential tumor dissection margin (R1). In this particular group of patients, a more radical surgical approach could reduce locoregional recurrence and thereby prolong disease-free survival. The thoracoscopic approach offers an excellent access to the mediastinum, allowing an extended lymphadenectomy as well as en bloc dissection of the peritumoral tissue. Indeed, the R0 resection rate in our series (76%), compares well to that found after open transthoracic resection (79%).²

The open transhiatal resection is generally associated with a shorter duration of surgery compared to the open transthoracic approach (3.5 vs 6 hours).² Moreover, median blood loss is lower (1.0 vs 1.9 liters) and respiratory complication rate is significantly less (57 vs 27%). In a large meta-analysis, the operative mortality rate of the transhiatal approach was around 6% versus 10% for the transthoracic approach.¹³ With these figures in mind, minimally invasive procedures have been developed, aiming at a lower complication rate combined with equally or better oncologic results. Various reports have shown the feasibility of the laparoscopic transhiatal approach.^{7,14-16} However, these procedures are technically demanding and do not significantly improve the already low morbidity and mortality rates and short operating time of the open transhiatal approach.¹⁷ More importantly, oncologic outcome will not be improved as mediastinal lymphadenectomy and en bloc tumor resection cannot be performed. To our opinion, maximal benefit should come from the minimally invasive thoracic procedures.⁷ Indeed, the largest reported series of 222 patients, combining the thoracoscopic and laparoscopic approach, shows major improvements of the peri-operative morbidity and

_____	1
_____	2
_____	3
3 _____	4
_____	5
_____	6
_____	7
_____	8
_____	9
_____	10
_____	11
_____	12
_____	13
_____	14
_____	15
_____	16
_____	17
_____	18
_____	19
_____	20
_____	21
_____	22
_____	23
_____	24
_____	25
_____	26
_____	27
_____	28
_____	29
_____	30
_____	31
_____	32

mortality rates.¹⁸ Median duration of surgery was 5 hours, blood loss 300 ml, pulmonary complication rate 22% and mortality 1.4%. However, it has to be noted that in their series, 5-year survival rate was comparable to the open transhiatal resection.

In our series we aimed at a complete mediastinal lymphadenectomy, which could be well performed with the aid of robotic technology. The median number of lymph nodes resected in our series is less than reported previously in the open transthoracic procedure (20 vs 31).² The explanation for this difference may be a less extensive resection in the robot-assisted thoracoscopic procedure, or the pathological technique of counting lymph nodes in our study. Before we introduced robot-assisted thoracoscopic esophageal resection, median number of thoracic and abdominal lymph nodes resected by means of transthoracic approach was 16 (range 1-43). Nonetheless, the outcome compares favourably to a recently published report of 25 laparoscopically assisted transhiatal procedures where a mean number of 7 nodes was found.¹⁷ In a large experience of 46 thoracolaparoscopic procedures, the mean number of nodes was 10.¹⁹

After evaluating the first 10 cases, we found that the incidence of pulmonary complications was high (60%), mainly caused by left sided pneumonia and associated ARDS in 3 (33%) patients. These complications were probably related to barotrauma of the left lung. During single-lung ventilation, high tidal volumes and pressures were found in a number of patients. In the following 11 patients we implemented measures to minimize injury to the collapsed right lung; we installed CPAP (5 mBar) during the desufflation phase. Furthermore, to reduce shear forces in the left lung, pressure controlled ventilation with small tidal volumes was applied. From that time on we did not encounter ARDS anymore. The pulmonary complication rate in the last 11 cases was reduced to 32%.

Another explanation is the learning curve associated with new technically complex procedures. In our series, the operating time of the robot-assisted thoracoscopic part reduced markedly with a median of 228 minutes in the first 10 cases to 168 minutes in the last 11. These figures are in agreement with other studies reporting a steep learning curve with video-assisted thoracoscopic esophago-lymphadenectomy.²⁰ Conversion rate in this series (14%) is comparable to other.¹⁹

In conclusion, we found that robot-assisted thoracoscopic esophago-lymphadenectomy for esophageal cancer is feasible. Robot-assistance allows precise dissection in the

mediastinum. This approach has the potential of reducing postoperative complications with optimal surgical en bloc dissection of the tumor and peri-esophageal tissues. Our aim is now to standardize the procedure so that it can be compared with other operative techniques.

3

- 1
- 2
- 3
- 4
- 5
- 6
- 7
- 8
- 9
- 10
- 11
- 12
- 13
- 14
- 15
- 16
- 17
- 18
- 19
- 20
- 21
- 22
- 23
- 24
- 25
- 26
- 27
- 28
- 29
- 30
- 31
- 32

REFERENCES

1. Lerut T, Coosemans W, Decker G, De Leyn P, Moons J, Naftoux P, Van Raemdonck D. Extended surgery for cancer of the esophagus and gastroesophageal junction. *J Surg Res* 2004; 117:58-63.
2. Hulscher JB, van Sandick JW, de Boer AG et al. Extended transthoracic resection compared with limited transhiatal resection for adenocarcinoma of the esophagus. *N Engl J Med* 2002; 347:1662-1669.
3. Buunen M, Gholghesaei M, Veldkamp R, Meijer DW, Bonjer HJ, Bouvy ND. Stress response to laparoscopic surgery: a review. *Surg Endosc* 2004; 18:1022-1028.
4. Bessell JR, Maddern GJ, Manncke K, Ludbrook G, Jamieson GG. Combined thoracoscopic and laparoscopic oesophagectomy and oesophagogastric reconstruction. *Endosc Surg Allied Technol* 1994; 2:32-36.
5. Cuschieri A, Shimi S, Banting S. Endoscopic oesophagectomy through a right thoracoscopic approach. *J R Coll Surg Edinb* 1992; 37:7-11.
6. Gossot D, Ghnassia MD, Debiolles H et al. Thoracoscopic dissection of the esophagus: an experimental study. *Surg Endosc* 1992; 6:59-61.
7. Law S and Wong J. Use of minimally invasive oesophagectomy for cancer of the oesophagus. *Lancet Oncol* 2002; 3:215-222.
8. Nguyen NT, Follette DM, Wolfe BM, Schneider PD, Roberts P, Goodnight JE, Jr. Comparison of minimally invasive esophagectomy with transthoracic and transhiatal esophagectomy. *Arch Surg* 2000; 135:920-925.
9. Broeders IA and Ruurda JP. Robotics in laparoscopic surgery: current status and future perspectives. *Scand J Gastroenterol Suppl* 2002; 76-80.
10. Hubens G, Ruppert M, Balliu L, Vaneerdeweg W. What have we learnt after two years working with the da Vinci robot system in digestive surgery? *Acta Chir Belg* 2004; 104:609-614.
11. Kernstine KH, DeArmond DT, Karimi M, Van Natta TL, Campos JC, Yoder MR, Everett JE. The robotic, 2-stage, 3-field esophagolymphadenectomy. *J Thorac Cardiovasc Surg* 2004; 127:1847-1849.
12. Hulscher JBF, van Sandick JW, Tijssen JGP, Obertop H, van Lanschot JJ. The recurrence pattern of esophageal carcinoma after transhiatal resection. *J Am Coll Surg* 2000; 191:143-148.
13. Hulscher JB, Tijssen JG, Obertop H, van Lanschot JJ. Transthoracic versus transhiatal resection for carcinoma of the esophagus: a meta-analysis. *Ann Thorac Surg* 2001; 72:306-313.
14. Cuesta MA, Van den Broek WT, van der Peet DL, Meijer S. Minimally invasive esophageal resection. *Semin Laparosc Surg* 2004; 11:147-160.

15.	DePaula AL, Hashiba K, Ferreira EA, de Paula RA, Grecco E. Laparoscopic transhiatal esophagectomy with esophagogastroplasty. Surg Laparosc Endosc 1995; 5:1-5.	1
16.	Swanstrom LL and Hansen P. Laparoscopic total esophagectomy. Arch Surg 1997; 132:943-947.	2
17.	Van den Broek WT, Makay O, Berends FJ, Yuan JZ, Houdijk AP, Meijer S, Cuesta MA. Laparoscopically assisted transhiatal resection for malignancies of the distal esophagus. Surg Endosc 2004; 18:812-817.	3
18.	Luketich JD, Alvelo-Rivera M, Buenaventura PO et al. Minimally invasive esophagectomy: outcomes in 222 patients. Ann Surg 2003; 238:486-494.	4
19.	Nguyen NT, Roberts P, Follette DM, Rivers R, Wolfe BM. Thoracoscopic and laparoscopic esophagectomy for benign and malignant disease: lessons learned from 46 consecutive procedures. J Am Coll Surg 2003; 197:902-913.	5
20.	Osugi H, Takemura M, Higashino M et al. Learning curve of video-assisted thoracoscopic esophagectomy and extensive lymphadenectomy for squamous cell cancer of the thoracic esophagus and results. Surg Endosc 2003; 17:515-519.	6
		7
		8
		9
		10
		11
		12
		13
		14
		15
		16
		17
		18
		19
		20
		21
		22
		23
		24
		25
		26
		27
		28
		29
		30
		31
		32

4

Journal of Thoracic and Cardiovascular Surgery 2006;132:1491-2

Gastric conduit staple line after esophagectomy: To oversee or not?

Judith Boone
Inne H.M. Borel Rinkes
Richard van Hillegersberg

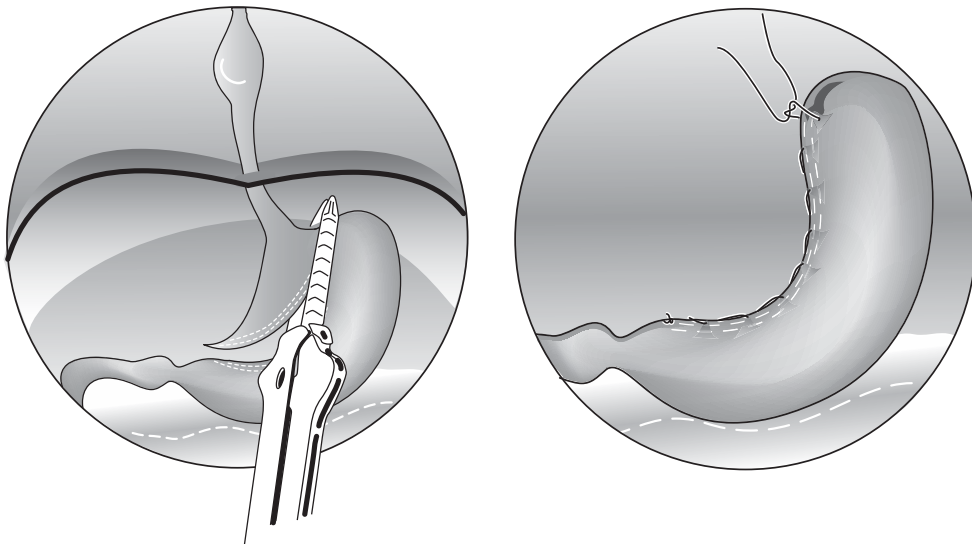
Department of Surgery,
University Medical Center Utrecht

- 1 _____
- 2 _____
- 3 _____
- 4 _____
- 5 _____
- 6 _____
- 7 _____
- 8 _____
- 9 _____
- 10 _____
- 11 _____
- 12 _____
- 13 _____
- 14 _____
- 15 _____
- 16 _____
- 17 _____
- 18 _____
- 19 _____
- 20 _____
- 21 _____
- 22 _____
- 23 _____
- 24 _____
- 25 _____
- 26 _____
- 27 _____
- 28 _____
- 29 _____
- 30 _____
- 31 _____
- 32 _____

4

After esophagectomy continuity is frequently restored by gastric replacement. The staple line of this gastric conduit is generally oversewn to prevent leakage and erosion of adjacent tissue (Figure 1). This last step is often omitted during minimally invasive esophagectomy (MIE) as technical difficulties make it time consuming.¹ Moreover, there is little evidence that supports the need for oversewing staple lines in gastrointestinal surgery. We describe two major complications that occurred after abandoning oversewing the staple line of the gastric conduit following esophagectomy.

Figure 1 - The gastric conduit is created by means of several linear staplers (left). The gastric conduit staple line is routinely oversewn with PDS 3-0 to prevent complications (right).



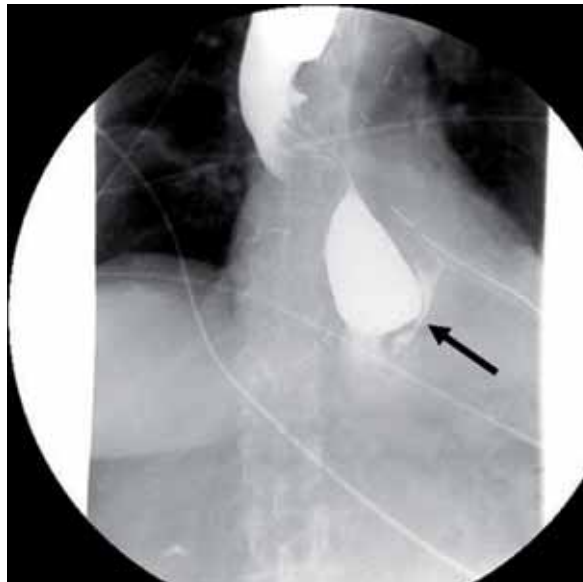Case 1

A 66-year-old female patient with a squamous cell carcinoma of the mid esophagus underwent robot-assisted thoracoscopic esophagectomy (RTE). Through laparotomy the resected specimen and abdominal lymph nodes were removed. Using the GIA-stapler (GIA 80, 3.8 mm, Tyco Healthcare, Norwalk USA) a 3 cm wide gastric conduit was created.²The staple line was not oversewn.

On the first postoperative day the left thoracic drain produced bile. Methylene blue was injected in the nasogastric tube, which was detected in the thoracic drain soon afterwards. A contrast enhanced X-ray examination of the gastric conduit showed leakage at the distal staple line at the level of the diaphragm (Figure 2).

Relaparotomy revealed a defect of the staple line just above the pylorus. A controlled fistula was made by placing a Foley catheter in the esophageal defect, covering the defect by omentum and draining the mediastinum. She recovered from the mediastinal sepsis after extended ICU stay of 39 days. On day 45 post surgery the Foley catheter could be removed. She left the hospital on day 61 in good condition.

Figure 2 - Case 1: Contrast examination of the neo-esophagus showing leakage (arrow) at the non-oversewn distal staple line.



- 1
- 2
- 3
- 4
- 5
- 6
- 7
- 8
- 9
- 10
- 11
- 12
- 13
- 14
- 15
- 16
- 17
- 18
- 19
- 20
- 21
- 22
- 23
- 24
- 25
- 26
- 27
- 28
- 29
- 30
- 31
- 32

- 1 —
- 2 —
- 3 —
- 4 —
- 5 —
- 6 —
- 7 —
- 8 —
- 9 —
- 10 —
- 11 —
- 12 —
- 13 —
- 14 —
- 15 —
- 16 —
- 17 —
- 18 —
- 19 —
- 20 —
- 21 —
- 22 —
- 23 —
- 24 —
- 25 —
- 26 —
- 27 —
- 28 —
- 29 —
- 30 —
- 31 —
- 32 —

4

Case 2

A 69-year-old male patient with an adenocarcinoma of the esophagus underwent RTE with gastric conduit formation through laparotomy. The staple line was not oversewn. At day 9 his condition deteriorated and he had to be reintubated. Since bronchoalveolar aspirate contained bile, a bronchoscopy was performed showing a fistula between the right bronchus and the gastric conduit.

Thoracotomy revealed a defect of 4 centimeters in the right main bronchus communicating with the neo-esophagus. Given the size of the bronchial defect and the condition of the lung with massive infiltrate, a pneumonectomy was performed. The gastric conduit was well perfused and the defect was closed with stitches. Despite this intervention, the patient died from ongoing sepsis.

DISCUSSION

Gastric conduit staple lines are routinely oversewn to prevent local complications. Nevertheless, evidence about the value of this step is scarce. No randomized controlled trials are available comparing complication rate of oversewn versus non-oversewn (gastric) staple lines. In MIE, oversewing the gastric conduit staple line is often omitted because of technical difficulties in laparoscopic suturing. To our knowledge, this is the first report describing the possible consequences of abandoning this step.

In our hospital from 1995 until 2003, 126 consecutive patients underwent esophagectomy for malignancy either by transthoracic or transhiatal approach. Conduit staple lines were routinely oversewn. No leakage at the staple line has occurred in any of the patients. In contrast, in the first 13 minimally invasive cases, staple lines were not oversewn, resulting in leakage in 2 patients (15%).² After these two events, we reintroduced this step and no staple line leakage was encountered in the following 20 patients.

The incidence of dehiscence of gastrotomy staple lines is not precisely described in the literature. Several factors may contribute to staple line leaks.³ Technical inadequacies of stapling material can lead to staple line disruptions, as probably occurred in our first case.³ Moreover, surrounding organs can be injured by protruding staples resulting in

fistula, as found in our second case. Thirdly, ischemia in the region of the staple line can cause leakage. Also, staples can be caught in the posterior mediastinum during the conduit pull up procedure, causing damage to adjacent structures and to the conduit itself. Gastrotomy leaks can lead to severe sepsis, mediastinitis and respiratory-neo-esophageal or aorto-neo-esophageal fistula.⁴

Respiratory-neo-esophageal fistula is a rare but dangerous complication of esophagectomy. Although several cases are described of fistula located at the esophagogastric anastomosis,⁴ few cases are depicted at the staple line of the gastric conduit.^{4,5} In these cases, oversewing of the staple line is not reported.

Remarkably, the largest reported series of MIE has not reported any complication at the non-oversewn staple lines in 222 patients.¹ Nevertheless, as the consequences of a possible leakage are severe and carry a high mortality rate, oversewing the gastric conduit staple line should be performed routinely, even in MIE. In MIE, extracorporeally the gastric tube can be created and conventionally oversewn through a 7 cm transverse incision.

4

- 1
- 2
- 3
- 4
- 5
- 6
- 7
- 8
- 9
- 10
- 11
- 12
- 13
- 14
- 15
- 16
- 17
- 18
- 19
- 20
- 21
- 22
- 23
- 24
- 25
- 26
- 27
- 28
- 29
- 30
- 31
- 32

REFERENCES

1. Luketich JD, Alvelo-Rivera M, Buenaventura PO et al. Minimally invasive esophagectomy: outcomes in 222 patients. *Ann Surg* 2003; 238:486-494.
2. van Hillegersberg R, Boone J, Draaisma WA, Broeders IA, Giezeman MJ, Borel Rinkes, IH. First experience with robot-assisted thoracoscopic esophagolymphadenectomy for esophageal cancer. *Surg Endosc* 2006; 20:1435-1439.
3. Baker RS, Foote J, Kemmeter P, Brady R, Vroegop T, Serveld M. The science of stapling and leaks. *Obes Surg* 2004; 14:1290-1298.
4. Buskens CJ, Hulscher JBF, Fockens P, Obertop H, van Lanschot JJ. Benign tracheo-neo-esophageal fistulas after subtotal esophagectomy. *Ann Thorac Surg* 2001; 72:221-224.
5. Pramesh CS, Sharma S, Saklani AP, Sanghvi BV. Broncho-gastric fistula complicating transthoracic esophagectomy. *Dis Esophagus* 2001; 14:271-273.

- 1
- 2
- 3
- 4
- 5
- 6
- 7
- 8
- 9
- 10
- 11
- 12
- 13
- 14
- 15
- 16
- 17
- 18
- 19
- 20
- 21
- 22
- 23
- 24
- 25
- 26
- 27
- 28
- 29
- 30
- 31
- 32

5

Diseases of the Esophagus 2008; 21:226-9

The effect of azygos vein preservation on mediastinal lymph node harvesting in thoracic esophagolymphadenectomy

Judith Boone¹
Marguerite E.I. Schipper²
Ronald L.A.W. Bleys³
Inne H.M. Borel Rinkes¹
Richard van Hillegersberg¹

Departments of ¹Surgery, ²Pathology and ³Pharmacology and Anatomy,
University Medical Center Utrecht

ABSTRACT

Background

The standard surgical procedure for esophageal cancer is transthoracic esophagectomy with en bloc resection of the azygos vein, thoracic duct and mediastinal lymph nodes. To reduce morbidity of esophagolymphadenectomy, minimally invasive techniques are increasingly being applied. In (robot-assisted) thoracoscopic esophagolymphadenectomy, the azygos vein is generally left in place, as the scopic ligation of the numerous intercostal veins is technically difficult and time-consuming. This could affect the extent of mediastinal lymph node dissection. Therefore, in this study, the effect of azygos vein preservation during thoracic esophagectomy on mediastinal lymph node harvesting was assessed.

Materials and Methods

In 15 human cadavers, a right-sided thoracotomy was performed, followed by esophagectomy with mediastinal lymph node dissection after ligation of the azygos arch (representing the situation in robot-assisted thoracoscopic esophagolymphadenectomy). Subsequently, the remaining azygos vein with surrounding tissue was resected. The number of lymph nodes in both specimens was determined.

Results

A mean of 17.3 (95% Poisson CI 15.3–19.6) lymph nodes was dissected en bloc with the esophagus, and 0.67 (95% Poisson CI 0.32–1.23) around the separately resected azygos vein. The additional azygos vein resection did not add to the number of lymph nodes dissected in 60% (9/15) of cadavers.

Conclusions

The extent of mediastinal lymph node dissection was not substantially affected by leaving the azygos vein in situ. Time-sparing azygos vein preservation in (robot-assisted) thoracoscopic esophagolymphadenectomy may therefore be considered justified.

INTRODUCTION

For patients with resectable esophageal cancer, surgery offers the best chance for cure with an overall 5-year survival rate of around 25%. To achieve radical tumor resection, a transthoracic en bloc esophagectomy (EBE) is performed within an envelope of adjacent tissues that includes lymphatic tissue, the azygos vein and the thoracic duct.¹ A recent randomized trial has shown a trend towards a survival benefit for EBE compared with the transhiatal approach.² Nevertheless, this gain in survival is accompanied by significant perioperative morbidity.² Minimally invasive thoracoscopic techniques have been developed to reduce morbidity and mortality.^{3,4} Recently, we have shown robot-assisted thoracoscopic esophago-lymphadenectomy to be feasible.⁵

In the thoracoscopic and robot-assisted thoracoscopic approaches, the azygos vein is left in place after ligation of the azygos arch, since ligating the numerous intercostal veins scopically is technically difficult and time-consuming.³⁻⁸ This might lead to a limited mediastinal lymph node dissection compared to the open transthoracic en bloc procedure, possibly affecting oncologic outcome.

The aim of the present study was to assess, in a cadaveric model, the effect of azygos preservation during transthoracic esophagolymphadenectomy on the extent of mediastinal lymph node dissection.

MATERIALS AND METHODS

Fifteen fresh frozen human adult cadavers donated to the Department of Pharmacology and Anatomy of the University Medical Center Utrecht were included. Since these cadavers were donated, autopsy was not routinely performed and causes of death were therefore unknown. Cadavers with thoracic trauma or thoracic disease were excluded from this study.

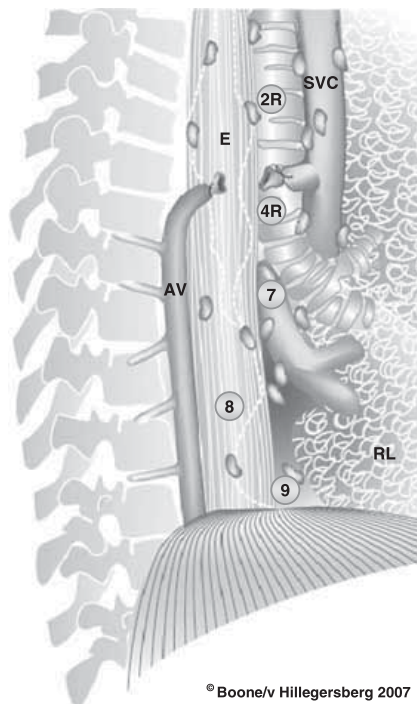
All surgical procedures were carried out by an experienced esophageal surgeon (RvH) assisted by one surgical assistant (JB) at the Department of Pharmacology and Anatomy. Prior to performing surgery, cadavers were defrosted.

After the cadaver was placed in left lateral position, a right-sided posterolateral

—	1
—	2
—	3
—	4
—	5
—	6
—	7
—	8
—	9
—	10
—	11
—	12
—	13
—	14
—	15
—	16
—	17
—	18
—	19
—	20
—	21
—	22
—	23
—	24
—	25
—	26
—	27
—	28
—	29
—	30
—	31
—	32

thoracotomy was performed through the 6th intercostal space. First, the esophagus with surrounding tissue was dissected exactly as performed in the robot-assisted thoracoscopic procedure. To achieve this, the pulmonary ligament was divided and the anterior parietal pleura was divided from diaphragm up to the level of the azygos arch. The azygos arch was ligated with sutures. Then, the posterior parietal pleura was divided along the azygos vein. The thoracic duct and mediastinal lymph nodes were dissected en bloc with the esophagus. The esophageal resected specimen included upper, lower and middle mediastinal, bilateral paratracheal and subcarinal lymph nodes. No abdominal resection or lymph node dissection was performed. Secondly, the azygos vein with surrounding fatty tissue was dissected separately from the ligated azygos arch up to the level of the diaphragm (Figure 1).

Figure 1 - Schematic view of the esophagus (E) and azygos vein (AV) during the rightsided thoracic dissection. Following ligation of the azygos arch, the esophagus with surrounding tissue is dissected conform the robot-assisted thoracoscopic approach. Separately, the azygos vein is resected after ligating the intercostal veins. The mediastinal lymph node stations are indicated according to the American Joint Committee for Cancer Staging and End-results,²⁰ with corresponding stations according to the Japanese Society for Esophageal Diseases¹⁹ in parantheses:



2R: right upper paratracheal (#105); 4R: right lower paratracheal (#106); 7: subcarinal (#107); 8: paraesophageal (#108 and #110) and 9: pulmonary ligament (#111). SVC: superior vena cava; RL: right lung.

By one pathologist with ample experience in oncologic pathology (MS), the esophageal resected specimens and azygos vein resected specimens were examined for lymph nodes by carefully slicing the surrounding fatty tissue. The selected tissues were fixed in formalin and embedded in paraffin. Then, slices were sectioned at 3 µm and stained with haematoxylin-and-eosin. By light microscopic examination, lymph nodes were identified and counted.

Results are presented as mean with 95% Poisson Confidence Interval (95% Poisson CI). To calculate the percentage of residual lymph nodes after azygos vein preservation, in each cadaver the number of lymph nodes surrounding the azygos vein was divided by the total amount of dissected mediastinal lymph nodes (lymph nodes at the esophagus + at the azygos vein) multiplied by 100%.

RESULTS

12 male and 3 female cadavers underwent transthoracic esophagolymphadenectomy with separate resection of the azygos vein. Age at time of death was 75 years (range 43 – 91).

An overview of the amount of lymph nodes located at the resected esophageal specimen and at the azygos vein specimen per cadaver is shown in Table 1. A mean amount of 17.3 lymph nodes (95% Poisson CI:15.3-19.6) was dissected en bloc with the esophagus. Around the separately resected azygos vein, a mean of 0.67 lymph nodes (95% Poisson CI 0.32–1.23) was located. In 60% of cadavers (9 out of 15), no lymph nodes were found around the azygos vein. In the 6 cadavers with lymph nodes in the azygos vein resected specimen, a range of 1– 3 lymph nodes (mean 1.7) were found. The mean percentage of residual lymph nodes was 3.3% (range 0-17.6).

- _____ 1
- _____ 2
- _____ 3
- _____ 4
- _____ 5
- _____ 6
- _____ 7
- 5** _____ 8
- _____ 9
- _____ 10
- _____ 11
- _____ 12
- _____ 13
- _____ 14
- _____ 15
- _____ 16
- _____ 17
- _____ 18
- _____ 19
- _____ 20
- _____ 21
- _____ 22
- _____ 23
- _____ 24
- _____ 25
- _____ 26
- _____ 27
- _____ 28
- _____ 29
- _____ 30
- _____ 31
- _____ 32

Table 1 - Overview of the amount of lymph nodes located at the esophageal resected specimen and the azygos vein resected specimen in 15 cadavers.

Cadaver	Gender	Age (years)	Lnn esophagus (n)	Lnn azygos vein (n)	Residual Lnn (%)
1	Male	63	25	1	3.8
2	Female	67	29	1	3.3
3	Male	91	32	2	5.9
4	Male	68	21	0	0
5	Male	91	11	0	0
6	Male	74	14	3	17.6
7	Female	74	13	0	0
8	Male	75	29	0	0
9	Male	43	7	0	0
10	Male	78	10	0	0
11	Male	80	7	0	0
12	Male	75	13	1	7.1
13	Male	81	13	0	0
14	Male	83	15	2	11.8
15	Female	85	21	0	0

Lnn: lymph nodes. Residual Lnn = (Lnn azygos vein / (Lnn esophagus + Lnn azygos vein)) x 100%

DISCUSSION

Transthoracic esophagolymphadenectomy is considered the best option for performing radical tumor resection, yet is accompanied by a high morbidity rate mainly due to pulmonary complications.² Minimally invasive techniques have been introduced to reduce this morbidity without compromising oncologic outcome.³ However, preserving the azygos vein during (robot-assisted) thoracoscopic esophagolymphadenectomy³⁻⁹ might impair mediastinal lymph node harvesting and thus oncologic outcome. The results of our cadaveric study show that the preservation of this vein leads to a negligible reduction of dissected mediastinal lymph nodes. Moreover, in 60% of the cadavers no residual lymph nodes were located around the azygos vein.

The main motive for surgeons to preserve the azygos trunk in thoracoscopic esophagolymphadenectomy, is that ligation of the numerous intercostal veins scopically is technically difficult and time-consuming. An additional reason to preserve the azygos

vein is to prevent injury of the bronchial artery, which may occur during dissection of the azygos vein.^{10,11} Extensive upper mediastinal lymph node dissection and bronchial artery injury in particular, frequently cause tracheal ischemia, resulting in severe complications such as ischemia or ulceration of the trachea.¹²

However, not only in thoracoscopic esophagolymphadenectomy the azygos vein and intercostal veins are spared. A comparable modification of the open transthoracic EBE has been described by even strong advocates of EBE.¹³ Even so, most proponents of en bloc resection have hold on to the traditional en bloc procedure with resection of the azygos vein and intercostal veins.^{2,14}

In this cadaveric study, we have focused on the effect of azygos vein preservation on mediastinal lymph node dissection. The lateral margins of the resected esophageal specimens were not assessed, as our experimental set-up with separate azygos vein removal did not allow for such a comparison. The robot-assisted thoracoscopic approach differs from the typically thoracoscopic approach in the resection of the thoracic duct.^{5,7} Therefore, we included the thoracic duct in the dissection en bloc with the resected esophageal specimen.

Human cadavers provide a natural model for esophagectomy.¹⁵⁻¹⁷ Anatomy of cadavers is similar to that of patients, and lifting of the abdominal viscera due to relaxation of the diaphragm following death resembles the patient receiving thoracic surgery under general anaesthesia.¹⁶ Although cadavers are conserved through procedures as refrigeration or embalming, changes produced have no significant consequences on experimental surgery.¹⁶ Nevertheless, a main disadvantage of the cadaveric model is that neither blood loss nor physiological functions are assessable.¹⁵

Consistent with the results of the cadaveric study by Herbella et al.^{18,18}, the number of mediastinal lymph nodes in our study varied widely. During right-sided transthoracic esophagolymphadenectomy, lymph node stations #105, #106, #107, #108, #110, #111 and #112 according to the Japanese Society for Esophageal Diseases¹⁹ and 2R, 2L, 3P, 4R, 5, 7, 8 and 9 according to the American Joint Committee for Cancer Staging and End-results²⁰ are to be dissected (partly shown in Figure 1). Dissection of these lymph node stations in our study has resulted in a range of 7 – 34 lymph nodes, compared to 7 – 15 as reported in the Brazilian cadaveric study.¹⁸ This implies that when examining esophageal resection specimens, not solely the total amount of mediastinal

_____	1
_____	2
_____	3
_____	4
_____	5
_____	6
_____	7
5 _____	8
_____	9
_____	10
_____	11
_____	12
_____	13
_____	14
_____	15
_____	16
_____	17
_____	18
_____	19
_____	20
_____	21
_____	22
_____	23
_____	24
_____	25
_____	26
_____	27
_____	28
_____	29
_____	30
_____	31
_____	32

- 1 _____
- 2 _____
- 3 _____
- 4 _____
- 5 _____
- 6 _____
- 7 _____
- 8 _____
- 9 _____
- 10 _____
- 11 _____
- 12 _____
- 13 _____
- 14 _____
- 15 _____
- 16 _____
- 17 _____
- 18 _____
- 19 _____
- 20 _____
- 21 _____
- 22 _____
- 23 _____
- 24 _____
- 25 _____
- 26 _____
- 27 _____
- 28 _____
- 29 _____
- 30 _____
- 31 _____
- 32 _____

5

lymph node metastases should be determined, but the percentage of tumor positive lymph nodes out of the total amount of resected mediastinal lymph nodes. Since we have not performed an abdominal lymph node dissection, the amount of dissected lymph nodes in this cadaveric study is less than numbers reported in clinically performed thoracoabdominal esophagolymphadenectomy.²

The number of lymph nodes located in the fatty tissue surrounding the azygos vein was inconsistent as well in the present study, ranging from 0 – 3. Yet, the mean amount of lymph nodes adjoining the azygos vein was only 0.67. Furthermore, in 60% of our cadavers, no residual nodes were present when the trunk of this vein was preserved. The clinical relevance of this small amount of residual nodes on local tumor recurrence rate and survival is to be questioned. In general, although some groups have described survival rates after minimally invasive esophageal resection,^{3,21} more studies on long-term outcome of thoracoscopic esophagolymphadenectomy for esophageal cancer have to be obtained to assess if this surgical technique results in survival rates comparable to the conventional transthoracic approach.

In conclusion, the extent of mediastinal lymph node dissection during thoracic esophagolymphadenectomy was not substantially affected by preserving the azygos vein. Since ligating the intercostal veins during the (robot-assisted) thoracoscopic approach is technically difficult and time-consuming, preservation of the azygos vein may be warranted. However, more clinical studies reporting the recurrence and survival rates after thoracoscopic esophagolymphadenectomy have to provide the ultimate proof that oncologic outcome is comparable to the open transthoracic approach.

ACKNOWLEDGMENTS

The authors thank Mr. Willem van Wolferen and Mr. Simon Plomp from the Department of Pharmacology and Anatomy for their great assistance in the preparation of the surgical procedures and Dr. Maria Schipper from the Centre for Biostatistics for her help with the statistical analysis.

REFERENCES

- | | |
|--|----|
| | 1 |
| | 2 |
| | 3 |
| | 4 |
| | 5 |
| | 6 |
| | 7 |
| | 8 |
| | 9 |
| | 10 |
| | 11 |
| | 12 |
| | 13 |
| | 14 |
| | 15 |
| | 16 |
| | 17 |
| | 18 |
| | 19 |
| | 20 |
| | 21 |
| | 22 |
| | 23 |
| | 24 |
| | 25 |
| | 26 |
| | 27 |
| | 28 |
| | 29 |
| | 30 |
| | 31 |
| | 32 |
1. Skinner DB. En bloc resection for neoplasms of the esophagus and cardia. *J Thorac Cardiovasc Surg* 1983; 85:59-71.
 2. Hulscher JB, van Sandick JW, de Boer AG et al. Extended transthoracic resection compared with limited transhiatal resection for adenocarcinoma of the esophagus. *N Engl J Med* 2002; 347:1662-1669.
 3. Luketich JD, Alvelo-Rivera M, Buenaventura PO et al. Minimally invasive esophagectomy: outcomes in 222 patients. *Ann Surg* 2003; 238:486-494.
 4. Nguyen NT, Roberts P, Follette DM, Rivers R, Wolfe BM. Thoracoscopic and laparoscopic esophagectomy for benign and malignant disease: lessons learned from 46 consecutive procedures. *J Am Coll Surg* 2003; 197:902-913.
 5. van Hillegersberg R, Boone J, Draaisma WA, Broeders IA, Giezeman MJ, Borel Rinkes IHM. First experience with robot-assisted thoracoscopic esophagolymphadenectomy for esophageal cancer. *Surg Endosc* 2006; 20:1435-1439.
 6. Osugi H, Takemura M, Higashino M et al. Video-assisted thoracoscopic esophagectomy and radical lymph node dissection for esophageal cancer. A series of 75 cases. *Surg Endosc* 2002; 16:1588-1593.
 7. Kernstine KH, DeArmond DT, Karimi M, Van Natta TL, Campos JC, Yoder MR, Everett JE. The robotic, 2-stage, 3-field esophagolymphadenectomy. *J Thorac Cardiovasc Surg* 2004; 127:1847-1849.
 8. Watson DI, Davies N, Jamieson GG. Totally endoscopic Ivor Lewis esophagectomy. *Surg Endosc* 1999; 13:293-297.
 9. Fernando HC, Luketich JD, Buenaventura PO, Perry Y, Christie NA. Outcomes of minimally invasive esophagectomy (MIE) for high-grade dysplasia of the esophagus. *Eur J Cardiothorac Surg* 2002; 22:1-6.
 10. Pramesh CS, Mistry RC, Sharma S, Pantvaidya GH, Raina S. Bronchial artery preservation during transthoracic esophagectomy. *J Surg Oncol* 2004; 85:202-203.
 11. Fujita H, Hawahara H, Yamana H et al. Mediastinal lymphnode dissection procedure during esophageal cancer operation--carefully considered for preserving respiratory function. *Jpn J Surg* 1988; 18:31-34.
 12. Bartels HE, Stein HJ, Siewert JR. Tracheobronchial lesions following oesophagectomy: prevalence, predisposing factors and outcome. *Br J Surg* 1998; 85:403-406.
 13. Altorki N and Skinner D. Should en bloc esophagectomy be the standard of care for esophageal carcinoma? *Ann Surg* 2001; 234:581-587.

- 1 _____
- 2 _____
- 3 _____
- 4 _____
- 5 _____
- 6 _____
- 7 _____
- 8 _____
- 9 _____
- 10 _____
- 11 _____
- 12 _____
- 13 _____
- 14 _____
- 15 _____
- 16 _____
- 17 _____
- 18 _____
- 19 _____
- 20 _____
- 21 _____
- 22 _____
- 23 _____
- 24 _____
- 25 _____
- 26 _____
- 27 _____
- 28 _____
- 29 _____
- 30 _____
- 31 _____
- 32 _____

5

- 14. Hagen JA, DeMeester SR, Peters JH, Chandrasoma P, DeMeester TR. Curative resection for esophageal adenocarcinoma: analysis of 100 en bloc esophagectomies. *Ann Surg* 2001; 234:520-530.
- 15. Herbella FA, Del Grande JC, Colleoni R. Efficacy of mediastinal lymphadenectomy in transhiatal esophagectomy with and without diaphragm opening: a cadaveric study. *Dis Esophagus* 2002; 15:160-162.
- 16. Herbella FA and Del Grande JC. Human cadavers as an experimental model for esophageal surgery. *Dis Esophagus* 2001; 14:218-222.
- 17. Coral RP, Constant-Neto M, Silva IS, Kalil AN, Boose R, Beduschi T, Gemelle TF. Comparative anatomical study of the anterior and posterior mediastinum as access routes after esophagectomy. *Dis Esophagus* 2003; 16:236-238.
- 18. Herbella FA, Del Grande JC, Colleoni R. Anatomical analysis of the mediastinal lymph nodes of normal Brazilian subjects according to the classification of the Japanese Society for Diseases of the Esophagus. *Surg Today* 2003; 33:249-253.
- 19. Japanese Society for Esophageal Diseases. Guidelines for the clinical and pathologic studies for carcinoma of the esophagus. Part.1. Clinical classification. *Jpn J Surg* 1976; 6:79-86.
- 20. American Joint Committee for Cancer Staging and End-results. Manual for staging of Cancer. Chicago 1977;
- 21. Smithers BM, Gotley DC, Martin I, Thomas JM. Comparison of the outcomes between open and minimally invasive esophagectomy. *Ann Surg* 2007; 245:232-240.

- 1
- 2
- 3
- 4
- 5
- 6
- 7
- 8
- 9
- 10
- 11
- 12
- 13
- 14
- 15
- 16
- 17
- 18
- 19
- 20
- 21
- 22
- 23
- 24
- 25
- 26
- 27
- 28
- 29
- 30
- 31
- 32

6

Submitted for publication

Robot-assisted thoracoscopic esophagectomy for esophageal cancer: Short- and mid-term results

Judith Boone¹
Marguerite E.I. Schipper²
Wouter A. Moojen¹
Inne H.M. Borel Rinkes¹
Geert-Jan E. Cromheecke³
Richard van Hillegersberg¹

Department of ¹Surgery, ²Pathology and ³Anaesthesiology,
University Medical Center Utrecht

ABSTRACT

Background

Thoracoscopic esophagectomy was introduced to reduce morbidity of transthoracic esophagectomy (TTE). Robotic systems were developed to facilitate scopic surgery. Aim of this study was to assess the short- and mid-term results of robot-assisted thoracoscopic esophagectomy (RTE) for esophageal cancer.

Patients and Methods

Between October 2003 and May 2007, 47 patients with resectable esophageal cancer underwent RTE. Clinical data were prospectively collected.

Results

Conversion to thoracotomy occurred in 15%. Median operation time was 450 minutes; median blood loss 625 millilitres. Median postoperative ventilation time was 1 day, ICU stay 3 days and hospital stay 18 days. Pulmonary complication rate decreased from 57% in the first 23 operated patients to 33% in the last 24 patients. In-hospital mortality was 6%. Radical resection (R0) was achieved in 77%. A median of 29 (range 8-68) lymph nodes were dissected. Forty-nine percent of patients had stage IVa disease. After a median follow-up of 35 months, median disease-free survival was 15 (95% CI 12-18) months.

Conclusions

RTE has proven to be oncologically safe with a lymphadenectomy and R0 rate comparable to open TTE, combined with low blood loss and a steep learning curve. It is expected that surgery time, blood loss and pulmonary complication rate will further decrease with growing experience.

INTRODUCTION

Esophageal carcinoma is the 8th most common type of cancer in the world, with an estimated 462.000 newly patients diagnosed globally in 2002.¹ Radical surgical resection of the esophagus and the surrounding lymph nodes has proven to offer the best chance for cure in patients with locoregional disease.² Transthoracic esophagectomy (TTE) allows for an en bloc resection of the esophagus and an extensive mediastinal lymphadenectomy. Yet, this approach through thoracotomy is associated with significant morbidity, predominantly respiratory.³ Transhiatal esophagectomy (THE) carries a lower complication rate, however, since the esophagus is stripped out of the mediastinum only a limited lymphadenectomy can be carried out, without a dissection of the carinal and paratracheal lymph nodes.³

To reduce surgical trauma and thereby the morbidity of esophagectomy, minimally invasive techniques have been developed.^{4,5} Several studies on minimally invasive esophagectomy (MIE) have shown a substantial decrease in blood loss, complication rate and hospital stay.^{4,5} However, conventional scopic surgery has several limitations, such as a 2-dimensional view, a disturbed eye-hand-coordination and a decrease in degrees of freedom due to the large, rigid scopic surgical instruments.^{6,7} This might hamper a proper mediastinal dissection during thoracoscopic esophagectomy.

Robotic systems have been designed to overcome the disadvantages of scopic surgery. The Da Vinci® robotic system (Intuitive, Sunnyvale, California, USA) provides a 3-dimensional, tenfold magnified view on the operating field.^{6,7} It filters the tremor of the surgeon, restores the natural eye-hand-coordination axis owing to the ergonomically designed surgeon’s console and offers more degrees of freedom through its articulating scopic surgical instruments. As a result, robotic systems facilitate a precise dissection in a confined surgical field. This could be of added value during the mediastinal dissection of the esophagus and the surrounding lymph nodes.

The first case description of a thoracoscopic esophagectomy aided by a robotic system was published by Kernstine et al. in 2004.⁸ Two years later we have published our initial experience with robot-assisted thoracoscopic esophagectomy (RTE) in conjunction with conventional laparoscopy.⁹ This innovative surgical procedure has shown to be technically feasible and was associated with low blood loss.⁹ In the current article, the short- and mid-term results of RTE with 2-field lymph node dissection (LND) will be described.

—	1
—	2
—	3
—	4
—	5
—	6
—	7
—	8
—	9
6 —	10
—	11
—	12
—	13
—	14
—	15
—	16
—	17
—	18
—	19
—	20
—	21
—	22
—	23
—	24
—	25
—	26
—	27
—	28
—	29
—	30
—	31
—	32

PATIENTS AND METHODS

From October 2003 - May 2007, 73 patients with potentially resectable esophageal cancer were surgically treated at the authors' institute. Forty-seven (64%) of 73 patients underwent thoracoscopic esophagectomy with a 2-field LND aided by the Da Vinci® robotic system. Patients with a distal esophageal or gastroesophageal junction (GEJ) tumor that had severe cardiopulmonary comorbidity were offered open THE (n=14) or conventional laparoscopy (n=2) instead of RTE, as it was judged that the risk of morbidity would be too high in case of one-lung-ventilation and extensive mediastinal dissection. Six patients underwent open TTE (due to the use of the robotic system for a different type of operation at the day of esophagectomy) and 4 a diagnostic conventional thoracoscopy.

6

Preoperative work-up

Routine diagnostic work-up consisted in all patients of esophagogastroscopy with tumor biopsy, endoscopic ultrasonography (EUS) with fine needle aspiration (FNA) of suspected malignant lymph nodes if indicated (M1b lymph nodes¹⁰), computed tomography (CT) scanning of the chest and abdomen, ultrasonography (US) of the neck with FNA if indicated, electrocardiography and lung function testing. Bronchoscopy was performed in case of suspected airway ingrowth and 18F-fluorodeoxy-glucose (FDG) positron emission tomography (PET) scanning with CT fusion when lymph node metastases beyond the surgical field or organ metastases were suspected on CT scanning. The exact location of the tumor in the esophagus was determined by gastroscopy or EUS. Tumors were considered upper esophageal when they were located between 18 and 24 cm of the incisor teeth, middle esophageal when located between 24 and 32 cm and lower esophageal (including GEJ tumors) when located between 32 and 40 cm.¹⁰ Neoadjuvant therapy was not administered routinely. In 3 patients neoadjuvant chemotherapy was given for distant lymph node metastases (M1a) diagnosed with EUS.

Anaesthesiology

All patients received an epidural catheter in the 6th, 7th or 8th epidural space to provide adequate postoperative analgesia. Patients were intubated with a left-sided double-

lumen tube to accomplish selective deflation of the right lung during the thoracoscopic phase. Antibiotic prophylaxis was provided by cefazolin (2000mg) and metronidazole (500mg). In addition, 30 minutes before the incision methylprednisolone (10mg/kg) was administered to minimize postoperative pulmonary complications.¹¹ Fluid strategy was aimed at a mild positive fluid balance of approximately 1 litre. During one-lung-ventilation, a pressure-controlled ventilation strategy was applied with maximal pressures of ≤ 20 cmH₂O.¹² Postoperatively, patients were transferred to the intensive care unit (ICU).

Surgical technique

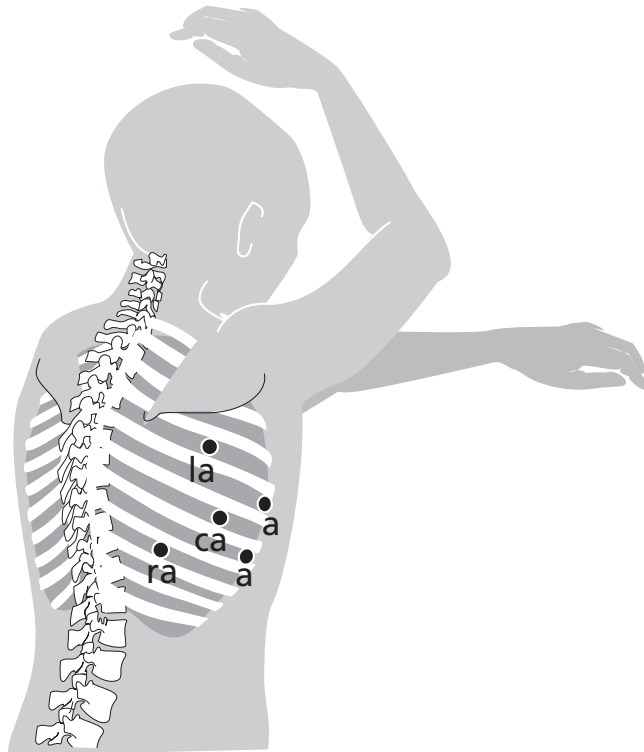
All surgical procedures were performed by 1 oncologic surgeon (RvH) with ample experience in minimally invasive surgery and in esophageal cancer surgery, who was assisted by a surgical assistant and a scrub nurse. Our surgical technique has been described extensively in 2006,⁹ but has meanwhile undergone some slight modifications. In short, the patient was positioned in left lateral decubitus position, 45° tilted towards prone position. The robotic system was placed at the dorsocranial side of the patient. The position of the robotic instrument ports and of the assistant's instrument ports are depicted in Figure 1. After the pulmonary ligament was divided, the parietal pleura was dissected at the anterior side of the esophagus from the diaphragm up to the azygos arch. The azygos arch was ligated. Then, the dissection of the parietal pleura was continued above the azygos arch for a right paratracheal lymph node dissection. Subsequently, the parietal pleura was dissected at the posterior side of the esophagus from cranially to caudally along the azygos vein, including the thoracic duct. At the level of the diaphragm, the thoracic duct was clipped with a 10 mm endoscopic clipping device (ENDOCLIP™ II, Covidien, Mansfield, MA, USA). A penrose drain was placed around the esophagus to facilitate esophageal mobilisation. In this way, the esophagus can be resected en bloc with the surrounding mediastinal lymph nodes and the thoracic duct from the diaphragm up to the thoracic inlet. The LND includes the right-sided paratracheal (lymph node station 2R), tracheobronchial (lymph node station 4), carinal (station 7) and periesophageal (station 8) lymph nodes.

In the first 15 patients the abdominal phase was performed through an open approach; in the following patients a conventional laparoscopic approach was used (without

- _____ 1
- _____ 2
- _____ 3
- _____ 4
- _____ 5
- _____ 6
- _____ 7
- _____ 8
- _____ 9
- _____ 10
- _____ 11
- _____ 12
- _____ 13
- _____ 14
- _____ 15
- _____ 16
- _____ 17
- _____ 18
- _____ 19
- _____ 20
- _____ 21
- _____ 22
- _____ 23
- _____ 24
- _____ 25
- _____ 26
- _____ 27
- _____ 28
- _____ 29
- _____ 30
- _____ 31
- _____ 32

the robotic system). The position of the laparoscopic trocars is shown in Figure 2. The surgical technique has been described previously.⁹ The LND included the lymph nodes surrounding the left gastric artery and the lesser omental lymph nodes. The resected specimen was removed through a 7 cm transverse transabdominal incision.

Figure 1 - Trocar set-up during the robot-assisted thoracoscopic phase.

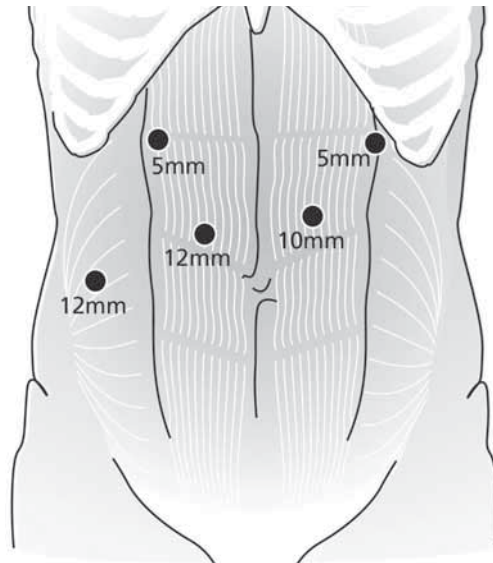


la: left robotic arm; ra: right robotic arm; ca: robotic camera arm; a: assistant port

By means of several linear staplers (GIA 80, 3.8 mm; Covidien), a 3-4 cm wide gastric conduit was created. In the first 13 RTE patients, the stapled line of the gastric conduit was not oversewn, since we were planning to perform an entirely minimally invasive procedure including intracorporeally creation of the gastric conduit. Due to 2 large complications at the non-oversewn stapled line, we have reintroduced this routine practise.¹³ Through a left-sided vertical incision along the sternocleidoid muscle, a handsewn end-to-side anastomosis was made between the gastric tube and the

cervical esophagus using 3-0 PDS one-layer running sutures. No formal cervical LND was carried out. Cervical lymph nodes were only dissected if during the cervical phase of esophagectomy lymph node metastases were macroscopically suspected.

Figure 2 - Trocar set-up during the conventional laparoscopic phase. The camera is inserted through the 10mm trocar port; two 5mm trocars are used as working ports. Through the 12mm right pararectal trocar port the liver retractor is inserted. The ultracision device is introduced through the 12mm paraumbilical port.



6

Histopathologic examination

The upper mediastinal (i.e. paratracheal, tracheobronchial, carinal and aortopulmonary window), peri-esophageal and left gastric lymph node stations were marked by the surgical team. At the Department of Pathology, lymph nodes were identified by slicing the fatty tissue surrounding the esophagus and gastric cardia. Subsequently, the resected tumor and the identified lymph nodes were fixed in formalin and embedded in paraffin. Tissue sections (3µm) were stained with Haematoxylin-Eosin for standard histopathological examination. For the present study, all resection specimens were revised by 1 oncologic pathologist (MS). Under light microscopic examination the following histopathologic characteristics were determined: histological type, grade of differentiation, tumor infiltration depth and presence of residual tumor at the resection

- 1
- 2
- 3
- 4
- 5
- 6
- 7
- 8
- 9
- 10
- 11
- 12
- 13
- 14
- 15
- 16
- 17
- 18
- 19
- 20
- 21
- 22
- 23
- 24
- 25
- 26
- 27
- 28
- 29
- 30
- 31
- 32

1 _____ margins. Dissected malignant and non-malignant lymph nodes were identified, counted
2 _____ and recorded by their anatomic location. Tumors were staged according to the most
3 _____ recent Tumor Node Metastasis (TNM) classification.¹⁰ For lower esophageal tumors,
4 _____ lymph node metastases near the celiac trunk and those within 1 cm of the origin of the
5 _____ left gastric artery were considered distant lymph node metastases (M1a disease). For
6 _____ mid-esophageal tumors, all non-regional lymph nodes were considered M1b disease.¹⁰
7 _____

8 ***Follow-up***

9 _____ After discharge from our hospital, patients were seen at our Outpatient Department at
10 _____ a 3-to 4-month interval for the 1st year, at a 6-month interval for the 2nd year and once a
11 _____ year in the subsequent years. At every visit, a medical interview and physical examination
12 _____ was done. Diagnostic modalities such as gastroscopy with biopsy, CT-scan, FDG-PET-
13 _____ scan or magnetic resonance imaging (MRI) were performed in case of suspected tumor
14 _____ recurrence, which is in accordance with the 2007 National Comprehensive Cancer
15 _____ Network (NCCN) Esophageal Cancer Clinical Practice Guidelines.¹⁴ Tumor recurrence in
16 _____ the anastomotic region or in the diaphragmatic crus (in case of pT4 crus) was considered
17 _____ local recurrent disease. Metastases in locoregional (i.e. mediastinal) lymph nodes were
18 _____ regarded as regional recurrence. Distant recurrent disease was divided according to the
19 _____ route of tumor spread: haematogenously (e.g. liver, bone, lung and cerebral metastases),
20 _____ lymphogenously (in case of cervical, celiac or other distant lymph node metastases),
21 _____ transperitoneally, transpleurally or a combination of these 4 categories.
22 _____

23 ***Data collection and statistical analysis***

24 _____ Data regarding surgery, postoperative course, postoperative complications and follow-
25 _____ up were prospectively recorded in an Access database (for Windows, 2002). Statistical
26 _____ analysis was performed when appropriate, using SPSS (Version 12.0, for Windows).
27 _____ Percentages were rounded to the nearest whole integer and consequently the sum
28 _____ of percentages may exceed 100%. For comparison of continuous data with a non-
29 _____ Gaussian distribution, the Mann-Whitney test was used. A p-value <0.050 was
30 _____ considered statistically significant. Disease-free survival was estimated using the Kaplan
31 _____ Meier survival analysis method and is presented as median with 95% Confidence
32 _____ Intervals (95%CI).

RESULTS

Patient characteristics

Thirty-three (70%) of 47 patients were male and 14 were female. Median age was 62 (range 39-78) years, median body mass index 25 (range 19-39). The American Society of Anaesthesiologists' (ASA) physical status score was 2 or 3 in 60% of patients.

Intra-operative characteristics

Forty (85%) procedures were completed thoracoscopically. Conversion to thoracotomy occurred in 7 (15%) patients and was due to insufficient deflation of the right lung (n=2), inadequate port position caused by kyphosis (n=1) or by a protruding scapular rim (n=1), extensive pleural adhesions (n=1), a bulky adhesive tumor in the upper mediastinum (n=1) or a bleeding from a bronchial artery which could not be controlled thoracoscopically (n=1).

Conversion of the laparoscopic phase was required in 4 (15%) of 26 patients because of widespread adhesions resulting from previous abdominal surgical procedures (n=2), possible tumor ingrowth in the right crus of the diaphragm (n=1) or considerable macroscopic lymph node metastases near the celiac trunk which were deemed too large for laparoscopic removal (n=1).

Median operation time of the robot-assisted thoracoscopic phase was 180 (range 120-240) minutes and of the total procedure 450 (360-550) minutes. Median blood loss of the thoracoscopic procedure was 250 (0-800) millilitres and of the entire procedure 625 (150-5300) millilitres. When comparing the first 23 operated patients with the last 24, a significant decrease in total blood loss was detected (median 900 vs. 450 millilitres, respectively; p=0.0004), even after exclusion of the 2 outliers of the first group (3rd patient, 2500 millilitres and 20th patient, 5300 millilitres; p=0.001; Figure 3a). In addition, a significant reduction in surgery time was noticed when comparing the first 23 patients with the last 24 patients (median 7.5 vs. 7.0 hours, respectively; p=0.024; Figure 3b).

1
2
3
4
5
6
7
8
9
10
11
12
13
14
15
16
17
18
19
20
21
22
23
24
25
26
27
28
29
30
31
32

Figure 3 - A: Boxplot graphs of total blood loss in the first 23 patients (with exclusion of 2 outliers) and the last 24 patients having undergone RTE ($p=0.001$). **B:** Boxplot graphs of total surgical time in the first 23 patients and the last 24 patients having undergone RTE ($p=0.024$).

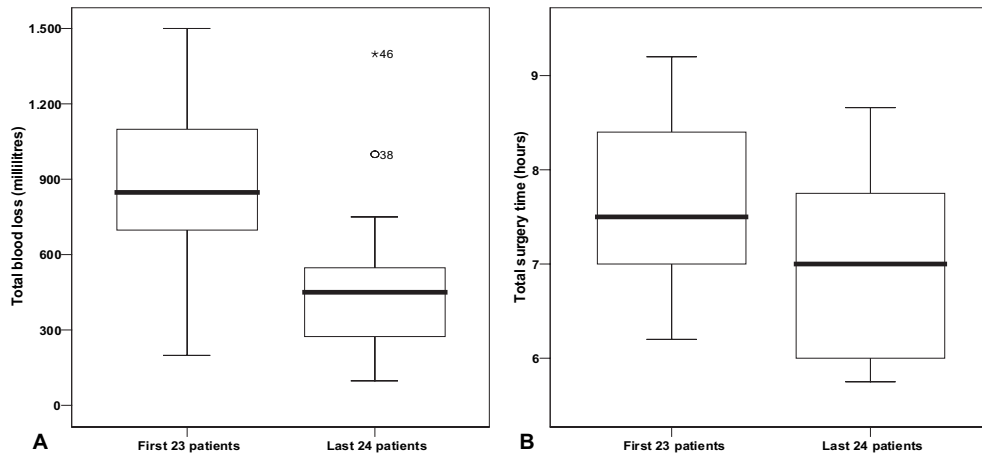


Table 1 - Postoperative complications of 47 esophageal cancer patients having undergone RTE.

	n (%)
Pulmonary complications*	21 (45)
Anastomotic leakage	10 (21)
Vocal cord paralysis	9 (19)†
Cardiac complications‡	6 (13)
Chylous leakage	6 (13)
Wound infection	4 (9)
Thoracic empyema	4 (9)
In-hospital mortality	3 (6)

* Pulmonary complications were defined as pneumonia (i.e. infiltrate on chest x-ray in combination with the identification of a pathogen in sputum culture), atelectasis (i.e. lobar collapse on chest x-ray) or Adult Respiratory Distress Syndrome (ARDS). † Of which 4 were temporary ‡ Cardiac complications consisted of myocardial infarction or atrial fibrillation.

Postoperative course

Patients were ventilated for 1 day (median; range 0-126). Median ICU stay was 3 (range 0-136) days and median hospital stay was 18 (range 10-182) days. Results on postoperative complications are shown in Table 1. Three (6%) patients died postoperatively, 1 due to a myocardial infarction, 1 due to Adult Respiratory Distress

Syndrome and 1 due to a tracheo-neo-esophageal fistula. The tracheo-neo-esophageal fistula was due to the non-oversewn gastric conduit stapled line.¹³ When comparing the first 23 operated patients with the last 24 patients a decrease in pulmonary complication rate was noticed (57% vs. 33%, respectively).

Table 2 - Histopathologic results of the 47 esophageal cancer patients having undergone RTE

Histologic type – n (%)	
Adenocarcinoma	29 (62)
Squamous cell carcinoma	18 (38)
Tumor location^a – n (%)	
Upper 1/3 part of esophagus	0 (0)
Middle 1/3 part of esophagus	12 (26)
Lower 1/3 part of esophagus/GE junction	35 (74)
Tumor size – median (range)	5.5 (2.0-11.5)
Tumor Node Metastasis (TNM) Stage – n (%)	
I	2 (4)
Ila	6 (13)
Ilb	3 (6)
III	8 (17)
IVa	23 (49)
IVb	5 (11)
Radicality^b – n (%)	
R0	36 (77)
R1	11 (23)
R2	0 (0)
Dissected lymph nodes – median (range)	29 (8-68)
Dissected metastatic lymph nodes – median (range)	3 (0-38)
Metastatic lymph node ratio – median % (range)	11 (0-69)

a - As determined by pre-operative gastroscopy or endoscopic ultrasonography

b - R0: no microscopic residual tumor; R1: microscopic residual tumor; R2: macroscopic residual tumor

Histopathologic results

An overview of the histopathologic results of the 47 malignancies is given in Table 2. The majority of tumors (74%) were located in the distal esophagus or on the GEJ. According to the TNM classification, 17% of tumors were stage III and 60% were stage IV. Of the 11 (23%) tumors with microscopic tumor residual (R1), 9 had involvement of the circumferential resection margins, 1 of the proximal and 1 of the distal resection margin. A total of 1479 lymph nodes were dissected (Figure 4), resulting in a median amount of 29 (range 8-68) per patient. Of these 1479 dissected lymph nodes, 257 (17%) were

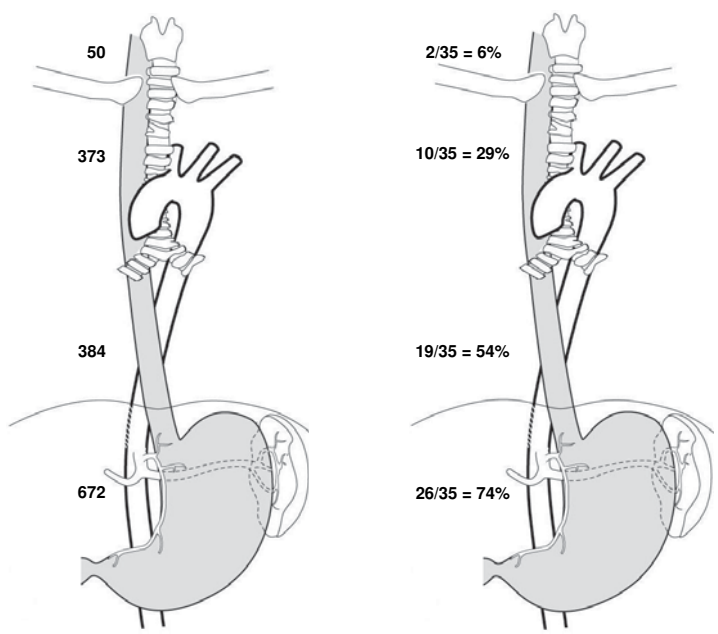
- 1 _____
- 2 _____
- 3 _____
- 4 _____
- 5 _____
- 6 _____
- 7 _____
- 8 _____
- 9 _____
- 10 _____
- 11 _____
- 12 _____
- 13 _____
- 14 _____
- 15 _____
- 16 _____
- 17 _____
- 18 _____
- 19 _____
- 20 _____
- 21 _____
- 22 _____
- 23 _____
- 24 _____
- 25 _____
- 26 _____
- 27 _____
- 28 _____
- 29 _____
- 30 _____
- 31 _____
- 32 _____

6

tumor positive. Lymph node metastases were detected in 39 (83%) patients, whereas 8 (17%) patients had no lymph node metastases. The median amount of lymph node metastases per patient was 3 (range 0-38) for the entire study-population and 4 (range 1-38) for the 39 patients with lymph node metastases. The median lymph node ratio in lymph node-positive patients was 13% (range 2%-69%).

In the 47 patients, 373 upper mediastinal lymph nodes were dissected (Figure 4) with a median of 6 lymph nodes per patient (range 0-28). Of 373 upper mediastinal lymph nodes, 303 (81%) were located at or above the carina (stations 4 and 7). Seventy (19%) upper mediastinal lymph nodes were found paratracheally. Eleven (23%) patients had at least 1 lymph node metastasis in the upper mediastinum. Of the 35 patients with a distal esophageal or GEJ tumor, 10 (29%) had upper mediastinal lymph node metastases (Figure 5). Of these 10 patients, 5 had 1 lymph node metastasis in the upper mediastinum, 3 had 2 tumor-positive lymph nodes and 2 had 3 tumor-positive lymph nodes.

Figure 4 (left) - Distribution of 1479 lymph nodes dissected in 47 patients having undergone RTE.
Figure 5 (right) - Location of lymph node metastases in 35 patients with a distal esophageal or gastroesophageal junction tumor having undergone RTE.



A total of 384 lymph nodes were dissected paraesophageally with a median of 8 (range 0-25). Sixty-nine (18%) of 384 paraesophageal lymph nodes contained tumor cells, resulting in a median of 1 metastatic paraesophageal lymph node per patient. In the upper abdomen, 672 lymph nodes were dissected with a median of 12 (range 1-37) per patient. Metastases were detected in 161 (24%) of the resected abdominal lymph nodes, with a median of 2 (range 0-31) per patient. In 12 patients a total of 50 cervical lymph nodes were dissected. Metastatic tumor cells were found in 8 (16%) of these lymph nodes, which resulted in upstaging of 3 patients.

Table 3 - Location of tumor recurrence in the 30 patients who developed recurrent disease after RTE

	N (%)
Local recurrence only	3 (10)
Regional recurrence only	2 (7)
Systemic recurrence only	18 (60)
Lymphogenous	7
Haematogenous	4
Haematogenous + Lymphogenous	3
Peritoneal	1
Haematogenous + Peritoneal	1
Lymphogenous + Peritoneal	1
Lymphogenous + Haematogenous + Peritoneal + Pleural	1
Combination	6 (20)
Regional + distant	5
Local + regional + distant	1
Unknown	1 (3)
Total	30 (100)

Recurrence

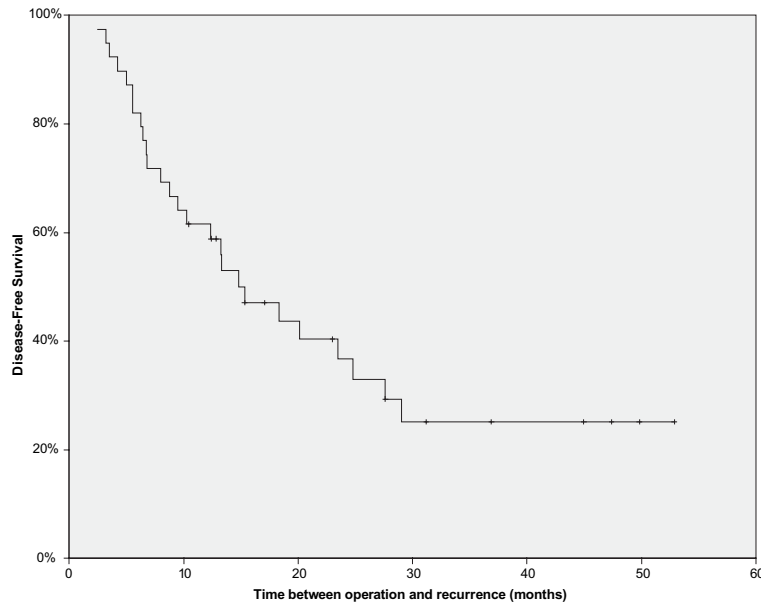
Since 3 (6%) patients had died in-hospital and 1 patient was diagnosed with liver metastases at the time of esophagectomy, 43 patients were evaluable for recurrence. At the time of analysis, all patients had undergone esophagectomy at least 12 months previously. None of these 43 patients were lost to follow-up. After a median follow-up interval of 35 (range 12-55) months, 13 (30%) of 43 patients had no symptomatic evidence of recurrent disease. The median follow-up of these 13 patients was 30 (range 12-54) months. In the 30 patients with symptomatic recurrent disease, the median time interval between esophagectomy and symptomatic tumor recurrence was 9 (range 3-29) months. Overall median disease-free survival was 15 (95% CI 12-18) months (Figure 6).

6

- _____ 1
- _____ 2
- _____ 3
- _____ 4
- _____ 5
- _____ 6
- _____ 7
- _____ 8
- _____ 9
- _____ 10
- _____ 11
- _____ 12
- _____ 13
- _____ 14
- _____ 15
- _____ 16
- _____ 17
- _____ 18
- _____ 19
- _____ 20
- _____ 21
- _____ 22
- _____ 23
- _____ 24
- _____ 25
- _____ 26
- _____ 27
- _____ 28
- _____ 29
- _____ 30
- _____ 31
- _____ 32

In Table 3 an overview is given on the first location of symptomatic tumor recurrence in the 30 patients with recurrent disease. In 1 patient with suspected recurrent disease based on the medical interview, no exact location of tumor recurrence could be registered, as the patient refused to undergo any diagnostic modality.

Figure 6 - Disease-free survival in 43 patients having undergone RTE and that were evaluable for follow-up.



DISCUSSION

Minimally invasive techniques for esophagectomy have been designed to reduce the morbidity of this major surgical procedure. Several clinical studies have reported MIE to be associated with a favourable outcome on blood loss and hospital stay when compared to open esophagectomy.^{5,15} Yet an ongoing debate continues on whether MIE, either conventional or robot-assisted, is oncologically equal to open esophagectomy. The current study reveals that RTE offers a lymphadenectomy and radical resection (R0) rate similar to open TTE.³ In addition, the median disease-free survival rate of 15 months in predominantly advanced (stage III-IVa) patients is comparable to open 2-field TTE.¹⁶ The extensive upper mediastinal LND provided by RTE has identified lymph node metastases

in almost 30% of patients with a distal esophageal or GEJ tumor (Figure 5). These lymph nodes would not have been dissected by a transhiatal approach,³ which is for many surgeons the preferred surgical approach in patients with a distal esophageal or GEJ tumor.

Due to the 3-dimensional magnified view of the operating field and the articulating surgical instruments, robotic systems facilitate a precise dissection in a confined operating space.⁶ Therefore, during RTE a proper mediastinal lymphadenectomy (Figure 4) including the carinal, aortopulmonary window and right paratracheal lymph node stations can be carried out. With a total of 757 dissected mediastinal lymph nodes in 47 patients, RTE has even provided a more extensive mediastinal LND when compared to open TTE (733 mediastinal lymph nodes in 51 patients with Barrett cancer).¹⁷ Overall, a median of 29 lymph nodes were dissected with RTE, which is comparable to the 31 lymph nodes reported in open TTE with 2-field LND.³ RTE has offered a more extensive lymphadenectomy when compared to conventional thoracoscopic esophagectomy. Berrisford et al.¹⁸ recently reported a median of 21 lymph nodes in 77 conventional thoracoscopic esophagectomies, while Smithers et al.¹⁵ found a median of 17 lymph nodes in 331 patients having undergone a thoracoscopic approach. With regard to tumor infiltration of the resection margins, the percentage of R0-resections in the current RTE series (77%) is similar to that of open TTE.³

The median disease-free survival of 15 months is in the range of open TTE having in mind that 60% of patients had stage IV disease.^{3,16} The relatively high amount of patients with stage IVa disease in our series could first of all be explained by the fact that our center is a tertiary referral center for esophageal cancer patients. Patients with localized disease are still treated in regional hospitals, whereas those having advanced stages are being referred. Secondly, the magnified view on the surgical field as provided by laparoscopy may have assisted in a more extensive dissection of the lymph nodes surrounding the celiac trunk. Yet, patients with M1a disease may have comparable survival to N1 patients.¹⁹ M1a disease is therefore not a contraindication for curative surgery, as also stated in the 2007 National Comprehensive Cancer Network (NCCN) Esophageal Cancer Clinical Practice Guidelines.¹⁴ Thirdly, it is generally acknowledged that it is difficult to distinguish locoregional lymph nodes (N1) located in the lesser omentum from those 1 cm near the origin of the left gastric artery and the celiac trunk (M1a).

6

- 1
- 2
- 3
- 4
- 5
- 6
- 7
- 8
- 9
- 10
- 11
- 12
- 13
- 14
- 15
- 16
- 17
- 18
- 19
- 20
- 21
- 22
- 23
- 24
- 25
- 26
- 27
- 28
- 29
- 30
- 31
- 32

- 1 —
- 2 —
- 3 —
- 4 —
- 5 —
- 6 —
- 7 —
- 8 —
- 9 —
- 10 —
- 11 —
- 12 —
- 13 —
- 14 —
- 15 —
- 16 —
- 17 —
- 18 —
- 19 —
- 20 —
- 21 —
- 22 —
- 23 —
- 24 —
- 25 —
- 26 —
- 27 —
- 28 —
- 29 —
- 30 —
- 31 —
- 32 —

6

A comparison on disease-free survival between RTE and conventional thoracoscopic esophagectomy is difficult to undertake, since the MIE case series reporting disease-free survival have in their initial experience predominantly treated patients with early stages of esophageal cancer.^{4,18}

The location of tumor recurrence was predominantly systemic (Table 3). Organ and peritoneal metastases occurred in 57% (17/30) of patients with tumor recurrence, which is somewhat higher compared to after open TTE (41%).²⁰ Yet, this is a reflection of early dissemination at the time of surgery rather than inadequate surgery. Since there is substantial evidence that neoadjuvant therapy significantly improves the survival in esophageal cancer by opposing early metastatic spread and by increasing the number of radical resections,²¹ preoperative chemotherapy is nowadays part of our routine treatment in patients with esophageal adenocarcinoma. This may increase the interval between surgery and tumor recurrence and may potentially decrease the number of patients with haematogenous recurrence.

In open TTE with 2-field LND or 3-field LND the reported rates of mediastinal recurrences were 21% and 35%, respectively.^{20,22} In our series, 8 (27%) patients with symptomatic recurrent disease have developed regional recurrence indicating that RTE provides for a proper mediastinal LND.

The operating time of RTE is relatively high when compared to open TTE.³ We had to deal with a changing team of surgical assistants and scrub nurses with variable experience in robotic surgery. Nonetheless, a significant decrease in operating time and in total blood loss was noticed over time (Figure 3), representing the learning curve of the surgeon and anaesthesiological team. Overall blood loss was substantially lower (625 milliliters) when compared to that of open TTE (1900 milliliters).^{3,23} Hospital stay was comparable to open TTE, but was higher than reported in MIE.^{3,4} This is partly due to the fact that the fast-track recovery program that is applied by other institutes has not been implemented in our hospital yet.⁴

Although currently the morbidity of RTE is comparable to that of open TTE, a reduction in pulmonary complication rate from 57% to 33% was noticed, which brings it in the range of the open transhiatal approach.³ The rate of recurrent nerve palsies of RTE is relatively high. This is a consequence of the extensive en bloc LND that is performed in the superior mediastinum. Since the recurrent nerve and its small branches are located in

the fatty tissue of the superior mediastinum, they might be partly damaged with the en bloc resection. The incidence of anastomotic leakage was relatively high.^{24,25} A possible explanation is the small (3-4 cm) diameter of the created gastric conduit created in the beginning of this series.⁹ Nowadays we make wider gastric tubes (5-6 cm), which has resulted in substantial reduction of anastomotic complications. With growing experience, we expect a further reduction in operating time, pulmonary complication rate and overall morbidity. When compared to conventional thoracoscopic series, (pulmonary) morbidity of RTE is presently higher.⁴ This is most probably a result of the substantially more extensive lymphadenectomy that is carried out during RTE.^{15,18} Secondly, this could be due to the position of the patient. During RTE, we place the patient in left lateral decubitus position, 45° tilted towards prone position. To accomplish optimal view on the mediastinum, the right lung is deflated. Deflation and reinflation of the lung may cause production of inflammatory mediators,²⁶ which may cause pulmonary complications. In case of a prone position of the patient, two-lung-ventilation can be preserved. This may further reduce the pulmonary complication rate.^{27,28}

In conclusion, RTE for esophageal cancer has offered a lymphadenectomy, radical resection rate and median disease-free survival comparable to open TTE. In addition, when compared to conventional thoracoscopic esophagectomy, RTE has provided a more extensive LND. At present, the morbidity is comparable to the open approach, but a substantial reduction in pulmonary complication rate has been noticed when comparing the first 23 to the last 24 operated patients representing our learning curve. With growing experience, a further reduction in operating time, pulmonary complication rate and overall morbidity is expected. Long-term overall survival data of a larger study population, preferably with an equal distribution of early and advanced stages of disease, have to be awaited to assess if overall survival of RTE is comparable to that of open TTE.

6

- _____ 1
- _____ 2
- _____ 3
- _____ 4
- _____ 5
- _____ 6
- _____ 7
- _____ 8
- _____ 9
- _____ 10
- _____ 11
- _____ 12
- _____ 13
- _____ 14
- _____ 15
- _____ 16
- _____ 17
- _____ 18
- _____ 19
- _____ 20
- _____ 21
- _____ 22
- _____ 23
- _____ 24
- _____ 25
- _____ 26
- _____ 27
- _____ 28
- _____ 29
- _____ 30
- _____ 31
- _____ 32

REFERENCES

1. Kamangar F, Dores GM, Anderson WF. Patterns of cancer incidence, mortality, and prevalence across five continents: defining priorities to reduce cancer disparities in different geographic regions of the world. *J Clin Oncol* 2006; 24:2137-2150.
2. Mariette C, Piessen G, Triboulet JP. Therapeutic strategies in oesophageal carcinoma: role of surgery and other modalities. *Lancet Oncol* 2007; 8:545-553.
3. Hulscher JB, van Sandick JW, de Boer AG, Wijnhoven BP, Tijssen JG, Fockens P, Stalmeier PF, ten Kate FJ, van Dekken H, Obertop H, Tilanus HW, van Lanschot JJ. Extended transthoracic resection compared with limited transhiatal resection for adenocarcinoma of the esophagus. *N Engl J Med* 2002; 347:1662-1669.
4. Luketich JD, Alvelo-Rivera M, Buenaventura PO, Christie NA, McCaughan JS, Litle VR, Schauer PR, Close JM, Fernando HC. Minimally invasive esophagectomy: outcomes in 222 patients. *Ann Surg* 2003; 238:486-494.
5. Gemmill EH and McCulloch P. Systematic review of minimally invasive resection for gastro-oesophageal cancer. *Br J Surg* 2007; 94:1461-1467.
6. Ruurda JP, van Vroonhoven TJ, Broeders IA. Robot-assisted surgical systems: a new era in laparoscopic surgery. *Ann R Coll Surg Engl* 2002; 84:223-226.
7. Camarillo DB, Krummel TM, Salisbury J. Robotic technology in surgery: Past, present, and future. *Am J Surg* 2004; 188:2-15.
8. Kernstine KH, DeArmond DT, Karimi M, Van Natta TL, Campos JC, Yoder MR, Everett JE. The robotic, 2-stage, 3-field esophagolymphadenectomy. *J Thorac Cardiovasc Surg* 2004; 127:1847-1849.
9. van Hillegersberg R, Boone J, Draaisma WA, Broeders IA, Giezeman MJ, Borel Rinkes IHM. First experience with robot-assisted thoracoscopic esophagolymphadenectomy for esophageal cancer. *Surg Endosc* 2006; 20:1435-1439.
10. Wittekind C, Greene FL, Hutter RVP, Klimpfinger M, Sobin LH TNM Atlas. Illustrated guide to the TNM/pTNM classification of malignant tumors. Berlin, Germany: Springer-Verlag, 2004.
11. Sato N, Koeda K, Ikeda K, Kimura Y, Aoki K, Iwaya T, Akiyama Y, Ishida K, Saito K, Endo S. Randomized study of the benefits of preoperative corticosteroid administration on the postoperative morbidity and cytokine response in patients undergoing surgery for esophageal cancer. *Ann Surg* 2002; 236:184-190.
12. Tugrul M, Camci E, Karadeniz H, Senturk M, Pembeci K, Akpir K. Comparison of volume controlled with pressure controlled ventilation during one-lung anaesthesia. *Br J Anaesth* 1997; 79:306-310.

13.	Boone J, Borel Rinkes IHM, van Hillegersberg R. Gastric conduit staple line after esophagectomy: to oversew or not? <i>J Thorac Cardiovasc Surg</i> 2006; 132:1491-1492.	1
14.	Ajani J, Bekaii-Saab T, D'Amico TA, Fuchs C, Gibson MK, Goldberg M, Hayman JA, Ilson DH, Javle M, Kelley S, Kurtz RC, Locker GY, Meropol NJ, Minsky BD, Orringer MB, Osarogiagbon RU, Posey JA, Roth J, Sasson AR, Swisher SG, Wood DE, Yen Y. Esophageal Cancer Clinical Practice Guidelines. <i>J Natl Compr Canc Netw</i> 2006; 4:328-347.	2
15.	Smithers BM, Gotley DC, Martin I, Thomas JM. Comparison of the outcomes between open and minimally invasive esophagectomy. <i>Ann Surg</i> 2007; 245:232-240.	3
16.	D'Journo XB, Doddoli C, Michelet P, Loundou A, Trousse D, Giudicelli R, Fuentes PA, Thomas PA. Transthoracic esophagectomy for adenocarcinoma of the oesophagus: standard versus extended two-field mediastinal lymphadenectomy? <i>Eur J Cardiothorac Surg</i> 2005; 27:697-704.	4
17.	Schroder W, Monig SP, Baldus SE, Gutschow C, Schneider PM, Holscher AH. Frequency of nodal metastases to the upper mediastinum in Barrett's cancer. <i>Ann Surg Oncol</i> 2002; 9:807-811.	5
18.	Berrisford RG, Wajed SA, Sanders D, Rucklidge MW. Short-term outcomes following total minimally invasive oesophagectomy. <i>Br J Surg</i> 2008; 95:602-610.	6
19.	Hulscher JB, Buskens CJ, Bergman JJ, Fockens P, van Lanschot JJ, Obertop H. Positive peritruncal nodes for esophageal carcinoma. not always a dismal prognosis. <i>Dig Surg</i> 2001; 18:98-101.	7
20.	Dresner SM and Griffin SM. Pattern of recurrence following radical oesophagectomy with two-field lymphadenectomy. <i>Br J Surg</i> 2000; 87:1426-1433.	8
21.	Gebski V, Burmeister B, Smithers BM, Foo K, Zalberg J, Simes J. Survival benefits from neoadjuvant chemoradiotherapy or chemotherapy in oesophageal carcinoma: a meta-analysis. <i>Lancet Oncol</i> 2007; 8:226-234.	9
22.	Nakagawa S, Kanda T, Kosugi S, Ohashi M, Suzuki T, Hatakeyama K. Recurrence pattern of squamous cell carcinoma of the thoracic esophagus after extended radical esophagectomy with three-field lymphadenectomy. <i>J Am Coll Surg</i> 2004; 198:205-211.	10
23.	Hulscher JB, Tijssen JG, Obertop H, van Lanschot JJ. Transthoracic versus transhiatal resection for carcinoma of the esophagus: a meta-analysis. <i>Ann Thorac Surg</i> 2001; 72:306-313.	11
24.	Walther B, Johansson J, Johnsson F, Von Holstein CS, Zilling T. Cervical or thoracic anastomosis after esophageal resection and gastric tube reconstruction: a prospective randomized trial comparing sutured neck anastomosis with stapled intrathoracic anastomosis. <i>Ann Surg</i> 2003; 238:803-812.	12
25.	Okuyama M, Motoyama S, Suzuki H, Saito R, Maruyama K, Ogawa J. Hand-sewn cervical anastomosis versus stapled intrathoracic anastomosis after esophagectomy for middle or lower thoracic esophageal cancer: a prospective randomized controlled study. <i>Surg Today</i> 2007; 37:947-952.	13

- 1 —
- 2 —
- 3 —
- 4 —
- 5 —
- 6 —
- 7 —
- 8 —
- 9 —
- 10 —
- 11 —
- 12 —
- 13 —
- 14 —
- 15 —
- 16 —
- 17 —
- 18 —
- 19 —
- 20 —
- 21 —
- 22 —
- 23 —
- 24 —
- 25 —
- 26 —
- 27 —
- 28 —
- 29 —
- 30 —
- 31 —
- 32 —

6

- 26. Funakoshi T, Ishibe Y, Okazaki N, Miura K, Liu R, Nagai S, Minami Y. Effect of re-expansion after short-period lung collapse on pulmonary capillary permeability and pro-inflammatory cytokine gene expression in isolated rabbit lungs. *Br J Anaesth* 2004; 92:558-563.
- 27. Dapri G, Himpens J, Cadiere GB. Robot-assisted thoracoscopic esophagectomy with the patient in the prone position. *J Laparoendosc Adv Surg Tech A* 2006; 16:278-285.
- 28. Dapri G, Himpens J, Cadiere GB. Minimally invasive esophagectomy for cancer: laparoscopic transhiatal procedure or thoracoscopy in prone position followed by laparoscopy? *Surg Endosc* 2008; 22:1060-1069.

- 1
- 2
- 3
- 4
- 5
- 6
- 7
- 8
- 9
- 10
- 11
- 12
- 13
- 14
- 15
- 16
- 17
- 18
- 19
- 20
- 21
- 22
- 23
- 24
- 25
- 26
- 27
- 28
- 29
- 30
- 31
- 32

7

Diseases of the Esophagus 2008; 21:90-3

Robot-assisted thoracoscopic esophagectomy for a giant upper esophageal leiomyoma

Judith Boone¹

Werner A. Draaisma¹

Marguerite E.I. Schipper²

Ivo A.M.J. Broeders¹

Inne H.M. Borel Rinkes¹

Richard van Hillegersberg¹

Departments of ¹Surgery and ²Pathology
University Medical Center Utrecht

ABSTRACT

This is the first report of a thoracoscopic esophagectomy for a giant leiomyoma of the upper esophagus aided by a robotic system. A 37-year-old man presented with progressive dysphagia and nocturnal aspiration. Endoscopic ultrasound and CT scan of the chest revealed an upper esophageal tumor of 9 × 4 cm arising from the muscularis mucosae. A fine needle aspiration showed clustering of mesenchymal cells, confirming the diagnosis of a stromal cell tumor. A mesenchymal malignancy was suspected because the tumor was located in the upper esophagus and was arising from the muscularis mucosae, both uncommon for a leiomyoma. Moreover, tumor size, an indicator of potential malignancy if >3 cm, was 9 cm. Therefore, an esophagectomy was performed thoracoscopically with the formation of a gastric conduit via laparotomy and a hand-sewn end-to-side cervical anastomosis. The thoracoscopic phase was performed with support of the da Vinci™ robotic system, which allowed for an excellent 3-dimensional view and a precise dissection of the esophagus along the vital mediastinal structures. The duration of the thoracoscopic part was 115 min and that of the total procedure was 270 min. Blood loss during the thoracoscopic phase was 50 mL; total blood loss was 200 mL. The patient was ventilated for 1 day; his total intensive care stay was 2 days. He left the hospital in good condition on the 11th postoperative day. Histopathological examination combined with immunohistochemistry revealed a leiomyoma of 9.0 × 5.0 × 2.5 cm. After 3 years of follow-up, the patient is in good health.

- 1 —
- 2 —
- 3 —
- 4 —
- 5 —
- 6 —
- 7 —
- 8 —
- 9 —
- 10 —
- 11 —
- 12 —
- 13 —
- 14 —
- 15 —
- 16 —
- 17 —
- 18 —
- 19 —
- 20 —
- 21 —
- 22 —
- 23 —
- 24 —
- 25 —
- 26 —
- 27 —
- 28 —
- 29 —
- 30 —
- 31 —
- 32 —

INTRODUCTION

Leiomyoma is the most common benign tumor of the esophagus, accounting for 70-80% of all benign esophageal neoplasms.¹ Generally, leiomyomas are solitary, well encapsulated submucosal tumors. Arising from smooth muscle cells, they are mainly located at the middle or lower third part of the esophagus.^{2,3} More than half the patients are asymptomatic.¹ Symptoms, predominantly dysphagia and retrosternal discomfort, occur mostly when tumor size becomes larger than 5 centimetres.^{1,2}

Therapy of choice in small leiomyomas is surgical enucleation because malignancy cannot otherwise be excluded and symptoms will arise or aggravate as tumor size increases.⁴ In general, giant leiomyoma (>8 cm) require esophagectomy, as enucleation would result in muscular defects too large to allow a tension-free suture.^{5,6} Moreover, large mesenchymal tumors are more suspicious for malignancy.⁷ When a mesenchymal malignancy of the esophagus is suspected, esophagectomy is indicated aiming at radical resection.⁶ As these malignancies only rarely spread to regional lymph nodes, a lymph node dissection can be omitted, unless nodal tumor involvement is established macroscopically during surgery.⁸

Since esophageal surgery is associated with a high morbidity,⁹ minimally invasive techniques have been introduced such as thoracoscopic and laparoscopic surgery.¹⁰ These techniques, however, are technically more demanding than open surgery due to a 2-dimensional vision, a disturbed eye-hand coordination and decreased degrees of freedom. Robotic systems have been developed to overcome these limitations. Advantages of robotic systems are a 3-dimensional vision, restoration of the natural eye-hand axis and enhanced dexterity due to articulated instruments.¹¹ In specialized centers, robotic systems are used to support delicate scopic procedures. Robotic systems may also be of added value in thoracoscopic esophageal tumor resection, to dissect precisely along vital structures such as the pulmonary vein, aorta or trachea.¹²

We report the first case of a robot-assisted thoracoscopic esophagectomy for a giant upper mesenchymal tumor of the esophagus in a young patient in which a mesenchymal malignancy was suspected.

1
2
3
4
5
6
7
8
9
10
11
7 12
13
14
15
16
17
18
19
20
21
22
23
24
25
26
27
28
29
30
31
32

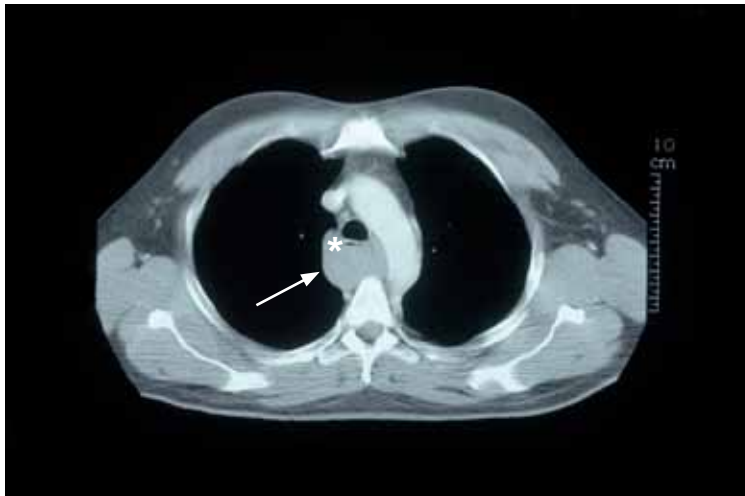MATERIALS AND METHODS

Patient

A 37-year-old man presented at our Outpatient Surgery Department with a five-month history of progressive dysphagia for solid food and nocturnal aspiration. Complaints of retrosternal pain, gastroesophageal reflux or weight loss were not present. Physical examination revealed no abnormalities.

Esophagogastroscopy showed normal esophageal mucosa with a luminal impression on 19 -24 cm from the incisor teeth. Subsequent endoscopic ultrasonography (EUS) demonstrated a hypoechoic, homogeneous tumor of 9 by 4 cm, arising from the muscularis mucosae. Fine needle aspiration (FNA) of the tumor showed clustering of mesenchymal cells, yet was inconclusive in distinguishing leiomyoma from a potentially malignant gastrointestinal stromal tumor (GIST) or a leiomyosarcoma. On computed tomography (CT)-scan of the chest, the tumor was located posteriorly to the esophagus, originating from the esophageal wall or the posterior mediastinum (Figure 1). Metastases in the liver or lung were not found. A mesenchymal malignancy was suspected since the tumor arose from the muscularis mucosae, was located at the upper esophagus and was 9 cm in length. A minimally invasive esophagectomy was performed.

Figure 1 - CT-scan of the chest. White arrow indicating the tumor originating from the esophageal wall or the posterior mediastinum. The esophageal lumen is indicated by the white asterisk.

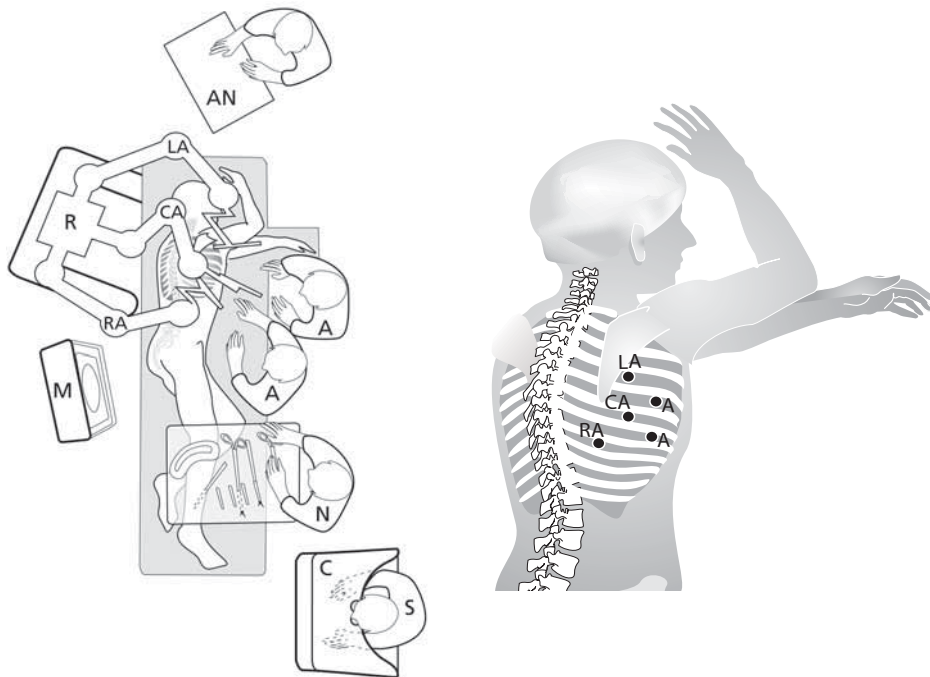


Surgical technique

The thoracoscopic phase was performed with support of the Da Vinci™ robotic system (Surgical Intuitive, Inc., Mountain View, CA). Under general anaesthesia, the patient was intubated with a double-lumen tube and placed in left lateral decubitus position, 45° tilted towards prone position. The robot was positioned on the dorso-cranial side of the patient (Figure 2). The robotic camera port was placed in 6th intercostal space posterior to the posterior axillary line. The left robotic port was placed in 4th intercostal space just anteriorly to the scapular rim and the right robotic port in 8th intercostal space more posteriorly than the left robotic port (Figure 3). Two additional ports were placed in the 5th and 7th intercostal spaces just posterior to the posterior axillary line for standard thoracoscopic assistance.

Figure 2 (left) - Schematic drawing of the set-up of the operating team during robot-assisted thoracoscopic esophageal resection. The da Vinci™ robotic system (R) is placed at the dorsocranial side of the patient. From behind the console (C) the surgeon (S) controls the robotic system and is assisted by two surgical assistants (A) and one scrub nurse (N). LA: left robotic arm; CA: camera arm; RA: right robotic arm; M: monitor; AN: anaesthesia team.

Figure 3 (right) - Schematic drawing of the positioning of the patient and placement of the trocars for connection of the robotic system and for conventional scopic assistance. LA: left robotic arm; RA: right robotic arm; CA: camera arm; A: conventional scopic assistance. See text for detailed explanation.



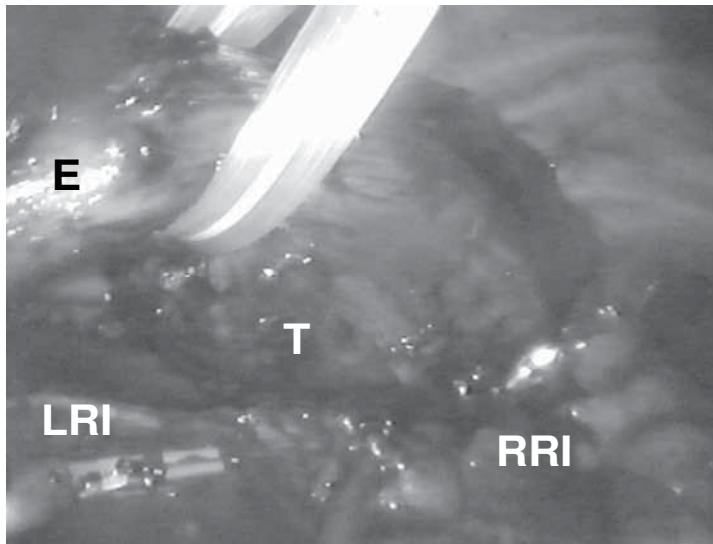
7

- 1
- 2
- 3
- 4
- 5
- 6
- 7
- 8
- 9
- 10
- 11
- 12
- 13
- 14
- 15
- 16
- 17
- 18
- 19
- 20
- 21
- 22
- 23
- 24
- 25
- 26
- 27
- 28
- 29
- 30
- 31
- 32

After division of the pulmonary ligament, the parietal pleura was divided at the anterior side up to the azygos vein. The azygos vein was ligated using clips and sutures. The giant esophageal tumor was located from the level of the azygos arch to the thoracic aperture (Figure 4). After dissection along the tumor, the parietal pleura was divided at the posterior side down the azygos vein and thoracic duct. The aorto-esophageal vessels were dissected and the thoracic duct was clipped at the level of the diaphragm. The right vagal nerve was identified and dissected below the level of the carina. Then, a penrose drain was placed around the esophagus to facilitate traction. In this way the entire thoracic esophagus was mobilized from the thoracic inlet to the diaphragmatic reflections.

7

Figure 4 - Thoracoscopic overview of the tumor (T). The esophagus (E) is lifted by a penrose drain.



LRI: left robotic instrument; RRI: right robotic instrument.

Through a laparotomy the greater and lesser curvature of the stomach were dissected and a gastric conduit was constructed with several linear GIA-staplers.

To create the cervical anastomosis, a right-sided approach is routinely performed in our institute. The rationale is that the cervical part of the thoracic duct, located at the left side of the neck, could be damaged during a left-sided approach, resulting in chylous leakage. Recently, we have changed this into the left-sided approach to

avoid bilateral recurrent nerve paresis. In short, a vertical incision of 10 cm is made at the anterior border of the sternocleido-mastoid muscle up to the cranial part of the manubrium sterni. Lateralisation of the great vessels with transection of the omohyoid muscle and ligation of the inferior thyroid artery. The right recurrent nerve is identified and preserved. Subsequently, the esophagus is mobilized circularly and transected. After removing the esophageal specimen via the abdomen and after placing the gastric conduit in the posterior mediastinum, a handsewn end-to-side esophagogastrostomy is made using one-layer PDS 3/0 running sutures.

RESULTS

Robotic set-up time consisting of sterile draping of the robotic arms and positioning of the robotic system next to the operation table was 9 minutes. Duration of the robot-assisted thoracoscopic phase was 115 minutes and of the total procedure 270 minutes. Blood loss during the thoracoscopic part was 50 ml; total amount of blood loss was 200 ml. There were no intraoperative complications.

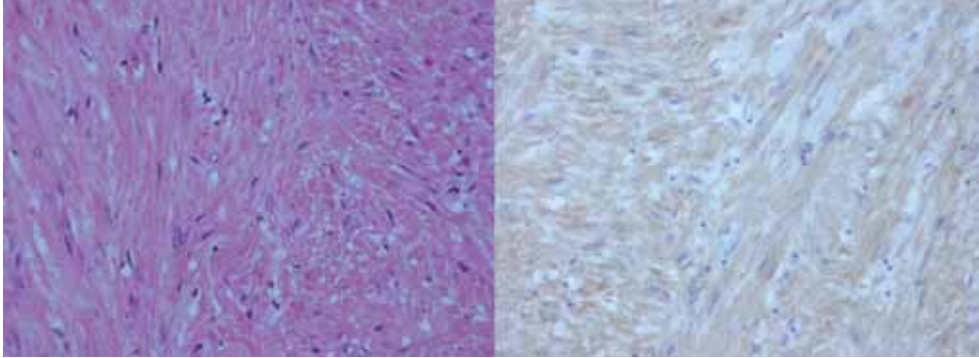
On the first day after surgery, the patient was extubated and on the second day he left the ICU. The patient was discharged home in good condition on the 11th postoperative day.

Gross examination of the resected specimen revealed an oval, sharply demarcated encapsulated submucosal mass of 9.0 x 5.0 x 2.5 cm. Histopathological examination displayed irregular bundles of spindle cells and low mitotic activity (1 mitosis / 2 mm²). Immunohistochemistry was negative for CD117 (c-KIT) and CD34, but positive for smooth muscle actin and desmin (Figure 5). So it was concluded to be a leiomyoma. At present, 3 years after surgery, the patient is in excellent health.

7

- 1
- 2
- 3
- 4
- 5
- 6
- 7
- 8
- 9
- 10
- 11
- 12
- 13
- 14
- 15
- 16
- 17
- 18
- 19
- 20
- 21
- 22
- 23
- 24
- 25
- 26
- 27
- 28
- 29
- 30
- 31
- 32

Figure 5 - Hematoxylin and eosin staining (left) and alpha-SMA immunohistochemical staining (right) of the mesenchymal tumor (magnification 200×) (see page 294 for color figure).



7

DISCUSSION

Although infrequent, leiomyoma is the most common benign esophageal tumor. The incidence reported in autopsy series varies from 0.006% to 0.1%.³ Esophageal leiomyomas are typically found in patients between 30 and 50 years old and are almost twice as common in men.^{3,5}

The diagnostic modalities of choice in the workup of a patient with an esophageal mesenchymal tumor are endoscopy, endoscopic ultrasound and CT-scan of the chest.⁵ Even with these diagnostic modalities, differentiating a benign from a malignant mesenchymal neoplasm before surgery is difficult.¹³ It is therefore not exceptional that a suspected mesenchymal malignancy turns out to be benign after resection,¹⁴ which also occurred in our patient. In our case, on EUS the tumor was shown to arise from the muscularis mucosae and was located in the upper esophagus, which are both uncommon for an esophageal leiomyoma.^{3,5} Moreover tumor size, which is an indicator of potential malignancy if > 3cm,⁷ was 9 cm. Although definitive diagnosis can only be made by histopathologic examination, FNA may help in determining the choice of esophagectomy or esophagus sparing enucleation, but should only be performed in case of suspicion of malignancy, as enucleation could be hampered by the previous puncture.⁵

Small leiomyomas are preferably resected by transthoracic enucleation and suturing

of the consequent muscular defect to prevent mucosal bulging.⁵ In tumors larger than 8 cm, enucleation would result in large muscular defects, necessitating application of a tissue flap. In these cases, esophagectomy is recommended.^{5,6,14} Esophagectomy is always indicated when a mesenchymal malignancy is suspected.

As conventional esophageal surgery is accompanied by high morbidity,⁹ minimally invasive surgical techniques have been developed.¹⁰ Robotic systems have been introduced to facilitate endoscopic surgery in a confined operating space. Recently, the first results of robot-assisted enucleation of 2 small esophageal leiomyomas (4.5 x 2.0 and 3.2 x 2.6 cm respectively) have been reported.¹⁵ In our patient, the large submucosal tumor of suspected malignant behaviour required esophagectomy, which was successfully performed thoracoscopically with support of the da Vinci™ robotic system. The robotic aid provided excellent 3-dimensional view and precise dissection of the esophagus along the vital mediastinal structures. This minimally invasive approach minimized total blood loss to 200 ml and resulted in a fast recovery of 11 days, compared to 19 days after open transthoracic esophagectomy.⁹ The relatively short hospital stay after thoracoscopic esophagectomy as described by Luketich can be attributed to the fast track recovery program, which is not available in our center so far.¹⁰

In our institute this robot-assisted thoracoscopic approach is now the preferred strategy for these giant tumors and for malignant esophageal neoplasms. However, further studies are needed to assess if a robot-assisted thoracoscopic approach is superior to the conventional thoracoscopic approach with regards to patient outcome.

In conclusion, robot-assisted thoracoscopic esophagectomy was performed with minimal blood loss and fast patient recovery for an upper giant esophageal leiomyoma which was suspected to be a malignant mesenchymal tumor.

7

1
2
3
4
5
6
7
8
9
10
11
12
13
14
15
16
17
18
19
20
21
22
23
24
25
26
27
28
29
30
31
32

REFERENCES

1. Seremetis MG, Lyons WS, deGuzman VC, Peabody JW. Leiomyomata of the esophagus. An analysis of 838 cases. *Cancer* 1976; 38:2166-2177.
2. Hatch GF, III, Wertheimer-Hatch L, Hatch KF, Davis GB, Blanchard DK, Foster RS, Skandalakis JE. Tumors of the esophagus. *World J Surg* 2000; 24:401-411.
3. Mutrie CJ, Donahue DM, Wain JC et al. Esophageal leiomyoma: a 40-year experience. *Ann Thorac Surg* 2005; 79:1122-1125.
4. Aurea P, Grazia M, Petrella F, Bazzocchi R. Giant leiomyoma of the esophagus. *European Journal of Cardio-Thoracic Surgery* 2002; 22:1008-1010.
5. Lee LS, Singhal S, Brinster CJ, Marshall B, Kochman ML, Kaiser LR, Kucharczuk JC. Current management of esophageal leiomyoma. *J Am Coll Surg* 2004; 198:136-146.
6. Cheng BC, Chang S, Mao ZF, Li MJ, Huang J, Wang ZW, Wang TS. Surgical treatment of giant esophageal leiomyoma. *World J Gastroenterol* 2005; 11:4258-4260.
7. Palazzo L, Landi B, Cellier C, Cuillerier E, Roseau G, Barbier JP. Endosonographic features predictive of benign and malignant gastrointestinal stromal cell tumours. *Gut* 2000; 46:88-92.
8. Blay J, Bonvalot S, Casali P et al. Consensus meeting for the management of gastrointestinal stromal tumors. Report of the GIST Consensus Conference of 20-21 March 2004, under the auspices of ESMO. *Ann Oncol* 2005; 16:566-578.
9. Hulscher JB, van Sandick JW, de Boer AG et al. Extended transthoracic resection compared with limited transhiatal resection for adenocarcinoma of the esophagus. *N Engl J Med* 2002; 347:1662-1669.
10. Luketich JD, Alvelo-Rivera M, Buenaventura PO et al. Minimally invasive esophagectomy: outcomes in 222 patients. *Ann Surg* 2003; 238:486-494.
11. Broeders IA and Ruurda JP. Robotics in laparoscopic surgery: current status and future perspectives. *Scand J Gastroenterol Suppl* 2002; 76-80.
12. van Hillegersberg R, Boone J, Draaisma WA, Broeders IA, Giezeman MJ, Borel Rinkes IHM. First experience with robot-assisted thoracoscopic esophagolymphadenectomy for esophageal cancer. *Surg Endosc* 2006; 20:1435-1439.
13. Kim TI, Park YS, Choi EH, Park SW, Chung JB, Kang JK, Song SY. Endoscopic resection of a large leiomyoma of the esophagus. *Gastrointest Endosc* 2004; 59:129-133.

- 14. Klaase JM, Hulscher JB, Offerhaus GJ, ten Kate FJ, Obertop H, van Lanschot JJ. Surgery for unusual histopathologic variants of esophageal neoplasms: a report of 23 cases with emphasis on histopathologic characteristics. *Ann Surg Oncol* 2003; 10:261-267.
- 15. Elli E, Espat NJ, Berger R, Jacobsen G, Knoblock L, Horgan S. Robotic-assisted thoracoscopic resection of esophageal leiomyoma. *Surg Endosc* 2004; 18:713-716.

- 1
- 2
- 3
- 4
- 5
- 6
- 7
- 8
- 9
- 10
- 11
- 12
- 13
- 14
- 15
- 16
- 17
- 18
- 19
- 20
- 21
- 22
- 23
- 24
- 25
- 26
- 27
- 28
- 29
- 30
- 31
- 32



PART II

MOLECULAR BIOLOGICAL
STRATEGIES

8

Validation of tissue microarray technology in squamous cell carcinoma of the esophagus

Judith Boone¹

Richard van Hillegersberg¹

Paul J. van Diest²

G. Johan A. Offerhaus²

Inne H.M. Borel Rinkes¹

Fiebo J.W. Ten Kate²

Departments of ¹Surgery and ²Pathology
University Medical Center Utrecht

ABSTRACT**Background**

Tissue microarray (TMA) technology has been developed to facilitate high throughput immunohistochemical and *in situ* hybridization analysis of tissues by inserting small tissue biopsy cores into a single paraffin block. Several studies have revealed novel prognostic biomarkers in esophageal squamous cell carcinoma (ESCC) by means of TMA technology, although this technique has not yet been validated for these tumors. Since representativeness of the donor tissue cores may be a disadvantage compared to full sections, the aim of this study was to assess if TMA technology provides representative immunohistochemical results in ESCC.

Materials and Methods

A TMA was constructed containing triplicate cores of 108 formalin-fixed, paraffin-embedded squamous cell carcinomas of the esophagus. The agreement in the differentiation grade and in immunohistochemical staining scores of CK5/6, CK14, E-cadherin, Ki-67 and p53 between TMA cores and a subset of 64 randomly selected donor paraffin blocks was determined using kappa statistics.

Results

The concurrence between TMA cores and donor blocks was moderate for Ki-67 ($\kappa=0.42$) and E-cadherin ($\kappa=0.47$), substantial for differentiation grade ($\kappa=0.65$) and CK14 ($\kappa=0.71$) and almost perfect for p53 ($\kappa=0.86$) and CK5/6 ($\kappa=0.93$).

Conclusion

TMA technology appears a valid method for immunohistochemical analysis of molecular markers in ESCC provided that the staining pattern in the tumor is homogeneous.

INTRODUCTION

Esophageal carcinoma is the 8th most common type of cancer in the world.¹ Although the recent rise in incidence of esophageal cancer has predominantly been caused by an increase in adenocarcinomas, the majority of esophageal cancer cases globally are squamous cell carcinomas.¹ For both histological types, radical en bloc esophagectomy with an extensive lymph node dissection offers the best chance for cure, leading to an overall 5-year survival rate of around 30%.^{2,3}

Well-known histopathological factors for prognostication of esophageal cancer include the TNM stage, the number of positive lymph nodes and the presence of extracapsular lymph node involvement.⁴⁻⁷ Recently, there has been a growing interest in the prognostic value of molecular markers in (esophageal) cancer.⁸ The expression of such markers is often studied by immunohistochemistry on formalin-fixed, paraffin-embedded tumor slides. Tissue microarray (TMA) technology has been developed to enable high throughput immunohistochemical analyses.⁹ By inserting small (diameter e.g. 0.6mm) donor tissue core biopsies into a single recipient paraffin block, this technique allows for rapid analysis of large numbers of tissues under standardized laboratory and evaluation conditions, without significantly damaging the patient's tissue. In addition, TMA technology leads to a significant reduction of the amount of consumables used and time needed for interpretation, increasing cost-effectiveness.

A potential disadvantage compared to full tissue sections is that the donor cores may not be representative for the whole tumor, particularly in case of heterogeneous tumors and heterogeneously expressed molecular markers. Hence, some validation studies have been performed in various cancers using different kinds of antibodies.¹⁰⁻¹⁷ Although several studies have revealed novel prognostic biomarkers in esophageal squamous cell cancer (ESCC) by means of TMA technology,¹⁸⁻²⁰ this technique has not yet been validated for these tumors.

The aim of the present study was therefore to validate TMA technology in ESCC by assessing the concurrence of immunohistochemical staining scores of established molecular markers with various expression patterns between triplicate 0.6mm core biopsies of the TMA and their whole tissue section counterparts.

1
2
3
4
5
6
7
8
9
10
11
12
13
14
15
16
17
18
19
20
21
22
23
24
25
26
27
28
29
30
31
32

MATERIALS AND METHODS

TMA construction

Formalin-fixed, paraffin-embedded tissues from thoracic ESCCs of consecutive patients having undergone esophagolymphadenectomy at the authors' institute between 1989 and 2006 were retrieved from the archives of the Department of Pathology. Patients who received neoadjuvant therapy were excluded from this study. The study was carried out in accordance with the ethical guidelines of our institution concerning informed consent about the use of patient's materials after surgical procedures.

By an experienced pathologist (FtK), 3 representative tumor regions were marked on one selected Haematoxylin and Eosin (H&E)-stained section of each tumor, avoiding areas of necrosis. From these 3 tumor regions, a tissue cylinder with a diameter of 0.6 mm was punched out of the corresponding paraffin block ('donor block') and placed into the TMA paraffin block using a manual tissue arrayer (MTA-I, Beecher Instruments Inc., Sun Prairie, USA), which was guided by the MTABooster® (Alphelys, Plaisir, France). The distribution and position of the cores was determined in advance with the TMA-designer Software (Alphelys-TMA Designer®, Version 1.6.8, Plaisir, France). Cores of normal esophageal mucosa, lymph node, kidney, liver, spleen and prostate were incorporated in the tissue array block as internal controls.

Immunohistochemistry

For each marker, a 4µm slide of the TMA and one of every selected donor paraffin block were immunohistochemically stained. Table 1 shows the details of all antibodies, dilutions, incubation times and antigen retrieval methods applied in this study.

For all stainings, sections were deparaffinized in xylene for 10 minutes followed by dehydration through graded alcohols. Endogenous peroxidase activity was blocked for 15 minutes in a buffer solution of pH5.8 (containing 8.32 g citric acid, 21.52 g disodium hydrogen phosphate, 2 g sodium azide in 1 litre of water) with hydrogen peroxide (0.3%). After antigen retrieval for 20 minutes, a cooling-down period of 30 minutes was followed by incubation with the primary antibody. Depending on the antibody used, slides were incubated with the secondary antibody followed by the streptavidin-biotin complex or slides were directly incubated with Powervision (details of both products shown in the

legend of Table 1). Then, the peroxidase reactivity was developed by 3,3'-diaminobenzidine for 10 minutes and slides were counterstained with Mayer's haematoxylin. In between steps, slides were washed with phosphate-buffered saline (pH 7.4).

Immunohistochemical scoring

By 2 observers (FtK and JB) conjointly, the degree of differentiation and the percentage of immunohistochemically stained tumor cells were determined in all TMA cores and in the full-sections of the selected donor blocks. Histologic grade was scored as well differentiated (G1), moderately differentiated (G2) or poorly differentiated (G3).²¹ Staining of p53 and Ki-67 were marked as negative (<10% of tumor nuclei stained), weakly positive (10–50%) or strongly positive (\geq 50%).^{22,23} Cytokeratin (CK)5/6 and CK14 staining were scored as negative (<10% of tumor cell cytoplasm stained), weakly positive (10-80%) or strongly positive (\geq 80%). E-cadherin expression was regarded negative when <50% of tumor cell membranes stained; positive when \geq 50% stained.^{24,25} Cores were considered lost if less than 10% of cells contained tumor ('sampling error') or when less than 10% of tissue was present ('absent core'). Cases were excluded if 2 out of 3 cores were lost. When the scores between the cores of a particular case differed, the most frequent score determined the overall score. In case of 3 different scores in one case, the middle score was chosen. When only 2 cores were available with both a different score, the case was excluded from further analysis.²⁶

Statistical analysis

Statistical analyses were performed using SPSS software for Windows (Version 12.0, SPSS, Chicago, IL). Sixty-four donor blocks (60% of the tumors incorporated in the TMA) were randomly chosen by means of a random selection function of SPSS. To determine the chance-corrected agreement between the immunohistochemical staining scores of TMA cores and large sections, the Cohen's weighted kappa (κ) statistic was calculated. Chance-corrected agreement was considered poor if $\kappa < 0.00$, slight if $0 < \kappa < 0.20$, fair if $0.21 < \kappa < 0.40$, moderate if $0.41 < \kappa < 0.60$, substantial if $0.61 < \kappa < 0.80$ and almost perfect if $0.81 < \kappa < 1.00$.²⁷ The overall agreement was defined as the percentage of correct agreement between the TMA and the donor blocks from the total number of cases.²⁸

Table 1 - Specification of antibodies used and details of tissue processing.

Primary Ab	Staining Pattern	Source*	Clone and Code	Antigen Retrieval	Dilution	Incubation Time	Detection**	Positive Control	Procedure
CK5/6	Cytoplasmic	Chemicon	D5/16 B4	EDTA pH 9.0	1:3,000	60 minutes/ room temp	Strept ABC	Breast	Autostainer
CK14	Cytoplasmic	Neomarkers	LL002	EDTA pH 9.0	1:400	60 minutes/ room temp	Powervision	Breast	Autostainer
E-cadherin	Membranous	Zymed	4A2C7	Citrate autoclave pH 6.0	1:200	60 minutes/ room temp	Powervision	Breast	Autostainer
MIB-1 (Ki-67)	Nuclear	Dako	M7240	Citrate pH 6.0	1:100	60 minutes/ room temp	Strept ABC	Tonsil	Autostainer
p53	Nuclear	Biogenex	BP53-12	Citrate pH 6.0	1:200	60 minutes/ room temp	Strept ABC	Serous adenocarcinoma of the endometrium	Autostainer

Ab = antibody

* Biogenex, Inc., San Ramon, Ca, USA; Chemicon, Chemicon International, Inc., Temecula, Ca, USA; Dako, DakoCytomation, Glostrup, Denmark; Neomarkers, Fremont USA; Zymed, Zymed Laboratories, Inc., San Francisco, Ca, USA.

** Strept ABC = biotinylated horse-anti-mouse Vector BA-2000, diluted 1:500 in PBS, followed by streptavidin-biotin complex, diluted 1:1000. Powervision ready to use (Poly-HRP-antiM/Rb/RtIgG biotin free, ImmunoVision Technologies, Norwell, Ca, USA)

RESULTS

Of the 324 (3x108) tumor tissue cores that were transferred into the TMA paraffin block, a median of 295 (91%) was available for immunohistochemical scoring on the 6 TMA-slides used in this study (Table 2). Of the 64 randomly selected cases, a median of 176 (92%) of 192 cores (3x64) was evaluable on the TMA-slides.

Table 2 - Overview of the amount of cores that were evaluable, absent or contained too little tumor in all 108 cases and in the 64 randomly selected cases on the TMA-slides.

	H&E	CK5/6	CK14	E-cadherin	Ki-67	p53	Median
Total TMA cases (n=108)							
No. of evaluable cores (%)	293 (90%)	309 (95%)	294 (91%)	306 (94%)	293 (90%)	295 (91%)	295 (91%)
No. of absent cores (%)	20 (6%)	7 (2%)	22 (7%)	9 (3%)	22 (7%)	22 (7%)	21 (7%)
No. of cores without tumor (%)	11 (4%)	8 (3%)	8 (3%)	9 (3%)	9 (3%)	7 (2%)	9 (3%)
Randomly selected TMA cases (n=64)							
No. of evaluable cores (%)	176 (92%)	187 (97%)	176 (92%)	185 (96%)	176 (92%)	176 (92%)	176 (92%)
No. of absent cores (%)	13 (7%)	3 (2%)	13 (7%)	4 (2%)	13 (7%)	13 (7%)	13 (7%)
No. of cores without tumor (%)	3 (2%)	2 (1%)	3 (2%)	3 (2%)	3 (2%)	3 (2%)	3 (2%)

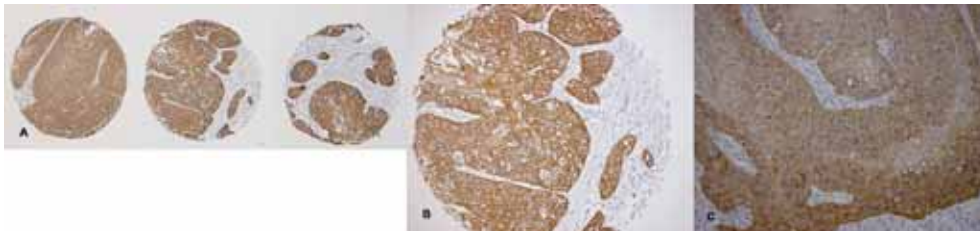
H&E = Haematoxylin and Eosin

On the H&E-stained TMA-slide, 49 (76%) of the 64 randomly chosen cases were represented by 3 cores; 14 (22%) by 2 cores. One (1.6%) case was excluded from further analysis because only a single core was available. The agreement in the scores for the grade of differentiation between the TMA cores and the full-sections is shown in Table 3. The weighted kappa score was 0.65.

Fifty-nine (92%) of the 64 randomly selected cases stained for CK5/6 were represented

by 3 cores (Figure 1); the 5 remaining cases by 2 cores. The immunohistochemical scores of the TMA and the donor blocks are shown in Table 4. Overall agreement in CK5/6 scores between the TMA and the donor blocks was 98%, with a kappa of 0.93.

Figure 1 - Example of strong CK5/6-staining in TMA cores and the corresponding full-section. (A) Three TMA cores representing one tumor; magnification 20x. (B) Enlargement of the middle TMA core depicted in (A); magnification 100x. (C) Part of the slide of the donor block of the same tumor; magnification 100x (see page 295 for color figure).



8

Figure 2 - Representative example of E-cadherin-staining in TMA cores and the corresponding full-section. (A) Three TMA cores representing one tumor; magnification 20x. (B) Enlargement of the right TMA core depicted in (A); magnification 100x. (C) Part of the slide of the donor block of the same tumor; magnification 100x (see page 295 for color figure).

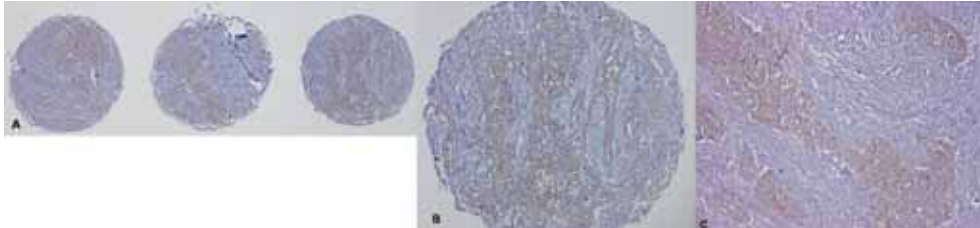
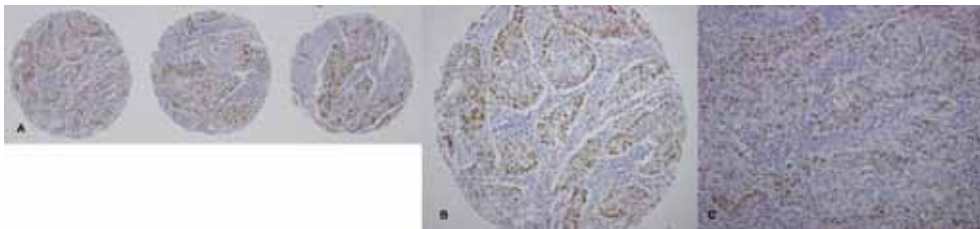


Figure 3 - Representative example of p53-staining in TMA cores and the corresponding full-section. (A) Three TMA cores representing one tumor; magnification 20x. (B) Enlargement of the left TMA core depicted in (A); magnification 100x. (C) Part of the slide of the donor block of the same tumor; magnification 100x (see page 295 for color figure).



For CK14, two cases were excluded since only 1 tumor core was left and 3 cases because the 2 available cores had discrepant immunohistochemical scores. Fifty (85%) of 59 cases had a complete agreement (Table 4). Four cases were scored 1 class higher on TMA when compared with the full-sections. Conversely, 5 other cases were classified lower on TMA, with 1 case 2 classes lower. Kappa score was 0.71.

Regarding E-cadherin staining, 3 assessable cores were present in 89% of the cases, two cores in 11%. Overall agreement in E-cadherin staining scores was accomplished in 72% of cases (Table 5). In one case, a higher score was found on the TMA compared to the full-section. In 17 cases, the expression of E-cadherin was scored lower on TMA than on the full-sections. The observed kappa was 0.47.

Table 3 - Agreement in the degree of differentiation between TMA cores and full sections.

		Full-section			Total	κ
		G1	G2	G3		
TMA	G1	2	3	0	5	0.65
	G2	2	21	2	25	
	G3	0	7	26	33	
	Total	4	31	28	63	

G1: well-differentiated, G2: moderately differentiated, G3: poorly differentiated

Three-core analysis of Ki-67 staining could be performed in 78% of selected cases and two-core-analysis in 19%. Two cases were represented by a single tumor core and were therefore excluded from further analysis. Ki-67 staining was scored as “moderate” on both TMA and full-sections in 42 (69%) of 61 selected cases. In 79% of cases, the Ki-67 scores of the TMA were similar to that of the full-sections. Thirteen cases were discordant (Table 6); kappa was 0.42.

With regard to p53 staining, two cores were present in 12 (19%) cases and 3 cores were available in 51 (80%) cases. One case was excluded as it was represented by only 1 TMA core. Complete agreement was achieved in 87% of the selected tumors (Table 6). In the 8 non-concordant cases, the difference was one class, resulting in a kappa of 0.86.

- 1
- 2
- 3
- 4
- 5
- 6
- 7
- 8
- 9
- 10
- 11
- 12
- 13
- 14
- 15
- 16
- 17
- 18
- 19
- 20
- 21
- 22
- 23
- 24
- 25
- 26
- 27
- 28
- 29
- 30
- 31
- 32

Table 4 - Agreement in immunohistochemical scores between TMA cores and full slides stained for CK5/6 and CK14

		Full-sections					
TMA	CK5/6	<10%	10-80%	≥80%	Total	κ	
TMA	<10%	1	1	0	2	0.93	
	10-80%	0	4	0	4		
	≥80%	0	0	58	58		
	Total	1	5	58	64		
		CK14					
	<10%	5	2	1	8	0.71	
	10-80%	0	11	2	13		
	≥80%	0	4	34	38		
	Total	5	17	37	59		

8

Table 5 - Agreement in immunohistochemical scores between TMA cores and full slides stained for E-cadherin.

		Full-sections				
TMA	E-cadherin	<50%	≥50%	Total	κ	
TMA	<50%	22	17	39	0.47	
	≥50%	1	24	25		
	Total	23	41	64		

Table 6 - Agreement in immunohistochemical scores between TMA cores and full slides stained for Ki-67 and p53.

		Full-sections					
TMA	Ki-67	<10%	10-50%	≥50%	Total	κ	
TMA	<10%	2	1	0	3	0.42	
	10-50%	3	42	3	48		
	≥50%	0	6	4	10		
	Total	5	49	7	61		
		p53					
	<10%	19	3	0	22	0.86	
	10-50%	0	1	2	3		
	≥50%	0	3	35	38		
	Total	19	7	37	63		

DISCUSSION

After its introduction in 1998, TMA technology has been applied in the immunohistochemical analysis of various malignancies, including squamous cell carcinomas and adenocarcinomas of the esophagus.^{20,29-33} Although it seems a very attractive method for high-throughput analysis of hundreds of tissues simultaneously, it may have limitations as the evaluation of the marker expression is reduced from full-section analysis to a few tissue cores of only 0.6mm in diameter, especially for proteins that are heterogeneously expressed or that are cell cycle dependent.³⁴ It is therefore essential to assess, in each type of cancer individually and for every molecular marker, whether or not TMA technology is feasible and valid.^{35,36} To our knowledge, this has not been done in esophageal cancer.

In our TMA containing triplicate cores of 108 ESCCs, a median of 9% of cores was uninformative (6% lost during tissue processing and 3% containing too little tumor), which is comparable to results reported in other studies.^{13,35,37} Improper selection of representative tumor areas on the donor block's H&E-slide by the pathologist or incorrect punching of these representative areas out of the donor block can cause tissue cores that contain too little tumor. Possible causes of absent cores are the size and fragility of the tumor tissue used and the aggressiveness of tissue processing applied.^{17,38,39}

Moreover, the number of available cores on the TMA-slide depends on the level at which the TMA paraffin block has been sectioned. The slides stained for H&E, CK14, Ki-67 and p53 were one of the first slides that were cut from our TMA block, whereas sections stained for CK5/6 and E-cadherin were taken slightly deeper. On these latter sections a lower number of absent cores was observed (Table 2), showing that not all cores were placed at the exact same level in the TMA block during TMA construction, mainly due to dissimilar thicknesses of the donor paraffin blocks that were used to construct the TMA.⁴⁰

The agreement in immunohistochemical results of the markers between our TMA and the full-sections varied from moderate to almost perfect (kappa 0.42 to 0.93), which is consistent with results reported in other TMA validation studies.^{11,13,17,35,38} The observed variation in agreement could be due to tumor heterogeneity, topographical variation in the expression pattern of the molecular marker or to the scoring criteria used.³⁸

Regarding tumor heterogeneity, the optimal amount of tissue cores incorporated in the TMA has been a matter of debate. Several validation studies have shown that 3 cores are highly representative for the full-section.^{12,15,26,41} The addition of a 4th core did not add to the percentage of agreement in a colorectal cancer TMA.¹⁵ Moreover, the more cores punched per case, the fewer cases can be placed into the TMA reducing throughput. Adding a 4th core may nevertheless be worthwhile in tissues prone to uninformative cores due to small lesions such as dysplasias or carcinomas in situ.³⁹ In our TMA the amount of uninformative cores was low (5-10%), probably because ESCCs have a large diameter, thereby increasing the chance of obtaining a core containing tumor tissue. Taken together, we consider it justified to utilize 3 biopsy cores in ESCCs. Nonetheless, using such a low amount of cores requires careful selection of the tumor regions by an experienced pathologist to deal with the heterogeneity of the tumor in the TMA.³⁶

The agreement between TMA and full-sections was substantial to almost perfect for cytokeratins 5/6 and 14. Since 91% of cases have shown a very strong expression of CK5/6 and only 1 of 64 cases showed negative staining, this molecular marker does not subdivide ESCCs and consequently will not be a prognostic marker for this malignancy. CK14 was more evenly distributed over the 3 scoring groups, but since 1 case was scored 2 classes lower on TMA when compared to the full-section, kappa was lower when compared to CK5/6.

The relatively moderate concordance in case of Ki-67 may be explained by the fact that almost 80% of cases were situated in 1 category (staining of 10-50% of tumor cells) with 13 discordant cases deviating from this category. E-cadherin also had a moderate concordance, mainly since the relatively faint staining intensity of this molecular maker made its assessment in our TMA very difficult (Figure 2).

TMA technology was also found to be valid for determining the histologic grade of differentiation in ESCC. Complete agreement between TMA and full-sections occurred in 78% (49 out of 63; kappa 0.65) of selected cases, which is high when compared to the 40% agreement achieved in a TMA of bladder cancer.⁴² Due to its homogeneous staining pattern, p53 showed excellent concordance (κ 0.86) in our microarray (Figure 3).

The concurrence between the TMA and the full-sections is affected by the cut-off values of the immunohistochemical scoring system of the stainings as well.^{13,38} The

application of a 2-class scoring system in an endometrial cancer TMA improved kappa to 1.0 compared to 0.81 with a 3-class system.¹³ In our study, the 2-class scoring system did not substantially affect the kappa (data not shown). Since the E-cadherin expression had a very low intensity in our ESCCs, we have chosen to apply a 2-class system. In addition, the cut-off values indicating a strong immunohistochemical expression were set higher in the cytokeratins (80%) than in the other molecular markers (cut-off value 50%), because otherwise practically all tumors would be designated having a strong expression of cytokeratins.

Now our esophageal cancer TMA has been validated, it will be used to correlate the expression of various molecular pathways with clinicopathologic data, aiming at detecting markers of prognostic significance and molecular targets for new therapies. Since the agreement between TMA slides and full-sections depended on the molecular marker stained for, it should be considered to assess the expression pattern of a marker on a full-section first, before staining a TMA slide. When a focal or heterogeneous expression pattern is noticed, it might be more valuable to assess marker expression by means of full-sections instead of TMA. On the other hand, when a marker shows a homogeneously diffuse expression pattern, staining a TMA slide does allow for high throughput screening of tumors. When a prognostic molecular marker has been identified by means of TMA technology, it is recommended to verify the results by full-section analysis.

In conclusion, this study has demonstrated TMA technology to be a valid method for immunohistochemical analysis in ESCC with agreement levels for well-known molecular markers with different staining potential between TMA and full-sections ranging from moderate to almost perfect.

1
2
3
4
5
6
7
8
9
10
11
12
13
14
15
16
17
18
19
20
21
22
23
24
25
26
27
28
29
30
31
32

REFERENCES

1. Kamangar F, Dores GM, Anderson WF. Patterns of cancer incidence, mortality, and prevalence across five continents: defining priorities to reduce cancer disparities in different geographic regions of the world. *J Clin Oncol* 2006; 24:2137-2150.
2. Alexiou C, Khan OA, Black E et al. Survival After Esophageal Resection for Carcinoma: The Importance of the Histologic Cell Type. *Ann Thorac Surg* 2006; 82:1073-1077.
3. Mariette C, Piessen G, Triboulet JP. Therapeutic strategies in oesophageal carcinoma: role of surgery and other modalities. *Lancet Oncol* 2007; 8:545-553.
4. Lagarde SM, ten Kate FJ, de Boer DJ, Busch OR, Obertop H, van Lanschot JJ. Extracapsular lymph node involvement in node-positive patients with adenocarcinoma of the distal esophagus or gastroesophageal junction. *Am J Surg Pathol* 2006; 30:171-176.
5. Pedrazzani C, deManzoni G, Marrelli D, Giacomuzzi S, Corso G, Bernini M, Roviello F. Nodal staging in adenocarcinoma of the gastro-esophageal junction. Proposal of a specific staging system. *Ann Surg Oncol* 2007; 14:299-305.
6. Rizk N, Venkatraman E, Park B, Flores R, Bains MS, Rusch V. The prognostic importance of the number of involved lymph nodes in esophageal cancer: Implications for revisions of the American Joint Committee on Cancer staging system. *J Thoracic Cardiovasc Surg* 2006; 132:1374-1381.
7. Takeno S, Noguchi T, Takahashi Y, Fumoto S, Shibata T, Kawahara K. Assessment of clinical outcome in patients with esophageal squamous cell carcinoma using TNM classification score and molecular biological classification. *Ann Surg Oncol* 2007; 14:1431-1438.
8. Nair KS, Naidoo R, Chetty R. Expression of cell adhesion molecules in oesophageal carcinoma and its prognostic value. *J Clin Pathol* 2005; 58:343-351.
9. Kononen J, Bubendorf L, Kallioniemi A et al. Tissue microarrays for high-throughput molecular profiling of tumor specimens. *Nat Med* 1998; 4:844-847.
10. Camp RL, Charette LA, Rimm DL. Validation of tissue microarray technology in breast carcinoma. *Lab Invest* 2000; 80:1943-1949.
11. Chen B, van den Brekel MW, Buschers W, Balm AJ, van Velthuisen ML. Validation of tissue array technology in head and neck squamous cell carcinoma. *Head Neck* 2003; 25:922-930.
12. Fernebro E, Dictor M, Bendahl PO, Ferno M, Nilbert M. Evaluation of the tissue microarray technique for immunohistochemical analysis in rectal cancer. *Arch Pathol Lab Med* 2002; 126:702-705.
13. Fons G, Hasibuan SM, Velden JV, Kate FJ. Validation of tissue micro array technology in endometrioid cancer of the endometrium. *J Clin Pathol* 2007; 60:500-503.

14.	Griffin MC, Robinson RA, Trask DK. Validation of tissue microarrays using p53 immunohistochemical studies of squamous cell carcinoma of the larynx. <i>Mod Pathol</i> 2003; 16:1181-1188.	1
15.	Jourdan F, Sebbagh N, Comperat E et al. Tissue microarray technology: validation in colorectal carcinoma and analysis of p53, hMLH1, and hMSH2 immunohistochemical expression. <i>Virchows Arch</i> 2003; 443:115-121.	2
16.	Pacifico MD, Grover R, Richman P, Daley F, Wilson GD. Validation of tissue microarray for the immunohistochemical profiling of melanoma. <i>Melanoma Res</i> 2004; 14:39-42.	3
17.	Van den Eynden GG, Van dA, I, Van Laere S et al. Validation of a tissue microarray to study differential protein expression in inflammatory and non-inflammatory breast cancer. <i>Breast Cancer Res Treat</i> 2004; 85:13-22.	4
18.	Xu F, Zhong W, Li J, Shanshen Z, Cui J, Nesland JM, Suo Z. Predictive value of EphA2 and EphrinA-1 expression in oesophageal squamous cell carcinoma. <i>Anticancer Res</i> 2005; 25:2943-2950.	5
19.	Xu FP, Xie D, Wen JM et al. SRC-3/AIB1 protein and gene amplification levels in human esophageal squamous cell carcinomas. <i>Cancer Letters</i> 2007; 245:69-74.	6
20.	Xue LY, Hu N, Song YM et al. Tissue microarray analysis reveals a tight correlation between protein expression pattern and progression of esophageal squamous cell carcinoma. <i>BMC Cancer</i> 2006; 6:296.	7
21.	Wittekind C, Greene FL, Hutter RVP, Klimpfinger M, Sobin LH TNM Atlas. Illustrated guide to the TNM/pTNM classification of malignant tumors. Berlin, Germany: Springer-Verlag, 2004.	8
22.	Han U, Can OI, Han S, Kayhan B, Onal BU. Expressions of p53, VEGF C, p21: could they be used in preoperative evaluation of lymph node metastasis of esophageal squamous cell carcinoma? <i>Dis Esophagus</i> 2007; 20:379-385.	9
23.	Xu M, Jin YL, Fu J et al. The abnormal expression of retinoic acid receptor-beta, p 53 and Ki67 protein in normal, premalignant and malignant esophageal tissues. <i>World J Gastroenterol</i> 2002; 8:200-202.	10
24.	Sato F, Shimada Y, Watanabe G, Uchida S, Makino T, Imamura M. Expression of vascular endothelial growth factor, matrix metalloproteinase-9 and E-cadherin in the process of lymph node metastasis in oesophageal cancer. <i>Br J Cancer</i> 1999; 80:1366-1372.	11
25.	Shiozaki H, Doki Y, Yamana H, Isono K. A multi-institutional study of immunohistochemical investigation for the roles of cyclin D1 and E-cadherin in superficial squamous cell carcinoma of the esophagus. <i>J Surg Oncol</i> 2002; 79:166-173.	12
26.	Hoos A, Urist MJ, Stojadinovic A et al. Validation of tissue microarrays for immunohistochemical profiling of cancer specimens using the example of human fibroblastic tumors. <i>Am J Pathol</i> 2001; 158:1245-1251.	13

1
2
3
4
5
6
7
8
9
10
11
12
13
14
15
16
17
18
19
20
21
22
23
24
25
26
27
28
29
30
31
32

27. Landis JR and Koch GG. The measurement of observer agreement for categorical data. *Biometrics* 1977; 33:159-74.
28. Kundel HL and Polansky M. Measurement of Observer Agreement. *Radiology* 2003; 228:303-308.
29. Chen AG, Yu ZC, Yu XF, Cao WF, Ding F, Liu ZH. Overexpression of Ets-like protein 1 in human esophageal squamous cell carcinoma. *World J Gastroenterol* 2006; 12:7859-7863.
30. Cheng MF, Tzao C, Tsai WC et al. Expression of EMMPRIN and matriptase in esophageal squamous cell carcinoma: Correlation with clinicopathological parameters. *Dis Esophagus* 2006; 19:482-486.
31. Langer R, Von Rahden BH, Nahrig J et al. Prognostic significance of expression patterns of c-erbB-2, p53, p16INK4A, p27KIP1, cyclin D1 and epidermal growth factor receptor in oesophageal adenocarcinoma: a tissue microarray study. *J Clin Pathol* 2006; 59:631-634.
32. Liu W, Yu ZC, Cao WF, Ding F, Liu ZH. Functional studies of a novel oncogene TGM3 in human esophageal squamous cell carcinoma. *World J Gastroenterol* 2006; 12:3929-3932.
33. Reichelt U, Duesedau P, Tsourlakis MC et al. Frequent homogeneous HER-2 amplification in primary and metastatic adenocarcinoma of the esophagus. *Mod Pathol* 2007; 20:120-129.
34. van Diest PJ, Vleugel M, van der Groep P, van der Wall E. VEGF-D and HIF-1alpha in breast cancer. *J Clin Pathol* 2005; 58:335.
35. Gomaa W, Ke Y, Fujii H, Helliwell T. Tissue microarray of head and neck squamous carcinoma: validation of the methodology for the study of cutaneous fatty acid-binding protein, vascular endothelial growth factor, involucrin and Ki-67. *Virchows Arch* 2005; 447:701-709.
36. Tawfik El-Mansi M and Williams AR. Validation of tissue microarray technology using cervical adenocarcinoma and its precursors as a model system. *Int J Gynecol Cancer* 2006; 16:1225-1233.
37. Rosen DG, Huang X, Deavers MT, Malpica A, Silva EG, Liu J. Validation of tissue microarray technology in ovarian carcinoma. *Mod Pathol* 2004; 17:790-797.
38. Su Y, Shrubsole MJ, Ness RM, Cai Q, Kataoka N, Washington K, Zheng W. Immunohistochemical expressions of Ki-67, cyclin D1, beta-catenin, cyclooxygenase-2, and epidermal growth factor receptor in human colorectal adenoma: a validation study of tissue microarrays. *Cancer Epidemiol Biomarkers Prev* 2006; 15:1719-1726.
39. Yang XR, Charette LA, Garcia-Closas M et al. Construction and validation of tissue microarrays of ductal carcinoma in situ and terminal duct lobular units associated with invasive breast carcinoma. *Diagn Mol Pathol* 2006; 15:157-161.
40. Tzankov A, Went P, Zimpfer A, Dirnhofer S. Tissue microarray technology: principles, pitfalls and perspectives--lessons learned from hematological malignancies. *Exp Gerontol* 2005; 40:737-744.

- 41. Rubin MA, Dunn R, Strawderman M, Pienta KJ. Tissue microarray sampling strategy for prostate cancer biomarker analysis. *Am J Surg Pathol* 2002; 26:312-319.
- 42. Nocito A, Bubendorf L, Tinner EM et al. Microarrays of bladder cancer tissue are highly representative of proliferation index and histological grade. *J Pathol* 2001; 194:349-357.

- 1
- 2
- 3
- 4
- 5
- 6
- 7
- 8
- 9
- 10
- 11
- 12
- 13
- 14
- 15
- 16
- 17
- 18
- 19
- 20
- 21
- 22
- 23
- 24
- 25
- 26
- 27
- 28
- 29
- 30
- 31
- 32

9

Submitted for publication

**Targets for molecular therapy in
esophageal squamous cell carcinoma:
an immunohistochemical analysis**

Judith Boone¹

Richard van Hillegersberg¹

G. Johan A. Offerhaus²

Paul J. van Diest²

Inne H.M. Borel Rinkes¹

Fiebo J.W. Ten Kate²

Departments of ¹Surgery and ²Pathology
University Medical Center Utrecht

ABSTRACT

Background

Neoadjuvant chemotherapy may improve the outcome of esophageal cancer after esophagectomy, but is accompanied by considerable toxicity by collateral destruction of normal cells. Such side-effects may be avoided by developing therapies that specifically target molecular characteristics of tumors. Aim of the present study was to determine the proportion of esophageal squamous cell carcinoma (ESCC) patients that could possibly benefit from (a combination of) currently available targeted therapies, by assessing the frequency of immunohistochemical expression of their target molecular markers in ESCC tissues.

Materials and methods

Sections from a validated tissue microarray comprising 108 ESCCs were immunohistochemically stained for Bcl-2, c-KIT, cyclo-oxygenase-2 (COX-2), cyclin D1, estrogen receptor (ER), epidermal growth factor receptor (EGFR), Her-2/neu, progesterone receptor (PR) and vascular endothelial growth factor (VEGF).

Results

VEGF, cyclin D1, EGFR and COX-2 could be detected in 55%, 42%, 40% and 40%, respectively. Her-2/neu, Bcl-2 and c-KIT were detected in 12%, 11%, and 10% of the tumors, respectively. No nuclear expression of ER or PR was noticed. The concurrent expression of 2 of the most frequently expressed markers (VEGF, cyclin D1, EGFR and COX-2) ranged from 11% (COX-2 and EGFR) to 26% (cyclin D1 and VEGF). The expression of all 4 markers was seen in 5% of ESCCs.

Conclusion

Promising targets for molecular therapy in ESCC appear COX-2, VEGF, EGFR and cyclin D1, since they are frequently overexpressed. Phase II clinical studies on these molecular markers may therefore be warranted. The role for targeted therapy against ER, PR, Her-2/neu, c-KIT or Bcl-2 in ESCC seems limited.

INTRODUCTION

With an estimated 462.000 newly diagnosed patients in 2002, esophageal carcinoma is the 8th most common type of malignancy in the world.¹ Although the recent rise in incidence of esophageal cancer has predominantly been caused by an increase in adenocarcinomas, the majority of esophageal cancer cases worldwide are squamous cell carcinomas. For patients with locoregional disease, surgical resection is the best treatment option for cure.² Yet, overall survival after resection is relatively poor with 5-year survival rates of around 35%, due to early tumor recurrence and early occurrence of metastatic disease.^{3,4}

A recent meta-analysis of randomized controlled trials (RCTs) has revealed that neoadjuvant chemo(radio)therapy could improve the survival after esophagectomy for esophageal cancer⁵ by increasing resectability and by opposing metastatic spread. As conventional chemotherapeutic agents are moderately specific for tumor cells, they are frequently accompanied by considerable toxicity.^{6,7} Consequently, many patients fail to complete their chemotherapy. With the increasing knowledge on molecular carcinogenesis, therapies have been developed directed against biological characteristics of tumors. In this way, selective destruction of tumor cells can be accomplished, possibly leading to increased efficiency and specificity with a reduction in toxicity of the therapy. Moreover, it allows for therapy tailored to the patient's individual tumor.

Targeted therapy can act at various molecular pathways, e.g. that of growth factor receptors (epidermal growth factor receptor [EGFR] and Her-2/neu), the cell cycle (cyclin-dependent kinases), apoptosis (Bcl-2) or angiogenesis (vascular endothelial growth factor [VEGF]).⁸ For breast carcinoma patients with a positive expression of molecular markers such as estrogen receptor (ER), progesterone receptor (PR) or Her-2/neu, targeted therapy against these molecules has nowadays been integrated into the standard adjuvant treatment regimen as several RCTs have shown a significant improvement in disease-free and overall survival.⁹⁻¹¹ In order to guide targeted therapy, analysis of the expression of these molecular markers is essential and is part of the routine histopathologic examination in breast cancer.¹²

In irresectable or recurrent esophageal cancer some phase II trials have been performed on the addition of targeted therapy to conventional chemotherapy, with variable

1
2
3
4
5
6
7
8
9
10
11
12
13
14
15
16
17
18
19
20
21
22
23
24
25
26
27
28
29
30
31
32

1 — results.^{8,13-16} The question remains which particular molecular marker(s) need targeting.
2 — The aims of the present study were therefore to determine the frequency of the
3 — immunohistochemical expression in esophageal squamous cell carcinoma (ESCC) of
4 — markers that are targets for currently available molecular therapies and to determine the
5 — coexpression of these markers, in that way assessing the proportion of ESCC patients
6 — that could potentially benefit from (a combination of) such targeted therapy.

9 MATERIALS AND METHODS

Tissue microarray (TMA) construction

11 — Formalin-fixed, paraffin-embedded tissues from thoracic ESCCs of 108 consecutive
12 — patients having undergone esophagectomy at the authors' institute between 1989 and
13 — 2006 were retrieved from the archives of the Department of Pathology. Patients who
14 — received neoadjuvant therapy were excluded. The study was carried out in accordance
15 — with the ethical guidelines of our institution concerning informed consent about the
16 — use of patient's materials after surgical procedures.¹⁷

17 — The construction of our TMA has extensively been described in a previous paper.¹⁸ In
18 — short, on 1 selected H&E-stained section of each tumor, 3 representative tumor areas
19 — were microscopically marked avoiding regions of necrosis. From these 3 tumor areas, a
20 — small tissue cylinder (diameter 0.6 mm) was punched out of the corresponding paraffin
21 — block and placed into the TMA paraffin block using a manual tissue arrayer (MTA-I,
22 — Beecher Instruments Inc., Sun Prairie, USA), which was guided by the MTABooster®
23 — (Alphelys, Plaisir, France). Recently, we have validated our TMA for well-known molecular
24 — markers.¹⁸


Immunohistochemistry

25 — In Table 1, an overview is given on the details of all primary antibodies, dilutions,
26 — incubation times and antigen retrieval methods applied in this study. TMA-sections
27 — (4µm) were immunohistochemically stained for Bcl-2, c-KIT, cyclin D1, Her-2/neu, ERα
28 — and PR using an automatic staining machine (Bond™ System, Leica Microsystems
29 — GmbH, Wetzlar, Germany) and a biotin-free Bond™ Polymer Define Detection System
30 — (Leica Microsystems GmbH, Catalog no DS9800).
31 —
32 —

Table 1 - Specification of primary antibodies used and details of tissue processing

Primary Ab	Staining Pattern	Source*	Clone and Code	Antigen Retrieval	Dilution	Incubation Time	Procedure
Bcl-2	Cytoplasmic	Dako	M0887	Bond™ epitope retrieval solution 1	1:100	15 min	Autostainer
c-KIT	Cytoplasmic	Dako	A4502	Bond™ epitope retrieval solution 2	1:200	15 min	Autostainer
COX-2	Cytoplasmic	Cayman Chemical	160112	Citrate pH6.0	1:200	20 min	Manual
Cyclin D1	Nuclear	Neomarkers	RM9104-s	Bond™ epitope retrieval solution 2	1:80	15 min	Autostainer
EGFR	Membranous	Zymed	31G7	Protein K	1:30	Over night	Manual
ER	Nuclear	Dako	M7047	Bond™ epitope retrieval solution 1	1:80	15 min	Autostainer
Her-2/neu	Membranous	Neomarkers	RM9103-s	Bond™ epitope retrieval solution 2	1:100	15 min	Autostainer
PR	Nuclear	Dako	M3569	Bond™ epitope retrieval solution 1	1:100	15 min	Autostainer
VEGF	Cytoplasmic	Santa Cruz	A20; Sc-152	Citrate pH6.0	1:1500	Over night	Manual

Legend: Ab = antibody. * Cayman Chemical Company, Inc., Ann Arbor, MI, USA; Dako, DakoCytomation, Glostrup, Denmark; Neomarkers, Fremont USA; Santa Cruz Biotechnology, Inc., Santa Cruz, Ca, USA; Zymed, Zymed Laboratories, Inc., San Francisco, Ca, USA.



1 —
2 —
3 —
4 —
5 —
6 —
7 —
8 —
9 —
10 —
11 —
12 —
13 —

For VEGF, slides were stained manually. After deparaffinization and dehydration, endogenous peroxidase was blocked for 30 minutes with a blocking buffer solution of pH5.8 (containing 8.32g citric acid, 21.52g disodium hydrogen phosphate, 2g sodium azide in 1 liter of water) with hydrogen peroxide (0.3%). Antigen retrieval was carried out for 20 minutes. After a cooling-off period of 30 minutes, slides were incubated with normal goat serum (Dako, Glostrup, Denmark, catalogue# X0907; dilution 1:50). Incubation with the primary antibody took place in normal goat serum overnight. The next day, slides were incubated with a polymerized horseradish peroxidase-conjugated goat anti-rabbit IgG (PowerVision; ImmunoVision Technologies, Norwell, MA, USA). The peroxidase reactivity was developed by 3,3'-diaminobenzidine for 10 minutes and slides were counterstained with Mayer's haematoxylin. Between all steps, slides were washed in phosphate-buffered saline with a pH of 7.4. Appropriate positive and negative controls were used throughout.

9

14 —
15 —
16 —
17 —
18 —
19 —
20 —
21 —
22 —

The immunohistochemistry staining protocol for COX-2 has extensively been described in a previous manuscript.¹⁹ For EGFR, antigen retrieval was carried out with Protein K for 5 minutes after deparaffinization, dehydration and blocking of endogenous peroxidase. Following incubation with the primary antibody, immunoreactivity was visualized with the Novolink™ polymer detection system (Leica Microsystems GmbH, Catalog no RE7280-k). The peroxidase reactivity was developed by 3,3'-diaminobenzidine and slides were counterstained with haematoxylin.

Immunohistochemical scoring

23 —
24 —
25 —
26 —

The immunohistochemical staining of all TMA cores was scored conjointly by 2 observers (FtK and JB). Cores were considered lost if less than 10% of the tissue contained tumor ('sampling error') or when less than 10% of tissue was present ('absent core'). Cases were excluded if 2 out of 3 cores were lost.

27 —
28 —
29 —
30 —
31 —
32 —

Staining of cyclin D1, ER α and PR were scored as 0 (no staining), 1 (<10% of tumor nuclei stained) or 2 (\geq 10%). Bcl-2 and c-KIT were scored as 0 (no staining or weak cytoplasmic staining), 1 (moderate cytoplasmic staining) or 2 (strong). Tumors were considered positive if they had a score of 1 or 2. The highest score determined the overall score of the tumor. Her-2/neu expression was scored according to the Dako scoring system.²⁰ EGFR was scored as 0 (no membranous staining), 1 (weak, membranous staining comparable to

normal esophageal epithelium), 2 (moderate membranous staining, stronger than normal epithelium) or 3 (strong membranous staining). At least 2 tumor cores had to have a score of 2 or higher to be considered EGFR positive.

The scoring of COX-2 was done according to a modification of the scoring system of Sivula et al.¹⁹: 0 (no staining), 1 (weak, diffuse cytoplasmic staining or stronger intensity in <10% of tumor cells), 2 (moderate or strong staining in 10-50%), 3 (moderate or strong staining in 50-80%) and 4 (strong staining in ≥80%). Tumors with a mean score of 0 or 1 were considered COX-2 negative, whereas those with score 2-4 were regarded as COX-2 positive.

For VEGF, cores were scored on a scale of 0-6. Cores with a score of 3 or more were considered VEGF positive.

Table 2 - Clinicopathologic characteristics of the 108 ESCCs incorporated in the TMA

	N	%
Gender		
Male	59	55
Female	49	45
Tumor location		
Upper 1/3	9	8
Middle 1/3	57	53
Lower 1/3	42	39
Differentiation grade		
Well	6	6
Moderately	66	61
Poor	36	33
TNM stage		
Stage I	8	7
Stage IIa	28	26
Stage IIb	7	7
Stage III	49	45
Stage IVa	6	6
Stage IVb	10	9
Lnn metastasis		
Yes	64	59
No	44	41
Extracapsular growth		
Yes	36	56
No	28	44
Total	108	100

Statistical analysis

Statistical analysis was performed using SPSS for Windows (Version 15.0). Percentages were rounded to the nearest integer.

RESULTS**Clinicopathologic data**

The clinicopathologic characteristics of the study population are shown in Table 2. The mean age at the time of surgery was 62 (range, 36-79) years. The average tumor size was 4.7 (range, 0.8-11.0) cm. Sixty percent of patients were stage III or IV. Sixty-four (59%) of 108 patients had lymph node metastases. Of those 64 patients with lymph node metastases, 36 (56%) had extracapsular growth.

Immunohistochemical results

On the 9 slides stained for the above-mentioned molecular markers, a median of 3 (3%; range, 1-7) of 108 tumors was lost due to absence of tissue or due to sampling errors. This resulted in a median of 105 (97%; range 101-107) assessable ESCCs (Table 3).

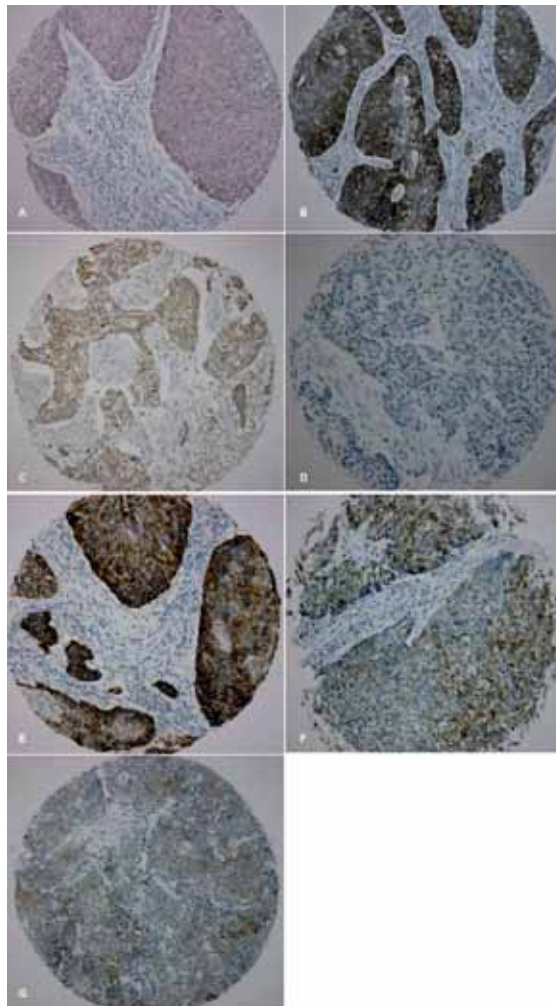
Table 3 - Number of evaluable tumors per molecular marker of the 108 tumors that were incorporated in the TMA and frequency of expression of the markers in the evaluable tumors

Marker	No. of assessable tumors (%)	Expression	
		Positive (%)	Negative (%)
ER	107 (99)	0 (0)	107 (100)
PR	105 (97)	0 (0)	105 (100)
c-KIT	101 (94)	10 (10)	91 (90)
Bcl-2	106 (98)	12 (11)	94 (89)
Her-2/neu	106 (98)	13 (12)	93 (88)
EGFR	105 (97)	42 (40)	63 (60)
COX-2	101 (94)	40 (40)	61 (60)
Cyclin D1	103 (95)	43 (42)	60 (58)
VEGF	101 (94)	56 (55)	45 (45)

In Table 3 an overview is given on the expression of the different markers in our ESCC population. For ER, nuclear expression was observed in none of the 107 evaluable tumors. A non-specific cytoplasmic staining was noticed in 23 (21%) tumors. None of the ESCC TMA cores showed any expression of PR, although in the control tissue a strong nuclear staining was observed.

Of the 101 evaluable ESCCs stained for c-KIT, 10 (10%) showed positive expression (Figure 1). Twelve (11%) of 106 tumors were positive for Bcl-2 (Figure 1). Expression of

Figure 1 - Immunohistochemical staining of (A) Cox-2, (B) EGFR, (C) VEGF, (D) cyclin D1, (E) Her-2/neu, (F) Bcl-2 and (G) c-KIT in our ESCC TMA (see page 296 for color figure).



- 1
- 2
- 3
- 4
- 5
- 6
- 7
- 8
- 9
- 10
- 11
- 12
- 13
- 14
- 15
- 16
- 17
- 18
- 19
- 20
- 21
- 22
- 23
- 24
- 25
- 26
- 27
- 28
- 29
- 30
- 31
- 32

Her-2/neu was noticed in 13 (12%) of the 106 tumors that were evaluable (Figure 1). Forty-three (42%) of 103 ESCCs have shown positivity for cyclin D1 (Figure 1), whereas 60 (58%) were negative. Expression of EGFR was noticed in 42 (40%) of 105 tumors (Figure 1). Of the 101 evaluable tumors for COX-2, 40 (40%) of tumors were positive (Figure 1). A score of '2' was assigned to 19 tumors, '3' to 18 tumors and '4' to 3 tumors. In 56 (55%) of 101 evaluable tumors, positive cytoplasmic expression of VEGF was detected (Figure 1).

Then, the concurrent expression of the most frequently expressed markers (cyclin D1, COX-2, EGFR and VEGFR) was determined. Concurrent expression of cyclin D1 and COX-2 was detected in 14 (14%) of 98 tumors (Table 4). Simultaneous expression of cyclin D1 and VEGF was noticed in 25 (26%) of 98 tumors, whereas cyclin D1 and EGFR in 21%. VEGF with COX-2 expression was noticed in 23 (24%) of 96 tumors and VEGF with EGFR in 23%. The expression of all 4 markers was noticed in 5 (5%) of 93 evaluable tumors.

9

Table 4 - Overview of the proportion of ESCCs with concurrent expression of 2 molecular markers out of the total amount of assessable ESCCs.

	EGFR	Cyclin D1	COX-2	VEGF
EGFR	-	21/102 = 21%	11/101 = 11%	23/100 = 23%
Cyclin D1	21/102 = 21%	-	14/98 = 14%	25/98 = 26%
COX-2	11/101 = 11%	14/98 = 14%	-	23/96 = 24%
VEGF	23/100 = 23%	25/98 = 26%	23/96 = 24%	-

DISCUSSION

Neoadjuvant chemotherapy may improve the survival of esophageal cancer patients. Targeted therapy could be of further benefit by selectively destroying tumor cells. To determine which molecular markers are potential candidates for the treatment of ESCC patients, we have performed an immunohistochemical study on a validated ESCC TMA. Several in vitro and in vivo studies have revealed that the growth of ESCC cell lines expressing ER can be inhibited by administering estrogen.²¹⁻²³ It could, therefore, be postulated that esophageal tumors with expression of ER may benefit from targeted therapy such as tamoxifen. However, none of our 108 ESCCs showed expression of

ER α , which is comparable to the results of Kalayarasan et al. ²⁴	1
Trastuzumab, a therapeutic monoclonal antibody that specifically targets Her-2/neu, is routinely given to Her-2/neu positive breast carcinoma patients as it significantly improves their disease-free survival. ¹⁰ Of particular interest for ESCC therapy, trastuzumab has shown to enhance radiosensitivity in ESCC cell lines. ²⁵ In our ESCCs, 12% was positive for Her-2/neu and would thus have been eligible for trastuzumab therapy. This is in the range of the frequency of Her-2/neu positivity (0-56 %) reported in previous articles ²⁶⁻²⁹ In patients with ESCC, no phase II clinical trials have yet investigated the effect of targeted therapy to Her-2/neu. In esophageal adenocarcinoma only one phase I/II study has been performed and this study was closed early due to a slow patient accrual which was a result of a disappointing low number of Her-2/neu positive patients. ³⁰	2 3 4 5 6 7 8 9 10 11
The Bcl-2 proto-oncogene plays a central role in inhibiting programmed cell death. ^{31,32} It has shown to be upregulated in various malignancies ^{33,34} and is associated with chemotherapy and radiotherapy resistance in lung and colon carcinoma. ^{35,36} Overexpression of Bcl-2 was detected in 11% of our ESCCs, which is relatively low when compared to the 18-100% reported in the literature. ³⁷⁻³⁹ In a large RCT, an antisense oligonucleotide against Bcl-2, oblimersen, has shown to improve the overall-survival in advanced melanoma patients. ⁴⁰ Currently, we are awaiting the results of the first phase I/II clinical trial (NCT00064259) on the effect of oblimersen in advanced esophageal patients given in combination with conventional chemotherapy (i.e. cisplatin and fluorouracil).	12 13 14 15 16 17 18 19 20 21
Cyclin D1 is an important regulator of cell cycle progression by phosphorylating and inactivating the retinoblastoma protein. ⁴¹ It is overexpressed in various malignancies, such as breast cancer and head and neck squamous carcinomas. ^{42,43} In the current study, 42% of ESCCs showed cyclin D1 expression. Flavopiridol has revealed to decrease cyclin D1 expression in esophageal cancer cells and to enhance tumor cell radiosensitivity, ⁴⁴⁻⁴⁶ but its exact working mechanism regarding cyclin D1 reduction is not fully understood.	22 23 24 25 26 27 28
Forty percent of our ESCCs were positive for EGFR, which is comparable to other reports. ⁴⁷ The 2 most common forms of therapy against EGFR are monoclonal antibodies (MoAb) and small molecule tyrosine kinase inhibitors (TKI). ⁴⁸ In ESCC cell lines, the TKI erlotinib induced growth inhibition and cell cycle arrest. ⁴⁹ In addition, in a phase II study	29 30 31 32

1 on the TKI gefitinib in second-line treatment of advanced esophageal cancer patients,
2 5 of 9 ESCC had stable disease.⁵⁰ Given these promising results, more studies targeting
3 this molecular marker are warranted.

4 Angiogenesis is crucial for tumor growth and metastasis. VEGF plays a pivotal role
5 in angiogenesis by stimulating the proliferation and migration of endothelial cells.⁵¹
6 Bevacizumab, a humanized monoclonal antibody directed against VEGF, has significantly
7 improved the survival of patients with metastatic colorectal cancer or advanced non-
8 small-cell lung cancer when given in combination with conventional chemotherapy.^{52,53}
9 In esophageal cancer, some phase II (neo)adjuvant trials of bevacizumab with
10 chemoradiotherapy are currently recruiting patients (trials NCT00570531 and
11 NCT00354679). VEGF expression was detected in 55% of our ESCCs, which is in the
12 range of the 24-93% as reported in the literature.⁵⁴ This proportion of patients may
13 therefore benefit from bevacizumab therapy.

14 Since the results of the current study reveal that 40% of the tumors are COX-2 positive,
15 the administration of selective COX-2 inhibitors such as celecoxib and meloxicam might
16 be advantageous in ESCC patients. Several in vitro studies have shown selective COX-2
17 inhibitors to restrain cell growth and to induce apoptosis in ESCC cell lines.⁵⁵⁻⁵⁷ Moreover,
18 in an RCT on the effect of preoperative administration of meloxicam in ESCC patients
19 scheduled to undergo esophagectomy, significantly more apoptotic tumor cells and a
20 decreased intratumoral level of COX-2 mRNA were detected in the group of patients
21 having received meloxicam.⁵⁸ However, an RCT of celecoxib in patients with mild or
22 moderate esophageal squamous dysplasia has shown no inhibition of esophageal
23 squamous carcinogenesis.⁵⁹ Additional phase II trials on the effect of selective COX-
24 2 inhibitors in ESCC patients are therefore warranted. Given the possible increased
25 cardiovascular risk of celecoxib,⁶⁰⁻⁶² the focus may shift to the other selective COX-2
26 inhibitors. Yet, in a large (n=222) RCT on the effect of celecoxib in patients with Barrett's
27 esophagus more cardiovascular toxic effects were detected in the placebo group.⁶³

28 In 1998, Kononen et al. introduced the TMA technology to facilitate high-throughput
29 immunohistochemical analysis of a large set of tissues simultaneously.⁶⁴ By inserting
30 small tissue biopsy cores of the donor paraffin blocks into a recipient TMA paraffin block,
31 tissues can be analyzed under identical laboratory and evaluation conditions, without
32 significantly damaging the patient's tissue. Since the small tissue cores may compromise

representativeness of the full-sections, we have recently validated our ESCC TMA.¹⁸ The current study has attempted to identify potential markers for targeted therapy in ESCC based on the frequency of their immunohistochemical expression. Yet, one should keep in mind that the immunohistochemical presence of a marker (e.g. EGFR) does not always predict the response of that tumor to targeted therapy.⁶⁵ Nevertheless, immunohistochemical studies such as the current one provide a basis for further research on targeted therapy.

We have not assessed the prognostic significance of the markers as our study population consisted mainly of patients with advanced (i.e. stage III/IV) disease. The presence of lymph node metastases would affect the survival more than would the presence or absence of molecular markers. As ESCC and esophageal adenocarcinoma are considered different disease entities, they should be treated differently.^{66,67} Now we have assessed the frequency of the expression of the different markers in ESCCs, it would be of value to perform a comparable study in (a TMA of) esophageal adenocarcinomas.

In conclusion, promising targets for molecular therapy in ESCC are cyclin D1, COX-2, VEGF and EGFR in view of their frequent immunohistochemical expression. Phase II clinical studies on (a combination of) these markers in ESCC patients are therefore warranted.

ACKNOWLEDGEMENTS

We would like to thank Mr. Folkert Morsink and Miss. Petra van der Groep from the Department of Pathology of the University Medical Center Utrecht for performing the immunohistochemical staining for COX-2 and EGFR, respectively.

_____	1
_____	2
_____	3
_____	4
_____	5
_____	6
_____	7
_____	8
_____	9
_____	10
_____	11
_____	12
_____	13
_____	14
9 _____	15
_____	16
_____	17
_____	18
_____	19
_____	20
_____	21
_____	22
_____	23
_____	24
_____	25
_____	26
_____	27
_____	28
_____	29
_____	30
_____	31
_____	32

REFERENCES

1. Kamangar F, Dores GM, Anderson WF. Patterns of cancer incidence, mortality, and prevalence across five continents: defining priorities to reduce cancer disparities in different geographic regions of the world. *J Clin Oncol* 2006; 24:2137-2150.
2. Mariette C, Piessen G, Triboulet JP. Therapeutic strategies in oesophageal carcinoma: role of surgery and other modalities. *Lancet Oncol* 2007; 8:545-553.
3. Omloo JM, Lagarde SM, Hulscher JB et al. Extended transthoracic resection compared with limited transhiatal resection for adenocarcinoma of the mid/distal esophagus: five-year survival of a randomized clinical trial. *Ann Surg* 2007; 246:992-1000.
4. Hulscher JB, van Sandick JW, Tijssen JG et al. The recurrence pattern of esophageal carcinoma after transhiatal resection. *J Am Coll Surg* 2000; 191:143-148.
5. GebSKI V, Burmeister B, Smithers BM et al. Survival benefits from neoadjuvant chemoradiotherapy or chemotherapy in oesophageal carcinoma: a meta-analysis. *Lancet Oncol* 2007; 8:226-234.
6. Vahid B, Marik PE. Pulmonary complications of novel antineoplastic agents for solid tumors. *Chest* 2008; 133:528-538.
7. Haddad TC, Greeno EW. Chemotherapy-induced thrombosis. *Thromb Res* 2006; 118:555-568.
8. Lin CC, Papadopoulos KP. Novel targeted therapies for advanced esophageal cancer. *Dis Esophagus* 2007; 20:365-371.
9. Smith I, Procter M, Gelber RD et al. 2-year follow-up of trastuzumab after adjuvant chemotherapy in HER2-positive breast cancer: a randomised controlled trial. *Lancet* 2007; 369:29-36.
10. Piccart-Gebhart MJ, Procter M, Leyland-Jones B et al. Trastuzumab after adjuvant chemotherapy in HER2-positive breast cancer. *N Engl J Med* 2005; 20;353:1659-1672.
11. Romond EH, Perez EA, Bryant J et al. Trastuzumab plus adjuvant chemotherapy for operable HER2-positive breast cancer. *N Engl J Med* 2005; 20;353:1673-1684.
12. Hicks DG, Kulkarni S. HER2+ breast cancer: review of biologic relevance and optimal use of diagnostic tools. *Am J Clin Pathol* 2008; 129:263-273.
13. Valverde CM, Macarulla T, Casado E et al. Novel targets in gastric and esophageal cancer. *Crit Rev Oncol Hematol* 2006; 59:128-138.
14. Tew WP, Kelsen DP, Ilson DH. Targeted therapies for esophageal cancer. *Oncologist* 2005; 10:590-601.
15. Schrupp DS, Nguyen DM. Novel molecular targeted therapy for esophageal cancer. *J Surg Oncol* 2005; 92:257-261.

16.	Aklilu M, Ilson DH. Targeted agents and esophageal cancer--the next step? <i>Semin Radiat Oncol</i> 2007; 17:62-69.	1
17.	van Diest PJ. No consent should be needed for using leftover body material for scientific purposes. <i>For. BMJ</i> 2002; 325:648-651.	2
18.	Boone J, van Hillegersberg R, van Diest PJ et al. Validation of tissue microarray technology in squamous cell carcinoma of the esophagus. <i>Virchows Archiv</i> 2008; 452:507-514.	3
19.	Sivula A, Buskens CJ, van Rees BP et al. Prognostic role of cyclooxygenase-2 in neoadjuvant-treated patients with squamous cell carcinoma of the esophagus. <i>Int J Cancer</i> 2005; 116:903-908.	4
20.	Gown AM. Current issues in ER and HER2 testing by IHC in breast cancer. <i>Mod Pathol</i> 2008; 21 Suppl 2:S8-S15.:S8-S15.	5
21.	Utsumi Y, Nakamura T, Nagasue N et al. Role of estrogen receptors in the growth of human esophageal carcinoma. <i>Cancer</i> 1989; 64:88-93.	6
22.	Utsumi Y, Nakamura T, Nagasue N et al. Effect of 17 beta-estradiol on the growth of an estrogen receptor-positive human esophageal carcinoma cell line. <i>Cancer</i> 1991; 67:2284-2289.	7
23.	Ueo H, Matsuoka H, Sugimachi K et al. Inhibitory effects of estrogen on the growth of a human esophageal carcinoma cell line. <i>Cancer Res</i> 1990; 50:7212-7215.	8
24.	Kalayarasan R, Ananthkrishnan N, Kate V, Basu D. Estrogen and progesterone receptors in esophageal carcinoma. <i>Dis Esophagus</i> . 2008; 21:298-303.	9
25.	Sato S, Kajiyama Y, Sugano M et al. Monoclonal antibody to HER-2/neu receptor enhances radiosensitivity of esophageal cancer cell lines expressing HER-2/neu oncoprotein. <i>Int J Radiat Oncol Biol Phys</i> 2005; 61:203-211.	10
26.	Aloia TA, Harpole DH, Reed CE et al. Tumor marker expression is predictive of survival in patients with esophageal cancer. <i>Ann Thorac Surg</i> 2001; 72:859-866.	11
27.	Kawaguchi Y, Kono K, Mimura K et al. Targeting EGFR and HER-2 with cetuximab- and trastuzumab-mediated immunotherapy in oesophageal squamous cell carcinoma. <i>Br J Cancer</i> 2007; 20;97:494-501.	12
28.	Mimura K, Kono K, Hanawa M et al. Frequencies of HER-2/neu expression and gene amplification in patients with oesophageal squamous cell carcinoma. <i>Br J Cancer</i> 2005; 92:1253-1260.	13
29.	Gibault L, Metges JP, Conan-Charlet V et al. Diffuse EGFR staining is associated with reduced overall survival in locally advanced oesophageal squamous cell cancer. <i>Br J Cancer</i> 2005; 93:107-115.	14
30.	Safran H, Dipetrillo T, Akerman P et al. Phase I/II study of trastuzumab, paclitaxel, cisplatin and radiation for locally advanced, HER2 overexpressing, esophageal adenocarcinoma. <i>Int J Radiat Oncol Biol Phys</i> 2007; 67:405-409.	15
		16
		17
		18
		19
		20
		21
		22
		23
		24
		25
		26
		27
		28
		29
		30
		31
		32

- 1 —
- 2 —
- 3 —
- 4 —
- 5 —
- 6 —
- 7 —
- 8 —
- 9 —
- 10 —
- 11 —
- 12 —
- 13 —
- 14 —
- 15 —
- 16 —
- 17 —
- 18 —
- 19 —
- 20 —
- 21 —
- 22 —
- 23 —
- 24 —
- 25 —
- 26 —
- 27 —
- 28 —
- 29 —
- 30 —
- 31 —
- 32 —

31. Danial NN. BCL-2 family proteins: critical checkpoints of apoptotic cell death. *Clin Cancer Res* 2007; 13:7254-7263.
32. Letai A. BCL-2: found bound and drugged! *Trends Mol Med* 2005; 11:442-444.
33. Chi KN. Targeting Bcl-2 with oblimersen for patients with hormone refractory prostate cancer. *World J Urol* 2005; 23:33-37.
34. Nahta R, Esteva FJ. Bcl-2 antisense oligonucleotides: a potential novel strategy for the treatment of breast cancer. *Semin Oncol* 2003; 30:143-149.
35. Herbst RS, Frankel SR. Oblimersen sodium (Genasense bcl-2 antisense oligonucleotide): a rational therapeutic to enhance apoptosis in therapy of lung cancer. *Clin Cancer Res* 2004; 10:4245s-4248s.
36. Prabhudesai SG, Rekhraj S, Roberts G et al. Apoptosis and chemo-resistance in colorectal cancer. *J Surg Oncol* 2007; 96:77-88.
37. Hsia JY, Chen CY, Hsu CP et al. Expression of apoptosis-regulating proteins p53, Bcl-2, and Bax in primary resected esophageal squamous cell carcinoma. *Neoplasma* 2001; 48:483-488.
38. Kurabayashi A, Furihata M, Matsumoto M et al. Expression of Bax and apoptosis-related proteins in human esophageal squamous cell carcinoma including dysplasia. *Mod Pathol* 2001; 14:741-747.
39. Azmi S, Dinda AK, Chopra P et al. Bcl-2 expression is correlated with low apoptotic index and associated with histopathological grading in esophageal squamous cell carcinomas. *Tumour Biol* 2000; 21:3-10.
40. Bedikian AY, Millward M, Pehamberger H et al. Bcl-2 antisense (oblimersen sodium) plus dacarbazine in patients with advanced melanoma: the Oblimersen Melanoma Study Group. *J Clin Oncol* 2006; 24:4738-4745.
41. Alao JP. The regulation of cyclin D1 degradation: roles in cancer development and the potential for therapeutic invention. *Mol Cancer* 2007; 6:24.:24.
42. Roy PG, Thompson AM. Cyclin D1 and breast cancer. *The Breast* 2006; 15:718-727.
43. Diehl JA. Cycling to cancer with cyclin D1. *Cancer Biol Ther* 2002; 1:226-231.
44. Schrupp DS, Matthews W, Chen GA et al. Flavopiridol mediates cell cycle arrest and apoptosis in esophageal cancer cells. *Clin Cancer Res* 1998; 4:2885-2890.
45. Raju U, Ariga H, Koto M et al. Improvement of esophageal adenocarcinoma cell and xenograft responses to radiation by targeting cyclin-dependent kinases. *Radiother Oncol* 2006; 80:185-191.
46. Sato S, Kajiyama Y, Sugano M et al. Flavopiridol as a radio-sensitizer for esophageal cancer cell lines. *Dis Esophagus* 2004; 17:338-344.
47. Hanawa M, Suzuki S, Dobashi Y et al. EGFR protein overexpression and gene amplification in squamous cell carcinomas of the esophagus. *Int J Cancer* 2006; 118:1173-1180.

48.	Syrigos KN, Zalonis A, Kotteas E et al. Targeted therapy for oesophageal cancer: an overview. <i>Cancer Metastasis Rev</i> 2008; 27:273-288.	1
49.	Sutter AP, Hopfner M, Huether A et al. Targeting the epidermal growth factor receptor by erlotinib (Tarceva) for the treatment of esophageal cancer. <i>Int J Cancer</i> 2006; 118:1814-1822.	2
50.	Janmaat ML, Gallegos-Ruiz MI, Rodriguez JA et al. Predictive factors for outcome in a phase II study of gefitinib in second-line treatment of advanced esophageal cancer patients. <i>J Clin Oncol</i> 2006; 24:1612-1619.	3
51.	O'Reilly MS. Antiangiogenesis and vascular endothelial growth factor/vascular endothelial growth factor receptor targeting as part of a combined-modality approach to the treatment of cancer. <i>Int J Radiat Oncol Biol Phys</i> 2007; 69:S64-S66.	4
52.	Hurwitz H, Fehrenbacher L, Novotny W et al. Bevacizumab plus irinotecan, fluorouracil, and leucovorin for metastatic colorectal cancer. <i>N Engl J Med</i> 2004; 350:2335-2342.	5
53.	Sandler A, Gray R, Perry MC et al. Paclitaxel-carboplatin alone or with bevacizumab for non-small-cell lung cancer. <i>N Engl J Med</i> 2006; 355:2542-2550.	6
54.	Kleespies A, Guba M, Jauch KW et al. Vascular endothelial growth factor in esophageal cancer. <i>J Surg Oncol</i> 2004; 87:95-104.	7
55.	Kase S, Osaki M, Honjo S et al. A selective cyclooxygenase-2 inhibitor, NS398, inhibits cell growth and induces cell cycle arrest in the G2/M phase in human esophageal squamous cell carcinoma cells. <i>J Exp Clin Cancer Res</i> 2004; 23:301-307.	8
56.	Yu HP, Shi LY, Lu WH et al. Expression of cyclooxygenase-2 (COX-2) in human esophageal cancer and in vitro inhibition by a specific COX-2 inhibitor, NS-398. <i>J Gastroenterol Hepatol</i> 2004; 19:638-642.	9
57.	Zhi H, Wang L, Zhang J et al. Significance of COX-2 expression in human esophageal squamous cell carcinoma. <i>Carcinogenesis</i> 2006; 27:1214-1221.	10
58.	Liu JF, Zhang SW, Jamieson GG et al. The effects of a COX-2 inhibitor meloxicam on squamous cell carcinoma of the esophagus in vivo. <i>Int J Cancer</i> 2008; 122:1639-1644.	11
59.	Limburg PJ, Wei W, Ahnen DJ et al. Randomized, placebo-controlled, esophageal squamous cell cancer chemoprevention trial of selenomethionine and celecoxib. <i>Gastroenterology</i> 2005; 129:863-873.	12
60.	Arber N, Eagle CJ, Spicak J et al. Celecoxib for the prevention of colorectal adenomatous polyps. <i>N Engl J Med</i> 2006; 355:885-895.	13
61.	Bertagnolli MM, Eagle CJ, Zauber AG et al. Celecoxib for the prevention of sporadic colorectal adenomas. <i>N Engl J Med</i> 2006; 355:873-884.	14
		15
		16
		17
		18
		19
		20
		21
		22
		23
		24
		25
		26
		27
		28
		29
		30
		31
		32

- 1 —
- 2 —
- 3 —
- 4 —
- 5 —
- 6 —
- 7 —
- 8 —
- 9 —
- 10 —
- 11 —
- 12 —
- 13 —
- 14 —
- 15 —
- 16 —
- 17 —
- 18 —
- 19 —
- 20 —
- 21 —
- 22 —
- 23 —
- 24 —
- 25 —
- 26 —
- 27 —
- 28 —
- 29 —
- 30 —
- 31 —
- 32 —

9

- 62. Solomon SD, McMurray JJ, Pfeffer MA et al. Cardiovascular risk associated with celecoxib in a clinical trial for colorectal adenoma prevention. *N Engl J Med* 2005; 352:1071-1080.
- 63. Heath EI, Canto MI, Piantadosi S et al. Secondary chemoprevention of Barrett's esophagus with celecoxib: results of a randomized trial. *J Natl Cancer Inst* 2007; 99:545-557.
- 64. Kononen J, Bubendorf L, Kallioniemi A et al. Tissue microarrays for high-throughput molecular profiling of tumor specimens. *Nat Med* 1998; 4:844-847.
- 65. Van Cutsem E. Challenges in the Use of Epidermal Growth Factor Receptor Inhibitors in Colorectal Cancer. *Oncologist* 2006; 11:1010-1017.
- 66. Siewert JR, Ott K. Are squamous and adenocarcinomas of the esophagus the same disease? *Semin Radiat Oncol* 2007; 17:38-44.
- 67. Mariette C, Finzi L, Piessen G et al. Esophageal carcinoma: prognostic differences between squamous cell carcinoma and adenocarcinoma. *World J Surg* 2005; 29:39-45.

- 1
- 2
- 3
- 4
- 5
- 6
- 7
- 8
- 9
- 10
- 11
- 12
- 13
- 14
- 15
- 16
- 17
- 18
- 19
- 20
- 21
- 22
- 23
- 24
- 25
- 26
- 27
- 28
- 29
- 30
- 31
- 32

10

Journal of Clinical Pathology 2008; 61:909-13

mTOR in squamous cell carcinoma of the esophagus: a potential target for molecular therapy?

Judith Boone¹

Fiebo J.W. Ten Kate²

G. Johan A. Offerhaus²

Paul J. van Diest²

Inne H.M. Borel Rinkes¹

Richard van Hillegersberg¹

Departments of ¹Surgery and ²Pathology
University Medical Center Utrecht

ABSTRACT**Background**

The mammalian target of rapamycin (mTOR), an important regulator of protein translation and cell proliferation, is activated in various malignancies. In a randomized controlled trial of advanced renal cell carcinoma patients, targeted therapy to mTOR by means of rapamycin analogues has shown to significantly improve survival. An in vitro study has revealed that mTOR is activated in esophageal squamous cell carcinoma (ESCC) cell lines and that mTOR expression is inhibited by rapamycin. The objectives of this histological study were to determine the proportion of ESCC tissues with activated mTOR (p-mTOR) expression, thereby assessing the percentage of patients with ESCC that would possibly benefit from neoadjuvant rapamycin therapy and to identify the clinicopathologic features of these potentially rapamycin-sensitive tumours.

Methods

The expression of p-mTOR (Ser2448) was immunohistochemically assessed in a validated tissue microarray comprising triplicate tissue biopsy cores of 108 formalin-fixed, paraffin-embedded ESCCs. Staining results were correlated with clinicopathologic data.

Results

Normal esophageal epithelium was negative for p-mTOR. Activated mTOR expression was located in the cytoplasm of esophageal tumor cells. Twenty-six (25%) of 105 assessable ESCCs showed tumour cells with positive staining for p-mTOR. Activated mTOR expression was only associated with a lesser degree of differentiation ($P=0.024$). No correlation was detected between p-mTOR and the proliferation marker Ki-67.

Conclusions

Activated mTOR can be detected in one quarter of ESCCs. Since this subset of patients may potentially benefit from mTOR inhibiting therapy, a phase II clinical trial of neoadjuvant mTOR-inhibiting therapy in patients with ESCC may be considered.

INTRODUCTION

Esophageal cancer is the 8th most common malignancy in the world with an estimated 462,000 new cases diagnosed in 2002.¹ Radical surgical resection of the esophagus with an extensive lymphadenectomy offers the best chance for cure.² Notwithstanding recent advances in surgical strategies and postoperative care, the prognosis of patients is limited with an overall 5-year survival rate after esophagectomy of around 30%.^{3,4} A meta-analysis has shown that neoadjuvant chemoradiotherapy, compared to surgery alone, improves the 2-year survival rate in esophageal cancer patients with approximately 10% by enhancing locoregional control and opposing early metastatic spread.⁵ Although at present the most commonly used neoadjuvant agents are conventional chemotherapeutics, the expanding knowledge on the molecular carcinogenetic pathways has ushered in a new era of neoadjuvant therapy; molecular targeted therapy.⁶ The addition of molecular-targeted agents to current neoadjuvant treatment regimens might further improve the survival after surgery for esophageal cancer.

An innovative target for molecular therapy is the mammalian Target of Rapamycin (mTOR). This 289-kDa serine/threonine protein kinase is activated by the phosphatidylinositol-3-kinase (PI3K)/Akt signalling pathway and functions as a key regulator of protein translation and cell proliferation by phosphorylating its downstream markers p70s6k and 4E-binding protein.⁷⁻⁹ mTOR is up-regulated in various adenocarcinomas, such as prostate cancer, renal cell carcinoma and breast cancer.¹⁰⁻¹³ This is of particular clinical interest as mTOR inhibitors (i.e. rapamycin analogues like temsirolimus and everolimus) are commercially available.¹⁴ A recent randomized controlled trial revealed that temsirolimus significantly improves the overall survival of advanced renal cell carcinoma patients.¹⁵

Regarding squamous cell carcinomas, analysis of the protein expression of mTOR is scarce and restricted to oral cancer and head and neck carcinomas.^{16,17} In esophageal squamous cell carcinoma (ESCC) only an in vitro study has been performed, which has shown an activated state of mTOR in cell lines, with rapamycin reducing mTOR expression.¹⁸ However, no studies are available that have assessed the activation status of mTOR protein in ESCC specimens.

The expression of molecular markers in paraffin-embedded tissues is usually assessed

1 _____
2 _____
3 _____
4 _____
5 _____
6 _____
7 _____
8 _____
9 _____
10 _____
11 _____
12 _____
13 _____
14 _____
15 _____
16 _____
17 _____
18 _____
19 _____
20 _____
21 _____
22 _____
23 _____
24 _____
25 _____
26 _____
27 _____
28 _____
29 _____
30 _____
31 _____
32 _____

by immunohistochemistry. In 1998, Kononen et al. introduced the tissue microarray (TMA) technology to enhance throughput.¹⁹ By inserting small (diameter 0.6mm) cores of paraffin-embedded tissues into a single recipient block, this technique allows for rapid immunohistochemical analysis of hundreds of tissues concurrently under identical laboratory and evaluation conditions, without significantly damaging the patient's tissue.²⁰

The objectives of the present study were to determine the proportion of ESCC tissues showing expression of activated mTOR (p-mTOR), thereby assessing the percentage of ESCC patients that would possibly benefit from neoadjuvant rapamycin therapy and to identify the clinicopathologic features of these potentially rapamycin sensitive tumours.

MATERIALS AND METHODS

Patients and specimens

One-hundred and eight consecutive patients with ESCC having undergone transhiatal or transthoracic esophagolymphadenectomy between 1989 and 2006 at the authors' institute were included in this study. Patients who received neoadjuvant therapy were excluded.

Paraffin-embedded tissue specimens of all patients were retrieved from the archives of the Department of Pathology. The study was carried out in accordance with the ethical guidelines of our institution concerning allowing anonymous or coded use of left over tissue from surgical procedures.²¹ From all paraffin blocks, a 4µm slide was stained with haematoxylin and eosin (H&E) for histopathologic diagnosis. All tumours were graded for differentiation (G1: well differentiated, G2: moderately differentiated, G3: poorly differentiated)²², infiltration depth (T1-T4)²³, number of dissected lymph nodes, metastatic lymph node involvement and presence of extracapsular growth by an experienced pathologist (FtK). Tumors were staged according to the most recent Tumor Node Metastasis (TNM) staging system.²³

TMA construction

On 1 selected H&E-stained section of each tumour, 3 representative tumour regions were marked avoiding areas of necrosis. From these regions, a tissue cylinder with a diameter of 0.6mm was punched out of the corresponding paraffin block and placed into the TMA paraffin block using a custom-made precision instrument (MTA-I, Beecher Instruments, Sun Prairie, USA), which was guided by the MTABooster® (Alphelys, Plaisir, France). The distribution and position of the cores was determined in advance with the TMA-Designer® Software (Version 1.6.8, Alphelys). Cores of normal esophageal mucosa, lymph node, kidney, liver, spleen and prostate were incorporated in the TMA as internal controls. In a previous study, we have validated this TMA approach using established molecular markers with various expression patterns.²⁴

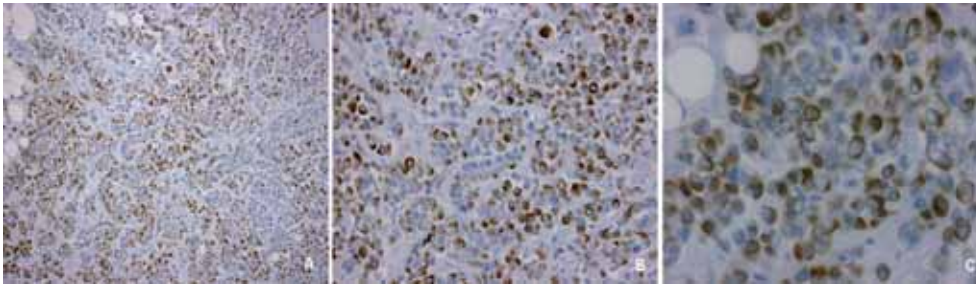
Immunohistochemistry

A 4µm section of the TMA was deparaffinized in xylene for 10 minutes followed by dehydration in serial ethanol dilutions. Antigen retrieval was carried out by boiling the slides in sodium citrate (pH 6.0) for 20 minutes. After a cooling-off period in the citrate buffer solution for 30 minutes, endogenous peroxidase activity was blocked by 3% hydrogen peroxide for 15 minutes. To avoid aspecific staining, endogenous Avidin and Biotin were blocked with Avidin Biotin blocking solution (Dako, Glostrup, Denmark, catalog#X0590) for 10 minutes. Subsequently, incubation with normal swine serum (Dako, catalog#X0901, dilution 1:5) was carried out for 10 minutes. Then, slides were incubated with the primary antibody against p-mTOR (Ser2448, Cell Signaling Technology Inc, Danvers, USA, catalog# 2976, dilution 1:50) in normal swine serum overnight in 4°C. The next day, incubation with the secondary antibody (swine-anti-rabbit, Dako catalog#E0353, dilution 1:300 in 10% human serum) was applied for 30 minutes, followed by the Strept Avidin Biotin Complex (Dako, catalog#K0377) for 60 minutes. The peroxidase reactivity was developed by 3,3'-diaminobenzidine (10 minutes) and slides were counterstained with Mayer's haematoxylin. Between all steps, slides were washed in phosphate-buffered saline (pH7.4). Breast carcinoma known for its p-mTOR positivity was used as positive control tissue (Figure 1).^{11,13,25} Negative control was obtained by omitting the primary antibody.

Since mTOR is involved in cell proliferation, a second TMA-slide was stained for the

proliferation marker Ki-67 (MIB-1) to assess if a correlation exists. After deparaffinization, rehydration and boiling in citrate buffer as mentioned above, slides were incubated with the primary antibody against MIB-1 (Dako, catalog#M7240, dilution 1:100) on an autostaining machine for 60 minutes. Subsequently, slides were incubated with the secondary antibody followed by the Strept Avidin Biotin Complex. Then, the peroxidase reactivity was developed and slides were counterstained with haematoxylin. Tonsil was used as positive control tissue.

Figure 1 - Positive activated mammalian target of rapamycin (p-mTOR) staining in control breast cancer tissue (A, original magnification x100; B, original magnification x200; C, original magnification x400). A strong, brown, cytoplasmic staining is seen (see page 297 for color figure).



10

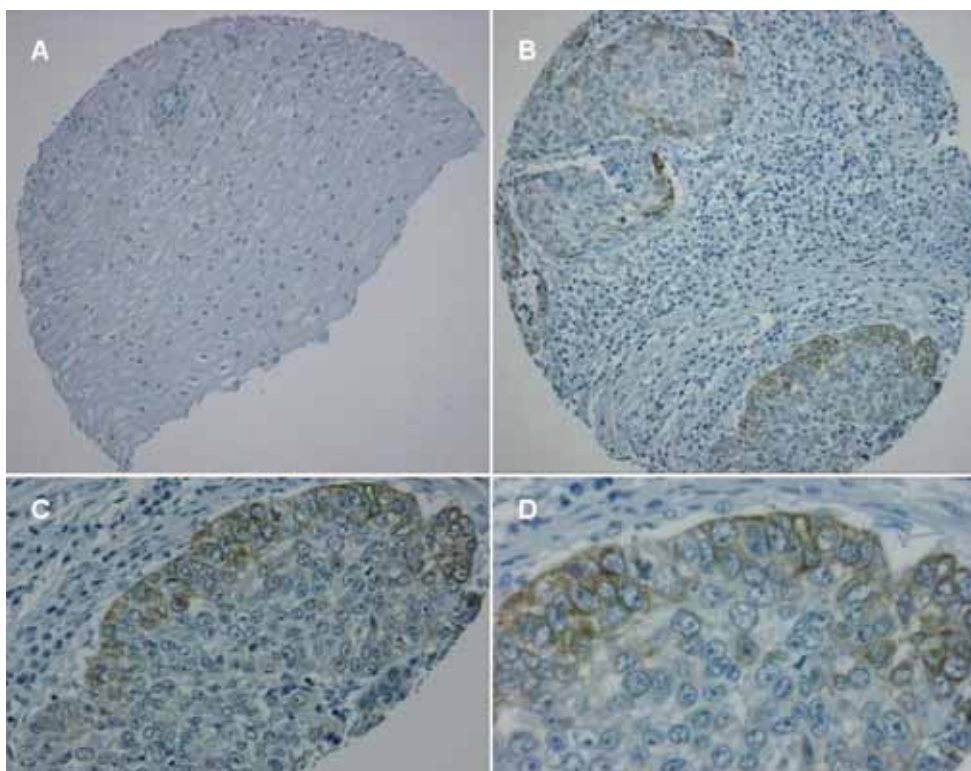
Scoring

Immunohistochemical staining of p-mTOR was scored conjointly by 2 observers (FtK and JB) using a scoring system that incorporates both staining intensity and percentage of positive tumour cells. Of each core, the intensity of p-mTOR staining (0 absent, 1 weak or 2 strong) was multiplied by the percentage of positive staining tumour cells, resulting in a score ranging from 0-200.²⁶ Cases were marked (-) in case all cores had a score 0, (+) when the highest score of the 3 cores was 1-19, or (++) when the highest score was 20 or higher (Figure 2).

Of each core the percentage of tumor cells expressing Ki-67 was assessed. For determining the Ki-67 score of a tumor, the mean Ki-67 score of the corresponding tumor cores was calculated. Then, tumors were divided into 3 groups according to their Ki-67 score: negative (<10% of tumor nuclei stained), weakly positive (10-50%) or strongly positive (>50%; Figure 3).²⁷

TMA cores were considered lost if less than 10% of cells contained tumour ('sampling error') or when less than 10% of tissue was present ('absent core'). Patient cases were excluded if 2 out of 3 cores were lost.

Figure 2 - No activated mammalian target of rapamycin (p-mTOR) staining was detected in normal oesophageal squamous epithelium (A, original magnification x100). A strong cytoplasmic staining (score ++) was detected in oesophageal squamous carcinoma cells (B, original magnification x100; C, original magnification x200; D, original magnification x400) (see page 297 for color figure).

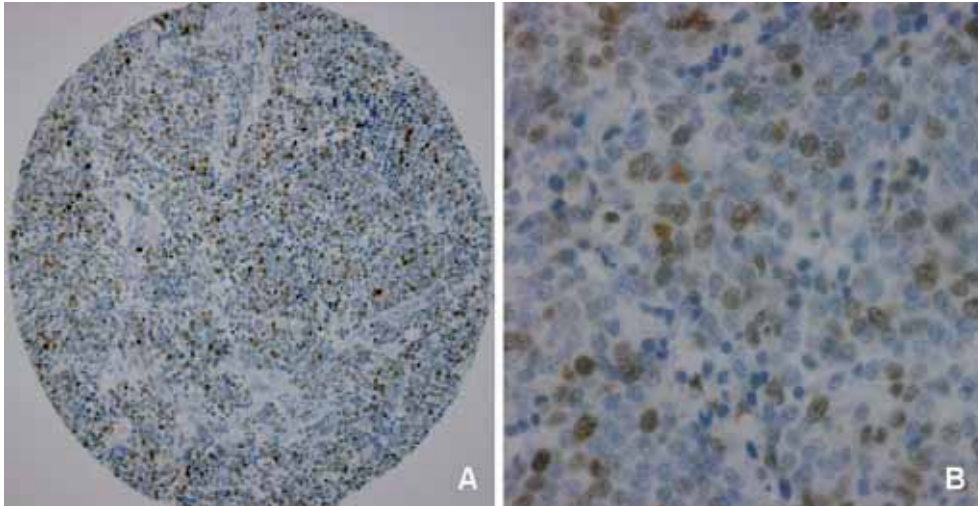


10

Statistical analysis

Statistical analysis was done using SPSS (Version 12.0). Percentages were rounded to the nearest whole integer. Tumors with p-mTOR expression (score + and ++) and those without p-mTOR expression (score -) were compared with the Pearson's chi-square test or Fisher's exact test. The Spearman's rank correlation coefficient (rho) was computed to determine the correlation between the expression of p-mTOR and the expression of Ki-67. Two-tailed P-values <0.050 were considered statistically significant.

Figure 3 - Ki-67 staining of an oesophageal squamous cell carcinoma core showing a strong, nuclear staining in more than 50% of tumour cells (A, original magnification x100; B, original magnification x400) (see page 298 for color figure).



RESULTS

10

Three (3%) of 108 cases were excluded, because only a single tumour biopsy core was evaluable on the TMA slide stained for p-mTOR. The study population therefore consisted of 105 patients, 56 male (53%) and 49 female, with a mean age of 62 (range 36-79). The average tumour size was 4.7cm (range 0.8-11.0). The grade of differentiation was predominantly moderate (62%) or poor (32%). A mean of 15 lymph nodes were dissected during esophagectomy. Sixty-two (59%) patients had lymph node metastases. In 55% of these lymph node-positive patients, extracapsular lymph node involvement was detected. An overview of clinicopathologic features of the study population is given in Table 1.

In the control tissue a perinuclear staining of p-mTOR was seen (Figure 1a, 1b, 1c). As depicted in Figure 2a, normal esophageal epithelium was negative for p-mTOR. In ESCC, p-mTOR staining was noticed in the cytoplasm of tumour cells (Figure 2b, 2c, 2d). Tumour cells expressing p-mTOR were noticed in 26/105 (25%) ESCCs. Eighteen (69%) of the p-mTOR expressing tumours had a score between 1 and 19 (+). A score of 20 or higher (++) was given to 8 (8%) ESCCs (Table 1).

As shown in Table 1, p-mTOR expression was associated only with a lesser degree of differentiation (P=0.024). No statistical significant difference could be detected between p-mTOR positive and p-mTOR negative tumors with regard to tumor location, TNM stage or the presence of lymph node metastases. In addition, no correlation was detected between the expression of p-mTOR and Ki-67 (Spearman's rho 0.058, P=0.56).

Table 1 - Activated-mTOR expression and clinicopathologic characteristics of 105 patients with squamous cell carcinomas of the esophagus

	No. of cases (%) [*]	p-mTOR (%) [*]			P-value [†]
		-	+	++	
Age					
≥62 years	54 (51)	43 (80)	9 (17)	2 (4)	0.37
<62 years	51 (49)	36 (71)	9 (18)	6 (12)	
Gender					
Male	56 (53)	42 (75)	9 (16)	5 (9)	1.00
Female	49 (47)	37 (76)	9 (18)	3 (6)	
Location tumour					
Upper 1/3 esophagus	9 (9)	7 (78)	2 (22)	0 (0)	1.00
Middle 1/3 esophagus	55 (52)	41 (75)	10 (18)	4 (7)	
Distal 1/3 esophagus	41 (39)	31 (76)	6 (15)	4 (10)	
Differentiation grade^{**}					
G1	6 (6)	5 (83)	0 (0)	1 (17)	0.024
G2	65 (62)	54 (83)	9 (14)	2 (3)	
G3	34 (32)	20 (59)	9 (27)	5 (15)	
TNM-stage					
I	7 (7)	4 (57)	1 (14)	2 (29)	0.62
Ila	28 (27)	23 (82)	4 (14)	1 (4)	
Ilb	7 (7)	4 (57)	1 (14)	2 (29)	
III	48 (46)	36 (75)	11 (23)	1 (2)	
IVa	6 (6)	5 (83)	0 (0)	1 (17)	
IVb	9 (9)	7 (78)	1 (11)	1 (11)	
Lnn metastasis (N1 & M1lym)					
No	43 (41)	31 (72)	8 (19)	4 (9)	0.65
Yes	62 (59)	48 (77)	10 (16)	4 (6)	
Extracapsular growth^{††}					
No	28 (45)	22 (79)	5 (18)	1 (4)	1.00
Yes	34 (55)	26 (76)	5 (15)	3 (9)	
Ki-67 score[‡]					
<10%	5 (5)	3 (60)	1 (20)	1 (20)	0.26
10-50%	85 (83)	66 (78)	14 (16)	5 (6)	
≥50%	13 (13)	8 (62)	3 (23)	2 (15)	
Total	105 (100)	79 (75)	18 (17)	8 (8)	-

*Sum of percentages may exceed 100% because of rounding. †Calculated between p-mTOR positive (score + and ++) tumors and p-mTOR negative (score -) tumors. **G1: well differentiated; G2: moderately differentiated; G3: poorly differentiated. ††Determined for the 62 patients with lymph node metastases. ‡For comparison of p-mTOR expression and Ki-67 expression, 2 extra cases have been excluded from the study population since the tumor cores of these cases were absent on the TMA slide stained for Ki-67.

DISCUSSION

MTOR plays an important role in protein translation, cell growth and cell proliferation by integrating both environmental and internal factors, including nutrients, growth factors and energy levels.²⁸ Subsequent to preclinical studies revealing the expression of mTOR protein in several cancer tissues and showing mTOR inhibitors to inhibit cell proliferation in cancer cell lines, rapamycin and its analogues are increasingly being tested in oncologic clinical trials.^{15,29} In a phase II trial of patients with locally advanced or metastatic breast carcinomas, weekly intravenous infusion of the rapalog temsirolimus resulted in a response rate of 9.2%.²⁹ In addition, a recent randomized controlled trial showed that temsirolimus significantly improved overall survival ($P=0.008$) and progression-free survival ($P<0.001$) in advanced renal cell carcinoma patients.¹⁵

As far as we know, no studies have yet investigated p-mTOR expression in ESCC or the application of mTOR inhibitors in ESCC patients. However, Hou et al. have shown expression of mTOR in 2 esophageal squamous cell carcinoma cell lines, with a higher expression in the poorly differentiated cell line.¹⁸ This is in line with the statistical significant association that was found in the current study between the expression of p-mTOR in ESCC and a poorer degree of tumor differentiation. Moreover, they detected a significant decrease in mTOR mRNA levels in ESCC cells treated with rapamycin.¹⁸ The goal of our study was to investigate the frequency of p-mTOR in human ESCC tissue samples, thereby assessing the amount of patients that would possibly benefit from mTOR inhibiting therapy.

To determine the expression of p-mTOR in a large study population under identical laboratory and evaluation conditions, we have used a TMA slide containing triplicate core biopsies of 108 ESCCs. The expression of mTOR has previously been determined by means of TMA technology in malignancies such as prostate, breast and renal cell cancer. Since a potential disadvantage of TMA technology might be that the small (diameter 0.6mm) tissue cores are not representative for the full-section, we have recently validated our TMA using well-known molecular markers.²⁴ Although our TMA has proven valid, one should keep in mind when interpreting the results of the current study that false-negative observations still may have occurred. Yet, this would only lead to a higher amount of ESCCs that are p-mTOR positive and that therefore might benefit

from rapamycin therapy. Moreover, when performing immunohistochemical analysis on full-sections instead of on a TMA slide the representativeness of a single slide for the entire tumor may be questioned as well and false-negative results may also occur. Nevertheless, as with all immunohistochemical studies, it should be worthwhile to perform this study in a different ESCC population to confirm the current data.

The reported percentages of malignancies expressing activated mTOR vary widely, from 15% in hepatocellular carcinomas to around 60% in gastric adenocarcinoma and biliary tract carcinoma.^{26,30,31} Although this could be explained by differences in tumour biology, it should be taken into account that the percentage of carcinomas expressing activated mTOR also depends to a great extent on the scoring system used. In several studies that have assessed the expression of mTOR in cancer tissues by immunohistochemistry, tumours were marked as positive in case any positivity was noticed.^{32,33} According to this scoring system 25% of our tumours would be positive for p-mTOR. However, in a recently published scoring system of p-mTOR applied in biliary tract adenocarcinomas, tumours were considered positive when the multiplication of percentage of staining tumour cells and staining intensity (on a scale of 0-2) was 20 or higher.²⁶ When we would apply this scoring system, only 8% of our ESCCs would be expressing p-mTOR. From a clinical point of view, it remains to be elucidated which degree of p-mTOR expressing would lead to benefit from mTOR inhibitors. One could imagine that in tumours in which only 20% of tumour cells express activated mTOR, mTOR inhibitors could only destroy 20% of tumour cells and leave the rest unaffected leading to outgrowth of resistant clones. Nevertheless, in these tumours mTOR inhibitors could still be effective when given in combination with chemotherapy.

Since p-mTOR is involved in the regulation of cellular proliferation,^{7-9,34} we have assessed the correlation between the expression of p-mTOR and that of the proliferation marker Ki-67. However, comparable to the results reported in primary liver neoplasms,³⁰ no correlation was found. This could be explained by the fact that the cell cycle is controlled by numerous other molecular pathways, for example the retinoblastoma protein, E2F-family proteins, cyclins and p53 protein, which are also commonly mutated in malignancies.³⁵⁻³⁸

Although some studies have shown p-mTOR to be an adverse prognostic marker in breast carcinoma and biliary tract cancer,^{13,26} we did not assess the prognostic significance of

_____	1
_____	2
_____	3
_____	4
_____	5
_____	6
_____	7
_____	8
_____	9
_____	10
_____	11
_____	12
_____	13
_____	14
_____	15
_____	16
10 _____	17
_____	18
_____	19
_____	20
_____	21
_____	22
_____	23
_____	24
_____	25
_____	26
_____	27
_____	28
_____	29
_____	30
_____	31
_____	32

1 — p-mTOR in ESCC since the current study population consisted mainly of patients with
2 — advanced disease. As the presence of (distant) lymph node metastases would probably
3 — affect the disease-free survival and overall-survival more than would the presence of
4 — p-mTOR expression, it should be recommended to study the prognostic significance of
5 — p-mTOR in a large population of early-staged ESCCs (i.e. stage I-IIa).

6 — In summary, activated mTOR was detected in 25% of patients with ESCC, predominantly
7 — in poorly differentiated tumours. Since patients with such tumours may benefit from
8 — mTOR inhibiting therapy, further clinical studies are warranted.

REFERENCES

	1
	2
	3
	4
	5
	6
	7
	8
	9
	10
	11
	12
	13
	14
	15
	16
	17
	18
	19
	20
	21
	22
	23
	24
	25
	26
	27
	28
	29
	30
	31
	32

15. Hudes G, Carducci M, Tomczak P et al. Temsirolimus, interferon alfa, or both for advanced renal-cell carcinoma. *N Engl J Med* 2007; 356:2271-2281.
16. Liu Y, Hidayat S, Su WH, Deng X, Yu DH, Yu BZ. Expression and activity of mTOR and its substrates in different cell cycle phases and in oral squamous cell carcinomas of different malignant grade. *Cell Biochem Funct* 2007; 25:45-53.
17. Nathan CA, Amirghahari N, Abreo F et al. Overexpressed eIF4E Is Functionally Active in Surgical Margins of Head and Neck Cancer Patients via Activation of the Akt/Mammalian Target of Rapamycin Pathway. *Clin Cancer Res* 2004; 10:5820-5827.
18. Hou G, Xue L, Lu Z, Fan T, Tian F, Xue Y. An activated mTOR/p70S6K signaling pathway in esophageal squamous cell carcinoma cell lines and inhibition of the pathway by rapamycin and siRNA against mTOR. *Cancer Lett* 2007; 253:236-248.
19. Kononen J, Bubendorf L, Kallioniemi A et al. Tissue microarrays for high-throughput molecular profiling of tumor specimens. *Nat Med* 1998; 4:844-847.
20. Simon R and Sauter G. Tissue microarray (TMA) applications: implications for molecular medicine. *Expert Rev Mol Med* 2003; 5:1-12.
21. van Diest PJ. No consent should be needed for using leftover body material for scientific purposes. *For. BMJ* 2002; 325:648-651.
22. Hamilton SR and Aaltonen LA. WHO classification of tumors - Pathology and genetics of tumours of the digestive system. 2000;
23. Wittekind C, Greene FL, Hutter RVP, Klimpfinger M, Sobin LH. TNM Atlas. Illustrated guide to the TNM/pTNM classification of malignant tumors. 2004; 5:
24. Boone J, van Hilleberg R, van Diest PJ, Offerhaus GJA, Borel Rinkes IHM, Ten Kate FJW. Validation of tissue microarray technology in squamous cell carcinoma of the esophagus. *Virchows Archiv* 2008; 452:507-514.
25. Lin HJ, Hsieh FC, Song H, Lin J. Elevated phosphorylation and activation of PDK-1/AKT pathway in human breast cancer. *Br J Cancer* 2005; 93:1372-1381.
26. Herberger B, Puhalla H, Lehnert M et al. Activated mammalian target of rapamycin is an adverse prognostic factor in patients with biliary tract adenocarcinoma. *Clin Cancer Res* 2007; 13:4795-4799.
27. Xu M, Jin YL, Fu J et al. The abnormal expression of retinoic acid receptor-beta, p 53 and Ki67 protein in normal, premalignant and malignant esophageal tissues. *World J Gastroenterol* 2002; 8:200-202.
28. Yang Q and Guan KL. Expanding mTOR signaling. *Cell Res* 2007; 17:666-681.

29.	Chan S, Scheulen ME, Johnston S et al. Phase II study of temsirolimus (CCI-779), a novel inhibitor of mTOR, in heavily pretreated patients with locally advanced or metastatic breast cancer. <i>J Clin Oncol</i> 2005; 23:5314-5322.	1
		2
		3
30.	Sahin F, Kannangai R, Adegbola O, Wang J, Su G, Torbenson M. mTOR and P70 S6 kinase expression in primary liver neoplasms. <i>Clin Cancer Res</i> 2004; 10:8421-8425.	4
		5
31.	Lang SA, Gaumann A, Koehl GE et al. Mammalian target of rapamycin is activated in human gastric cancer and serves as a target for therapy in an experimental model. <i>Int J Cancer</i> 2007; 120:1803-1810.	6
		7
		8
32.	Sieghart W, Fuereder T, Schmid K et al. Mammalian target of rapamycin pathway activity in hepatocellular carcinomas of patients undergoing liver transplantation. <i>Transplantation</i> 2007; 83:425-432.	9
		10
33.	Noh WC, Kim YH, Kim MS, Koh JS, Kim HA, Moon NM, Paik NS. Activation of the mTOR signaling pathway in breast cancer and its correlation with the clinicopathologic variables. <i>Breast Cancer Res Treat</i> 2007; .:	11
		12
		13
34.	Smolewski P. Recent developments in targeting the mammalian target of rapamycin (mTOR) kinase pathway. <i>Anticancer Drugs</i> 2006; 17:487-494.	14
		15
35.	Hickman ES, Moroni MC, Helin K. The role of p53 and pRB in apoptosis and cancer. <i>Curr Opin Genet Dev</i> 2002; 12:60-66.	16
		17
36.	Adams PD and Kaelin WG, Jr. Negative control elements of the cell cycle in human tumors. <i>Curr Opin Cell Biol</i> 1998; 10:791-797.	18
		19
37.	Stewart CL, Soria AM, Hamel PA. Integration of the pRB and p53 cell cycle control pathways. <i>J Neurooncol</i> 2001; 51:183-204.	20
		21
38.	Kawakubo H, Ozawa S, Ando N, Kitagawa Y, Mukai M, Ueda M, Kitajima M. Alterations of p53, cyclin D1 and pRB expression in the carcinogenesis of esophageal squamous cell carcinoma. <i>Oncol Rep</i> 2005; 14:1453-1459.	22
		23
		24
		25
		26
		27
		28
		29
		30
		31
		32



PART III
DIAGNOSTIC IMAGING
STRATEGIES

11

Diseases of the Esophagus; accepted for publication

International survey on esophageal cancer: Part II Staging and neoadjuvant therapy

Judith Boone¹

Daan P. Livestro¹

Sjoerd G. Elias²

Inne H.M. Borel Rinkes¹

Richard van Hillegersberg¹

¹Department of Surgery, University Medical Center Utrecht

²Julius Center for Health Sciences and Primary Care,
University Medical Center Utrecht

ABSTRACT**Background**

The outcome of esophagectomy could be improved by optimal diagnostic strategies leading to adequate preoperative patient selection. Neoadjuvant therapy could improve outcome by increasing the number of radical resections and by controlling metastatic disease. The purposes of this study were to gain insight into the current worldwide practice of staging modalities and neoadjuvant therapy in esophageal cancer and to detect intercontinental differences.

Methods

Surgeons with particular interest in esophageal surgery, including members of the International Society for Diseases of the Esophagus (ISDE), the European Society of Esophagology - Group d'Etude Européen des Maladies de l'Oesophage (ESE-GEEMO) and the OESO, were invited to participate in an online questionnaire. Questions were asked regarding staging modalities, neoadjuvant therapy and response evaluation applied in esophageal cancer patients.

Results

Of 567 invited surgeons, 269 participated resulting in a response rate of 47%. The responders currently performing esophagectomies (n=250; 44%) represented 41 countries across the 6 continents. Esophagogastroscope with biopsy and computed tomography (CT) scanning were routinely performed by 98% of responders for diagnosing and staging esophageal cancer, while endoscopic ultrasound (EUS) and barium esophagography were routinely applied by 58% and 51% respectively. Neoadjuvant therapy is routinely administered by 33% and occasionally by 63% of responders. Of the responders that administer identical neoadjuvant regimens to esophageal adenocarcinoma and squamous cell carcinoma, 54% favor chemoradiotherapy. For adenocarcinoma, chemotherapy is preferred by 31% of the responders that administer neoadjuvant therapy, whereas for squamous cell carcinoma the majority of responders (38%) prefer chemoradiotherapy. Response to neoadjuvant therapy is predominantly assessed by CT scanning of the chest and abdomen (86%). Barium esophagography, EUS

and combined CT/PET-scan are requested for response monitoring in equal frequency (25%). Substantial differences in applied staging modalities and neoadjuvant regimens were detected between surgeons from different continents.

Conclusions

Currently, the most commonly applied diagnostic modalities for staging and restaging esophageal cancer are CT scanning of the chest and abdomen, gastroscopy, barium esophagography and EUS. Neoadjuvant therapy is routinely applied by one third of the responders. Intercontinental differences have been detected in the diagnostic modalities applied in esophageal cancer staging and in the administration of neoadjuvant therapy. The results of this survey provide baseline data for future research and for the development of international guidelines.

- 1
- 2
- 3
- 4
- 5
- 6
- 7
- 8
- 9
- 10
- 11
- 12
- 13
- 14
- 15
- 16
- 17
- 18
- 19
- 20
- 21
- 22
- 23
- 24
- 25
- 26
- 27
- 28
- 29
- 30
- 31
- 32

INTRODUCTION

Due to the rise in occurrence of esophageal adenocarcinoma (AC) the incidence of esophageal cancer is rapidly increasing, more than any other type of malignancy.^{1,2} With an estimated 462,000 newly diagnosed patients in 2002, it is the 8th most common malignancy worldwide.³ Esophageal cancer patients are frequently diagnosed at an advanced stage owing to late presentation of symptoms. Consequently, less than half of patients are eligible for curative treatment.⁴ For patients with locoregional disease the best chance of cure is offered by radical resection of the esophagus and the surrounding lymph nodes.⁵ The overall 5-year survival rate after surgery is around 35%.⁶

The outcome of esophagectomy could be improved by adequate preoperative patient selection using diagnostic modalities such as computed tomography (CT) scanning, endoscopic ultrasonography (EUS) and ultrasonography (US) of the neck.⁷⁻⁹ Patients diagnosed with distant metastases (M1b) or local irresectable disease should not undergo esophageal resection, but should be offered palliative therapy.^{7,10,11} Several diagnostic modalities are available for diagnosing, staging and restaging esophageal cancer.¹²⁻¹⁴ At this moment, it is unclear in what frequency these different diagnostic modalities are being applied in the work-up of esophageal cancer patients.

Nearly half of patients develop recurrent or metastatic disease within the first year after esophagectomy, indicating that resection was not extensive enough or that micrometastases were already present at the time of surgery.¹⁵ Neoadjuvant treatment has therefore been introduced aiming at increasing resectability by reducing tumor size and by controlling early metastatic spread.¹⁶ A recent meta-analysis of randomized controlled trials has shown a significant survival benefit in patients with esophageal AC or squamous cell carcinoma (SCC) receiving neoadjuvant chemoradiotherapy (CRTx) and, to a lesser extent, in patients with AC receiving neoadjuvant chemotherapy (CTx).¹⁷ Although substantial evidence for the application of neoadjuvant therapy is provided, it is indefinite if and how neoadjuvant therapy is nowadays incorporated in the treatment of esophageal cancer patients.

The aims of the present study were to gain insight into the current practice of the application of staging modalities and neoadjuvant therapy in esophageal cancer patients by surgeons worldwide and to identify intercontinental differences.

MATERIALS AND METHODS

Questionnaire

A web-based questionnaire (<http://www.esophagussurvey.com>) was designed in 2007 that consisted of 5 parts: (I) demographic data and surgical experience in esophageal cancer surgery; (II) pre-operative work-up of esophageal cancer patients; (III) techniques of esophageal cancer surgery; (IV) postoperative management and (V) additional commentaries. In this manuscript the results of parts I, II and V will be presented. Answers to most questions could be given on a 3-point-scale: 'never-occasionally-routinely'. Sporadically, responders were asked to reply to questions by choosing from a multiple-choice list or by giving percentages. The answers from returned questionnaires were directly entered into an online software database.

Invited physicians

By electronic mail (e-mail) an invitation to participate in the questionnaire together with a link to the website, a personal login name and a password were sent to surgical members of the International Society for Diseases of the Esophagus (ISDE), the European Society of Esophagology - Group d'Etude Européen des Maladies de l'Oesophage (ESE-GEEMO) and the OESO. Written permission was obtained from the Presidents of these societies in order to gain access to their membership databases and to contact their members. In addition, surgeons known from personal networks were invited to participate in the survey and responders were able to recommend colleagues in the field. The first invitation was sent on July 23, 2007. Reminder e-mail notices were sent every 2 weeks to those who had not responded to the initial request. The survey was closed on October 23, 2007. A recipient was considered a non-responder if no reply was received on this day. If the responder did not perform esophageal cancer surgery (by replying 'no' to the corresponding question), the questionnaire would end and no further data were collected.

There has been a lot of interest recently in the effect of operation volume on the outcome of esophageal cancer surgery.¹⁸⁻²⁰ For comparing the results of low-volume and high-volume surgeons, we defined low-volume surgeons as surgeons who performed ≤ 10 esophagectomies per year, medium-volume surgeons as surgeons who carried out 11-20 esophagectomies, and high-volume surgeons ≥ 21 . To reveal differences in between

regular and senior esophageal cancer surgeons, responders were divided into 3 groups according to the years of experience in esophageal cancer surgery: surgeons having performed esophagectomy for ≤ 10 years, 11-20 years or ≥ 21 years.

Statistical analysis

All data were analyzed anonymously. Statistical analysis was performed when appropriate, using SPSS (Version 12.0, for Windows). The application of the various diagnostic modalities and of neoadjuvant therapy was compared with regard to surgeon's case volume, years of experience and the continent the responder is from. Percentages were rounded to the nearest integer and as a consequence the sum of percentages may not equal 100%. For comparison of data between continents, the continents South-America, Oceania and Africa were excluded since they each had less than 5% ($n=13$) of the total amount of responders.

RESULTS

Characteristics of Responders

Of 567 invited physicians, 269 participated in the questionnaire, resulting in an overall response rate of 47%. Nineteen (7%) responders indicated not to actively practice esophageal cancer surgery. The remaining 250 responders (specific response rate 44%) formed the basis for all further analysis. They represented 41 countries across the 6 continents (Table 1).

Sixty-four percent of responders were member of the ISDE, 15% were member of more than 1 esophageal society, 8% were ESE member, 14% were known from personal networks and 1 responder was referred by a colleague. An overview of the responders' function, case volume per year and years of experience is given in Table 2. North-American responders were mainly medium- and high-volume surgeons, while Asian responders were predominantly high-volume surgeons. European responders were equally distributed over the 3 categories. Surgeons with ≥ 11 years of experience are predominantly high-volume surgeons, whereas those with ≤ 10 years of experience were equally distributed over the 3 categories.

Table 1 - Response rates per continent and country.

Country	No. invited	No. participated†	Specific Response Rate, %
Europe:	253	125	49
The Netherlands	34	31	91
Italy	50	21	42
Spain	23	12	52
United Kingdom	21	10	48
Germany	18	6	33
Belgium	11	5	45
France	20	5	25
Greece	10	4	40
Sweden	7	4	57
Finland	5	4	80
Asia:	181	51	28
Japan	134	30	22
Korea	10	6	60
India	8	5	63
China	12	4	33
North America:	73	42	58
USA	63	37	59
Canada	10	5	50
South America:	36	18	50
Brazil	20	11	55
Oceania:	21	12	57
Australia	20	12	60
Africa	3	2	67
Overall	567	250	44

†Countries with 3 or less responders include: Portugal (3), Austria (3), Hungary (3), Czech Republic (2), Poland (2), Serbia (2), Turkey (2), Israel (2), Taiwan (2), Mexico (2), Argentina (2), Chile (2), Ireland (1), Slovenia (1), Romania (1), Croatia (1), Norway (1), Switzerland (1), Saudi Arabia (1), Thailand (1), Uruguay (1), Sudan (1), South Africa (1)

Table 2 - Overview of the function, personal esophagectomy case volume per year and years of experience in esophageal cancer surgery of the 250 surgical responders.

	n	%
Function		
Fellow	10	4
Senior staff	49	20
Regular staff	188	75
Other	3	1
Personal case volume/year		
<11	59	24
11 – 20	79	32
21 – 30	53	21
31 – 40	27	11
41 – 50	10	4
51 – 60	4	2
>60	18	7
Years of experience		
<6	30	12
6 – 10	49	20
11 – 15	49	20
16 – 20	51	20
21 – 25	41	16
26 – 30	18	7
>30	12	5
Overall	250	44

11

Staging modalities

Esophagogastrosopy with biopsy and CT-scan of the chest and abdomen are part of the routine preoperative work-up of esophageal cancer patients in 98% of responders (Figure 1). The combination of EUS, CT-scan and US of the neck is routinely requested by 17% of surgeons. Of the 244 responders that routinely execute a CT-scan of chest and abdomen, 71 (29%) also routinely perform an US of the liver. Of the 127 responders who routinely apply a barium esophagogram to diagnose esophageal cancer, 126 (99%) also routinely perform a gastroscopy with biopsy.

In Figure 2, an overview is given on the intercontinental differences regarding the various diagnostic modalities used for diagnosing and staging esophageal cancer. EUS is routinely employed by 70% of North-American and European responders compared to 35% of Asian responders. Laparoscopic staging is routinely performed by 14% of North-American responders compared to 10% of European and 2% of Asian responders.

Surgeons with ≥ 21 years of experience routinely employ EUS less often than those with ≤ 10 years of experience (49% vs. 63%, respectively). In addition, the former execute

an US of the liver more often than the latter (37% vs. 24%, respectively). Moreover, surgeons with ≥ 21 years of experience in esophageal cancer surgery routinely perform a barium examination more often than do surgeons with ≤ 10 years of experience (63% vs. 46% respectively). High-volume surgeons perform an FDG-PET scan more routinely than low-volume surgeons (24% vs. 15%, respectively). In addition, high-volume surgeons more routinely request a CT/FDG-PET scan than low-volume surgeons (34% vs. 19%, respectively).

Neoadjuvant therapy

Neoadjuvant therapy is routinely given by 33%, occasionally by 63% and never by 4% of responders (Figure 3). Of the 241 surgeons that apply neoadjuvant therapy, 148 (61%) give identical neoadjuvant regimens to SCC and AC.

In case of identical regimens, CRTx is favored by 54% of responders, whereas CTx is the preferred method for 17% of responders (Figure 4). Radiotherapy (RTx) is only given occasionally (24%). Cisplatin combined with 5-fluorouracil (5-FU) is the most frequently applied chemotherapeutic regimen, applied by 53% of the responders that give neoadjuvant chemo(radio)therapy to esophageal cancer patients. Both the combination Carboplatin with 5-FU and Epirubicin with Cisplatin and 5-FU (ECF) are applied by 13%. The indications for neoadjuvant treatment are summarized in Table 3.

Figure 1 - Application of the different diagnostic modalities for diagnosing and staging esophageal cancer by the 250 responders. Values within bars represent number of responders

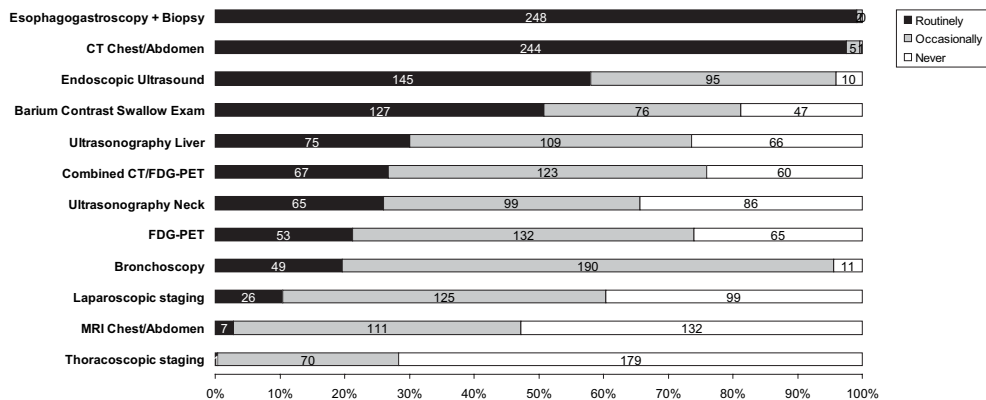


Figure 2 - Application of barium contrast swallow examination A), endoscopic ultrasonography (EUS) B), 18F-fluoro-2-deoxy-D-glucose positron emission tomography (FDG-PET) scan C), ultrasonography (US) of the neck D) and US of the liver E) by all responders, responders from Europe, North-America and Asia. Values within bars represent number of responders

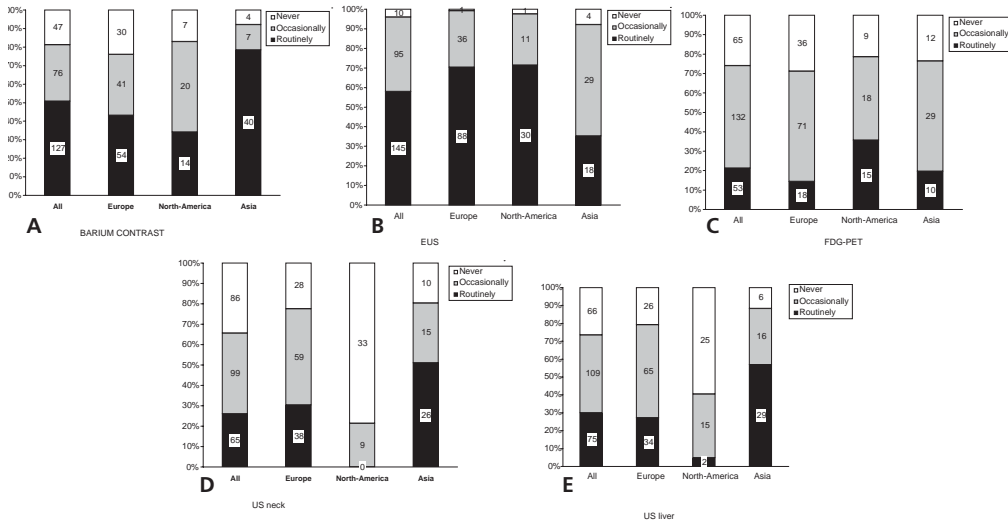


Table 3 - Indication for neoadjuvant therapy in esophageal cancer patients according to stage. Responders are divided to those who give identical regimens to adenocarcinoma (AC) and squamous cell carcinoma (SCC) and those who treat AC and SCC differently.

	Identical regimens	AC	SCC
Stage I	3%	0%	0%
Stage IIa	26%	16%	14%
Stage IIb	60%	48%	50%
Stage III	87%	79%	81%
Stage IVa	62%	62%	68%

Ninety-three responders (39%) apply different neoadjuvant regimens for SCC and AC. For AC, CTx is preferred by 31% of these responders. CRTx is favored by 11% of the responders that administer neoadjuvant therapy, whereas RTx is never preferred. In SCC, on the contrary, CRTx is the preferred method (38%). CTx is favored by 9% of the responders that use neoadjuvant therapy and RTx by 7%. The most frequently used chemotherapeutic regimen in AC is ECF (35%), while in case of SCC it is Cisplatin with 5-FU (51%). The indications for neoadjuvant in AC and SCC are summarized in Table 3. Asian responders less often use neoadjuvant therapy compared to North-American

and European responders (Figure 3). Surgeons with ≥ 21 years of experience routinely perform neoadjuvant therapy less often than those with ≤ 10 years of experience (25% vs. 37%, respectively). In addition, North-American responders more frequently give identical neoadjuvant regimens to SCC and AC than European or Asian responders (83% vs. 58% and 59%, respectively).

Figure 3 - Administration of neoadjuvant therapy in esophageal cancer by all responders, European responders, North-American responders and Asian responders. Values within bars represent number of responders

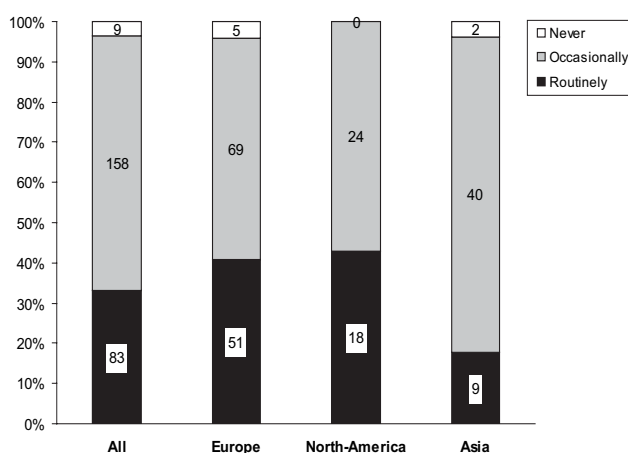
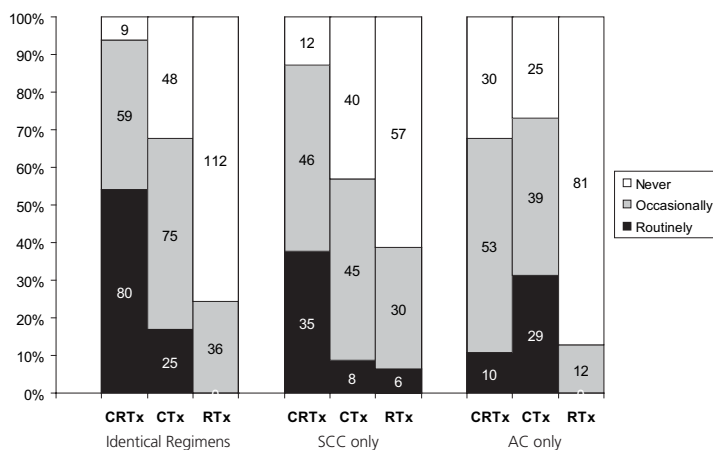
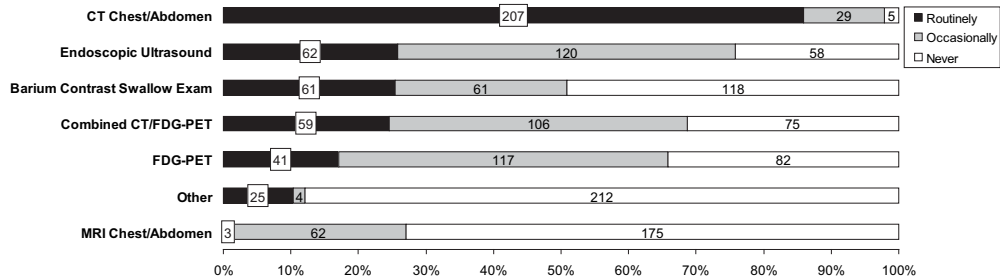


Figure 4 - Administration of chemoradiotherapy (CRTx) chemotherapy (CTx) and Radiotherapy (RTx) by the 148 responders giving identical neoadjuvant regimens to squamous cell carcinoma (SCC) and adenocarcinoma (AC) (left figure), and by the 93 responders giving different regimens to SCC (middle) and AC (right). Values with in bars represent number of responders



11

Figure 5 - Frequency of the different diagnostic modalities used for restaging esophageal cancer after neoadjuvant therapy. Values with in bars represent number of responders



Response monitoring

Response to neoadjuvant treatment is predominantly assessed by CT scanning of the chest and abdomen (Figure 5). Of the 25 responders that routinely perform a diagnostic modality for assessing the response to neoadjuvant therapy other than those mentioned in Figure 5, 16 perform a gastroscopy with biopsy.

Almost 50% of Asian responders routinely perform a barium esophagography to evaluate the response to neoadjuvant therapy, compared to 24% of European and 7% of North-American responders. A CT scan is routinely performed by 92% of Asian and European responders, compared to 69% of North-American responders. North-American surgeons routinely perform a combined CT/FDG-PET scan more often than Asian and European responders (52% vs. 20% and 16%, respectively).

11

DISCUSSION

The results of this survey have gain insight into the use of the various diagnostic modalities for (re)staging esophageal cancer and in the application of neoadjuvant therapy by surgeons worldwide. In addition, several intercontinental differences on these topics have been revealed.

Patients with dysphagia may undergo barium esophagography in an attempt to diagnose esophageal cancer by identifying contour abnormalities.^{21,22} Although less invasive and less expensive than endoscopy, it neither does allow for direct visualization

of esophageal wall abnormalities nor does provide histologic samples. Consequently, gastroscopy should still be performed subsequent to esophagography when a malignancy is suspected.²³ Half of responders (predominantly Asian) routinely perform an esophagogram in the preoperative work-up. Inevitably, almost all of these responders routinely perform a gastroscopy as well.

EUS has proven to be the most accurate tool for assessing the depth of tumor infiltration into the esophageal wall and for detecting locoregional and celiac lymph node metastases.^{9,24,25} Fifty-eight percent of responders routinely executes an EUS. Asian responders routinely use EUS less often than European and North-American responders (Figure 2) which, in combination with the higher frequency of the use of barium esophagograms in this continent, may reflect that Asians more often assess tumor infiltration depth by means of esophagograms.^{26,27} Nonetheless, the major advantage of EUS is that it also enables the detection (and FNA) of lymph node metastases.²⁸

FDG-PET scanning has recently been introduced into esophageal cancer staging to enhance the detection of lymph node metastases as well as organ metastases.²⁹⁻³¹ A systematic review has shown a moderate sensitivity and specificity of 0.51 and 0.84, respectively, for the detection of locoregional lymph node metastases and 0.67 and 0.97, respectively, for distant metastases.³⁰ The broad implementation of FDG-PET in staging esophageal cancer is further questioned by Van Westreenen et al. since in their large prospective study no substantial benefit was detected for FDG-PET over 'conventional' diagnostic modalities (EUS, CT scan and cervical US). In the current survey 21% of the responders routinely perform an FDG-PET scan.

According to the current staging systems,^{32,33} lymph node metastases in the cervical region are considered M1b disease in case of a mid or distal esophageal tumor and hence these patients should be offered palliative treatment. Several studies have shown that US of the neck (with FNA if indicated) is the preferred diagnostic tool for detecting supraclavicular lymph node metastases, with a sensitivity and specificity of 75% and 91% respectively for US alone and 72% and 100% respectively for US with FNA.^{11,34} Only half of the responders routinely executes a cervical US.

Neoadjuvant therapy significantly improves survival of esophageal cancer patients, except for those that do not respond.^{16,17} Neoadjuvant therapy is routinely applied by 33% of responders and occasionally by 63%. As SCC and AC have different

- _____ 1
- _____ 2
- _____ 3
- _____ 4
- _____ 5
- _____ 6
- _____ 7
- _____ 8
- _____ 9
- _____ 10
- _____ 11
- _____ 12
- _____ 13
- _____ 14
- _____ 15
- _____ 16
- _____ 17
- _____ 18
- 11** _____ 19
- _____ 20
- _____ 21
- _____ 22
- _____ 23
- _____ 24
- _____ 25
- _____ 26
- _____ 27
- _____ 28
- _____ 29
- _____ 30
- _____ 31
- _____ 32

1 pathogeneses, they should be viewed as separate tumor entities³⁵ and perchance should
2 be given different neoadjuvant regimens. Nevertheless, more than half of responders
3 that apply neoadjuvant therapy give identical regimens to both histologic types. By
4 these responders, neoadjuvant CRTx is most commonly administered. When different
5 regimens are given, CTx is most commonly used in AC versus CRTx in SCC. However,
6 a meta-analysis has shown a significant survival benefit in patients with AC receiving
7 neoadjuvant CRTx and to a lesser extent in case of CTx.¹⁷

8 Response assessment to neoadjuvant therapy is very important, as it can alter the
9 treatment plan in non-responding patients. A systematic review has shown EUS and FDG-
10 PET scan to have comparable accuracy (86%) for assessing the response to neoadjuvant
11 therapy, whereas that of CT-scan was significantly lower (54%).³⁶ Our results show
12 that CT-scan is still the preferred diagnostic modality for response assessment. Almost
13 half of Asian responders routinely perform a barium esophagogram to evaluate tumor
14 response, which is surprising as it is only capable of assessing changes in esophageal
15 tumor size.⁴⁰ No judgment can be made regarding the response in lymph nodes.

16 Although for our research question the current study set-up is best, some remarks have
17 to be made. First, questions regarding neoadjuvant therapy were asked to surgeons
18 as these questions were part of a survey that addressed surgical techniques as well.
19 Nevertheless, since multimodality treatment is coordinated by both the surgical and
20 medical oncologist, the results of this study will give an adequate reflection of the
21 currently applied neoadjuvant regimens. Second, the responders' answers may not have
22 been representative for all esophageal cancer surgeons. Yet, with a specific response
23 rate of 44%, predominantly from members of prominent esophageal societies, our
24 results are likely to reflect the current view regarding staging and neoadjuvant therapy.
25 In conclusion, intercontinental differences have been detected in the diagnostic modalities
26 applied in esophageal cancer staging and in the administration of neoadjuvant therapy.
27 Currently, esophagogastrosocopy with biopsy and CT scanning are most frequently used.
28 Neoadjuvant therapy is routinely administered by 33% of responders. The responders
29 that give identical regimens to SCC and AC most commonly administer CRTx. It should
30 be very worthwhile to repeat this study within several years to detect possible changes
31 over time.
32

ACKNOWLEDGEMENTS

The authors would like to thank all responders for their appreciated participation in the survey and for sharing their expertise in the field of esophageal cancer diagnosis and treatment. We would like to express special gratitude to Professor Kahrilas and Professor DeMeester from the International Society for Diseases of the Esophagus (ISDE), Professor Lundell and Professor Zaninotto from the European Society of Esophagology Group d'Etude Européen des Maladies de l'Oesophage (ESE-GEEMO) and Professor Giuli from the OESO for providing access to their membership databases.

- 1
- 2
- 3
- 4
- 5
- 6
- 7
- 8
- 9
- 10
- 11
- 12
- 13
- 14
- 15
- 16
- 17
- 18
- 19
- 20
- 21
- 22
- 23
- 24
- 25
- 26
- 27
- 28
- 29
- 30
- 31
- 32

REFERENCES

1. Pera M, Manterola C, Vidal O, Grande L. Epidemiology of esophageal adenocarcinoma. *J Surg Oncol* 2005; 92:151-159.
2. Holmes RS and Vaughan TL. Epidemiology and pathogenesis of esophageal cancer. *Semin Radiat Oncol* 2007; 17:2-9.
3. Kamangar F, Dores GM, Anderson WF. Patterns of cancer incidence, mortality, and prevalence across five continents: defining priorities to reduce cancer disparities in different geographic regions of the world. *J Clin Oncol* 2006; 24:2137-2150.
4. Mariette C, Piessen G, Triboulet JP. Therapeutic strategies in oesophageal carcinoma: role of surgery and other modalities. *Lancet Oncol* 2007; 8:545-553.
5. DeMeester SR. Adenocarcinoma of the Esophagus and Cardia: A Review of the Disease and Its Treatment. *Ann Surg Oncol* 2006; 13:12-30.
6. Omloo JM, Lagarde SM, Hulscher JB et al. Extended Transthoracic Resection Compared With Limited Transhiatal Resection for Adenocarcinoma of the Mid/Distal Esophagus: Five-Year Survival of a Randomized Clinical Trial. *Ann Surg* 2007; 246:992-1001.
7. Stein HJ, Brucher BL, Sendlir A, Siewert JR. Esophageal cancer: patient evaluation and pre-treatment staging. *Surg Oncol* 2001; 10:103-111.
8. Bergman JJ. The endoscopic diagnosis and staging of oesophageal adenocarcinoma. *Best Pract Res Clin Gastroenterol* 2006; 20:843-866.
9. Lightdale CJ and Kulkarni KG. Role of Endoscopic Ultrasonography in the Staging and Follow-Up of Esophageal Cancer. *J Clin Oncol* 2005; 23:4483-4489.
10. von Rahden BH and Stein HJ. Staging and treatment of advanced esophageal cancer. *Curr Opin Gastroenterol* 2005; 21:472-477.
11. van Vliet EP, van der Lugt A, Kuipers EJ et al. Ultrasound, computed tomography, or the combination for the detection of supraclavicular lymph nodes in patients with esophageal or gastric cardia cancer: a comparative study. *J Surg Oncol* 2007; 96:200-206.
12. Ajani J, Bekaii-Saab T, D'Amico TA et al. Esophageal Cancer Clinical Practice Guidelines. *J Natl Compr Canc Netw* 2006; 4:328-347.
13. Allum WH, Griffin SM, Watson A, Colin-Jones D. Guidelines for the management of oesophageal and gastric cancer. *Gut* 2002; 50 Suppl 5:v1-23.
14. Society for Surgery of the Alimentary Tract. SSAT patient care guidelines. Surgical treatment of esophageal cancer. *J Gastrointest Surg* 2007; 11:1216-1218.

15.	Hulscher JB, van Sandick JW, Tijssen JG, Obertop H, van Lanschot JJ. The recurrence pattern of esophageal carcinoma after transhiatal resection. <i>J Am Coll Surg</i> 2000; 191:143-148.	1
16.	Kleinberg L and Forastiere AA. Chemoradiation in the management of esophageal cancer. <i>J Clin Oncol</i> 2007; 25:4110-4117.	2
17.	GebSKI V, Burmeister B, Smithers BM, Foo K, Zalberg J, Simes J. Survival benefits from neoadjuvant chemoradiotherapy or chemotherapy in oesophageal carcinoma: a meta-analysis. <i>Lancet Oncol</i> 2007; 8:226-234.	3
18.	Migliore M, Choong CK, Lim E, Goldsmith KA, Ritchie A, Wells FC. A surgeon's case volume of oesophagectomy for cancer strongly influences the operative mortality rate. <i>Eur J Cardiothorac Surg</i> 2007; 32:375-380.	4
19.	van Lanschot JJ, Hulscher JB, Buskens CJ, Tilanus HW, ten Kate FJ, Obertop H. Hospital volume and hospital mortality for esophagectomy. <i>Cancer</i> 2001; 91:1574-1578.	5
20.	Swisher SG, Deford L, Merriman KW et al. Effect of operative volume on morbidity, mortality, and hospital use after esophagectomy for cancer. <i>J Thorac Cardiovasc Surg</i> 2000; 119:1126-1132.	6
21.	Moss AA, Koehler RE, Margulis AR. Initial accuracy of esophagograms in detection of small esophageal carcinoma. <i>AJR Am J Roentgenol</i> 1976; 127:909-913.	7
22.	Lightdale CJ. Esophageal cancer. <i>American College of Gastroenterology. Am J Gastroenterol</i> 1999; 94:20-29.	8
23.	Kumbasar B. Carcinoma of esophagus: radiologic diagnosis and staging. <i>Eur J Radiol</i> 2002; 42:170-180.	9
24.	Marsman WA and Fockens P. State of the art lecture: EUS for esophageal tumors. <i>Endoscopy</i> 2006; 38 Suppl 1:S17-S21.	10
25.	Kelly S, Harris KM, Berry E et al. A systematic review of the staging performance of endoscopic ultrasound in gastro-oesophageal carcinoma. <i>Gut</i> 2001; 49:534-539.	11
26.	Lee SS, Ha HK, Byun JH et al. Superficial esophageal cancer: esophagographic findings correlated with histopathologic findings. <i>Radiology</i> 2005; 236:535-544.	12
27.	Kato H, Momma K, Yoshida M. Early esophageal cancer: radiologic estimation of invasion into the muscularis mucosae. <i>Abdom Imaging</i> 2003; 28:464-469.	13
28.	Kutup A, Link BC, Schurr PG et al. Quality control of endoscopic ultrasound in preoperative staging of esophageal cancer. <i>Endoscopy</i> 2007; 39:715-719.	14
29.	van Westreenen HL, Westerterp M, Sloof GW et al. Limited additional value of positron emission tomography in staging oesophageal cancer. <i>Br J Surg</i> 2007; 94:1515-1520.	15

- 1 —
- 2 —
- 3 —
- 4 —
- 5 —
- 6 —
- 7 —
- 8 —
- 9 —
- 10 —
- 11 —
- 12 —
- 13 —
- 14 —
- 15 —
- 16 —
- 17 —
- 18 —
- 19 —
- 20 —
- 21 —
- 22 —
- 23 —
- 24 —
- 25 —
- 26 —
- 27 —
- 28 —
- 29 —
- 30 —
- 31 —
- 32 —

11

- 30. van Westreenen HL, Westerterp M, Bossuyt PM et al. Systematic review of the staging performance of 18F-fluorodeoxyglucose positron emission tomography in esophageal cancer. *J Clin Oncol* 2004; 22:3805-3812.
- 31. Ott K, Weber W, Siewert JR. The importance of PET in the diagnosis and response evaluation of esophageal cancer. *Dis Esophagus* 2006; 19:433-442.
- 32. Wittekind C, Greene FL, Hutter RVP, Klimpfinger M, Sobin LH. TNM Atlas. Illustrated guide to the TNM/pTNM classification of malignant tumors. Berlin: Springer-Verlag; 2004.
- 33. American Joint Committee on Cancer. AJCC cancer staging handbook. New York: Springer; 2002.
- 34. van Vliet EP, Steyerberg EW, Eijkemans MJ, Kuipers EJ, Siersema PD. Detection of distant metastases in patients with oesophageal or gastric cardia cancer: a diagnostic decision analysis. *Br J Cancer* 2007; 97:868-876.
- 35. Lordick F, Stein HJ, Peschel C, Siewert JR. Neoadjuvant therapy for oesophagogastric cancer. *Br J Surg* 2004; 91:540-551.
- 36. Westerterp M, van Westreenen HL, Reitsma JB et al. Esophageal cancer: CT, endoscopic US, and FDG PET for assessment of response to neoadjuvant therapy--systematic review. *Radiology* 2005; 236:841-851.
- 37. Lordick F, Ott K, Krause BJ et al. PET to assess early metabolic response and to guide treatment of adenocarcinoma of the oesophagogastric junction: the MUNICON phase II trial. *Lancet Oncol* 2007; 8:797-805.
- 38. Port JL, Lee PC, Korst RJ et al. Positron emission tomographic scanning predicts survival after induction chemotherapy for esophageal carcinoma. *Ann Thorac Surg* 2007; 84:393-400.
- 39. Sloof GW. Response monitoring of neoadjuvant therapy using CT, EUS, and FDG-PET. *Best Pract Res Clin Gastroenterol* 2006; 20:941-957.
- 40. Kato H, Kuwano H, Nakajima M et al. Usefulness of positron emission tomography for assessing the response of neoadjuvant chemoradiotherapy in patients with esophageal cancer. *Am J Surg* 2002; 184:279-283.

- 1
- 2
- 3
- 4
- 5
- 6
- 7
- 8
- 9
- 10
- 11
- 12
- 13
- 14
- 15
- 16
- 17
- 18
- 19
- 20
- 21
- 22
- 23
- 24
- 25
- 26
- 27
- 28
- 29
- 30
- 31
- 32

12

Submitted for publication

Sentinel node biopsy in esophageal cancer: Results of a Western European feasibility study

Judith Boone¹

Monique G.G. Hobbelink²

Marguerite E.I. Schipper³

Frank P. Vleggaar⁴

Inne H.M. Borel Rinkes¹

Pieter H.W. Lubbert^{1,5}

Johannes W. van Isselt²

Richard van Hillegersberg¹

Department of ¹Surgery, ²Radiology and Nuclear Medicine, ³Pathology and
⁴Gastroenterology and Hepatology, University Medical Center Utrecht
Department of ⁵Surgery, Martini Hospital Groningen

ABSTRACT**Background**

The morbidity of esophagectomy could be reduced by omitting the extensive lymph node dissection (LND) in patients without lymph node metastases. The aims of this study were to assess the feasibility of the sentinel node (SN) concept in Western European esophageal cancer patients and to compare our results with those reported in the literature.

Methods

The SN procedure was performed in 8 esophageal cancer patients without evidence of lymph node metastases, who were scheduled for robot-assisted thoracoscopic esophagectomy with 2-field LND. The day before surgery, 4 deposits of Tc-99m-labeled nanocolloid (400 MBq) were endoscopically injected into the submucosa of the tumor. Lymphoscintigraphy was performed 1 and 3 hours after injection. Intraoperatively, SNs were detected by gamma probe. Resected specimens were analyzed for remaining activity by scintigraphy and by gamma probe.

Results

Visualization rates of lymphoscintigraphy 1 and 3 hours after tracer injection were 88% and 100%, respectively. Intra-operative identification rate was 38%. The accuracy of the SN procedure was 38%; false-negative rate was 100%. Studies reported in the literature have shown visualization rates of SNs ranging from 60-92%. The overall false-negative rate varied from 4-100%.

Conclusion

With a false-negative rate of 100%, the results of our feasibility study have shown SN biopsy to be of no value in our study group. Nevertheless, since the results reported from Japanese institutes in superficial carcinomas are promising, this technique may still be feasible in superficial (i.e. cT1) tumors.

INTRODUCTION

Esophageal cancer is the 8th most common malignancy in the world with an estimated 462.000 newly diagnosed patients in 2002.¹ For patients with locoregional disease, the best chance of cure is offered by radical esophagectomy.² As the esophagus has a unique submucosal lymphatic drainage system, the lymphatic spread of esophageal cancer is unpredictable and very variable.³ Hence, during transthoracic esophagectomy (TTE) an extensive mediastinal and upper abdominal lymph node dissection (LND) is performed to clear all metastatic disease. As the cervical region is a common site of tumor recurrence, some surgeons routinely carry out a cervical LND as well.⁴⁻⁶

TTE is accompanied by substantial morbidity, predominantly cardiopulmonary, which is a result of the thoracotomy, the concurrent one-lung-ventilation and the extensive mediastinal dissection.² Surgical strategies have been employed to reduce the morbidity, e.g. less extensive procedures such as a transhiatal approach without thoracotomy or minimally invasive techniques such as thoracoscopy and laparoscopy.^{7,8} For patients without lymph node metastases in the resected specimen (pN0), the extensive LND of TTE may be regarded redundant. In these patients, morbidity might be reduced by tailoring the extent of LND. This could be accomplished by the application of sentinel node navigation surgery.

A sentinel node (SN) is defined as the lymph node that receives lymphatic flow directly from the primary tumor, being the first site of metastatic spread.⁹ Depending on the tracer used, SNs can be detected by a gamma camera, a gamma probe, computed tomography (CT) lymphography, magnetic resonance imaging (MRI) lymphography or by observing blue dye. The SN concept states that when pathologic analysis of the detected SN(s) shows no tumor invasion, extensive dissection of the lymph nodes that drain the SN(s) can be omitted.¹⁰ SN biopsy is now widely adopted in the management of early stage breast cancer and melanoma.¹⁰⁻¹²

In esophageal cancer, SN mapping by radioactive tracer was first described by Kitagawa et al. in 2000.¹³ In subsequent years several other clinical studies on this subject have been performed, predominantly in Japanese institutes.¹⁴⁻¹⁸ In Japan screening modalities have been introduced to detect and treat esophageal cancer at an early stage, as it is a very common malignancy in that country. Patients with early stage disease generally

1 have no lymph node metastases and are therefore candidates for the SN procedure.
2 The aims of the current study were to assess the feasibility of SN mapping in Western
3 European esophageal cancer patients and to compare our results with those reported
4 in the literature.
5
6

7 **MATERIALS AND METHODS**

8 ***Patients***

9 Eight patients with resectable esophageal cancer who were scheduled to undergo
10 esophagectomy with 2-field LND were included in our feasibility study. Routine
11 diagnostic work-up consisted of esophagogastroduodenoscopy (EGD) with biopsy,
12 radial endoscopic ultrasonography (EUS) (GIF-UM130, Olympus, Hamburg, Germany),
13 CT scan of the chest and abdomen, ultrasonography (US) of the neck with fine needle
14 aspiration (FNA) when indicated, lung function testing and bronchoscopy in case of
15 suspected airway ingrowth. Patients were eligible for SN biopsy if all of the following
16 criteria were fulfilled: (i) proven adenocarcinoma (AC) or squamous cell carcinoma
17 (SCC) of the esophagus; (ii) resectable disease (i.e. cT1-3 or cT4pleura/crus); (iii) no
18 pre-operative evidence of lymph node metastases (cN0, cM0) and (iv) no neoadjuvant
19 therapy. The study was approved by our local medical research ethics committee and
20 written informed consent was obtained from all participating patients.
21

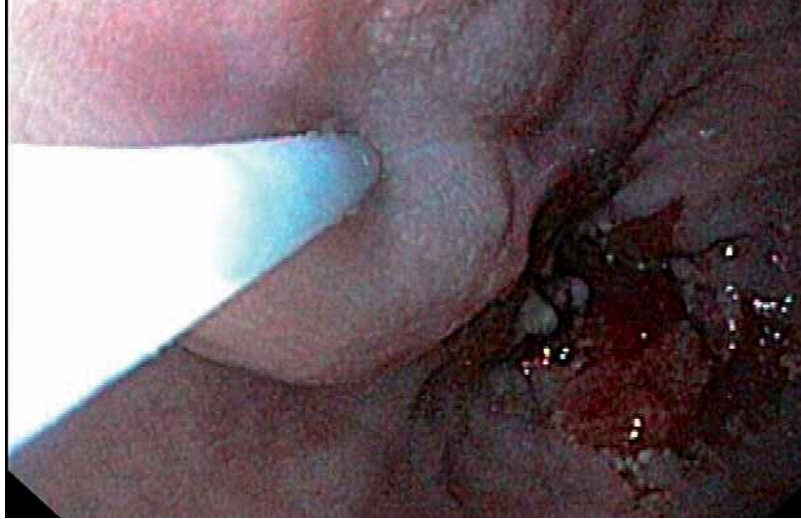12

22 ***Radiocolloid injection and preoperative SN identification***

23 One day before surgery patients underwent EGD under light sedation. Using a 9.8
24 mm gastroscop (GIF-140, Olympus, Hamburg, Germany), 400 MBq Tc-99m-labeled
25 nanocolloid (Amersham Cygne, Eindhoven, The Netherlands) in a maximum volume
26 of 2 mL was injected into the submucosal layer overlaying the tumor in 4 quadrants (2
27 proximal and 2 distal from the tumor; Figure 1).
28

29 One hour and approximately 3 hours after injection, static images in anterior, posterior
30 and lateral planes were obtained by a dual-head gamma camera with a low energy, high
31 resolution (LEHR) collimator (Argus®; Philips Medical Systems, Best, The Netherlands) to
32 locate focal areas of radioactivity. (Figure 2 and 3)

Figure 1 - Peritumoral injection of the radioactive tracer into 4 quadrants during esophagogastrosocopy (see page 298 for color figure).

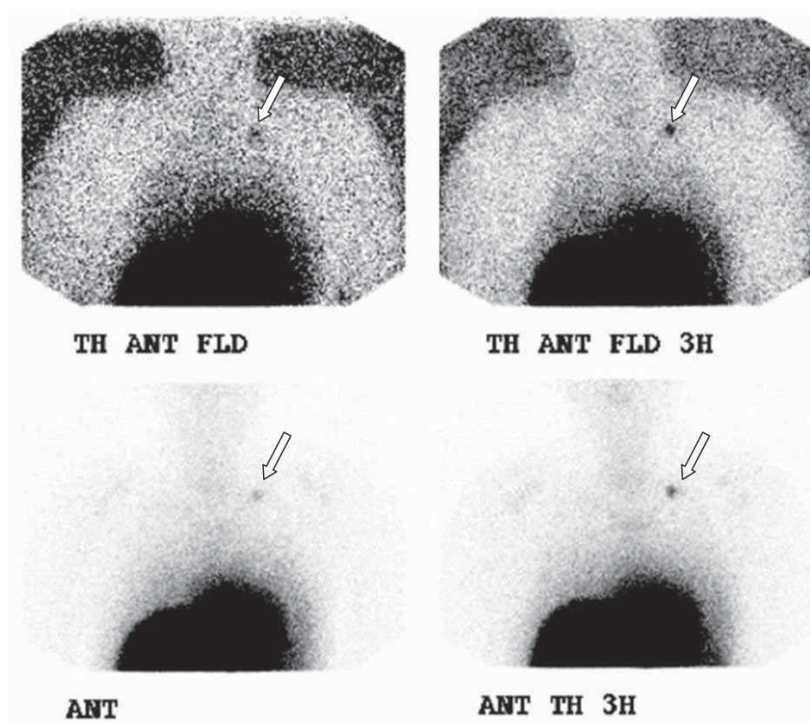


Surgical procedure and intraoperative SN identification

All patients underwent thoracolumbaroscopic esophagectomy with two-field LND aided by the Da Vinci™ robotic system (Intuitive Surgical, Sunnyvale, USA).¹⁹ Dissected lymph nodes included the paratracheal, subcarinal, aortopulmonary window, periesophageal, celiac and lesser omental nodes. The digestive tract was reconstructed by a gastric conduit, which was anastomosed in the neck.

During surgery, potential SNs in the thoracic and abdominal cavities were identified by intracorporeally measuring the radioactivity with a handheld gamma probe (Europrobe II; Eurorad, Strasbourg, France). Radioactivity of the cervical region was assessed with the handheld gamma probe through the cervical incision at the left side and percutaneously at the right side of the neck. After the resected specimen was removed from the patient, the thoracic and abdominal cavities were explored with the gamma probe for remaining radioactivity.

Figure 2 - Example of scintigraphic examination (thoracic part) performed one hour (left) and 3 hours (right) after radioactive tracer injection. A focal area of radioactivity is noticed in the left infraclavicular region.



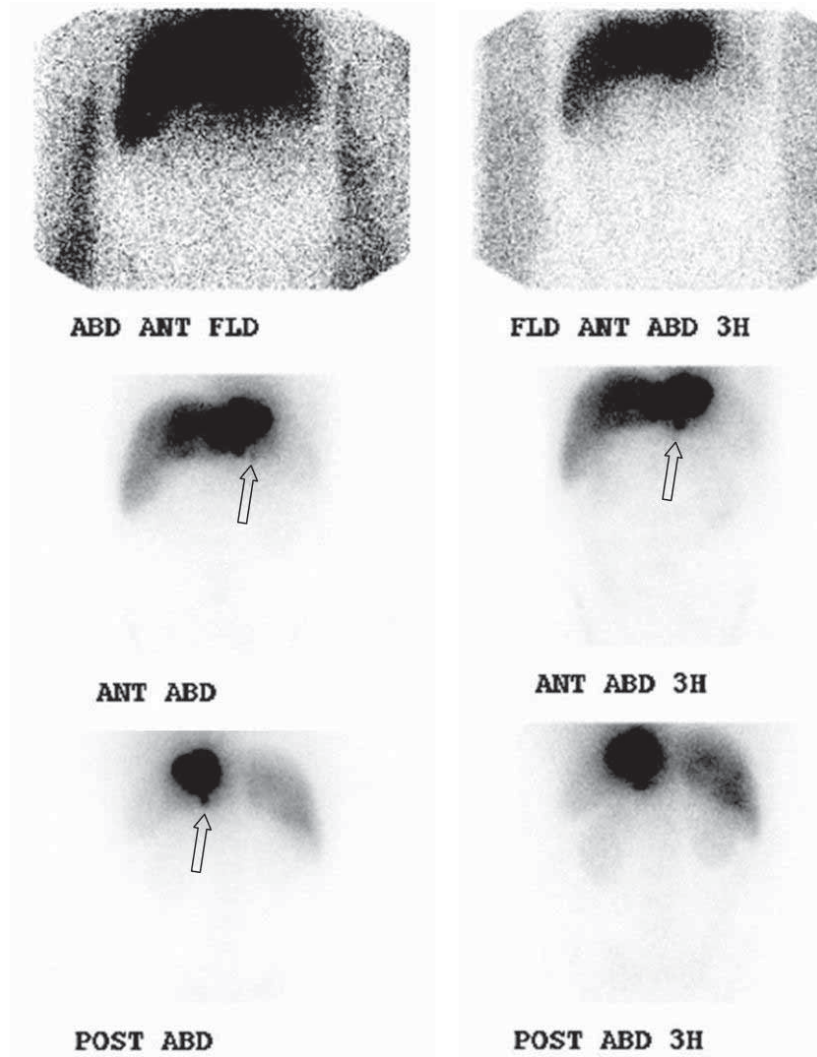
ANT: anterior; TH: thoracic; FLD: views with flood source (delineating the patient's body contour).

12

Postoperative SN identification

At the Department of Pathology the resected specimen was opened and was attached on a paraffin board. In this way, overlap in radioactivity from the tumor and from possible lymph nodes was avoided. Lymphoscintigraphy of the resected specimen was performed at the Department of Nuclear Medicine in order to visualize the location of focal radioactivity; possible SNs were marked. Subsequently, the radioactivity of the detected possible SNs was counted with the handheld gamma probe and the identified hot nodes were separated from the resected specimen for individual histopathologic examination.

Figure 3 - Scintigraphic examination (abdominal part) performed one hour (left) and 3 hours (right) after radioactive tracer injection in the same patient as in Figure 2. A focal area of radioactivity is seen caudal to one of the injection sites.



ANT: anterior; POST: posterior; ABD: abdominal; FLD: views with flood source (delineating the patient's body contour).

- 1
- 2
- 3
- 4
- 5
- 6
- 7
- 8
- 9
- 10
- 11
- 12
- 13
- 14
- 15
- 16
- 17
- 18
- 19
- 20
- 21
- 22
- 23
- 24
- 25
- 26
- 27
- 28
- 29
- 30
- 31
- 32

Histopathologic examination

The resected esophageal specimen including the remaining non-sentinel lymph nodes were fixed in 4% formalin for 24 hours. Non-sentinel lymph nodes were identified by slicing the fatty tissue surrounding the esophagus and gastric cardia. The resected specimen and non-SNs, cut in largest diameter, were fixed in formalin and embedded in paraffin. Tissue sections (3 μ m) were stained with haematoxylin and eosin (H&E) for routine histopathologic examination. All resected specimens were examined by 1 experienced oncologic pathologist (MS).

SNs were processed according to a regional standard protocol. After formalin fixation and paraffin embedding, step sections of 3 μ m thick were cut at 5 levels with 250 μ m intervals for H&E staining. In case no lymph node metastases could be identified by H&E examination, immunohistochemical analysis was performed at each level with CAM 5.2 (Becton-Dickinson Biosciences, San Jose, USA, catalog# 349205) in case of primary adenocarcinoma or CK AE1/3 (Neomarkers/Lab Vision, Fremont, USA, catalog# MS-343-P) in case of SCC to detect micrometastases or isolated tumor cells.

Statistical analysis

Statistical analysis was performed using the SPSS software for Windows (Version 12.0, SPSS, Chicago, IL, USA). The identification rate, accuracy, false-negative rate and sensitivity of the SN procedure were calculated according to the standard definitions.²⁰

12**RESULTS**

The median age at the time of surgery was 62 (range, 45-71) years (Table 1). The tumor was located in the middle third part of the esophagus in 2 (25%) patients, the lower third in 5 (63%) and the gastroesophageal junction in 1 (13%). The median tumor size was 3.5 (range, 2-8) cm. Histopathologic examination of the resected specimens revealed that 50% of the tumors were adenocarcinomas and 50% were squamous cell carcinomas.

Pre-operative lymphoscintigraphy

No complications of the SN procedure were noticed. The lymphoscintigraphy performed 1 hour after radiocolloid injection identified possible SNs in 7 out of 8 patients, resulting in a visualization rate of 88%. A median of 2 SNs (range 0-4) were detected by the lymphoscintigraphy performed 1 hour after injection (Table 1). The visualization rate of lymphoscintigraphy performed 3 hours post injection was 100%, with a median of 3.5 (range 2-7) identified SNs.

Intraoperative SN detection

With the intraoperative gamma probe, the identification rate was 38% (3 patients out of 8). The main cause of failure was the accumulation of the radioactive tracer in direct proximity to the tumor, surpassing the radioactivity of surrounding (regional) lymph nodes. In 3 patients a total of 5 SNs could be detected with the intraoperative gamma probe. These 5 SNs were detected cervically (n=3), para-esophageally (n=1) and subcarinally (n=1).

SN detection in resected specimen

Scintigraphic examination of the resected specimen revealed a median of 5 SNs (range 1-5). The identification rate was 100%. When analysing the resected specimen with the gamma probe, in all 8 patients 1 or more SN(s) were detected. Therefore, the post-surgical identification rate for the gamma probe was 100%. A median number of 3 SNs (range 1-5) were detected by gamma probe analysis of the resected specimens.

In all 5 patients with lymph node metastases in the resected specimen, the SN was tumor negative even after immunohistochemical analysis and additional serial sectioning. Therefore the false-negative rate was 100% and the sensitivity 0%. The overall accuracy of SN biopsy in our study population was 38%.

DISCUSSION

The aim of the SN concept in esophageal cancer is to reduce the morbidity of esophagectomy by diminishing the extent of LND based on the identification and intraoperative histological examination of SNs in patients with clinically node-negative disease. With a false-negative rate of 100%, the results of our feasibility study have shown SN biopsy to be of no value in our study group.

Some technical issues deserve more consideration. In our series, lymphoscintigraphy 1 hour and 3 hours after radioactive tracer injection resulted in visualization rates of 88% and 100%, respectively. The higher rate in the latter is probably due to further flow of tracer particles in the lymphatics, resulting in the appearance of more first echelon lymph nodes. These results exceed those reported in the literature (60-92%; Table 2), despite the fact that the time between tracer injection and initial lymphoscintigraphy in those studies was longer (range 3-12 hours).^{16,21} This difference could be explained by the variation in particle size of the radioactive tracers used. As shown in Table 2, the most commonly used tracer in Japan is Tc-99m-labeled stannous colloid^{13,14,16-18,21,22} (particle size 400-500 nm), whereas in the Western world it is Tc-99m nanocolloid²³⁻²⁵ (<80 nm). The larger the particle size, the longer it takes to pass through the lymphatic system.

In order to determine the location of the SNs, most research groups produce lymphoscintigraphic images in 1 or 2 planes: anterior^{13,22,26-28}, posterior or both^{15,16}. However, due to overprojection of our injection sites it may be difficult to image SNs.

In order to increase the yield we added an oblique plane to the anterior and posterior acquisition planes. Additionally, in the first patient we performed a single photon emission CT (SPECT) study. Despite these efforts, visualization of peritumoral SNs remained difficult due to massive retention of radioactivity at the injection sites. This may have caused false-negative examinations. Overall, the false-negative rate of our study (100%) is identical to that of Kosugi et al.¹⁶, but substantial higher than results reported in 4 other series (4-22%).^{14,15,21,25}

Table 1 - Overview of the 8 esophageal cancer patients having undergone SN biopsy

Patient	Age	Sex	cTNM	Scint. 1 hr	Scint. 3 hrs	Intra-op.	Scint. Spec.	# hot SN ex vivo	# dissected In	# In meta-stases	# SN tumor pos	Histol.	pTNM
1	69	F	cT1smNOM0	1	5	0	-	4	29	0	0	SCC	T1NOM0
2	57	M	cT3NOM0	2	2	0	1	1	29	10	0	AC	T3N1M1a
3	69	M	cT3NOM0	4	4	0	5	3	39	4	0	AC	T3NOM1a
4	63	M	cT1mNOM0	3	3	2	5	1	35	2	0	SCC	T1N1M0
5	45	M	cT3NOM0	2	2	1	2	3	23	4	0	AC	T3N1M1a
6	60	M	cT3N1M0	2	4	2	5	3	33	5	0	SCC	T3N1M1a
7	71	M	cT2NOM0	0	3	0	4	1	30	0	0	AC	T1NOM0
8	54	M	cT1NOM0	4	7	0	5	5	14	0	0	SCC	T1NOM0
Median	62	-	-	2	3.5	0	5	3	30	3	0	-	-

AC : adenocarcinoma
cTNM : clinical Tumor Node Metastasis stage
F : female
Histol : histology
Hr(s) : hour(s)
intra-op : number of intra-operatively identified structures with focal radioactivity by gamma probe
Ln : lymph node
M : male
Pos : positive
pTNM : pathologic Tumor Node Metastasis stage
SCC : squamous cell carcinoma
Scint : scintigraphy
Scint 1 hr : number of focal areas of radioactivity as identified by scintigraphic examination performed 1 hour after injection
Scint 3 hrs : number of focal areas of radioactivity as identified by scintigraphic examination performed 3 hours after injection
Scint specimen : number of focal areas of radioactivity as identified by scintigraphic examination of the resected specimen
hot SN ex vivo : number of hot sentinel nodes identified by gamma probe examination of the resected specimen
SN : sentinel node

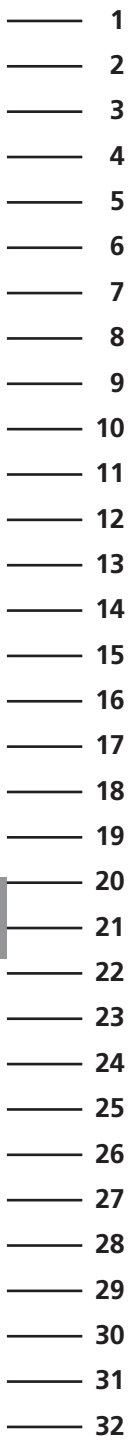


Table 2 - Overview of the literature on SN mapping with a radioactive tracer in esophageal cancer including the results of the current feasibility study

Author	N	Histology	Tracer	Scint	Time of scint	Probe	DR overall	DR probe	Accuracy	FN Rate	Sensitivity
Arima ¹⁴	19	SCC	99mTc Sn	No	n.a.	Intra + ex vivo	n.a.	95%	78%	22%	78%
Bohanes ²³	1	SCC	99mTc nano	Yes	Directly after injection	Intra	n.a.	n.a.	n.a.	n.a.	n.a.
Burian ²⁴	20	AC	99mTc colloid + dye	?	n.a.	?	85%	?	?	?	?
Fujii ^{21*}	61	?	99mTc Sn	Yes	?	Intra	92%	?	92%	14%	?
Kato ¹⁵	25	SCC	99mTc ReS	Yes	+/- 12 hrs after injection	Intra	92%	?	91.3%	8.7%	86.7%
Kitagawa 2000 ^{13*}	16	?	99mTc Sn	Yes	?	Intra	88%	?	93%	?	89%
Kitagawa 2001 ^{22*}	33	?	99mTc Sn	?	?	Intra	?	?	?	?	85%
Kosugi ¹⁶	10	?	99mTc Sn	Yes	3 hrs after injection	Ex vivo	60%	90%	77.8%	100%	0%
Lamb ²⁵	57	AC	99mTc nano	No	n.a.	Intra + ex vivo	n.a.	100%	96%	4%	?
Tanaka ¹⁷	1	SCC	99mTc Sn	Yes	3 hrs after injection	No	n.a.	n.a.	n.a.	n.a.	n.a.
Yasuda ¹⁸	23	?	99mTc Sn	No	n.a.	Intra	?	?	?	?	?
Current study	8	AC + SCC	99mTc nano	Yes	1hr & 3hrs after injection	Intra + ex vivo	88%; 100%	38%	38%	100%	0%

*These 3 reports are from the same research group and describe the results of the same, but enlarged, study population

AC : adenocarcinoma
 Colloid : colloid (unspecified)
 DR : detection rate
 FN : false-negative
 Intra : intraoperatively
 n.a. : not applicable
 nano : nanocolloid

ReS : rhenium sulfide
 SCC : squamous cell carcinoma
 Scint : scintigraphy
 Sn : tin
 Tc : technetium
 ? : not reported

It is hypothesized that our false-negative results could also be a result of metastatic tumor cells. When either the lymphatic drainage channels or the lymph nodes are blocked by tumor cells, the tracer may not be able to enter the initial lymphatic drainage of the tumor and may follow an alternative route, in that way bypassing the SNs. This hypothesis is supported by data from the literature. In 43 patients with esophageal or gastric cancer having undergone SN mapping with 0.75 mCi ^{99m}Tc -Sn colloid, radioisotope uptake was significantly decreased in lymph nodes in which more than 60% of the lymph node contained metastatic tumor cells.¹⁴ Remarkably, when reviewing the current literature on SN biopsy in esophageal cancer, 4 (36%) of 11 studies included patients with clinical suspicion of lymph node metastases.^{14,15,17,25} As this is an indication for extensive LND, SN biopsy in these patients offers no added value. For this reason, our aim was to include only cN0 patients in our feasibility study. Nonetheless, histopathologic examination of the resected specimens revealed lymph node metastases in 5 (63%) of 8 patients.

Our intraoperative gamma probe detection rate was 38%. Eight other research groups have attempted to intraoperatively identify SNs with a gamma probe as well (Table 2).^{13-15,18,21-23,25} Lamb et al. reported an intraoperative detection rate of 100%.²⁵ An explanation for their excellent results could be their open surgical procedure, which facilitated proper assessment for radioactivity of all lymph node stations separately. In addition, they have injected the radioactive tracer immediately before start of surgery, which allowed for the identification of early lymphatic spread. Yet, the authors reported no screening for undetected lymph nodes of resected specimens (e.g. with a gamma camera). In our opinion, the *intraoperative* gamma probe is beneficial only in detecting hot nodes in the cervical region and for exploring the abdominal and thoracic cavities for remaining radioactivity after resection. *Ex vivo* SN identification by means of the gamma probe was possible in all (100%) patients, which is comparable to the 90-95% reported in the literature (Table 2).^{14,16} As lymphoscintigraphy visualizes radioactive tracer accumulation as well as tracer pathways, the actual amount of SNs identified by gamma probe analysis of the resected specimens in our series was less than the number of areas with high amounts of radioactivity as identified by lymphoscintigraphic examination of the resected specimens.

As an alternative for the radionuclide procedure, Suga et al. have developed interstitial CT

1 lymphography to detect SNs.^{29,30} With this technique the water-soluble iodine contrast
2 medium iopamidol is endoscopically injected into the submucosal layer surrounding
3 the tumor. By multiplanar reconstruction and maximum intensity projection images
4 reconstructed from the transaxial post-contrast CT images, the route of enhanced
5 lymphatic vessels can be visualized. The first lymph nodes with direct connection to these
6 lymphatic vessels are considered the SNs. In 12 patients with superficial esophageal
7 cancer, a median of 2.3 SNs were detected. All pre-operatively detected SNs were
8 identified during surgery. With a sensitivity of 100% and with no false-negative cases,
9 this technique seems promising.^{29,30} Comparable favorable results of CT lymphography
10 have been obtained in other malignancies, such as lung and breast carcinoma.³¹⁻³³ So
11 far only one research group has reported their experience with this technique.

12 SN mapping could also be done by means of ferumoxide-enhanced MRI lymphography.
13 ³⁴⁻³⁶ Similar to the 2 techniques described before, superparamagnetic iron oxide is
14 injected into the submucosa of the peritumoral region during gastroscopy. Overall
15 sensitivity of this procedure was only 66% (4 out of 6 patients), due to absence of flux
16 of ferumoxides to metastatic lymph nodes in 2 patients.³⁵ An additional disadvantage
17 of this technique in esophageal cancer is that cardiac motion artifacts limit the scanning
18 area to the region from the larynx to the carina and from the gastric cardia to the renal
19 hilus.³⁷ Consequently, periesophageal (i.e. regional) lymph nodes, which frequently are
20 the first site of metastatic tumor spread, can not be assessed. This may cause false-
21 negative examinations as well.

12

22 Although dye-guided detection of SNs is commonly used in breast cancer and melanoma,
23 it has not gained wide popularity in esophageal cancer. As the lymphatic drainage of
24 the esophagus is unpredictable and variable, real-time observation of the lymphatic
25 pathway of esophageal tumors by blue dye is only feasible when the esophagus is
26 entirely mobilized. This, however, will lead to destruction of the active lymphatic flow
27 from the primary tumor and will compromise the further detection of SNs. Furthermore,
28 it is difficult to differentiate blue colored upper mediastinal lymph nodes from nodes
29 that are pigmented by anthracosis. Additionally, it is impossible to directly follow the
30 lymphatic flow from the primary tumor to cervical lymph nodes. Only one group has
31 described the application of blue dye (in combination with a radioactive tracer) in SN
32 mapping for esophageal cancer.²⁴ Blue dye was easily detected in abdominal lymph

nodes during laparotomy of patients with AEG III (subcardial) tumors. In case of distal esophageal or AEG II carcinomas, SNs located in the lower mediastinum could only be detected with the radioactive tracer.²⁴

In conclusion, with a false-negative rate of 100%, our feasibility study has shown that SN biopsy was of no value in our study group. Nevertheless, with a view on the results of some Japanese studies regarding this subject, SN biopsy might still be applicable in early stage (T1-2) esophageal cancer.

- 1
- 2
- 3
- 4
- 5
- 6
- 7
- 8
- 9
- 10
- 11
- 12
- 13
- 14
- 15
- 16
- 17
- 18
- 19
- 20
- 12** — 21
- 22
- 23
- 24
- 25
- 26
- 27
- 28
- 29
- 30
- 31
- 32

REFERENCES

1. Kamangar F, Dores GM, Anderson WF. Patterns of cancer incidence, mortality, and prevalence across five continents: defining priorities to reduce cancer disparities in different geographic regions of the world. *J Clin Oncol* 2006; 24:2137-2150.
2. Hulscher JB, van Sandick JW, de Boer AG et al. Extended transthoracic resection compared with limited transhiatal resection for adenocarcinoma of the esophagus. *N Engl J Med* 2002; 347:1662-1669.
3. Zuidema GD, Yeo CJ. *Surgery of the Alimentary Tract*, 5th Edition. Philadelphia: W.B. Saunders, 2002.
4. Lerut T, Naftoux P, Moons J et al. Three-field lymphadenectomy for carcinoma of the esophagus and gastroesophageal junction in 174 R0 resections: impact on staging, disease-free survival, and outcome: a plea for adaptation of TNM classification in upper-half esophageal carcinoma. *Ann Surg* 2004; 240:962-972.
5. Isono K, Sato H, Nakayama K. Results of a nationwide study on the three-field lymph node dissection of esophageal cancer. *Oncology* 1991; 48:411-420.
6. Baba M, Aikou T, Yoshinaka H et al. Long-term results of subtotal esophagectomy with three-field lymphadenectomy for carcinoma of the thoracic esophagus. *Ann Surg* 1994; 219:310-316.
7. Orringer MB, Marshall B, Chang AC et al. Two thousand transhiatal esophagectomies: changing trends, lessons learned. *Ann Surg* 2007; 246:363-372.
8. Luketich JD, Alvelo-Rivera M, Buenaventura PO et al. Minimally invasive esophagectomy: outcomes in 222 patients. *Ann Surg* 2003; 238:494-495.
9. Nieweg OE, Tanis PJ, Kroon BB. The definition of a sentinel node. *Ann Surg Oncol* 2001; 8:538-541.
10. Amersi F, Morton DL. The role of sentinel lymph node biopsy in the management of melanoma. *Adv Surg* 2007; 41:241-56:241-256.
11. Sato K, Shigenaga R, Ueda S et al. Sentinel lymph node biopsy for breast cancer. *J Surg Oncol* 2007; 96:322-329.
12. Kim T, Giuliano AE, Lyman GH. Lymphatic mapping and sentinel lymph node biopsy in early-stage breast carcinoma: a metaanalysis. *Cancer* 2006; 106:4-16.
13. Kitagawa Y, Fujii H, Mukai M et al. The role of the sentinel lymph node in gastrointestinal cancer. *Surg Clin North Am* 2000; 80:1799-1809.
14. Arima H, Natsugoe S, Uenosono Y et al. Area of nodal metastasis and radioisotope uptake in sentinel nodes of upper gastrointestinal cancer. *J Surg Res* 2006; 135:250-254.
15. Kato H, Miyazaki T, Nakajima M et al. Sentinel lymph nodes with technetium-99m colloidal rhenium sulfide in patients with esophageal carcinoma. *Cancer* 2003; 98:932-939.

16. Kosugi S, Nakagawa S, Kanda T et al. Radio-guided sentinel node mapping in patients with superficial esophageal carcinoma: Feasibility study. *Minim Invasive Ther Allied Technol* 2007; 16:181-186. — 1
17. Tanaka C, Fujii H, Kitagawa Y et al. Oblique view of preoperative lymphoscintigraphy improves detection of sentinel lymph nodes in esophageal cancer. *Ann Nucl Med* 2005; 19:719-723. — 2
18. Yasuda S, Shimada H, Chino O et al. Sentinel Lymph Node Detection with Tc-99m Tin Colloids in Patients with Esophagogastric Cancer. *Jpn J Clin Oncol* 2003; 33:68-72. — 3
19. van Hillegersberg R, Boone J, Draaisma WA et al. First experience with robot-assisted thoracoscopic esophagolymphadenectomy for esophageal cancer. *Surg Endosc* 2006; 20:1435-1439. — 4
20. de Haas RJ, Wicherts DA, Hobbelink MG et al. Sentinel lymph node mapping in colon cancer: current status. *Ann Surg Oncol* 2007; 14:1070-1080. — 5
21. Fujii H, Kitagawa Y, Kitajima M et al. Sentinel nodes of malignancies originating in the alimentary tract. *Ann Nucl Med* 2004; 18:1-12. — 6
22. Kitagawa Y, Ohgami M, Fujii H et al. Laparoscopic detection of sentinel lymph nodes in gastrointestinal cancer: a novel and minimally invasive approach. *Ann Surg Oncol* 2001; 8:865-895. — 7
23. Bohanes T, Neoral C, Aujesky R et al. Sentinel lymph node in esophageal cancer before neoadjuvant therapy. *Biomed Pap Med Fac Univ Palacky Olomouc Czech Repub* 2005; 149:145-147. — 8
24. Burian M, Stein HJ, Sandler A et al. Sentinel Node Detection in Barrett's and Cardia Cancer. *Ann Surg Oncol* 2004; 11:255S-258. — 9
25. Lamb PJ, Griffin SM, Burt AD et al. Sentinel node biopsy to evaluate the metastatic dissemination of oesophageal adenocarcinoma. *Br J Surg* 2005;92:60-7. — 10
26. Kitagawa Y, Kitajima M. Gastrointestinal cancer and sentinel node navigation surgery. *J Surg Oncol* 2002; 79:188-193. — 11
27. Kitagawa Y, Fujii H, Mukai M et al. Intraoperative lymphatic mapping and sentinel lymph node sampling in esophageal and gastric cancer. *Surg Oncol Clin N Am* 2002; 11:293-304. — 12
28. Aikou T, Kitagawa Y, Kitajima M et al. Sentinel lymph node mapping with GI cancer. *Cancer Metastasis Rev* 2006; 25:269-277. — 13
29. Suga K, Shimizu K, Kawakami Y et al. Lymphatic drainage from esophagogastric tract: feasibility of endoscopic CT lymphography for direct visualization of pathways. *Radiology* 2005; 237:952-960. — 14
30. Hayashi H, Tangoku A, Suga K et al. CT lymphography-navigated sentinel lymph node biopsy in patients with superficial esophageal cancer. *Surgery* 2006; 139:224-235. — 15
31. Suga K, Yuan Y, Okada M et al. Breast sentinel lymph node mapping at CT lymphography with iodipamidol: preliminary experience. *Radiology* 2004; 230:543-552. — 16

- 1 —
- 2 —
- 3 —
- 4 —
- 5 —
- 6 —
- 7 —
- 8 —
- 9 —
- 10 —
- 11 —
- 12 —
- 13 —
- 14 —
- 15 —
- 16 —
- 17 —
- 18 —
- 19 —
- 20 —
- 21 —
- 22 —
- 23 —
- 24 —
- 25 —
- 26 —
- 27 —
- 28 —
- 29 —
- 30 —
- 31 —
- 32 —

12

- 32. Suga K, Yuan Y, Ueda K et al. Computed tomography lymphography with intrapulmonary injection of iopamidol for sentinel lymph node localization. *Invest Radiol* 2004; 39:313-324.
- 33. Tangoku A, Yamamoto S, Suga K et al. Sentinel lymph node biopsy using computed tomography-lymphography in patients with breast cancer. *Surgery* 2004; 135:258-265.
- 34. Imano H, Motoyama S, Saito R et al. Superior mediastinal and neck lymphatic mapping in mid- and lower-thoracic esophageal cancer as defined by ferumoxides-enhanced magnetic resonance imaging. *Jpn J Thorac Cardiovasc Surg* 2004; 52:445-450.
- 35. Motoyama S, Ishiyama K, Maruyama K et al. Preoperative mapping of lymphatic drainage from the tumor using ferumoxide-enhanced magnetic resonance imaging in clinical submucosal thoracic squamous cell esophageal cancer. *Surgery* 2007; 141:736-747.
- 36. Ishiyama K, Motoyama S, Tomura N et al. Visualization of lymphatic basin from the tumor using magnetic resonance lymphography with superparamagnetic iron oxide in patients with thoracic esophageal cancer. *J Comput Assist Tomogr* 2006; 30:270-275.
- 37. Nishimura H, Tanigawa N, Hiramatsu M et al. Preoperative esophageal cancer staging: magnetic resonance imaging of lymph node with ferumoxtran-10, an ultrasmall superparamagnetic iron oxide. *J Am Coll Surg* 2006; 202:604-611.

- 1
- 2
- 3
- 4
- 5
- 6
- 7
- 8
- 9
- 10
- 11
- 12
- 13
- 14
- 15
- 16
- 17
- 18
- 19
- 20
- 21
- 22
- 23
- 24
- 25
- 26
- 27
- 28
- 29
- 30
- 31
- 32

13

ANZ Journal of Surgery: 78(9);784-90

**Diagnostic value of routine aqueous
contrast swallow examination
after esophagectomy for
detecting leakage of the cervical
esophagogastric anastomosis**

Judith Boone¹

Inne H.M. Borel Rinkes¹

Maarten S. van Leeuwen²

Richard van Hillegersberg¹

Departments of ¹Surgery and ²Radiology
University Medical Center Utrecht

ABSTRACT**Background**

Water-soluble contrast swallow examination is routinely performed after oesophagectomy to detect leakage of the cervical oesophagogastric anastomosis. This study evaluated the diagnostic accuracy and clinical value.

Methods

Patients with oesophageal carcinoma receiving oesophagectomy with gastric conduit formation and a handsewn cervical anastomosis between 1989 and 2003 were reviewed on outcome of routine aqueous contrast swallow examination (RACSE) and appearance of clinical anastomotic leakage.

Results

RACSE was performed in 207 (82%) of 252 patients on postoperative day 8 (range 3-15). In 45 patients, no RACSE was executed, mainly due to a prolonged intensive care unit stay. In 18 (9%) of 207 cases, the RACSE could not be interpreted by the radiologist. In 19 (53%) of 36 patients who developed a clinical leakage, the leak had already manifested clinically before the routine contrast examination was planned. Taken together, the false positive rate was 8%, the false negative rate 48%, sensitivity 52%, specificity 92%, positive predictive value 46% and negative predictive value 93%. No significant differences were found between the accuracy of RACSE in end-to-end or end-to-side cervical anastomoses.

Conclusion

Given the very low sensitivity and low positive predictive value and given the fact that in 53% of patients with a clinical leak, the leakage had appeared clinically before the contrast swallow examination was routinely planned, we propose to abandon the routine contrast swallow examination after oesophagectomy to detect cervical anastomotic leakage. Alternatively, anastomotic integrity can be tested by drinking small amounts of water with simultaneous observation of the cervical wound.

INTRODUCTION

Radical oesophagolymphadenectomy remains the best chance for cure in patients with esophageal cancer. It is one of the most invasive operations in gastrointestinal surgery, associated with significant morbidity and mortality.¹ A feared complication of oesophageal resection is anastomotic leakage, because of the potentially catastrophic consequences of extravasation of gastrointestinal contents.^{2,3}

After oesophagectomy, continuity of the digestive tract is generally restored with a gastric conduit, which is anastomosed in the neck or intrathoracically. Although associated with a higher leak rate, cervical anastomoses are favored by many surgeons. The main reason is that when anastomotic leakage occurs, it is often restricted to the neck and can clinically be detected by the occurrence of wound infection or a salivary fistula. This leakage can mostly be treated conservatively by opening the cervical wound and applying local wound care.³

However, cervical leakage may descend into the posterior mediastinum, causing severe sepsis and mediastinitis.⁴ This will result in considerable morbidity and mortality, especially if untreated.

Consequently, to detect and treat anastomotic leakage timely, an aqueous contrast swallow examination is routinely performed around the 7th postoperative day in many hospitals worldwide. The value of this standard practice remains controversial, since false-negative contrast swallows frequently occur and since these examinations are occasionally accompanied by severe complications.⁵⁻⁷

The objective of this study was to determine the accuracy and clinical value of the routine aqueous contrast swallow examination (RACSE) in detecting or excluding leakage of the cervical oesophagogastric anastomosis following oesophageal resection.

METHODS

All consecutive patients who underwent oesophagectomy for esophageal cancer with gastric conduit formation and a cervical anastomosis at the authors' institute from January 1989 to June 2003 were retrospectively reviewed. Patients having received other types of reconstruction (colon, jejunum) were excluded from this study.

Surgical technique

Oesophagolymphadenectomy was performed through a transhiatal or a right-sided transthoracic approach. To reconstruct the digestive tract, a 3 cm wide gastric tube was fashioned along the greater curvature with a linear stapler device. After the staple line was oversewn, the gastric conduit was brought up to the neck through the posterior mediastinum. Using one-layer running suture (3-0 PDS), a cervical end-to-end or end-to-side anastomosis was executed, depending on the surgeon's preference and experience. After completion of the anastomosis, a nasogastric tube was positioned in the distal part of the gastric conduit. A feeding jejunostomy was placed to provide enteral feeding.

Routine contrast swallow examination

Radiographic contrast swallow examination was routinely performed in our hospital between the 7th and 10th postoperative day to detect anastomotic leakage. At the Department of Radiology, patients were given 120 ml of a water-soluble contrast agent (Ultravist 300) orally. Under fluoroscopy, spot images were obtained in anteriorposterior, oblique and lateral planes. All studies were interpreted by the attending radiologist.

Postoperative management

Until the contrast swallow examination was executed, oral intake was prohibited and patients were fed through the feeding jejunostomy. Furthermore, nasogastric suction was maintained to decompress the gastric conduit. When the RACSE did not show contrast leakage, oral intake was gradually resumed, starting with drinking small amounts of water. However, when a radiological leak was detected without clinical symptoms, oral intake was omitted for another week, followed by a second contrast swallow examination to determine if the radiological leak had resolved.

The treatment of a clinical leak was dependent on the severity of leakage. In case of limited clinical leakage, conservative treatment was carried out by opening the cervical wound and applying local wound care. Excessive leakage with systemic manifestations required surgical treatment by means of extensive drainage or takedown of the anastomosis.

Data collection and definitions

Data was collected from medical records of all patients that underwent oesophagectomy from January 1989–June 2003. Collected data included age, gender, operative approach, type of anastomosis (end-to-end or end-to-side), date, outcome and complications of contrast swallow examination and date, appearance and treatment of clinical leakage. Radiological leakage was defined by any extravasation of contrast during the swallow examination observed by the radiologist, which was not due to contrast aspiration. The gold standard “clinical leakage” was defined by: (i) the appearance of saliva through the cervical wound, or (ii) anastomotic leakage assessed by other diagnostic examination (e.g. gastroscopy, bronchoscopy or computed tomography scan), or (iii) anastomotic dehiscence seen at re-exploration, appearing before or after the RACSE was performed. A RACSE was defined true-positive when a patient with a radiological anastomotic leak developed a clinical leakage postoperatively; true-negative when in a patient without contrast leakage, no signs of a clinical leakage arose. The routine contrast examination was considered false-positive or ‘subclinical’, when a radiological leak was detected, but no clinical leakage occurred during the entire hospital stay; false-negative when an anastomotic leakage arose clinically despite the absence of radiological leakage.

Statistical analysis

Statistical analysis was done using SPSS for Windows (Version 12.0). Numbers are presented as mean (range). Percentages were rounded to the nearest whole number. False-positive rate, false-negative rate, sensitivity, specificity, positive predictive value (PPV) and negative predictive value (NPV)⁸ of the conclusive RACSEs in detecting clinical anastomotic leakage were calculated.

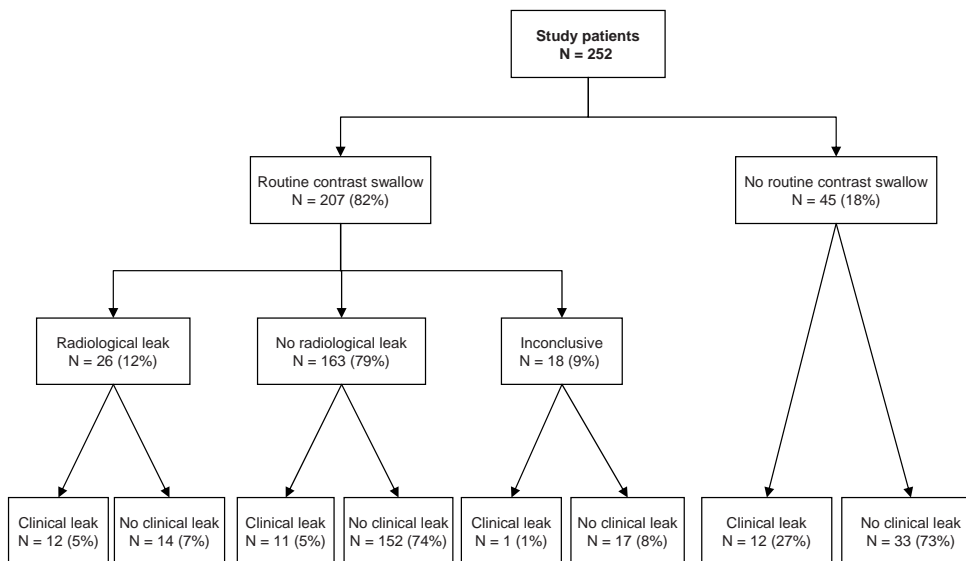
A subanalysis of end-to-end and end-to-side anastomoses was performed to compare the accuracy of RACSE in detecting anastomotic leakage. Groups were compared by Fisher’s exact test. *P* values of less than 0.050 were considered significant.

RESULTS

During the study period, 252 patients underwent oesophagolymphadenectomy for oesophageal cancer with gastric conduit formation and a handsewn cervical anastomosis. The study group consisted of 180 male patients and 72 female patients with a mean age of 62 (range 35-86). 189 patients were operated via a transhiatal and 63 via a transthoracic approach.

In Figure 1, an overview is given of the application of RACSE and the appearance of clinical leakage in the study group.

Figure 1 - Overview of the outcome of the routine aqueous contrast swallow examination and the appearance of clinical leakage in the study patients.



In 207 (82%) patients, a routine contrast swallow examination was performed on the 8th postoperative day (range 3-15). RACSE was not executed in 45 patients, because they had an extended stay at the intensive care unit (n=31), because anastomotic leakage had appeared clinically before performing the routinely planned swallow examination (n=10), because leakage was detected by an other diagnostic modality (n=2) or for other reasons (n=2). Clinically, a leakage occurred in 12 (27%) of these 45 patients on

the 6th postoperative day (range 2-12).

In 18 out of 207 (9%), radiographic examinations were inconclusive. In 12 patients, the cervical anastomosis could not be adequately assessed radiographically due to aspiration, resulting in an inadequate amount of contrast in the gastric conduit. Overall, some extent of aspiration occurred in 45 patients (22%); none of them developed aspiration pneumonia or pulmonary oedema afterwards. RACSE was inconclusive in 4 other patients, because the end-to-side anastomosis hampered the radiologist in differentiating leakage from filling of the blind end of the conduit, and in 2 patients due to other causes. Consequently, in 5 of 18 patients a second contrast swallow examination was planned. In one of the patients with an inconclusive first swallow examination, a clinical leakage occurred, which was detected by the second radiological examination.

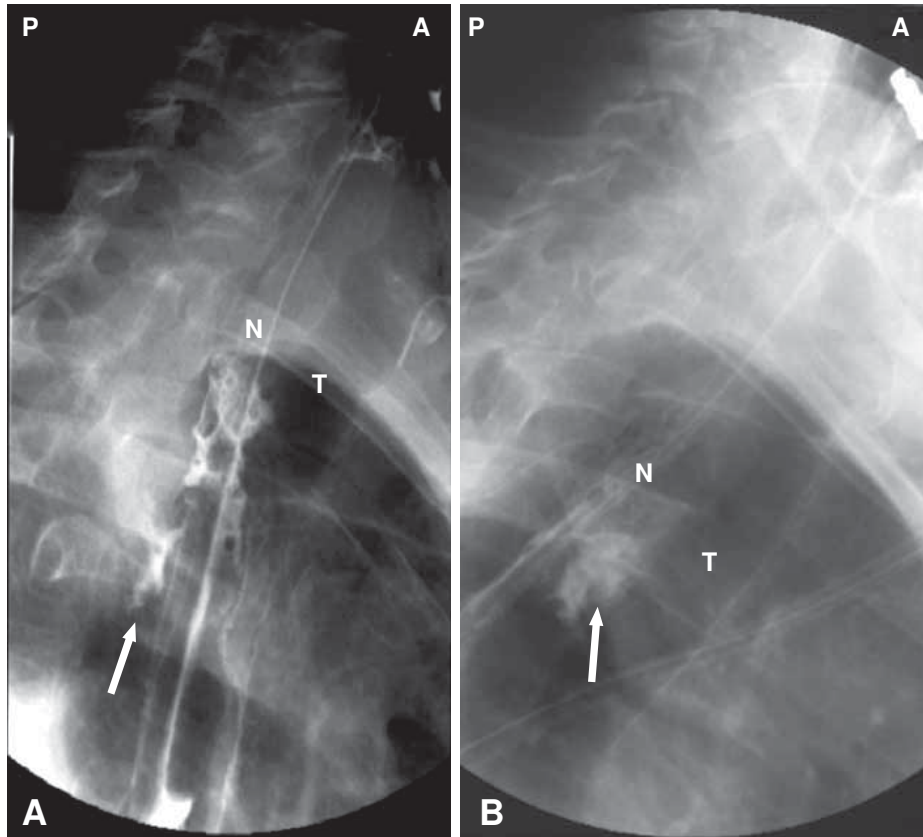
Of 207 routine swallow examinations, 26 (12%) showed radiological leakage. In 14 of these patients, no clinical leakage occurred during the postoperative course. Of the conclusive RACSEs, 7% (14 of 189) revealed a subclinical leak or was false-positive (Figure 2).

Contrast leakage did not occur in 163 (79%) examinations. 11 patients with a negative swallow examination developed a clinical leak, thus RACSE was false-negative in 6% of the conclusive examinations. False-positive rate, false-negative rate, sensitivity, specificity, PPV and NPV are shown in Table 1.

Table 1 - False-positive rate, false-negative rate, sensitivity, specificity, positive predictive value (PPV) and negative predictive value (NPV) of the conclusive routine aqueous contrast swallow examinations in detecting anastomotic leakage. All data are expressed as percentages.

False-positive rate	8
False-negative rate	48
Specificity	92
Sensitivity	52
PPV	46
NPV	93

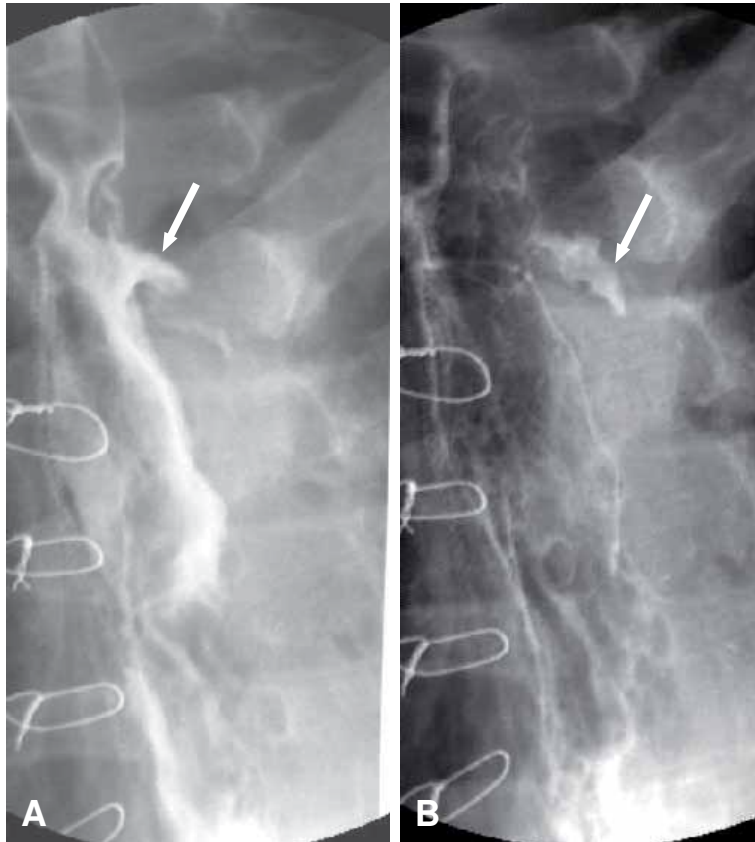
Figure 2 - False-positive RACSE. Right anterior oblique view showing suggestion of contrast leakage (arrow) on the early view (A), with subsequent extraluminal accumulation of contrast (arrow) (B) at the level of the anastomosis anterior to the nasogastric tube (N) and posterior to the trachea (T). The patient developed no clinical signs of anastomotic leakage during the postoperative course. A: anterior; P: posterior.



13

Of the 26 patients with radiological anastomotic leakage, 12 patients developed clinical signs of leakage on the 10th (2-22) postoperative day (Figure 3). In 3 (25%) of these patients, clinical leakage had already occurred before the RACSE was performed. Twelve patients with radiological leakage seen on RACSE, but without clinical leakage before or 7 days after this examination, received a second examination after 7 days (2-17) to evaluate if radiological leakage was still present. In 7 patients a radiological leakage was seen again on second swallow examination, of which 2 patients developed a clinical leak after the 2nd swallow examination. Of 4 patients with a negative 2nd swallow examination, a clinical leakage occurred afterwards in 2 patients. One contrast examination was inconclusive, but no clinical leakage arose in this patient.

Figure 3 - True-positive RACSE. Anteriorposterior views during the early (A) and late (B) phases of the RACSE. Leakage of aqueous contrast (arrow) at the cervical anastomosis. The patient developed a clinical anastomotic leakage 5 days after the RACSE was performed.



13

Table 2 - False-positive rate, false-negative rate, sensitivity, specificity, positive predictive value (PPV) and negative predictive value (NPV) of routine contrast swallow examination in detecting anastomotic leakage: comparison between end-to-end and end-to-side anastomoses.

*All data are expressed as percentages.

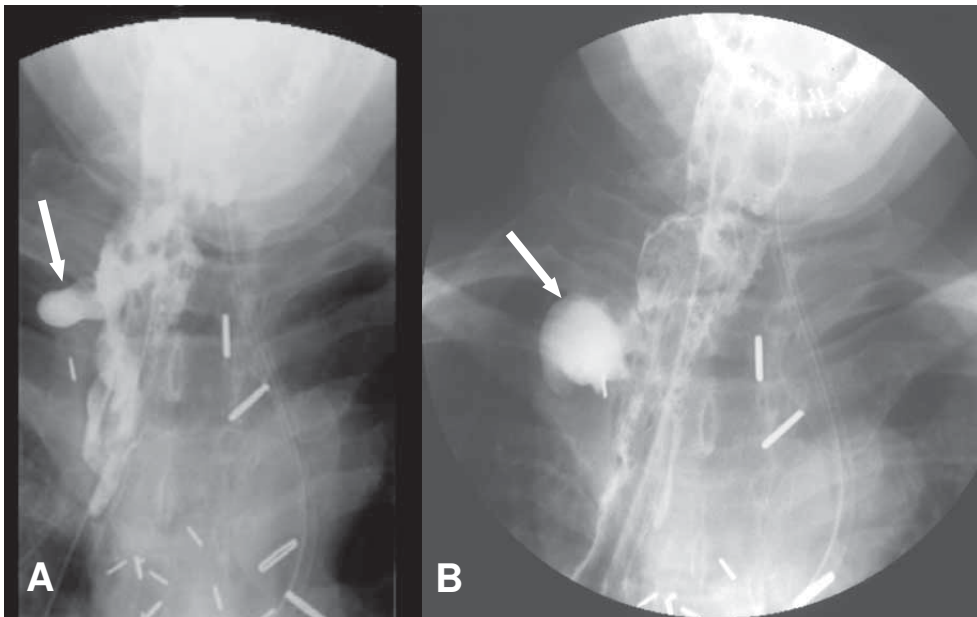
	End-to-end (n = 90) *	End-to-side (n = 111) *	P
False-positive rate	12	6	0.2
False-negative rate	27	67	0.1
Specificity	88	94	0.2
Sensitivity	73	33	0.1
PPV	50	44	1.0
NPV	95	92	0.5
Clinical leak rate	12	12	1.0

Type of anastomosis

Of the 207 patients that have undergone a RACSE, 90 patients (44%) had received an end-to-end anastomosis and 111 patients an end-to-side. In 6 patients, the type of anastomosis was unknown. Clinical leak rate was 12% in both groups ($P= 1.0$).

Table 2 shows the false-positive rate, the false-negative rate, sensitivity, specificity, PPV and NPV of the conclusive RACSEs in predicting clinical leakage in patients with an end-to-end or end-to-side anastomosis. No significant differences were found between the two groups. In Figure 4, an example of a false-negative RACSE is shown. This examination was interpreted as filling of the blind loop of the end-to-side cervical anastomosis, in a patient who developed a clinical leakage afterwards.

Figure 4 - False-negative RACSE; end-to-side anastomosis. Routine swallow examination showing delineated accumulation of aqueous contrast (arrows) in the early (A) and late (B) phases, interpreted as filling of the blind loop of the end-to-side anastomosis. No leakage was observed. The patient developed a clinical leak 5 days after the RACSE was performed. N: nasogastric tube.

**Clinical leakage**

Clinical leakage occurred in 36 (14%) patients at a median of 9 days after surgery (range 2-22). A salivary fistula had appeared in 23 patients, in 8 patients dehiscence of

the anastomosis was seen at reexploration, and in 5 patients anastomotic leakage was assessed by another diagnostic modality (gastroscopy or CT-scan) since an extensive leakage was suspected clinically in an intubated patient.

A RACSE had been performed in 24 of 36 patients who developed a clinical leak during their postoperative course. In 12 out of 24 (50%), the RACSE confirmed or detected clinical leakage. Although in 7 of 24 (29%) patients, clinical leakage had already presented before the contrast examination was executed, the contrast swallow examination was not cancelled.

In 12 of 36 patients with a clinical leak, a RACSE was not executed, since a clinical leak had presented before the 7th postoperative day (n=10) or because anastomotic leakage had been detected by an other diagnostic modality (n=2). Thus overall, in 19 (53%) of 36 patients, clinical leakage had already occurred before the RACSE was planned.

Anastomotic leakage was treated conservatively in 24 patients. Surgical intervention was required in the remaining 12 patients, and consisted of anastomotic takedown (n=8) or reexploration with drainage (n=4). Of all 36 patients with a clinical leak, 4 died due to the consequences of anastomotic leakage.

DISCUSSION

Leakage of the cervical oesophagogastric anastomosis has many presentations, ranging from a subclinical radiological leak to severe mediastinitis.³ To minimize morbidity, early detection and treatment of these leaks is essential. In many hospitals throughout the world, a contrast swallow examination is therefore routinely performed to detect subclinical anastomotic leakage. However, the results of the current study show that this routine examination has a low sensitivity and a low positive predictive value.

The cervical anastomosis between the gastric conduit and the remnant oesophagus can be done handsewn or with a mechanical stapling device. A randomized controlled trial has shown the incidence of anastomotic leakage in both methods to be comparable, with a shorter operating time in case of a stapled cervical anastomosis.⁹ The handsewn anastomosis can be created by an end-to-end or end-to-side technique, depending on the surgeon's preference. Consistent with previous results published by our institute, no

- _____ 1
- _____ 2
- _____ 3
- _____ 4
- _____ 5
- _____ 6
- _____ 7
- _____ 8
- _____ 9
- _____ 10
- _____ 11
- _____ 12
- _____ 13
- _____ 14
- _____ 15
- _____ 16
- _____ 17
- _____ 18
- _____ 19
- _____ 20
- _____ 21
- _____ 22
- _____ 23
- _____ 24
- _____ 25
- _____ 26
- _____ 27
- _____ 28
- _____ 29
- _____ 30
- _____ 31
- _____ 32

1 significant difference in the occurrence of clinical anastomotic leakage between both
2 handsewn techniques was shown in the current study.¹⁰ In general, incidence rates of
3 cervical leakage reported in the literature vary widely, from 0.8 to 30%.

4 To assess the integrity of the cervical oesophago-gastric anastomosis, a contrast swallow
5 examination is routinely carried out around the 7th postoperative day. The contrast media
6 of choice are water-soluble contrast agents, since they have no known harmful effects
7 on the neck or mediastinum and they are rapidly absorbed from these spaces if a leak
8 is present.¹¹ Conversely, barium can elicit an intense inflammatory response and can
9 cause granulomata formation in the mediastinum.^{11,12} The disadvantage of aqueous
10 contrast is, that it has less radiographic density than barium and has less mucosal
11 adherence, thus limiting the ability to detect leaks, particularly in case of subtle ones.¹²⁻
12 ¹⁴ Moreover, aspiration of aqueous contrast might lead to pulmonary oedema due to its
13 hypertonicity, even causing death.^{7,15} Although in our study more than 20% of patients
14 aspirated water-soluble contrast to some extent, none of the patients developed serious
15 pulmonary complications afterwards, as the aqueous contrast agent Ultravist has a low
16 osmotic pressure. In our experience, the detection of aspiration is not the primary goal
17 of performing a RACSE. Detected aspiration is transient in most cases.

18 Since contrast aspiration during the swallow examination frequently occurs, with possible
19 injurious consequences, and given the high incidence of false-positive and false-negative
20 results, the value of this routine practise following oesophagectomy has recently been
21 criticized.^{16,17} However, the studies on this subject have focused on barium contrast¹⁸⁻
22 ²⁰, intrathoracic anastomoses²¹, different types of resection^{18,20}, or pooled results of
23 patients with various types of (routes of) reconstruction.^{5,6,19} In addition, patients who
24 did not undergo this routine examination or patients with an inconclusive routine
25 swallow examination were excluded.⁵ We have therefore performed this retrospective
26 study to assess in a contiguous homogenous study population (patients with a gastric
27 conduit placed in the posterior mediastinum and a handsewn cervical oesophago-gastric
28 anastomosis) the clinical value and diagnostic accuracy of this routine examination
29 performed with aqueous contrast.

30 Of our study patients, 18% did not undergo a RACSE. Main cause was an extended stay
31 at the intensive care unit (ICU), which is regularly seen after oesophageal resection. Of
32 141 patients who were randomly assigned to undergo transthoracic oesophagectomy,

52 patients stayed 6 days or longer at the ICU, 14 (10%) of whom more than 2 weeks.²² As clinical apparent cervical leaks generally manifest between 2-10 days³, performing a swallow examination in these latter patients is ineffective, as clinical leakage will present before RACSE is performed in most cases.

In 18 (9%) patients, the performed RACSE was unsatisfactory, mainly due to an inadequate amount of contrast in the gastric conduit due to aspiration of contrast. Only 28% of these patients received a second swallow examination to reveal subclinical anastomotic leakage. So in more than 70%, the surgeon accepted that no reliable conclusions with regard to the integrity of the cervical anastomosis could be drawn by the radiologist, and diet was gradually resumed based on clinical findings. None of these patients developed a clinical leak during the postoperative course.

Comparable to the results of Tirnaksiz et al.⁵, RACSE performed in our study was associated with a very high false-negative rate (48%) and consequently a low sensitivity. First, this could be due to the timing of the RACSE. Although a water-soluble contrast examination is routinely performed on postoperative day 7, it is in some cases performed earlier, e.g. when patient recovery is fast. Hence, a clinical leakage that will manifest at the 10th postoperative day may be missed by the RACSE. Secondly, since the radiographic density and the mucosal coating ability of water-soluble contrast agents are less than barium, small leaks may be missed.^{13,14}

In 14 patients, although RACSE had shown extravasation of contrast, no clinical leakage occurred during their postoperative course. As a result, positive predictive value of RACSE was less than 50%. A possible explanation could be that in these patients the size of the leak may be too small to become clinically apparent. Secondly, conservative treatment after detection of a radiological leak could have resulted in healing of the anastomotic leak. In addition, the contrast examination could have been truly false-positive.

Focusing on the 36 patients with a clinical leak, signs of leakage had already occurred before the RACSE was planned in 53% of patients. Nevertheless, a routine swallow examination was performed in 24 patients. Only 50% of the executed contrast examinations detected the clinical leakage. So in no more than 12 of 36 patients, contrast swallow examination detected or confirmed the clinical leak.

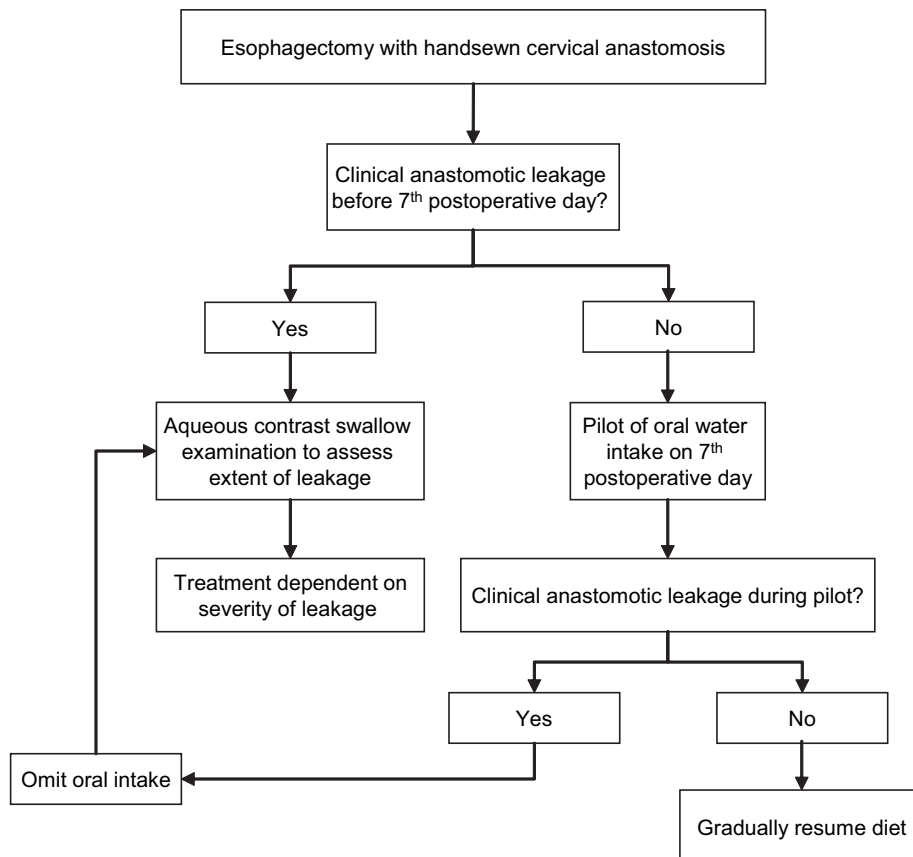
To assess if filling of the blind loop of the end-to-side anastomosis with contrast during radiological swallow examination might hinder detecting leakage, a subanalysis was

_____	1
_____	2
_____	3
_____	4
_____	5
_____	6
_____	7
_____	8
_____	9
_____	10
_____	11
_____	12
_____	13
_____	14
_____	15
_____	16
_____	17
_____	18
_____	19
_____	20
_____	21
_____	22
13 _____	23
_____	24
_____	25
_____	26
_____	27
_____	28
_____	29
_____	30
_____	31
_____	32

performed. No significant differences were detected in diagnostic accuracy compared to the end-to-end anastomosis.

Because of its low sensitivity and low positive predictive value, the routine use of water-soluble contrast swallow examination following oesophagectomy with a cervical anastomosis is not justified. As an alternative, we propose to allow patients who have no signs of a clinical leakage, small amounts of water from the 7th postoperative day to test the cervical anastomosis (Figure 5).^{6,16} When no leakage of the cervical wound is noticed, diet can gradually be resumed. When an anastomotic leak is suspected clinically, an aqueous contrast swallow examination can be justified to evaluate the extent of the leakage.

Figure 5 - Proposed algorithm for assessing the integrity of the cervical oesophagogastric anastomosis following oesophagectomy.



Since June 2006, this is the current postoperative practise in our hospital. In 18 consecutive patients that have undergone oesophagectomy, an aqueous contrast swallow examination was only performed on indication. In 16 of 18 patients, no clinical signs of anastomotic leakage were present on the 7th postoperative day, so patients were allowed to drink small amounts of water. None of the patients showed leakage of the cervical wound during the test hence diet was gradually resumed. None of the patients developed a clinical anastomotic leakage afterwards. In the two other patients, a clinical anastomotic leakage occurred before the anastomosis was tested.

As our study population only consists of patients with a cervical anastomosis, we would like to stress that our recommendation of abandoning the RACSE and introducing the described clinical test is only applicable in case of a cervical anastomosis; we have no experience with this test in intrathoracic anastomoses. Nevertheless, several studies have described that the RACSE is also of limited value in these anastomoses.^{5,16}

In conclusion, in this retrospective study the routine contrast swallow examination has shown very disappointing diagnostic accuracy. Moreover, in more than 50% of patients with a clinical leak, leakage occurred before the RACSE was planned. We therefore propose to abandon routine water-soluble contrast swallow examination after oesophagectomy to detect leakage of the cervical oesophagogastric anastomosis. Alternatively, the integrity of the cervical oesophagogastric anastomosis can be tested by drinking small amounts of water with simultaneous observation of the cervical wound. An aqueous contrast swallow examination is only justified when an anastomotic leak is suspected on clinical grounds, to visualize the extent of leakage.

— 1
— 2
— 3
— 4
— 5
— 6
— 7
— 8
— 9
— 10
— 11
— 12
— 13
— 14
— 15
— 16
— 17
— 18
— 19
— 20
— 21
— 22
— 23
— 24
— 25
— 26
— 27
— 28
— 29
— 30
— 31
— 32

REFERENCES

1. Hulscher JB, van Sandick JW, de Boer AG et al. Extended transthoracic resection compared with limited transhiatal resection for adenocarcinoma of the esophagus. *N Engl J Med* 2002; 347:1662-1669.
2. Alanezi K and Urschel JD. Mortality secondary to esophageal anastomotic leak. *Ann Thorac Cardiovasc Surg* 2004; 10:71-75.
3. Urschel JD. Esophagogastrostomy anastomotic leaks complicating esophagectomy: a review. *Am J Surg* 1995; 169:634-640.
4. Korst RJ, Port JL, Lee PC, Altorki NK. Intrathoracic manifestations of cervical anastomotic leaks after transthoracic esophagectomy for carcinoma. *Ann Thorac Surg* 2005; 80:1185-1190.
5. Tirnaksiz MB, Deschamps C, Allen MS, Johnson DC, Pairolero PC. Effectiveness of screening aqueous contrast swallow in detecting clinically significant anastomotic leaks after esophagectomy. *Eur Surg Res* 2005; 37:123-128.
6. Goel AK, Sinha S, Chattopadhyay TK. Role of gastrografin study in the assessment of anastomotic leaks from cervical oesophagogastric anastomosis. *ANZ J Surg* 1995; 65:8-10.
7. Fan ST, Lau WY, Yip WC, Poon GP, Yeung C, Wong KK. Limitations and dangers of gastrografin swallow after esophageal and upper gastric operations. *Am J Surg* 1988; 155:495-497.
8. Armitage P, Berry G, Matthews J.N.S. *Statistical methods in medical research*. 4th edn. Oxford: Blackwell Science, 2002.
9. Hsu HH, Chen JS, Huang PM, Lee JM, Lee YC. Comparison of manual and mechanical cervical esophagogastric anastomosis after esophageal resection for squamous cell carcinoma: a prospective randomized controlled trial. *Eur J Cardiothorac Surg* 2004; 25:1097-1101.
10. Pierie JP, de Graaf PW, Poen H, Van DT, I, Obertop H. End-to-side and end-to-end anastomoses give similar results in cervical oesophagogastronomy. *Eur J Surg* 1995; 161:893-896.
11. Ginai AZ, ten Kate FJ, ten Berg GM, Hoornstra K. Experimental evaluation of various available contrast agents for use in the upper gastrointestinal tract in case of suspected leakage: effects on mediastinum. *Br J Radiol* 1985; 58:585-592.
12. James AE, Montali RJ, Chaffee V, Strecker EP, Vessal K. Barium or gastrografin: which contrast media for diagnosis of esophageal tears? *Gastroenterology* 1975; 68:1103-1113.
13. Foley MJ, Ghahremani GG, Rogers LF. Reappraisal of contrast media used to detect upper gastrointestinal perforations: comparison of ionic water-soluble media with barium sulfate. *Radiology* 1982; 144:231-237.
14. Buecker A, Wein BB, Neuerburg JM, Guenther RW. Esophageal perforation: comparison of use of aqueous and barium-containing contrast media. *Radiology* 1997; 202:683-686.

15.	Trulzsch DV, Penmetsa A, Karim A, Evans DA. Gastrografin-induced aspiration pneumonia: a lethal complication of computed tomography. <i>South Med J</i> 1992; 85:1255-1256.	1
16.	Griffin SM, Lamb PJ, Dresner SM, Richardson DL, Hayes N. Diagnosis and management of a mediastinal leak following radical oesophagectomy. <i>Br J Surg</i> 2001; 88:1346-1351.	2
17.	Page RD, Shackcloth MJ, Russell GN, Pennefather SH. Surgical treatment of anastomotic leaks after oesophagectomy. <i>Eur J Cardiothorac Surg</i> 2005; 27:337-343.	3
18.	Agha FP, Orringer MB, Amendola MA. Gastric interposition following transhiatal esophagectomy: radiographic evaluation. <i>Gastrointest Radiol</i> 1985; 10:17-24.	4
19.	Gollub MJ and Bains MS. Barium sulfate: a new (old) contrast agent for diagnosis of postoperative esophageal leaks. <i>Radiology</i> 1997; 202:360-362.	5
20.	Swanson JO, Levine MS, Redfern RO, Rubesin SE. Usefulness of high-density barium for detection of leaks after esophagogastrectomy, total gastrectomy, and total laryngectomy. <i>AJR Am J Roentgenol</i> 2003; 181:415-420.	6
21.	Owen JW, Balfe DM, Koehler RE, Roper CL, Weyman PJ. Radiologic evaluation of complications after esophagogastrectomy. <i>AJR Am J Roentgenol</i> 1983; 140:1163-1169.	7
22.	Cense HA, Hulscher JB, de Boer AG et al. Effects of prolonged intensive care unit stay on quality of life and long-term survival after transthoracic esophageal resection. <i>Crit Care Med</i> 2006; 34:354-362.	8
		9
		10
		11
		12
		13
		14
		15
		16
		17
		18
		19
		20
		21
		22
		23
		24
		25
		26
		27
		28
		29
		30
		31
		32

14

Summary

Chapter I gives a short introduction on esophageal cancer, its current treatment and its related diagnostic imaging modalities. It describes the aim of this thesis, which was to investigate various strategies in the field of surgery (**Part I**), molecular biology (**Part II**) and diagnostic imaging (**Part III**) through which the outcome of esophagectomy for esophageal cancer could possibly be improved. In addition, central questions were formulated to guide the studies described in this thesis.

PART I: SURGICAL STRATEGIES

For patients with locoregional esophageal cancer, radical surgical resection offers the best chance for cure. Nevertheless, no standard surgical treatment exists with regard to the approach to esophagectomy, the extent of lymphadenectomy or the anastomotic technique. In order to gain insight into the current worldwide practice of esophageal cancer surgery, we have initiated an international survey among 567 surgeons with particular interest in esophageal cancer surgery, including members of the ISDE, the ESE and the OESO. The results of this survey showed that surgical techniques vary widely and depend on the surgeon's experience in esophageal cancer surgery and the surgeon's nationality (**Chapter 2**). Open TTE with a 2-field LND and a gastric conduit anastomosed at the left side of the neck is presently the most commonly applied surgical technique. This survey has provided baseline data for further studies on these subjects

To reduce the morbidity of open TTE, minimally invasive surgical techniques such as thoracoscopy and laparoscopy have been applied. Robotic systems have been developed to overcome the limitations of conventional scopic surgery. Our first experience with robot-assisted thoracoscopic esophagectomy (RTE) in 21 esophageal cancer patients has been described in **Chapter 3**. This innovative surgical technique has shown to be technically feasible and was associated with low blood loss. The robotic system facilitated a precise dissection along the vital mediastinal structures such as the pulmonary vein, the trachea and the aorta. A steep decrease in pulmonary complication rate was noticed, which represented the learning curve of both the surgical and anaesthesiological team.

The gastric conduit is the most commonly used reconstruction for the digestive tract following esophagectomy. It is made by means of several linear staplers (Figure 3; p12). The linear stapled line is routinely oversewn to prevent leakage at this stapled line and to avoid damage to the mediastinal structures by possible protruding staples. Some surgeons performing minimally invasive esophagectomy (MIE) create the gastric conduit laparoscopically as well, in order to accomplish an entirely scopic surgical procedure. Because oversewing the stapled line by means of scopic instruments is technically difficult and time-consuming, this routine step is often abandoned. In our first 15 RTE patients, we did not oversee the stapled line. This resulted in fulminant leakage at the linear stapled line in 2 (13%) patients (**Chapter 4**). Since then, we have reintroduced this routine practise and no local complications have been encountered afterwards. It should therefore be recommended to always oversee the gastric conduit linear stapled line, irrespective of the surgical approach.

During open TTE, the esophagus is resected en bloc with the surrounding mediastinal lymph nodes and structures such as the azygos vein, the parietal pleura and the thoracic duct. In (robot-assisted) thoracoscopic esophagectomy, the azygos vein is preserved as the scopic ligation of the numerous intercostal veins is time-consuming and technically difficult. One may postulate that this could negatively affect the extent of mediastinal lymph node harvesting. A cadaveric study was therefore initiated to determine which percentage of mediastinal lymph nodes would be left in situ when the trunk of the azygos vein would be preserved (**Chapter 5**). A mean amount of 0.67 lymph nodes were identified surrounding the azygos trunk. The mean percentage of residual lymph nodes was 3.3%. Additionally, in 60% of cadavers no lymph nodes could be detected at all near the azygos trunk. We therefore consider it justified to leave the azygos vein in situ during (robot-assisted minimally invasive) transthoracic esophagectomy.

The short-and mid-term results of the world's largest patient series on RTE have shown a substantial lower blood loss when compared to open TTE (**Chapter 6**). Moreover, blood loss and operation time significantly decreased when comparing the last 24 patients with the first 23, which represents the learning curve of the surgical team. The overall morbidity was in the range of open TTE, but a steep reduction in pulmonary

1 — complication rate was observed. The pulmonary complication rate (33%) in the last 24
2 — patients was comparable to results reported in open THE. With increasing experience, it is
3 — to be expected that surgery time, blood loss and complication rate will further decrease.
4 — The median number of dissected lymph nodes was equal to open TTE, but more than
5 — the conventional thoracoscopic approach. Of great clinical importance is the finding
6 — that in almost one third of patients with a distal esophageal tumor having undergone
7 — RTE, lymph node metastases were found in the upper mediastinum. These patients
8 — benefited from the extensive mediastinal LND as provided by RTE, as in other hospitals
9 — they would have undergone a transhiatal approach without a proper mediastinal LND.
10 — The disease-free survival after RTE was comparable to open TTE as well, having in mind
11 — that the majority of our patients had advanced stage disease.

12 —
13 — Although squamous cell carcinoma and adenocarcinoma arise from dysplastic and
14 — metaplastic esophageal epithelium, respectively, malignancies can also originate from
15 — the mesenchymal layer of the esophagus (e.g. gastrointestinal stromal tumors and
16 — leiomyosarcomas). In **Chapter 7** we report the first case worldwide of robot-assisted
17 — thoracoscopic esophagectomy for a giant submucosal tumor of the upper esophagus in
18 — a young patient in whom a mesenchymal malignancy was highly suspected. Although
19 — histopathologic analysis of the resected specimen revealed the mesenchymal tumor
20 — to be benign, therapy would have been similar, as the enucleation of a large (>8 cm)
21 — esophageal leiomyoma would create muscular defects too large to achieve tension-free
22 — sutures.

PART II: MOLECULAR BIOLOGICAL STRATEGIES

23 —
24 —
25 —
26 —
27 — By selectively destructing tumor cells, neoadjuvant molecular therapy may possibly
28 — lead to increased efficiency and specificity with a reduction in toxicity when compared
29 — to conventional chemotherapy. The question is which particular molecular markers
30 — need targeting. The aim of this part of the thesis was to identify potential markers for
31 — targeted therapy in esophageal squamous cell carcinoma (ESCC), the histologic type
32 — that constitutes the majority of esophageal cancer cases globally.

The immunohistochemical analysis of molecular markers in tissues is facilitated by the tissue microarray (TMA) technology. Since the small (diameter 0.6mm) tissue biopsy cores on a TMA may not be representative for the donor paraffin block, we have validated our TMA consisting of triplicate core biopsies of 108 ESCCs for well-known molecular markers (**Chapter 8**). The chance-corrected agreement between the TMA cores and the corresponding full-sections ranged from moderate to almost perfect, provided that the staining pattern in the tumor is heterogeneous.

After the TMA was validated, it was used to identify possible targets for molecular therapy in ESCC. Several therapeutic agents are nowadays commercially available that act at specific tumor markers such as Bcl-2, cyclo-oxygenase-2 (COX-2), cyclin D1, c-KIT, epidermal growth factor receptor (EGFR), estrogen receptor (ER), Her-2/neu, progesterone receptor (PR) and vascular endothelial growth factor (VEGF). The immunohistochemical study described in **Chapter 9** has shown that potential targets for molecular therapy in ESCC appear COX-2, EGFR, VEGF and cyclin D1, since they were frequently overexpressed in our TMA. Phase II clinical studies on these molecular markers may therefore be warranted. The role for targeted therapy against ER, PR, Her-2/neu or Bcl-2 in ESCC seems limited.

Another promising target for molecular therapy is the mammalian Target of Rapamycin (mTOR), a protein kinase that regulates protein translation and cell proliferation. This marker is activated in various malignancies, which is of clinical interest as mTOR-inhibitors are commercially available. A recent randomized controlled trial in advanced renal cell cancer patients has revealed that the mTOR-inhibitor temsirolimus significantly improved their survival. In esophageal carcinoma only an in vitro study has been performed with ESCC cell lines, which has shown that mTOR was activated and that the expression of mTOR was reduced by mTOR-inhibitors. Based on these results, we have initiated an immunohistochemical study on our TMA to assess the percentage of ESCCs that express activated mTOR, in that way determining the proportion of ESCC patients that might benefit from mTOR-inhibiting therapy (**Chapter 10**). In addition, the histopathological characteristics of potential rapamycin-sensitive ESCCs were determined. The expression of activated mTOR was detected in 25% of ESCCs and was associated with a poorer degree of differentiation. Since this subset of ESCCs could benefit from mTOR-inhibiting therapy,

1
2
3
4
5
6
7
8
9
10
11
12
13
14
15
16
17
18
19
20
21
22
23
24
25
26
27
28
29
30
31
32

1 _____ a phase II trial in the neoadjuvant setting may be considered. Yet, more research on the
2 _____ Akt-mTOR-p70s6-kinase pathway should be carried out to gain more knowledge on the
3 _____ interactions in this pathway.
4 _____
5 _____

6 _____ **PART III: DIAGNOSTIC IMAGING STRATEGIES**

7 _____
8 _____ Adequate preoperative staging is important for the outcome of esophagectomy as it
9 _____ allows for the selection of patients with resectable disease that will benefit from surgery
10 _____ and for the identification of patients with metastatic disease that require palliative
11 _____ therapy. Neoadjuvant treatment could improve the survival after esophagectomy by
12 _____ downstaging of the tumor and by early opposing metastatic spread. Since it was unclear
13 _____ at what frequency the various diagnostic modalities were being applied in esophageal
14 _____ cancer and since it was indefinite if and how neoadjuvant therapy was incorporated in
15 _____ the treatment of esophageal cancer patients, the international survey (partly described
16 _____ in Chapter 2) addressed questions regarding these topics as well. Substantial differences
17 _____ were detected in the application of diagnostic modalities and neoadjuvant therapy
18 _____ between surgeons from different continents (**Chapter 11**). The most commonly applied
19 _____ diagnostic modalities in esophageal cancer are gastroscopy with biopsy and CT scan
20 _____ of the chest and abdomen. Neoadjuvant therapy is routinely given by one third of the
21 _____ responders. Of these responders, 61% give identical neoadjuvant regimens to SCC and
22 _____ AC. In case of identical regimens, chemoradiotherapy is the preferred regimen. In case
23 _____ different regimens are given to SCC and AC, chemoradiotherapy is favoured for the
24 _____ former whereas chemotherapy alone is preferred for the latter.
25 _____

14

26 _____ The morbidity of esophagectomy could be reduced by tailoring the extent of LND in
27 _____ clinically node-negative patients. This might be achieved by introducing the sentinel
28 _____ node (SN) concept in esophageal cancer surgery. The results of our feasibility study have
29 _____ revealed a false-negative rate of 100% (**Chapter 12**). Therefore, SN biopsy was not of
30 _____ value in our study group. Yet, based on the results reported from Japanese institutes,
31 _____ this technique may be promising for superficial (i.e. cT1-2) tumors.
32 _____

In many hospitals worldwide, a water-soluble contrast swallow examination is routinely performed around the 7th postoperative day to assess the integrity of the cervical esophagogastric anastomosis before oral intake is resumed. The retrospective study described in **Chapter 13** has revealed that the routine contrast swallow examination (RACSE) has a low sensitivity and low positive predictive value. Moreover, in more than half of patients with a clinical anastomotic leak, the leakage had already appeared clinically before the RACSE was carried out. Based on these results we recommended abandoning RACSE in patients with a cervical anastomosis. The integrity of the cervical anastomosis can easily be tested by drinking small amounts of water from the 7th postoperative day with simultaneous observation of the cervical wound. In case no signs of clinical leakage occur, diet can gradually be resumed. However, when a leakage is suspected an aqueous contrast swallow examination should be performed to assess the extent of leakage.

- 1
- 2
- 3
- 4
- 5
- 6
- 7
- 8
- 9
- 10
- 11
- 12
- 13
- 14
- 15
- 16
- 17
- 18
- 19
- 20
- 21
- 22
- 23
- 14** — 24
- 25
- 26
- 27
- 28
- 29
- 30
- 31
- 32

15

General discussion and conclusions

The results of the studies described in this thesis are discussed in this chapter, guided by the central questions that were formulated in the General Introduction (Chapter 1).

• ***What is the current worldwide practice in surgical techniques, preoperative staging and neoadjuvant therapy as applied in esophageal cancer?***

The results of our international survey have shown that the most commonly applied surgical techniques are open transthoracic esophagectomy (TTE) with a 2-field lymph node dissection (LND) and a gastric conduit anastomosed at the left side of the neck. Esophagogastroscope with biopsy and computed tomography scanning of chest and abdomen are the most frequently performed preoperative diagnostic modalities. Neoadjuvant therapy is routinely administered by one third of responders.

With a response rate of 47%, predominantly members of prominent esophageal societies, the results of our survey give a representative overview on the current worldwide practise in the management of esophageal cancer. Moreover, this survey has provided baseline data for further studies and guidelines on these subjects. As a wide variety in preoperative work-up and surgical techniques was detected among surgeons worldwide, it should be encouraged to formulate an evidence-based international guideline for the management of esophageal cancer patients. In addition, it would be worthwhile to repeat this international survey within several years to detect changes over time.

Although the results of our international survey have revealed that only one third of surgeons routinely administer neoadjuvant therapy in esophageal cancer patients, it is to be expected that in the near future it will be incorporated in the routine treatment regimen. After all, several convincing studies, including a recent meta-analysis of randomized controlled trials, favoring pre-operative therapy are currently available.¹⁻³

It is generally accepted that esophageal squamous cell carcinoma (SCC) and adenocarcinoma (AC) are different disease entities with distinct pathogenesis, tumor biology and prognosis.^{4,5} Yet, more than 60% of responders administer identical neoadjuvant regimens to both histologic types. Further research should likely determine which neoadjuvant regimens are best for SCC and AC separately, so that they can be treated most efficiently.

• Could the application of minimally invasive robotic systems reduce the morbidity of transthoracic esophagectomy without compromising oncologic outcome?

After the optimal position of the trocars and the robotic system was determined and extensively tested in our laboratory on living pigs and human cadavers, we introduced robot-assisted thoracoscopic esophagectomy (RTE) into clinical practise on October 17, 2003. This thesis describes both the feasibility of RTE and the results of the first 47 patients having undergone RTE, which is the largest study on RTE published so far.

RTE was accompanied by significantly lower blood loss (median 625 mL) than open TTE (mean 1900 mL).⁶ Moreover, a statistically significant decrease in blood loss was detected with increasing experience. This is of particular clinical interest as several studies have shown that esophageal cancer patients with major blood loss receiving allogenic blood transfusions have a significant worse prognosis than patients without transfusions.⁷⁻¹¹

The operation time of RTE is currently longer than open TTE, even in our last 24 operated patients.⁶ First, this is due to the ongoing learning curve of the surgeon. Second, it is a consequence of the fact that we had to deal with a changing team of surgical assistants with variable experience in minimally invasive (robotic) surgery. With increasing experience and consistency of the surgical team including the employment of a physician assistant specialised in robotic surgery, operation time may be expected to decrease further.

At present, the morbidity of RTE is comparable to that of open TTE. A steep decrease in pulmonary complication rate was noticed when comparing the last 24 operated patients with the first 23. With 33%, the pulmonary complication rate of the last 24 patients was comparable to the open transhiatal approach.⁶ An additional reduction in pulmonary complications may be anticipated with increasing experience and consistency of both the surgical and anaesthesiological team. Still, during RTE, similar to open TTE but in contrast to open THE, the right lung is deflated for 2-3 hours to achieve optimal exposure of the mediastinal structures. Deflation with subsequent reinflation of the lung is accompanied by the release of various cytokines and chemokines.^{12,13} As these inflammatory mediators may cause pulmonary complications,^{12,13} effort should be undertaken to antagonize their production. This may be achieved by anaesthesiological

1
2
3
4
5
6
7
8
9
10
11
12
13
14
15
16
17
18
19
20
21
22
23
24
25
26
27
28
29
30
31
32

1 strategies (e.g. protective ventilation strategies for the deflated or the dependent lung¹⁴,
2 or systemic administration of anti-inflammatory or immunosuppressive drugs^{15,16}) and
3 surgical strategies (e.g. less manipulation of the deflated lung with surgical instruments
4 or optimal patient positioning so that gravity can aid in retracting the deflated lung).

5 When esophagectomy is performed it should be strongly recommended to oversee the
6 gastric conduit stapled lines even when the conduit is created intracorporeally during
7 minimally invasive esophagectomy, in order to avoid severe local complications at the
8 stapled lines, such as tracheo-neo-esophageal fistula.

9 The 3-dimensional, tenfold magnified view of the surgical field provides for an extensive
10 en bloc dissection of the esophagus and the surrounding mediastinal lymph nodes.
11 With a median number of 29 dissected lymph nodes, the extent of lymphadenectomy
12 of RTE is similar to that of open TTE.⁶ The LND of RTE includes the superior mediastinal
13 lymph nodes as well. For 29% of patients with a distal esophageal or gastroesophageal
14 junction tumor, this was of particular interest as microscopic analysis showed the
15 presence of metastatic tumor cells in those superior mediastinal lymph nodes. When
16 surgically treated by a transhiatal esophagectomy, these tumor deposits would not have
17 been resected.¹⁷

18 As shown by the results of our cadaveric study, azygos vein preservation did not diminish
19 the extent of mediastinal lymphadenectomy. One may postulate that preserving the
20 azygos vein may affect the circumferential radical resection (R0) rate. Yet, the results
21 of our patient series on RTE have shown that the R0 resection rate is similar to that
22 reported in open TTE.⁶ Thus, leaving the azygos vein *in situ* during (robot-assisted)
23 thoracoscopic esophagectomy neither affects the extent of mediastinal LND, nor the
24 R0 resection rate.

25 The disease-free survival of RTE is comparable to open TTE bearing in mind that a large
26 subset of patients had stage IVa disease.^{6,18} An explanation for the high amount of
27 stage IVa patients is that our medical center is a tertiary referral center for esophageal
28 cancer patients. Secondly, the magnified view on the left gastric artery as provided by
29 laparoscopy facilitates an extensive dissection of these potential metastatic lymph nodes.
30 In addition, a recognized difficulty of the current TNM classification is the discrimination
31 of regional lymph nodes (e.g. lymph nodes in the proximal part of the lesser omentum)
32 from M1a lymph nodes (i.e. lymph nodes near the origin of the left gastric artery or the
celiac trunk).

To confirm our data and to assess if long-term oncologic outcome of RTE is comparable to open TTE, more prospective studies with a longer follow-up of larger study populations are warranted. We are, therefore, pleased to see that other institutions have commenced RTE.¹⁹⁻²¹ For the ultimate comparison of RTE, open TTE and conventional thoracoscopic esophagectomy, a (multicenter) randomized controlled trial should be conducted.

• Which markers are potential targets for neoadjuvant molecular therapy in squamous cell carcinoma of the esophagus?

Of the molecular markers investigated in this thesis cyclo-oxygenase-2 (COX-2), vascular endothelial growth factor (VEGF), cyclin D1, endothelial growth factor receptor (EGFR) and mammalian target of rapamycin (mTOR), seem promising targets for molecular therapy in esophageal squamous cell carcinoma (ESCC) based on the frequency of their expression in our ESCC tissue microarray (TMA). Clinical trials with targeted therapy against these markers are therefore warranted.

As esophageal SCC and AC are different disease entities,^{4,5} it should be worthwhile to assess the immunohistochemical expression of the above-mentioned molecular markers in esophageal AC as well and to compare the results with those found in ESCC. Since several studies have described a high expression of activated (p-) mTOR in glandular malignancies,²²⁻²⁴ the expression of p-mTOR should in particular be investigated in esophageal adenocarcinoma. In addition, it would be interesting to determine the prognostic value of activated mTOR in both esophageal SCC and AC. In our series, no accurate conclusions on the prognostic value of p-mTOR could be drawn. First, because the clinical data of the ESCCs that were included in our TMA were primarily retrieved from a retrospective database that included overall survival data only (without proper assessment of cause of death) and not disease-free survival data. Second, because a large subset of these patients had an irradical resection (R1/R2). This would affect the prognosis more than would the presence or absence of p-mTOR.

In the clinical setting, the choice for a targeted therapy could be made on an individual patient's basis by immunohistochemical analysis of tumor biopsy tissue which is obtained during preoperative esophagogastrosocopy. Yet, one should keep in mind when analyzing the results of immunohistochemical analyses that the expression of a marker does not always guarantee effectiveness of the targeted therapy in that patient.²⁵ When

1
2
3
4
5
6
7
8
9
10
11
12
13
14
15
16
17
18
19
20
21
22
23
24
25
26
27
28
29
30
31
32

1 _____ a clinical trial on targeted therapy is conducted, it is, therefore, recommended to assess
2 _____ in patients both clinical and immunohistochemical effects of the therapy.

3 _____
4 _____ **• Is there a justification for sentinel node biopsy or routine post-esophagectomy
5 _____ aqueous contrast swallow examination in esophageal cancer?**

6 _____ The enormously high false-negative rate of our feasibility study has revealed the sentinel
7 _____ (SN) procedure to be of no value in our study patients. One other research group has
8 _____ published an identical high false-negative rate in esophageal cancer patients.²⁶ Our
9 _____ high false-negative rate could be due to metastatic tumor cells blocking the initial
10 _____ lymphatic drainage pattern of the esophageal tumor, causing an alternative flow of the
11 _____ radioactive tracer particles.²⁷ In the Western world, screening programs are currently
12 _____ not being applied for early detection of esophageal cancer, as they are not considered
13 _____ cost-effective. Since esophageal cancer only causes symptoms when the tumor size is
14 _____ substantial, most of the patients are diagnosed at an advanced stage, which includes
15 _____ deep esophageal wall infiltration and lymph node metastases. In contrast, in Japan,
16 _____ effective screening programs are carried out resulting in the diagnosis of early-stage
17 _____ disease.²⁸ In these superficial tumors, the lymphatic vessels located in the submucosal
18 _____ layer may not have been infiltrated by tumor cells yet, which might make SN biopsy
19 _____ feasible. Indeed, promising results have been published on this subject by certain
20 _____ Japanese research groups.²⁹⁻³¹ Therefore, there could be a role for SN biopsy in this
21 _____ subgroup of esophageal cancer patients.

22 _____
23 _____ Based on its low sensitivity and low positive predictive value and given the fact that in
24 _____ half of patients with a clinical anastomotic leak, leakage had appeared clinically before
25 _____ the routine aqueous contrast swallow examination (RACSE) was carried out, there
26 _____ seems no role for RACSE in assessing the integrity of the cervical anastomosis after
27 _____ esophagectomy with gastric conduit formation. As an alternative, patients without
28 _____ signs of a clinical leakage could be allowed to drink small amounts of water from
29 _____ the 7th postoperative day to test the cervical anastomosis. When no leakage of the
30 _____ cervical wound is noticed, diet can gradually be resumed. When an anastomotic leak
31 _____ is suspected clinically, an aqueous contrast swallow examination can be justified to
32 _____ evaluate the extent of the leakage. Although in our experience this test is very useful

and is currently part of our routine postoperative management, its diagnostic value (e.g. sensitivity and negative predictive value) should objectively be assessed.

It should be stressed that our suggestion of abandoning the RACSE and introducing the clinical test is for patients with a cervical anastomosis and a gastric conduit only. After all, the consequences of anastomotic leakage in patients with an intrathoracic anastomosis are much more severe.³² Yet, some studies have reported that RACSE has a limited value in these anastomoses as well.^{33,34} In addition, although the gastric conduit is the most frequently used reconstruction after esophagectomy,³⁵ a colonic or jejunal interposition is applied in case a gastric conduit is not feasible.³⁶ As these interpositions have both a proximal and distal anastomosis that cannot easily drain through the surgical wound in case of clinical leakage, a RASCE should always be carried out.

CONCLUSIONS

The following conclusions can be drawn from the studies described in this thesis:

- Surgical techniques, preoperative staging and neoadjuvant therapy, as currently applied in esophageal cancer patients by surgeons worldwide, depend largely on locoregional habits and the surgeon's experience in esophageal cancer surgery.
- RTE is technically feasible and is associated with low blood loss. At present, the overall morbidity is comparable to open TTE, but the substantial reduction in pulmonary complication rate over time reveals a steep learning curve of both surgical and anaesthesiological team. Blood loss, operation time and morbidity might further decrease with more experience. The extent of lymphadenectomy, radical resection rate and disease-free survival are similar to open TTE.
- The molecular markers mTOR, VEGF, cyclin D1, EGFR and COX-2 may be potential targets for molecular therapy in ESCC, based on their frequent expression in our TMA. Phase II clinical trials on compounds targeting these markers are warranted.
- Based on the high false-negative rate of our feasibility study, there seems no role for sentinel node biopsy in esophageal cancer patients. Yet, given the results reported from Japanese institutes in superficial carcinomas, there still might be a role for cT1 tumors. The routine aqueous contrast swallow examination after esophagectomy

_____	1
_____	2
_____	3
_____	4
_____	5
_____	6
_____	7
_____	8
_____	9
_____	10
_____	11
_____	12
_____	13
_____	14
_____	15
_____	16
_____	17
_____	18
_____	19
_____	20
_____	21
_____	22
_____	23
_____	24
_____	25
_____	26
_____	27
_____	28
_____	29
_____	30
_____	31
_____	32

- 1 —
- 2 —
- 3 —
- 4 —
- 5 —
- 6 —
- 7 —
- 8 —
- 9 —
- 10 —
- 11 —
- 12 —
- 13 —
- 14 —
- 15 —
- 16 —
- 17 —
- 18 —
- 19 —
- 20 —
- 21 —
- 22 —
- 23 —
- 24 —
- 25 —
- 26 —
- 27 —
- 28 —
- 29 —
- 30 —
- 31 —
- 32 —

15

with a gastric conduit formation and a cervical anastomosis should be abandoned as it has a poor sensitivity and poor positive predictive value.

REFERENCES

1.	Medical Research Council Oesophageal Cancer Working Group. Surgical resection with or without preoperative chemotherapy in oesophageal cancer: a randomised controlled trial. <i>Lancet</i> 2002; 359:1727-1733.	1
2.	Gebski V, Burmeister B, Smithers BM, Foo K, Zalcborg J, Simes J. Survival benefits from neoadjuvant chemoradiotherapy or chemotherapy in oesophageal carcinoma: a meta-analysis. <i>Lancet Oncol</i> 2007; 8:226-234.	2
3.	Walsh TN, Noonan N, Hollywood D, Kelly A, Keeling N, Hennessy TP. A comparison of multimodal therapy and surgery for esophageal adenocarcinoma. <i>N Engl J Med</i> 1996; 335:462-467.	3
4.	Siewert JR and Ott K. Are squamous and adenocarcinomas of the esophagus the same disease? <i>Semin Radiat Oncol</i> 2007; 17:38-44.	4
5.	Mariette C, Finzi L, Piessen G, Van S, I, Triboulet JP. Esophageal carcinoma: prognostic differences between squamous cell carcinoma and adenocarcinoma. <i>World J Surg</i> 2005; 29:39-45.	5
6.	Hulscher JB, van Sandick JW, de Boer AG et al. Extended transthoracic resection compared with limited transhiatal resection for adenocarcinoma of the esophagus. <i>N Engl J Med</i> 2002; 347:1662-1669.	6
7.	Tachibana M, Kinugasa S, Dhar DK et al. Prognostic factors after extended esophagectomy for squamous cell carcinoma of the thoracic esophagus. <i>J Surg Oncol</i> 1999; 72:88-93.	7
8.	Dresner SM, Lamb PJ, Shenfine J, Hayes N, Griffin SM. Prognostic significance of peri-operative blood transfusion following radical resection for oesophageal carcinoma. <i>Eur J Surg Oncol</i> 2000; 26:492-497.	8
9.	Langley SM, Alexiou C, Bailey DH, Weeden DF. The influence of perioperative blood transfusion on survival after esophageal resection for carcinoma. <i>Ann Thorac Surg</i> 2002; 73:1704-1709.	9
10.	Christein JD, Hollinger EF, Millikan KW. Prognostic factors associated with resectable carcinoma of the esophagus. <i>Am Surg</i> 2002; 68:258-262.	10
11.	Tachibana M, Kinugasa S, Dhar DK et al. Prognostic factors in node-negative squamous cell carcinoma of the thoracic esophagus. <i>Int J Surg Investig</i> 2000; 1:389-395.	11
12.	Funakoshi T, Ishibe Y, Okazaki N et al. Effect of re-expansion after short-period lung collapse on pulmonary capillary permeability and pro-inflammatory cytokine gene expression in isolated rabbit lungs. <i>Br J Anaesth</i> 2004; 92:558-563.	12
13.	Sakao Y, Kajikawa O, Martin TR et al. Association of IL-8 and MCP-1 with the development of reexpansion pulmonary edema in rabbits. <i>Ann Thorac Surg</i> 2001; 71:1825-1832.	13

14. Michelet P, D'Journo XB, Roch A et al. Protective ventilation influences systemic inflammation after esophagectomy: a randomized controlled study. *Anesthesiology* 2006; 105:911-919.
15. Sato N, Koeda K, Ikeda K et al. Randomized study of the benefits of preoperative corticosteroid administration on the postoperative morbidity and cytokine response in patients undergoing surgery for esophageal cancer. *Ann Surg* 2002; 236:184-190.
16. Nakazawa K, Narumi Y, Ishikawa S et al. Effect of prostaglandin E1 on inflammatory responses and gas exchange in patients undergoing surgery for oesophageal cancer. *Br J Anaesth* 2004; 93:199-203.
17. Orringer MB. Transhiatal esophagectomy without thoracotomy for carcinoma of the thoracic esophagus. *Ann Surg* 1984; 200:282-288.
18. D'Journo XB, Doddoli C, Michelet P et al. Transthoracic esophagectomy for adenocarcinoma of the oesophagus: standard versus extended two-field mediastinal lymphadenectomy? *Eur J Cardiothorac Surg* 2005; 27:697-704.
19. Dapri G, Himpens J, Cadiere GB. Robot-assisted thoracoscopic esophagectomy with the patient in the prone position. *J Laparoendosc Adv Surg Tech A* 2006; 16:278-285.
20. Kernstine KH, DeArmond DT, Shamoun DM, Campos JH. The first series of completely robotic esophagectomies with three-field lymphadenectomy: initial experience. *Surg Endosc* 2007; 21:2285-2292.
21. Bodner J, Wykypiel H, Wetscher G, Schmid T. First experiences with the da Vinci operating robot in thoracic surgery. *Eur J Cardiothorac Surg* 2004; 25:844-851.
22. Kremer CL, Klein RR, Mendelson J et al. Expression of mTOR signaling pathway markers in prostate cancer progression. *Prostate* 2006; 66:1203-1212.
23. Bose S, Chandran S, Mirocha JM, Bose N. The Akt pathway in human breast cancer: a tissue-array-based analysis. *Mod Pathol* 2006; 19:238-245.
24. Pantuck AJ, Seligson DB, Klatte T et al. Prognostic relevance of the mTOR pathway in renal cell carcinoma: implications for molecular patient selection for targeted therapy. *Cancer* 2007; 109:2257-2267.
25. Van Cutsem E. Challenges in the use of epidermal growth factor receptor inhibitors in colorectal cancer. *Oncologist* 2006; 11:1010-1017.
26. Kosugi S, Nakagawa S, Kanda T et al. Radio-guided sentinel node mapping in patients with superficial esophageal carcinoma: Feasibility study. *Minim Invasive Ther Allied Technol* 2007; 16:181-186.
27. Arima H, Natsugoe S, Uenosono Y et al. Area of nodal metastasis and radioisotope uptake in sentinel nodes of upper gastrointestinal cancer. *J Surg Res* 2006; 135:250-254.

28.	Pathirana A and Poston GJ. Lessons from Japan - endoscopic management of early gastric and oesophageal cancer. <i>Eur J Surg Oncol</i> 2001; 27:9-16.	1
29.	Fujii H, Kitagawa Y, Kitajima M, Kubo A. Sentinel nodes of malignancies originating in the alimentary tract. <i>Ann Nucl Med</i> 2004; 18:1-12.	2
30.	Kitagawa Y, Fujii H, Mukai M et al. The role of the sentinel lymph node in gastrointestinal cancer. <i>Surg Clin North Am</i> 2000; 80:1799-1809.	3
31.	Kitagawa Y, Ohgami M, Fujii H et al. Laparoscopic detection of sentinel lymph nodes in gastrointestinal cancer: a novel and minimally invasive approach. <i>Ann Surg Oncol</i> 2001; 8:865-895.	4
32.	Urschel JD. Esophagogastrostomy anastomotic leaks complicating esophagectomy: a review. <i>Am J Surg</i> 1995; 169:634-640.	5
33.	Griffin SM, Lamb PJ, Dresner SM, Richardson DL, Hayes N. Diagnosis and management of a mediastinal leak following radical oesophagectomy. <i>Br J Surg</i> 2001; 88:1346-1351.	6
34.	Tirnaksiz MB, Deschamps C, Allen MS, Johnson DC, Pairolero PC. Effectiveness of screening aqueous contrast swallow in detecting clinically significant anastomotic leaks after esophagectomy. <i>Eur Surg Res</i> 2005; 37:123-128.	7
35.	Urschel JD. Does the interponat affect outcome after esophagectomy for cancer? <i>Dis Esophagus</i> 2001; 14:124-130.	8
36.	Davis PA, Law S, Wong J. Colonic interposition after esophagectomy for cancer. <i>Arch Surg</i> 2003; 138:303-308.	9
		10
		11
		12
		13
		14
		15
		16
		17
		18
		19
		20
		21
		22
		23
		24
		25
		26
		27
		28
		29
		30
		31
		32

16

**Nederlandse samenvatting
voor niet-ingewijden**

ACHTERGROND

Slokdarmkanker

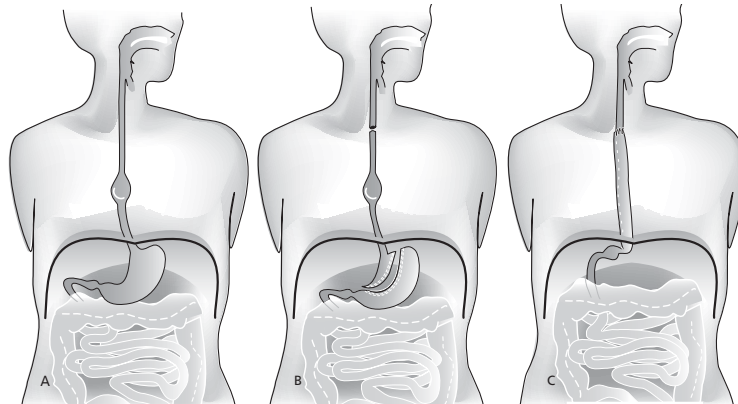
Slokdarmkanker (oesophaguscarcinoom) is wereldwijd de 8st meest voorkomende vorm van kanker en is de 6^{de} meest voorkomende oorzaak van kankersterfte. In 2002 werd wereldwijd bij 462.000 nieuwe patiënten slokdarmkanker vastgesteld. De 2 meest voorkomende vormen van slokdarmkanker zijn het plaveiselcelcarcinoom en het adenocarcinoom. De eerste is voornamelijk het gevolg van roken en overmatig alcoholgebruik, terwijl de tweede veroorzaakt wordt door het optreden van zuurbranden in de slokdarm. De snelle stijging in het jaarlijks aantal nieuwe patiënten met slokdarmkanker is voornamelijk het gevolg van het toenemend optreden van het adenocarcinoom. Wereldwijd is het plaveiselcelcarcinoom de meest voorkomende vorm. Voor slokdarmkankerpatiënten is chirurgie de beste vorm van behandeling. Echter, doordat de symptomen, zoals bijvoorbeeld slikklachten en pijn achter het borstbeen, vaak pas ontstaan als de tumor de gehele slokdarmopening heeft versperd, wordt de ziekte dikwijls in een vergevorderd stadium ontdekt. Hierdoor is behandeling met uitzicht op genezing in meer dan de helft van de patiënten niet meer mogelijk.

Chirurgie

Slokdarmkanker heeft een onvoorspelbaar groei- en uitzaaiingspatroon. Om deze reden wordt tijdens slokdarmkankeroperaties niet alleen de tumor verwijderd, maar de gehele slokdarm, de slokdarm-maag overgang en de omringende lymfeklieren in borstkas en buik (Figuur 1). Deze operatie wordt meestal uitgevoerd via grote snedes in de borstkas, de buik en de hals (open transthoracale benadering) en gaat gepaard met veel complicaties.

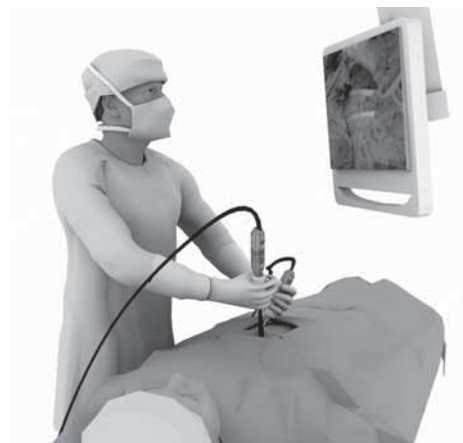Om de chirurgische schade te beperken en om zo de complicaties van de operatie te verminderen zijn andere operatieve benaderingen ontwikkeld. Zo is een operatietechniek ontwikkeld waarbij alleen via de buik en de hals wordt geopereerd en waarbij de borstkas gesloten blijft (open transhiatale benadering). Het nadeel hiervan is echter dat lymfeklieren die in de borstkas liggen en die mogelijk kanker bevatten, niet verwijderd kunnen worden. Een andere operatietechniek is slokdarmkankeroperatie via minimaal invasieve chirurgie ('kijkoperatie' of 'sleutelgatchirurgie').

Figuur 1 - Schematische weergave van de slokdarmkankeroperatie. A: tumor in het middelste deel van de slokdarm; B: tijdens de operatie worden bijna de gehele slokdarm en de slokdarm-maagovergang verwijderd, waarna van de maag een buis wordt gemaakt; C: de buismaag wordt op de oorspronkelijke plaats van de slokdarm gelegd en vastgemaakt aan het restant slokdarm in de hals.



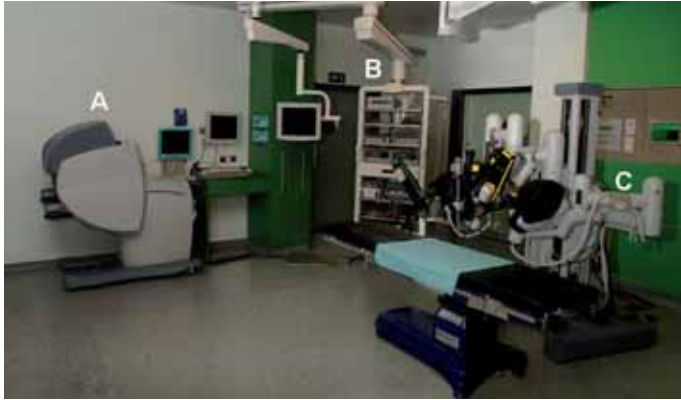
Minimaal invasieve chirurgie biedt ten opzichte van de open operatietechnieken verschillende voordelen voor de patiënt: er wordt minder schade aangericht doordat er wordt geopereerd via zeer kleine snedes, de pijn na de operatie is minder, de herstelduur na de operatie is korter en het cosmetisch resultaat is beter. Voor de chirurg brengen minimaal invasieve operatietechnieken echter nadelen met zich mee. Zo is er sprake van 2-dimensionaal zicht (de chirurg kijkt naar een monitor) en is het zicht van de chirurg afhankelijk van de camerastand die door de assistent wordt bepaald (Figuur 2). De

Figuur 2 - Nadelen van huidige minimaal invasieve operaties: 2-dimensionaal zicht, een veranderde oog-hand-doel coördinatie en het gebruik van lange, starre operatie-instrumenten.



- 1
- 2
- 3
- 4
- 5
- 6
- 7
- 8
- 9
- 10
- 11
- 12
- 13
- 14
- 15
- 16
- 17
- 18
- 19
- 20
- 21
- 22
- 23
- 24
- 25
- 26
- 27
- 28
- 29
- 30
- 31
- 32

Figuur 3 - Het Da Vinci® robotsysteem bestaande uit de console (A), de kar met elektronische apparatuur (B) en de robot (C) (Voor kleurenfiguur zie pagina 292).



natuurlijke oog-hand-doel coördinatie is verstoord, doordat de chirurg niet naar het operatiegebied kijkt, maar naar de monitor. Tevens vindt verstoring plaats, doordat de beweging van de uiteinden van de operatie-instrumenten tegengesteld is aan de beweging van de handen van de chirurg. Een ander nadeel is dat de lange, starre operatie-instrumenten minder goed te manoeuvreren zijn, waardoor verschillende handelingen niet met hetzelfde gemak als in de open situatie kunnen worden uitgevoerd.

Het Da Vinci® robotsysteem is ontwikkeld om aan de nadelen van de huidige minimaal invasieve chirurgie tegemoet te komen. Dit robotsysteem bestaat uit 3 delen (Figuur 3): I) de console waarmee de chirurg op afstand de robot bestuurt (Figuur 3A), II) de operatie-robot met de 3 robotarmen (Figuur 3C) en III) de kar met elektronische apparatuur

(Figuur 3B). De Da Vinci® robot biedt de chirurg een 3-dimensionaal, 10x vergroot zicht op het operatiegebied. De operatie-instrumenten hebben kleine gewrichtjes aan het (inwendige) uiteinde, waardoor soepele bewegingen mogelijk zijn. De camera is bevestigd aan de middelste robotarm, die door de chirurg zelf te besturen is. Daarnaast biedt de console de chirurg een comfortabele en ergonomisch verantwoorde werkplek.

Het Da Vinci® robotsysteem wordt momenteel in Amerika standaard toegepast bij prostaat­kankeroperaties, aangezien is gebleken dat deze techniek beter is dan de open prostaat­kankeroperatie en beter dan de minimaal invasieve operatie zonder robot­assistentie. Het Da Vinci® robotsysteem zou ook van toegevoegde waarde kunnen zijn bij slokdarmkankeroperaties, tijdens het vrijmaken van de slokdarm en de omringende lymfeklieren van de omliggende belangrijke organen zoals het hart en de luchtpijp.

Neoadjuvante behandeling

Door het frequente optreden van terugkeer van de ziekte (tumor recidief), is de overleving na slokdarmkankeroperaties relatief ongunstig. Vijf jaar na de operatie is gemiddeld nog 35% van de patiënten in leven. Om de kans op tumor recidivering te verminderen, kan voorafgaand aan de operatie (= neoadjuvant) chemotherapie, al dan niet in combinatie met bestraling, worden gegeven. Momenteel is onbekend in welke mate neoadjuvante therapie wereldwijd wordt toegepast bij slokdarmkankerpatiënten.

Een groot nadeel van chemotherapie is dat het niet selectief is en daardoor alle delende cellen kapot maakt, inclusief gezonde cellen. Als gevolg hiervan gaat chemotherapie vaak gepaard met veel bijwerkingen. Verschillende medicamenten zijn onlangs ontwikkeld die selectief aangrijpen op kankercellen, doordat zij gericht zijn tegen bepaalde moleculaire karakteristieken (markers) van deze kankercellen. Onderzoek zal moeten aantonen welke moleculaire markers aangegrepen moeten worden in slokdarmkanker.

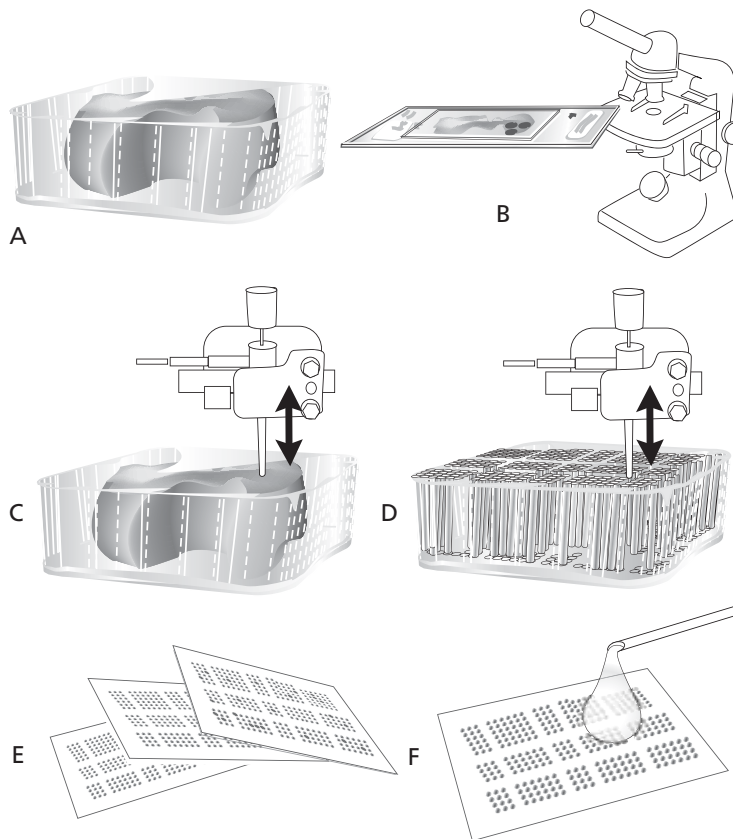
De aanwezigheid van een moleculaire marker in een weefsel kan worden onderzocht met behulp van een weefselkleuring. Deze kleuring wordt verricht op een heel dun plakje weefsel (coupe), dat is gesneden van een blokje paraffine (soort kaarsvet dat het snijden van coupes vereenvoudigd) met daarin het te onderzoeken weefsel. Om de aanwezigheid van een marker in een groot aantal weefsels te onderzoeken, dient dus van elk weefsel een coupe te worden gesneden en dient elke coupe met verschillende

—	1
—	2
—	3
—	4
—	5
—	6
—	7
—	8
—	9
—	10
—	11
—	12
—	13
—	14
—	15
—	16
—	17
—	18
—	19
—	20
—	21
—	22
—	23
—	24
—	25
—	26
—	27
—	28
—	29
—	30
—	31
—	32

vloeistoffen te worden gekleurd, wat erg tijdrovend en duur is.

De tissue microarray (TMA) technologie is ontwikkeld om het gelijktijdig onderzoeken van een groot aantal weefsels te vergemakkelijken (Figuur 4). Door het overplaatsen van 3 kleine (diameter 0.6mm), representatieve naaldbiopten uit het weefsel in een nieuw paraffine blokje (het TMA blokje), kan een groot aantal weefsels onder gelijke laboratoriumomstandigheden worden onderzocht, zonder dat hierbij het weefsel van de patiënt ernstig wordt beschadigd. Deze techniek leidt bovendien tot een afname van de tijd die nodig is voor de beoordeling van de resultaten van de weefselkleuring.

Figuur 4 - Schematische, vereenvoudigde weergave van het maken van een tissue microarray (TMA). A: paraffine-blokje met hierin weefsel (donker); B: van het paraffine-blokje in (A) wordt een coupe gesneden. Hierop worden met behulp van een microscoop de 3 meest representatieve weefselgebieden geselecteerd; C: prikken van weefselbiopten uit het paraffine-blokje in (A) ter plaatse van de meest representatieve weefselgebieden; D: prikken van deze weefselbiopten in een nieuw, leeg paraffine blokje (dit wordt het TMA-paraffine blokje); E: van het TMA-paraffine blokje kunnen meerdere coupes gesneden worden; F: kleuring van 1 TMA-coupe levert resultaten van honderden weefsels gelijktijdig



Beeldvormende modaliteiten

Voorafgaand aan de operatie kan de uitgebreidheid van slokdarmkanker in het lichaam in kaart worden gebracht met beeldvormende technieken zoals bv. inwendige echografie van de slokdarm, CT-scan van de borstkas en buik of echografie van de hals. Het is echter onbekend in welke frequentie deze verschillende modaliteiten wereldwijd worden gebruikt in slokdarmkankerpatiënten.

Voor geopereerde patiënten bij wie de patholoog in het verwijderde weefsel geen lymfeklieruitzaaiingen kan aantonen, was de uitgebreide verwijdering (dissectie) van alle lymfeklieren achteraf gezien overbodig. In deze patiënten zouden de complicaties van slokdarmkankeroperaties mogelijk verminderd kunnen worden door de uitgebreidheid van de lymfeklierdissectie in te perken. Dit zou mogelijk bereikt kunnen worden door het introduceren van de schildwachtklier(SWK) procedure in slokdarmkankeroperaties.

Een SWK is een lymfeklier die directe afvoer van lymfe krijgt uit de tumor. Hierdoor is de SWK (theoretisch) de eerste plaats van tumoruitzaaiing. Wanneer de patholoog geen kankercellen in de SWK kan aantonen, kan de dissectie van de lymfeklieren die aansluiten op deze SWK achterwege gelaten worden, aangezien deze lymfeklieren (theoretisch) ook geen kankercellen zullen bevatten. Deze techniek is zeer betrouwbaar gebleken in vroeg-stadium borstkankerpatiënten en wordt in deze patiëntengroep dan ook veelvuldig toegepast.

Nadat de slokdarm is verwijderd, dient de continuïteit van het spijsverteringskanaal te worden hersteld. Dit gebeurt door van de maag een buis te maken met behulp van een nietjesapparaat (Figuur 1b, p. 251). Deze buismaag wordt in de borstkas omhoog getrokken en in de hals vastgemaakt aan het restant slokdarm (Figuur 1b-c, p. 251). Een veel voorkomende complicatie van slokdarmkankeroperaties is lekkage van de verbinding (anastomose) tussen buismaag en restant slokdarm. Voordat de patiënt na de operatie weer mag drinken of eten, wordt in veel ziekenhuizen rond de 7^e dag na de operatie routinematig een röntgen slikfoto vervaardigd om te onderzoeken of de anastomose goed geheeld is. Indien op de röntgenfoto geen lekkage wordt aangetoond, dan mag het dieet langzaam worden uitgebreid. Wordt een radiologische lekkage vastgesteld, dan wordt de inname van water en voedsel voor nog een week

— 1
 — 2
 — 3
 — 4
 — 5
 — 6
 — 7
 — 8
 — 9
 — 10
 — 11
 — 12
 — 13
 — 14
 — 15
 — 16
 — 17
 — 18
 — 19
 — 20
 — 21
 — 22
 — 23
 — 24
 — 25
 — 26
 — 27
 — 28
 — 29
 — 30
 — 31
 — 32

1 _____ uitgesteld. Er bestaat internationaal veel discussie over de waarde van deze routine
2 _____ röntgen slikfoto, aangezien niet elke lekkage kan worden opgespoord en aangezien het
3 _____ verslikken in het contrastmateriaal tot longontstekingen kan leiden.
4 _____
5 _____
6 _____

CENTRALE VRAAGSTELLINGEN VAN DIT PROEFSCHRIFT

7 _____ Het doel van dit proefschrift was om verschillende strategieën op het gebied van
8 _____ chirurgie (**Deel I**), moleculaire biologie (**Deel II**) en beeldvormende diagnostiek (**Deel III**)
9 _____ te onderzoeken die de uitkomst van patiënten die een slokdarmkankeroperatie hebben
10 _____ ondergaan, zouden kunnen verbeteren. De studies beschreven in dit proefschrift werden
11 _____ geleid door de volgende onderzoeksvragen:
12 _____

- 13 _____ • Wat is het huidige wereldwijde gebruik van operatietechnieken, beeldvormende
14 _____ technieken en neoajuvante behandeling in patiënten met slokdarmkanker?
 - 15 _____ • Kunnen minimaal invasieve robotsystemen de complicaties van open transthoracale
16 _____ slokdarmkankeroperaties verminderen, zonder de overleving van de patiënt nadelig
17 _____ te beïnvloeden?
 - 18 _____ • Welke markers zijn aangrijpingspunten voor moleculaire behandeling in het
19 _____ plaveiselcelcarcinoom van de slokdarm?
 - 20 _____ • Is er een rol voor de schildwachtklierprocedure en de routine röntgenslikfoto in
21 _____ slokdarmkanker?
22 _____
- 23 _____
24 _____
25 _____
26 _____
27 _____

SAMENVATTING

In **hoofdstuk 1** wordt een algemene introductie gegeven over slokdarmkanker, de mogelijke vormen van behandeling en beeldvorming. Tevens worden de centrale vraagstellingen van het proefschrift vermeld.

Deel I: Chirurgische strategieën

Voor patiënten met slokdarmkanker is het algemeen geaccepteerd dat chirurgie de beste vorm van behandeling biedt. Desalniettemin bestaat er geen standaard slokdarmkankeroperatie. Om meer inzicht te krijgen in de huidige gebruikte operatietechnieken is een internationale enquête gehouden onder chirurgen met interesse in slokdarmkanker, waaronder leden van verschillende internationale slokdarmkankerverenigingen. De resultaten van deze enquête laten zien dat chirurgische technieken erg verschillen en afhangen van de ervaring van de chirurg in het uitvoeren van slokdarmkankeroperaties en van de nationaliteit van de chirurg (**Hoofdstuk 2**). De meest gebruikte techniek is de open transthoracale benadering met een buismaag en een anastomose in de hals.

Voordat op 17 Oktober 2003 de eerste slokdarmkankerpatiënt met behulp van de operatierobot werd geopereerd, is de operatietechniek uitgebreid getest in ons laboratorium op varkens. Onze eerste ervaring met robotgeassisteerde slokdarmkankeroperaties in 21 slokdarmkankerpatiënten is beschreven in **hoofdstuk 3**. De operatietechniek was technisch uitvoerbaar en ging gepaard met zeer weinig bloedverlies. De chirurg had veel baat bij de robot tijdens het vrijmaken van de slokdarm en de omringende lymfeklieren in de borstkas. Een sterke afname in het aantal longcomplicaties werd gezien in de laatste groep geopereerde patiënten vergeleken bij de eerste, wat de leercurve van het operatieteam en het anaesthesiologisch team weergaf.

Tijdens een slokdarmkankeroperatie wordt de continuïteit van het spijsverteringskanaal hersteld door van de maag een buis te maken. Dit gebeurt met behulp van nietjesapparaat. De nietjesrij wordt tijdens een open slokdarmkankeroperatie standaard met hechtingen

1 — overhecht om schade door eventuele uitstekende nietjes aan organen in de borstkas te
2 — voorkomen. Tijdens minimaal invasieve slokdarmkankeroperaties wordt de buismaag in
3 — de buik gemaakt. De nietjesrij wordt dan niet overhecht omdat dit door de lange, starre
4 — operatie-instrumenten technisch zeer lastig is. In **hoofdstuk 4** laten wij zien dat het
5 — niet overhechten van de nietjesrij ernstige gevolgen kan hebben. In 1 patiënt waarbij
6 — de nietjesrij niet was overhecht werd tijdens een 2^e operatie een gat in de buismaag
7 — gezien. In een andere patiënt was door een uitstekend nietje een directe verbinding
8 — ontstaan tussen de luchtpijp en de buismaag, waarvoor de rechter long operatief
9 — moest worden verwijderd. Uiteindelijk overleed deze patiënt aan de gevolgen hiervan.
10 — Hierna hebben wij het overhechten van de nietjesrij direct weer ingevoerd. Tijdens onze
11 — robot-geassisteerde minimaal invasieve operaties wordt de buismaag buiten de patiënt
12 — gemaakt, waardoor het overhechten met de hand kan worden gedaan en niet met de
13 — minimaal invasieve operatieinstrumenten. Sindsdien hebben we dergelijke complicaties
14 — niet meer waargenomen.

15 —
16 — Naast de slokdarm loopt een ader (genaamd 'vena azygos') die een verbinding
17 — vormt tussen de vele aderen tussen de ribben en de bovenste holle ader. Tijdens open
18 — slokdarmkankeroperaties wordt deze ader samen met de slokdarm en het tussenliggende
19 — vetweefsel verwijderd, om zoveel mogelijk lymfeklieren die in dit vetweefsel liggen, uit de
20 — patiënt te verwijderen. Tijdens minimaal invasieve slokdarmkankeroperaties, al dan niet
21 — uitgevoerd met de robot, wordt deze ader niet verwijderd (maar wel het tussenliggende
22 — vetweefsel), omdat het technisch moeilijk en tijdrovend is om alle zijtakken van deze
23 — ader af te binden. In **hoofdstuk 5** hebben wij op menselijke stoffelijke overschotten
24 — onderzocht hoeveel lymfeklieren achterblijven als deze ader niet wordt verwijderd.
25 — Gemiddeld bleken 0.67 lymfeklieren aanwezig te zijn rond deze ader. Verder kon in
26 — 60% van de stoffelijke overschotten totaal geen lymfeklieren gevonden worden rond
27 — deze ader. Wij concluderen dan ook dat tijdens (zowel open als minimaal invasieve)
28 — slokdarmkankeroperaties deze ader niet verwijderd hoeft te worden.

16

30 — In **hoofdstuk 6** worden de korte en middellange termijn resultaten beschreven van
31 — 's werelds grootste aantal slokdarmkankeroperaties uitgevoerd met behulp van een
32 — operatierobot. Wanneer de resultaten van de laatste 24 geopereerde patiënten worden

vergeleken met de eerste 23, dan wordt een significante afname in bloedverlies en operatieduur gezien, wat de leercurve van het operatieteam weergeeft. Hoewel het aantal complicaties momenteel gelijk is als bij de open transthoracale benadering, wordt een duidelijke afname in het aantal longcomplicaties gezien over de tijd. Het aantal verwijderde lymfeklieren tijdens de robot-geassisteerde operatie was vergelijkbaar met de open transthoracale operatie. Een belangrijke bevinding was dat in 29% van de patiënten met een tumor in het onderste deel van de slokdarm, tijdens de robotoperatie lymfeklieren hoog uit de borstkas zijn verwijderd die kankercellen bevatten. Deze lymfeklieren zouden niet verwijderd zijn tijdens de open transhiatale benadering, wat voor veel chirurgen de standaardbehandeling is in patiënten met tumoren laag in de slokdarm. De ziekte-vrije overleving na de robotgeassisteerde operatie was gelijk aan de open transthoracale benadering.

Slokdarmkanker ontstaat meestal uit de oppervlakkige cellaag (epitheel) van de slokdarm. Kanker kan echter ook ontstaan uit het bindweefsel van de slokdarm. In **Hoofdstuk 7** wordt een patiënt beschreven bij wie in de spierlaag van de slokdarm een zeer grote (diameter 9 cm) zwelling werd vastgesteld die zeer verdacht was voor kanker. Met behulp van de Da Vinci® robot werd de slokdarm verwijderd. Dit was 's werelds eerste robot-geassisteerde slokdarmverwijdering voor een zwelling in de spierlaag van de slokdarm. Onderzoek door de patholoog toonde aan dat de zwelling goedaardig was. Desalniettemin was de behandeling hetzelfde geweest, aangezien de zwelling veel klachten gaf.

Deel II: Moleculair biologische strategieën

De TMA technologie is ontwikkeld om de gelijktijdige analyse van grote aantallen weefsels te vergemakkelijken. Aangezien de mogelijkheid bestaat dat de kleine (diameter 0.6mm) weefselbiopten niet representatief zijn voor de weefselblokjes waaruit zij afkomstig zijn, hebben wij onze TMA bestaande uit 108 plaveiselceltumoren van de slokdarm gevalideerd (**Hoofdstuk 8**). Een TMA-coupe en een coupe van het blokje waar de weefselbiopten uit afkomstig waren, zijn gekleurd voor verschillende moleculaire markers. De patholoog heeft deze coupes afzonderlijk van elkaar beoordeeld en heeft een score gegeven voor de mate van aankleuring. De (kans-gecorrigeerde)

—	1
—	2
—	3
—	4
—	5
—	6
—	7
—	8
—	9
—	10
—	11
—	12
—	13
—	14
—	15
—	16
—	17
—	18
—	19
—	20
—	21
—	22
—	23
—	24
—	25
—	26
—	27
—	28
—	29
—	30
—	31
—	32

1 ————— overeenkomst tussen de score van de TMA biopten en de corresponderende donor
 2 ————— blokjes varieerde van matig tot bijna perfect.

3 —————
 4 ————— Nadat onze TMA valide was bevonden, is het gebruikt om mogelijke aangrijpingspunten
 5 ————— voor moleculaire therapie in plaveiselceltumoren van de slokdarm te identificeren. In
 6 ————— **hoofdstuk 9** is met behulp van weefselkleuringen op TMA coupes aangetoond dat de
 7 ————— moleculaire markers COX-2, EGFR, VEGF en cycline D1 mogelijke kandidaten zijn voor
 8 ————— moleculaire therapie in plaveiselceltumoren van de slokdarm, aangezien deze markers
 9 ————— frequent in onze TMA voorkwamen.

10 —————
 11 ————— Een nieuwe, interessante moleculaire marker is mTOR, aangezien onlangs medicatie
 12 ————— tegen deze marker is ontwikkeld. De aanwezigheid van deze marker is al in
 13 ————— verschillende soorten kanker aangetoond, waaronder nierkanker. Tevens is gebleken
 14 ————— dat de overleving van patiënten met nierkanker die behandeld worden met het mTOR-
 15 ————— remmende medicijn langer is dan patiënten die dit medicijn niet krijgen. In een studie
 16 ————— van een andere onderzoeksgroep op 3 verschillende typen losse slokdarmkankercellen
 17 ————— is aangetoond dat mTOR ook aanwezig is en dat de aanwezigheid verminderd kan
 18 ————— worden met het mTOR-remmende medicijn. Op basis van deze resultaten hebben wij
 19 ————— een weefselkleuring voor actief mTOR gedaan op een TMA-coupe, om te bepalen
 20 ————— welk percentage van de plaveiselceltumoren van de slokdarm nu deze marker bezitten
 21 ————— (**Hoofdstuk 10**). Op deze manier kon indirect worden bepaald welk percentage
 22 ————— van de patiënten met een plaveiselceltumor van de slokdarm in aanmerking zou
 23 ————— kunnen komen voor behandeling met het mTOR-remmende medicijn. Actief mTOR
 24 ————— was aanwezig in 25% van de plaveiselceltumoren van de slokdarm. Op basis hiervan
 25 ————— zou overwogen kunnen worden een studie te starten naar de effectiviteit van mTOR-
 26 ————— remmende medicijnen voorafgaand aan de slokdarmkankeroperatie in patiënten met
 27 ————— een plaveiselceltumor van de slokdarm.

Deel III: Diagnostische beeldvormende strategieën

30 ————— Om inzichtelijk te krijgen in welke mate de verschillende diagnostische modaliteiten
 31 ————— momenteel worden toegepast in slokdarmkankerpatiënten, en in welke mate
 32 ————— neoadjuvantetherapie(chemotherapie,bestraling)wordtgegeven,zijnindeinternationale

enquête onder slokdarmchirurgen (zie hoofdstuk 2) ook vragen over deze onderwerpen gesteld. De resultaten hiervan zijn beschreven in **hoofdstuk 11**. De meest gebruikte diagnostische modaliteiten zijn de scopie van de slokdarm en maag en de CT-scan van de borstkas en buik. Een derde van de chirurgen behandelt slokdarmkankerpatiënten routinematig met neoadjuvante therapie. Aanzienlijke verschillen werden aangetoond tussen chirurgen afkomstig van verschillende continenten.

Om te onderzoeken of de SWK procedure ook toepasbaar is in slokdarmkanker, hebben wij een haalbaarheidsanalyse gedaan in 8 slokdarmkankerpatiënten (**Hoofdstuk 12**). In 5 van de 8 patiënten werden na de operatie door de patholoog in het verwijderde weefsel lymfeklieruitzaaiingen vastgesteld. De opgespoorde SWK in deze patiënten toonde echter geen tumorweefsel. Hierdoor waren deze onderzoeken (100%) dus fout-negatief. Deze patiënten hadden dus geen baat bij de SWK procedure. Echter, de goede resultaten behaald in Japanse onderzoeken met patiënten met zeer vroege vormen van slokdarmkanker tonen aan dat er mogelijk wel een rol voor de SWK procedure is weggelegd in deze patiëntengroep. Doordat in Nederland geen screening op slokdarmkanker wordt toegepast, zal het aantal patiënten dat hiervoor in aanmerking komt, minimaal zijn.

In **hoofdstuk 13** worden de resultaten beschreven van het patiëntendossieronderzoek naar de waarde van de routine röntgenslikfoto uitgevoerd na slokdarmkankeroperaties. Uit deze studie bleek dat veel slikfoto's geen lekkage lieten zien, terwijl in de praktijk wel een lekkage ontstond (fout-negatief onderzoek). Bovendien waren in meer dan de helft van de patiënten bij wie een lekkage ontstond, de symptomen al opgetreden voordat de routine röntgenslikfoto werd uitgevoerd. Wij vinden dat daarom afgestapt moet worden van het routinematig vervaardigen van een röntgenslikfoto. Om de anastomose te testen introduceren wij als alternatief een klinische test.

CONCLUSIE

- **Wat is het huidige wereldwijde gebruik van operatietechnieken, beeldvormende technieken en neoadjuvante behandeling in patiënten met slokdarmkanker?**

De operatietechnieken, pre-operatieve beeldvormende onderzoeken en neoadjuvante therapie zoals momenteel door chirurgen wereldwijd worden toegepast in slokdarmkankerpatiënten hangen zeer af van de nationaliteit van de chirurg en zijn/haar ervaring in slokdarmkankeroperaties. De meest toegepaste operatietechniek is de open transthoracale benadering met een buismaag en een anastomose in de hals. De meest gebruikte diagnostische modaliteiten zijn de scopie van de slokdarm en maag en de CT-scan van de borstkas en buik. Een derde van de chirurgen behandelt slokdarmkankerpatiënten routinematig met neoadjuvante therapie.

- **Kunnen minimaal invasieve robotsystemen de complicaties van open slokdarmkankeroperaties verminderen, zonder de overleving van de patiënt nadelig te beïnvloeden?**

Robot-geassisteerde slokdarmkankeroperaties zijn technisch uitvoerbaar en gaan gepaard met weinig bloedverlies. Op dit moment is het aantal complicaties vergelijkbaar met de open transthoracale benadering. Echter, de aanzienlijke afname in het percentage longcomplicaties dat is aangetoond, laat een steile leercurve zien van zowel het chirurgisch als het anaesthesiologisch team. Met toenemende ervaring zal het aantal complicaties naar alle verwachting nog meer dalen. Het aantal verwijderde lymfeklieren en de ziekte-vrije overleving zijn vergelijkbaar met de open transthoracale benadering. De meest nauwkeurige methode om deze onderzoeksvraag te onderzoeken, zou met behulp van een studie zijn waarbij slokdarmkankerpatiënten geloot worden voor het ondergaan van een open transthoracale slokdarmkankeroperatie of een robot-geassisteerde minimaal invasieve slokdarmkankeroperatie.

• Welke markers zijn aangrijpingspunten voor moleculaire behandeling in het plaveiselcelcarcinoom van de slokdarm?	1
De moleculaire markers mTOR, VEGF, cycline D1, EGFR en Cox-2 lijken potentiële doelen voor moleculaire behandeling in plaveiselceltumoren van de slokdarm, door hun frequente voorkomen in onze TMA. Klinische studies naar het effect van therapie gericht tegen deze markers dient overwogen te worden in deze patiëntengroep.	2
	3
	4
	5
	6
	7
	8
• Is er een rol voor de schildwachtklierprocedure en de routine röntgen slikfoto in slokdarmkanker?	9
Op basis van het hoog aantal vals-negatieve resultaten aangetoond in onze studie lijkt er geen rol weggelegd te zijn voor de schildwachtklierprocedure in slokdarmkankerpatiënten. Echter, gezien de veelbelovende resultaten van Japanse onderzoekers in oppervlakkige slokdarmtumoren, zou er wel een rol weggelegd kunnen zijn in deze patiëntengroep.	10
	11
	12
	13
	14
	15
Het valt aan te bevelen het routinematig uitvoeren van een röntgenslikfoto na slokdarmkankeroperaties met een buismaag en een anastomose in de hals achterwege te laten. Dit routine onderzoek gaat gepaard met een hoog aantal fout-negatieve resultaten. Daarnaast zijn in meer dan de helft van de patiënten bij wie klinisch een lekkage optreedt, de symptomen van lekkage al ontstaan voordat de routine slikfoto wordt uitgevoerd.	16
	17
	18
	19
	20
	21
	22
	23
	24
	25
	26
	27
	28
	29
	30
	31
	32

17

Addenda

Addendum I

Robot-assisted thoracolaparoscopic esophagolymphadenectomy for esophageal cancer

Judith Boone

Inne H.M. Borel Rinkes

Richard van Hillegersberg

Department of Surgery,
University Medical Center Utrecht

Dear Editors,

With interest we have read the article by Kernstine and co-authors in which they describe their initial experience with totally robot-assisted thoracoscopic esophagolymphadenectomy.¹

Their series consists of 3 consecutive groups, each combining the robot-assisted thoracoscopic procedure with either 1) open abdominal surgery, 2) laparoscopy or 3) robot-assisted laparoscopy. These groups represent the learning curve followed by the authors. Indeed, we followed a similar strategy in our first 21 cases of robot-assisted thoracoscopic esophagolymphadenectomy, published in this journal in 2006.² We experienced a steep learning curve and only found a reduction of the pulmonary complication rate after we introduced the laparoscopic abdominal phase. This is consistent with previous reports of conventional thoracoscopic esophagectomy.³ Before introducing the procedure in our clinic, we have tested the port position and the position of the robotic system extensively in a cadaveric study and came to a similar thoracic position as presented by Kernstine et al.¹ The position of the robotic system in our set-up, however, is more dorsocranially.^{2,4}

In our experience, the Da Vinci® robotic system is very beneficial during the thoracoscopic phase of esophageal resection and lymph node dissection, allowing for a very precise dissection along the vital mediastinal structures. Yet, we found the robotic system less suitable for the abdominal phase, requiring manoeuvres with large amplitude leading to collisions of the robotic arms. Especially during the dissection along the greater curvature of the stomach, a large area of various positions has to be covered. We therefore perform the abdominal phase by conventional laparoscopy, using an ultrasonic dissector device. Selective use of the robot can save operating time. The median operating time of robot-assisted thoracoscopy with conventional laparoscopy is 7.5 hours², versus 11.2 hours in case of the totally robotic procedure.¹

The authors do not describe any benefit of using the robotic system during the abdominal phase. The median amount of lymph nodes dissected in the current series was less when compared to our series: 18¹ vs 20², even though they denominate their procedure a three-field lymph node dissection. A formal cervical lymph node dissection was not performed in this series, so in fact a two-field lymphadenectomy was carried out.⁵

With regard to the azygos vein, we agree with the authors that the trunk of this vein can be preserved during robot-assisted thoracoscopic esophagolymphadenectomy. We have recently shown in a cadaveric study that preservation of the azygos vein during thoracic esophagolymphadenectomy did not substantially affect the extent of mediastinal lymph node harvesting.⁶

REFERENCES

1. Kernstine KH, DeArmond DT, Shamoun DM, Campos JH. The first series of completely robotic esophagectomies with three-field lymphadenectomy: initial experience. *Surg Endosc* 2007; 21:2285-2292.
2. van Hillegersberg R, Boone J, Draaisma WA, Broeders IA, Giezeman MJ, Borel Rinkes IHM. First experience with robot-assisted thoracoscopic esophagolymphadenectomy for esophageal cancer. *Surg Endosc* 2006; 20:1435-1439.
3. Luketich JD, Alvelo-Rivera M, Buenaventura PO et al. Minimally invasive esophagectomy: outcomes in 222 patients. *Ann Surg* 2003; 238:486-494.
4. Boone J, Draaisma WA, Schipper ME, Broeders IA, Borel Rinkes IHM, van Hillegersberg R. Robot-assisted thoracoscopic esophagectomy for a giant upper esophageal leiomyoma. *Dis Esophagus* 2008; 21:90-93.
5. Lerut T, Nafteux P, Moons J et al. Three-field lymphadenectomy for carcinoma of the esophagus and gastroesophageal junction in 174 R0 resections: impact on staging, disease-free survival, and outcome: a plea for adaptation of TNM classification in upper-half esophageal carcinoma. *Ann Surg* 2004; 240:962-972.
6. Boone J, Schipper ME, Bleys RL, Borel Rinkes IHM, van Hillegersberg R. The effect of azygos vein preservation on mediastinal lymph node harvesting in thoracic esophagolymphadenectomy. *Dis Esophagus* 2008; 21:226-229.

1
2
3
4
5
6
7
8
9
10
11
12
13
14
15
16
17
18
19
20
21
22
23
24
25
26
27
28
29
30
31
32

Addendum II

Transhiatal robot-assisted esophagectomy

Judith Boone
Inne H.M. Borel Rinkes
Richard van Hillegersberg

Department of Surgery,
University Medical Center Utrecht

Dear Editor,

With interest we read the article by Galvani and co-authors, to be published in a forthcoming issue of *Surgical Endoscopy*, in which they describe their initial experience with laparoscopic transhiatal esophagectomy partly aided by a robotic system.¹

Their series consists of 18 selected patients with Barrett's esophagus and high-grade dysplasia (n=9), adenocarcinoma in situ (n=2), superficial adenocarcinoma (n=5) or T2-3 esophageal adenocarcinoma (n=2) without clinical evidence of lymph node metastases. Since robot-assisted laparoscopic esophagectomy in these patients was accompanied by low blood loss, low cardiopulmonary complication rate and no in-hospital mortality, the authors conclude their surgical technique to be a safe and effective alternative for the treatment of esophageal adenocarcinoma. We agree with the authors that this procedure may be safe and effective for the treatment of high grade dysplasia or in situ carcinoma, however, for esophageal cancer some remarks have to be made regarding its oncologic effectiveness.

The mean amount of 14 lymph nodes dissected is less than in the open transhiatal (mean 16) and transthoracic (mean 31) approach.² The authors fail to describe the location of these lymph nodes, retrieved either abdominally (e.g. left gastric artery nodes) or mediastinally. Most probably the mediastinal lymphadenectomy was limited to the periesophageal and the carinal stations. Several studies however, have shown that distal esophageal adenocarcinomas frequently metastasize to lymph nodes located in the upper mediastinum.^{3,4} When performing the hybrid robot-assisted transhiatal approach, these potential metastatic lymph nodes will be left in situ. Recently, 2 series of robot-assisted thoracoscopic esophagolymphadenectomy have been published describing a technique where a proper mediastinal lymph node dissection is performed including the bilateral paratracheal and aortopulmonary window nodes.^{5,6}

This may be the reason for the relatively high rate of tumor recurrence in the Galvani series.¹ After a mean follow-up of 22 months, 2 (11%) patients had died and 3 (17%) had recurrence in a patient population with 50% of patients diagnosed with high grade dysplasia and 50% with superficial adenocarcinoma with neither lymph node metastases nor tumor involvement in the resection margins. The technique described by Galvani et al. may therefore not be suitable for esophageal cancer, but rather for high grade dysplasia.

REFERENCES

1. Galvani CA, Gorodner MV, Moser F et al. Robotically assisted laparoscopic transhiatal esophagectomy. *Surg Endosc* 2008; 22:188-195.
2. Hulscher JB, van Sandick JW, de Boer AG et al. Extended transthoracic resection compared with limited transhiatal resection for adenocarcinoma of the esophagus. *N Engl J Med* 2002; 347:1662-1669.
3. Feith M, Stein HJ, Siewert JR. Pattern of lymphatic spread of Barrett's cancer. *World J Surg* 2003; 27:1052-1057.
4. Schroder W, Monig SP, Baldus SE, Gutschow C, Schneider PM, Holscher AH. Frequency of nodal metastases to the upper mediastinum in Barrett's cancer. *Ann Surg Oncol* 2002; 9:807-811.
5. van Hillegersberg R, Boone J, Draaisma WA, Broeders IA, Giezeman MJ, Borel Rinkes IHM. First experience with robot-assisted thoracoscopic esophagolymphadenectomy for esophageal cancer. *Surg Endosc* 2006; 20:1435-1439.
6. Kernstine KH, DeArmond DT, Shamoun DM, Campos JH. The first series of completely robotic esophagectomies with three-field lymphadenectomy: initial experience. *Surg Endosc* 2007; 21:2285-2292.

— 1
 — 2
 — 3
 — 4
 — 5
 — 6
 — 7
 — 8
 — 9
 — 10
 — 11
 — 12
 — 13
 — 14
 — 15
 — 16
 — 17
 — 18
 — 19
 — 20
 — 21
 — 22
 — 23
 — 24
 — 25
 — 26
 — 27
 — 28
 — 29
 — 30
 — 31
 — 32

Addendum III

The azygos vein: To resect or not?

Judith Boone
Richard van Hillegersberg

Department of Surgery,
University Medical Center Utrecht

Dear Editor,

1 —
2 —
3 —
4 —
5 —
6 —
7 —
8 —
9 —
10 —
11 —
12 —
13 —
14 —
15 —
16 —
17 —
18 —
19 —
20 —
21 —
22 —
23 —
24 —
25 —
26 —
27 —
28 —
29 —
30 —
31 —
32 —

With great interest we read the article by Schröder et al., to be published in a forthcoming issue of the Journal of Gastrointestinal Surgery, in which they investigated the potential value of resecting the azygos vein in transthoracic esophagectomy for esophageal cancer.¹ During (robot-assisted) thoracoscopic esophagectomy the trunk of the azygos vein is often preserved as the scopic ligation of the numerous intercostal veins is technically difficult and time-consuming.²⁻⁶ One may postulate that this may negatively affect the extent of lymph node harvesting or the circumferential radical (R0) resection rate.

Schröder et al. have therefore performed a prospective evaluation on the amount of lymph nodes surrounding the azygos vein in 92 patients with esophageal cancer having undergone open transthoracic esophagectomy with two-field lymphadenectomy.¹ Lymph nodes near the azygos vein were identified in 65% of patients and metastases in these lymph nodes were found in 8%. They therefore conclude that the dissection of the azygos vein should not be abandoned, irrespective of the surgical approach.

A comment should be made on the design of the study. As clearly shown in Figure 2 of their article, they dissected the azygos vein with the surrounding tissues sharply from the esophagus, which is not representative for (robot-assisted) thoracoscopic esophagectomy. In (robot-assisted) thoracoscopic esophagectomy, subsequent to the ligation of the azygos arch, the mediastinal dissection of the esophagus and surrounding tissues is performed sharply along the azygos trunk. In this way, the fatty tissue in between the esophagus and the azygos vein (including the lymph nodes of stations 108 and 110) as well as the thoracic duct are included in the esophageal resected specimen and are not left in situ when the trunk of the azygos vein is preserved.² The number of lymph nodes that will be left in situ with (robot-assisted) thoracoscopic esophagectomy will therefore be much less than stated in this article. Indeed, in our recently published cadaveric study in which we investigated an identical research question, a mean amount of only 0.67 lymph nodes were identified around the azygos vein using the thoracoscopic dissection method.⁷ Using this approach, in 60% of cadavers no lymph nodes near the azygos vein were detected at all.

With regard to the possible effect of azygos vein preservation on the radical resection

rate, we can refer to our first report on 21 esophageal cancer patients having undergone robot-assisted thoracoscopic esophagectomy. The R0 resection rate of 76% in that series is similar to that of open transthoracic esophagectomy.^{2,8} In our opinion, it is therefore justified to preserve the azygos trunk during (minimally invasive) transthoracic esophagectomy.

REFERENCES

1. Schroder W, Vallbohmer D, Bludau M, Banczyk A, Gutschow C, Holscher AH. The Resection of the Azygos Vein - Necessary or Redundant Extension of Transthoracic Esophagectomy? *J Gastrointest Surg* 2008; 12:1163-7.
2. van Hillegersberg R, Boone J, Draaisma WA, Broeders IA, Giezeman MJ, Borel Rinkes IHM. First experience with robot-assisted thoracoscopic esophagolymphadenectomy for esophageal cancer. *Surg Endosc* 2006; 20:1435-1439.
3. Luketich JD, Alvelo-Rivera M, Buenaventura PO et al. Minimally invasive esophagectomy: outcomes in 222 patients. *Ann Surg* 2003; 238:486-494.
4. Nguyen NT, Roberts P, Follette DM, Rivers R, Wolfe BM. Thoracoscopic and laparoscopic esophagectomy for benign and malignant disease: lessons learned from 46 consecutive procedures. *J Am Coll Surg* 2003; 197:902-913.
5. Osugi H, Takemura M, Higashino M et al. Video-assisted thoracoscopic esophagectomy and radical lymph node dissection for esophageal cancer. A series of 75 cases. *Surg Endosc* 2002; 16:1588-1593.
6. Watson DI, Davies N, Jamieson GG. Totally endoscopic Ivor Lewis esophagectomy. *Surg Endosc* 1999; 13:293-297.
7. Boone J, Schipper ME, Bleys RL, Borel Rinkes IHM, van Hillegersberg R. The effect of azygos vein preservation on mediastinal lymph node harvesting in thoracic esophagolymphadenectomy. *Dis Esophagus* 2008; 21:226-229.
8. Hulscher JB, van Sandick JW, de Boer AG et al. Extended transthoracic resection compared with limited transhiatal resection for adenocarcinoma of the esophagus. *N Engl J Med* 2002; 347:1662-1669.

1
2
3
4
5
6
7
8
9
10
11
12
13
14
15
16
17
18
19
20
21
22
23
24
25
26
27
28
29
30
31
32

18

List of abbreviatons

List of publications

Review committee

Dankwoord

Curriculum Vitae

Color figures

LIST OF ABBREVIATIONS

1		
2		
3	AC	adenocarcinoma
4	ASA	American Society of Anesthesiologists
5	CI	confidence interval
6	COX-2	cyclo-oxygenase-2
7	CRTx	chemoradiotherapy
8	CT	computed tomography
9	CTx	chemotherapy
10	EAC	esophageal adenocarcinoma
11	ECF	Epirubicin with Cisplatin and 5-FU
12	EGFR	endothelial growth factor receptor
13	ER	estrogen receptor
14	ESCC	esophageal squamous cell carcinoma
15	ESE-GEEMO	European Society of Esophagology - Group d'Etude Européen des
16		Maladies de l'Oesophage
17	EUS	endoscopic ultrasonography
18	FDG-PET	18F-fluorodeoxy-glucose positron emission tomography
19	5-FU	5-fluorouracil
20	GIST	gastrointestinal stromal tumor
21	ICU	intensive care unit
22	ISDE	international society for diseases of the esophagus
23	LND	lymph node dissection
24	MIE	minimally invasive esophagectomy
25	MRI	magnetic resonance imaging
26	mTOR	mammalian target of rapamycin
27	PET	positron emission tomography
28	PR	progesterone receptor
29	RACSE	routine aqueous contrast swallow examination
30	RTE	robot-assisted esophagectomy
31	RTx	radiotherapy
32	SCC	squamous cell carcinoma

SN	sentinel node	1
THE	transhiatal esophagectomy	2
TMA	tissue microarray	3
TNM	tumor node metastasis	4
TTE	transthoracic esophagectomy	5
US	ultrasonography	6
VEGF	vascular endothelial growth factor	7
		8
		9
		10
		11
		12
		13
		14
		15
		16
		17
		18
		19
		20
		21
		22
		23
		24
		25
		26
		27
		28
		29
		30
		31
		32

LIST OF PUBLICATIONS

1 —
2 —
3 — J Boone, IHM Borel Rinkes, DP Livestro, R van Hillegersberg. International survey on
4 — esophageal cancer: Part I Surgical techniques.

5 — *Diseases of the Esophagus, accepted for publication*

6 —
7 — J Boone, IHM Borel Rinkes, DP Livestro, R van Hillegersberg. International survey on
8 — esophageal cancer: Part II Staging and neoadjuvant therapy.

9 — *Diseases of the Esophagus, accepted for publication*

10 —
11 — J Boone, R van Hillegersberg. The azygos vein: to resect or not?

12 — *Journal of Gastrointestinal Surgery; accepted for publication*

13 —
14 — J Boone, FJW Ten Kate, GJA Offerhaus, PJ van Diest, IHM Borel Rinkes, R van Hillegersberg.
15 — mTOR in esophageal squamous cell carcinoma: a potential target for therapy?

16 — *Journal of Clinical Pathology 2008;61:909-13.*

17 —
18 — J Boone, IHM Borel Rinkes, MS van Leeuwen, R van Hillegersberg. Value of routine aqueous
19 — contrast swallow examination after esophagectomy to detect anastomotic leakage.

20 — *ANZ Journal of Surgery 2008; 78:784-90.*

21 —
22 — J Boone, R van Hillegersberg, PJ van Diest, GJA Offerhaus, IHM Borel Rinkes, FJW ten Kate.
23 — Validation of tissue microarray technology in squamous cell carcinoma of the esophagus.

24 — *Virchows Archiv 2008;452(5):507-514.*

25 —
26 — J Boone, MEI Schipper, RLAW Bleys, IHM Borel Rinkes, R van Hillegersberg. The
27 — effect of azygos vein preservation on mediastinal lymph node harvesting in thoracic
28 — esophagolymphadenectomy.

29 — *Diseases of the Esophagus 2008;21(3):226-9.*

J Boone, WA Draaisma, MEI Schipper, IAMJ Broeders, IHM Borel Rinkes, R van Hillegersberg. Robot-assisted thoracoscopic esophagectomy for an upper esophageal leiomyoma. <i>Diseases of the Esophagus 2008;21(1):90-3.</i>	1 2 3 4 5
J Boone, IHM Borel Rinkes, R van Hillegersberg. Gastric conduit staple line after esophagectomy: to oversee or not? <i>Journal of Thoracic and Cardiovascular Surgery 2006; 132(6):1491-2.</i>	6 7 8 9
J Boone, IHM Borel Rinkes, IAMJ Broeders, R van Hillegersberg. Robotsystemen in de oncologische chirurgie. <i>Nederlands Tijdschrift voor Oncologie 2006;3:231-7.</i>	10 11 12 13
R van Hillegersberg, J Boone, WA Draaisma, IAMJ Broeders, MJMM Giezeman, IHM Borel Rinkes. First experience with robot-assisted thoracoscopic esophago-lymphadenectomy for esophageal cancer. <i>Surgical Endoscopy 2006;20(9):1435-9.</i>	14 15 16 17 18
J Boone, IHM Borel Rinkes, R van Hillegersberg. Transhiatal robot-assisted esophagectomy. <i>Surgical Endoscopy 2008;22(4):1139-40.</i>	19 20 21
J Boone, IHM Borel Rinkes, R van Hillegersberg. Robot-assisted thoracoscopic esophagolymphadenectomy for esophageal cancer. <i>Surgical Endoscopy 2007; 21(12):2342-3.</i>	22 23 24 25
J Boone, R van Hillegersberg. Familiaire maagkanker: diagnose en mogelijkheden voor screening. <i>Nederlands Tijdschrift voor Oncologie 2007;4:74.</i>	26 27 28 29 30 31 32

REVIEW COMMITTEE

Prof. dr. P.D. Siersema

Department of Gastroenterology and Hepatology
University Medical Center Utrecht

Prof. dr. G.J.A. Offerhaus

Department of Pathology
University Medical Center Utrecht

Prof. dr. J.J.B. van Lanschot

Department of Surgery
Erasmus Medical Center Rotterdam

Prof. dr. M.A. Cuesta

Department of Surgery
Free University Medical Center Amsterdam

Prof. dr. E.E. Voest

Department of Oncology
University Medical Center Utrecht

FURTHER MEMBERS OF THE OPPOSING COMMITTEE

Prof. dr. H. Obertop

Emeritus Professor in Surgery

Prof. dr. W.P.Th.M. Mali

Department of Radiology
University Medical Center Utrecht

DANKWOORD

Graag wil ik een ieder danken die op enigerlei wijze heeft bijgedragen aan de totstandkoming van dit proefschrift. Een aantal personen wil ik in het bijzonder danken:

Mijn eerste promotor, **Prof. dr. R. van Hillegersberg**, beste Richard. Fantastisch om je nu als Professor aan te mogen spreken! Ik ben vereerd dat ik als eerste onderzoeker bij jou, in de hoedanigheid van promotor, mag promoveren. Dit is voor mij de kroon op onze samenwerking! Samen hebben wij in het UMC Utrecht de wetenschappelijke onderzoekslijn Slokdarmkanker opgezet. Het bedenken, opstarten, uitvoeren en opschrijven van de vele studies is niet altijd even makkelijk geweest. Ik ben dan ook ontzettend trots dat we met deze studies ons ziekenhuis op ons onderzoeksgebied internationaal op de kaart hebben weten te zetten. Dit is mede het resultaat van jouw aanstekelijke gedrevenheid, enthousiasme en positiviteit. Ik ben je enorm dankbaar voor wat je mij in de afgelopen jaren allemaal hebt geleerd, zowel op wetenschappelijk als op medisch en organisatorisch gebied. Daarnaast wil ik je danken voor je vertrouwen in mij. Ondanks dat mijn carrière zich nu verder voortzet in de Radiologie in het AMC hoop ik in de toekomst nog vaak met je te mogen samenwerken en veel van je te mogen leren!

Prof. dr. I.H.M. Borel Rinkes, beste Inne. Jouw scherpe en kritische blik is van grote waarde geweest voor dit proefschrift. Ik ben je zeer dankbaar voor de mogelijkheden die jij mij de afgelopen jaren hebt geboden en voor het vertrouwen dat je in mij hebt gehad.

Prof. dr. F.J.W. ten Kate, beste Professor. Wat was (en ben) ik verheugd over uw komst en die van Professor Offerhaus, internationaal erkende autoriteiten op het gebied van de gastro-intestinale pathologie, naar het UMC Utrecht! Het is voor mij een ontzettend grote eer om onder uw begeleiding promotieonderzoek te hebben mogen verrichten. Veel dank voor alle tijd die u hebt vrijgemaakt voor het onderzoek en veel dank voor alles wat u mij heeft geleerd!

De leden van de beoordelingscommissie, **Prof. dr. P.D. Siersema**, **Prof. dr. G.J.A. Offerhaus**, **Prof. dr. J.J.B. van Lanschot**, **Prof.dr. M.A. Cuesta** en **Prof. dr. E.E.**

—	1
—	2
—	3
—	4
—	5
—	6
—	7
—	8
—	9
—	10
—	11
—	12
—	13
—	14
—	15
—	16
—	17
—	18
—	19
—	20
—	21
—	22
—	23
—	24
—	25
—	26
—	27
—	28
—	29
—	30
—	31
—	32

1 _____
2 _____
3 _____
4 _____
5 _____
6 _____
7 _____
8 _____
9 _____
10 _____
11 _____
12 _____
13 _____
14 _____
15 _____
16 _____
17 _____
18 _____
19 _____
20 _____
21 _____
22 _____
23 _____
24 _____
25 _____
26 _____
27 _____
28 _____
29 _____
30 _____
31 _____
32 _____

Voest, ben ik bijzonder erkentelijk voor hun bereidheid het proefschrift op zijn wetenschappelijke waarde te beoordelen. **Prof. dr. H. Obertop** en **Prof. dr. W.P.Th. M. Mali** wil ik danken voor hun bereidheid zitting te nemen in de promotiecommissie.

De leden van de beoordelingscommissie van het Alexandre Suerman stipendium en de leden van de Raad van Bestuur van het UMC Utrecht ben ik bijzonder dankbaar voor het mij toekennen van het stipendium. Zonder deze beurs was financiering van mijn promotie-traject een lastige opgave geweest. Mijn intervisie-groepsgenoten **Anne, Kim, Mirjam** en **Maurits** wil ik danken voor het delen van hun ervaringen en voor het geven van feedback. Succes met het afronden van jullie proefschriften!

Daan Livestro, wat ben je toch een held! Je bouwt fantastische Acces-databases met de meest uitgebreide gadgets zonder dat het je enige moeite lijkt te kosten. Zonder jou was de internationale enquête nooit mogelijk geweest. Dank voor alles! Veel succes en geluk gewenst in Philadelphia.

I would like to thank all **responders** of the International Survey on Esophageal Cancer for their appreciated participation and for sharing their expertise.

Dr. S.G. Elias, beste Sjoerd, ontzettend bedankt voor je statistische hulp bij de internationale enquête. **Maria Schipper** en **Cas Kruitwagen** van het Centrum voor Biostatistiek wil ik danken voor hun statistische adviezen bij de hoofdstukken 5 en 13.

Prof. dr. I.A.M.J. Broeders, beste Ivo. Mede dankzij jou beschikte het UMCU als eerste ziekenhuis in Nederland over een operatierobot en kon de basis voor deel 1 van dit proefschrift worden gelegd. **Dr. A. Hennipman**, een substantieel deel van dit proefschrift heeft betrekking op de operaties die u in het verleden heeft verricht. Dank voor alle gedetailleerde informatie over deze operaties en patiënten. **Dr. E.J. Hazebroek**, beste Erik. Fijn dat nog een ervaren scopisch chirurg zich aan het operatieteam heeft toegevoegd. Wanneer spring jij achter de console? **Romy** en **Mariëlle**, dank voor het vinden van de gaatjes in de overvolle agenda's, voor jullie belangstelling voor mijn onderzoek en voor alle gezelligheid! **Carlo Schippers** wil ik danken voor het bijhouden

van de database en voor het informeren van alle patiënten over de vele klinische studies. **Sylvia van der Horst**, succes met je opleiding tot physician assistant. Jammer dat we maar zo kort hebben samengewerkt. Alle **OK-assistenten**, in het bijzonder **Karen, Ada, Signe, Gertine, Kim** en **Nynke**.

Maurice Giezeman, dank voor je hulp bij de eerste robotoperaties en bij het opstarten van de COCTAIL-studie (resultaten volgen spoedig). Dé anaesthetist van het UMCU, **Geert-Jan Cromheecke**. Geweldig dat je altijd bereid bent om bij de slokdarmoperaties aanwezig te zijn.

Dr. R.L.A.W. Bleys, beste Ronald, dank voor de prettige samenwerking. Geweldig dat je de mogelijkheid hebt geboden de dag voorafgaand aan de verdediging een hands-on symposium te organiseren! De heren **Willem van Wolferen** en **Simon Plomp** wil ik danken voor hun bijdrage aan de anatomische studie. Het was een bijzondere ervaring om op de snijzaal slokdarmoperaties te verrichten met klassieke muziek op de achtergrond.

Prof. dr. G.J.A. Offerhaus, beste Professor. Veel dank voor uw enorme betrokkenheid bij het onderzoek en voor alle mogelijkheden die u mij hebt geboden. **Prof. dr. P.J. van Diest**, beste Paul. Ontzettend veel dank voor je bereidheid het TMA-project op te starten en voor je verdere faciliterende rol in het onderzoek. **Marguerite Schipper** wil ik danken voor haar grote bijdrage aan dit proefschrift; fijn dat ik altijd bij je terecht kon met een opzet voor een nieuw project! **Petra van der Groep**, dank dat je mij de beginselen van de immunohistochemie hebt aangeleerd. Veel succes met het afronden van jouw proefschrift. **Alle medewerkers** van het **immunohistochemie-lab**, in het bijzonder **Sabrina, Domenico, Jan, Petra, Helga, Cathy** en **John**, wil ik danken voor hun gastvrijheid op het lab en voor hun hulp als ik even niet meer wist hoe het ook alweer moest. **Folkert**, ontzettend bedankt voor je hulp bij het maken van de TMA en voor het (2x!) uitvoeren van de COX-2 kleuring. De **arts-assistenten** van de **afdeling Pathologie** voor het nauwkeurig uitsnijden van de SOEF-preparaten. **Aad** en **Frank**, dank voor de altijd snelle levering van de vele coupes uit het archief. **Marjon, Willy** en **Irma** voor het maken van alle afspraken.

—	1
—	2
—	3
—	4
—	5
—	6
—	7
—	8
—	9
—	10
—	11
—	12
—	13
—	14
—	15
—	16
—	17
—	18
—	19
—	20
—	21
—	22
—	23
—	24
—	25
—	26
—	27
—	28
—	29
—	30
—	31
—	32

1 —————
 2 —————
 3 —————
 4 —————
 5 —————
 6 —————
 7 —————
 8 —————
 9 —————
 10 —————
 11 —————
 12 —————
 13 —————
 14 —————
 15 —————
 16 —————
 17 —————
 18 —————
 19 —————
 20 —————
 21 —————
 22 —————
 23 —————
 24 —————
 25 —————
 26 —————
 27 —————
 28 —————
 29 —————
 30 —————
 31 —————
 32 —————

Pieter Lubbert wil ik danken voor het bedenken, schrijven en indienen van het schildwachtklier-protocol. **Frank Vleggaar, Thijs Schwartz** en **Bas Oldenburg**, dank voor het verrichten van alle gastroscopieën voor deze studie. **Monique Hobbelink** en **Hans van Isselt** voor hun enorme bijdrage aan deze studie. Ik waardeer het zeer dat jullie ondanks alle drukte op jullie afdeling toch tijd hebben vrijgemaakt voor de SOEF-patiënten.

Dr. M.S. van Leeuwen, beste Maarten. Hartelijk dank voor je bijdrage aan hoofdstuk 13 en voor de back-up tijdens de Radiologendagen.

Alle **stafleden en arts-assistenten** van de **Afdeling Heelkunde** van het UMC Utrecht wil ik danken voor hun interesse in mijn onderzoek en voor de vele gezellige momenten tijdens de borrels, lunches, de chirurgencup en de skireizen.

Dr. J.D.W. van der Bilt en **Dr. L.M. Veenendaal**, lieve Jarrie en Lies! Jullie hebben altijd voor mij (en voor vele andere onderzoekers) klaar gestaan, ondanks dat jullie zelf enorm druk waren met jullie eigen proefschriften. Veel dank daarvoor! Jar, het briljante idee van een internationale enquête kwam van jou. Lief van je dat je mij een vergelijkbare studie hebt gegund. **Dr. W.A. Draaisma**, beste Werner. Dank voor alle hulp bij het begin van dit project en veel dank dat je mij de 2^e auteursplek van het robotartikel hebt toegekend! **Dr. J.P. Ruurda**, beste Jelle, robotonderzoeker No. 1! Fijn dat we sinds jouw terugkeer in het UMCU weer van je (robot)expertise gebruik kunnen en mogen maken! **Koen van Dongen**, succes met de laatste loodjes van jouw onderzoek!

Collega-onderzoekers van **Isengard**. Wat een fijne tijd heb ik met jullie gehad in de SEH-toren! Mijn roomies **Nikol** en **Eline**, hoge toppen en diepe dalen hebben we samen gedeeld. Ik wil jullie enorm danken voor jullie steun, jullie gezelligheid en voor de vele engelse synoniemen... Veel succes met jullie promoties! **Dr. F. Hietbrink**, beste Falco, je was altijd bereid om even te helpen met statistiek, reference manager en alle andere onderzoeksprikelen; veel dank daarvoor! Fijn om je zo te zien genieten in de kliniek. **Stijn**, wat zal ik alle foute grappen en okkernoten gaan missen! Nog even doorzetten en dan is jouw boek ook binnenkort af! **Maarten**, thanks voor alle tips & tricks in het lab.

Immuunhistochemie is inderdaad voor koningen! Bob (R. Jeremy), veel succes met het afronden van je proefschrift naast je opleiding. Tjaakje , knap van je dat je het zo lang op de mannenkamer hebt volgehouden... Wil je goed voor mijn plantje zorgen?	1
	2
	3
	4
Collega's van de Tower of Sin: Onno, Menno, Winan en Frederik . Tijdens de lever-researchbesprekingen was ik als slokdarmkanker-onderzoeker een beetje een vreemde eend in de bijt. Desalniettemin waren jullie altijd bereid adviezen te geven over mijn onderzoek. Dank daarvoor!	5
	6
	7
	8
	9
Collega-onderzoekers van de traumatologie, vaatchirurgie, oncologische chirurgie en gastro-intestinale chirurgie: Janesh, Joris, Dennis, Robbert, Charlotte, Olaf, Hjalmar, Joffrey, Wouter(s), Ralph, Erik, Daphne en Rian . Succes met jullie promoties.	10
	11
	12
	13
Wouter Moojen wil ik danken voor zijn (creatieve) bijdrage aan hoofdstuk 6. Succes met je opleiding neurochirurgie!! Roy Verhage , ontzettend veel succes en plezier met de onderzoekslijn. Ik had me geen betere opvolger kunnen wensen!	14
	15
	16
	17
De slokdarmkanker-onderzoekers uit de andere Nederlandse academische centra: Jikke Omloo, Sjoerd Lagarde, Mark van Heijl, Jurjen Boonstra, Brechtje Grotenhuis, Vera Rempe-Sorm, Linetta Koppert, Ewout Courrech Staal, Joris Scheepers . Dank voor alle gezellige momenten tijdens de vele (inter)nationale congressen!	18
	19
	20
	21
	22
Jennifer , veel succes in San Francisco. Jammer dat je er de 29 ^e en 30 ^e niet bij kunt zijn!	23
Femke , wat een bewondering heb ik voor jou! Het merendeel van je onderzoek heb je in het buitenland verricht. Bedankt voor je steun en belangstelling vanuit Zweden. Gaan we snel weer een hapje eten in het hippe Amsterdam? Liselotte , marathon-ster! Dank voor je vriendschap en voor je hulp bij mijn sollicitatie!	24
	25
	26
	27
	28
Schaerweijde Dames 9 , bedankt voor de vele sportieve en gezellige momenten!	29
	30
	31
	32

1 _____
2 _____
3 _____
4 _____
5 _____
6 _____
7 _____
8 _____
9 _____
10 _____
11 _____
12 _____
13 _____
14 _____
15 _____
16 _____
17 _____
18 _____
19 _____
20 _____
21 _____
22 _____
23 _____
24 _____
25 _____
26 _____
27 _____
28 _____
29 _____
30 _____
31 _____
32 _____

Mijn **jaarclubgenootjes (en vriendjes)**, ontzettend lief dat jullie altijd zo hebben meegeleefd. Sorry dat ik de afgelopen weken te druk was om af te spreken... **Maartje, Merel (& Vincent)** en **Wieteke**, nog even en jullie staan hier! Veel succes nog met schrijven.

Bram, Toos, Femke en **Tim**, wat is het toch altijd heerlijk om bij jullie te borrelen en even het onderzoek achter me te laten. Veel dank voor de brabantse gezelligheid, de hulp bij het vinden van sponsoring en niet te vergeten voor de goede adviezen!

Lieve **Lisanne**, als oud-huisgenootjes kennen we elkaar door en door. Met jou is het altijd heerlijk ontspannen, al shoppend in Amsterdam of al zonnend op Rhodos. Wat ben ik blij dat je tijdens de promotie naast me staat! Veel geluk met Ties in jullie nieuwe huis!

Lieve **Elfi**, vriendinnetje vanaf dag 1 van de studie. Ontzettend bedankt voor je vriendschap, je adviezen en je steun in de afgelopen 8 jaar. Ik ben enorm trots dat je mijn paranimf wilt zijn! Friends forever! Gaan we binnenkort weer naar HP?

Lianne, Ingrid, Fred en **Rob**. Ondanks dat we (relatief) ver van elkaar vandaan wonen, merk ik daar gelukkig heel weinig van. Bedankt voor jullie interesse, jullie betrokkenheid en voor de vele gezellige weekendjes Zeeland. Fijn dat jullie er altijd voor me zijn!

Lieve **Pap** en **Mam**, dit proefschrift is niet voor niets aan jullie opgedragen. Ik ben jullie ontzettend dankbaar voor jullie onvoorwaardelijke steun, vertrouwen en liefde. Zonder jullie stimulerende en liefdevolle opvoeding was ik nooit zover gekomen. Nogmaals bedankt, pap, dat je me helemaal naar Innsbruck hebt gebracht!

Liefste **Bas(ke)**. Heel veel dank voor je enorme steun, je relativeringsvermogen, je humor, maar bovenal je liefde. Kus!!

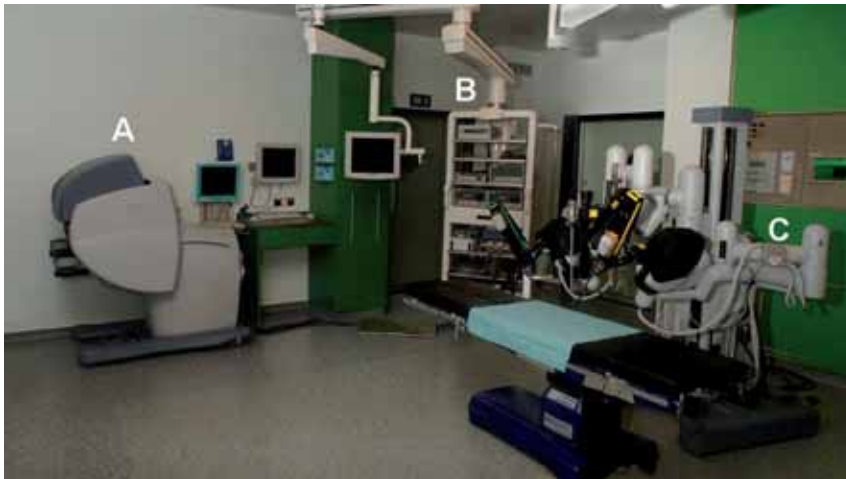
CURRICULUM VITAE

Judith Boone werd geboren op 29 augustus 1982 in Middelburg. In 2000 behaalde zij haar Gymnasium-beta diploma aan de Nehalennia Stedelijke Scholengemeenschap te Middelburg. Datzelfde jaar werd zij toegelaten tot de opleiding Geneeskunde aan de Universiteit Utrecht. In het 3^e studiejaar (2003) startte zij in het Universitair Medisch Centrum Utrecht de wetenschappelijke onderzoekslijn 'Slokdarmkanker' op onder begeleiding van Prof. dr. R. van Hillegersberg en Prof. dr. I.H.M. Borel Rinkes (Afdeling Heelkunde). In de periode 2004-2006 combineerde zij haar co-schappen met het verrichten van wetenschappelijk onderzoek. De studies uitgevoerd in deze periode vormden de basis van haar promotietraject. In 2006 ontving zij van de Raad van Bestuur van het UMC Utrecht het Alexandre Suermann stipendium. Deze beurs maakte het voor haar mogelijk om na het behalen van haar arts-examen in oktober 2006 full-time aan haar promotie-onderzoek te werken. Op 1 februari 2009 zal zij starten met de opleiding tot Radioloog in het Academisch Medisch Centrum te Amsterdam (Opleider dr. O.M. van Delden).

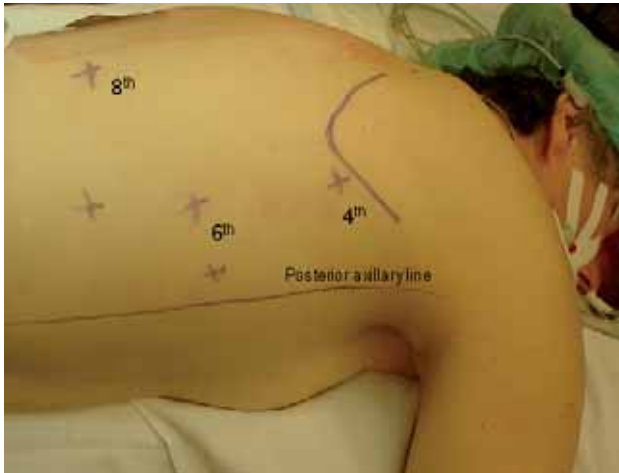
—	1
—	2
—	3
—	4
—	5
—	6
—	7
—	8
—	9
—	10
—	11
—	12
—	13
—	14
—	15
—	16
—	17
—	18
—	19
—	20
—	21
—	22
—	23
—	24
—	25
—	26
—	27
—	28
—	29
—	30
—	31
—	32

COLOR FIGURES

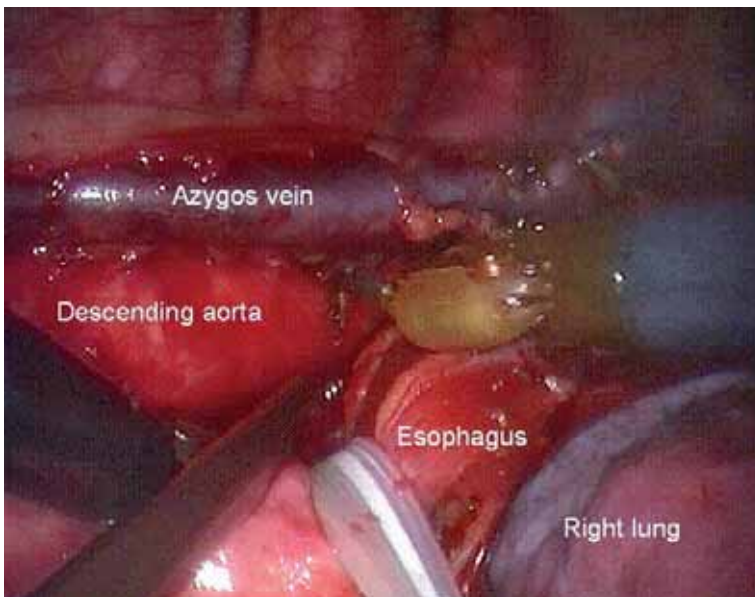
Chapter 1 - Figure 1



Chapter 3 - Figure 2

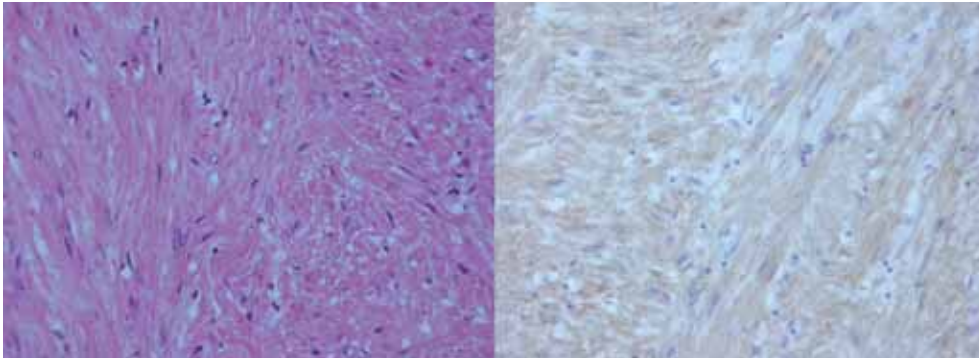


Chapter 3 - Figure 3



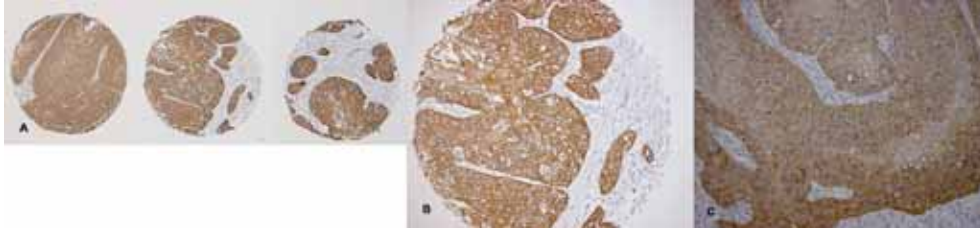
- 1
- 2
- 3
- 4
- 5
- 6
- 7
- 8
- 9
- 10
- 11
- 12
- 13
- 14
- 15
- 16
- 17
- 18
- 19
- 20
- 21
- 22
- 23
- 24
- 25
- 26
- 27
- 28
- 29
- 30
- 31
- 32

Chapter 7 - Figure 5

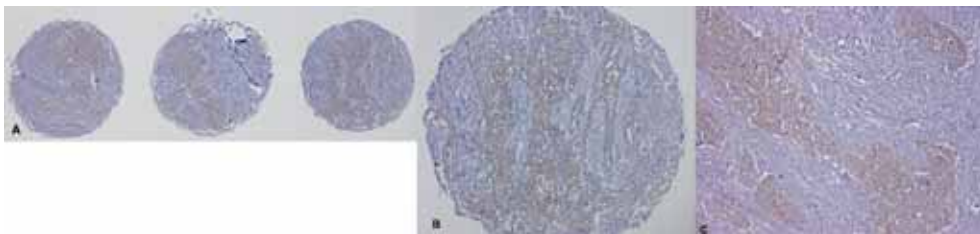


- 1 —
- 2 —
- 3 —
- 4 —
- 5 —
- 6 —
- 7 —
- 8 —
- 9 —
- 10 —
- 11 —
- 12 —
- 13 —
- 14 —
- 15 —
- 16 —
- 17 —
- 18 —
- 19 —
- 20 —
- 21 —
- 22 —
- 23 —
- 24 —
- 25 —
- 26 —
- 27 —
- 28 —
- 29 —
- 30 —
- 31 —
- 32 —

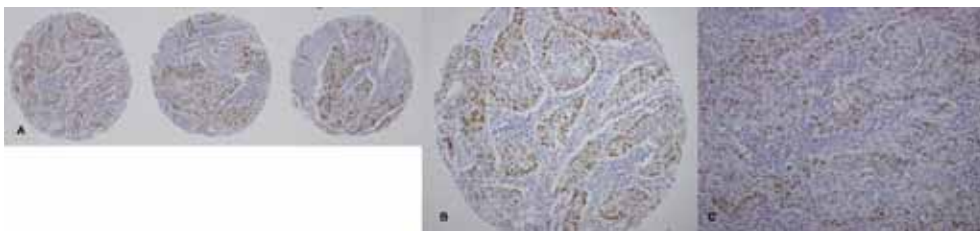
Chapter 8 - Figure 1



Chapter 8- Figure 2

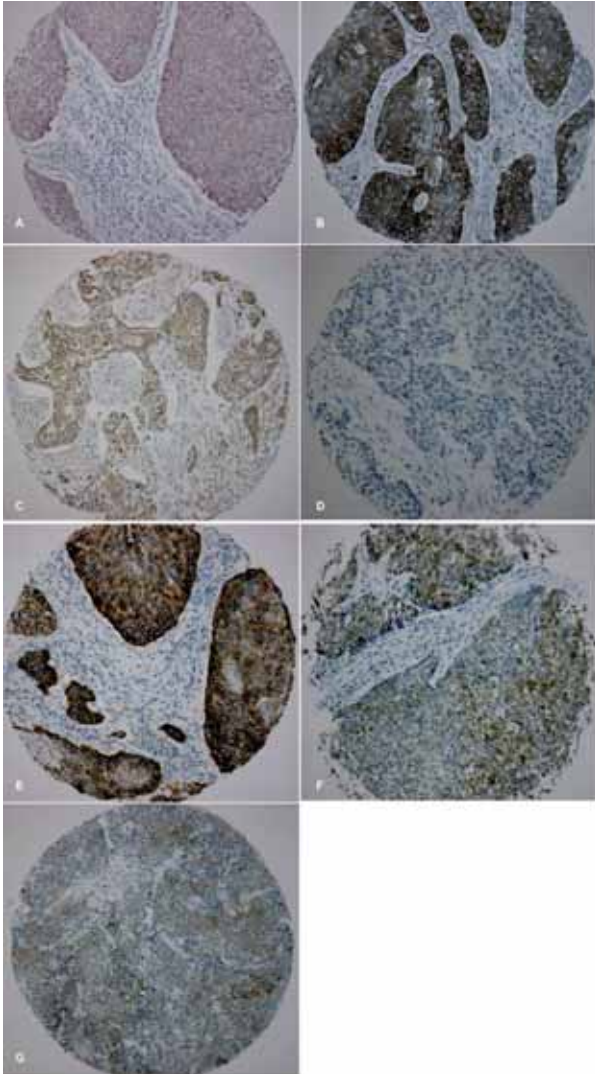


Chapter 8 - Figure 3



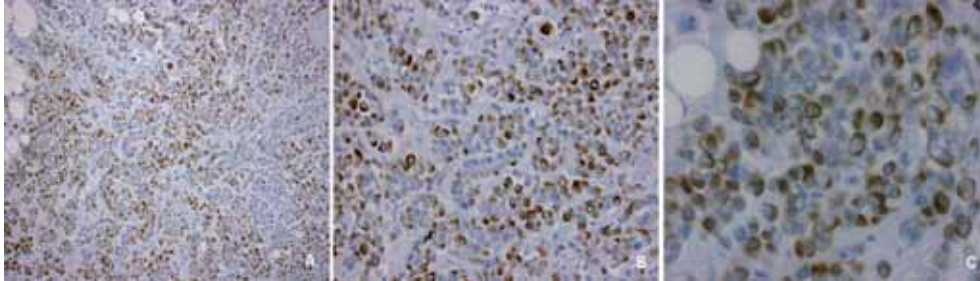
- 1
- 2
- 3
- 4
- 5
- 6
- 7
- 8
- 9
- 10
- 11
- 12
- 13
- 14
- 15
- 16
- 17
- 18
- 19
- 20
- 21
- 22
- 23
- 24
- 25
- 26
- 27
- 28
- 29
- 30
- 31
- 32

Chapter 9 - Figure 1

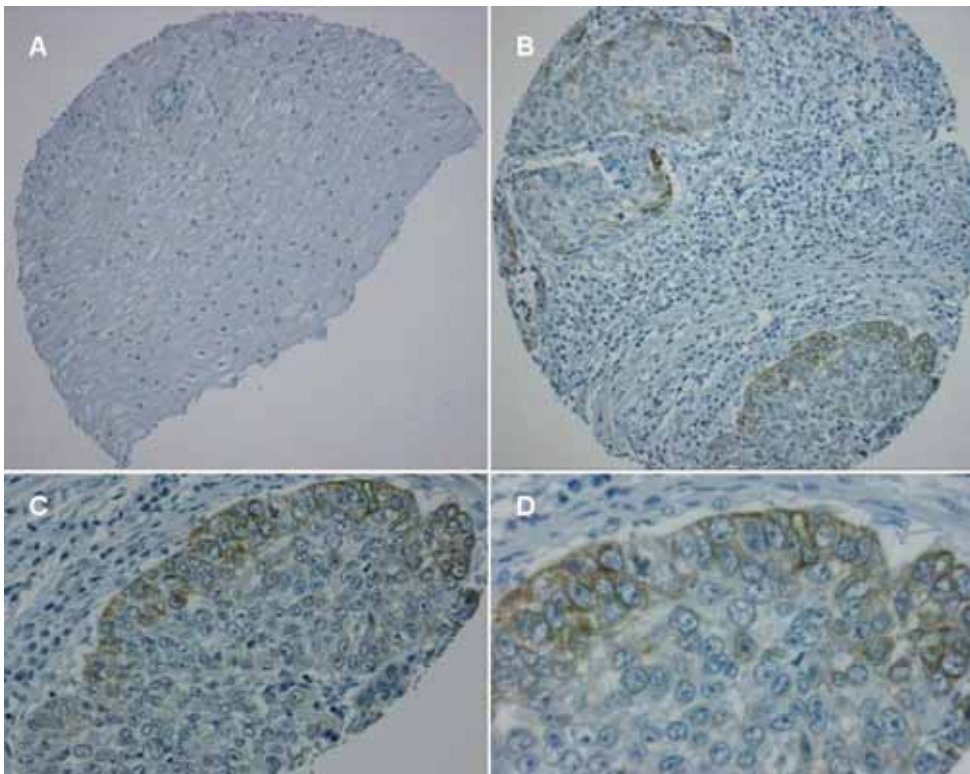


- 1 —
- 2 —
- 3 —
- 4 —
- 5 —
- 6 —
- 7 —
- 8 —
- 9 —
- 10 —
- 11 —
- 12 —
- 13 —
- 14 —
- 15 —
- 16 —
- 17 —
- 18 —
- 19 —
- 20 —
- 21 —
- 22 —
- 23 —
- 24 —
- 25 —
- 26 —
- 27 —
- 28 —
- 29 —
- 30 —
- 31 —
- 32 —

Chapter 10 - Figure 1

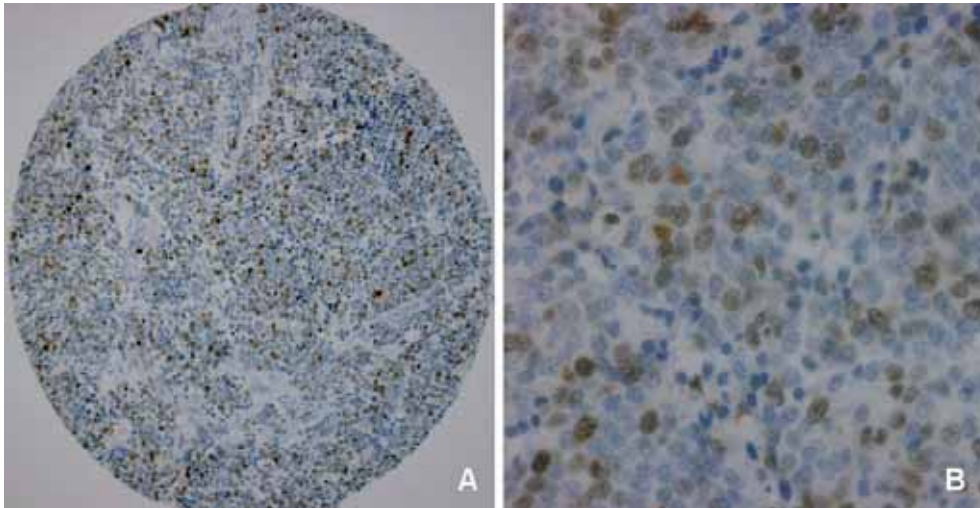


Chapter 10 - Figure 2

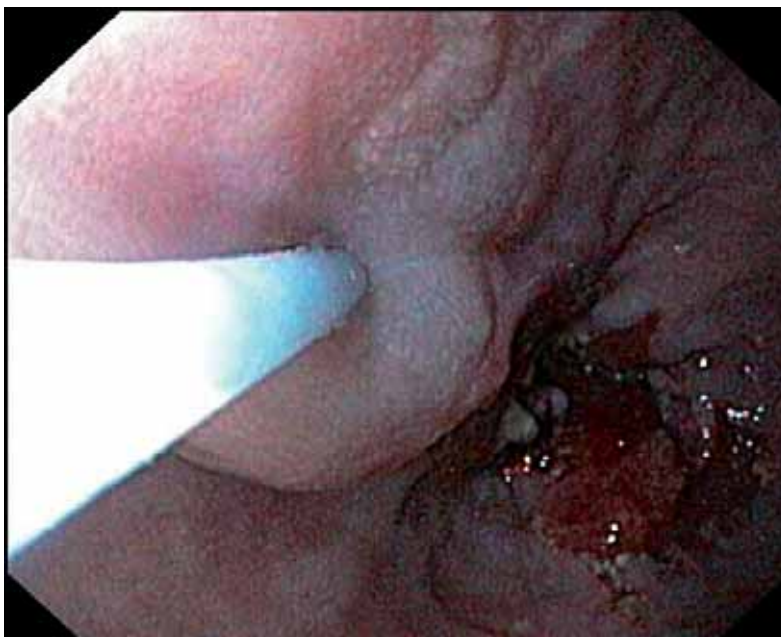

- 1
- 2
- 3
- 4
- 5
- 6
- 7
- 8
- 9
- 10
- 11
- 12
- 13
- 14
- 15
- 16
- 17
- 18
- 19
- 20
- 21
- 22
- 23
- 24
- 25
- 26
- 27
- 28
- 29
- 30
- 31
- 32

Chapter 10 - Figure 3



Chapter 12 - Figure 1



- 1
- 2
- 3
- 4
- 5
- 6
- 7
- 8
- 9
- 10
- 11
- 12
- 13
- 14
- 15
- 16
- 17
- 18
- 19
- 20
- 21
- 22
- 23
- 24
- 25
- 26
- 27
- 28
- 29
- 30
- 31
- 32

