Muscular Ventricular Septal Defects: A Reappraisal of the Anatomy

ARNOLD C. G. WENINK, MD
ARENTJE OPPENHEIMER-DEKKER, MD
ANDRÉ J. MOULAERT, MD

Leiden and Utrecht, The Netherlands

Among 79 autopsy specimens of hearts with an isolated ventricular septal defect, there were 29 cases of muscular defect. Among 60 hearts with complete transposition of the great arteries and a ventricular septal defect, there were 13 cases with a muscular defect. All muscular defects could be classified in three different types, based on the specific pathologic anatomy of the ventricular septum. The central and posterior defects were usually large and single, the marginal defects were frequently small and multiple. In hearts with transposition, central muscular defects were extremely rare, whereas these defects were by far the most frequent muscular defects in isolated ventricular septal defect. Alternatively, the posterior type was more common in cases of transposition. Marginal muscular defects were rare in both groups of malformations.

In a study of hearts with complete transposition of the great arteries,[1–5] we encountered many with an abnormal left ventricular morphology that had not been described before. We observed that many hearts with transposition exhibited a so-called posteromedial muscle, whereas normal hearts did not, and we considered this finding relevant to the morphogenesis of transposition.[5] The posteromedial muscle is a distinct, often pyramidal, muscular band whose apex is situated in the corner where the membranous septum and mitral and arterial valves meet. From there, it courses toward the apex of the heart, lying in the groove between the septum and the posterior left ventricular wall (Fig. 1, top and 2, top).

A ventricular septal defect may be present between the posteromedial muscle and the rest of the ventricular septum, and in such cases the posteromedial muscle is still more obvious. We consider this particular defect, with its close relation with the posteromedial muscle, a distinct pathologic entity. To assess whether this entity is present in hearts with normally connected arteries, we studied all hearts in our collection with isolated ventricular septal defect. We also restudied our hearts with transposition of the great arteries with ventricular septal defect and concluded that three types of muscular defect occur, but with a different frequency, in both types of hearts.

Previous reports[6–11] have not classified muscular defects very strictly or categorized them into distinct subtypes. Only Edwards et al.[12] distinguished a defect in the basal portion of the septum posteriorly that we think is the type mentioned earlier. However, the majority of our hearts meet strict anatomic descriptions.

Material and Methods

Seventy-nine hearts with an isolated ventricular septal defect or defects were studied. These hearts had no additional abnormalities other than extracardiac malformations such as aortic arch anomalies or venous malformations. The 79 hearts were compared with 60 hearts with complete transposition of the great arteries with ventricular septal defect. Hearts with straddling atrioventricular

From the Department of Anatomy and Embryology, State University of Leiden, and from the Department of Pediatric Cardiology, Wilhelmina Children's Hospital, Utrecht, The Netherlands.
Manuscript received July 11, 1978; revised manuscript received September 12, 1978, accepted September 13, 1978.
Address for reprints: A. C. G. Wenink, MD, Anatomisch-Embryologisch Laboratorium, Wassenaarseweg 62, Leiden, The Netherlands.

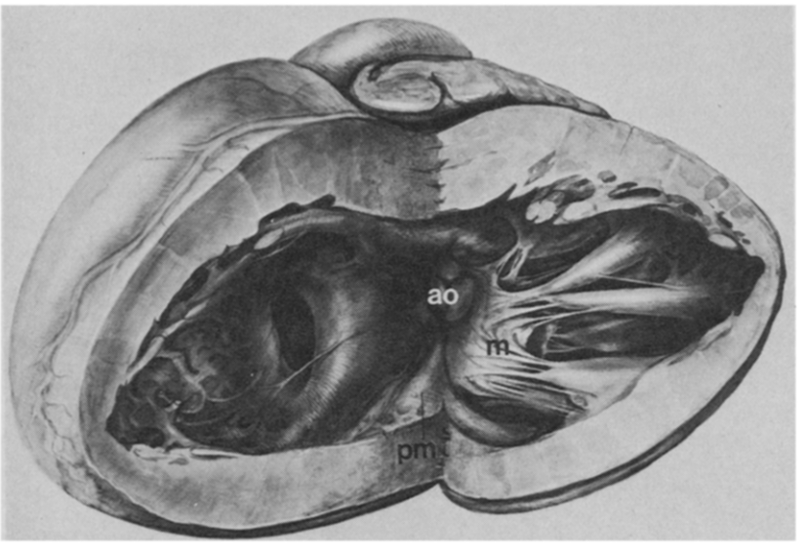

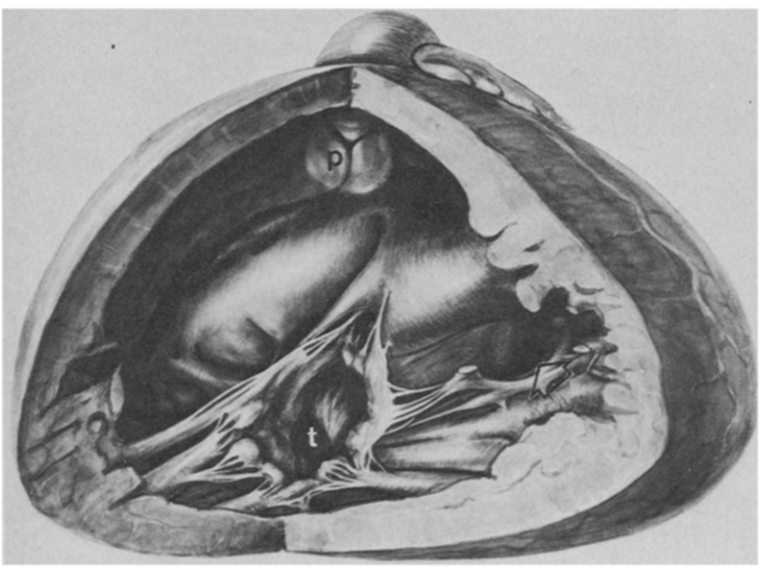

FIGURE 1. Central muscular ventricular septal defect, **Top,** left ventricular view. A posteromedial muscle (pm) is present. ao = aortic orifice; m = mitral valve. **Bottom,** right ventricular view (**arrow** points to defect). p = pulmonary orifice; t = tricuspid orifice.

TABLE I

Type of Muscular Defect in 29 Hearts With Isolated Muscular Ventricular Septal Defect

Type	no.	
I. Central muscular defects		
Central only	14	
Central + outflow	3	
Central + outflow + marginal*	1	
Total		18
II. Posterior muscular defects		
Posterior only	3	
Posterior + outflow	1	
Posterior + marginal*	1	
Total		5
III. Marginal defects		
Marginal only	4	
Marginal + outflow	2	
Marginal + outflow + central*	1	
Marginal + posterior*	1	
Total		8
Total number*		31

* Because of a combination of defects, two cases were counted twice.

or pulmonary valves were not included. In this paper, we describe only hearts with muscular ventricular septal defects, the other types of defects present in these hearts having been described elsewhere.[4,13] We define a muscular defect as one entirely bordered by myocardium.

Results

Isolated Ventricular Septal Defect

Of 79 hearts with isolated ventricular septal defects, 29 presented with one or more muscular ventricular septal defects. These could be grouped into three distinct categories (Table I).

I. Central muscular ventricular septal defect (Fig. 1): There were 18 hearts with this anomaly. Characteristically, when viewed from the right side, this defect is at a considerable distance from the tricuspid valve. It is always posterior to the trabecula septomarginalis. This structure is defined as the prominent myocardial band that separates the inflow and outflow regions of the right ventricle. Its basal part, originating just below the pulmonary orifice, adheres to the septum. Its

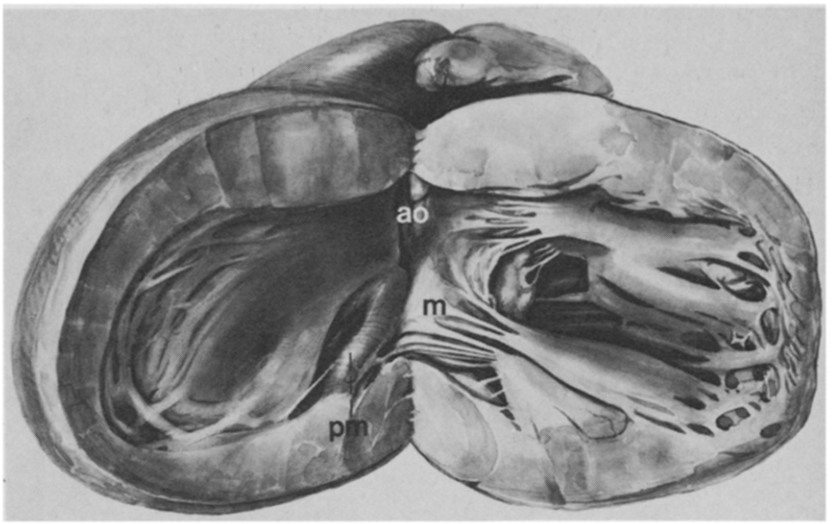

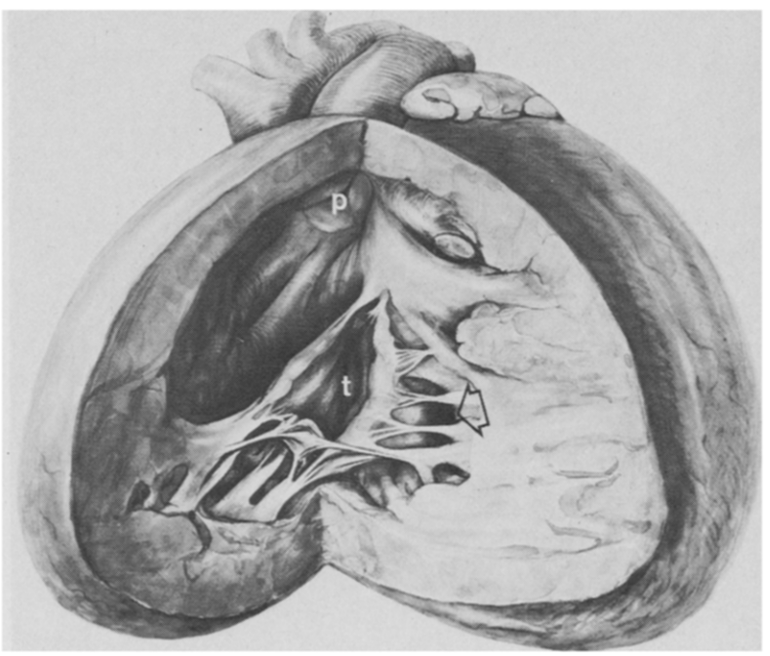

FIGURE 2. Posterior muscular ventricular septal defect. **Top,** left ventricular view. Note that the slit-like opening is bordered by the posteromedial muscle (pm). ao = aortic orifice; m = mitral valve. **Bottom,** right ventricular view. The defect (**arrow**) is relatively close to the tricuspid orifice (t) (compare Fig. 1, **bottom**). p = pulmonary orifice.

apical part, bearing the anterior papillary muscle, connects the septal and parietal walls and lies freely in the ventricular cavity. Commonly, the defect is partly hidden by some small overlying trabeculae, which might give the impression that there are multiple defects. From the left, however, it can nearly always be recognized as a single rounded-off defect that is well away from both the anterior and posterior left ventricular walls. Its basal boundary is formed by a solid and glabrous part of the ventricular septum, which is concave toward the apex. The posterior portion of this septal structure reaches far into the apex, from where it curves superiorly and anteriorly, finally disappearing behind (that is, to the right of) broad bundles of fine trabeculae that curve along the anterior ventricular wall. These trabeculae are part of the apical border of the defect, formed by a trabeculated portion of the septum. This portion is concave toward the base of the heart, and it is contiguous with the apical extremity of the solid basal portion of the septum. From this portion, it curves anteriorly and superiorly to spread along the anterior ventricular wall. Its trabeculae lie upon the anterior extremity of the solid and glabrous septal portion and terminate just below the aortic orifice.

Thus, seen from the left, the defect is oval-shaped and bordered by two crescent-shaped septal structures, obliquely fitted to each other. The distance of the defect from the apex varied conspicuously. In the presence of a broad glabrous septal portion and a small trabeculated part, the defect was located near the apex. Alternatively, the defect was near the base of the heart whenever the trabeculated part was large and the solid portion only small. In three cases, the trabeculated septal portion gave off some very tiny trabeculae that partly crossed the defect on its left side, so as to produce a possible appearance of multiplicity, but never warranting the name of "swiss cheese." Four of these 18 hearts had additional de-

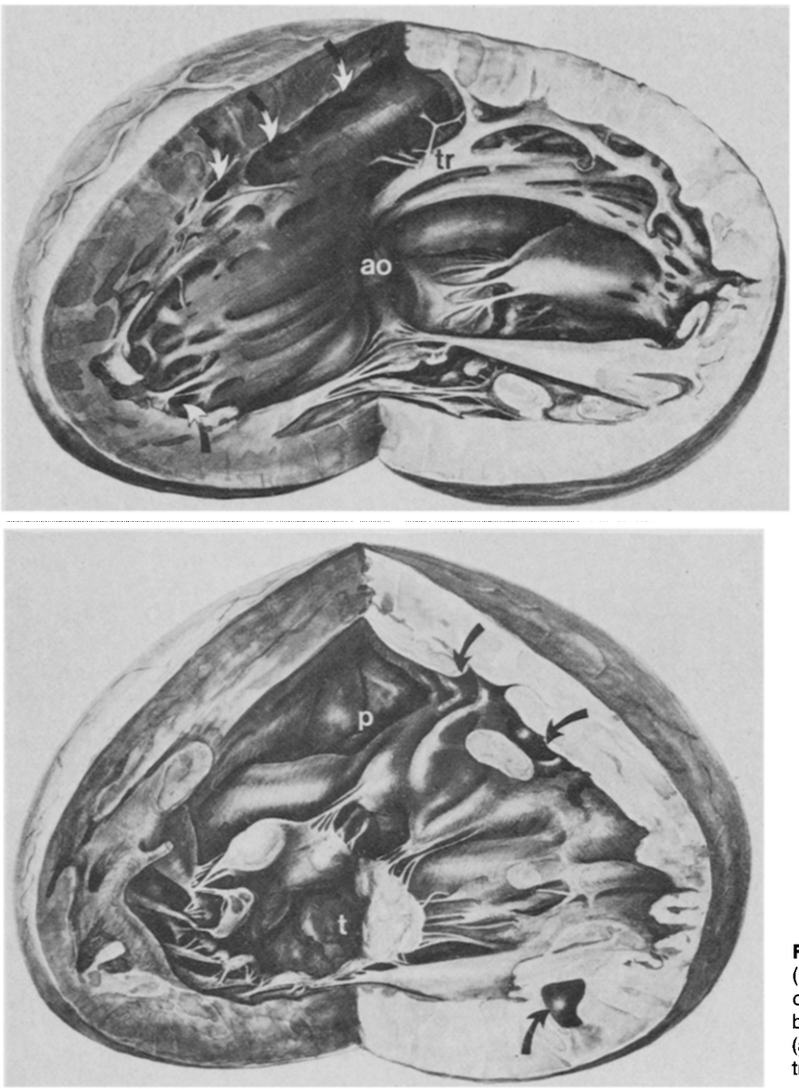

FIGURE 3. Marginal muscular ventricular septal defects (**arrows**). **Top,** left ventricular view. In this specimen the architecture is further disturbed by the presence of thick trabeculae (tr) on the anterior ventricular wall. The aortic orifice (ao) is abnormally distant from this wall. **Bottom,** right ventricular view. p = pulmonary orifice; t = tricuspid orifice.

fects in the outflow region, one having the further complication of some small muscular defects belonging to our group III (see later).

The posteromedial muscle, which could be said to form part of the solid portion of the septum, was present in 4 of the 14 hearts with an isolated central muscular ventricular septal defect. The remaining four hearts with more than one defect all exhibited a posteromedial muscle.

II. Posterior muscular ventricular septal defect (Fig. 2): There were five hearts with this anomaly. By definition, all five hearts showed a distinct posteromedial muscle. Characteristically, the defect reaches to the apical extension of the posteromedial muscle, which forms its posteroinferior border. The defect may be slit-like, its long axis being nearly parallel to the long axis of the ventricular septum. Its anterior border is formed by the rest of the septum, of which glabrous and trabeculated regions merge imperceptibly into each other.

When viewed from the right ventricle, the defect may reach to the posterior ventricular wall, and it is much closer than the central defect to the tricuspid anulus. Characteristically, its long axis is nearly perpendicular to the long axis of the septum. It may be partly hidden by the septal leaflet of the tricuspid valve, and invariably it is partly covered by accessory papillary muscles belonging to this valve leaflet. Three of the five hearts had no other defects. One heart had an additional defect related to the outflow tract, and another had a second defect classified in our group III (see later).

III. Marginal muscular ventricular septal defect (Fig. 3): There were eight hearts with this anomaly. This type of defect is sometimes multiple. It is always close to the ventricular wall, but it may be distributed all along the septal margins. Thus, it can be found anterior to the trabecula septomarginalis, at the very apex of the heart, or posterior to the posteromedial muscle when present. The left and right ventricular views of these defects are identical, being dominated by bordering and overlying trabeculae. Sometimes they are tortuous channels that are difficult to probe. Because these defects do not affect the ventricular septum as a whole, but only its rims, the term "swiss cheese" is not applicable to the malformation. Four of our eight hearts had the marginal defect alone, one of them showing this type in its multiple form.

Three hearts had additional defects related to the outflow tract, one having the further complication of a central muscular ventricular septal defect. One heart had a small marginal defect in addition to a larger posterior one.

Four of these hearts showed a posteromedial muscle. The four hearts that did not were the four hearts with a marginal defect alone.

Transposition of the Great Arteries With Ventricular Septal Defect

Sixty hearts with this anomaly were studied; 13 had muscular ventricular septal defects that could be grouped into the three categories previously described (Table II).

I. Central muscular ventricular septal defect: Only two hearts showed this type of defect. One heart had two small central defects, but no other anomaly. In the left ventricle, the solid septal portion was well set off from the apical trabeculated portion, the two defects lying along the dividing line. The second heart had two additional ventricular septal defects, one related to the outflow tract, the other classified in our group III. Both hearts had a posteromedial muscle.

II. Posterior muscular ventricular septal defect: Eight hearts showed this anomaly. In five hearts there was no other anomaly; in three hearts a second ventricular septal defect was related to the outflow tract. By definition, all cases showed a posteromedial muscle.

III. Marginal muscular ventricular septal defect: Four hearts showed this anomaly. Two hearts had no other defect. One heart had two additional defects, one related to the outflow tract and one classified in our group I. The fourth heart had an additional defect related to the outflow tract. A posteromedial muscle was present only in the heart with three types of defect.

TABLE II

Type of Muscular Defect in 13 Hearts With Transposition of the Great Arteries and a Ventricular Septal Defect

Type	no.	
I. Central defect		
Central only	1	
Central + outflow + marginal*	1	
Total		2
II. Posterior defect		
Posterior only	5	
Posterior + outflow	3	
Total		8
III. Marginal defect		
Marginal only	2	
Marginal + outflow	1	
Marginal + outflow + central*	1	
Total		4
Total number*		14

* Because of a combination of defects, one case was counted twice.

Discussion

Our study indicates that muscular defects may occur in hearts with other, more frequent types of ventricular septal defect. However, it is unusual to find more than one muscular defect in one heart. This observation is important, because it has been stated that most muscular defects are multiple.[12,14] In our hearts the marginal defect was the only type of muscular defect that tended to be multiple. Marginal defects may be difficult to detect because of their branching, sinusoidal nature,[15] and special techniques may be necessary to find them all.[16]

Anatomic features of muscular development: The site of muscular defects may vary considerably. This may explain why Becu et al.[6] categorized them as "not related to any of the valvular structures." Warden et al.[7] called them "defects in unusual positions (including muscular defects)," and Kirklin et al.[8] simply used the term "low defects." However, we have tried to stress the pathologic anatomy of the ventricular septum in cases of ventricular septal defect. Apparently, the anatomy is fairly constant in the majority of our hearts. The structures that form the boundaries of muscular defects are morphologically invariable. Only their sizes are not constant. Thus, although central defects may be at different distances from the apex, their site is constant when defined with respect to their bordering structures. Similarly, the posterior defect may occupy various positions with regard to the posterior wall, but this variation merely depends on the width of the posteromedial muscle. The marginal defect is defined as being close to the anterior or diaphragmatic ventricular walls. When these defects are not accompanied by another type of muscular defect, the main septal surface is intact. A "sieve-like septum"[17] was not encountered in our collection, although a central defect with some overlying trabeculae might give the false impression of such a multiply perforated septum.

Comparison of the present classification with previously published descriptions is not fully satisfying, because we have based our classification on the actual septal morphology alone. We have not used the term "smooth septum." Although this term may sound merely descriptive, it suggests very schematic diagrams that show the ventricular septum to be divided from a developmental point of view. Diagrams, such as those presented by Goor et al.,[18] do not group all types of defects logically. In their classification a "smooth type IV" defect exists, which does not relate to any of the recognized structures. We believe that this difficulty is inevitable in any system that uses diagrammatic division lines that are neither clearly evident in normal embryonic hearts nor apparent from adult anatomy. In our hearts, we found no type of muscular defect that did not conform to one of our three anatomic descriptions.

An accurate description of the central muscular ventricular septal defect was given by Moulaert,[13] who paid due attention to the striking features of the left ventricular aspect in this anomaly. His "defects in the dorsal part of the ventricular septum" comprise all our posterior defects, and some of our marginal defects. This is probably the effect of our describing the posteromedial muscle as a distinct structure in all cases with a posterior muscular defect.

Embryologic development: The posteromedial muscle has been described before. We consider that it is the same structure as the dorsomedian muscle ridge of Devloo and Ritter[19] and the portion of the true posterior septum and the posterior median ridge in "single"

and "common" ventricle.[20] We believe that it is a regular component of the ventricular septum, which can only be recognized in the presence of a posterior muscular defect or deviation of the rest of the septum.[2,5] Its development is considered to be linked to atrioventricular septation rather than to the partitioning of the ventricles proper. In normal hearts, where it cannot be recognized, we suppose it to be incorporated in what has been called the inflow septum.[21]

We agree with Goor et al.[18] that development of the ventricular septum must be a key to the characteristic features of different types of ventricular septal defect. We speculate that the solid septal portion and the trabeculated portion visible in hearts with central muscular defects, and the posteromedial muscle of hearts with posterior defects, are all regular components of the ventricular septum. However, the exact relations between the posteromedial muscle and the solid septal portion are not clear. Similarly, the anatomy of central muscular defects shows relations of solid and trabeculated septal divisions that are too complicated to be derived from the present knowledge of embryology. They are certainly more complicated than indicated in the diagrams of Goor et al.[18]

Developmentally, the marginal muscular ventricular septal defect could be interpreted as lack of sufficient coaptation of ventricular trabeculae. Thus considered, these are minor anomalies of ventricular septation. These defects are usually small. The other two types of muscular defects are examples of much more disturbed septal development, and they are usually larger.

Developmental speculations can be made on the different frequency of the other two types of muscular defect in isolated ventricular septal defect and in transposition of the great arteries with ventricular septal defect. The central defect is the dominating type in hearts with an isolated muscular defect, whereas the posterior defect dominates the muscular defects in hearts with transposition. Although our relatively small number of specimens does not permit statistical conclusions, the difference in frequency suggests that different morphogenetic mechanisms may be responsible. It has been hypothesized that transposition is not merely a malformation of the outflow tracts.[5] Now, it can be suggested that the morphogenetic mechanisms that produce a malformed septum in hearts with transposition differ from those mechanisms that lead to a malformed septum as an isolated anomaly.

Acknowledgment

We thank Messrs. Wetselaar and Van Duyvenbode for art work and photography and Miss Stokman for preparation of the manuscript.

References

1. **Oppenheimer-Dekker A, Wenink ACG, Van Gils FAW, Gittenberger-de Groot AC, Moulaert AJMG:** Transposition of the great arteries: morphological study of 150 cases (abstr). J Anat 122–3:724–725, 1976
2. **Wenink ACG, Oppenheimer-Dekker A, Van Gils FAW, Gittenberger-de Groot AC, Moulaert AJMG:** Transposition of the great arteries: embryological considerations (abstr). 7th Eur Congr Cardiol Abstract Book I:33, 1976
3. **Van Gils FAW, Moulaert AJ, Oppenheimer-Dekker A, Wenink ACG:** Transposition of the great arteries with ventricular septal defect and pulmonary stenosis. Br Heart J 40:494–499, 1978
4. **Oppenheimer-Dekker A:** Interventricular communication in transposition of the great arteries. In, Embryology and Teratology of the Heart and Great arteries (Van Mierop LHS, Oppenheimer-Dekker A, Bruins CLDC, ed). Leiden University Press, Leiden, The Netherlands, 1978, p 139–159
5. **Wenink ACG:** Considerations pertinent to the embryogenesis of transposition. In Ref 4, p 129–135.
6. **Becu LM, Fontana RS, DuShane JW, Kirklin JW, Burchell HB, Edwards JE:** Anatomic and pathologic studies in ventricular septal defect. Circulation 14:349–364, 1956
7. **Warden HE, Dewall RA, Cohen M, Varco RL, Lillehei CW:** A surgical-pathologic classification for isolated ventricular septal defects and for those in Fallot's tetralogy based on observations made on 120 patients during repair under direct vision. J Thorac Surg 33:21–44, 1957
8. **Kirklin JW, Harshbarger HG, Donald DE, Edwards JE:** Surgical correction of ventricular septal defect: anatomic and technical considerations. J Thorac Cardiovasc Surg 33:45–59, 1957
9. **Lev M:** The pathologic anatomy of ventricular septal defects. Dis Chest 35:533–545, 1959
10. **Imperial ES, Nogueira C, Kay EB, Zimmermann HA:** Isolated ventricular septal defects. An anatomic-hemodynamic correlation. Am J Cardiol 5:176–184, 1960
11. **Edwards JE:** The pathology of ventricular septal defect. Semin Roentgenol 1:2–33, 1966
12. **Edwards JE, Carey LS, Neufeld HN, Lester RG:** Congenital Heart Disease. Correlation of Pathologic Anatomy and Angiocardiography. Philadelphia, WB Saunders, 1965, p 95–97
13. **Moulaert AJMG:** Ventricular Septal Defects and Anomalies of the Aortic Arch. Thesis, State University Leiden, Leiden, 1974
14. **Dammann JF, Thompson WM, Sosa O, Christlieb I:** Anatomy, physiology and natural history of simple ventricular septal defects. Am J Cardiol 5:136–166, 1960
15. **Breckenridge JM, Stark J, Waterston DJ, Bonham-Carter RE:** Multiple ventricular septal defects. Ann Thorac Surg 130:128–136, 1972
16. **Bernhard WF, Innis R, Gross RE:** Transillumination of the ventricular septum. A method for the detection of multiple occult septal defects. N Engl J Med 267:909–912, 1962
17. **Friedman WF, Mehrizi A, Pusch AL:** Multiple muscular ventricular septal defects. Circulation 32:35–42, 1965
18. **Goor DA, Lillehei CW, Rees R, Edwards JE:** Isolated ventricular septal defect. Development basis for various types and presentation of classification. Chest 58:468–484, 1970
19. **Devloo A, Ritter DG:** A dorsomedian muscle ridge between both atrioventricular valves in transposition of the great vessels (abstr). 7th Eur Congr Cardiol Abstract Book II:56 1976
20. **Lev M, Liberthson RR, Kirkpatrick JR, Eckner FAO, Arcilla RA:** Single (primitive) ventricle. Circulation 39:577–591, 1969
21. **Anderson RH:** Embryology of the ventricular septum. In, Pediatric Cardiology 1977 (Anderson RH, Shinebourne EA, ed). Edinburgh, Churchill Livingstone, 1978, p 103–112