EUROP. J. OBSTET. GYNEC. REPROD. BIOL., 1979, 9/1, 13–22

Prenatal diagnosis of congenital malformations in 500 pregnancies*

N.J. Leschot [1], P.E. Treffers [2], M. Verjaal [1], J.J. der Weduwen [2], J. Bennebroek Gravenhorst [3] and H.J.T. Coelingh Bennink [4]

[1] *Department of Human Genetics, Sarphatistraat 217, University of Amsterdam,* [2] *University Department of Obstetrics and Gynecology, Wilhelmina Gasthuis, Amsterdam,* [3] *University Department of Obstetrics and Gynecology, Leiden and* [4] *State University Hospital Department of Obstetrics and Gynecology, Utrecht, The Netherlands*

Accepted for publication 16 August 1978

LESCHOT, N.J., TREFFERS, P.E., VERJAAL, M., DER WEDUWEN, J.J., BENNEBROEK GRAVENHORST, J. and COELINGH BENNINK, H.J.T. (1979): Prenatal diagnosis of congenital malformations in 500 pregnancies. *Europ. J. Obstet. Gynec. reprod. Biol., 9/1,* 13–22.

The organization, techniques used and diagnostic findings of 500 prenatal diagnoses are reported in detail. In 15 cases the pregnancy was terminated because of abnormal laboratory findings. Follow-up of the remaining pregnancies revealed a perinatal mortality of 1.7%, and the risk of an abortion induced by amniocentesis, performed in the 15–16th wk, to be 1–2%. Serious counseling problems arose in 2 cases with trisomy X, in 2 instances of a balanced chromosome translocation and in 1 case of a de novo translocation.

risk of amniocentesis; genetic counseling; perinatal mortality; antenatal diagnosis; chromosome aberration; neural tube closure defect; series of 500 cases

Introduction

In 1974 our Amsterdam group, consisting of 2 gynecologists (P.E.T. and J.J.d.W.) and 2 geneticists (N.J.L. and M.V.), started prenatal diagnosis of chromosomal aberrations by means of amniotic fluid cell cultures. From the beginning of 1975 α_1-fetoprotein (AFP) estimation has been carried out routinely on all amniotic fluid samples, and in addition all stored earlier samples have been assayed retrospectively. We think that a detailed account of prenatal diagnosis of congenital malformations in 500 pregnancies can contribute to the understanding of the possibilities and problems of this procedure.

* Financial support from the municipality Amsterdam and the Amsterdam "Ziekenfondsen" allowed for the prenatal investigations.

Organization

Before amniocentesis is performed, we consider that every couple should be aware of the procedure in detail. This patient counseling was done by one of our two geneticists. Information was given about the risks involved, i.e. the chance of a miscarriage due to amniocentesis, the possibility of the need of a second puncture in cases of poor cell growth, and the chance of unexpected findings. The desirability of interrupting the pregnancy and the methods used in the eventuality of abnormal findings were also discussed.

At the same time a family history of both partners was recorded to discover any additional risk factors.

In the 12–13th wk of gestation a gynecologic examination was performed, including an estimation of the size of the pregnant uterus compared with the duration of the amenorrhea and an ultrasound detection of fetal heart activity. Amniocentesis was routinely performed in the 15–16th wk. As soon as the results of the tests were known, the couple was informed by the geneticist or, in the case of an abnormal outcome, by the family doctor.

When amniotic fluid investigations were normal, the patient was seen by the gynecologist again 3 wk after amniocentesis. During this visit the results of the amniotic fluid investigations were discussed, the growth of the pregnant uterus was determined and the presence of fetal heart action was confirmed by ultrasound.

In our opinion, the organization described so far is the ideal one; it held true only for the amniocenteses performed in the Department of Obstetrics and Gynecology of the Wilhelmina Gasthuis of the University of Amsterdam (n = 262). In this article, patients of our Amsterdam group are marked with an asterisk. The other amniocenteses were done in the Department of Obstetrics and Gynecology of the University of Leiden (Prof. J. Bennebroek Gravenhorst; n = 96) and in the Department of Obstetrics and Gynecology of the University of Utrecht (Prof. A.A. Haspels; n = 48). About 20% of the samples (n = 94) came from other external gynecologists.

Materials and methods

Amniocentesis

With growing experience we now consider 15–16 wk the most appropriate time for amniocentesis, because at 14 wk failures were more frequent. The procedure was preceded by a second gynecological examination to determine the size of the pregnant uterus. The presence of fetal heart action was confirmed, and localization of the placenta was carried out by ultrasound. Transabdominal amniocentesis was performed with 18–20-gauge needles, after manual fixation of the uterus against the abdominal wall by an assistant, in a position to prevent lesions of the placenta. Usually a 20 ml sample was obtained. Of the 262 women attending our own department, amniocentesis did not succeed in 15 cases, and was repeated 1 or 2 wk later.

Cell culture and karyotyping

Each sample was divided into at least 3 equal parts, and the cells were cultured as described before (Leschot, Verjaal, Bennebroek Gravenhorst and van de Kamp, 1977). When the cell growth was sufficient, Colcemid (Merck) (0.008 μg/ml culture medium) was added for 2–4 h. Hypotonic treatment was given by replacing the culture medium with a mixture of fetal calfs serum and distilled water (1:9) for 20–25 min at 37°C. Then the hypotonic solution was very gradually replaced by fixative. The coverslip was finally centrifuged at 4°C (308 × *g*) and stained.

Up until April 1976 only conventional orcein staining was used. From that time onwards all preparations have been stained with 0.5% Atebrin (Sigma). Q-banded metaphase spreads were used for chromosome analysis, and a minimum of 10 cells from at least 2 different cultures were counted.

AFP estimation

AFP estimation was done by a modification of the Laurell rocket immunoelectrophoresis technique (Laurell, 1966). Behringwerke reagents were used. Normal values have been reported previously (Kleyer, de Bruyn and Leschot, 1978).

Results and comment

General remarks

In 469 cases (94%) cell growth in the initial cultures yielded sufficient metaphases for karyotype analysis. Poor cell growth occurred in 31 cases (6%), including 17 heavily blood-stained samples. 19 patients had a second amniocentesis; chromosomal analysis was possible in all these pregnancies. The mean culture time was 13.5 days (n = 469 + 19 = 488). The mean culture time of 57 sanguinolent samples was 19.4 days. Amniocentesis was not

repeated in 12 cases: twice (cases 39 and 49) a spontaneous abortion occurred before a second puncture was planned, 8 were for AFP estimation only, and in two (**) cases, after several dry taps further attempts were omitted.

The outcome of all pregnancies is known. Prenatal sex determination was in all cases in accordance with the sex diagnosed at birth. Poor-quality slides prevented the determination of the fetal sex in 3 cases.

Indications

The frequency of the different indications for amniocentesis, the abnormal diagnostic findings and the outcome of pregnancies are shown in Table I.

Maternal age is defined in our series as the age at the time of amniocentesis. In the obstetrical department the risk of Down's syndrome and the possibility of prenatal diagnosis were pointed out to women over 40 at the time of their first visit to the prenatal clinic; women over 35 requesting amniocentesis were given information about the procedure and the risk of a chromosomally abnormal baby. If a couple of this latter group was firmly asking for prenatal diagnosis, amniocentesis was carried out.

A family history of neural tube defects (NTD) was the reason for amniocentesis in 151 pregnancies. In 111 cases a previous child (n = 100) or one of the parents (n = 11) had been born with an NTD (first-degree relatives). In 34 cases a second-degree relative with a neural tube defect was indicative for AFP estimation. The birth of a previous child with an NTD in combination with other congenital malformations was the reason for amniocentesis in 6 instances. Three

TABLE I Analysis of 500 cases for prenatal diagnosis

Indication	n	Abnormal findings	Therapeutic abortion	Normal live births	Abnormal outcomes not due to amniocentesis	Abnormal outcomes due (?) to amniocentesis
Maternal age	175					
over 40:	90	6[a,b,c,d,e]	4	74	5	7
35–39:	85	1[f]	–	77	1	7
Central nervous system malformation	151	2[g,h]	2	134	1	14
Recurrence risk for num. chrom. aberration	113	2[i,j]	–	109	–	4
X-linked disorder	17	8[k]	6	10	1	–
Parental translocation	16	13[l,m,n]	1	13	1	1
Metabolic disorder	3	2[p]	2	1	–	–
Miscellaneous	25	–	–	21	1	3
Total	500	34	15	439	10	36

[a*] trisomy 21 (2): ther. ab.: diagnosis confirmed.
[b*] trisomy X; chrom. analysis: Dept. Cell Biology, Rotterdam Univ.; ther. ab.; diagnosis confirmed.
[c*] trisomy X; pregnancy continued; diagnosis confirmed.
[d*] 45,XX,t(13q14q).
[e] 46,XX/47,XX,+C: ther. ab.; karyotype of aborted fetus: 46,XX.
[f*] paracentric inversion 11q: 46,XY,inv. (11)(q13q21); pregnancy continued; diagnosis confirmed.
[g*] AFP: 308 μg/ml; ther. ab.; anencephalic fetus with spina bifida.
[h] AFP: 240 μg/ml; ther. ab.; fetus with Meckel syndrome (details in Leschot, de Nef, Becker-Bloemkolk, Verjaal and Wiesenhaan, 1978).
[i*] 45,XX,t(DqGq).
[j*] 46,X,t(22;Y)(p11;q11); de novo translocation; pregnancy continued; diagnosis confirmed.
[k] the pregnancy of a male fetus was continued for 2 patients.
[l] 11 balanced translocations.
[m] 46,XY,t(13q21q)/45,XY,t(DqGq); spontaneous ab. of 2 male fetuses.
[n*] 46,XX,del(1)(q43); ther. ab.; congenital anomalies of the fetus; no cytogenetic confirmation.
[p] Lesch–Nyhan syndrome (2); biochemical analysis: Dept. Human Genet. Nijmegen University; ther. ab.; diagnosis confirmed once.

of these were diagnosed as Meckel syndrome.

90 prenatal diagnoses were performed because of a previous child with a chromosomal anomaly, most of them trisomy 21. In addition the procedure was carried out 23 times because of a 'family history of Down's syndrome'. The time was lacking in these latter cases for a preceding lymphocyte culture of the index case or the parents.

The various X-linked disorders are listed in Table II. Two cases in the table concern fathers who, suffering from an X-linked disease themselves, asked for prenatal sex determination so as to prevent the birth of obligate carrier daughters.

Three times an inborn error of metabolism was reason for amniocentesis. Cultured cells were studied by Dr. Patrick (London) for cystinosis and by Dr. de Bruyn (Nijmegen) twice for Lesch–Nyhan syndrome (Hösli, de Bruyn, Oerlemans, Verjaal and Nobrega, 1977).

The parental chromosome translocations are listed in Table III.

Most cases in the miscellaneous group concern severe parental anxiety.

TABLE II Indication: X-linked recessive disorders (n = 17)

Disease	Karyotype	Outcome pregnancy
Duchenne muscular dystrophy (DMD)	46,XX	fetal death (♀)
DMD next pregnancy	46,XY	♂ (healthy)
DMD next pregnancy	46,XY	ther. ab.
DMD	46,XX	♀
* DMD	46,XX	♀
* DMD	46,XY	ther. ab.
* DMD	46,XX	♀
* DMD	46,XX	♀
* DMD	46,XY	ther. ab.
* DMD	46,XY	ther. ab.
Hemophilia	46,XY	♂ (healthy)
Hemophilia (father)	46,XY	♂
* Bullous dystrophy	46,XX	♀
* Bullous dystrophy	46,XY	ther. ab.
Agammaglobulinemia (Bruton type)	46,XY	ther. ab
* Choroideremia	46,XX	♀
Retinoschisis (father)	46,XY	♂

'Unexpected' laboratory findings

Chromosomal analysis of 4 amniotic fluid cultures showed unexpected structural anomalies (Table I; i, d, f, j). The parents were karyotyped directly after these findings. In the first 3 cases (Table I; i, d, f), the abnormal chromosome of the fetus was also found in one of the parents. The 3 babies born from these pregnancies were reported to be phenotypically nor-

TABLE III Carrier parent known at time of amniocentesis (n = 16)

Translocation	Fetus	Outcome pregnancy
*P: t(DqGq)	45,XY,t(DqGq)	healthy boy
next pregnancy	46,XX	healthy girl
*P: t(DqGq)	45,XY,t(DqGq)	missed abortion
M: t(DqGq)	46,XY,t(DqGq) / 45,XY,t(DqGq)	spontaneous abortion of 2 male fetuses
next pregnancy	45,XY,t(13q21q)	healthy boy
*P: t(DqGq)	45,XY,t(DqGq)	healthy boy
next pregnancy	45,XX,t(13q21q)	healthy girl
*M: t(6;12)(q26;q11)	46,XY,t(6;12)(q26;q11)	healthy boy
*P: t(13q21q)	45,XY,t(13q21q)	healthy boy
M: t(13;17)(q14;q23)	46,XX	healthy girl
*M: t(14q21q)	45,XY,t(14q21q)	healthy boy
*M: t(DqGq)	46,XY	healthy boy
M: t(9q−;14q+)	46,XY,t(9q−;14q+)	healthy boy
M: t(6;10)(p12;q26)	46,XX,t(6;10)(p12;q26)	healthy girl
*M: t(14q21q)	45,XX,t(14q21q)	healthy girl
*M: t(1;22)(q43;q13)	46,XX,del(1q)(q43)	therapeutic abortion

mal. The Y/22 translocation proved to be de novo (see 'counseling').

Twice a fetal karyotype 47,XXX was found in the maternal age group 40 yr and over. In other series this is an unusual finding (see 'counseling').

In a twin pregnancy, cultured cells from one amniotic fluid sample presumably revealed metaphases from both fetuses (Table I; m). Ten days after the puncture the mother had a spontaneous abortion of two macerated male fetuses. Intrauterine death may have already occurred before the amniocentesis (Leschot et al., 1977).

In one case (Table I; e) only 8 well-spread, orcein-stained metaphases were found. Of these, 7 had a normal female karyotype (46,XX); 1 had an extra chromosome in the C-group. Because the possibility of mosaicism could not be excluded, the parents asked for termination of the pregnancy. Chromosomal analysis of different fetal skin biopsies revealed only normal cells.

An AFP value of 160 μg/ml was found retrospectively in a sample derived from a 16-wk pregnancy. Chromosomal analysis at that time had revealed a normal karyotype (46,XX). After this finding in the 34th wk, a fetography clearly showed a neural tube defect; the AFP value on that occasion was less than 2 μg/ml. 5 wk later a girl was born with a severe spina bifida; she died shortly after birth.

'Unexpected' obstetrical findings

All patients from our department were asked to void urine before amniocentesis to prevent puncture of the bladder. Nevertheless, in one patient 20 ml of yellow fluid was obtained and sent to the laboratory, where a laboratory assistant recognized it as urine. In this patient a previous pregnancy had been terminated by cesarean section; during the operation the bladder was damaged and sutured. A second amniocentesis was successful. Scrupulous investigation by ultrasound during this procedure revealed that, after voiding, the bladder still contained a notable amount of urine, and was localized in front of the pregnant uterus.

Although we did not undertake a systematic examination of all children born after amniocentesis in early pregnancy, we discovered 3 children who had scars present at birth, suspected as being caused by the puncture. One child had two punch-hole scars in the upper arm and shoulder (Fig. 1), and the second had two similar scars in the upper leg. The scars on the medial and lateral side of the left upperarm in the third child strongly suggested perforation of this extremity during amniocentesis. Up till now no signs of functional disability could be found.

On one occasion a minimal tissue fragment was obtained by amniocentesis which, on histological examination, was recognized as a needle biopsy of fetal liver tissue. However, amniotic fluid was obtained at the second puncture. The pregnancy was uneventful and the child was normal, except for two scars on its upper leg (see above). The skin of the trunk was free from scars.

Abnormal outcomes

A. Risk(s) resulting from amniocentesis. A criterion for a relationship between amniocentesis and a

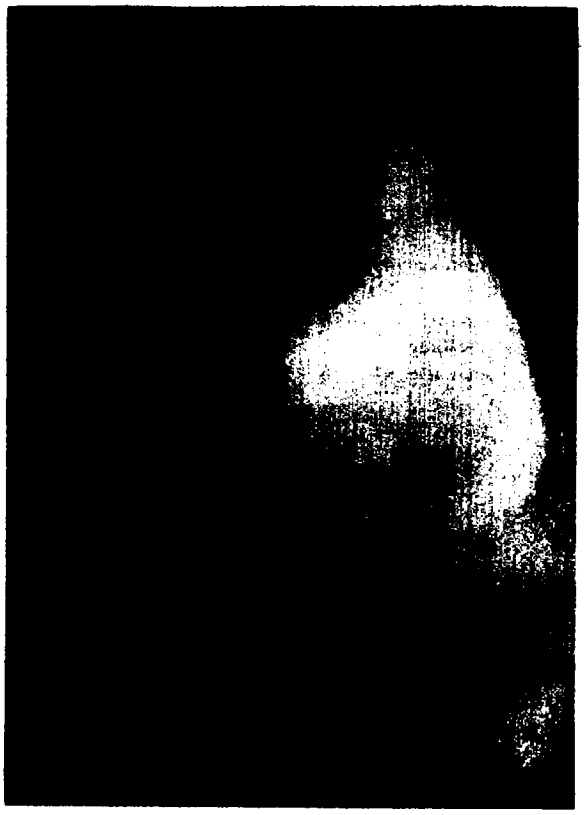

Fig. 1. Punch-hole scars on left upper arm.

subsequent abortion is difficult to define. When a 'spontaneous' abortion occurred within 3 wk of amniocentesis, a (possible) relation was accepted. When intrauterine death was evident within 3 wk of amniocentesis, a (possible) relation was accepted regardless of the time interval between amniocentesis and the definite moment of the abortion itself. When at the time of the routine examination by the gynecologist (1.5–3 wk after amniocentesis) a normal pregnant uterus was found and the presence of fetal heart action was confirmed by ultrasound, no relation between amniocentesis and any future fetal loss was accepted. Table IV lists the 10 cases, in which a relationship between amniocentesis and abortion may exist in detail. Except for case 582 no gross fetal malformations were noticed.

B. Table V: review of the 36 pregnancies with abnormal outcomes which are probably not related to amniocentesis. None of the 7 infants under heading III showed congenital anomalies on physical examination. Fetal death (heading IVa) was diagnosed at 20, 20, 22, 23, 26, 31 and 40 wk, respectively. In 3 patients a cause for intrauterine death was found. One fetus died in the 31st wk of pregnancy after an unsuccessful attempt at intrauterine blood transfusion because of severe Rh-antagonism. In a second patient the cause of intrauterine death at 22 wk appeared to be serious infarction of the placenta. Insufficiency of the placenta was responsible for intrauterine death diagnosed at term after an uneventful pregnancy in a third case.

Perinatal mortality (more than 28 wk and up to

TABLE IV Abnormal outcome possibly due to amniocentesis

Case	Indication	Amniocentesis in (wk)	Chromosomal analysis	AFP (μg/ml)	Fetal death diagn.	Other findings	Outcome pregnancy
39	X-linked disorder	21 [a]	–	15.0	–	blood-stained amniotic fluid	22nd wk; female fetus of 22 cm, 250 g
49	mat. age: 44	14	–	17.8	–	mother: hyperthyroidism	16th wk; macerated male fetus
56 *	P: t(D/G)	15	45,XY,t(D/G)	30.7	18 wk		30th wk [b]; macerated fetus
210 *	mat. age: 43	15/16	46,XX,Dp+	41.3	18/19 wk	uterine fibroids	22nd wk; macerated fetus, 85 g
260	vaginal bleeding	16	46,XX	18.5	–	brown amniotic fluid	spontaneous abortion 4 days after puncture
305 *	mat. age: 41	16	46,XX	47.0 [c]	18 wk	blood-stained amniotic fluid	27th wk; macerated fetus
448	anencephaly before	13	46,XX	17.0	–	1 day after puncture: septic temperatures	incomplete abortion 6 days after puncture
413	mat. age: 40	16	46,XX	15.8	–		spontaneous abortion 3 days after puncture
581 *	mat. age: 36	16	46,XX	17.2	–		spontaneous abortion 4 days after puncture; non-autolytic fetus
582	mat. age: 40	14	46,XY	27.6	20 wk		20th wk; male fetus of 8 cm, neck strangulated 5 times; left foot and ankle anomaly

[a] Cell growth in 2 samples taken earlier was insufficient (examined elsewhere).
[b] Terminated by oxytocin intravenously and digital removal of placenta remnants.
[c] HbF: detected by Dr. Brock (Edinburgh).

TABLE V Abnormal outcomes *not* due to amniocentesis (n = 36)

I Multiple pregnancies (3)	
* Twins	2 girls; both healthy
Twins	2 girls; both healthy
Triplets	2 girls; 1 boy; all healthy
II Congenital anomalies/diseases (18)	
* Bilateral clubfeet	girl; otherwise healthy
* Bilateral clubfeet	girl; otherwise healthy
Cleft lip/cleft palate	girl; otherwise healthy
* Cleft lip	girl; otherwise healthy
Cleft palate	girl; otherwise healthy
Meningomyelocele [a]	girl; died soon after birth
Congenital heart defect	girl; died 2 wk old
* Congenital heart defect	boy; otherwise healthy
Congenital heart defect	girl; otherwise healthy
Congenital heart defect	boy; otherwise healthy
* Werdnig–Hoffmann disease	boy; died 11 mth old
Birth trauma	boy; hemiplegia; seizures
* Retarded development	boy; died 2 yr old
* Kidney tubular acidosis	boy; symptoms after 1 yr
* Multiple anomalies	boy; died 1 day old
Lung hypoplasia	girl; died 1 day old
Hemophilia A [b]	boy; otherwise healthy
Brachydactyly	boy; otherwise healthy
III Preterm delivery of a live born child (7)	
*26 wk	girl; died 6 days old
28 wk	boy; birthweight 900 g; healthy
29 wk	girl; died soon after birth
30 wk	boy; died 7 days old
* 31 wk	boy; healthy
* 33 wk	boy; died 1 day old
35 wk	boy; healthy
IV Intrauterine death (8)	
a. Fetal heart action positive at least 1.5 wk after amniocentesis (n = 7; of which 2 * patients)	
b. Fetal heart action not investigated (n = 1) [c]	

[a] See unexpected laboratory findings.
[b] Indication; recurrence risk for chromosome aberration; negative family history for hemophilia.
[c] See unexpected laboratory findings (Table I; m).

7 days after birth) comprised 8 cases in 472 children from 468 pregnancies lasting beyond 28 wk (1.7%). One more child died 2 wk after birth.

Counseling

During the performance of the prenatal diagnoses described, we met some unusual questions which we did not come across in the extensive literature.

Four times, before amniocentesis was performed, the parents intimated the wish to have an abortion of a phenotypically normal baby. Twice (**) this question was raised by a couple in which one of the parents was carrier of a balanced translocation. Both couples wanted the pregnancy to be terminated in case the fetus should be found to be carrier of either the balanced or the unbalanced form of the translocation. Twice the fathers suffered from an X-linked recessive disorder, hemophilia and retinoschisis, respectively, and asked for an abortion if a female karyotype (a certain carrier of the disease) was diagnosed. Chromosome studies in the first two cases showed the fetuses to be balanced carriers. When the parents were informed of these findings, both couples nevertheless wanted the pregnancy to continue. Both fetuses of fathers suffering from X-linked recessive disorders turned out to be male and pregnancies were continued.

In the series presented, one couple asked for AFP estimation only, because the parents felt that, by the time the chromosome analysis was ready, they would not be able to bring themselves to agree with an induced abortion.

Counseling two couples after finding a 47,XXX karyotype was difficult because of the scarce data available concerning prognosis, and especially mental development. The uncertainties were discussed with the parents. One couple, having a mentally retarded son, did not want to take the risk of another subnormal child, and had the pregnancy terminated. The other couple was childless and decided to continue the pregnancy. A phenotypically normal daughter was born, whose development will be followed.

The finding of a de novo Y/22 translocation, seemingly balanced, caused even greater counseling problems. A patient with a similar karyotype could not be found in the literature. The parents were told that we were not able to predict the phenotype of the prospective baby. The couple did not want an abortion of a fetus that might be developing normally. So the pregnancy proceeded and an apparently normal boy was born at full term (further details are in press: Verjaal, Treffers, Nagai and Leschot).

Discussion and conclusions

A causal relationship between amniocentesis and fetal death is possible in 10 cases of spontaneous

abortion (2%). In the literature there is no agreement about the risk of abortion following early amniocentesis. Published figures are 1:238 (Gerbie, Nadler and Gerbie, 1971), 2:40 (Cederbaum, Holzman and Sparkes, 1971), 4:73 (Doran, Rudd, Gardner, Lowden, Benzie and Liedgren, 1974), 3:100 (Golbus, Conte, Schneider and Epstein, 1974), 1:50 (Prescott, Pernoll, Hecht and Nicholas, 1973), 10:128 (Robinson, Bowes, Droegemueller, Puck, Goodman, Shikes and Greenshur, 1973), 7:477 (Milunsky and Atkins, 1974), 4:219 (Wahlström, Bartsch and Lundberg, 1974), 7:223 (Jahodova, 1975), 0:78 (Munk-Andersen, Weber and Mikkelsen, 1977). Most authors conclude that a causal relation between amniocentesis and abortion exists in only a small number of fetal deaths. Galjaard (1976) gives the combined results of 20 European centers. Frequency of abortion following amniocentesis was low (49:3462), and a causal relationship was assumed in only 10 cases. Our figure of fetal death possibly due to amniocentesis (10:500) is high compared with the figures of some authors, especially Galjaard's combined European statistics. The difference could be due to bad luck, to wrong technique, or to a more accurate search for pathologic events following amniocentesis. We cannot definitely decide between these possibilities, but we suppose that in the literature the risk due to early amniocentesis could sometimes be underestimated. Some authors only assume a causal relation between amniocentesis and abortion when the abortion occurs within 2 wk of amniocentesis (Jahodova, 1975). However, our cases 56*, 210* and 305* illustrate that intrauterine fetal death probably caused by amniocentesis may result in a missed abortion; the actual delivery of fetus and placenta may be delayed for weeks or even months. Sometimes the abortion rate after amniocentesis is compared to standard abortion rates after 15 wk pregnancy. Jahodova (1975) and Galjaard (1976) compare their abortion rates with Shapiro's figures (Shapiro, Jones and Densen, 1962) and conclude that the risk of abortion in the 16–28th wk of pregnancy is not notably increased by the procedure of transabdominal amniocentesis. Shapiro reports about 6844 pregnancies in New York City, 1958–1959. This standard is derived from a population different in time, age and risk factors from the women undergoing early amniocentesis. Most important, however, in Shapiro's population is that the rate of induced abortion is unknown, although this was a very frequent phenomenon in New York City in 1958–1959. This means that Shapiro's percentage of fetal death from 16–27 wk of pregnancy (2.2) is certainly too high, excluding induced abortions. Probably the frequency of spontaneous termination of pregnancy between 16 and 28 wk is very low. In our hospital from 1952 to 1971 we observed 305 spontaneous and self-induced terminations between 16 and 28 wk in 39,381 pregnancies (0.77%). In an unselected population this figure is certainly lower, possibly about 0.5% (Kloosterman, 1973). Our 10 cases of abortion possibly due to amniocentesis are not, without any doubt, causally related to the procedure. From Table I it is clear that 5 of these suspected abortions (50%) occurred in 90 pregnant women beyond the age of 40 yr (18% of all pregnant women). These figures could be an indication that increasing maternal age predisposes to second-trimester abortion; some of these abortions could perhaps have occurred without amniocentesis as well. Nevertheless, our 3 cases of fetal damage (probably) due to amniocentesis are a further indication that the procedure of early amniocentesis carries a certain risk. Similar lesions have been described by Broome, Wilson, Weiss and Kellogg (1976) and by Rauskolb, Fuhrmann-Rieger, Fuhrman and Jovanovic (1978). It seems justified to estimate the risk of abortion due to early amniocentesis at between 1 and 2%.

Several authors described their experiences with chromosomal mosaicism in cultured amniotic fluid cells. Repeatedly, pregnancies have been interrupted because cell-lines with different karyotypes were found. Occasionally chromosomal analysis of the fetus or the newborn showed true mosaicism (Sutherland, Bowser-Riley and Bain, 1975; Milunsky, 1976; Med. Res. Council, 1977). More often, examination of the fetus or neonatus revealed only normal karyotypes and, consequently, as in our case (Table I; e), it had to be concluded that prenatal diagnosis had been inaccurate (Katayama, Park, Heller, Barakat, Preston and Jones, 1974; Milunsky and Atkins, 1974; Niermeijer, 1975; Sutherland et al., 1975). On the other hand, the diagnosis of a normal fetal karyotype does not exclude the possibility of chromosomal mosaicism (Katayama et al., 1974). Though the 'in situ' technique for making metaphase preparations is

more reliable for detecting chromosomal mosaicism than preparing slides from trypsinized cells (Schmid, 1975), chromosomal mosaicism will probably remain a real pitfall in prenatal diagnosis.

The results of the chromosomal investigations in the 'parental translocation' indication group are striking. More balanced translocations were found than had been expected. In 16 cases amniocentesis was performed because of a known parental translocation and only 3 normal karyotypes were diagnosed (Table III). Boué and Stene (1978), presenting the data of the European collaborative study, reported a similar deviation to the theoretical expectation (n = 504; balanced: 272; normal: 185; expected 1:1).

The frequency of 'de novo' reciprocal translocations in prenatal diagnosis seems to be very low. In the Canadian series (1977) of 1020 pregnancies, one mutant 5/16 translocation was detected. Niermeijer (1975), reporting the results of 350 investigated pregnancies, found a sporadic 7/21 translocation. In both cases the pregnancy was interrupted, and both fetuses showed no abnormalities. In our case of the Y/22 translocation (Table I; j), however, the pregnancy was continued (see Counseling).

The results of the AFP estimation in our series must be divided into 2 groups: the high-risk group (n = 151) and the population risk group (n = 349). Table I shows that only two elevated AFP values (1.3%) have been found in the high-risk group (previous child with anencephaly in combination with spina bifida and Meckel syndrome, respectively). This is a low recurrence risk compared to the figures reported by Carter (1974). Pooled data from the Dutch centers for prenatal diagnosis indicate that the recurrence risk in the Netherlands is considerably lower than in the United Kingdom (Kleyer et al., 1978).

Blood contamination of the amniotic fluid sample can have severe disadvantages. Firstly the presence of fetal serum can cause false positive elevated AFP values (Ward and Stewart, 1974). It also has a negative effect on the cell culture of amniotic fluid cells. As mentioned under general remarks, the mean culture time for 57 contaminated samples was 6 days longer than the overall culture time. In the near future, as more amniocenteses are carried out under direct ultrasonic control, the incidence of sanguinolent samples will probably be lowered.

In our opinion, the ideal procedure of prenatal diagnosis should be as follows: prior to amniocentesis (preferably before pregnancy) information should be given about the details of the procedure, including the risk of fetal death and abortion caused by amniocentesis. A short family history should be recorded during the same visit. After a gynecologic examination in the 12–13th wk of gestation, amniocentesis should be performed in the 15–16th wk. For the accurate assessment of possible fetal damage resulting from the puncture, it is important to detect fetal heart action directly prior to amniocentesis and 1–3 wk after amniocentesis in every patient. A follow-up of the patient and her future baby seems justified, because there are still few data available concerning possible long-term effects of amniocentesis.

Acknowledgements

We are grateful for the help of Mrs. R.M. Slater-Sweeting in preparing the manuscript. We thank Mrs. J.M. Vermeulen, Mrs. M.A. Stam-Johan, Mrs. D.J. Mieras, Mrs. A.A.J. Scholten-Peters, Mrs. P. v.d. Lagemaat, H. Temminck, F. Koperdraad and R. Lutgerhorst for their dedicated technical assistance.

The Dept. Cell Biology, Rotterdam University established the karyotype in a case of trisomy X. We thank Dr. D.J.H. Brock (Edinburgh) for his help in setting up the AFP determination.

We thank the gynecologists of the following hospitals for sending us amniotic fluid for prenatal diagnosis. Amsterdam: Andreas Hospital, Midwifery Training School, Onze Lieve Vrouwe Gasthuis, University Hospital Vrije Universiteit, Boerhaave Clinic; Haarlem: Elisabeth Gasthuis, Maria Stichting; Hoorn: St. Jans Gasthuis.

References

Boué, A. and Stene, J. (1978): European collaborative study on structural chromosomal anomalies in prenatal diagnosis. In: *Proc. 3rd Europ. Conf. Prenatal Diagnosis of Genetic Disorders.* In press.

Broome, D.L., Wilson, M.G., Weiss, B. and Kellog, B. (1976): Needle puncture of fetus: a complication of second

trimester amniocentesis. *Amer. J. Obstet. Gynec., 126,* 247.

Carter, C.O. (1974): Clues to the etiology of neural tube malformations. *Develop. Med. Child Neurol., 16, Suppl. 32,* 3–15.

Cederbaum, S.D., Holzman, G.B. and Sparkes, R.S. (1971): Spontaneous abortion and hemorrhage following attempted amniocentesis in a carrier of haemophilia A. *Lancet, 2,* 429.

Doran, T.A., Rudd, N.L., Gardner, H.A., Lowden, J.A., Benzie, R.J. and Liedgren, S.I. (1974): The antenatal diagnosis of genetic disease. *Amer. J. Obstet. Gynec., 118,* 314.

Galjaard, H. (1976): European experience with prenatal diagnosis of congenital disease: a survey of 6121 cases. *Cytogenet. Cell Genet., 16,* 453–467.

Gerbie, A.B., Nadler, H.L. and Gerbie, M.V. (1971): Amniocentesis in genetic counseling. *Amer. J. Obstet. Gynec., 109,* 765.

Golbus, M.S., Conte, F.A., Schneider, E.L. and Epstein, C.J. (1974): Intrauterine diagnosis of genetic defects: results, problems and follow-up of one hundred cases in a prenatal detection center. *Amer. J. Obstet. Gynec., 118,* 897.

Hösli, P., de Bruyn, C.H.M.M., Oerlemans, F.J.J.M., Verjaal, M. and Nobrega, R.E. (1977): Rapid prenatal diagnosis of HG-PRT deficiency using ultra-microchemical methods. *Hum. Genet., 37,* 195–200.

Jahodova, M.G.J. (1975): *Klinische Aspecten van de Prenatale Diagnostiek.* Thesis, Erasmus University, Rotterdam.

Katayama, K.P., Park, J., Heller, R.H., Barakat, B.Y., Preston, E. and Jones, H.W. (1974): Errors of prenatal cytogenetic diagnosis. *Obstet. and Gynec., 44,* 693–698.

Kleyer, W.J., de Bruyn, H.W.A. and Leschot, N.J. (1978): Amniotic fluid alpha fetoprotein levels and the prenatal diagnosis of neural tube defects: a collaborative study of 2180 pregnancies in the Netherlands. *Brit. J. Obstet. Gynaec., 85,* 512–517.

Kloosterman, G.J. (1973): *De Voortplanting van de Mens.* Uniboek, Bussum.

Laurell, C.B. (1966): Quantitative estimation of proteins by electrophoresis in agarose gel containing antibodies. *Analyt. Biochem., 15,* 45–52.

Leschot, N.J., Verjaal, M., Bennebroek Gravenhorst, J. and van de Kamp, J.J.P. (1977): An unusual case of prenatal diagnosis in twin pregnancy. *Clin. Genet., 11,* 441–443.

Leschot, N.J., de Nef, J.J., Becker-Bloemkolk, M.J., Verjaal, M. and Wiesenhaan, W.F. (1978): Prenatal diagnosis of Meckel syndrome. *Hum. Genet., 43,* 333–336.

Medical Research Council, Canada (1977): *Diagnosis of Genetic Disease by Amniocentesis During the Second Trimester of Pregnancy.* Report no. 5.

Milunsky, A. and Atkins, L. (1974): Prenatal diagnosis of genetic disorders, an analysis of experience with 600 cases. *J. Amer. med. Ass., 230,* 232–235.

Milunsky, A. (1976): Prenatal diagnosis of chromosomal mosaicism. *J. Pediat., 88,* 365–366.

Munk-Andersen, E., Weber, J. and Mikkelsen, M. (1977): Amniocentesis in prenatal diagnosis. A controlled series of 78 cases. *Clin. Genet., 11,* 18–24.

Niermeijer, M.F. (1975): *Prenatal Diagnosis of Congenital Diseases.* Pasmans, Den Haag.

Prescott, G.H., Pernoll, M.L., Hecht, F. and Nicholas, A. (1973): A prenatal diagnosis clinic: an initial report. *Amer. J. Obstet. Gynec., 116,* 942.

Rauskolb, R., Fuhrmann-Rieger, A., Fuhrmann, W. and Jovanovic, V. (1978): Hautdefekte bei Neugeborenen oder Feten als fragliche Verletzungsfolgen nach Amniozentese in der Frühschwangerschaft. *Geburtsh. u. Frauenheilk., 38,* 107.

Robinson, A., Bowes, W., Droegemueller, W., Puck, M., Goodman, S., Shikes, R. and Greenshur, A. (1973): Intrauterine diagnosis: potential complications. *Amer. J. Obstet. Gynec., 116,* 937.

Schmid, W. (1975): A technique for in situ karyotyping of primary amniotic fluid cell cultures. *Humangenetik, 30,* 325–330.

Shapiro, S., Jones, E.W. and Densen, P.N. (1962): A life table of pregnancy terminations and correlations of fetal loss. *Milbank Mem. Fd Quart., 40,* 7.

Sutherland, G.R., Bowser-Riley, S.M. and Bain, A.D. (1975): Chromosomal mosaicism in amniotic fluid cell cultures. *Clin. Genet., 7,* 400-404.

Verjaal, M., Treffers, P.E., Nagai, Y. and Leschot, N.J. (1978): Prenatal diagnosis of a de novo Y/22 translocation. *J. med. Genet.* In press.

Wahlström, J., Bartsch, F.K. and Lundberg, J. (1974): Prenatal chromosome determination. A study of 219 cases. *Clin. Genet., 6,* 184–191.

Ward, A.M. and Stewart, C.R. (1974): False positive results in antenatal diagnosis of neural tube disorders. *Lancet, 2,* 345.