Journal of the Neurological Sciences, 1979, 43: 367–375

CALCIUM DEPOSITS IN THE PERINEURIUM AND THEIR RELATION TO LIPID ACCUMULATION

J. M. J. VAN LIS*, F. G. I. JENNEKENS and H. VELDMAN

Laboratory for Neuromuscular Diseases, Department of Neurology, State University Hospital, Utrecht (The Netherlands)

(Received 29 March, 1979)
(Accepted 23 April, 1979)

SUMMARY

Calcification of the perineurium in sural nerves occurs in human adults. Deposits of calcium salts can be found focally in the middle and outer layers of the perineurium. Evidence indicates that this calcification is related to nerve fibre breakdown and to the local presence of lipids in the perineurium. The origin of the lipids may be senescent cells or degradation myelin.

INTRODUCTION

Intensive metastatic calcification was observed by Paetau and Haltia (1976) in the perineurial sheaths of the sural nerve from a 33-year-old woman with end-stage diabetic nephropathy. Johnson et al. (1978) noticed the presence of calcium salts in perineurial sheaths of diabetics but the phenomenon was not considered to be specific for this disorder.

The present study was initiated by the chance observation of calcium salts in the perineurium of a patient with olivopontocerebellar atrophy. An investigation was conducted on the occurrence of calcium salts in normal and pathological nerves. Since lipids are thought to be involved in dystrophic calcification of tissue (Anderson 1976) the possible association of calcium salts with lipid material was studied.

The results indicate that calcification of perineurial sheaths in sural nerves occurs in adults. It is related to degeneration of nerve fibres and probably to the local presence of lipids in the perineurium.

* Present address: Landslaboratorium Aruba, Aruba.
This study was supported in part by the Prinses Beatrix Fonds.

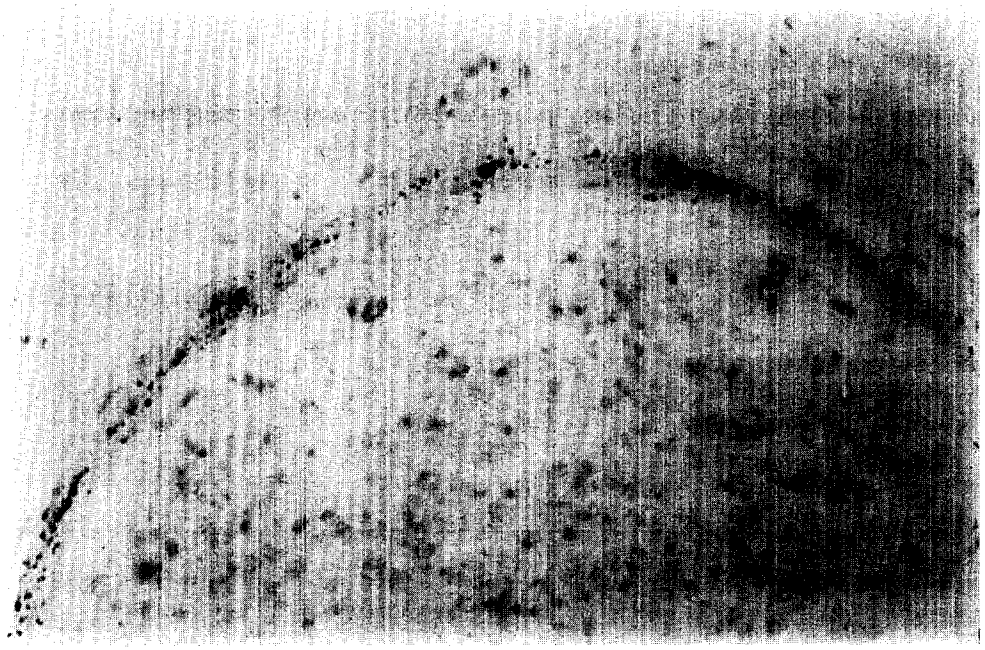

Fig. 1. Transverse section of sural nerve from case 16. There is a granular product in the middle and outer layers of the perineurium. Alizarine red S, × 320.

MATERIALS AND METHODS

Sural nerve biopsies from 23 patients were snap frozen in isopentane which had been cooled in liquid nitrogen, and kept at —90 °C until use. Transverse, 8-μm cryostat sections were stained for the presence of calcium salts both with the von Kossa and with the Alizarine red S method (Pearse 1972). Rinsing with an acid–ethanol solution in the Alizarine red S method was omitted, because this treatment did not give better staining results. Both methods are known to be not wholly specific for calcium salts. Therefore, the glyoxal bis-(2-hydroxyanil) or GBHA method was used on freeze-substituted material (Ganter and Jolles 1970) from two biopsies.

Magnesium salts were localized according to the Titan yellow method and ferric salts according to the Perls' method (Pearse 1972). Lipids were localized with Sudan black B and oil red O. Routine stainings included silver impregnation according to Glees–Marsland, haematoxylin and eosin, toluidine blue, PAS, Congo red and acid phosphatase techniques. Nerve fibres were teased from most biopsies and quantitative studies were performed on several biopsies. If these routine histological and histochemical methods did not reveal any obvious pathological change, a biopsy was judged to be non-pathological.

For electron microscopy tissues from 3 cases were fixed in 2% glutaraldehyde in 0.1 M cacodylate buffer containing 0.01 M $CaCl_2$, pH 7.4, postfixed in 1% osmium tetroxide and embedded in epon 812. Thin sections were stained with lead citrate, or with uranyl acetate and lead citrate and viewed in an electron microscope (Siemens Elmiskop 1).

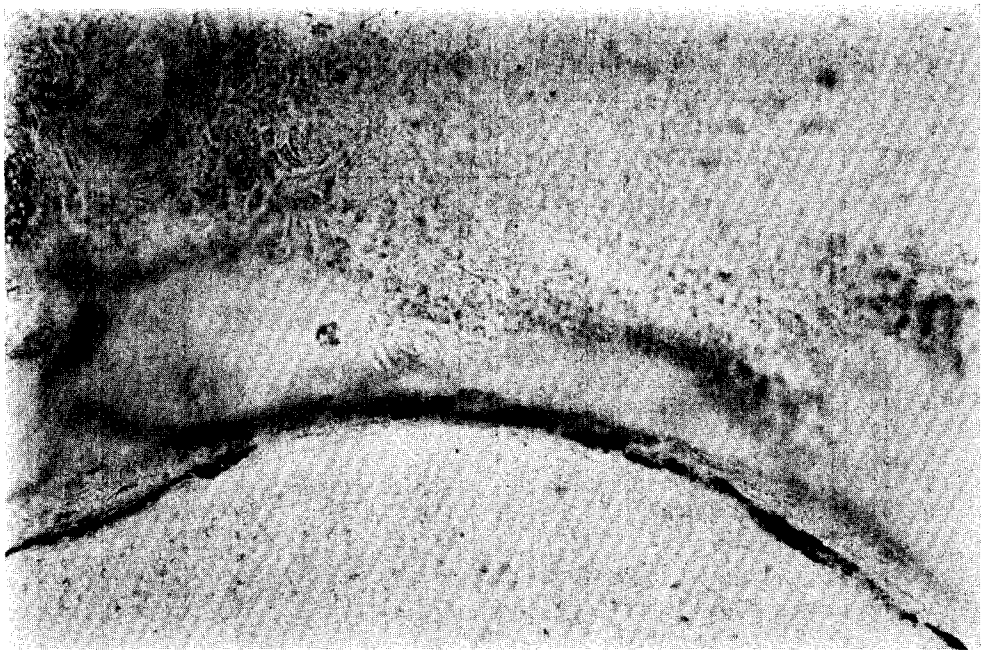

Fig. 2. Transverse section of sural nerve from case 16. Calcium deposits in the perineurium. A similar staining pattern as in Fig. 1. GBHA, × 320.

RESULTS

The von Kossa as well as the Alizarine red S staining methods demonstrated a granular material in the middle and outer layers of the perineurial sheaths in most nerve biopsies (Fig. 1). Staining by the GBHA method of sections from cases 14 and 15 was less pronounced but showed a similar pattern to the two other methods (Fig. 2). Calcium deposits were found in perineurial sheaths of individuals of 16 years or older irrespective of the presence or absence of nerve fibre pathology (Table 1). Calcium staining was negative in younger subjects with the exception of the Alizarin red S staining in a case of chronic inflammatory neuropathy. An obvious increase with advancing age was not observed, though it could not be excluded.

The staining pattern of the perineurial sheaths was not continuous but focal (Figs. 1 and 3). Moreover, in each section the fascicles showed a significant variation in the presence or absence of staining of the perineurial sheaths (Fig. 3). As the number of biopsies without obvious pathological changes was limited, the relation between calcium deposits in the perineurial sheaths and nerve fibre breakdown could not be investigated sufficiently. Positive calcium staining in subjects without nerve fibre pathology (cases 4–8) was, however, less pronounced than in subjects of comparable age (cases 12–15) with nerve fibre pathology. In most cases endoneurial and epineurial spaces did not show calcium deposits, except in the media and to a lesser degree in the intima of epineurial arteries. The arteries did not contain calcium deposits in biopsies from individuals younger than 16 years. Staining for magnesium and ferric salts was

TABLE 1

LOCALIZATION OF CALCIUM SALTS AND LIPIDS IN NERVE BIOPSIES

No.	Age (yr)	Sex	Clinical diagnosis[a]	Presence of calcium[b]				Presence of lipids[c]	
				Epineurial vessels		Perineurium		Perineurium	
				VK	AZR	VK	AZR	ORO	Sudan
Non-pathological									
1	18/12	m	Nemaline myopathy	—	—	—	—	—	—
2	8	m	Duchenne dystrophy	—	—	—	—	—	—
3	16	m	myoclonus epilepsy	—	—	—	+	—	—
4	19	m	asymmetric neuropathy	—	—	—	+	—	—
5	19	f	abnormal gait	—	—	+	+	—	—
6	36	f	pes cavus	—	+	+	+	—	—
7	42	m	vitamin B_{12} deficiency	—	+	+	+	+	+
8	43	m	myelopathy	—	+	—	+	+	+
Pathological									
9	13/12	m	Krabbe's disease	—	—	—	—	—	—
10	4	m	HMSN type III	—	—	—	—	—	—
11	6	m	chron. inflamm. neuropathy	—	—	—	+	—	—
12	7	f	HMSN type I	—	—	—	—	—	+
13	16	m	HMSN type I	+	+	+	+	—	+
14	28	m	uremia and intoxication	—	+	+	+	+	+
15	35	m	HMSN type II	—	+	+	+	—	+
16	39	m	vitamin E deficiency	—	—[d]	+	+	—	+
17	54	m	polyneuropathy	+	+	+	+	+	+
18	54	m	sensory neuropathy, syphilis	—	—[d]	+	+	+	+
19	55	f	HMSN type II	—	+	+	+	+	+
20	56	m	polyneuropathy	—	—	+	+	+	+
21	57	m	polyneuropathy	+	+	+	+	—	+
22	58	m	Wegener's granulomatosis	+	+	+	+	+	+
23	58	m	HMSN type II	+	+	+	+	—	—
24	68	m	olivopontocerebellar degeneration	—	—	+	+	—	+
25	71	m	sensory neuropathy, ALS	+	+	+	+	+	+

[a] HMSN, hereditary motor and sensory neuropathy (nomenclature according to Dyck 1975).
[b] Presence (+) or absence (—) of calcium salts in epineurial blood vessels and perineurium, according to the von Kossa (VK) and Alizarine red S (AZR) method.
[c] Presence of lipids in perineurium, according to the oil red O (ORO) and Sudan black B (Sudan) method.
[d] Also in the epineurium outside the blood vessels.

always negative. Staining with oil red 0 and especially Sudan black B showed the presence of lipids in the perineurium in most cases in which calcium deposits were demonstrated (Table 1). Staining of serial sections with Sudan black B and Alizarine red S showed that lipids were located in areas where calcium deposits were present (Fig. 3).

Three biopsies (cases 13, 14 and 22) which showed heavy calcium deposits were

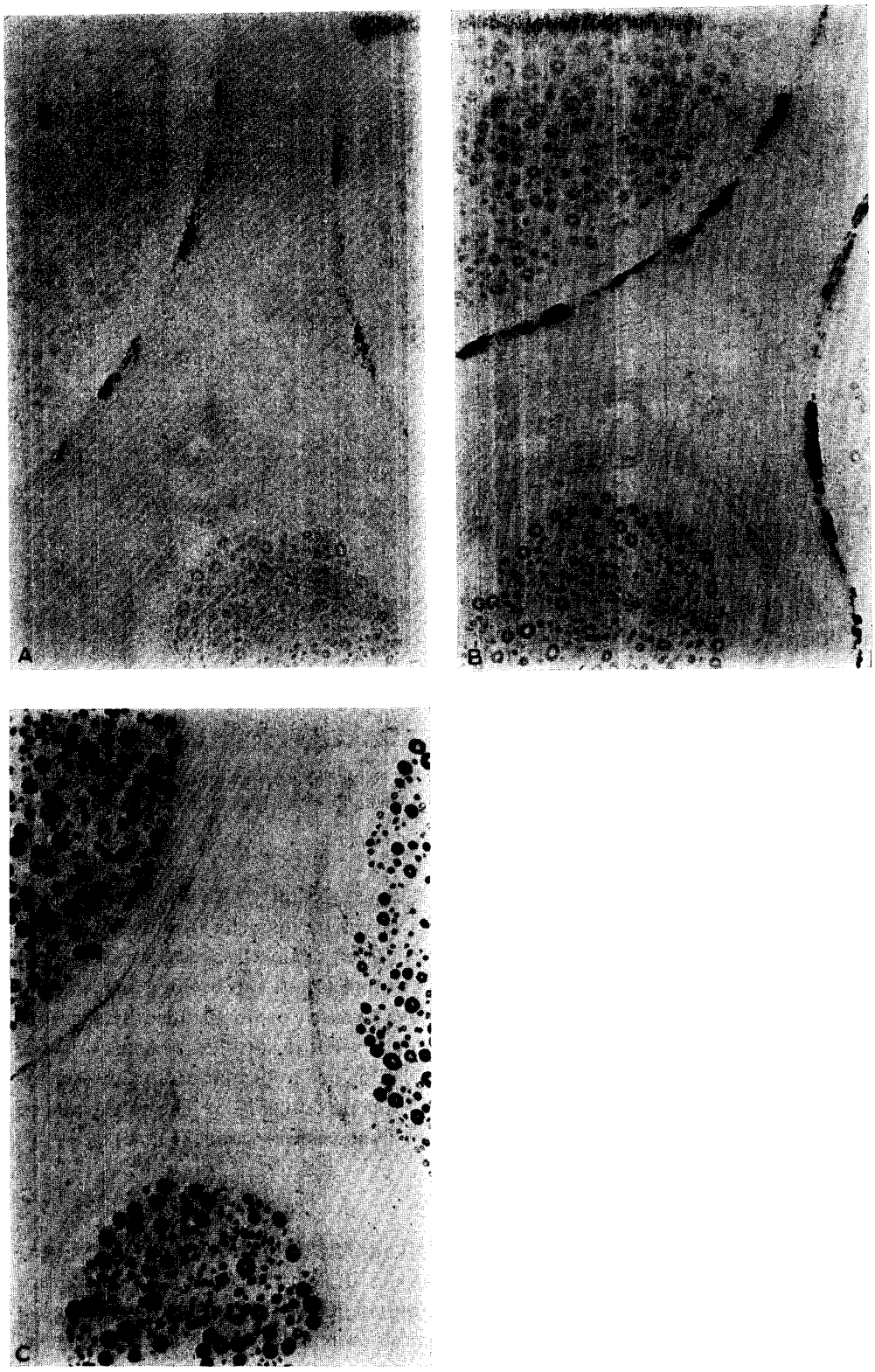

Fig. 3. Serial transverse sections of sural nerve from case 15. *A*: focal staining of the perineurial sheaths. von Kossa, × 256. *B*: focal staining of the perineurial sheaths. The staining pattern has changed. Alizarine red S, × 256. *C*: lipid is present in perineurial sheaths containing calcium deposits. Sudan black B, × 256.

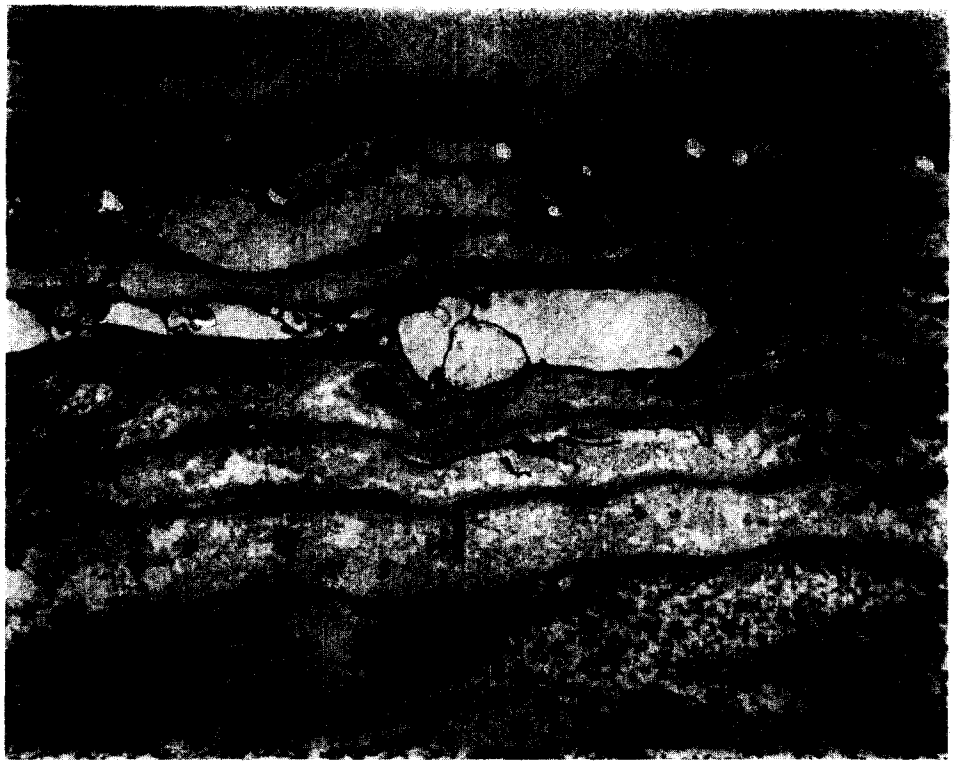

Fig. 4. Electron micrograph of perineurium from case 16. Round holes, partly filled with electron-dense material are present between middle and outer perineurial cell layers. The cutting artifacts are due to the callousness of this material. Lead citrate, × 5400.

investigated ultrastructurally. In thin sections stained routinely with uranyl acetate and lead citrate a number of usually empty holes varying in diameter from 0.2 to 1.6 μm were observed between perineurial cell layers. When section thickness was increased from 700 Å to 900 Å, and when staining with uranyl acetate was omitted and washing solutions kept at pH 9.0, many holes appeared to be partly or wholly filled by electron-dense masses. These were difficult to cut as shown by cutting artifacts arising at the site of the holes (Fig. 4). The edges of this material often had a spicular or thready appearance suggesting that they contained crystals of calcium salts (Fig. 5). The holes could be well discerned in light microscopy of toluidine blue stained sections (Fig. 6).

DISCUSSION

The specificity of the histochemical methods for calcium localization have been discussed in detail elsewhere (Ganter and Jolles 1970; Pearse 1972; Chaplin and Grace 1976; Bodensteiner and Engel 1978). Briefly, the von Kossa silver nitrate procedure is a metal-substituting method demonstrating anions such as phosphates and carbonates. In humans these anions are nearly always associated with calcium. The Alizarine red S method forms a stained adsorption compound with soluble and insoluble calcium salts.



Fig. 5. Electron micrograph of dense material in round holes between perineurial cell layers of sural nerve from case 22. The rims of this material show a spicular or thready appearance. Uranyl acetate and lead citrate, × 54,000.

Salts of other elements may be stained as well but they do not show the same color (Be, Hg, Sr, etc.) or are unlikely to be present regularly in substantial amounts in human peripheral nerves (Ba, Sr, Be, Cd, etc.). Ferric ions were shown not to be present in this material. GBHA forms red complexes with calcium ions. The method as used in this study is a sensitive, specific but inconsistent indicator of calcium salts (Chaplin and Grace 1976).

In many biopsies of peripheral nerves histochemical evidence for the presence of focal deposits of calcium salts was found. The deposits were observed in adults in the middle and outer layers of the perineurium both in cases with and without neuropathic changes. Electron microscopy showed that a hard material with a crystalline organization — presumably calcium salt — was present within electron-dense masses. It is known that calcium salt deposits are lost easily during processing for electron microscopy (Scherft 1978). When adequate precautions were taken, the electron-dense masses were much more frequently seen.

A similar but less heavy, also age-related calcium deposition was observed in epineurial arterioles. Calcification of arteries has been studied intensively. Calcification of human aortic media and to a lesser degree of aortic intima occurs commonly (Blu-

Fig. 6. Transverse section of sural nerve from case 22. Round empty holes between middle and outer layers of the perineurium. Toluidine blue, × 1000.

menthal et al. 1944; Kim and Trump 1972). Aortic calcification begins in the young and increases progressively with advancing age.

There is increasing evidence that lipids are involved primarily in calcification of various tissues, including both the aortic media and valve (Anderson 1976; Kim 1976). Sell and Scully (1965) showed that lipid accumulation in mitral valves and aortic valves precedes calcification. Our results indicate that accumulation of lipid material in the perineurium is age-related. The time of onset is uncertain. In a few biopsies calcium staining was positive while lipids could not be demonstrated. In other cases, however, serial sectioning showed an association of calcium deposits with lipids when these substances were both present. As pointed out by Kim et al. (1976) lipids may correspond structurally with membraneous vesicles from senescent and degenerate cells. In the perineurium these cells may be fibroblasts (Burkel 1967; Thomas and Jones 1967) or macrophages as seen in pathological conditions (De la Motte et al. 1975). Lipid material may also originate from myelin that has been broken down in the endoneurium and then transported into the sheath (Van Lis et al. 1979).

The mechanism of calcification of these cellular degradation products is not clear. It may be the result of several predisposing factors: (1) Presence of lipids absorbing a large amount of calcium ions from the perineurial extracellular fluid. (2) A high concentration of calcium and phosphate ions in the perineurium. Accumulation of calcium and phosphate ions in the sheath may be related to its function as a diffusion barrier to these ions (Causey and Palmer 1953; Martin 1964; Ochs et al. 1977). (3) Local presence of ATPase and alkaline phosphatase activity (Shanthaveerappa and Bourne 1962).

ACKNOWLEDGEMENTS

The authors are indebted to Dr. J. Koudstaal, Dr. J. P. Scherft and Dr. W. J. Visser for helpful discussions and advice, and to Mr. H. J. W. Eelderink for histochemistry and photography.

REFERENCES

Anderson, H. C. (1976) Matrix vesicle calcification, *Fed. Proc.*, 35: 105–108.

Blumenthal, H. T., A. I. Lansing and P. A. Wheeler (1944) Calcification of the media of human aorta and its relation to intimal arteriosclerosis, ageing and disease, *Amer. J. Path.*, 20: 665–687.

Bodensteiner, J. B. and A. G. Engel (1978) Intracellular calcium accumulation in Duchenne dystrophy and other myopathies — A study of 567,000 muscle fibers in 114 biopsies, *Neurology (Minneap.)*, 28: 439–446.

Burkel, W. E. (1967) The histological fine structure of perineurium, *Anat. Rec.*, 158: 177–190.

Causey, C. and E. Palmer (1953) The epineurial sheath of a nerve as a barrier to the diffusion of phosphate ions, *J. Anat. (Lond.)*, 87: 30–36.

Chaplin, A. J. and S. R. Grace (1976) An evaluation of some complexing methods for the histochemistry of calcium, *Histochemistry*, 47: 263–269.

De la Motte, D. J., S. M. Hall and G. Allt (1975) A study of the perineurium in peripheral nerve pathology, *Acta neuropath. (Berl.)*, 33: 257–270.

Dyck, P. J. (1975) Inherited neuronal degeneration and atrophy affecting peripheral motor, sensory, and autonomic neurons. In: P. J. Dyck, P. K. Thomas and E. H. Lambert (Eds.), *Peripheral Neuropathy*, Saunders, Philadelphia, London, Toronto, pp. 190–200.

Ganter, P. and G. Jolles (1970) *Histochemie — Normale et Pathologique*, Gauthier-Villars, Paris, pp. 1662–1664.

Johnson, P. C., M. P. Yoshima and J. A. Gaines (1978) Thickening of the perineurial cell basement membrane in diabetes and aging. Cited in: A. K. Asbury and P. C. Johnson (Eds.), *Pathology of Peripheral Nerve*, Saunders, Philadelphia, London, Toronto, p. 190.

Kim, K. M. (1976) Calcification of matrix vesicles in human aortic valve and aortic media, *Fed. Proc.*, 35: 156–162.

Kim, K. M. and B. F. Trump (1972) Calcification of human aortic media — An electron microscopic study, *Circulation*, 46: Suppl. II, p. 176.

Kim, K. M., J. M. Valigorsky, W. J. Mergner, R. T. Jones, R. F. Pendergrass and B. F. Trump (1976) Aging changes in the human aortic valve in relation to dystrophic calcification, *Human Path.*, 7: 47–60.

Martin, K. H. (1964) Untersuchungen über die perineurale Diffusionsbarriere an gefriertrockneten Nerven, *Z. Zellfrosch.*, 64: 404–428.

Ochs, S., R. M. Worth and S. Y. Chan (1977) Calcium requirement for axoplasmic transport in mammalian nerve, *Nature (Lond.)*, 270: 748–750.

Paetau, A. and M. Haltia (1976) Calcification of the perineurium – A case report, *Acta neuropath. (Berl.)*, 36: 185–191.

Pearse, A. G. E. (1972) *Histochemistry*, 3rd edition, Churchill Livingstone, Edinburgh, London.

Scherft, J. P. (1978) Personal communication.

Sell, S. and R. E. Scully (1965) Aging changes in the aortic and mitral valves, *Amer. J. Path.*, 46: 345–365.

Shantaveerappa, T. R. and G. H. Bourne (1962) The perineurial epithelium, a metabolically active, continuous, protoplasmic cell barrier surrounding peripheral nerve fasciculi, *J. Anat. (Lond.)*, 96: 527–537.

Thomas, P. K. and D. G. Jones (1967) The cellular response to nerve injury, Part 2 (Regeneration of the perineurium after nerve section), *J. Anat. (Lond.)*, 101: 45–55.

Van Lis, J. M. J., H. Veldman and F. G. I. Jennekens (1979) In preparation.