J. max.-fac. Surg. 12 (1984) 193–200

The Influence of Age at Operation for Clefts on the Development of the Jaws

Peter Blijdorp, Peter Egyedi

Department of Maxillofacial Surgery (Head: Prof. Dr. P. Egyedi, M.D., D.M.D.), State University of Utrecht, The Netherlands

Accepted for publication 29. 12. 1983

Summary

In this follow-up study of adult cleft patients with a unilateral cheilognathopalatoschisis, the effect on maxillo-mandibular development of the age at which the palatoplasty had been performed was investigated.
It was concluded that it makes little difference whether the hard palate is closed at the age of 3 or 6 years.

Key-Words

Cleft – Palatoplasty age – Jaw development

Introduction

In the unoperated cleft patient there is a dento alveolar malposition. In the case of a unilateral total cleft, this manifests itself as a cross-bite in the molar region and under-eruption of the cuspid, and sometimes of the lateral incisor as well (*Bishara* et al., 1976, 1978). Otherwise the general development of the maxilla and mandible proceeds normally as reported, among others, by *Van Limborgh* (1964), *Pitangui* and *Franco* (1967), *Ross* and *Johnston* (1972), *Balan* and *Stellmach* (1973). From this we may deduce that the intrinsic growth potential of the tissue in the cleft patient is on the whole fair, and that the inhibition of growth in the operated patient should, on the whole, not be attributed to the primary deficiency of tissue but to the surgical trauma at an early age. Admittedly, *Veau* (1931), writing on compression of the upper arch, writes: "Pour ma part, sur 500 staphylorraphies, que je rapporte plus loin, je n'ai pas observé un seul cas de rétraction cicatricielle et j'opère dans le très jeune age" and *Morley* (1966) states: "growth, however, may be stimulated by appropriate surgery if carried out in early life, etc.", but they fail to mention any relevant investigations and their statements should therefore be received critically. Accordingly, we persist in our assumption that apart from a primary tissue deficiency surrounding the cleft itself, the development of the palatal halves is largely normal, unless operation is performed. The primary tissue deficiency constitutes an unchangeable fact in each individual patient. What is variable is the surgical trauma.
For this reason, many surgeons have devised techniques and surgical techniques to reduce the damage inflicted to a minimum in order to avoid impairment of cranial growth. Consequently, in the surgical treatment of cleft patients, two main trends can be distinguished.
One trend attaches major importance to the social aspects, speech and hearing, and accordingly prefers to operate at any early stage (e.g. *Trusler* et al., 1955; *Kilner*, 1958; *Honig*, 1964; *Stark*, 1968), whereas others take the stand that operating on a growing maxilla should, in principle, be avoided, and close the hard palate at a later age (e.g. *Schweckendiek*, 1955; *Widmaier*, 1966; *Hotz* and *Perko*, 1974; *Perko*, 1979; *Hotz* and *Gnoinski*, 1979).
In this follow-up study, cranial growth and the dento-alveolar relations were evaluated in two groups of patients who had been subjected to operation on the hard palate at the age of approx. 3 (group A) and of approx. 6 years (group B). During this period, the growth of the palate and alveolar process creates space for the first molar (*Salzmann*, 1966).
In the sagittal direction this would amount to a little more than 10 mm (*Sicher*, 1952). In non-cleft Europeans this is just less than half the total growth after the 3rd year of life. Were the growth to be disturbed after the age of 6, growth between 3 and 6 years would be even more important. This may also be deduced indirectly from data presented by *Narula* and *Ross* (1970) who, in a group of operated cleft patients (cheilognathopalatoschisis duplex totalis), observed an increase in length of the maxilla by 12.2 % after the age of 6. Postulating a length of 56.3 mm in the 6-year-old, their figures indicate growth in this category of almost 7 mm after the age of 6, which seems very little. Admittedly, in unilateral clefts the situation is different, but there are no reasons to assume that the order of magnitude of maxillary growth after the age of 6 is greatly different. In this connection, it may be pointed out that this estimate is not in accordance with the findings obtained by *Sillman* (1964) in *normal* children, in whom a considerably larger percentage growth was still recorded after the age of 6. *Moorees* (1959) also reports different figures for non-cleft children. Undoubtedly the best criteria are the size of the teeth, the gain of space after the shedding of the deciduous molars and the lack of space for the (2nd and) 3rd molar, as well as the closure of the diastemata in the primary dentition.
Analysis of all these data together suggests that in all probability, approximately one-half of growth after the age of 3 occurs during the period between 3 and 6 years, at any rate in the operated cleft patient. If there were a significant influence of the operation on the development of the maxilla, a difference in jaw size between the two groups ought to be observed: postponement of the operation from 3 to 6 years would allow undisturbed growth for 3 extra years.

Clinical Material

The groups studied consisted of patients of the University Clinic for Maxillofacial Surgery, University Hospital, Utrecht.
In this clinic, between 1945 and 1965, over 2500 patients with primary cheiloschisis, some of them with, others without gnathopalatoschisis, were treated. In addition, there were a large number of patients with isolated palatoschisis. Nearly all these patients were operated on by the head of the department, Prof. J. W. A. Tjebbes. The surgical tech-

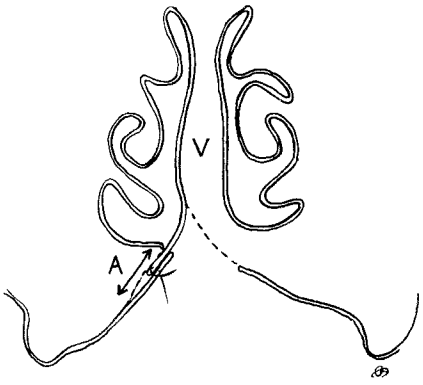

Fig. 1

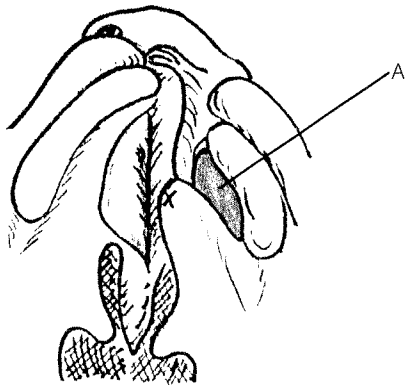

Fig. 2

Fig. 1 Depiction of the vomerine flap used to close the anterior part of the hard palate during the first operation.
Note: small area of raising of palatal mucosa at A.
V = Vomer
A = Area of denuded palatal bone

Fig. 2 Drawing of the Veau type anterior palatal closure during lip surgery
A = Area of denuded palatal bone

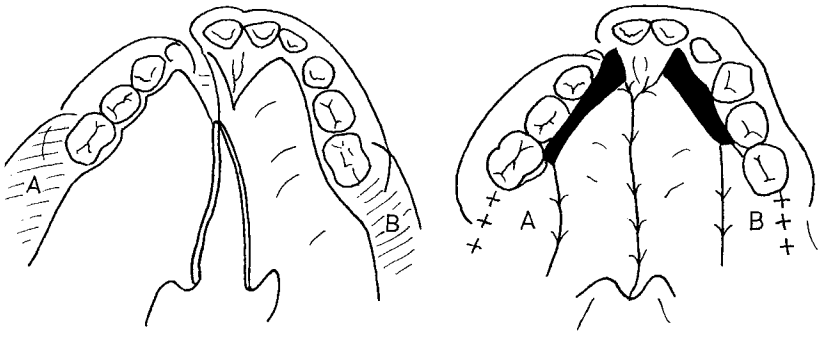

Fig. 3

Fig. 3 Depiction of closure of posterior palate during second operation. Partial covering of denuded palatal bone by flap A and B.

nique was not changed during this period. For this follow-up, adult (c.q. fully grown) patients who during childhood had been operated on by Prof. Tjebbes, were recalled.
Two groups of patients with total unilateral cleft lip, jaw and palate were formed: 51 who had had palate operations when approximately 3, and 54 operated on when approximately 6 years of age. In principle, the surgeon wanted to operate on all palates at the age of approximately 2.5 years (after eruption of all deciduous molars), but his heavy caseload forced him to postpone the operation in a fairly large number of cases until approximately the age of 6. In other words, there has been no selection of material by the surgeon. The two groups of patients discussed in this paper are therefore in all probability comparable, with only one variable element: the age at operation on the palate.

The Surgical Technique applied Considered in Relation to Maxillary Growth

Operation of the lip and the gnathoschisis.
It is generally accepted that the cheiloplasty affects the growth of the anterior portion of the alveolar process of the maxilla (*Onizuka* and *Isshiki*, 1975; *Eisbach* et al., 1978). Since the principal growth occurs further dorsally, its influence on jaw size is not very great. During the cheiloplasty, which was performed around the age of 3 months, in our series of patients the surgeon also closed the gnathoschisis and the anterior portion of the palatoschisis. This was achieved by suturing a vomerine flap (*Veau*, 1938) beneath the mucoperiostal edge of the palate, elevated only over a short distance, on the side of the cleft (see fig. 1), in other words, a single layer closure. In this respect the technique differed from *Veau*'s, in which the palatal mucosa on the side of the cleft was mobilized in its entirety and sutured it across the cleft, thereby establishing a double closure (except in the alveolar region) (see fig. 2).
Accordingly, *Tjebbes* exposed the palatine bone in babies to a far lesser extent than *Veau*.

Operation on the palate.
This was carried out approximately according to the *Ganzer* (1920) – *Veau-Ruppe* (1922) (VY-pushback) technique (see fig. 3). On completion of the operation an iodoform-vaseline gauze-lined plate was inserted and fixed to the teeth. This plate pressed the palatal mucosa against the underlying bone and fixed it in a dorsal position. The plate was removed after 7 days. A point to be noted in the early-operation group is that operation was only performed after complete eruption of the decidous dentition. In the case of a wide cleft, much denuded bone was exposed laterally on the palate. Fairly often, this was partially covered with a rotation flap with a dorsal pedicle, taken from the vestibule dorso-lateral to the last deciduous molars (see fig. 3). In a small number of patients from both groups, reoperation of

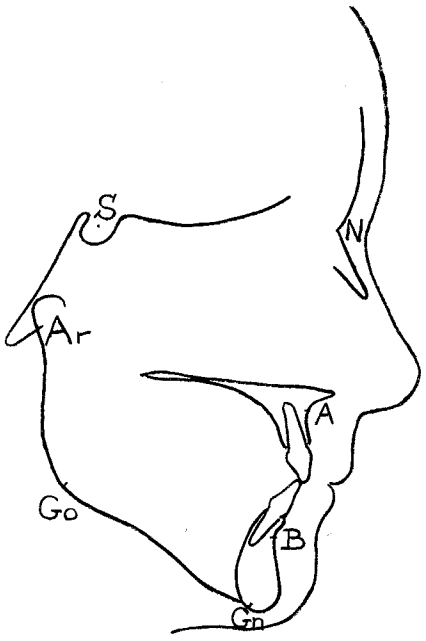

Fig. 4 The landmarks used in the cephalometric analysis of the patients.

oro-nasal fistulae was necessary. This was never done by means of complete mobilization of the palatal mucosa but always by means of small local flaps.

Pharyngoplasty
The technique is described in a paper on the logopaedic findings in the same group of patients (*Blijdorp* and *Müller* – in press).

Methods of Examination*

Maxillary bone and dental arch
A cephalometric X-ray and an orthopantomogram (O.P.T.) were made of every patient. The former yielded cephalometric values of interest for the investigation. The following landmarks were used: (fig. 4)
A: Anterior delimitation of the apical base of the maxilla. This corresponds to the lowest point of the curvature between the spina nasalis anterior (S.N.A.) and the prosthion. Locating point A is difficult, especially in the cleft patient. In the cleft patient, the suture of the intermaxillary bone is turned toward the side of the cleft. For point A, the point furthest ventrally was always used.
Ar: Articulare. This is defined by the point of intersection of the contours of the posterior border of the ascending ramus of the mandible and the lower surface (pars basilaris) of the occipital bone. This point is not actually present on the skull. It was introduced by *Björk* (1974).
B: Anterior delimitation of the apical base of the mandible. This corresponds to the deepest point of the anterior aspect of the outline of the chin.
Gn: Gnathion. The furthest caudal point of the lower edge of the symphyseal contour.
Go: Gonion. The point of intersection of the tangent at the posterior border of the ramus and the tangent along the symphysis and masseteric protuberance.
N: Nasion. This is the point on the frontonasal suture situated in the median plane.
S: Sellar point. Centre of the sella turcica.
SNA: Sagittal position of the maxilla in relation to the base of the skull. (Not to be confused with the abbreviation of spina nasalis anterior.)
SNB: Sagittal position of the mandible in relation to the base of the skull.
NSAr: The angle of the base of the skull. According to *Hotz* and *Dietrich* (1969), the angle of the base of the skull constitutes a criterion of underdevelopment of the maxilla, and permits distinction between genuine mandibular prognathism and pseudoprognathism.
ArGoGn: The angle of the angulus mandibulae.
On the orthopantomogram, a tangent to the plane of occlusion was drawn. The shortest distance from this plane to the tip of the cuspid on the side of the cleft was an indication of the degree of under-eruption of the cuspid (fig. 5).

The plaster cast analysis was used to check the measurements and the occlusion observed in the patient. No significant differences between measurements were found, but if there were any, the observation in the chair was always accepted as the correct one.
The measurements were carried out as follows:
In the upper and the lower jaw, the distances between the lowest points of the marginal gingiva of the first premolars were measured and compared. In principle, the same was done with the first molars, with the difference that here the landmarks used were the prolongation of the palatine fissure into the marginal gingiva in the upper jaw, and the prolongation of the lingual fissure into the marginal gingiva in the lower jaw (fig. 6).

Soft parts
The soft parts largely follow the bony skeleton (*Henderson*, 1974; *Steinhäuser*, 1974). Naturally, we should not limit ourselves to cephalometric radiography but also look at the profile. A criterion very easy to apply is the lip line: by a negative lip line we mean the situation where the lower lip lies too far ventrally, by a positive lip line the situation where the lower lip is situated too far dorsally (fig. 7).
Other elements taken into account were scar formation and the appearance of the lip (tightness).
For the purpose of comparison of the two age groups, the two last-mentioned criteria proved to be of little interest.
The function of the lip was also considered.
During the closure of the lip, the sphincter action of the orbicularis muscle is restored as much as possible by suturing this muscle separately with catgut in order to regain a continuous sling. This (sphincter) function is of importance when the patient is requested to raise the pressure in the oral cavity and to blow into a tube attached to the manometer (fig. 8). The sphincter function may also play a part with regard to the position of the incisors. When air escaped past the tube, this function was classified as inadequate. A study of the effect of this inadequacy on occlusion was later found to be outside the scope of this investigation, and will be published separately later.

*see also *Blijdorp* and *Cornelissen* (1977)

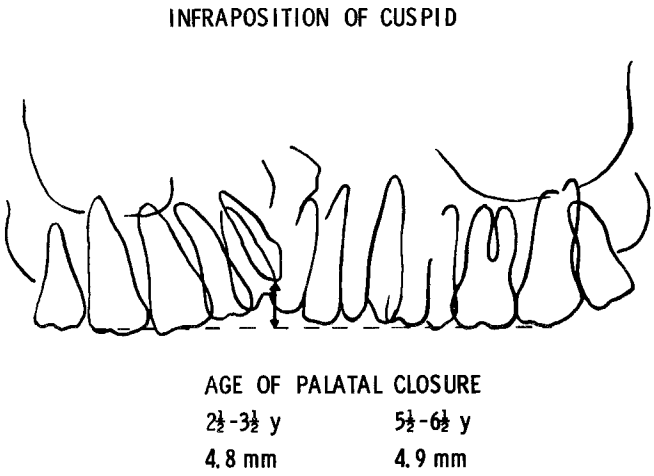

Fig. 5a Depiction of measurements on the orthopantomogram of position of the cuspid, including the results.

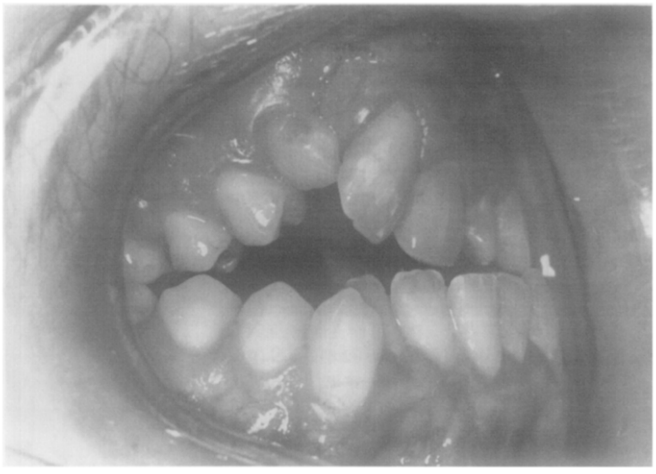

Fig. 5b Example of marked infraposition of cuspid and first premolar in cleft area.

Fig. 5c Example of very satisfactory position of cuspid in cleft area. This case represents the best result obtained. Orthodontic treatment had been given.

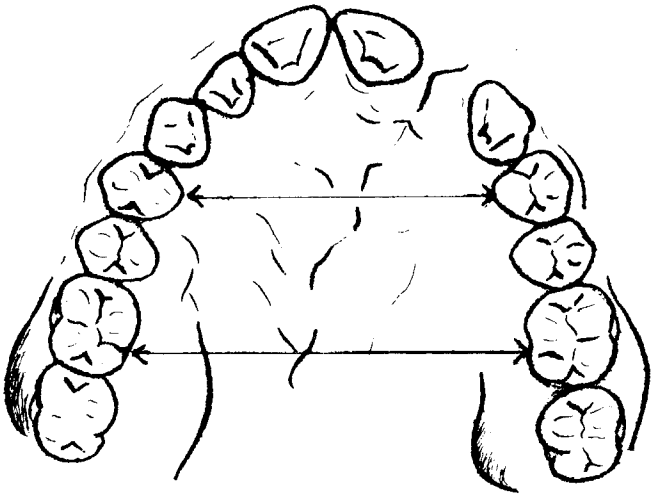

Fig. 6 Method of measuring the compression of the dental arch.

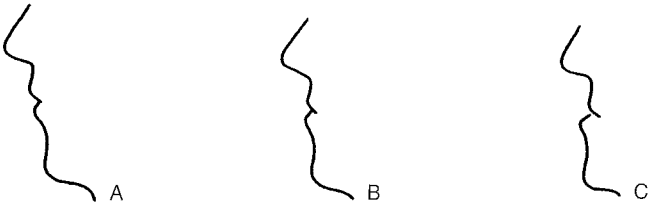

Fig. 7 The different types of lip relation referred to in the article.
A. negative lip step
B. neutral lip step
C. positive lip step

Hard palate

The hard palate has already been inspected during determination of the compression of the upper jaw and the Angle classification.

At this stage, special attention was given to oro-nasal fistulae. The simplest method, better than the most thorough inspection with a probe, is to request the patient to take a little water into his mouth and to try to force water through the fistula into the nose. The examiner should, however, be on his guard against a false positive reaction owing to palatal inadequacy.

Results

Maxillary bone and dental arch

Evaluation of the cephalometric X-ray (table 1).

The measurements of the angle of the base of the skull gave an average value considerably higher than the normal value in unaffected persons. The mean SNB angle was slightly smaller in group B than in group A. The mean value for both groups was lower than the normal value, indicating retrognathia of the mandible. This is in accordance with papers published earlier by *Hayashi* et al. (1973), *Mowbray* (1975) and *Vora* and *Joshi* (1977).

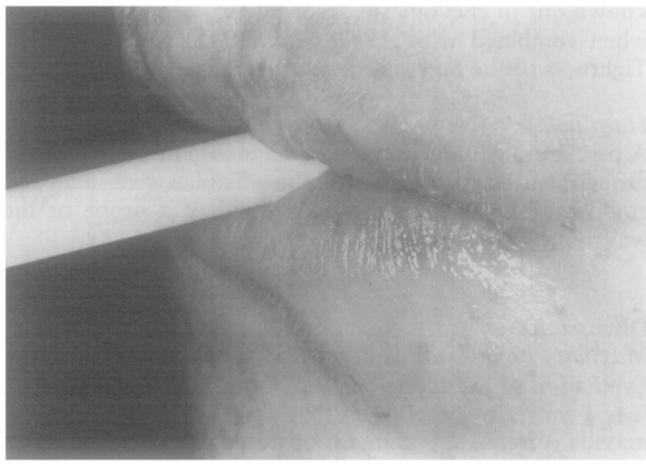

Fig. 8 Illustration of competent sphincter during blowing.

Other authors, however, such as *Korkhaus* (1955) and *Krijgers Janzen* (1961) report a larger proportion of cases of genuine mandibular prognathism in cleft patients.
In agreement with the findings concerning the angle of the base of the skull we found that the mean SNA value was lower than the normal value. Here, again, there was a difference between the two groups studied. In the patients in group B, point A was situated slightly further dorsally. As regards the angle of the mandible (ArGoGn), its mean value was above normal, and the difference between group A and B was slight (figs. 9 a and 9 b).
The assumption may be justified that the mandible has grown on, in a ventral direction, below the apices of the various elements, resulting in a prognathic chin position after all.
Finally, for both groups combined, we studied the influence of the pharyngoplasty on the SNA angle, although this is not actually part of this investigation.
No correlation was found ($p = 0.82$).

At the O.P.T. evaluation, an under-eruption of the cuspid on the side of the cleft was found, of 4.8 and 4.9 mm on the average.

For incisor and molar occlusion according to Angle's classification, the reader is referred to tables 2, 3, 4 and 5. None of these differences were significant (for comparison see tables 6 and 7).

Soft parts
The sphincter function of the orbicularis muscle appeared to be slightly better in the patients in group B ($chi^2 = 2.37$; $p = 0.131$). Also, in this group there were fewer patients with hypertrophic scars of the lip (table 8). As regards the sphincter function, there was air escape in 28 % of group A and 10 % of group B. A positive lip line occurred significantly more often in group B ($chi^2 = 3.90$; $p = 0.048$).
This is in accordance with the results of the cephalometric X-ray evaluation, which proves once again that the soft parts follow the bony skeleton. In either group there were only a few patients with a tight upper lip. Tissue deficiency of the upper lip in the vertical direction was fairly frequent, the percentage is shown in the scheme (table 9). The criteria are shown in figs. 10 and 11). This phenomenon is a well

Table 1 Cephalometric Findings

	normal values	age at palatal closure 2½–3½ years	5½–6½ years	p-value
ArSNa.	122	125.3	126.2	0.38
SNB	79	77.4	76.0	0.12
SNA	82	75.7	74.4	0.16
ArGoGn	125	128.8	130.4	0.20

Table 2 P.O.P. cast analysis relationship of 1st incisors

	age at palatal closure 2½–3½ years number	percentage	5½–6½ years number	percentage	p-value
"Class III" relation	13	26 %	16	32 %	
edge-to-edge relation	7	14 %	12	24 %	
normal relation	23	46 %	19	38 %	0.30
"Class II" relation	7	14 %	3	6 %	
	50		50		

Table 3 P.O.P. cast analysis relationship of 2nd incisors

	age at palatal closure 2½–3½ years number	percentage	5½–6½ years number	percentage	p-value
"Class III" relation	18	37.5 %	18	36 %	
edge-to-edge relation	5	10.4 %	10	20 %	
normal relation	22	45.8 %	20	40 %	0.59
"Class II" relation	3	6.3 %	2	4 %	
	48		50		

Table 4 P.O.P. cast analysis cleft side relationship of 1st molars

	age at palatal closure 2½–3½ years number	percentage	5½–6½ years number	percentage	p-value
Class III	18	36 %	18	36.7 %	
edge-to-edge relation	4	8 %	4	8.2 %	
Class I	19	38 %	22	44.9 %	0.72
Class II	9	18 %	5	10.2 %	
	50		49		

Table 5 P.O.P. cast analysis non-cleft side relationship of 1st molars

	age at palatal closure 2½–3½ years number	percentage	5½–6½ years number	percentage	p-value
Class III	17	34 %	25	51.0 %	
edge-to-edge relation	5	10 %	3	6.1 %	
Class I	20	40 %	17	34.7 %	0.31
Class II	8	16 %	4	8.2 %	
	50		50		

Table 6 P.O.P. cast analysis compression in premolar area

	age at palatal closure 2½–3½ years		5½–6½ years	
mean distance 1st upper premolars		22.65 (A)		22.84 (B)
	s. d.	3.79	s. d.	3.64
mean distance 1st lower premolars		26.45 (C)		26.27 (D)
	s. d.	2.34	s. d.	2.08
(A) – (C)	–	3.82		
	s. d.	3.49		
(B) – (D)			–	3.43
			s. d.	3.44

Wilcoxon Rank Sum Test between the two groups:

2½–3½ years	5½–6½ years	U	Z	two-tailed p.
−3.82	−3.43	1200.0	0.1785	0.4292

corrected for ties

Table 7 P.O.P. cast analysis compression in molar area

	age at palatal closure 2½–3½ years		5½–6½ years	
mean distance 1st upper molars		33.61 (A)		33.29 (B)
	s. d.	3.49	s. d.	4.34
mean distance 1st lower molars		35.40 (C)		36.00 (D)
	s. d.	3.64	s. d.	3.33
(A) – (C)	–	2.06		
	s. d.	3.72		
(B) – (D)			–	2.71
			s. d.	3.90

Wilcoxon Rank Sum Test between the two groups:

2½–3½ years	5½–6½ years	U	Z	two-tailed p.
−2.06	−2.71	1073.5	0.9198	0.3577

Table 8 Analysis of soft tissue pattern

Sphincter function	age at palatal closure 2½–3½ years number	percentage	5½–6½ years number	percentage	p-value
good function	36	70.6 %	45	83.3 %	0.19
appearance of scar: good	32	62.7 %	45	83.3 %	
acceptable	16	33.3 %	9	16.7 %	0.04
poor	2	3.9 %	–	–	

Table 9 Analysis of soft tissue pattern

Lip relationship	age at palatal closure 2½–3½ years number	percentage	5½–6½ years number	percentage	p-value
lip line: positive	19	37.3 %	29	53.7 %	0.13
neutral	32	62.7 %	25	46.3 %	
negative	–	–	–	–	
tight upper lip	3	5.9 %	3	5.6 %	1.0
short upper lip	16	31.4 %	15	27.8 %	0.85

known one in cheiloplasty according to *Veau* (1938), even when combined with *Axhausen's* (1941) triangular flap. Tightness of the lip could not be visualized.

Hard palate

A fistula in the hard palate was diagnosed in 14 patients in group B and 12 in group A. All these fistulae were small and could only be diagnosed with the aid of a probe or the water-into-nose test.

Discussion

Maxillary bone and dental arch.

Evaluation of the cephalometric X-ray:

It is a generally known fact that underdevelopment of the maxilla is frequent in patients operated on for cleft lip, jaw and palate. In our material also, maxillary retroposition could be clearly demonstrated in all cases. If we postulate that early operation causes more inhibition of growth than late operation, we would expect more pronounced retrognathism in group A than in group B. This proved not to be the case, however. The highly surprising finding was that maxillary retrognathism was not influenced as much as expected by the difference between the age at operation (3 or 6 years).

With reference to the value of SNA and the width of the mandibular angle, the assumption has already been advanced that basal bone below the alveolar level continues to grow in a ventral direction, leading to a chin in a relatively ventral position. Indeed, in cleft patients we often observe retroclination of the lower anterior teeth and a pointed chin, which together with the underdevelopment of the maxilla bring about the typical physiognomy. Could it be the increased lip pressure of the orbicularis muscle that causes the lower anteriors to tilt lingually? According to *Van der Laar* (1977), the lip pressure on the upper incisors in cleft patients does not exceed that in healthy subjects. However, in patients with mandibular prognathism, this would seem to have to be the case, or how else could the lips be closed?

We have also given some attention to the question to what extent the pharyngoplasty which had been performed in some patients had influenced maxillary growth (*Subtelny* and *Pineda*, 1978), although this was not really within the scope of this paper. No such influence could be established, for which reason the corresponding table was not included in this publication, the more so since in general the pharyngoplasty was performed at a later age; the above, therefore, does not imply that primary pharyngoplasty in infancy might not cause inhibition of maxillary growth.

O.P.T. evaluation:

The observations speak for themselves. Under-eruption of the cuspid is present in both groups, and to more or less the same extent. This was not unexpected in view of the fact that in both groups, the gnathoschisis was closed at the age of 3 months.

Plaster casts:

There is practically no difference in compression in the premolar and molar regions. The angle classification where maxillary development is concerned is on the whole slightly more favourable for group A. Not too much importance should be attached to this, however, since in most adult cleft patients a number of teeth in the premolar and molar regions have already been lost due to various causes. Much

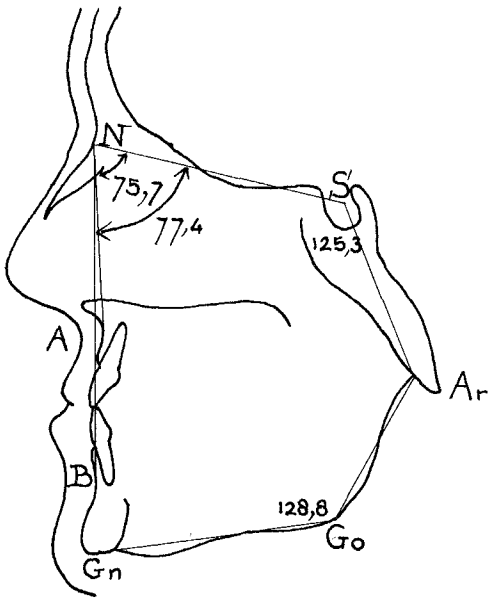

Fig. 9a The mean result of the cephalometric measurements in group A.

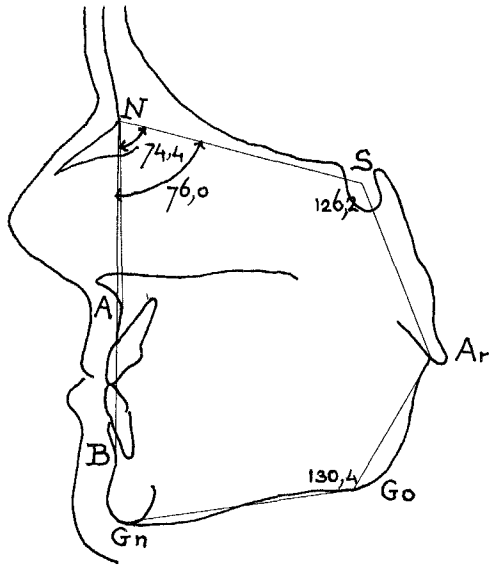

Fig. 9b The mean result of the measurements in group B.

Fig. 10 Illustration of moderate vertical insufficiency of upper lip.

Fig. 11 Example of satisfactory vertical development of upper lip.

more importance from the diagnostic and aesthetic points of view must be attached to incisor relationship.

A "class III relationship" occurred more often in patients in group B, whereas a "class I relationship" was seen more often in patients in group A. For a possible explanation of this unexpected finding see "sphincter function".

Since cheiloplasty was performed at the age of 3 months in both groups the appearance of the lip as such need not to be discussed in this paper. Function however is a different matter since it may affect the inclination of the incisors.

The sphincter function appeared to be better in patients subjected to the "late" operation. It seems a plausible hypothesis that the palatal insufficiency lasting 3 years longer has resulted in more muscular activity in the lip (grimacing) and consequently in better sphincter function. This may be the reason that the sagittal relation of the incisors in group B was slightly less favourable than that in group A and the positive lip line more common.

Hard palate.

Such fistulae as were seen were of no clinical significance, from which we may conclude that in regard to the surgical treatment the difference in age was irrelevant.

We have asked ourselves whether orthodontic treatment should be included in the investigation. We found that the frequency of orthodontic treatment was approximately the same in both groups. It is impossible for the examiner to check whether such treatment has been adequatly performed. Accordingly we arrived at the conclusion that the orthodontic treatment that had been given could not be made part of the evaluation. We can but hope that more or less the same has been done in the two groups. To recapitulate, the results of this follow-up study suggest that postponement of the operation on the palate from the age of 3 to the age of 6 years is of little benefit from the orthodontic point of view. This should not, however, mean that operation at a much earlier age (prior to eruption of the

deciduous molars) might not lead to severe deformity. It may do just that (*Graber*, 1964), although the publication of *Mazaheri* et al. (1971) does not support this supposition. In this connection it may further be pointed out that the surgeon was an extraordinarily experienced man; that the introduction of a plate eliminated dead space between the mucosa and the palatine bone, thereby precluding a thick scar; and finally, that of the patients invited for follow-up only 46 % actually attended.

Did the "orthodontic cripples" stay away? It is not probable, but it would be the only really satisfactory explanation of the fact that the results of this follow-up study are so clearly at variance with the assumption made in the introduction and with the opinion of so many competent authors.

Conclusion

Raising of a muco-periosteal flap on the palate at the age of about 3 years did not impair growth of the maxilla significantly more than if done at the age of 6.

The implication may be that growth is impaired to a lesser extent than previously thought, at least after the eruption of the complete deciduous dentition has been completed.

Acknowledgements

The authors are indebted to Prof. Leppink et al., Utrecht University, Institute for Medical Statistics for their help.

References

Axhausen, G.: Technik und Ergebnisse der Lippenplastik. Thieme, Leipzig 1941, p. 33.

Balan, E. H., R. Stellmach: Beobachtungen an erwachsenen, unoperierten Spaltträgern mit Konsequenzen für die Frage der Sekundärbehandlung. In: K. Schuchardt: Fortschr. Kiefer-Gesichtschir. 16 Thieme, Stuttgart (1973) 209.

Bishara, S. E., C. J. Krause, W. H. Olin.: Facial and dental relationships of individuals with unoperated clefts of the lip and/or palate. Cleft Palate J. 13 (1976) 238.

Bishara, S. E., C. J. Krause, W. H. Olin.: Cephalometric findings in two cases with unrepaired bilateral cleft lip and palate. Cleft Palate J. 15 (1978) 233.

Björk, A.: The face in profile. Berlingska Boktryckeriet, Lund 1947.

Blijdorp, P. A., R. Cornelissen.: Onderzoekmethoden bij volwassen schisispatienten. Ned. Tijdschr. Thk. 84 (1977) 122.

Eisbach, K. J., J. Bardach, E. C. Klausner.: The influence of primary unilateral cleft lip repair on facial growth. Cleft Palate J. 15 (1978) 109.

Ganzer, H.: Wolfsrachenplastik mit Ausnutzung des gesamten Schleimhautmaterials zur Vermeidung der Verkürzung des Gaumensegels. Berl. Klin. Wschr. 57 (1920) 141.

Graber, T. M.: A study of cranio-facial growth and development in the cleft palate child from birth to six years of age. In: Hotz: Early treatment of cleft lip and palate. Huber, Bern 1964, p. 43.

Hayashi, I., M. Sakuda, K. Takimoto, T. Miyazaki.: Craniofacial growth in complete unilateral cleft lip and palate: A roentgenocephalometric study. Cleft Palate J. 10 (1973) 215.

Henderson, D.: The assessment and management of bony deformities of the middle and lower face. Br. J. Plast. Surg. 27 (1974) 287.

Honig, C. A.: The operative treatment of bilateral complete clefts of the primary and secondary palate in the first year of life. In: Hotz: Early treatment of cleft lip and palate. Huber, Bern 1964, p. 148.

Hotz, M. M., M. Perko.: Early treatment of bilateral total cleft lip and palate. Scand. J. Plast. Reconstr. Surg. 8 (1974) 104.

Hotz, M. M., W. M. Gnoinski.: Effects of early maxillary orthopaedics in coordination with delayed surgery for cleft lip and palate. J. max.-fac. Surg. 7 (1979) 201.

Hotz, D., R. Dietrich.: Die Morphologie der mandibulären Prognathie und der maxillären Retrognathie im Fernröntgenbild. Fortschr. der Kieferorthopädie 4 (1969) 497.

Kilner, T. P.: The management of the patient with cleft lip and/or palate. Am. J. Surg. 93 (1958) 204.

Korkhaus, G.: Die kieferorthopädische Behandlung von L.K.G.-Spalten-Patienten. Fortschr. Kiefer-Gesichtschir. (1955) 1.

Krijgers Janzen, E.: Der postoperative Status von Spaltträger in zahnärztlicher Sicht. Dissertation, Zürich 1961.

Mazaheri, M., R. L. Harding, J. A. Cooper, J. A. Meyer, T. S. Jones.: Changes in arch form and dimensions of cleft patients. Am. J. of Orthodont. 60 (1971) 19.

Moorees, C. F. A.: The dentition of the growing child. Harvard University Press, Cambridge 1959.

Morley, M. E.: Cleft Palate and Speech. E & S Livingstone, Edinburgh and London 1966, p. 123.

Mowbray, J. B.: A cephalometric appraisal of a group of children with surgically repaired unilateral cleft lip and palate. Br. J. of Orthodont. 1 (1975) 33.

Narula, J. K., R. B. Ross.: Facial growth in children with complete bilateral cleft lip and palate. Cleft Palate J. 7 (1970) 239.

Onizuka, T., Y. Isshiki.: Development of the palatal arch in relation to unilateral cleft lip and palate surgery: A comparison of the effects of different surgical approaches. Cleft Palate J. 12 (1975) 444.

Perko, M. A.: Two-stage closure of cleft palate. J. max.-fac. Surg. 7 (1979) 76.

Pitangui, I., T. Franco: Non-operated facial fissures in adults. Plast. Rec. Surg. 49 (1967) 149.

Ross, R. B., M. C. Johnston.: Cleft lip and palate. Williams and Wilkins, Baltimore 1972, p. 115.

Salzmann, J. A.: Practice of orthodontics. Lippincott, Philadelphia 1966, p. 117.

Schweckendiek, W.: Zur zweiphasigen Gaumenspaltenoperation bei primärem Velumverschluß. In: K. Schuchardt: Fortschr. Kiefer-Gesichtschir. (1955) 73.

Sicher, H.: Oral Anatomy. Mosby, St. Louis 1952, p. 120.

Sillman, J. H.: Dimensional changes of the dental arches: longitudal study from birth to 25 years. Amer. J. of Orthod. 50 (1964) 824.

Stark, F. B.: Cleft palate. Harper and Row, New York 1968.

Steinhäuser, E. W.: Weichteilveränderungen bei korrektiven Osteotomien im Kieferbereich. Dtsch. Zahnärztl. Z. 29 (1974) 1065.

Subtelny, J. D., R. Pineda.: A longitudal study of maxillary growth following pharyngeal flap surgery. Cleft Palate J. 15 (1978) 118.

Trusler, H. M., T. B. Bauer, J. M. Tondra.: The cleft lip and palate problem. Plast. Rec. Surg. 16 (1955) 174.

Van der Laar, A. J. W.: Lipdrukmetingen bij patiënten met aangeboren lip-kaak-en gehemelte spleten. Elinkwijk B. V., Thesis, Utrecht 1977.

Van Limborgh, J.: Some aspects of the development of the cleft affected face. In: Hotz: Early treatment of cleft lip and palate. Huber, Bern 1964, p. 28.

Veau, V.: Bec. de Lièvre. Masson., Paris 1938.

Veau, V., C. Ruppe.: Technique de l'urano-staphylorraphie. J. Chir. 20 (1922) 113.

Veau, V.: Division palatine. Masson., Paris 1931, p. 130.

Vora, J. M., M. R. Joshi.: Mandibular growth in surgically repaired cleft lip and cleft palate individuals. The Angle Orthod. 47 (1977) 304.

Widmaier, W.: A surgical procedure for the closure of palatal clefts. In: K. Schuchardt: Treatment of patients with clefts of lip, alveolus and palate. Int. Symposium Hamburg, Thieme Leipzig, 1966.

Peter Blijdorp, M.D., D.M.D.
Kliniek voor Mondziekten en Kaakchirurgie
Academisch ziekenhuis Utrecht
Catharijnesingel 101
3511 GV Utrecht
The Netherlands