Extrait du *Bulletin de la Société Internationale de Chirurgie,*
Tome XXI, 1962, n° 4, pp. 403 à 410.

Direct (apical) drainage of the left ventricle

J. Wieberdink, S. Bouma, F. L. Meyler (*), M. E. Sluyter (**)
and W. Stortenbeek (***) (Amsterdam).

Extracorporeal circulation was designed to provide the surgeon with a « dry heart », while oxygen supply to the tissues was maintained. However, even « total bypass » does not answer this purpose because several normal and pathologic pathways shunt blood from the systemic circulation to the heart and lungs. Therefore, « coronary suction » is necessary to remove blood from the operating field (a more adequate name is « field suction »). In addition, measures have to be taken to prevent dangerous accumulation of blood in the heart and lungs. Our paper deals with this problem.

Figure 1 shows the part of the cardiovascular system excluded from circulation during « total bypass ». In all heart chambers as well as in the lungs blood enters, even in tremendous amounts, under certain pathologic conditions. The direction of flow of this blood will generally be towards the left ventricle, due to the prevention of retrograde flow by the heart valves and the influence of blood pressure changes. These are caused by the systole of all heart chambers, the active diastole (causing suction) of the ventricles (1), respiratory movements and the vis a tergo of the blood. It is to be realized that even if the heart is opened somewhere, even if ventricular fibrillation or cardiac arrest occurs, part of these factors remain at work, tending to accumulate blood in the left ventricle.

This accumulation of blood in the left ventricle during total bypass has, for several reasons, escaped attention. First, several cardiac

(*) Cardiological consultant.
(**) Anaesthesiologist.
(***) Medical consultant.
From the University Department of Surgery (Head Prof. I. Boerema), Wilhelmina Gasthuis.

(1) Because the ventricles act as pressure - suction pumps, isolated hearts with widely opened auricles can be used as « jet motors », when submersed in a bath. A short movie is presented showing rat hearts used in this way as « outboard motors » to small toy boats.

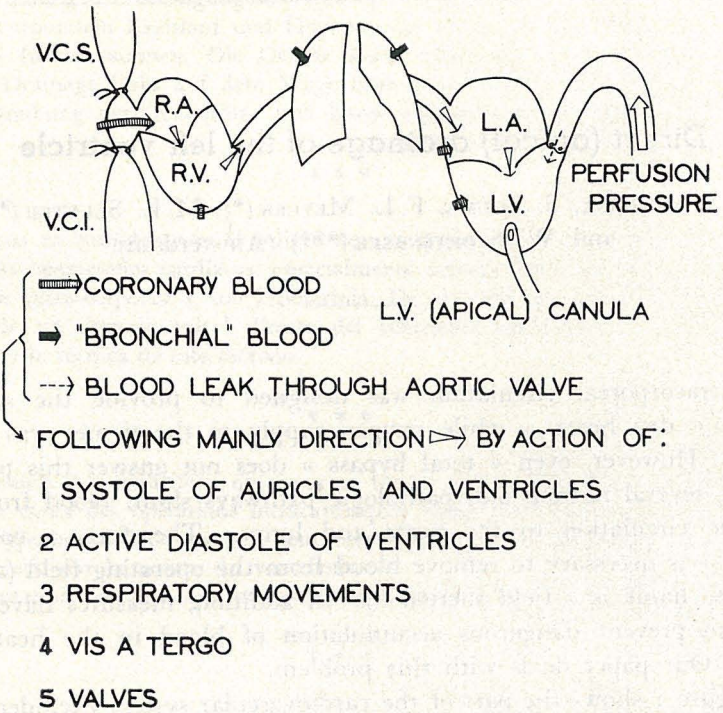

FIG. 1. — Total heart-lung bypass. Modes of entrance of blood into the excluded part of the cardio-vascular system.

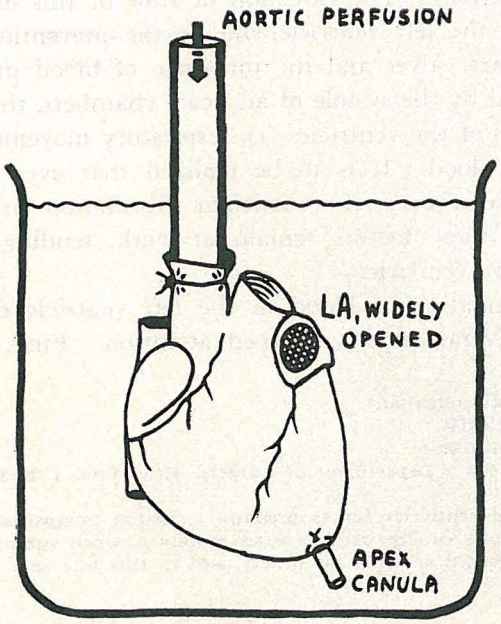

FIG. 2. — Perfusion of isolated heart.

malformations (those with interventricular septal defect and/or mitral insufficiency) drain the left ventricle as long as their correction is not completed. Secondly, much attention was drawn to « perfusion lungs », which were found to be promoted by stagnation of blood in the lungs. To prevent this, left auricle drainage proved effective to a great extent [1]. Thirdly, normothermic extracorporeal circulation with adequate coronary perfusion usually enables the left ventricle to expel its load against the perfusion pressure of the aorta.

Accumulation of blood in the left ventricle may lead to acute left ventricular failure if discrepancy arises between the left ventricular and aortic perfusion pressures. Such may be the case in normothermic perfusion after a period of artificial arrest. The « support » given by the extracorporeal circulation may cause a vicious circle if distention of the left ventricle is not prevented by adequate drainage. The severest menace to the left ventricle, however, was started when extracorporeal circulation was combined with hypothermia. Here, decrease of myocardial contractility, due to « deep cooling » may prevent the left ventricle to pump its content against perfusion pressures in the aorta considered desirable to maintain adequate circulation. The long duration of perfusions, necessary to cool, operate and rewarm, increases the chance that left ventricular dilatation results in irreversible myocardial damage.

Several disappointing experiences with extracorporeal circulation and/or deep hypothermia, reported in the literature, can be understood in the light of these considerations. In this paper, some experimental evidence is presented to show the value of left ventricular drainage. Two kinds of experiments were performed : 1) Perfusion of isolated hearts; 2) Extracorporeal circulation with a gas-heat exchanger.

1. Perfusion of isolated hearts.

Isolated hearts of dogs and rabbits were perfused according to the technique of Langendorff [2]. The hearts were submersed in a bath filled with perfusion fluid, with temperature maintained at 37° C (fig. 2).

In the earliest of these experiments it was noticed that the left ventricular function diminished considerably in about half an hour, whereas the right ventricle continued to beat much longer. We presumed that this might be caused by inability of the left ventricle to expel its content against the perfusion pressure in the aorta. Confirmation was given by the observation that left ventricular function could be preserved much longer by drainage of this chamber (performed through its apex) or by perfusion with low pressures (not exceeding 75 cm of water).

For surgical application of these experiments it is important to mention that the left auricle was widely opened. In other words, the mitral valve remaining competent, left atrial drainage proved unable to prevent impairment of left ventricular function.

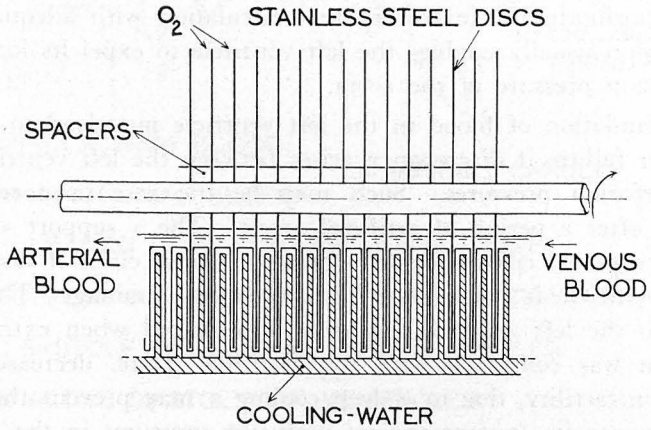

FIG. 3. — Longitudinal section of gas-heat exchanger showing disk-oxygenator with cooling ribs (filled with water) between disks.



FIG. 4. — Gas-heat exchanger used for experiments with dogs.

Further experiments with isolated hearts are considered necessary to gain quantitative evidence of the value of left ventricular drainage at different temperatures.

2. Extracorporeal circulation with the aid of a gas-heat exchanger.

These experiments on dogs intended to be the preparation to a clinical set-up, chosen to combine the advantages of extracorporeal circulation and hypothermia. Circulatory arrest was principally avoided. Peripheral canulations, arterial as well as venous, were employed. The heart was exposed in all cases, mostly by median sternotomy. Partial bypass was used as long as ventricular fibrillation did not occur. Total bypass was used when the heart failed as the circulatory pump, due to ventricular fibrillation or inflow occlusion. This was practised during one hour at an esophageal temperature of 18-20° C. If during that period ventricular fibrillation occurred, one caval vein was left open as an escape for coronary blood. Defibrillation was practised when rewarming reached 29° C.

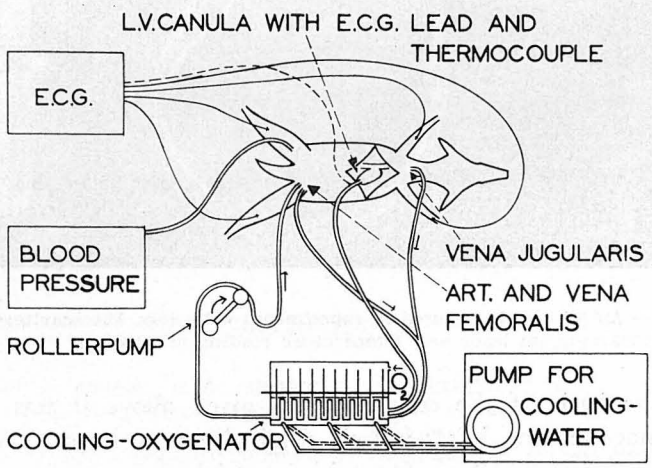

Fig. 5. — Experimental set-up, used to demonstrate effectiveness of left ventricle drainage.

Oxygenation and heat exchanger were combined in one apparatus, to be described in detail elsewhere. Its design is based on the consideration that gas-exchange as will as heat exchange needs surface enlarging of the blood. The interposition of cooling ribs in the blood between the disks of a disk-oxygenator combined these functions. It minimised priming volume and hemolysis because, in a sense, *one* enlarging surface is used for both functions. Figures 3 and 4 show some features of our « gas-heat exchanger » (design 1959). It is used with some modifications of a rollerpump disk oxygenator published elsewhere [4, 5]. Figure 5 shows the experimental set-up.

In our first series of experiments, distention of the left ventricle was almost always noticed, whether ventricular fibrillation occurred or not. The left ventricle became highly cyanotic, whereas the right ventricle and auricles remained of normal size and pinkly coloured. During and after rewarming these hearts proved unable to resume work. Ventricular tachycardia with uncombatable hypotension was at least a probable cause of death in these cases.

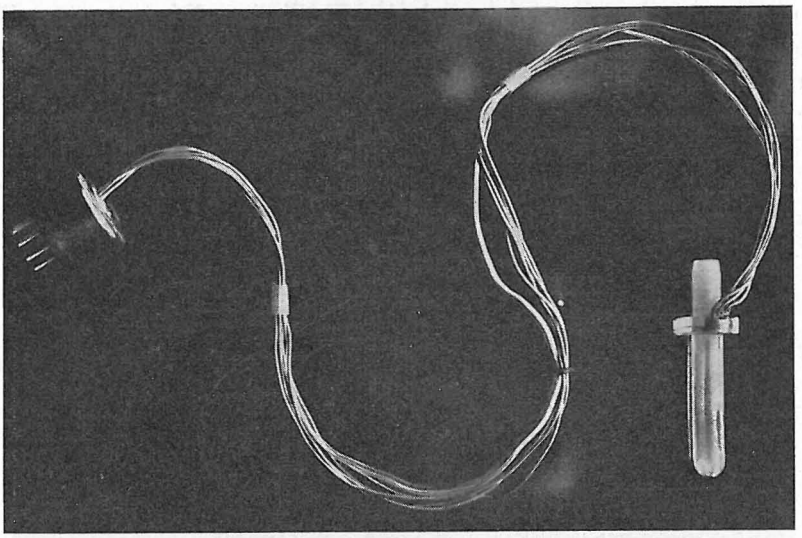

FIG. 6. — Apical canula, as used in experiments with dogs. Intracavitary and intramural electrocardiogram leads and temperature reading are possible.

On the basis of the considerations given above it was presumed that drainage of the left ventricle might prevent impairment of left ventricular function. Therefore, this ventricle was canulated through its apex when the esophageal temperature sank below 29° C. Flow from this canula (delivering mainly blood, saturated in the lungs) joined the extracorporeal circuit in the gas-heat exchanger. In this way seven experiments were performed. In none of these left ventricular distention was observed. Immediately postoperative ventricular tachycardia with hypotension did not take place. The colour of the left ventricle remained good throughout the perfusion and defibrillation at 29° C proved always easy. Temporary clamping of the apex canula at 20° C in one experiment resulted within a few minutes in cyanosis and dilatation of the left ventricle, and in another case probably in ventricular fibrillation.

Though these experiments also have to be worked out quantitatively, we feel justified to recommend the consideration of left ventri-

cular drainage in cardiac surgery, especially if performed with the aid of extracorporeal circulation and hypothermia. In view of this the merits of direct, apical drainage of the left ventricle are summarised :

1. Left ventricular drainage is often the most logic and most effective way of decompression of the heart and lungs during total bypass, as all blood collected in the « dry » part of the cardio-vascular system tends to be driven to the left ventricle. It is principally preferable to left auricular drainage, which does not warrant against left ventricular dilatation.

2. If thoracotomy gives adequate access to the apex, direct (apical) drainage is preferable to left ventricular drainage through the left auricle, as it avoids passage of the catheter through the mitral valve and gives minimal impediment to most types of intracardiac repair.

3. Apical drainage is probably the most effective means of preventing air embolism [3].

4. The apex is thin walled, and vascularized from all directions, major coronary vessels not being present here. Therefore, the introduction of an apical catheter, as well as closure of the myocardial wound, is easy and safe. A simple purse-string suture is effective.

5. Apical drainage can be performed with a short, stiff catheter, Such a catheter can be used too for intraventricular E.C.G. leads, blood pressure and temperature readings, and probably for other studies also.

Figure 6 shows the canula as it is now used in dogs.

BIBLIOGRAPHY.

1. KOLFF, W. J., EFFLER, D. B., GROVES, L. K., HUGHES, C. R. and McCORMACK, L. J. — Pulmonary complications of open-heart operations : their pathogenesis and avoidance. *Cleveland Clin. Quart.*, 25, 1958, 84.
2. MEIJLER, F. L. — Over de mechanische activiteit van het geisoleerde, volgens Langendorff doorstroomde, zoogdierhart. Thesis Amsterdam, 1960.
3. STARR, A. — The mechanism and prevention of air embolism during correction of congenital cleft mitral valve. *J. Thor. Cardiovasc. Surg.*, 39, 1960, 808.
4. VALKENBURG, S. J., BOUMA, S. and WIEBERDINK, J. — Electronic control of a rollerpump-disk oxygenator. *Arch. Chir. Neerland.*, 12, 1961
5. WIEBERDINK, J., de GROENE, M. E., van AALDEREN, W., GERRITSEN, J., MEIJNE, N. G. and BOUMA, S. — Control of blood volume and temperature in extracorporeal circulation. *Arch. Chir. Neerland.*, 12, 1960, 236.

SUMMARY.

The menace of left ventricle distention during cardiac surgery, especially if performed with the aid of extra corporeal circulation and hypothermia, is considered. In connection with this the merits of direct, apical drainage of the left ventricle are discussed.

The principles and construction of a « gas-heat exchanger » are briefly given.

* * *

Besprechung der Bedingungen, welche im Verlaufe intracardialer Operationen mit extracorporalem Kreislauf und Hypothermie zu einer Erweiterung des linken Ventrikels führen können. Die Gefahr kann vermieden werden durch direkte Ventrikel-Drainage links auf dem Wege über eine Ventrikelpunktion.

Beschreibung der Grundsätze und Konstruktionsart eines « gas-heat exchanger ».

* * *

Se toma en consideración el peligro de una distensión del ventrículo izquierdo durante las operaciones cardíacas, especialmente cuando éstas son efectuadas bajo circulación extra-corpórea y con hipotermia. De acuerdo con ello, se discuten las ventajas de un drenaje apical directo del ventrículo izquierdo. Se exponen los principios y la técnica de este método.

* * *

Discussion des conditions qui peuvent mener à une distension du ventricule gauche au cours des opérations intracardiaques faites sous circulation extracorporelle et hypothermie. Ce danger peut être écarté par le drainage ventriculaire gauche direct, par la pointe du ventricule.

Présentation des principes et modes de construction d'un « gas-heat exchanger ».

* * *

La minaccia della distensione del cuore sinistro durante la chirurgia cardiaca specialmente se eseguita con la circolazione estracorporea ed ipotermia, é stata esaminata ed in conseguenza é stato studiata la possibilità di un drenaggio apicale sul ventricolo sinistro.

Sono brevemente esposto i principi sulla costruzione di un « scambiatore di gas-calore » (gas-heat exchanger).