The pituitary-gonadal axis in healthy female dogs and bitches with gynecological disorders

Jenny Buijtels

2011

Het zijn de kleine dingen die het leven zo mooi en intens maken

Voor mijn allerliefste Laurens
en mijn prachtige meisjes Isabelle en Annelie

The pituitary-gonadal axis in healthy female dogs and bitches with gynecological disorders

De hypofyse-gonade as bij gezonde vrouwelijke honden en teven met gynaecologische afwijkingen
(*met een samenvatting in het Nederlands*)

PROEFSCHRIFT

ter verkrijging van de graad van doctor aan de Universiteit Utrecht
op gezag van de rector magnificus, prof. dr. G.J. van der Zwaan,
ingevolge het besluit van het college voor promoties
in het openbaar te verdedigen
op donderdag 9 juni 2011 des ochtends te 10.30 uur

door

Jenny Johanna Cornelia Walthera Maria Buijtels

geboren op 17 december 1974 te Eindhoven

Promotor:	Prof. Dr. J. Rothuizen
Co-promotoren:	Dr. H.S. Kooistra Dr. A.C. Schaefers-Okkens

The studies described in this thesis were conducted and financially supported by the Department of Clinical Sciences of Companion Animals, Faculty of Veterinary Medicine, Utrecht University, Utrecht, The Netherlands

Publication of this thesis was made possible by the generous support of:

Alfasan Diergeneesmiddelen B.V.

AUV Dierenartsencoöperatie

Boehringer Ingelheim B.V.

Dechra Veterinary Products

Elanco Animal Health

Eurovet Animal Health

Intervet Schering Plough

Jurriaanse Stichting

Menarini Diagnostics

Merial

Novartis Animal Health

Petplan

Royal Canin

Scil Animal Care Company

Vetin Aacopharma

Virbac

CIP-DATA KONINKLIJKE BIBLIOTHEEK, DEN HAAG

Buijtels, Jenny Johanna Cornelia Walthera Maria

The pituitary-gonadal axis in healthy female dogs and bitches with gynecological disorders
Jenny Johanna Cornelia Walthera Maria Buijtels
Universiteit Utrecht, Faculteit Diergeneeskunde
Thesis Universiteit Utrecht. –With ref. – With summary in Dutch.
ISBN 978-90-39355572
Subject headings: GnRH-stimulation test, ovary, remnant ovarian tissue, hermaphroditism, granulosa cell tumor, dog

Omslag: Anjolieke Dertien, Multimedia
Lay out: Harry Otter, Multimedia
Druk: Drukkerij Ridderprint, Ridderkerk

Contents

Chapter 1	Outline of the thesis	1
Chapter 2	General introduction	5
Chapter 3	Effects of gonadotropin-releasing hormone administration on the pituitary-ovarian axis in anestrous versus ovariectomized bitches	25
Chapter 4	Basal and GnRH-induced secretion of FSH and LH in anestrous versus ovariectomized bitches	41
Chapter 5	The pituitary-ovarian axis in dogs with remnant ovarian tissue	55
Chapter 6	Alterations of the pituitary-ovarian axis in dogs with a functional granulosa cell tumor	73
Chapter 7	Dogs with a disorder of sexual development and associated changes in the pituitary-gonadal axis	91
Chapter 8	Minimal external masculinization in a SRY-negative XX male Podenco dog	109
Chapter 9	Effects of gonadotropin-releasing hormone administration on the pituitary-gonadal axis in male and female dogs before and after gonadectomy	125
Chapter 10	Summarizing discussion and conclusions	149
Chapter 11	Samenvatting en conclusies	165
	Dankwoord	183
	Curriculum Vitae	187
	List of publications	189

Chapter 1

Outline of the thesis

The reproductive cycle of the domestic bitch (*canis lupus familiaris)*, a mono-estrous species, is characterized by a follicular phase with spontaneous ovulations, followed by a luteal phase of about 75 days, and a non-seasonal anestrus of 2-10 months. The reproductive cycle is under control of the hypothalamic-pituitary-ovarian axis. The gonadotroph cells in the anterior lobe of the pituitary gland produce and secrete follicle-stimulating hormone (FSH) and luteinizing hormone (LH) in a pulsatile fashion. Although each FSH pulse occurs concurrently with a LH pulse, differential regulation of FSH and LH has been reported. The frequency and amplitude of the pulses of the hypothalamic peptide gonadotropin-releasing hormone (GnRH) can only partly explain this differential regulation. A specific hypothalamic FSH-releasing factor may also play a role. Moreover, intracellular mechanisms for storage and release differ for FSH and LH. The granulosa, theca and luteal cells in the ovary are capable of secreting hormones, such as estradiol and progesterone, in response to LH and FSH. The type and amount of hormones released vary according to the morphological status of the follicle and corpus luteum. The ovarian hormones exert a feedback at the hypothalamic-pituitary axis, thereby also influencing, in a differential way, the secretion of LH and FSH.

In the general introduction of this thesis (**Chapter 2**) a summary is given of the nomenclature and functional aspects of the pituitary gland, the pituitary-gonadal axis before and after gonadectomy, and the main gynecological abnormalities which may influence the pituitary-ovarian axis in the bitch.

Estrus can be prevented medically, e.g. by administration of progestagens or androgens, or surgically. The surgical option, ovariectomy (OVX), has the advantages of lowering the risk for mammary cancer and preventing the development of disorders such as pyometra and progesterone-induced growth hormone excess. Although side effects may occur, OVX is the estrus prevention method of choice for many dog owners. Whether or not OVX has been performed in a bitch can be unclear, for instance when the animal has had previous owners or is acquired from a shelter. In addition, the ovaries are not always completely removed and it may be challenging to prove the presence of remnant ovarian tissue. To diagnose the presence of ovarian tissue in bitches is especially challenging during anestrus. Vaginal cytology and vaginoscopy, ideal in diagnosing estradiol influence during the follicular phase, have no diagnostic value in anestrus. Plasma progesterone concentrations, suitable in diagnosing ovarian tissue during the late follicular phase, ovulation, and luteal phase, overlap in anestrous and OVX bitches. Gonadotropin concentrations in the blood may provide some distinction, but the pulsatile secretion pattern of gonadotropins can cause overlap in circulating gonadotropin concentrations between anestrous and OVX bitches. A provocation test of the pituitary-ovarian axis using GnRH has been suggested to distinguish between bitches with or without ovarian tissue,

but studies regarding this subject are scarce. Therefore one of the aims of this thesis was to get more insight in the effects of GnRH administration on the plasma concentrations of LH, estradiol-17β, progesterone and testosterone before and after the administration of GnRH in OVX bitches and anestrous bitches (**Chapter 3**). Research in women revealed that plasma FSH concentrations are more reliable than plasma LH concentrations to determine whether ovaries are inactive or removed or functional and therefore the study described in **Chapter 4** compares the basal and GnRH-induced plasma concentrations of FSH in OVX bitches with those in anestrus.

Abnormalities affecting the ovaries can be congenital or acquired and of these disorders remnant ovarian tissue, often leading to cysts, functional granulosa cell tumors, and disorders in sexual development are the most important ones. These abnormalities may influence the pituitary-ovarian axis, but information about their effect on this axis is lacking. Therefore another aim of this thesis was to increase the knowledge about the pituitary-ovarian axis in bitches with remnant ovarian tissue, granulosa cell tumors and disorders in sexual development.

Remnant ovarian tissue (ROT) occurs after incomplete surgical removal of one or both ovaries. Bitches with ROT present with periodic or continuous symptoms at highly variable intervals after OVX. As with dogs with unknown reproductive status, the diagnostic challenge is to differentiate bitches with ROT from bitches in anestrus. In **Chapter 5** the usefulness of a GnRH-stimulation test in distinguishing anestrous bitches from bitches with ROT has been described.

Granulosa cell tumors (GCTs) are germ cell tumors which are capable of producing estrogens and small amounts of progesterone causing persistent estrous behavior with vulvar discharge and swelling. In humans, it has been demonstrated that GCTs express gonadotropin receptors and respond to gonadotropins, which raises the suspicion that gonadotropins may be involved in the pathogenesis of GCT. Information on the pituitary-ovarian axis in dogs with GCT is however lacking. The goal of the study reported in **Chapter 6** was to describe the alterations in the pituitary-ovarian axis in dogs with a GCT.

Normal mammalian sex differentiation depends on the completion of the chromosomal sex determination, gonadal differentiation, and the development of the phenotype sex. An irregularity in any of these three genetically controlled steps may result in abnormal sexual development. Gonads can contain both testicular and ovarian tissue or contain endocrine tissue of the opposite chromosomal sex. What the effect of these gonads is on the pituitary-gonadal axis is not known. Therefore the goal of the study described in **Chapter 7** was to learn more about the pituitary-gonadal axis in dogs with a disorder in sexual development. In addition, in **Chapter 8** a rare occurrence of a dog with a disorder

in sexual development is described, including the plasma concentrations of LH, estradiol-17β, progesterone, and testosterone, before and after administration of GnRH.

The results of the studies presented in this thesis demonstrate the need for proper reference values for the GnRH-stimulation test in bitches, both before and after gonadectomy. Therefore, the last study described in this thesis (**Chapter 9**) reports on the results of a GnRH-stimulation test obtained in different dog breeds and higher numbers of animals than in previous studies.

In **Chapter 10** the results of the studies described in this thesis are summarized and discussed.

Chapter 2

General introduction

The pituitary gland

Nomenclature of the pituitary gland

Pituitary gland development is primarily the result of the interaction between neuroectodermal and oroectodermal tissues. During embryogenesis, Rathke's pouch arises from the roof of the primitive mouth and contacts with a part of the developing diencephalon (Figure 1). Rathke's pouch then separates from the oral cavity by constriction. The anterior wall of Rathke's pouch proliferates and forms the anterior lobe. The posterior wall is in direct contact with the neural tissue and is separated from the anterior lobe by Rathke's cleft, a remnant of Rathke's pouch, and forms the pars intermedia. When contact is established between the neuroectodermal tissue of the diencephalon and the oroectodermal tissue of Rathke's pouch, the neurohypophysis is formed from neuroectodermal tissue of the diencephalon (Dubois and ElAmraoui 1995; Watkins-Chow and Camper 1998).

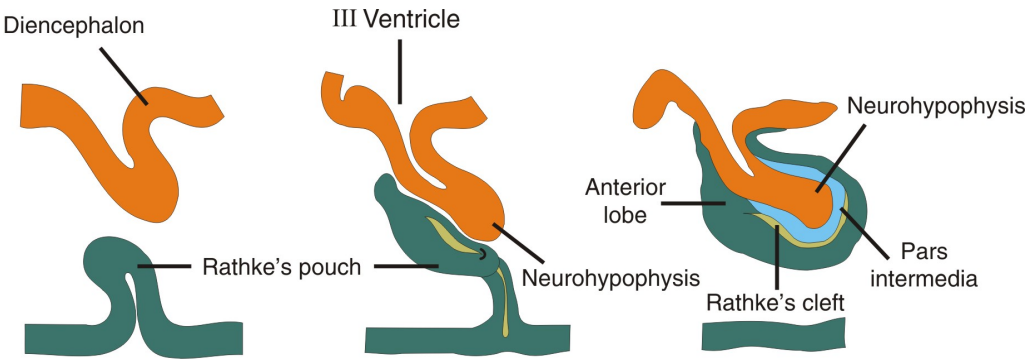

***Figure 1**. Schematic representation of the ontogenesis of the pituitary gland (Meij et al. 2010).*

Functional aspects of the pituitary gland

The hypothalamus and pituitary provide a beautiful example of the close interaction between endocrine and neural regulation. Many key elements are neither purely endocrine nor purely neural. Three different mechanisms can be discerned with regard to the regulation of the pituitary by the hypothalamus:

1) endocrine regulation of the anterior lobe by means of a portal circulation
2) a neurosecretory pathway via the neurohypophysis
3) direct innervation by nerve fibers of the pars intermedia (Meij et al. 2010).

The portal circulation connects a neuroendocrine to an endocrine system (Figure 2). The neuroendocrine system, located in the anterior and middle portion of the ventral hypothalamus, consists of clusters of peptide- and monoamine-secreting cells. These cells produce releasing hormones and inhibiting factors which are transported by nerve fibers to terminals in the outer layer of the median eminence. In this part of the hypothalamus they are released into capillaries of the hypothalamic-hypophyseal portal system. In the anterior lobe of the pituitary they regulate hormone production and secretion (Meij et al. 2010).

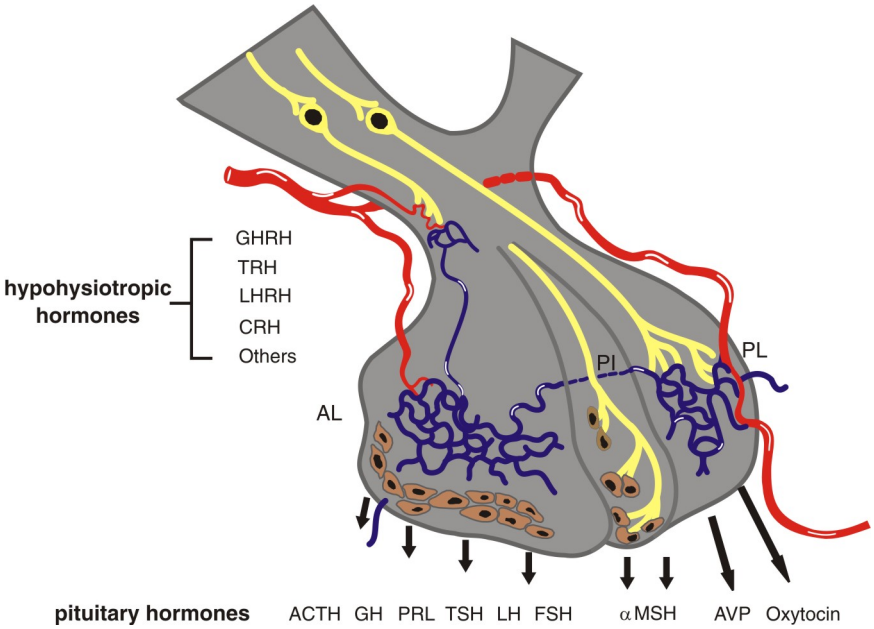

Figure 2. *Schematic representation of the relationship of the hypothalamus and pituitary (Meij et al. 2010).*

In the neurosecretory pathway, neurons in the anterior hypothalamus produce hormones, which are transported by nerve fibers that pass through the ventral hypothalamus and pituitary stalk to end on fenestrated blood vessels in the neurohypophysis. The hormones are stored in secretory vesicles in the final parts of the nerve fibers and secreted into the systemic circulation in reaction to an appropriate stimulus.

The last regulatory mechanism that can be noticed in the pituitary is direct innervation by nerve fibers from the hypothalamus of the pars intermedia. This direct neural control is largely a tonic (dopaminergic) inhibitory influence (Meij et al. 2010).

The main hormones secreted by the hypothalamus and hypophysis are shown in Figures 2 and 3. The cells of the adenohypophysis, consisting of the anterior lobe and pars intermedia, follow three main pathways of differentiation (Meij et al. 2010):

1. Corticotroph and melanotroph cells which both express pro-opiomelanocortin (POMC), leading to secretion of adrenocorticotropic hormone (ACTH) and α-melanocyte-stimulating hormone (α-MSH), respectively.
2. Gonadotroph cells secreting follicle-stimulating hormone (FSH) and luteinizing hormone (LH).
3. Somatotroph, lactotroph, and thyrotroph cells, the Pit1-dependent cell lines, leading to secretion of growth hormone (GH), prolactin (PRL), and thyroid-stimulating hormone (TSH).

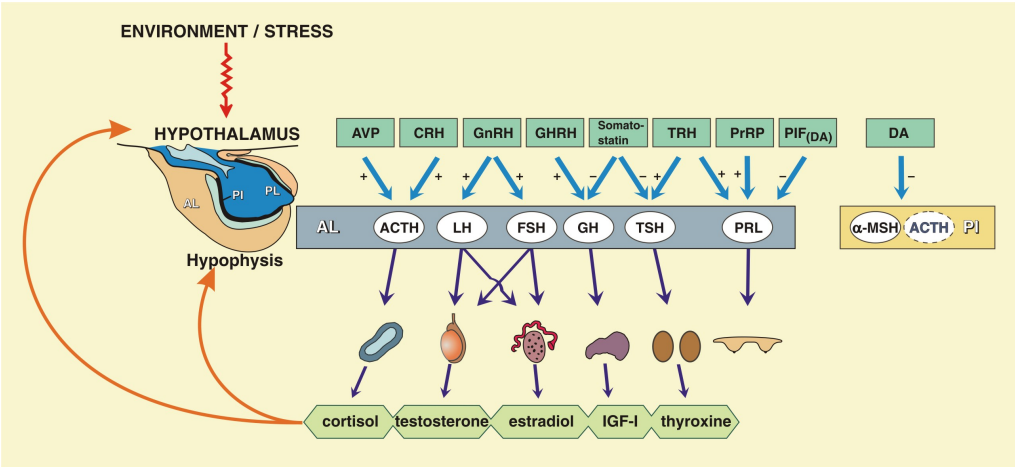

Figure 3. *Schematic illustration of the hypophysiotropic regulation of the secretion of hormones by the adenohypophysis (Meij et al. 2010).*

As in other species, in the fetal dog adenohypophysis ACTH-immunoreactive cells are the first to differentiate from the pituitary progenitor cells (Sasaki and Nishioka 1998). The distribution of the various secretory cells of the anterior lobe is not random but has a topological and numeric organization in man, which may also be true for the dog and cat. The anterior lobe consists of a central wedge containing thyrotropes (10%) and corticotropes (15%) and lateral wings containing somatotropes (50%) and lactotropes (15%). The gonadotropes (10%) are distributed diffusely throughout the gland (Yeung et al. 2006).

The classical concept that each cell type stores a single hormone and that its secretion is regulated by a specific hypothalamic releasing hormone can nowadays be questioned. Some anterior pituitary cells are multifunctional and display mixed phenotypes with numerous receptor expression and/or hormone storage. This allows the cells to immediately react at times in which increased hormone production is necessary such as lactation, ovulation, hypothyroidism, and low temperatures (Senovilla et al. 2005; Senovilla et al. 2008).

Under physiologic and most pathologic conditions the basal plasma concentration of each of the six major anterior lobe hormones (ACTH, LH, FSH, TSH, GH, and PRL) is regulated via a feedback (closed loop) system. Apart from this long-loop feedback, some hormones such as PRL regulate their own secretion directly by acting on the hypothalamus (short-loop feedback). The feedback mechanism can be superimposed by other signals which originate within the central nervous system as a result of influences from the environment (temperature, light-dark), stress (pain, fear), and intrinsic rhythmicity (Meij et al. 2010).

In the median eminence of the hypothalamus, releasing and inhibiting hormones are stored in nerve terminals in which their concentration is 10 to100 times greater than elsewhere in the hypothalamus. Due to the presence of specific receptors on individual cells of the anterior lobe, the hormones accomplish their specificity. These releasing and inhibiting hormones influence peptide synthesis and/or release in anterior lobe cells by modulation of the amount of mRNA, the efficiency of transcription and translation, the processing from preprohormone to hormone, and intracellular degradation of stored hormone. The hypophysiotropic hormones are, with the exception of dopamine, peptides with sequence lengths ranging from 3 to 44 amino acids. Species variation in amino acid sequences can occur with increasing length. Whereas the structures of thyrotropin-releasing hormone (TRH), gonadotropin-releasing hormone (GnRH), and somatostatin (3, 10, and 14 amino acids, respectively) are identical in all mammals studied, the structure of growth hormone releasing hormone (GHRH) varies. Yet corticotropin-releasing hormone (CRH), with 41 amino acids, is identical in man, dog, horse, and rat (Mol et al. 1994).

Secretion of LH and FSH

The pituitary gonadotropes secrete both FSH and LH, which is in contrast to the other endocrine cell types of the pituitary, in which each hormone is secreted by a specific cell type. Both FSH and LH consist of an α and a β subunit, which are encoded by different genes (Gharib et al. 1990). The secretion pattern of both FSH and LH reflects the multifaceted integration between hypothalamic, pituitary and peripheral signals. In the hypothalamus, the GnRH pulse generator, which exhibits spontaneous, synchronized autorhythmicity in the release of the deacapeptide GnRH (Mellon et al. 1990) translates neural signals into a periodic, oscillatory GnRH signal in a coordinated manner to drive and control the pituitary

gonadotropic components (Knobil 1974; Knobil 1980). The pituitary gonadotropes release LH and FSH in a pulsatile manner (Kooistra et al. 1999a) in response to the GnRH rhythmic signals. Each pulse of LH and FSH is induced by a pulse of GnRH (Shacham et al. 2001), but FSH and LH are most likely not discharged concomitantly, because in most mammalian species, including the dog (De Gier et al. 2006b), differential secretion of LH and FSH has been demonstrated. This indicates the presence of regulatory mechanisms that allow independent secretion of LH and FSH. One of these mechanisms is gonadal feedback, because both estradiol and inhibin can specifically suppress FSH synthesis and secretion (Shupnik 1996). Another mechanism is the frequency and amplitude of GnRH pulses, which have been shown to differentially alter LH and FSH gene expression as well as the secretion of these hormones (Vizcarra et al. 1997). A change in the frequency of GnRH pulses can modify the ratio of FSH to LH released (Wildt et al. 1981). Kisspeptin, a neuropeptide hormone, is also thought to play a crucial role in coordinating negative and positive feedback pathways within the hypothalamic-pituitary-gonadal axis (Clarkson et al. 2008; Oakley et al. 2009; Tena-Sempere 2010)

FSH and LH regulate gonadal steroid biosynthesis and initiate and maintain germ cell development. In females, granulosa, theca, interstitial, and luteal cells are capable of secreting hormones in response to LH and FSH. The type and amount of hormones released vary according to the morphological status of the follicle and corpus luteum.

The gonads

Normal mammalian sex differentiation depends on the completion of three genetically controlled steps: chromosomal sex determination (XX or XY), gonadal differentiation, and development of the phenotypic sex (Meyers-Wallen 1993). The diploid number of chromosomes of the dog consists of 39 pairs (78 chromosomes) of which 38 pairs are autosomes and one pair the sex chromosomes. The chromosomal sex of the conceptus, known as XX or XY, is established during fertilization. Prior to sex differentiation, male and female gonads cannot be distinguished until after day 30 of gestation in the dog (Evans and Christensen 1993) and are therefore termed bipotential or indifferent. They have bipotential genital ridges, Wolffian and Mullerian ducts, an urogenital sinus, a genital tubercle, and genital swellings. Gonadectomy performed before gonadal differentiation results in the development of a female phenotype (Jost et al. 1973), indicating that the basic embryonic plan is female. Essential in the development of the male gonadal sex in mammals is the expression of a dominant genetic factor localized on the Y chromosome: the SRY gene (sex-determining region of the Y chromosome). The product of the SRY

gene is a transcription factor (often called testes determining factor) that is thought to play a key role in initiating the cascade of gene regulations resulting in testicular induction (Meyers-Wallen 1999; Patel et al. 2001; Meyers-Wallen 2006). In the presence of SRY undifferentiated gonads always develop into testes, while in the absence of the SRY gene or its gene product the gonads develop into ovaries. The gonads develop from the ventromedial portion of the genital ridge and migrate caudally during fetal development. In the male dog, the gonads migrate after birth to a scrotal position, while in the female they remain in the abdominal cavity, just caudal to the kidneys and are completely enclosed in the ovarian bursa, a peritoneal pouch. The last genetically controlled step is the development of the phenotypic sex. At the indifferent stage, male and female embryos have two identical sets of paired ducts: the Mullerian (paramesonephric) ducts and the Wolffian (mesonephric) ducts (Parker et al. 1999). In the presence of a Y chromosome, testes develop and the Sertoli cells start to secrete Mullerian inhibiting substance (MIS), also known as antiMullerian hormone (AMH), which causes regression of the Mullerian system (Marshall et al. 1982; Atilola and Pennock 1986; Belville et al. 1999; Meyers-Wallen 1999). Testosterone, produced by the Leydig cells, causes the stabilization and differentiation of the Wolffian duct into the ductus deferens and epididymis. In the cells of the urogenital sinus, genital tubercle and genital swellings, 5α-reductase converts testosterone into dihydrotestosterone and mediates the androgenic action necessary for the formation of the prostate, urethra, penis, and scrotum (Wilson et al. 1980). Female organogenesis is characterized by regression of the Wolffian ducts due to absence of the SRY gene and stabilization of the Mullerian ducts, which will form the oviduct, uterus, and cranial vagina (O'Rahilly 1977). The urogenital sinus, genital tubercle, and genital swellings differentiate into the caudal vagina, vestibule, clitoris, and vulva due to the absence of dihydrotestosterone (O'Rahilly 1977; Meyers-Wallen 1993).

The pituitary-ovarian axis

The bitch is a nonseasonal, mono-estrous animal of which the estrous cycle can be classified behavior-oriented or according to the function of the ovary (Figure 4).

The behavior-oriented classification distinguishes proestrus, estrus, and metestrus (diestrus). Proestrus is defined as the period from onset of sanguineous vaginal discharge and vulvar swelling until the first willingness to accept mating. During estrus the bitch accepts mating and the vulva begins to shrink and soften. Metestrus (diestrus) begins when the bitch no longer accepts mating and ends when plasma progesterone concentration declines for the first time to <3 nmol/l.

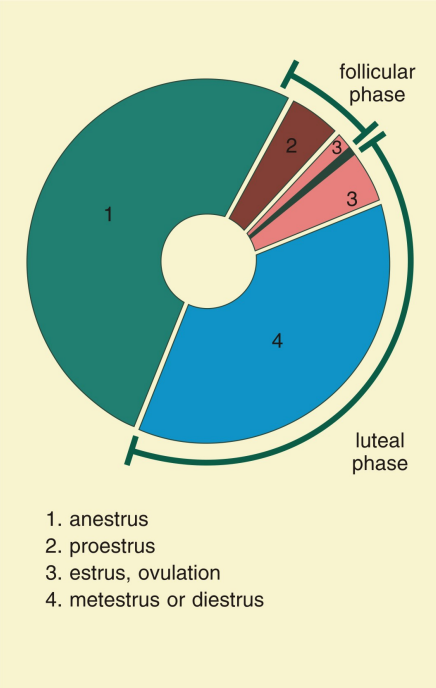

Figure 4. *Schematic presentation of the estrous cycle and anestrus in the dog (Schaefers-Okkens and Kooistra 2010).*

The classification based on ovarian function distinguishes the follicular phase, the phase of preovulatory luteinization and ovulation, and the luteal phase (Schaefers-Okkens and Kooistra 2010). During the follicular phase, tertiary follicles develop and produce estradiol-17β. The plasma estradiol-17β concentration increases gradually during the early follicular phase, leading either to a plateau interval or a sharp increase just before the beginning of the preovulatory LH surge, with peak concentrations about 1-2 days before the preovulatory LH surge (Olson et al. 1982; De Gier et al. 2006a; Schaefers-Okkens and Kooistra 2010). The external signs of proestrus, such as hyperemia and edema of the vulva and bloody vaginal discharge, are related to the high estradiol-17β concentration. Vaginoscopy will reveal that the vaginal mucosal folds are swollen, very pale, and have a smoothly rounded (balloon-like) surface during the follicular phase (Figure 5). Estradiol-17β declines at the end of the follicular phase and a rise in plasma progesterone concentration, as a result of partial luteinization of granulosa cells, starts. Plasma LH concentration is low during the follicular phase, with frequent increases of short duration (Kooistra et al. 1999a; De Gier et al. 2006a). The plasma concentration of FSH is relatively high at the beginning of the follicular phase, but declines to low levels during the progression of the follicular phase.

Estrus behavior normally occurs at the same time as the preovulatory LH surge, but in some bitches it begins days before the surge and in others not until days thereafter or never. The plasma LH concentration before and after the preovulatory LH surge is not different, in contrast to the plasma FSH concentration, which is higher after the FSH surge (De Gier et al. 2006b). In some dogs the FSH surge starts earlier than the LH surge, suggesting a differential regulation of FSH and LH secretion in the dog (De Gier et al. 2006b). During vaginoscopy, shrinkage of the vaginal mucosa with many longitudinal folds can be observed (Figure 6). Plasma progesterone concentration is around 6-13 nmol/l at the time of the LH surge and 15-25 nmol/l at the time of ovulation, 1.5-2 days later. The concentration of progesterone, originating from the corpora lutea, increases in the

peripheral blood during the remainder of estrus and the onset of the luteal phase (Schaefers-Okkens and Kooistra 2010). Then a plateau is reached, after which it declines slowly to a basal level of 3 nmol/l for the first time about 75 days after the onset of the luteal phase. The secretion patterns of LH and FSH during the luteal phase are characterized by a fluctuating baseline with occasional distinct elevations, indicating pulsatile secretion (Kooistra et al. 1999a; Kooistra et al. 1999b).

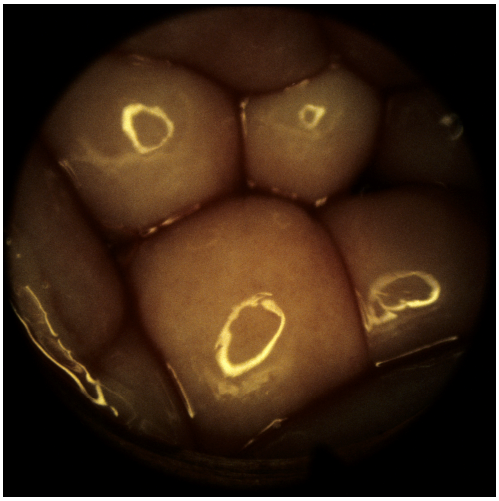

Figure 5. *Vaginoscopic view in the bitch at the onset of the follicular phase (Schaefers-Okkens and Kooistra, 2010).*

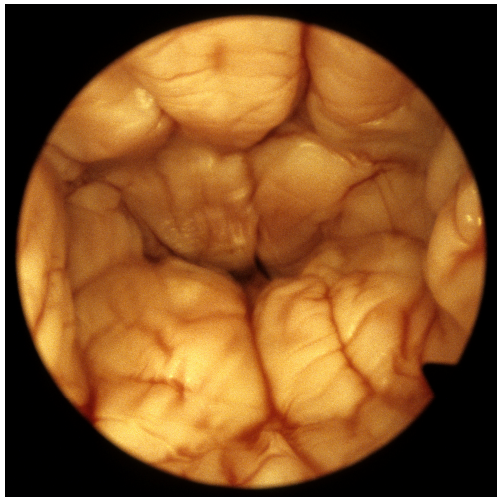

Figure 6. *Vaginoscopic view at the time of ovulation (Schaefers-Okkens and Kooistra 2010).*

The transition from the luteal phase to anestrus is gradual and varies considerably among bitches. The endocrine changes that lead to termination of anestrus are not completely understood in the bitch. The increase in basal plasma FSH concentration which occurs during the progression of anestrus is critical in the initiation of folliculogenesis (Kooistra et al. 1999a; Onclin et al. 2001) and there is increased LH pulsatility shortly before the onset of proestrus (Concannon 1993; Kooistra et al. 1999a; Beijerink et al. 2004). The progression from early to late anestrus is characterized by a greater number and greater amplitude of GnRH pulses (Tani et al. 1996) and there is increased pituitary sensitivity to GnRH and increased ovarian responsiveness to gonadotropins from early to late anestrus (Van Haaften et al. 1994; Tani et al. 1999). Although there are sporadic elevations, plasma estradiol concentration is usually low and does not begin to rise until late anestrus (Olson et al. 1982).

The pituitary-ovarian axis before and after ovariectomy

Estrus prevention in the bitch can be achieved medically, e.g. by administration of progestagens or androgens, or surgically. The surgical option, ovariectomy (OVX), has the advantages of lowering the risk for mammary cancer and preventing the development of disorders such as pyometra and progesterone-induced growth hormone excess. Although side effects can occur, such as urinary incontinence and unwanted changes in hair coat, the advantages mentioned above together with the permanent prevention of estrus makes OVX the first choice for most dog owners. It may be unclear whether or not OVX has been performed in a bitch, for instance when the animal has had previous owners or is acquired from a shelter and (early age) neutering cannot be excluded (Olson et al. 1992). In addition, OVX is not always performed correctly and this may result in the presence of remnant ovarian tissue in bitches, which may be challenging to diagnose.

During the follicular phase, demonstration of the presence of ovarian tissue is straightforward in bitches. The concentration of estradiol rises during this phase and reaches peak levels around the preovulatory LH surge (Olson et al. 1982; De Gier et al. 2006a; Schaefers-Okkens and Kooistra 2010). Vaginoscopy and vaginal cytology, of which the last one is even more reliable than a single plasma estradiol determination (Shille and Olson 1989), can be used to recognize the influence of estrogens (Schutte 1976; Schaefers-Okkens and Kooistra 2010). During the progression to the late follicular phase, ovulation, and luteal phase, an elevated plasma progesterone concentration provides evidence for the presence of ovarian tissue (Okkens et al. 1981).

The demonstration of ovarian tissue during anestrus is challenging. There are no obvious clinical or behavioral differences between the anestrous bitch and the OVX bitch. Vaginal cytology has no diagnostic value in this differentiation and ultrasonographic visualization of ovarian tissue in anestrous bitches is sometimes difficult (England and Allen 1989; Root and Spaulding 1994). Production of the ovarian-derived hormones estradiol and progesterone ceases with OVX, but their plasma concentrations in anestrous and OVX bitches overlap (Jeffcoate 1993; Frank et al. 2003). The loss of negative feedback of ovarian steroids causes a rapid increase in the concentration of circulating gonadotropins (Chaffaux et al. 1981; Olson et al. 1992; Jeffcoate 1993; Concannon 1993; Löfstedt and Vanleeuwen 2002; Reichler et al. 2004), while their secretion pattern remains pulsatile (Concannon 1993). Baseline gonadotropin levels may provide useful information, but due to the pulsatile secretion pattern overlap in the plasma concentrations may be expected between intact and OVX animals and thus the diagnostic value of a single hormone measurement is questionable (Jeffcoate 1993; Löfstedt and Vanleeuwen 2002).

To differentiate between bitches with and without ovarian tissue, a provocative test of the pituitary-ovarian axis using GnRH may be helpful. In the intact bitch, GnRH

administration during anestrus causes an increment in the circulating concentrations of LH and estradiol (Van Haaften et al. 1994). Information regarding the response to exogenous GnRH after ovariectomy is limited to a few studies. One study found a rise in LH after GnRH administration in OVX bitches (Chaffaux et al. 1981), while another found an unpredictable response (Jeffcoate 1993). The discrepancy may be due to differences in sampling times and doses of GnRH that were used. Only one study investigated the effect of a GnRH challenge on plasma estradiol concentration in OVX bitches; in this study no increase could be found (Jeffcoate 1993). Studies comparing the response on GnRH administration in anestrous bitches and OVX bitches are lacking.

Disorders of the ovaries

Disorders affecting the ovary can be congenital or acquired. Congenital abnormalities of the canine ovary include complete absence of one or both ovaries (agenesis), ovarian hypoplasia caused by an abnormal number of sex chromosomes and the presence of gonadal tissue which is not in agreement with the phenotype, like in pseudo- or true hermaphrodites. Acquired disorders include ovarian cysts, oophoritis, remnant ovarian tissue or (hormone producing) ovarian tumors. The three most common gynecological disorders seen in referring institutions are remnant ovarian tissue, hormone producing tumors and pseudo- or true hermaphroditism. There is only a limited knowledge about the pituitary-ovarian axis in these ovarian abnormalities.

Remnant ovarian tissue

Remnant ovarian tissue (ROT) is the presence of ovarian tissue in a seemingly ovariectomized bitch. Ectopic ovarian tissue has not been reported to occur in dogs and accessory ovaries have only been described in cows and humans (McEntee 1990). Therefore, ROT in bitches is the result of incomplete surgical removal of one or both ovaries (Wallace 1991). ROT has been reported to be distributed equally between the right and left side (Miller 1995). Most authors, however, describe that ROT occurs more frequently on the right side, probably because of the more cranial position of the right ovary, which makes it more difficult to remove than the left ovary (Pearson 1972; Okkens et al. 1981; Marretta et al. 1989; Ball et al. 2010).

The most common presentation of ROT is symptoms and signs of recurrent estrus, such as vulvar swelling, vaginal discharge, and attractiveness to male dogs after OVX. The interval between OVX and occurrence of clinical signs is highly variable and the symptoms can be periodic or continuous. Recognizing bitches with ROT can be

straightforward or very challenging, depending on the phase of the reproductive cycle. A clinical diagnosis of ROT during the follicular phase is straightforward, because the plasma concentration of estradiol is elevated, which leads to obvious changes assessed by vaginoscopy and vaginal cytology (Schutte 1976; Olson et al. 1982; De Gier et al. 2006; Schaefers-Okkens and Kooistra 2010). During the late follicular phase, ovulation, and the luteal phase, the plasma concentration of progesterone is increased (Schaefers-Okkens and Kooistra 2010), providing evidence for ROT (Okkens et al. 1981). When there is no clinical or behavioral evidence of an increased plasma estradiol concentration, recognition of bitches with ROT is challenging. The production of estradiol and progesterone decreases markedly after OVX, but nevertheless basal plasma concentrations of both hormones in anestrous and OVX bitches overlap (Jeffcoate 1993; Frank et al. 2003). The concentrations of circulating LH and FSH are significantly higher in OVX bitches than in bitches in anestrus, due to the loss of negative feedback of ovarian hormones after OVX (Jeffcoate 1993; Olson et al. 1992; Concannon 1993; Löfstedt and Vanleeuwen 2002; Reichler 2004). Relatively low plasma gonadotropin concentrations may therefore suggest the presence of (functional) ovarian tissue, but the pulsatile secretion of gonadotropins (Concannon 1993) can cause overlapping of their plasma concentrations between OVX bitches and bitches in anestrus. A gonadotropin-releasing hormone challenge test could maybe be used to distinguish completely ovariectomized bitches from bitches with ROT. However, Okkens et al. (1981) found that 12 of 47 bitches with ROT had macroscopic cysts in the ROT. Their effect on the results of a GnRH-stimulation test is unknown and the successful use of this test in detecting bitches with ROT has not yet been reported.

Granulosa cell tumor

Ovarian neoplasia is relatively uncommon in the dog, but among domestic animals they appear to be most common in the bitch and cow (Cotchin and Marchant 1977). The pathogenesis of ovarian neoplasia is unknown. In dogs with neoplasia diagnosed at necropsy the reported incidence of canine ovarian tumors ranges from 0.5 to 6 per cent (Dow 1960; Hayes and Harvey 1979; Jergens and Shaw 1987; Madewell and Theilen 1987). Neoplasia can be primary or secondary, of which the last one includes metastatic malignant lymphoma, mammary carcinoma, intestinal carcinoma and pancreatic carcinoma (Dow 1960; Madewell and Theilen 1987). The three general categories of primary ovarian neoplasms are those arising from epithelial cells, tumors of sex cord/stromal origin, and those arising from germ cells.

The histogenetic origin of the epithelial ovarian tumors is believed to be the ovarian surface epithelium, a single layer of flat-to-cuboidal epithelial cells covering the ovary and extending into the ovarian cortex (Auersperg et al. 2001). Epithelial tumors are the most

frequently diagnosed canine ovarian neoplasms at necropsy (Patnaik and Greenlee 1987); adenocarcinomas, with a metastatic frequency of 50%, being more common than adenomas (Dow 1960; Jergens and Shaw 1987; Madewell and Theilen 1987; Patnaik and Greenlee 1987; Greene et al. 1979; Goodwin et al. 1990; Rocken 1991; Booth 1994; Nagarajan et al. 1994). The most common clinical presentation of dogs with epithelial tumors of the ovaries is ascites and abdominal distention (Madewell and Theilen 1987).

Ovarian germ cell tumors develop from primitive germ cells of the embryonic gonad. The incidence at necropsy of canine ovarian germ cell tumors is quite low, and in this category only dysgerminomas and teratomas have been reported in dogs (Patnaik and Greenlee 1987). Both tumor types may lead to abdominal distention and do not impair ovarian function, because dogs with these tumors are reported to have normal estrous cycles (Dillberger and Altman 1987; McCormick and McEntee 1988).

Sex cord-stromal tumors arise from various cell types in gonadal stroma and sex cords. The incidence at necropsy of canine sex cord-stromal tumors lies between those of the epithelial tumors and the germ cell tumors (Patnaik and Greenlee 1987). Three different types are distinguished, with the granulosa cell tumor (GCT) occurring more frequently than the rare occurring theca cell tumors and luteomas (Jergens and Shaw 1987).

Granulosa cell tumors appear to arise from granulosa cell cords derived from atretic follicles (McEntee 1990). Most GCTs are unilateral, although bilateral masses have been described (Madewell and Theilen 1987). GCTs usually are well encapsulated with no local invasion (Dow 1960) and metastases are reported to occur in 10 to 20 per cent of cases (Madewell and Theilen 1987). The occurrence of cysts in the contralateral ovary has been reported (McEntee 2002). There are also two case reports describing GCT in three previously ovariohysterectomized dogs (Pluhar et al. 1995; Sivacolundhu et al. 2001). Granulosa cell tumors are capable of producing estrogens and small amounts of progesterone (Feldman and Nelson 1987; Davidson and Feldman 2005; Schaefers-Okkens and Kooistra 2010). In most cases of GCT, the clinical signs are referable to increased estrogen and progesterone secretion and to a lesser extent to the mass effect of the tumor. The latter may cause abdominal distension and sometimes ascites. Persistent estrus behavior with serosanguineous vulvar discharge and vulvar swelling are frequently noticed in bitches with GCT (Hayes and Harvey 1979; McCandlish et al. 1979; Jergens and Shaw 1987; Feldman and Nelson 1987; Madewell and Theilen 1987; Malm et al. 1994; Pluhar et al. 1995). The progesterone secreted by the GCT enhances endometrial growth and glandular secretion, which can lead to the cystic endometrial hyperplasia-pyometra complex (Feldman and Nelson 1987). It has been demonstrated in humans that GCTs express gonadotropin receptors (Stouffer et al. 1984) and respond to gonadotropins

(Graves et al. 1985). In this regard, it has been speculated that gonadotropins may be involved in the pathogenesis of GCT. If this is also true in dogs is however not known. Moreover, information about the pituitary-ovarian axis in dogs with GCTs before and after stimulation with GnRH is lacking.

Disorders of sexual development

As described previously in this general introduction, the normal mammalian sex differentiation depends on the completion of the chromosomal sex determination, gonadal differentiation, and development of the phenotypic sex (Meyers-Wallen 1993). An irregularity in any of the three genetically controlled steps results in abnormal sexual development. To facilitate differential diagnosis of an abnormal sexual development, the irregularities are categorized according to the first step that differs from normal (Meyers-Wallen 2009). Examples of disorders in chromosomal sex are chimerism, mosaicism, XO syndrome, XXY syndrome, and XXX syndrome (Johnston et al. 1985; Giger et al. 1989; Löfstedt et al. 1992; Genero et al. 1998; Mayenco-Aguirre et al. 1999; Goldinski and Bereszynki 2000; Switonski et al. 2000; Goldsmidt et al. 2001; Kuiper and Distl 2004; Goldsmidt et al. 2006; Kuiper 2010).

Animals in which chromosomal sex determination and gonadal development are not in agreement are mentioned to be sex reversed (Meyers-Wallen 1993; Meyers-Wallen 1999). XX sex-reversed animals have a normal female chromosome makeup but their gonads contain variable amounts of both testicular and ovarian tissue. Animals having both gonads entirely composed of testicular tissue are termed XX males. Frequently the gonads contain both testicular and ovarian tissue (ovotestes) and the animals are then referred to as XX true hermaphrodites (Meyers-Wallen 1999). The external appearance of XX sex-reversed dogs can be ambiguous. In a female phenotype there may be an enlarged clitoris or the anogenital distance can be altered. The degree of masculinization in true hermaphrodites depends directly on the amount of testicular tissue in the gonads. In most true hermaphrodites there may be no visible difference in the phenotype and the animals may be fertile and may remain undiscovered in the dog population (Meyers-Wallen and Patterson 1989; Meyers-Wallen 1993; Kuiper 2010).

In mice and humans, XX sex reversal can be due to a translocation of the SRY gene from the Y chromosome to the X chromosome during male meiosis (De la Chapelle 1981), but all XX sex-reversed dogs reported thus far have been SRY negative (Meyers-Wallen et al. 1995a; Meyers-Wallen et al. 1995b; Hubler et al. 1999; Melniczek et al. 1999; Meyers-Wallen et al. 1999; Kuiper et al. 2005). The development of ovotestes or testes in XX dogs indicates that also other mutated genes can induce testicular tissue development in the absence of SRY (Meyers-Wallen et al. 1999). XX sex reversal is inherited as an autosomal

recessive trait in the American cocker spaniel; in the beagle and German shorthaired pointer the inheritance is also consistent with an autosomal recessive trait (Meyers-Wallen and Patterson 1988; Meyers-Wallen et al. 1995a; Meyers-Wallen et al. 1995b; Melniczek et al. 1999; Meyers-Wallen et al. 1999).

Disorders in phenotypic sex, known as pseudohermaphroditism, are animals in which the chromosomal and gonadal sex always agree, but the phenotype appears to be partly or completely the opposite sex (Meyers-Wallen and Patterson 1988), leading to genital ducts and/or external genitalia that are incompletely masculinized (Kuiper 2010). Male pseudohermaphrodites can have a defective Mullerian duct regression, known as persistent Mullerian duct syndrome or disturbances in androgen-dependent masculinization (Kuiper 2010). Complete or partial XY gonadal dysgenesis can also lead to agreement in chromosomal and gonadal sex but with the opposite phenotype in humans (Achermann and Hughes 2008). The effects of disorders in sexual development on the pituitary-gonadal axis are unknown in dogs.

References

Achermann JC, Hughes LA. Disorders of sexual development. In: Williams Textbook of endocrinology, 11th edition. Kronenberg HM, Melmed S, Polonsky KS, Larsen PR (Eds). Philadelphia, Saunders Elsevier, 2008, pp. 783-849.

Atilola MAO, Pennock PW. Cystic uterus masculinus in the dog. Six case history reports. Vet Rad 1986;27:8-14.

Auersperg N, Wong AS, Choi KC, Kang SK, Leung PC. Ovarian surface epithelium: biology, endocrinology and pathology. Endocr Rev 2001;22:255-288.

Ball RL, Birchard SJ, May LR, Threlfall WR Young GS. Ovarian remnant syndrome in dogs and cats: 21 cases (2000-2007). J Am Vet Med Assoc 2010;236:548-553.

Belville C, Josso N, Picard JY. Persistence of Mullerian derivates in males. Am J Med Genet 1999;98:218-223.

Beijerink NJ, Kooostra HS, Dieleman SJ, Okkens AC. Serotonin-antagonist-induced lowering of prolactin secretion does not affect the pattern of pulsatile secretion of follicle-stimulating hormone and luteinizing hormone in the bitch. Reproduction 2004;128:181-188.

Booth JM. Canine transmissible venereal tumour and ovarian papillary cystadenocarcinoma in a bitch. J Small Anim Pract 1994;35:39-42.

Concannon PW. Biology of gonadotrophin secretion in adult and prepubertal female dogs. J Reprod Fertil Suppl 1993;47:3-27.

Chaffaux S, Chassagnite F, Thibier M. Concentration of LH après stimulation par la gonadoliberine (LRH) chez la chienne et effet de l'ovariectomie. Rec Med Vet 1981;10:725-733.

Clarkson J, d'Anglemont de Tassigny X, Santos Moreno A, Colledge WH, Herbison AE. Kisspeptin-GPR54 Signalling is essential for preovulatory gonadotropin-releasing hormone neuron activation and the luteinising surge. J Neurosci 2008;28:8692-8697.

Cotchin E, Marchant J. Animal tumours of the female reproductive tract. Spontaneous and experimental. In: Pathology of the female genital tract. Blaustein A (Ed). New York, Springer-Verlag, 1977, pp. 55-56.

Davidson AP, Feldman EC. Ovarian and estrous cycle abnormalities. In: Textbook of Veterinary Internal Medicine. Ettinger SJ, Feldman EC (Eds). Philadelphia, Elsevier Saunders, 2005, pp. 1649-1655.

De Gier J, Kooistra HS, Djajadiningrat-Laanen SC, Dieleman SJ, Okkens AC. Temporal relations between plasma concentrations of luteinizing hormone, follicle-stimulating hormone, estradiol-17β, progesterone, prolactin and alpha-melanocyte-stimulating hormone during the follicular, ovulatory, and early luteal phase in the bitch. Theriogenology 2006a;65:1346-1359.

De Gier J, Kooistra HS, Djajadiningrat-Laanen SC, Dieleman SJ, Okkens AC. Differential regulation of the secretion of luteinizing hormone and follicle-stimulating hormone around the time of ovulation of the bitch. Theriogenology 2006b;66:1419-1422.

De la Chapelle A. The aetiology of maleness in XX men. Hum Genet 1981;58:105-116.

Dillberger JE, Altman NH. A canine ovarian germ cell tumor with extraembryonic differentiation. Vet Pathol 1987;24:96-98.

Dow C. Ovarian abnormalities in the bitch. J Comp Pathol 1960;70:59-69.

Dubois PM, ElAmraoui A. Embryology of the pituitary gland. Trends Endocrinol Metab 1995;6:1-7.

England GCW, Allen WE. Real-time ultrasonic imaging of the ovary and uterus of the dog. J Reprod Fertil Suppl 1989;39:91-100.

Evans HE, Christensen GC. The urogenital system. In: Miller's anatomy of the dog. Christensen GC, Evans HD (Eds). Philadelphia, WB Saunders, 1993, pp. 494-558.

Feldman EC, Nelson RW. Canine female reproduction. In: Canine and Feline Endocrinology and Reproduction. Feldman EC, Nelson RW (Eds). Philadelphia, WB Saunders, 1987, pp. 399-480.

Frank LA, Rohrbach BW, Bailey EM, West JR, Oliver JW. Steroid hormone concentration profiles in healthy intact and neutered dogs before and after cosyntrophin administration. Domest Anim Endocrinol 2003;24:43-57.

Genero ER, Moreno-Millan M, Ocana-Quero JM. XX/XY chromosome chimaerism in an intersex dog. Vet Red 1998;142:340.

Gharib SD, Wierman ME, Shupnik MA, Chin WW. Molecular biology of the pituitary gonadotropins. Endocr Rev 1990;11:177-199.

Giger U, Meyers-Wallen VN, Patterson DF. A 6-month-old Dobermann pinscher with ambiguous genitalia as a first case of X-chromosomal monosomy in the dog. J Vet Intern Med 1989;3:245.

Goldschmidt B, El-Jaick KB, Souza LM, Carvalho ECQ, Moura VLS, Benevides Filho IM. Cryptorchidism associated with 78,XY/79,XXY mosaicism in a dog. Israel J Vet Med 2001;56 (http://www.isrvma.org/arrticle/56_2_4.htm).

Goldschmidt B, Paulino FO, Souza LM, Gomes HF. Infertilty related to X-trisomy in a Labrador Retriever bitch. Israel J Vet Med 2006;58 (http://www.isrvma.org/article/58_4_7.htm).

Greene JA, Richardson RC, Thornhill JA, Boon GD. Ovarian papillary cystadenocarcinoma in a bitch: Case report and literature review. J Am Anim Hosp Assoc 1979;15:351-356.
Goodwin JK, Hagar D, Philips L, Lyman R. Bilateral ovarian adenocarcinoma in a dog: Ultrasonographic-aided diagnosis. Vet Radiol 1990;31:265-267.
Graves PE, Surwit EA, Davis JR, Stouffer RL. Adenylate cyclase in human ovarian cancers: sensitivity to gonadotrophins and nonhormonal activators. Am J Obstet Gynecol 1985;153:877-882.
Hayes A, Harvey HJ. Treatment of metastatic granulosa cell tumour in a dog. J Am Vet Med Assoc 1979;174:1304-1306.
Hubler M, Hauser B, Meyers-Wallen VN, Arnold S. Sry-negative XX true hermaphrodite in a Basset hound. Theriogenology 1999;51:1391-1403.
Jeffcoate IA. Gonadotrophin-releasing hormone challenge to test for the presence of ovaries in the bitch. J Reprod Fertil Suppl 1993;47:536-538.
Jergens AE, Shaw DP. Tumours of the canine ovary. Compend Contin Educ Pract Vet 1987;9:489-495.
Johnston SD, Buoen LC, Weber AF, Madl JE. X trisomy in an Airdale bitch with ovarian dysplasia and primary anestrus. Theriogenology 1985;24:597.
Jost A, Vigier B, Prepin J, Perchellet JP. Studies on sex differentiation in mammals. Rec Prog Horm Res 1973;29:1-41.
Knobil E. On the control of gonadotrophin secretion in the rhesus monkey. Recent Prog Horm Res 1974;30:1-46.
Knobil E. The neuroendocrine control of the menstrual cycle. Recent Prog Horm Res 1980;36:53-88.
Kooistra HS, Okkens AC, Bevers MM, Poppsnijders C, van Haaften B, Dieleman SJ, Schoemaker J. Concurrent pulsatile secretion of luteinizing hormone and follicle-stimulating hormone during different phases of the estrous cycle and anestrus in beagle bitches. Biol Reprod 1999a;60:65-71.
Kooistra HS, Okkens AC, Bevers MM, Poppsnijder C, van Haaften B, Dieleman SJ, Schoemaker J. Bromocriptine-induced premature oestrus is associated with changes in the pulsatile secretion pattern of follicle-stimulating hormone in beagle bitches. J Reprod Fertil 1999b;117:387-393.
Kuiper H, Distl O. XX/XY chromosome chimaerism in a Border terrier. Vet Rec 2004;154:637.
Kuiper H, Bunck C, Günzel-Apel A-R, Drögemüller C, Hewicker-Trautwein M, Distl O. SRY-negative XX sex reversal in a Jack Russell Terrier: a case report. Vet J 2005;169:116-117.
Kuiper HJ, 2010. Gonadal development and disorders of sexual differentiation. In: Clinical Endocrinology of Dogs and Cats. Rijnberk A, Kooistra HS (Eds). Hannover, Schlütersche, 2010, pp. 187-202.
Löfstedt RM, Buoen LC, Weber AF, Johnston SD, Huntington A, Concannon PW. Prolonged proestrus in a bitch with X-chromosomal monosomy (77:XO). J Am Vet Med Assoc 1992;200:1104-1106.
Löfstedt RM, Vanleeuwen JA. Evaluation of a commercially available luteinizing hormone test for its ability to distinguish between ovariectomized and sexually intact bitches. J Am Vet Med Assoc 2002;220:1331-1335.
Madewell BR, Theilen GH. Tumours of the urogenital tract. In: Veterinary Cancer Medicine. Theilen GH, Madewell BR (Eds). Philadelphia, Lea & Febiger, 1987, pp. 567-600.
Marretta SM, Matthiesen DT, Nichols R. Pyometra and its complications. Probl Vet Med 1989;1:50-62.
Malm C, Ferreira HI, Nascimento EF. Clinical and histopathological survey of ovarian and uterine disorders in ovariohysterectomized bitches. I. Granulosa cell tumours. Arq Bras Med Vet Zootec 1994;46:13-18.
Marshall LS, Oehlert ML, Haskins ME, Selden JR, Patterson DF. Persistent Mullerian duct syndrome in miniature schnauzers. J Am Vet Med Assoc 1982;81:798-801.
Mayenco-Aguirre AM, Padilla JA, Flores JM, Daza MA. Canine gonadal dysgenesis syndrome: a case of mosaicism (77,XO-78,XX). Vet Rec 1999;145:582-584.
McCandlish IAP, Munro CD, Breeze RG, Nash AS. Hormone producing ovarian tumours in the dog. Vet Rec 1979;105:9-11.
McCormick AE, McEntee M. Analyzing an unusual canine ovarian mass. Vet Med 1988;83:368-373.
McEntee K. The ovary and Ovarian Neoplasms. In: Reproductive Pathology of Domestic Animals. McEntee K (Ed). San Diego, Academic Press Inc, 1990, pp. 31-93.
McEntee MC. Reproductive oncology. Clin Tech in Small Anim Prac 2002;17:133-149.
Meij BP, Kooistra HS, Rijnberk A. Hypothalamus-pituitary system. In: Clinical Endocrinology of Dogs and Cats. Rijnberk A, Kooistra HS (Eds). Hannover, Schlütersche, 2010, pp. 13-54.
Mellon PL, Windle JJ, Goldsmith PC, Padula CA, Roberts JL, Weiner RI. Immortalization of hypothalamic GnRH neurons by genetically targeted tumorigenesis. Neuron 1990;5:1-10.
Melniczek JR, Damhach D, Prociuk U, Jezyk PF, Henthorn PS, Patterson DF, Giger U. Sry-negative XX sex reversal in a family of Norwegian Elkhounds. J Inter Med 1999;13:564-569.
Meyers-Wallen VN, Patterson DF. XX sex reversal in the American cocker spaniel dog: phenotypic expression and inheritance. Hum Gen 1988;80:23-30.

Meyers-Wallen VN, Patterson DF. Sexual differentiation and inherited disorders of sexual development in the dog. J Reprod Fertil Suppl 1989;39:57-64.
Meyers-Wallen VN, Manganaro FF, Kuroda T, Concannon PW, MacLaughlin DT, Donahoe PK. The critical period for Mullerian duct regression in the dog embryo. Biol Reprod 1991;45:623-633.
Meyers-Wallen VN. Genetics of sexual differentiation and anomalies in dogs and cats. J Reprod Fertil Suppl 1993;47:441-452.
Meyers-Wallen VN, Bowman L, Acland GM, Palmer VL, Schlafer D, Fajt V. Sry-negative XX sex reversal in the German shorthaired pointer dog. J Hered 1995a;86:369-374.
Meyers-Wallen VN, Palmer VL, Acland GM, Herschfield B. Sry-negative XX sex reversal in the American Cocker Spaniel Dog. Mol Reprod Dev 1995b;41:300-305.
Meyers-Wallen VN. Inherited disorders in sexual development. Amer Gen Ass 1999;90:93-95.
Meyers-Wallen VN, Schlafer D, Barr I, Lovell-Badge R, Keyzner A. Sry-negative XX sex reversal in purebred dogs. Mol Reprod Dev 1999;53:266-273.
Meyers-Wallen VN. Genetics, genomics, and molecular biology of sex determination in small animals. Theriogenology 2006;66:1655-1658.
Meyers-Wallen VN. Review and update: Genomic and molecular advances in sex determination and differentiation in small animals. Reprod Dom Anim Suppl 2009;44:40–46.
Miller DM. Ovarian remnant syndrome in dogs and cats: 46 cases (1988-1992). J Vet Diagn Invest 1995;7:572-574.
Mol JA, van Wolferen M, Kwant M, Meloen R. Predicted primary and antigenic structure of canine corticotropin releasing hormone. Neuropeptides 1994;27:7-13.
Nagarajan L, Ramani C, Ramanujam K. Ovarian serous cystadenocarcinoma in a bitch. Indian J Vet Surg 1994;15:45.
Oakley AE, Clifton DK, Steiner RA. Kisspeptin signaling in the brain. Endocr Rev 2009;30:713-743.
Okkens AC, Dieleman SJ, Van Der Gaag I. Gynaecologische complicaties na ovario-hysterectomie bij de hond ten gevolge van: 1. Het incompleet verwijderen van de ovaria. 2. Een ontsteking van uterus-cervixstomp. Tijdschr Diergeneesk 1981;106:1142-1158.
Olson PN, Bowen RA, Behrendt M, Olson JD, Nett TM. Concentrations of reproductive hormones in canine serum throughout late anestrus, proestrus and estrus. Biol Reprod 1982;27:1196-1206.
Olson PN, Mulnix JA, Nett TM. Concentration of luteinizing hormone and follicle stimulating hormone in the serum of sexually intact and neutered dogs. Am J Vet Res 1992;53:762-766.
Onclin K, Lauwers F, Verstegen JP. FSH secretion pattern during pregnant and nonpregnant luteal periods and 24 h secretion patterns in male and female dogs. J Reprod Fertil Suppl 2001;57:15-21.
O'Rahilly R. The development of the vagina in the human. In: Morphogenesis and malformation of the genital system. Blandau RJ, Bergsma D (Eds). New York, Alan Liss, 1977, pp. 123-136.
Parker KL, Schimmer BP, Schedl A. Genes essential for early events in gonadal development. Cell Mol Life Sci 1999;55:831-838.
Patel M, Dorman KS, Zhang YH, Huang BL, Arnold AP, Sinsheimer JS, Vilain E, Mccabe ER. Primate DAX1, SRY, and SOX9. Evolutionary stratification of sex-determination pathway. Am J Hum Genet 2001;68:275-280.
Patnaik AK, Greenlee PG. Canine ovarian neoplasms: A clinicopathologic study of 71 cases, including histology of 12 granulosa cell tumours. Vet Pathol 1987;24:509-514.
Pearson H. The complications of ovariohysterectomy in the bitch. J Small Anim Pract 1972;14:257-266.
Pluhar GE, Memon MA, Wheaton LG. Granulosa cell tumour in an ovariohysterectomized dog. J Am Vet Med Assoc 1995;207:1063-1065.
Reichler IM, Pfeiffer E, Piché CA, Jöchle W, Roos M, Hubler M, Arnold S. Changes in plasma gonadotropin concentrations and urethral closure pressure in the bitch during the 12 months following ovariectomy. Theriogenology 2004;62:1391-1402.
Rocken H. A cystadenofibroma (Brenner's tumour?) of a dog (abstract). Prakt Tierarzt 1991;72:33.
Root CR, Spaulding KA. Diagnostic imaging in companion animal theriogenology. Semin Vet Med Surg (Small Anim) 1994;9:7-27.
Sasaki F, Nishioka S. Fetal development of the pituitary gland in the beagle. Anat Rec 1998;251:143-151.
Schaefers-Okkens AC, Kooistra HS. Ovaries. In: Clinical Endocrinology of Dogs and Cats. Rijnberk A, Kooistra HS (Eds). Hannover, Schlütersche, 2010, pp. 203-234.
Shille VM, Olson PM. Dynamic testing in reproductive endocrinology. In: Current Veterinary Therapy X. Kirk RW (Ed). Philadelphia; WB Saunders, 1989, pp. 1282-1288.
Schutte AP. Canine vaginal Cytology II. Cyclic changes. J Small Anim Pract 1976;8:307-311.
Senovilla L, García-Sancho J, Villalobos C. Changes in expression of hypothalamic releasing hormone receptors in individual rat anterior pituitary cells during maturation, puberty and senescence. Endocrinology 2005;146:4627-4634.

Senovilla L, Núñez L, Villalobos C, García –Sancho J. Rapid changes in anterior pituitary cell phenotypes in male and female mice after acute cold stress. Endocrinology 2008;149:2159-2167.
Shacham S, Harris D, Ben-Shlomo H, Cohen I, Bonfil D, Przedecki F, Lewy H, Ashkenazi IE, Seger R, Naor Z. Mechanism of GnRH Receptor signaling on gonadotrophin release and gene expression in pituitary gonadotrophs. Vitam Horm 2001;63:63-90.
Shupnik MA. Gonadal hormone feedback on pituitary gonadotrophin genes. Trends Endocrinol Metab 1996;7:272-276.
Sivacolundhu RK, O'Hara AJ, Read RA. Granulosa cell tumour in two spayed bitches. Aust Vet J 2001;79:173-176.
Stouffer RL, Grodin MS, Davis JR, Surwit EA. Investigation of binding sites for follicle-stimulating hormone and chorionic gonadotropin in human ovarian cancers. J Clin Endocrinol Metab 1984;59:441-446.
Switonski M, Godynicke S, Jackowiak H, Pienkowska A, Turczuk-Bierla I, Szymas J, Goldinski P, Bereszynki A. X trisomy in an infertile bitch: cytogenetic, anatomic and histologic studies. J Hered 2000;91:149-150.
Tani H, Inaba T, Tamada H, Sawada T, Mori J, Torii R. Increasing gonadotrophin-releasing hormone release by perfused hypothalamus form early to late anestrus in the beagle bitch. Neurosci Letters 1996;207:1-4.
Tani H, Inaba T, Nonami M, Matsuyama S, Takamorj Y, Torii R, Tamada H, Kawate N, Sawada T. Increased LH pulse frequency and estrogen secretion associated with termination of anestrus followed by enhancement of uterine estrogen receptor gene expression in the beagle bitch. Theriogenology 1999;52:593-607.
Tena-Sempere M. Kisspeptin signalling in the brain: recent developments and future challenges. Mol Cell Endocrinol 2010;314:164-169.
Van Haaften B, Bevers MM, van den Brom WE, Okkens AC, van Sluijs FJ, Willemse AH, Dieleman SJ. Increasing sensitivity of the pituitary to GnRH from early to late anestrus in the beagle bitch. J Reprod Fertil 1994;101:221-225.
Vizcarra JA, Wetteman RP, Braden TD, Turzillo AM, Nett TM. Effect of gonadotrophin-releasing hormone (GnRH) pulse frequency on serum and pituitary concentrations of luteinizing hormone and follicle-stimulating hormone, GnRH receptors, and messenger ribonucleic acid for gonadotrophin subunits in cows. Endocrinology 1997;138:594-601.
Wallace MS. The ovarian remnant syndrome in the bitch and queen. Vet Clin North Am Small Anim Pract 1991;21:501-507.
Watkins-Chow DE, Camper SA. How many home-box genes does it take to make a pituitary gland. Trends Genet 1998;14:184-290.
Wildt L, Hausler A, Marshall G, Hutchison JS, Plant TM, Belchetz PE, Knobil E. Frequency and amplitude of gonadotropins-releasing hormone stimulation and gonadotropins secretion in the rhesus monkey. Endocrinology 1981;109:376-385.
Wilson JD, Griffin JE, George FW. Sexual differentiation: Early hormone synthesis and action. Biol Reprod 1980;22:9-18.
Yeung CM, Chan CB, Leung PS, Cheng CHK. Cells of the anterior pituitary. Int J Biochem Cell Biol 2006;38:1441-1449.

Chapter 3

Effects of gonadotropin-releasing hormone administration on the pituitary-ovarian axis in anestrous versus ovariectomized bitches

JJCWM Buijtels[1,3], NJ Beijerink[1,3], HS Kooistra[1], SJ Dieleman[2], AC Okkens[1]

Reproduction in Domestic Animals 2006;41:555-561

[1] Department of Clinical Sciences of Companion Animals, Faculty of Veterinary Medicine, Utrecht University, The Netherlands
[2] Department of Farm Animal Health, Section of Reproduction, Faculty of Veterinary Medicine, Utrecht University, Utrecht, The Netherlands
[3] Both authors contributed equally to this article

Abstract

The aim of this study was to determine the effects of gonadotropin-releasing hormone (GnRH) administration on the plasma concentrations of reproductive hormones in intact and ovariectomized (OVX) bitches. Therefore, blood samples were collected at multiple times before and after the administration of 10 μg/kg GnRH (Fertagyl®) for the determination of the plasma concentrations of luteinizing hormone (LH), estradiol, progesterone, and testosterone in 6 anestrous and in 6 OVX bitches.

The mean plasma LH concentrations before and 60 min after GnRH administration were significantly lower in the anestrous bitches than in the OVX bitches. In both groups GnRH administration resulted in a significant increase in the plasma LH concentration. The highest plasma LH concentrations were found at 10 min after GnRH administration and these values did not differ significantly between the 2 groups. Only in the anestrous bitches a significant increase in plasma estradiol concentrations was found after GnRH administration and these values were significantly higher than those in the OVX bitches. The plasma concentrations of progesterone and testosterone were low (close to or below the limit of quantitation) both before and after GnRH administration and the differences between anestrous and OVX bitches were not significant.

It can be concluded that 1) basal plasma LH concentration is significantly higher in OVX bitches than in anestrous bitches, 2) plasma LH concentration increases after GnRH administration in both anestrous and OVX bitches, 3) GnRH administration causes a significant rise in plasma estradiol concentration only if ovarian tissue is present, and 4) measurement of plasma progesterone and testosterone concentrations before and after GnRH administration does not aid in distinguishing between anestrous and OVX bitches. The results of this study may provide a basis for the diagnosis of remnant ovarian tissue and verification of neuter status in the bitch.

Introduction

It can be difficult to verify the neuter status of dogs with an unknown reproductive status. In addition, it is occasionally difficult to differentiate ovariectomized (OVX) dogs having remnant ovarian tissue from completely OVX dogs. The presence of ovarian tissue can be confirmed by cytological evaluation of a vaginal smear and vaginoscopy during the follicular phase, measurement of the plasma progesterone concentration during the progression to the late follicular phase, ovulation and luteal phase, abdominal ultrasonography and exploratory laparotomy (Wallace 1991; Root and Spaulding 1994; Schaefers-Okkens 2005).

In the intact bitch, the stages of the estrous cycle can be classified on the basis of ovarian function as the follicular phase, the phase of preovulatory luteinization and ovulation, the luteal phase, and non-seasonal anestrus (Schaefers-Okkens 2005). During the follicular phase, demonstration of the presence of ovarian tissue is straightforward. The concentration of estradiol, which is mainly synthesized and secreted by granulosa cells in developing ovarian follicles, rises during this phase and reaches peak levels around the pre-ovulatory luteinizing hormone (LH) surge (Olson et al. 1982; Schaefers-Okkens 2005; De Gier et al. 2006). Vaginoscopy and vaginal cytology can be used to recognize the influence of estrogens (Schutte 1976; Schaefers-Okkens 2005). The use of cytological evaluation of a vaginal smear as a bioassay for estrogen influence is even more reliable than a single plasma estradiol determination (Shille and Olson 1989). The plasma concentration of progesterone, which is secreted by partially luteinizing granulosa cells before ovulation and by mature luteal cells after ovulation, is increased in the progression to the late follicular phase, ovulation, and during the luteal phase (Schaefers-Okkens 2005). Elevated plasma progesterone concentrations provide evidence for the presence of ovarian tissue (Okkens et al. 1981).

During anestrus, which lasts from 2 to 10 months, the plasma progesterone concentration is in general below 3 nmol/l (Okkens et al. 1985a). Plasma estradiol concentration is also usually low and does not begin to rise again until late anestrus, although sporadic elevations have been reported (Olson et al. 1982). During anestrus, LH is secreted in a pulsatile fashion but the basal plasma LH concentration is low (Olson et al. 1982; Kooistra et al. 1999). Plasma testosterone concentrations are also low during anestrus in the bitch. Plasma testosterone concentration begins to rise near the end of anestrus and reaches peak levels near the time of the preovulatory LH surge (Olson et al. 1984; Concannon and Castracane 1985).

There are no obvious clinical or behavioral differences between the anestrous bitch and the OVX bitch. Vaginal cytology also has no diagnostic value in this differentiation

and ultrasonographic visualization of ovarian tissue in anestrous bitches is sometimes difficult (England and Allen 1989; Root and Spaulding 1994). Production of the ovarian-derived hormones estradiol and progesterone ceases with OVX, but their plasma concentrations in anestrous and OVX bitches overlap (Jeffcoate 1993a; Frank et al. 2003). The loss of negative feedback of ovarian steroids causes a rapid increase in the concentration of circulating gonadotropins (Chaffaux et al. 1981; Olson et al. 1992; Jeffcoate 1993a; Concannon 1993; Löfstedt and Vanleeuwen 2002; Reichler et al. 2004), while their secretion pattern remains pulsatile (Concannon 1993). Baseline gonadotropin levels may provide some useful information, but due to the pulsatile secretion pattern a considerable overlap in the plasma concentrations may be expected between intact and OVX animals and thus the diagnostic value of a single hormone measurement is questionable (Jeffcoate 1993a; Löfstedt and Vanleeuwen 2002).

To differentiate between bitches with and without ovarian tissue, a provocative test of the pituitary-ovarian axis using GnRH may be helpful. In the intact bitch, GnRH administration during anestrus causes an increment in the circulating plasma concentrations of LH and estradiol (Van Haaften et al. 1994). The GnRH-induced plasma LH and estradiol responses are higher in late anestrus than in early anestrus (Van Haaften et al. 1994). Information regarding the response to exogenous GnRH after ovariectomy is limited to a few studies. One study found a rise in LH after GnRH administration in OVX bitches (Chaffaux et al. 1981), while another found an unpredictable response (Jeffcoate 1993a). The discrepancy may be due to differences in sampling times and doses of GnRH that were used. Only one study investigated the effect of a GnRH challenge on plasma estradiol concentration in OVX bitches (Jeffcoate 1993a). The low dose of GnRH that was used in the latter study produced no increase in plasma estradiol concentration. No data have been reported on the response of the plasma testosterone concentration to GnRH stimulation in intact and OVX bitches.

The aim of this study was to determine the effects of gonadotropin-releasing hormone (GnRH) administration on the plasma concentrations of reproductive hormones in intact and OVX bitches. Therefore, blood samples were collected at multiple times before and after the administration of GnRH for the determination of the plasma concentrations of LH, estradiol, progesterone and testosterone in anestrous and in OVX bitches.

Materials and Methods

Animals, treatment and collection of blood samples

Twelve bitches, consisting of ten Beagles, one Border Collie, and one mongrel, were used in this study. Six of them, 3 to 7 years of age and weighing 13.6 to 16.9 kg, were sexually intact. The other six, 5 to 12 years of age and weighing 13.2 to 27.0 kg, were ovariectomized. The Beagles were whelped and raised in the Department of Clinical Sciences of Companion Animals and were accustomed to the laboratory environment and handling such as collection of blood samples. They were housed in pairs in indoor-outdoor runs, fed a standard commercial dog food once daily, and given water ad libitum. The Border Collie and the mongrel dog were owned by veterinarians working at the Department of Clinical Sciences of Companion Animals and were also accustomed to the collection of blood samples.

The six intact Beagles were examined three times weekly for swelling of the vulva and a serosanguinous vaginal discharge, which were considered to signify the onset of pro-estrus. Plasma concentrations of progesterone were determined three times weekly from the start of pro-estrus until plasma progesterone concentration exceeded 16 nmol/l, at which time ovulation was assumed to occur (Concannon et al. 1977; Wildt et al. 1979; Okkens et al. 1985b). During this study the 6 Beagle bitches were in anestrus (123–203 days after ovulation), as confirmed by plasma progesterone concentrations below 3 nmol/l (Okkens et al. 1985a). Six dogs had been ovariectomized at the Department of Clinical Sciences of Companion Animals at Utrecht University at least one year before the start of the experiment and there had been no subsequent signs of estrus as demonstrated by the absence of swelling of the vulva, vaginal discharge and attractiveness to male dogs.

Blood samples were collected for measurement of the plasma concentrations of LH (at -40, 0, 10, and 60 min), estradiol (at -40, 0, 60, and 120 min), progesterone (at -40, 0, 60, and 120 min), and testosterone (at 0, 60, and 90 min) after the iv administration of 10 µg GnRH (Fertagyl®; Intervet, Boxmeer, The Netherlands) per kg body weight at 0 min. GnRH was administered via the cephalic vein. Blood samples were collected from the jugular vein, placed immediately in chilled heparin-coated tubes, and centrifuged at 4 ºC for 10 min at 1500 *g*. Plasma was stored at –25 ºC until analysis.

Hormone measurements

Plasma LH concentration was measured by use of a heterologous radioimmunoassay (RIA) as described previously (Nett et al. 1975) with the following modifications. A rabbit antiserum raised against ovine LH (CSU-204, kindly supplied by G.D. Niswender,

Colorado State University, CO, USA), radioiodinated bLH-7981 as prepared for our bovine LH assay (Dieleman and Bevers 1987) and canine pituitary standard LER 1685-1 (a gift from Dr. L.E. Reichert, Albany Medical College, NY, USA) were used in this assay. The intra-assay and interassay coefficients of variation (CV) for values above 0.5 µg/l were 2.3% and 10.5%, respectively. The lower limit of quantitation was 0.3 µg/l.

Plasma estradiol-17β concentration was measured by use of a solid-phase RIA (Count-A-Count TKE; Diagnostic Products Corporation, Los Angeles, CA) according to the manufacturer's instructions with modifications as described previously (Dieleman and Bevers 1987) and validated for the dog (Van Haaften et al. 1994). The intra-assay and interassay CV were 14% and 11.8%, respectively. The lower limit of quantitation was 7 pmol/l.

Plasma progesterone concentration was measured in the sample collected at -40 min by a previously validated I^{125}-RIA (Okkens et al. 2001). The intra-assay and interassay CVs were 6% and 10.8%, respectively. The lower limit of quantitation was 0.15 nmol/l.

Plasma testosterone concentration was measured by RIA (Coat-A-Count® Total Testosterone, Diagnostic Product Corporation) according to the manufacturer's protocol with the following two modifications to increase the sensitivity. First, three extra standard points were included corresponding with 51, 255 and 1020 pmol/l producing standard curves with an average estimated dose of 1643 (CV 11.4%, n=10 RIAs), 230 (7.1%) and 37 (6.8%) pmol/tube at 20, 50 and 80 % relative binding, respectively. Second, aliquots of 1 ml plasma were extracted with 2.5 ml diethylether. The residue after evaporating under nitrogen was dissolved in 125 µl A-serum (Diagnostic Products Corporation) of which 50 µL duplicates were used for RIA. The average extraction efficiency was 85% (CV 1.8%, n=10 RIAs) as determined on the basis of 3H-testosterone added to parallel series of plasma samples (n=6 per RIA). Values of the samples obtained in pmol/tube were calculated into pmol/l by correction for volume and extraction efficiency. The intra-assay and interassay CV were 5 and 6%, respectively. The lower limit of quantitation was 51 pmol/l.

Data analysis

Statistical analysis was performed using SPSS® for Windows, version 12.0.1 (SPSS Inc., Chicago, IL, USA). When the plasma concentration of estradiol, progesterone, or testosterone was below the limit of quantitation, the respective lower limit value was assigned to the sample. For each bitch the mean basal plasma hormone concentration was calculated from the hormone concentrations before GnRH administration. The average plasma hormone concentration per group was calculated as the average of the mean values of the individual dogs. The plasma LH, estradiol, progesterone, and testosterone data were made normally distributed by converting them to their natural (or neperian) logarithms (ln)

and these were analyzed using a multivariate repeated measures model, with 'time' as the within-subject variable and 'group' as the between-subject variable. Subsequently, a contrast study was performed to evaluate time effects within each group in comparison with the mean basal level. $P<0.05$ was considered significant. Results are presented as mean ± SEM and range.

Ethics of experimentation

This study was approved by the Ethical Committee of the Faculty of Veterinary Medicine, Utrecht University.

Results

No adverse effects of GnRH administration on health or behavior were observed in any of the dogs. Mean plasma LH concentrations before and 60 min after GnRH administration were significantly lower ($P<0.001$ and $P<0.01$, respectively) in the intact bitches than in the OVX bitches. Moreover, there was no overlap between the two groups when these values were compared (Table 1). In both groups GnRH administration resulted in a significant increase in the plasma LH concentration (Figure 1). In the protocol used, the highest plasma LH concentrations were found at 10 min after GnRH and these values did not differ significantly between the two groups. The mean plasma LH concentration at 10 min after GnRH was significantly higher than those before ($P<0.001$) and 60 min after GnRH ($P<0.001$) in the anestrous dogs. In the OVX dogs, the mean plasma LH concentration at 10 min after GnRH was significantly higher ($P<0.05$) than the mean basal plasma LH concentration.

Basal plasma estradiol concentration in all dogs except one anestrous bitch was below the detection limit of the assay. The difference in the basal plasma estradiol concentration between the two groups was not significant. After GnRH stimulation, plasma estradiol concentration was below the detection limit in all OVX dogs but above this level in all anestrous bitches. In the protocol used, the maximum plasma estradiol concentration after GnRH administration was observed at 60 min in three of the anestrous bitches and at 120 min in the other three. At 60 and 120 min after GnRH stimulation, plasma estradiol concentrations were significantly higher in the anestrous bitches than in the OVX bitches ($P<0.05$ in both cases) and the increase above baseline in the anestrous bitches was also significant ($P<0.02$ and $P<0.01$, respectively).

Table 1. *Mean ± SEM and range of plasma concentrations of LH, estradiol, progesterone and testosterone in 6 anestrous and 6 ovariectomized (OVX) bitches before and after intravenous administration of 10 µg per kg body weight of GnRH (Fertagyl®).*

	Anestrous bitches		Ovariectomized bitches	
	Mean ± SEM	Range	Mean ± SEM	Range
Basal LH (µg/l)	0.64 ± 0.04[*,a]	0.48 – 0.93	20.2 ± 3.6[*,a]	6.2 – 41.0
LH 10 min after GnRH(µg/l)	58.0 ± 11.1[b]	25.4 – 101	63.9 ± 15.3[b]	30.3 – 113
LH 60 min after GnRH (µg/l)	4.9 ± 0.5[*,a]	2.8 – 6.2	28.4 ± 8.7[*,ab]	10.9 -68.9
Basal estradiol (pmol/l)	NC[a]	< 7 – 14.1	NC	< 7
Estradiol 60 min after GnRH (pmol/l)	23.0 ± 4.0*[,b]	14.1 – 35.7	NC [*]	< 7
Estradiol 120 min after GnRH (pmol/l)	24.4 ± 3.5*[,b]	12.3 – 32.4	NC [*]	< 7
Basal progesterone (nmol/l)	NC	<0.13 – 2.2	NC	<0.13 – 0.95
Progesterone 60 min after GnRH (nmol/l)	NC	<0.13 – 1.9	NC	< 0.13
Progesterone 120 min after GnRH (nmol/l)	NC	<0.13 – 1.6	NC	< 0.13
Basal testosterone (pmol/l)	NC	< 51 – 75.6	NC	< 51.0 – 70.0
Testosterone 60 min after GnRH (pmol/l)	74.7 ± 7.8	56.2 – 102.5	NC	< 51.0 – 55.7
Testosterone 90 min after GnRH (pmol/l)	80.4 ± 7.8	56.7 – 101.8	NC	< 51.0

[*] *indicates a significant difference in mean hormone concentration between the anestrous and the OVX bitches*
[a, b, ab]*: Different letters within a column per hormone indicate significant differences*
NC: mean not calculated because not all plasma hormone concentrations were above the detection limit. When a plasma hormone concentration was below the limit of quantitation, in order to perform statistical analysis, the respective lower limit value was assigned to the sample.

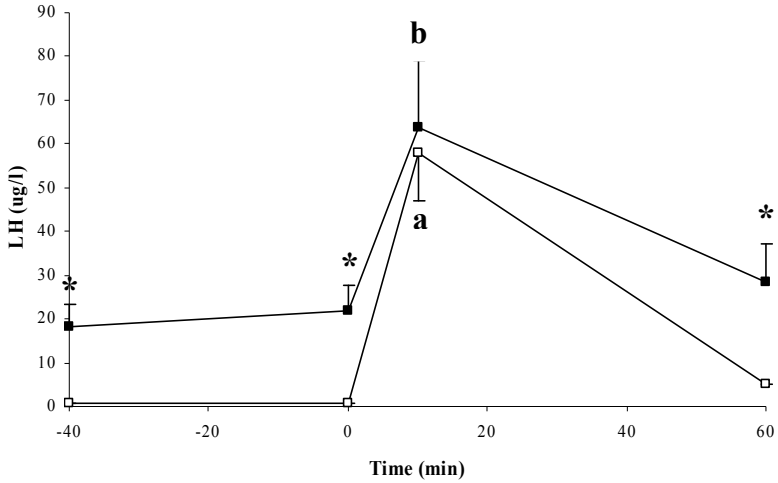

Figure 1. *Mean (± SEM) plasma LH concentration after intravenous administration of GnRH in a dose of 10 µg per kg body weight at t = 0 min in six anestrous (□) and six ovariectomized (OVX) (■) bitches.*
(*) indicates a significant difference in mean plasma LH concentration between the anestrous and the OVX bitches
(a) indicates a significantly higher mean plasma LH concentration at t = 10 min in the anestrous dogs compared with the values before and 60 min after GnRH administration
(b) indicates a significantly higher mean plasma LH concentration at t = 10 min in the OVX bitches compared with the values before GnRH administration

Basal plasma progesterone concentration was above the detection limit of the assay in all but three samples from the anestrous bitches, whereas it was below the detection limit in all but one sample from the OVX bitches. In both groups, no change in plasma progesterone concentration after GnRH administration was significant. Differences in mean plasma progesterone concentration between the two groups before and after GnRH administration were not significant (Table 1).

Basal plasma testosterone concentration was above the detection limit of the assay in three anestrous bitches and one OVX bitch. After GnRH administration, plasma testosterone concentration was detectable in all anestrous bitches but only one OVX bitch. Plasma testosterone concentration did not change significantly after GnRH administration and the difference in mean plasma testosterone concentration between the anestrous dogs and the OVX dogs was not significant.

Discussion

The plasma concentrations of reproductive hormones were measured before and after GnRH administration in OVX bitches and bitches in anestrus, to evaluate the applicability of such measurements for ascertaining the presence or absence of ovarian tissue. The anestrous period was chosen because during this phase neither vaginoscopy nor vaginal cytology nor the basal plasma progesterone concentration are of value in differentiating between intact and OVX bitches.

The different sampling times for LH and estradiol were based upon information from previous experiments (Van Haaften et al. 1994; Meij et al. 1996). No data have been reported on the response of the plasma testosterone concentration to GnRH stimulation in the bitch. In intact male dogs administration of 10 µg/kg GnRH results in a maximum testosterone concentration at 60 min after injection (Knol et al. 1993), and therefore we assumed that a GnRH-induced increase in plasma testosterone concentration will be found in blood samples at 60 and 90 min after GnRH administration. Because circulating testosterone concentrations in bitches are described to be low or undetectable (Nickel 1996), and no studies could be found that report diurnal variation of plasma testosterone concentrations in bitches, only one pre-GnRH trial sample for testosterone was collected.

The results of this study demonstrate that mean basal plasma LH concentrations were significantly higher in OVX bitches than in anestrous bitches. Moreover, there was no overlap in basal plasma LH concentrations between the two groups. The higher basal plasma LH concentrations in the OVX dogs are in agreement with the results of other studies (Chaffaux et al. 1981; Olson et al. 1992; Jeffcoate 1993a; Concannon 1993; Löfstedt and Vanleeuwen 2002; Reichler et al. 2004) and can be explained by the loss of negative feedback of the ovarian hormones. However, taking into account the pulsatile nature of LH release (Concannon 1993; Kooistra et al. 1999), overlapping of plasma LH concentrations between larger groups of intact and OVX bitches may be expected, and therefore one single LH result should be interpreted with caution. Indeed, a single measurement of LH has been shown not to be a reliable means of determining whether or not a bitch was intact (Löfsteds and Vanleeuwen 2002). In addition, circulating LH concentrations of < 1 µg/l 10 to 16 weeks after ovariectomy in some bitches have been found (Reichler et al. 2004). Consequently, the presence or absence of ovarian tissue should not be based solely upon the results of a single basal plasma LH measurement.

In both anestrous and OVX bitches, GnRH administration provoked a significant increase in the plasma LH concentration. Due to the complete loss of negative feedback of ovarian hormones a maximal stimulation of pituitary gonadotropin release may have been expected. However, in postmenopausal women the secretion pattern of LH is still

pulsatile, and GnRH administration provokes an increase in the plasma LH concentration (Rossmanith et al. 1991), indicating that stimulation of pituitary LH release is still occurring in ovarian hormone-deprived women. Moreover, pulsatile LH release has also been reported in OVX bitches (Concannon 1993).

In agreement with previous studies (Van Haaften et al. 1994; Meij et al. 1996), in the protocol used plasma LH concentration reached its maximum level at 10 min after GnRH administration in both groups. It also reached its maximum in OVX bitches at 10 min after intramuscular administration of GnRH (Chaffaux et al. 1981). The overlap between anestrous bitches and OVX bitches in plasma LH values 10 min after GnRH administration makes this measurement an unreliable method for distinguishing between the two groups.

Plasma estradiol concentration was below the detection limit of the assay in all OVX dogs and 5 of the 6 anestrous dogs before GnRH administration and in the OVX dogs after GnRH administration. There was a significant increase in plasma estradiol concentration following GnRH stimulation in all the intact bitches but in none of the OVX bitches. As found in a previous study (Van Haaften et al. 1994), the dose of GnRH (Fertagyl®) of 10 µg/kg was sufficient to induce an increase in plasma estradiol concentration in the intact bitches. In other studies (Jeffcoate 1992; Jeffcoate 1993b), a dose of 0.16 µg GnRH (Receptal®) per dog, which is, although Receptal® is more efficient than Fertagyl® (Chenault 1990), a much lower dose than used in this protocol, failed to induce a clear increase in plasma estradiol concentration in intact dogs. LH and estradiol responses after GnRH administration in anestrous bitches are significantly dose dependent; a dose of 0.01 µg/kg produced little or no response (Van Haaften et al. 1994). The results of the present study suggest that the plasma estradiol response to an adequate dose of GnRH (Fertagyl®; 10 µg/kg) may be a useful and reliable test with which to distinguish between bitches with and without ovarian tissue. The time at which the plasma estradiol concentration is maximal after GnRH administration could not been determined in this study. Also in another study, it has been observed that GnRH doses of 0.1 to 100 µg/kg raise plasma estradiol concentration for 160 min (Van Haaften et al. 1994).

In women, estradiol is also produced in a number of extra-ovarian sites. These sites include the mesengial cells of adipose tissue including that of the breast, osteoblasts and chondrocytes of bone, vascular endothelium and aortic smooth muscle cells and numerous sites in the brain. However, at these sites estradiol acts locally as a paracrine or intracrine factor, rather than that it is secreted into the circulation (Simpson 2003). Most probably this also accounts for the dog, and therefore a significant rise in plasma estradiol concentration after GnRH administration can be expected only if ovarian tissue is present. In addition, Frank et al. (2003) performed an ACTH-stimulation test and no increase in

circulating estradiol could be evoked in either OVX or intact bitches, indicating that the adrenal glands do not contribute to the circulating estradiol concentration.

The difference in plasma progesterone concentration between anestrous and OVX bitches was not significant and the ranges overlapped both before and after GnRH administration. This is in agreement with the findings of others (Jeffcoate 1993a; Frank et al. 2003). Although the main source of progesterone in the intact bitch is the ovary, progesterone can also be secreted by the adrenal cortex (Frank et al. 2004), which is the most logical explanation for the detectable plasma progesterone level in one of the OVX dogs (Concannon 1986). This could be related to stress, since progesterone increases have been reported to occur as a reaction to fear provocations in dogs (Hydbring-Sandberg et al. 2004). On the other hand, in the male dog LH and testosterone values are not influenced by blood sampling (Knol et al. 1992), implying that under the experimental conditions used the validity of results will not be affected by blood collection. Since it is not completely clear to what extent stress might influence the results, the potential effect of stress has to be considered when examining the function of the hypothalamic-pituitary-ovarian axis.

The differences in plasma testosterone concentrations before and after GnRH administration between intact and OVX bitches were not significant. For baseline testosterone concentrations this is in agreement with the results in another study in the dog (Frank et al. 2003). Although mean plasma testosterone concentration in the anestrous bitches appeared to reflect the increase in mean plasma estradiol concentration, the change was not significant ($P=0.15$). As estradiol is formed from testosterone by the action of the aromatase system (Edqvist and Forsberg 1997), this non-significant increase in the plasma testosterone concentration most probably reflects estradiol synthesis in the follicles. Different findings have been reported in women. The basal plasma testosterone concentration in oophorectomized women is significantly lower than that in intact women. Furthermore, stimulation with human chorionic gonadotropin (hCG) raises plasma testosterone concentration in intact women but not in oophorectomized women (Burger 2002; Piltonen et al. 2002).

It is uncertain whether the plasma LH and estradiol responses observed in intact bitches can be expected to be completely the same in bitches with remnant ovarian tissue. In a previous study (Okkens et al. 1981) 12 of 47 bitches with remnant ovarian tissue were found to have macroscopic cystic structures in the residual ovarian tissue. The effect of these cystic remnants on the results of the GnRH-stimulation test is unknown and the successful use of this test in the detection of remnant ovarian tissue has not yet been reported in animals, as it has in humans (Scott et al. 1995).

It can be concluded that 1) basal plasma LH concentration is significantly higher in OVX bitches than in anestrous bitches, 2) plasma LH concentration increases after GnRH

administration in both anestrous and OVX bitches, 3) GnRH administration causes a significant rise in plasma estradiol concentration only if ovarian tissue is present, and 4) measurement of plasma progesterone and testosterone concentrations before and after GnRH administration does not aid in distinguishing between anestrous and OVX bitches. The results of this study provide a basis for the diagnosis of remnant ovarian tissue and verification of neuter status in the bitch. However, further studies remain to be applied in bitches suspected of remnant ovarian tissue.

Acknowledgements

The authors would like to acknowledge Mr. H.G.H. van Engelen for his assistance in performing the experiments. The excellent assistance of Mrs. D.M. Blankenstein and Ms. C.H.Y Oei of the Biochemical Laboratory is highly appreciated. We thank Mr. J. van den Broek for his valuable assistance with the statistical analysis. The critical reading of the manuscript by Prof. Dr. J. Rothuizen and Dr. B.E. Belshaw is highly appreciated.

References

Burger HG. Androgen production in women. Fertil Steril 2002;77:S3-S5.

Chaffaux S, Chassagnite F, Thibier M. Concentration of LH après stimulation par la gonadoliberine (LRH) chez la chienne et effet de l'ovariectomie. Rec Med Vet 1981;10:725-733.

Chenault JR. Effect of fertirelin acetate or buserelin on conception rate at first or second insemination in lactating dairy cows. J Dairy Sci 1990;73:633-638.

Concannon PW, Hansel W, McKentee K. Changes in LH, progesterone and sexual behavior associated with preovulatory luteinization in the bitch. Biol Reprod 1977;17:604-613.

Concannon PW, Castracane VD. Serum androstenedione and testosterone concentrations during pregnancy and nonpregnant cycles in dogs. Biol Reprod 1985;33:1078-1083.

Concannon PW. Canine physiology of reproduction. In: Small Animal Reproduction and Fertility: A clinical approach to diagnosis and treatment. Burke TJ (Ed). Lea and Febiger, Philadelphia, 1986; pp. 23-77.

Concannon PW. Biology of gonadotropin secretion in adult and prepubertal female dogs. J Reprod Fertil Suppl 1993;47:3-27.

De Gier J, Kooistra HS, Djajadiningrat-Laanen SC, Dieleman SJ, Okkens AC. Differential regulation of the secretion of luteinizing hormone and follicle-stimulating hormone around the time of ovulation in the bitch. Theriogenology 2006;66:1419-1422.

Dieleman SJ, Bevers MM. Effects of monoclonal antibody against PMSG administered shortly after the preovulatory LH surge on time and number of ovulations in PMSG/PG-treated cows. J Reprod Fertil 1987;81:533-542.

Edqvist L, Forsberg M. Clinical Reproductive Endocrinology. In: Clinical Biochemistry of Domestic Animals. Kaneko JJ, Harvey JW, Bruss ML (Eds). Academic Press San Diego, 5th ed, 1997, pp. 589-618.

England GCW, Allen WE. Real-time ultrasonic imaging of the ovary and uterus of the dog. J Reprod Fertil Suppl 1989;39:91-100.

Frank LA, Rohrbach BW, Bailey EM, West JR, Oliver JW. Steroid hormone concentration profiles in healthy intact and neutered dogs before and after cosyntropin administration. Domest Anim Endocrinol 2003;24:43-57.

Frank LA, Davis JA, Oliver JW. Serum concentrations of cortisol, sex hormones of adrenal origin and adrenocortical steroid intermediates in healthy dogs following stimulation with two doses of cosyntropin. Am J Vet Res 2004;65:1631-1633.

Hydbring-Sandberg E, Von Walter LW, Höglund K, Svartberg K, Swenson L, Forkman B. Physiological reactions to fear provocation in dogs. Endocrinology 2004;180:439-448.

Jeffcoate IA. Concentrations of luteinizing hormone and estradiol in plasma and response to injection of gonadotropin releasing hormone analogue at selected stages of anestrus in domestic bitches. J Reprod Fertil 1992;94:423-429.

Jeffcoate IA. Gonadotropin-releasing hormone challenge to test for the presence of ovaries in the bitch. J Reprod Fertil Suppl 1993a;47:536-538.

Jeffcoate IA. Endocrinology of anestrous bitches. J Reprod Fertil Suppl 1993b;47:69-76.

Knol BW, Dieleman SJ, Bevers MM, van den Brom WE, Mol JA. Effects of methods used for blood collection on plasma concentrations of luteinizing hormone, testosterone, and cortisol in male dogs. Vet Quart 1992;14:126-129.

Knol BW, Dieleman SJ, Bevers MM, van den Brom WE. GnRH in the male dog: dose-response relations with LH and testosterone. J Reprod Fertil 1993;98:159-161.

Kooistra HS, Okkens AC, Bevers MM, Popp-Snijders C, van Haaften B, Dieleman SJ, Schoemaker J. Concurrent pulsatile secretion of luteinizing hormone and follicle-stimulating hormone during different phases of the estrous cycle and anestrus in beagle bitches. Biol Reprod 1999;60:65-71.

Löfstedt RM, Vanleeuwen JA. Evaluation of a commercially available luteinizing hormone test for its ability to distinguish between ovariectomized and sexually intact bitches. J Am Vet Med Assoc 2002;220:1331-1335.

Meij BP, Mol JA, Hazewinkel HAW, Bevers MM, Rijnberk A. Assessment of a combined anterior pituitary function test in beagle dogs: rapid sequential intravenous administration of four hypothalamic releasing hormones. Domest Anim Endocrinol 1996;13:161-170.

Nett TM, Akbar AM, Phemister RD, Holst PA, Reichert LE Jr, Niswender GD. Levels of luteinizing hormone, estradiol and progesterone in serum during the estrous cycle and pregnancy in the beagle bitch. Proc Soc Exp Biol Med 1975;148:134-139.

Nickel RF. Disorders of sexual differentiation. In: Clinical Endocrinology of Dogs and Cats, Rijnberk A (Ed). Kluwer Academic Publishers, Dordrecht, The Netherlands, 1996, pp. 157-166.

Okkens AC, Dieleman SJ, Van Der Gaag I. Gynaecologische complicaties na ovario-hysterectomie bij de hond ten gevolge van: 1. Het incompleet verwijderen van de ovaria. 2. Een ontsteking van uterus-cervixstomp. Tijdschr Diergeneesk 1981;106:1142-1158.

Okkens AC, Dieleman SJ, Bevers MM, Willemse AH. Evidence for the non-involvement of the uterus in the lifespan of the corpus luteum in the cyclic dog. Vet Quart 1985a;7:169-173.

Okkens AC, Bevers MM, Dieleman SJ, Willemse AH. Shortening of the interestrous interval and lifespan of the corpus luteum of the cyclic dog by bromocriptine treatment. Vet Quart 1985b;7:173-176.

Okkens AC, Teunissen JM, Van Osch W, Van Den Brom WE, Dieleman SJ, Kooistra HS. Influence of litter size and breed on the duration of gestation in dogs. J Reprod Fertil Suppl 2001;57:193–197.

Olson PN, Bowen RA, Behrendt M, Olson JD, Nett TM. Concentrations of reproductive hormones in canine serum throughout late anestrus, prestrus and estrus. Biol Reprod 1982;27:1196-1206.

Olson PN, Bowen RA, Behrendt MD, Olson JD, Nett TM. Concentrations of testosterone in canine serum during late anestrus, prestrus, estrus, and early diestrus. Am J Vet Res 1984;1:145-148.

Olson PN, Mulnix JA, Nett TM. Concentrations of luteinizing hormone and follicle-stimulating hormone in the serum of sexually intact and neutered dogs. Am J Vet Res 1992;53:762-766.

Piltonen T, Koivunen R, Morin-Papunen L, Ruokonen A, Huhtaniemi IT, Tapanainen JS. Ovarian and adrenal steroid production: regulatory role of LH/HCG. Hum Reprod 2002;17:620-624.

Reichler IM, Pfeiffer E, Piché CA, Jöchle W, Roos M, Hubler M, Arnold S. Changes in plasma gonadotropin concentrations and urethral closure pressure in the bitch during the 12 months following ovariectomy. Theriogenology 2004;62:1391-1402.

Root CR, Spaulding KA. Diagnostic imaging in companion animal theriogenology. Semin Vet Med Surg (Small Anim) 1994;9:7-27.

Rossmanith WG, Scherbaum WA, Lauritzen C. Gonadotropin secretion during aging in postmenopausal women. Neuroendocrinology 1991;54:211-218.

Schaefers-Okkens AC. Estrous cycle and breeding management of the healthy bitch. In: Textbook of Veterinary Internal Medicine. Diseases of the dog and cat. Ettinger SJ, Feldman EC (Eds). Saunders Philadelphia, 6th ed, 2005, pp. 1640-1649.

Schutte AP. Canine vaginal Cytology II. Cyclic changes. J Small Anim Pract 1976;8:307-311.

Scott RT, Beatse SN, Illions EH, Snyder RR. Use of the GnRH agonist stimulation test in the diagnosis of ovarian remnant syndrome. A report of three cases. J Reprod Med 1995;40:143-146.

Shille VM, Olson PM. Dynamic testing in reproductive endocrinology. In: Kirk RW (Ed). Current Veterinary Therapy X. WB Saunders Philadelphia; 1989;1282-1288.

Simpson ER. Sources of estrogen and their importance. J Steroid Biochem Mol Biol 1989;86:225-230.

Van Haaften B, Bevers MM, van den Brom WE, Okkens AC, van Sluijs FJ, Willemse AH, Dieleman SJ. Increasing sensitivity of the pituitary to GnRH from early to late anestrus in the beagle bitch. J Reprod Fertil 1994;101:221-225.

Wallace MS. The ovarian remnant syndrome in the bitch and queen. Vet Clin North Am Small Anim Pract 1991;21:501-507.

Wildt DE, Panko WB, Chakraborty PK, Seager SWJ. Relationship of serum estrone, estradiol-17β and progesterone to LH, sexual behavior and time of ovulation in the bitch. Biol Reprod 1979;20:648-658.

4

Chapter

Basal and GnRH-induced secretion of FSH and LH in anestrous versus ovariectomized bitches

NJ Beijerink[1], JJCWM Buijtels[1], AC Okkens[1], HS Kooistra[1], SJ Dieleman[2]

Theriogenology 2007;67:1039-1045

[1] Department of Clinical Sciences of Companion Animals, Faculty of Veterinary Medicine, Utrecht University, The Netherlands
[2] Department of Farm Animal Health, Section of Reproduction, Faculty of Veterinary Medicine, Utrecht University, Utrecht, The Netherlands

Abstract

The basal and gonadotropin-releasing hormone (GnRH)-induced plasma concentrations of follicle stimulating hormone (FSH) and luteinizing hormone (LH) were studied in four anestrous and four ovariectomized (OVX) bitches. Blood samples were obtained via jugular venipuncture 40 min before and 0, 10, 20, 30, 60, 90, and 120 min after the i.v. administration of synthetic GnRH in a dose of 10 µg/kg body weight.

The basal plasma FSH and LH concentrations were significantly higher in the OVX bitches than in the anestrous bitches. In the anestrous bitches the plasma FSH concentration was significantly higher than the pretreatment level at 10, 20, and 30 min, whereas the plasma LH concentration was significantly elevated at 10 and 20 min. The maximal GnRH-induced plasma FSH concentration in the anestrous bitches did not surpass the lowest plasma FSH concentration in the OVX bitches, whereas the GnRH-induced plasma LH concentrations in the anostrous bitches overlapped with the basal plasma LH concentrations in the OVX bitches. In the OVX bitches GnRH administration did not induce a significant change in the plasma FSH concentration, whereas the plasma LH concentration increased significantly at 10 and 20 min.

In conclusion, the results of the present study indicate that in anestrous bitches GnRH challenge results in increased plasma levels of both FSH and LH, whereas in the OVX bitches, in which the basal plasma FSH and LH concentrations are higher, only a rise in the plasma LH concentration is present after GnRH stimulation. The results also suggest that a test to measure plasma concentration of FSH in single samples appears to have potential in verification of neuter status in bitches.

Introduction

The reproductive cycle of the bitch is under endocrine control exerted by interactions among the hypothalamus, anterior pituitary, and ovary; the so-called hypothalamic-pituitary-ovarian axis. The neuroendocrinological mechanisms responsible for the release of follicle stimulating hormone (FSH) and luteinizing hormone (LH) by the pituitary are very complex. It is generally accepted that these gonadotropins are secreted in a pulsatile fashion (Kooistra et al. 1999) in response to the similarly pulsatile release of gonadotropin releasing hormone (GnRH). The gonadotropins stimulate ovarian hormone secretion, which in turn regulates the gonadotropins via a negative feedback mechanism (long-loop negative feedback). The extent of GnRH release and subsequently gonadotropin release seems to be dependent upon sensitivity of the hypothalamus to estradiol. During progression of anestrus, there is gradual reestablishment of positive feedback of estradiol on the hypothalamus (Klein et al. 2003), and GnRH secretion (Tani et al. 1996) and the responsiveness of the pituitary to GnRH increase (Van Haaften et al. 1994). In addition, a large amount of LH is released prior to ovulation, due to this positive feedback elicited by the rapidly rising plasma estradiol level (De Gier et al. 2006). Apart from the feedback of the gonadal hormones, two additional feedback loops have been identified. These are the gonadotropin-dependent inhibition of GnRH production (short-loop negative feedback) and the GnRH-dependent inhibition of GnRH production, known as ultrashort-loop negative feedback (Speroff and Fritz, 2005).

The measurement of plasma FSH and LH concentrations before and after administration of a GnRH analogue during different reproductive conditions, such as during anestrus and after ovariectomy, permits assessment of the capacity of the pituitary to secrete gonadotropins. Knowledge about the characteristics of gonadotropin secretion after intravenous administration of a GnRH analogue in the anestrous bitch is mainly limited to LH (Buijtels et al. 2006), the response of which is dosage-dependent (Van Haaften et al. 1994; Chakraborty and Fletcher 1977). Furthermore, an increasing dosage-dependent response of LH to stimulation with GnRH was found in the bitch during the progression of anestrus (Van Haaften et al. 1994), but another study revealed no apparent correlation between stage of anestrus and LH response (Jeffcoate 1992). However, the used GnRH dosage in the latter study was minimal. Only one study was concerned with the concomitant secretion of the gonadotropins in the bitch after GnRH administration and showed that in cyclic bitches FSH and LH levels increased within 15 min after GnRH stimulation (Reimers et al. 1978).

Ovariectomy (OVX) influences the long-loop feedback. The loss of inhibitory influence of ovarian steroids and peptides on the hypothalamic-pituitary axis causes a

rapid increase in the plasma concentration of both LH (Chaffaux et al. 1981; Olson et al. 1992; Concannon 1993; Jeffcoate 1993; Löfstedt and Vanleeuwen 2002; Reichler et al. 2004; Buijtels et al. 2006) and FSH (Olson et al. 1992; Concannon 1993; Reichler et al. 2004), while there are indications that the secretion pattern of both remains pulsatile (Concannon 1993). Little is known about the characteristics of gonadotropin secretory response to exogenous GnRH in the OVX bitch. Both a rise (Chaffaux et al. 1981; Buijtels et al. 2006) and an unpredictable response (Jeffcoate, 1993) in the plasma LH concentration have been reported. So far, in OVX bitches there is neither information on GnRH-induced FSH secretion nor on the concomitant secretion of FSH and LH after GnRH administration.

The present study was designed to compare the basal and GnRH-induced plasma concentrations of FSH and LH in OVX bitches with those in anestrous bitches.

Materials and Methods

Animals, treatment and collection of blood samples

Four intact Beagle bitches (weighing 11.3 to 14.1 kg and aged 2 to 5 years), in which the previous estrus cycle had been monitored and characterized, and four OVX Beagle bitches (weighing 12.8 to 16.0 kg and aged 9 to 10 years) were included in this study. All dogs were whelped and raised in the Department of Clinical Sciences of Companion Animals and were accustomed to the laboratory environment and procedures, such as the collection of blood samples. They were housed in pairs in indoor-outdoor runs, fed a standard commercial dog food once daily, and provided with water ad libitum. The four intact Beagles were examined three times per week for the presence of swelling of the vulva and a serosanguinous vaginal discharge, which were considered to signify the onset of pro-estrus. Plasma concentrations of progesterone were determined three times per week from the start of pro-estrus until the day on which the plasma progesterone concentration exceeded 16 nmol/l, which is when ovulation was assumed to occur (Concannon et al. 1977; Wildt et al. 1979; Okkens et al. 1985a). During this study all bitches were in anoestrus (104 to 118 days after ovulation), as confirmed by plasma progesterone concentrations below 3 nmol/l (Okkens et al. 1985b). The four remaining dogs had been ovariectomized at the Department of Clinical Sciences of Companion Animals at Utrecht University at least one year before the start of the experiment and had exhibited no signs of recurrent estrus.

At 09.00 h (time is 0 min) 10 μg/kg synthetic GnRH (Fertagyl® batch 20105B; Intervet International BV, Boxmeer, The Netherlands) was administered via the cephalic

vein in all Beagle bitches. Blood samples were taken 40 min before and 0, 10, 20, 30, 60, 90, and 120 min after the administration of GnRH.

Blood samples were collected from the jugular vein, immediately placed in chilled EDTA-coated tubes, and centrifuged at 4 ºC for 10 min at 1500 *g*. Plasma was stored at –25 ºC until analysis. All samples from each dog were measured in the same FSH or LH assay.

Hormone measurements

Plasma FSH concentration was measured by the canine immunoradiometric assay (IRMA) of Biocode SA (Liège, Belgium) coded AHCOO4. This IRMA uses a first and a second monoclonal mouse anti-FSH antibody. These antibodies were raised against rat-FSH and have cross-species reactivity (rat, dog, horse) (personal communication, Biocode SA). Briefly, the procedure used highly purified canine FSH diluted in horse serum provided by the manufacturer to produce a standard curve ranging from 1.5 to 240 µg/l. An excess of a first monoclonal mouse anti-rat FSH antibody bound to polystyrene tubes captured the canine FSH present in 100 µl standards or samples. Thereafter, a second [^{125}I]-labeled monoclonal mouse anti-rat FSH antibody (50 µl), directed to another determinant on the FSH molecule, was added to the tubes, which were incubated at room temperature for 90 min. According to the manufacturer, the cFSH used as standard was derived from extracts of pituitary glands of dogs collected over several years in Belgium. Pituitary extracts were purified by ion exchange and gel filtration. The monoclonal antibodies were obtained by injecting highly purified rat FSH in mice after which splenocytes of the mice were fused with Sp2O myeloma cells. Finally, diluted positive clones were tested for binding to iodinated cFSH to obtain highly stabilized monoclonal cells. The reported purity of the antibodies (IgG class) is >95%. More detailed information on the reagents is not available.

To validate the FSH IRMA for parallelism, accuracy, and precision, plasma from an OVX bitch 10 min after the administration of 10 µg/kg GnRH was diluted with plasma from an anestrous bitch before GnRH stimulation (dilutions 1:2 to 1:32). Each level of dilution was measured six times. As shown in Table 1, the precision and accuracy are within commonly accepted ranges. In addition, the intra-assay coefficient of variation (CV) was measured in 12 replicates of each of four samples in a single assay. These four quality controls samples were included in duplicate in all assays (n=12) to determine the interassay CV. The intra-assay and the interassay CV for values above 1.60 µg/l were 3.5% and 15.1%, respectively. Cross-reactivity of canine LH (LER 1685-1; Dr. L.E. Reichert, Albany Medical College, NY, USA) with the first mouse anti-rat FSH monoclonal antibodies bound to the tube was determined by adding the preparation to PBS buffer containing 0.29 % (w/v) human immunoglobulin (Central Laboratory of the

Netherlands Red Cross Blood Transfusion Service, Amsterdam, The Netherlands) and 0.36 % (w/v) bovine serum albumin (BSA; Povite, Organon, Oss, The Netherlands) at pH of 7.4. Maximal binding in the FSH IRMA was 36.8 ± 2.2%. At 50% of the maximal binding the cross-reactivity of canine LH (LER 1685-1) in this assay was 1.8%. The limit of quantitation of canine FSH was arbitrarily defined as the value of the lowest standard, 1.50 µg/l, and FSH values below this were arbitrarily assigned the value of one-third of this limit, i.e., 0.5 µg/l.

Table 1. *Accuracy and precision in the estimation of follicle stimulating hormone (FSH) by immunoradiometric assay. Each dilution was measured six times. All samples were measured in the same assay.*

Dilution	Added dose µg/l *[1]	Estimated dose µg/l *[2]	SD µg/l *[3]	CV % *[4]	Recovery % *[5]
Undiluted	47.76	47.76	0.99	2.07	100
1:2	23.88	22.25	0.95	4.26	93.2
1:4	11.94	10.59	0.41	3.88	88.7
1:8	5.97	5.24	0.31	5.90	87.8
1:16	2.98	2.65	0.13	4.95	88.9
1:32	1.49	1.32	0.13	9.88	88.6

*[*1] Canine FSH was added by diluting plasma collected from an ovariectomized bitch 10 minutes after intravenous administration of a GnRH analogue (10 µg/kg) with plasma from an anoestrus bitch. [*2] Values were corrected for the FSH responses in the IRMA of 1.57 µg/l of the plasma of the anoestrus bitch. [*3] SD: standard deviation. [*4]CV: coefficient of variation, this value indicates the precision of the assay. [*5] Accuracy (recovery) is defined as estimated dose relative to added dose (E/A * 100%).*

Plasma LH concentration was measured by a heterologous RIA as described previously (Nett et al. 1975; Van Haaften et al. 1994). Briefly, a rabbit antiserum raised against ovine LH (CSU-204, kindly supplied by GD Niswender, Colorado State University, CO, USA), radioiodinated bLH-7981 as prepared for our bovine LH assay (Dieleman and Bevers, 1987), and canine pituitary standard LER 1685-1 (a gift from Dr. LE Reichert) were used in this assay. The intra-assay and interassay CV for values above 0.5 µg/L were 2.3% and 10.5%, respectively, and the limit of quantitation was 0.3 µg/l.

Plasma progesterone concentration was measured by a previously validated ^{125}I RIA (Okkens et al. 2001). The intra-assay and interassay CV were 6% and 10.8%, respectively, and the limit of quantitation was 0.15 nmol/l.

Data analysis

A Kolmogorov Smirnov test showed that, even after transformation to natural logarithms, the plasma profile data were not normally distributed. Hence the untransformed plasma profile data for FSH and LH were compared per group by the nonparametric Friedman test, followed by a multiple comparisons test using Dunnett's procedure. This test evaluated the changes in the GnRH stimulation test compared with the mean of the two pretreatment values. Differences in the pretreatment values, the peak concentration, the relative peak compared with the pretreatment value (i.e. peak value/basal value) and the area under the curve (AUC) above the pretreatment concentration between the two groups were assessed for statistical significance by the nonparametric Wilcoxon-Mann-Whitney test. The AUC of the hormone concentrations after the GnRH challenge test was calculated by the trapezoidal method after subtraction of the mean pretreatment level per dog. Results are presented as median and range or mean ± SEM. The level of significance was $P < 0.05$.

Ethics of experimentation

This study was approved by the Ethical Committee of the Faculty of Veterinary Medicine, Utrecht University.

Results

The basal (pre-GnRH) plasma concentrations of FSH and LH were significantly higher in the OVX dogs than in the anestrous dogs (Table 2). In the anestrous dogs, plasma concentrations of both FSH and LH increased after GnRH administration. The plasma FSH concentration was significantly elevated at 10, 20, and 30 min, whereas the plasma LH concentration was significantly higher than the basal level at 10 and 20 min (Figure 1). In the anestrous dogs, GnRH-induced plasma profiles of both FSH and LH were characterized by an abrupt and rapid rise followed by a slow decline; slower for FSH than for LH. The GnRH-induced increase in plasma LH concentration above basal levels was much higher than that of FSH. In the OVX bitches, plasma FSH concentration remained unchanged after GnRH administration. In contrast, plasma LH concentration was significantly increased at 10 and 20 min (Figure 2). The median peak concentration of LH

was significantly higher in the OVX dogs than in the anestrous dogs, but the relative increase in LH was significantly greater in the anestrous dogs than in the OVX dogs. The median AUC of the LH response did not differ between the anestrous dogs and the OVX dogs (Table 2). The maximal GnRH-induced plasma FSH concentration in the anestrous bitches did not exceed the lowest plasma FSH concentration in the OVX bitches, whereas the GnRH-induced plasma LH concentrations in the anestrous bitches overlapped with the basal plasma LH concentrations in the OVX bitches (Table 2).

***Table 2**. Characteristics of the GnRH-induced surges of follicle stimulating hormone (FSH) and luteinizing hormone (LH) in four anestrous and four ovariectomized (OVX) bitches (median and range).*

	Anestrous bitches (n=4)	Ovariectomized bitches (n=4)
FSH pre-GnRH concentration (µg/l)	5.6* 2.8 – 13.9	81.7* 40.7 - 107.5
FSH peak amplitude (µg/l)	25.4 18.4 - 27.0	_
FSH peak amplitude relative to basal	3.9 2.0 - 9.5	_
FSH time of peak amplitude (min)	20 10 - 20	_
FSH AUC above baseline (µg*min/l)	1475 333 - 1952	_
LH pre-GnRH concentration (µg/l)	1.02* 0.81 - 5.4	31.4* 6.4 - 64.3
LH peak amplitude (µg/l)	34.9* 26.5 - 38.4	60.7* 48.3 - 359
LH peak amplitude relative to basal	30.7* 9.7 - 41.4	3.8* 1.3 - 6.4
LH time of peak amplitude (min)	10 10 - 10	10 10 - 10
LH AUC above baseline (µg*min/l)	1038 862 - 1237	2032 688 - 5546

** indicates significant difference between anestrous and OVX dogs.*

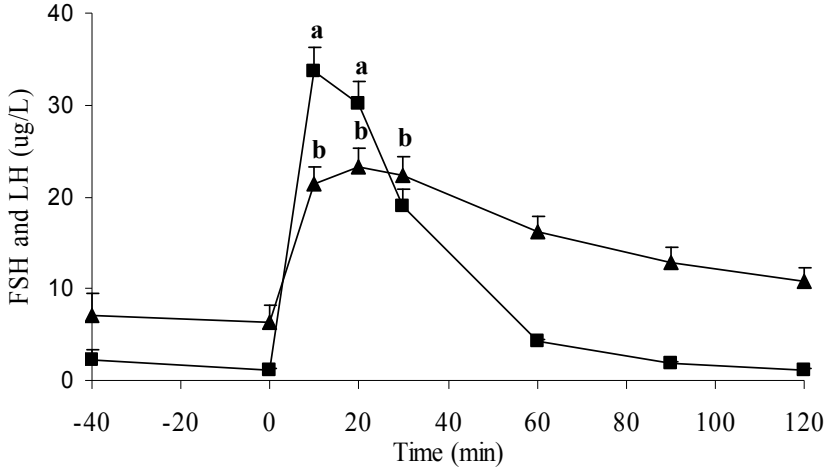

Figure 1. *Mean (± SEM) plasma concentrations of follicle stimulating hormone (FSH) and luteinizing hormone (LH) in four intact anestrous bitches after administration of synthetic GnRH (gonadotropin releasing hormone) (10 µg/kg) via the cephalic vein at t = 0 min. ▲= FSH, ■ = LH. The letters (a, b) indicate significant difference compared with the mean of the pre-GnRH values for the plasma concentrations of LH and FSH, respectively. The bars indicating the SEM are shown only when they exceed the size of the symbols.*

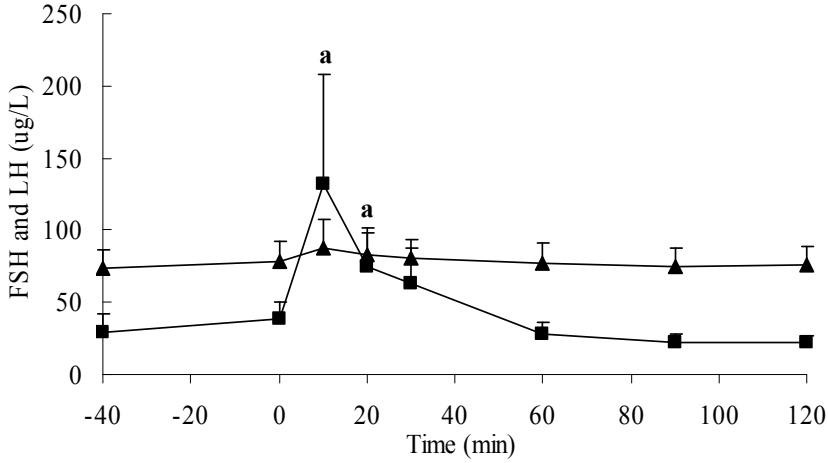

Figure 2. *Mean (± SEM) plasma concentrations of follicle stimulating hormone (FSH) and luteinizing hormone (LH) in four ovariectomized bitches after administration of synthetic GnRH (gonadotropin-releasing hormone) (10 µg/kg) via the cephalic vein at t = 0 min. ▲= FSH, ■ = LH. Letter (a) indicates significant difference compared with the mean of the pre-GnRH values for the plasma LH concentration. The bars indicating the SEM are shown only when they exceed the size of the symbols.*

Discussion

Pituitary gonadotropin release plays a central role in the development and function of the canine reproductive system. The measurement of plasma LH and FSH concentrations before and after the administration of a GnRH analogue permits assessment of the capacity of the pituitary to secrete gonadotropins under different reproductive conditions. In agreement with the findings of others, GnRH administration elicited a distinct release of LH (Chakraborty and Fletcher 1977; Reimers et al. 1978; Jeffcoate 1992; Van Haaften et al. 1994; Buijtels et al. 2006) and FSH (Reimers et al. 1978). The course of the GnRH-induced surges in FSH and LH in the anestrous bitches was comparable to what has been reported previously for spontaneous FSH and LH pulses in anestrous bitches (Kooistra et al. 1999). The GnRH-induced plasma LH increments above the pre-GnRH levels were much greater than the corresponding FSH increments. Subsequently, plasma FSH concentration declined more slowly than plasma LH concentration in the anestrous bitches. As in other mammals (Schwartz, 1995), this may be explained by a different pattern of glycosylation of FSH and LH, resulting in a longer half-life for FSH than LH.

The loss of ovarian feedback after ovariectomy resulted in increased plasma concentrations of FSH and LH in all OVX bitches, as has been reported earlier (Chaffaux et al. 1981; Olson et al. 1992; Concannon 1993; Jeffcoate 1993; Löfstedt and Vanleeuwen 2002; Reichler et al. 2004). In the OVX bitches, GnRH only elicited a significant response in the plasma LH concentration. Since there was no significant rise in plasma FSH concentration, it can be concluded that the pituitary response to GnRH in OVX bitches differs from that in anestrous bitches. It may be hypothesized that this is the consequence of different intracellular mechanisms for storage and release for FSH and LH. This view is supported by in vitro studies with cells of other mammalian species, which have shown that although FSH and LH are produced in the same cell type, they are stored in different secretory granules (Moyle and Campbell 1995), newly synthesized FSH is secreted at a greater rate than LH (Chowdhury and Steinberger 1975), and that the magnitude of the FSH response to secretagogues is smaller than that of LH (Chowdhury and Steinberger 1975; Muyan et al. 1994).

Occasionally, it can be difficult to verify the neuter status of dogs with an unknown reproductive status (Buijtels et al. 2006). Although all pre-GnRH plasma LH concentrations were higher in OVX dogs than in sexually intact dogs, measurement of circulating LH concentration in a single sample has limited potential for distinguishing between OVX and sexually intact bitches. Taking into account the strong pulsatile nature of LH release (Kooistra et al. 1999; Concannon 1993), an overlap in the plasma LH concentration between larger groups of intact and OVX bitches may be expected. Indeed,

in the current study GnRH-induced LH increments in the intact bitches overlapped pre-GnRH plasma LH concentrations in the OVX bitches. A single high LH value measured by a commercial test kit was not reliable in indicating whether a bitch was intact (Löfstedt and Vanleeuwen, 2002). In contrast, the results reported here indicate that measurement of plasma FSH concentration in a single sample may well prove reliable for determination of neuter status. Even after GnRH administration the maximum plasma FSH level in the intact bitches did not exceed the lowest plasma FSH level during the entire GnRH-stimulation test in the OVX bitches. Other investigators have also suggested that the pituitary capacity to secrete FSH in the absence of ovarian negative feedback is far greater than that ever observed in the intact bitch (Olson et al. 1992; Concannon 1993). Such a difference could be expected if there is a specific inhibition of FSH as opposed to LH secretion in intact bitches, i.e., due to ovarian-derived inhibin (Shupnik 1996). Furthermore, plasma FSH levels in women usually increase more than do LH levels when the ovaries are functionally inactive or surgically removed (Bulun and Adashi 2003, Genuth 2004). This indicates that differences in circulating FSH concentration between intact and OVX bitches could be greater than within-group variability. Another study with a greater number of animals is needed to evaluate the measurement of plasma FSH concentration as a potential diagnostic marker of neuter status.

In conclusion, the results of the present study indicate that in anestrous bitches GnRH challenge results in increased plasma levels of both FSH and LH, whereas in the OVX bitches, in which the basal plasma FSH and LH concentrations are higher, only a rise in the plasma LH concentration is present after GnRH stimulation. The results also suggest that a test to measure plasma concentration of FSH in single samples appears to have potential in verification of neuter status in bitches.

Acknowledgements

The authors thank Mr. H.G.H. van Engelen for his assistance in performing the experiments. The excellent assistance of Mrs. D.M. Blankenstein and Ms. C.H.Y Oei of the Biochemical Laboratory is highly appreciated. The critical reading of the manuscript by Prof. Dr. J. Rothuizen and Dr. B.E. Belshaw is highly appreciated. We thank Dr. W.E. van den Brom for his valuable assistance with the statistical analysis and Beckman Coulter BV (Mijdrecht, The Netherlands) for support with the FSH IRMA.

References

Buijtels JJCWM, Beijerink NJ, Kooistra HS, Dieleman SJ, Okkens AC. Effects of gonadotropin releasing hormone administration on the pituitary-ovarian axis in anestrous vs ovariectomized bitches. Reprod Dom Anim 2006;41:555-561.

Bulun SE, Adashi EY. The physiology and pathology of the female reproductive axis. In: Williams Textbook of Endocrinology 10th edition. Larsen PR, Kronenberg HM, Melmed S, Polonsky KS (Eds). Saunders, Philadelphia, PA, USA, 2003, pp. 587-664.

Chaffaux S, Chassagnite F, Thibier M. Concentration of LH après stimulation par la gonadoliberine (LRH) chez la chienne et effet de l'ovariectomie. Rec Med Vet 1981;10:725-733.

Chakraborty PK, Fletcher WS. Responsiveness of anoestrus Labrador bitches to GnRH. Proc Soc Exp Biol Med 1977;154:125-126.

Chowdhury M, Steinberger E. Biosynthesis of gonadotropins by rat pituitaries in vitro. J Endocrinol 1975;66:369-374.

Concannon PW, Hansel W, McKentee K. Changes in LH, progesterone and sexual behavior associated with preovulatory luteinization in the bitch. Biol Reprod 1977;17:604-613.

Concannon PW. Biology of gonadotropin secretion in adult and prepubertal female dogs. J Reprod Fertil Suppl 1993;47:3-27.

De Gier J, Kooistra HS, Djajadiningrat-Laanen SC, Dieleman SJ, Okkens AC. Temporal relations between plasma concentrations of luteinizing hormone, follicle-stimulating hormone, estradiol-17β, progesterone, prolactin, and α-melanocyte-stimulating hormone during the follicular, ovulatory, and early luteal phase in the bitch. Theriogenology 2006;65:1346–1359.

Dieleman SJ, Bevers MM. Effects of monoclonal antibody against PMSG administered shortly after the preovulatory LH surge on time and number of ovulations in PMSG/PG-treated cows. J Reprod Fertil 1987;81:533-542.

Genuth SM. The hypothalamus and pituitary gland. In: Physiology, 5th edition. Berne RM, Levy MN, Koeppen BM, Stanton BA (Eds). Mosby, St. Louis, MO, USA, 2004, pp. 819-859.

Jeffcoate IA. Concentrations of luteinizing hormone and estradiol in plasma and response to injection of gonadotropin-releasing hormone analogue at selected stages of anoestrus in domestic bitches. J Reprod Fertil 1992;94:423-429.

Jeffcoate IA. Gonadotropin-releasing hormone challenge to test for the presence of ovaries in the bitch. J Reprod Fertil Suppl 1993;47:536-538.

Klein R, Schams D, Failling K, Hoffmann B. Investigations on the re-establishment of the positive feedback of estradiol during anoestrus in the bitch. Reprod Dom Anim 2003;38:13-20.

Kooistra HS, Okkens AC, Bevers MM, Popp-Snijders C, Van Haaften B, Dieleman SJ, Schoemaker J. Concurrent pulsatile secretion of luteinizing hormone and follicle-stimulating hormone during different phases of the oestrus cycle and anoestrus in Beagle bitches. Biol Reprod 1999;60:65-71.

Löfstedt RM, Vanleeuwen JA. Evaluation of a commercially available luteinizing hormone test for its ability to distinguish between ovariectomized and sexually intact bitches. J Am Vet Med Assoc 2002;220:1331-1335.

Moyle WR, Campbell RK. Gonadotropins. In: Reproductive Endocrinology, Surgery and Technology. Adashi EY, Rock JA, Rosenwaks Z (Eds). Lippincott-Raven Publishers, Philadelphia, PA, USA, 1995, pp. 683-724.

Muyan M, Ryzmkiewicz DM, Boime I. Secretion of lutropin and follitropin from transfected GH_3 cells: evidence for separate secretory pathways. Mol Endocrinol 1994;8:1789-1797.

Nett TM, Akbar AM, Phemister RD, Holst PA, Reichert Jr LE, Niswender GD. Levels of luteinizing hormone, estradiol and progesterone in serum during the estrus cycle and pregnancy in the Beagle bitch. Proc Soc Exp Biol Med 1975;148:134-139.

Okkens AC, Bevers MM, Dieleman SJ, Willemse AH. Shortening of the interestrus interval and lifespan of the corpus luteum of the cyclic dog by bromocriptine treatment. Vet Quart 1985a;7:173-176.

Okkens AC, Dieleman SJ, Bevers MM, Willemse AH. Evidence for the non involvement of the uterus in the lifespan of the corpus luteum in the cyclic dog. Vet Quart 1985b;7:169-173.

Okkens AC, Teunissen JM, Van Osch W, Van Den Brom WE, Dieleman SJ, Kooistra HS. Influence of litter size and breed on the duration of gestation in dogs. J Reprod Fertil Suppl 2001;57:193-197.

Olson PN, Mulnix JA, Nett TM. Concentrations of luteinizing hormone and follicle-stimulating hormone in the serum of sexually intact and neutered dogs. Am J Vet Res 1992;53:762-766.

Reichler IM, Pfeiffer E, Piché CA, Jöchle W, Roos M, Hubler M, Arnold S. Changes in plasma gonadotropin concentrations and urethral closure pressure in the bitch during the 12 months following ovariectomy. Theriogenology 2004;62:1391-1402.

Reimers TJ, Phemister RD, Niswender GD. Radioimmunological measurement of follicle stimulating hormone and prolactin in the dog. Biol Reprod 1978;19:673-679.

Schwartz NB. The 1994 Stevenson Award Lecture. Follicle-stimulating hormone an luteinizing hormone: a tale of two gonadotropins. Can J Physiol Pharmacol 1995;73:675-684.

Shupnik MA. Gonadal hormone feedback on pituitary gonadotropin genes. Trends Endocrinol Metab 1996;7:272-276.

Speroff L, Fritz MA. Neuroendocrinology. In: Clinical Gynecologic Endocrinology and Infertility. Lippincott Williams and Wilkins, Philadelphia, PA, USA, 2005;145-185.

Tani H, Inaba T, Tamada H, Sawada T, Mori J, Torii R. Increasing gonadotropin-releasing hormone release by perifused hypothalamus from early to late anestrus in the beagle bitch. Neuroscience Letters 1996;207:1–4.

Van Haaften B, Bevers MM, Van den Brom WE, Okkens AC, Van Sluijs FJ, Willemse AH, Dieleman SJ. Increasing sensitivity of the pituitary to GnRH from early to late anoestrus in the beagle bitch. J Reprod Fertil 1994;101:221-225.

Wildt DE, Panko WB, Chakraborty PK, Seager SWJ. Relationship of serum estrone, estradiol-17β and progesterone to LH, sexual behavior and time of ovulation in the bitch. Biol Reprod 1979;20:648-658.

Chapter 5

The pituitary-ovarian axis in dogs with remnant ovarian tissue

JJCWM Buijtels[1], J de Gier[1], HS Kooistra[1], EC Naan[1], CHY Oei[2], AC Okkens[1]

Theriogenology 2011;75:742-751

[1] Department of Clinical Sciences of Companion Animals, Faculty of Veterinary Medicine, Utrecht University, The Netherlands
[2] Department of Farm Animal Health, Section of Reproduction, Faculty of Veterinary Medicine, Utrecht University, The Netherlands

Abstract

It can be difficult to confirm the presence of remnant ovarian tissue (ROT) in bitches that are presumed to be ovariohysterectomized. A GnRH stimulation test can be used to distinguish ovariectomized bitches from those in anestrus, but it is uncertain whether the GnRH-induced changes in plasma LH and estradiol concentrations that occur in intact bitches also occur in ROT-bitches. We report here eighteen ROT-bitches and compare the results of GnRH stimulation tests with those of six ovariectomized and six bitches in anestrus.

The basal (n=17) and/or GnRH-stimulated (n=18) plasma estradiol concentration was above the detection limit of the assay, i.e., <7 pmol/l, in all ROT-bitches but below the detection limit in all ovariectomized bitches. Basal plasma LH concentration was significantly higher in ROT-bitches (4.1 ± 0.7 μg/l) than those in anestrus (0.64 ± 0.04 μg/l), and significantly lower than in ovariectomized bitches (20.2 ± 3.6 μg/l). Basal plasma LH concentration was relatively high in bitches in which there was a long interval between ovariectomy and appearance of estrus. GnRH administration resulted in a significant increase in plasma LH and estradiol concentrations in ROT-bitches. The GnRH-induced increase and subsequent decline in plasma LH concentration were significantly less in ROT-bitches than in either ovariectomized bitches or those in anestrus. The GnRH-induced increase in plasma estradiol concentration was significantly smaller in ROT-bitches than in those in anestrus.

In conclusion, the results of this study demonstrate that in dogs ROT is associated with noticeable changes in the pituitary-ovarian axis and suggest that a GnRH stimulation test may be used to distinguish between completely ovariectomized bitches and those with ROT.

Introduction

Remnant ovarian tissue (ROT) is defined as that remaining in a presumably ovariectomized bitch. Ectopic ovarian tissue has not been reported to occur in dogs and accessory ovaries have only been reported in cows and humans (McEntee 1990). Consequently, ROT is the result of incomplete surgical removal (Wallace 1991). ROT is described in the literature as usually occurring on the right side, probably because the more cranial position of the right ovary hinders its surgical exposure and removal (Pearson 1972; Okkens et al. 1981; Marretta et al. 1989; Ball et al. 2010). Miller (1995) however, found ROT to be equally distributed between the right and left side.

Most dogs with ROT are presented with symptoms of vulvar swelling, vaginal discharge, and attractiveness to male dogs, at highly variable intervals after ovariectomy. These symptoms can be periodic or continuous. Recognizing bitches with ROT can be straightforward or very challenging, depending on the phase of the reproductive cycle. A clinical diagnosis of ROT during the follicular phase is straightforward, because the plasma concentration of estradiol, which is secreted by granulosa cells in developing ovarian follicles, is elevated. This leads to obvious changes that can be assessed by vaginoscopy and vaginal cytology (Schutte 1976; Olson et al. 1982; De Gier 2006; Schaefers-Okkens and Kooistra 2010). During the late follicular phase, ovulation, and the luteal phase, the plasma concentration of progesterone, secreted by partially luteinized granulosa cells before ovulation and by mature luteal cells after ovulation, is increased (Schaefers-Okkens and Kooistra 2010), providing evidence for ROT (Okkens et al. 1981). When there is no clinical or behavioral evidence of an increased plasma estradiol concentration, recognition of bitches with ROT is challenging. The production of estradiol and of progesterone decreases markedly after ovariectomy, but basal plasma concentrations of both hormones in anestrous and ovariectomized bitches overlap (Jeffcoate 1993; Buijtels et al. 2006; Frank et al. 2006). The concentrations of circulating gonadotropins are significantly higher in ovariectomized bitches than in bitches in anestrus, due to the loss of negative feedback of ovarian hormones after ovariectomy (Olson et al. 1992; Concannon 1993; Jeffcoate 1993; Löfstedt and Vanleeuwen 2002; Reichler 2004; Buijtels et al. 2006; Beijerink et al. 2007). Plasma gonadotropin concentrations may suggest the presence of ovarian tissue, but the pulsatile secretion of gonadotropins (Concannon 1993) can cause overlapping of their plasma concentrations between ovariectomized bitches and bitches in anestrus. Stimulation of the pituitary-ovarian axis with gonadotropin-releasing hormone (GnRH) may also help to distinguish between ovariectomized bitches and those in anestrus, because administering GnRH causes a significant rise in plasma estradiol concentration only if ovarian tissue is present

(Buijtels et al. 2006). It is, however, uncertain whether this response in plasma estradiol concentration is the same in intact bitches and those with ROT. Okkens et al. (1981) found that 12 of 47 bitches with ROT had macroscopic cysts in the ROT. Their effect on the results of the GnRH stimulation test is unknown and the successful use of this test in detecting bitches with ROT has not yet been reported.

Here we present our findings in eighteen bitches with ROT, including clinical signs, results of ultrasonography, laparotomy, and histological examination, basal plasma progesterone levels, and the plasma concentrations of luteinizing hormone (LH) and estradiol-17β before and after administration of GnRH. The results of the GnRH stimulation tests are compared with those in six ovariectomized bitches and six in anestrus.

Materials and Methods

Case selection

The bitches with ROT included in this study were referred to the Department of Clinical Sciences of Companion Animals, Utrecht University between 1997 and 2007 because of vaginal discharge and/or attractiveness to male dogs after ovariectomy. The plasma progesterone concentration obtained by the referring veterinarian was less than 6 nmol/l in all bitches with ROT. Only those in which a GnRH stimulation test was performed were included and those in which a tumor was found in the ROT were excluded. The diagnosis of ROT was based on the presence of estradiol-induced changes observed by vaginoscopy and vaginal cytology, an elevated (>6 nmol/l) plasma progesterone concentration at the time of referral, and/or histopathological examination of resected ovarian pedicles.

Among the 18 dogs which satisfied the inclusion and exclusion criteria, there were three golden retrievers, two Bernese mountain dogs, two Labrador retrievers, one Barsoi, one Rottweiler, one Bordeaux dog, and eight mixbreed dogs. Their ages ranged from one year and 9 months to 11 years and 9 months, with a median of 4 years and 7 months. The body weights ranged from 13 to 41 kg, with a median of 31 kg.

Control dogs

The twelve control bitches consisted of ten Beagles, one Border Collie, and one mixed breed dog, as previously described by Buijtels et al. (2006). Six of them, 3 to 7 years of age (median 5 years) and weighing 13.6 to 16.9 kg (median 14.3 kg) were sexually intact and in anestrus as confirmed by plasma progesterone concentrations below 3 nmol/l, 123 - 203 days after ovulation.

The other six, 5 to 12 years of age (median 11 years) and weighing 13.2 to 27.0 kg (median 16.8 kg), were ovariectomized at the Department of Clinical Sciences of Companion Animals at Utrecht University at least one year before the start of the study described by Buijtels et al. (2006) and there had been no subsequent signs of estrus as demonstrated by the absence of swelling of the vulva, vaginal discharge and attractiveness to male dogs.

GnRH-stimulation test, blood sampling, and hormone determination

Blood samples were collected at 40 min before and 0, 10, 60, and 120 min after the intravenous administration of 10 µg GnRH (Fertagyl®, Intervet, Boxmeer, The Netherlands) per kg body weight via the cephalic vein. Blood samples were collected from the jugular vein and centrifuged at 4 ºC for 10 min at 1500 *g*. Progesterone was analyzed in fresh plasma and the remaining plasma was stored at –25 ºC for other analyses.

Plasma LH concentration was measured in the samples collected at -40, 0, 10, and 60 min using a heterologous radioimmunoassay (RIA) as described previously (Nett et al. 1975) with the following modifications. A rabbit antiserum raised against ovine LH (CSU-204, kindly supplied by G.D. Niswender, Colorado State University, CO, USA), radioiodinated bLH-7981 as prepared for the bovine LH assay (Dieleman and Bevers 1987), and canine pituitary standard LER 1685-1 (a gift from Dr. L.E. Reichert, Albany Medical College, NY, USA) were used in this assay. The intra-assay and interassay coefficients of variation (CVs) for values above 0.5 µg/l were 2.3% and 10.5%, respectively. The lower limit of quantitation was 0.3 µg/l.

Plasma estradiol-17β concentration was measured in the samples collected at -40, 0, 60, and 120 min using a solid-phase RIA (Count-A-Count TKE; Diagnostic Products Corporation, Los Angeles, CA) according to the manufacturer's instructions with modifications as described previously (Dieleman and Bevers 1987) and validated for the dog (Van Haaften et al. 1994). The intra-assay and interassay CVs were 14% and 11.8%, respectively. The lower limit of quantitation was 7 pmol/l.

Plasma progesterone concentration was measured in the sample collected at -40 min by a previously validated I^{125}-RIA (Okkens et al. 2001). The intra-assay and interassay CVs were 6% and 10.8%, respectively. The lower limit of quantitation was 0.15 nmol/l.

Histopathology

The surgically removed ovarian tissue of the dogs with ROT was fixed in 10% neutral buffered formalin. Paraffin-embedded sections were cut at 4 µm, stained with haematoxylin and eosin (H&E), and examined with an Olympus light microscope.

Statistical analyses

Statistical analysis was performed using SPSS® for Windows, version 15.0.1. (SPSS Inc., Chicago, Il, USA). In some dogs the plasma estradiol concentration was below the detection limit of the assay. To enable statistical analysis, such samples were assigned the value of this lower limit. For each bitch the mean basal plasma hormone concentration was calculated from the two values before GnRH administration.

The increase in plasma LH concentration after administration of GnRH was calculated as the difference between the mean basal concentration and concentration at 10 min after GnRH administration. The decrease in plasma LH concentration was obtained by subtracting the value at 60 min after GnRH administration from that at 10 min. The increase in plasma estradiol concentration after GnRH administration was obtained by subtracting the mean basal concentration from the concentrations at 60 and 120 min.

Hormone concentrations in the different groups, with the exception of progesterone, were analyzed by the independent sample t-test. The effects of GnRH stimulation were analyzed using the paired sample t-test (with Bonferroni correction). Progesterone concentrations were not normally distributed and therefore the non-parametric Mann-Whitney test was used to compare values in different groups. Results are presented as mean and standard error of the mean and for the bitches with ROT the standard deviation is given. $P<0.05$ was considered significant.

Ethics of experimentation

This study was approved by the Ethical Committee of the Faculty of Veterinary Medicine, Utrecht University.

Results

The histories, results of gynecological examination, abdominal ultrasonography, and histopathological examination, and the appearance of the ovarian pedicles during laparotomy are presented in Table 1. The interval between ovariectomy and referral ranged from 2 months to 11 years. The interval between ovariectomy and the appearance of estrous was one week to 11 years. In seven dogs estrus was first observed more than one year after surgery and in four dogs the interval was more than three years. Vaginal discharge was observed in 16 of the 18 bitches and attractiveness to male dogs was reported by the owners of 12 of them.

Ultrasonography, laparotomy, and histopathological examination were performed in 10 of the dogs. Ultrasonography was falsely negative in two (number 3 and 5). In two dogs

(numbers 13 and 14) ultrasonography indicated unilateral ROT while histopathology revealed it to be bilateral. In dog 8, ultrasonography indicated bilateral ROT but histopathological examination revealed it to be unilateral.

Both laparotomy and histopathological examination were performed in 12 dogs, eight of which had macroscopic and/or microscopic cysts in the ROT. The surgeon's observations during laparotomy were not always confirmed by histopathological examination. The surgeon suspected bilateral ROT in dog 2, but it was only confirmed on the left side by histopathological examination. In dog 5 the surgeon judged that neither ovarian pedicle contained ROT but histopathological examination revealed it on the right side. The surgeon also noticed an abnormal structure in the omentum of one dog, which histopathological examination showed to be ROT containing a corpus luteum.

The results of the GnRH stimulation test are shown in Table 2. The mean basal plasma LH concentration was higher in the bitches with ROT (4.1 ± 0.7; S.D.: 3.2 μg/l) ($P<0.05$) than in the control bitches in anestrus (0.64 ± 0.04 μg/l) and lower ($P<0.001$) than in the ovariectomized control bitches (20.2 ± 3.6 μg/l) (Fig. 1). Basal plasma LH concentration was higher in bitches in which the interval between ovariectomy and the appearance of estrus was more than 3 years ($P<0.01$) than in those in which the interval was less than 3 years (Fig. 2).

Administration of GnRH resulted in an increase ($P<0.001$) in mean plasma LH concentration at both 10 min (19.6 ± 2.4; S.D.: 10.1 μg/l) and 60 min (12.3 ± 2.1; S.D.: 8.7 μg/l) in the dogs with ROT (Fig. 1). The increase in plasma LH concentration 10 min after GnRH administration was less ($P<0.001$) in the bitches with ROT (15.5 ± 1.9; S.D.: 8.3 μg/l) than in ovariectomized control bitches (43.6 ± 10.5 μg/l) or those in anestrus (57.3 ± 11.1 μg/l) (Fig. 1).

In most bitches with ROT, plasma LH concentration was lower at 60 min than at 10 min after GnRH administration, but in three of them (dogs 2, 9 and 16) it was higher at 60 min than that at 10 min. The decrease in mean plasma LH concentration from 10 min to 60 min after GnRH administration was less ($P<0.001$) in the bitches with ROT (7.3 ± 1.8; S.D.: 7.8 μg/l) than in ovariectomized bitches (35.4 ± 9.9 μg/l) or those in anestrus (53.0 ± 10.6 μg/l).

Table 1. *The signalement, history, gynecological and ultrasonographic findings, appearance of ovarian pedicles at laparotomy, and histopathological findings in 18 bitches with remnant ovarian tissue (ROT).*

Dog no.	Breed (BW in kg) Age	Time between - OVX and referral - OVX and first symptoms of estrus	Vaginoscopic and cytological findings	Ultrasonographic findings	Appearance of ovarian pedicles during laparotomy	Histopathological findings
1	Golden (35) 9 y + 6 m	9 y Not mentioned	Estradiol influence	Not performed	L: no abnormalities R: cystic ROT	R: partially cystic ROT with primary follicles
2	BM (27) 3 y	2 m 1 m	Estradiol influence	L: cystic structure	L: cystic ROT R: probably ROT	L: ROT with corpora lutea and follicles R: collagen-rich scar tissue
3	MB (16) 3 y + 3 m	1 y 3 m	Estradiol influence	No abnormalities	L: no abnormalities R: cystic ROT	R: luteinized follicular cyst
4	MB (21) 11 y + 9 m	11 y + 3 m 11 y	Estradiol influence	L: cystic structure	L: ROT with one cyst R: no abnormalities	L: ROT with CL-like aspect and luteinized small cyst
5	Barsoi (30) 5 y + 6 m	1 y + 4 m 1 y + 3 m	Anoestrus	No abnormalities	No abnormalities, but structure in omentum	L: no ROT R: ROT, Omentum: ovarian tissue with CL
6	MB (31) 6 y + 10 m	5 y + 10 m 5 y + 9 m	Estradiol influence	Not performed	Surgery by referring veterinarian	Not performed
7	BM (31) 3 y	6 m 6 m	Estradiol influence	L: suspected ROT R: ROT	Surgery by referring veterinarian	Not performed
8	BD (41) 3 y +8 m	1 y + 2 m 1 y + 1 m	Signs of inflammation	Left and R: ROT	L: scar tissue R: cystic ROT	L: adipose tissue R: cystic structure
9	MB (17) 10 y + 9 m	2 y + 9 m 6 m	Estradiol influence	L: no abnormalities R: ROT	Surgery by referring veterinarian	Not performed
10	MB (13) 9 y + 1 m	7 y 5 y	Estradiol influence	L: suspected ROT R: multiple cysts	L: small cyst in ROT R: large cystic mass	L: ROT R: many luteinized cysts
11	MB (35) 3 y + 5 m	2 y + 5 m 1 w	Estradiol influence	L: suspected ROT R: no abnormalities	Surgery by referring veterinarian	Not performed
12	Rottweiler (NR) 2 y + 8 m	1 y 3 m	Luteal phase	Not performed	Surgery by referring veterinarian	Not performed
13	MB (31) 10 y + 5 m	8 y 7 y + 11 m	Estradiol influence	L: cystic structure R: no abnormalities	L and R: ROT	L and R: ROT with cystic follicles and CL tissue
14	Labrador (39) 8 y	3 y + 4 m 1.5 y	Estradiol influence	L: no abnormalities R: small abnormal structure	Both sides abnormal structures visible	L: ROT with follicles and one cyst R: ROT with CL

15	Golden (33) 5 y + 7 m	2 y + 6 m Not recorded	Estradiol influence	L: not found R: cystic structures	L: no abnormalities R: cystic ROT	R: cystic ROT
16	Labrador (21) 2 y + 4 m	1 y + 4 m 2 m	Not recorded	L: no abnormalities R: suspected ROT	Surgery by referring veterinarian	Not performed
17	Golden (30) 3 y + 3 m	1 y + 2 m 4 m	Not recorded	L: no abnormalities R: suspected ROT	L: no abnormalities R: ROT with cyst	R: ROT with corpora lutea and follicles
18	MB (41) 1 y + 9 m	4 m 1 m	Anoestrus	Not performed	L: cystic ROT R: complete ovary present	L: cystic ROT R: complete ovary with CL

BW = Body Weight; kg = kilogram; BM = Bernese mountain dog; MB = Mixbreed; BD = Bordeaux dog, Golden = Golden retriever; Labrador = Labrador retriever. OVX = ovariectomy; y = year; m = month; w = week; ROT = remnant ovarian tissue; L = Left; R = Right; CL = corpus luteum; NR = not recorded

Table 2. *Plasma concentrations of LH, estradiol, and progesterone in 18 bitches with remnant ovarian tissue (ROT) before and after intravenous administration of 10 µg GnRH (Fertagyl®) per kg body weight.*

Dog no.	Mean basal LH (µg/l)	LH 10 min after GnRH (µg/l)	LH 60 min after GnRH (µg/l)	Mean basal estradiol (pmol/l)	Estradiol 60 min after GnRH (pmol/l)	Estradiol 120 min after GnRH (pmol/l)	Basal progesterone (nmol/l)
1	1.4	13.6	7.3	22.1	31.2	36.0	2.1
2	5.5	7.8	9.0	85.9	72.9	60.4	2.5
3	4.3	12.9	5.7	45.7	47.0	48.8	2.4
4	11.5	34.9	16.1	37.3	31.5	38.9	2.9
5	3.8	19.5	9.5	30.0	32.7	31.9	3.2
6	9.5	34.0	29.3	47.5	57.4	43.3	1.6
7	0.96	21.8	13.4	17.9	23.1	23.8	2.5
8	0.78	1.6	1.4	24.4	32.7	30.5	1.9
9	1.7	25.7	26.4	51.6	50.5	49.6	2.5
10	7.8	40.7	22.9	48.7	52.9	45.7	1.6
11	5.9	19.9	14.8	35.4	36.7	37.8	1.3
12	3.4	19.7	7.6	17.2	39.7	35.2	6.5
13	6.9	23.9	5.4	39.0	38.6	49.2	7.0
14	2.2	18.9	12.1	25.7	32.2	27.8	8.4
15	1.5	8.2	4.5	34.5	44.1	41.1	6.0
16	0.79	16.3	26.7	<7	<7	15.9	1.0
17	3.6	23.0	5.1	41.1	47.5	47.1	81.9
18	2.6	10.1	3.7	48.3	57.5	55.7	54.1

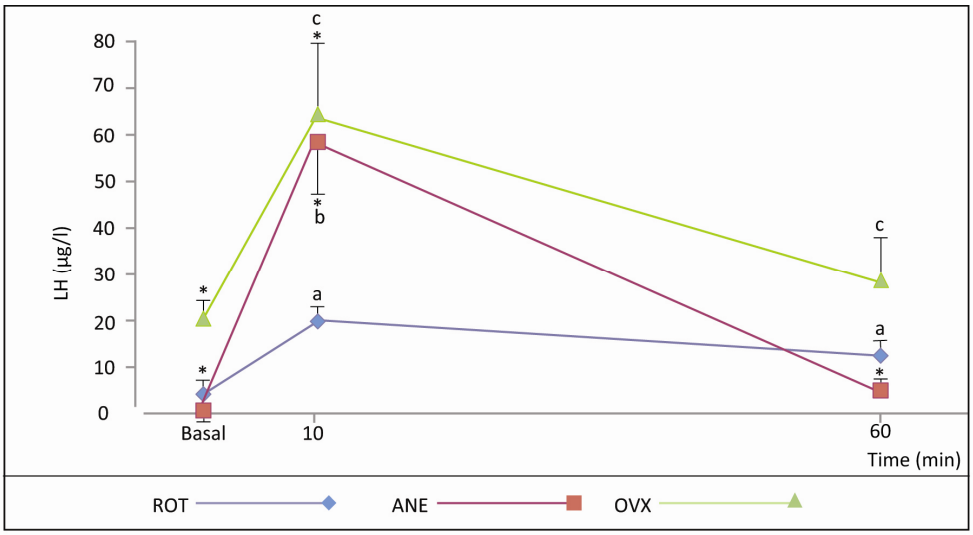

Figure 1. *Mean plasma LH concentration after intravenous administration of 10 µg GnRH (Fertagyl®) per kg body weight in 18 bitches with remnant ovarian tissue (ROT), six ovariectomized bitches (OVX) and six bitches in anestrus (ANE).*
a, b, and c indicate significant differences between the plasma LH concentration and the mean basal plasma LH concentration.
** indicates a significant difference in the plasma LH concentration between bitches with ROT and those in anestrus or ovariectomized. Significant differences between ovariectomized bitches and those in anestrus and are not indicated and have been described previously by Buijtels et al. (2006).*

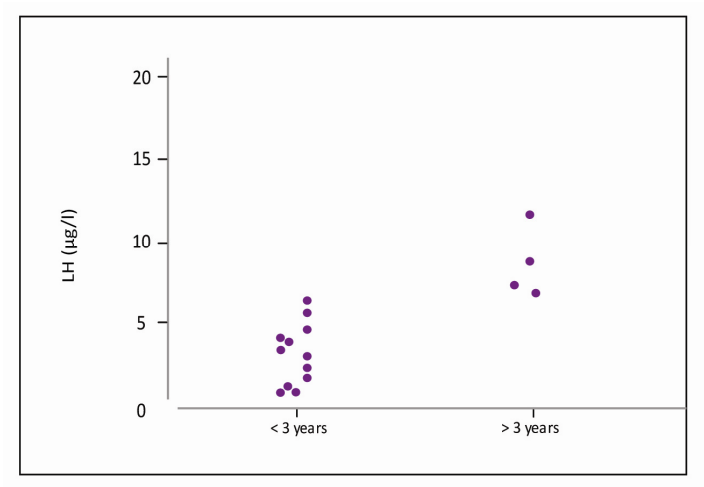

Figure 2. *Mean basal plasma LH concentration in bitches with remnant ovarian tissue (ROT) in which the interval between ovariectomy and the appearance of estrus was less than or greater than three years.*

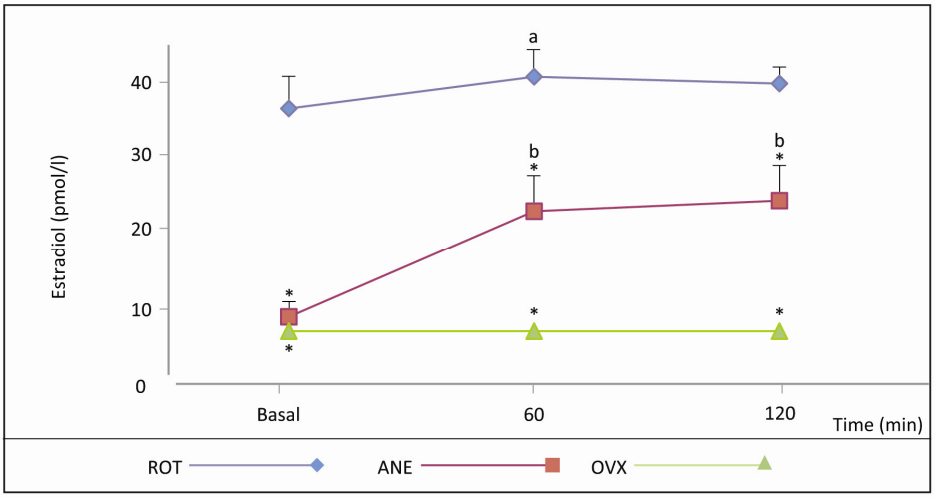

Figure 3. *Mean plasma estradiol concentration after intravenous administration of 10 µg GnRH (Fertagyl®) per kg body weight in 18 bitches with remnant ovarian tissue (ROT), 6 ovariectomized bitches (OVX), and 6 in anestrus (ANE).*
a and b indicate plasma estradiol concentration significantly higher than the mean basal concentration in bitches with ROT.
** indicates a significant difference in plasma estradiol concentration between bitches with ROT and ovariectomized bitches or bitches in anestrus. Significant differences between ovariectomized bitches and those in anestrus are not indicated and have been described previously by Buijtels et al. (2006).*

Basal and/or GnRH-stimulated plasma estradiol concentration was above the detection limit of the assay in ROT bitches with the exception of dog 16, but below the detection limit in all ovariectomized bitches. The mean basal plasma estradiol concentration (Fig. 3) was higher ($P<0.001$) in bitches with ROT (36.6 ± 4.1; S.D.: 17.7 pmol/l) than in ovariectomized bitches (< 7.0 pmol/l) or those in anestrus (8.9 ± 1.3 pmol/l). Administration of GnRH resulted in an increase ($P<0.05$) in mean plasma estradiol concentration at 60 min in bitches with ROT (40.8 ± 3.5; S.D.: 14.9 pmol/l) (Fig. 3); in four bitches no increase was seen. The increase in the plasma estradiol concentration at 60 and 120 min after GnRH administration was less ($P<0.05$ and $P<0.01$, respectively) in the bitches with ROT (4.2 ± 1.8; S.D.: 7.5 pmol/l and 3.4 ± 2.1; S.D.: 9.1 pmol/l, respectively) than in bitches in anestrus (14.0 ± 3.7 pmol/l and 15.5 ± 2.9 pmol/l, respectively).

Discussion

Neither Wallace (1991) nor Miller (1995) found a correlation between the occurrence of ROT and the age at ovariectomy, breed, or physical condition of the bitch. The eighteen dogs described in the present study were all relatively large, with a median body weight of 31 kg. This may indicate that a higher body weight is associated with a higher risk of ROT, which was also suggested by Okkens et al. (1981), who reported that 42 of 55 bitches with gynecological complications after ovario(hyster)ectomy had a body weight exceeding 20 kg.

Due to the retrospective nature of the study there were some differences between the groups of bitches in terms of breed, age and body weight. However, it is not likely that these differences influenced the results.

All dogs described in the present study had at least one of the clinical symptoms typical of ROT, either periodically or continuously. Sixteen of the 18 dogs had vaginal discharge, which was hemorrhagic in nine, indicating the presence of endometrial tissue (Okkens et al. 1981). Although there were obvious symptoms of ROT in some of the dogs, all were referral cases in which the referring veterinarian had difficulty in diagnosing ROT. The results of abdominal ultrasonography were in agreement with those of histopathological examination in only five of ten dogs. Similarly, Ball et al. (2010) reported that ROT was correctly diagnosed in only 9 of 12 cases, whereas in women ROT has been correctly diagnosed by ultrasonography in almost 93% of cases (Petit and Lee 1988; Magtibay and Magrina 2006). However, those results in women were obtained after provocative testing with chlomiphene citrate, which causes cystic structures on the ovarian remnant. Without this provocation it is also difficult to image ROT in women (Petit and Lee 1988). In addition, ultrasonography of the abdomen of these dogs was sometimes difficult because the majority were relatively large and no anesthesia was used during the examination.

This study also revealed that it is not always easy to diagnose ROT correctly during laparotomy, for observations during laparotomy were not in agreement with histopathological findings in two of twelve cases. It would therefore seem advisable to remove both ovarian pedicles, including granulation tissue, in case of any doubt about the presence of ovarian tissue during surgery.

In one dog in this study, the surgeon noticed an abnormal structure in the omentum which histopathological examination showed to be an ovarian remnant with a corpus luteum. The most probable explanation is that a fragment of ovarian tissue was freed in the abdomen during ovariectomy and regained functionality after revascularization.

Revascularization of a piece of ovarian tissue was previously reported in the cat (DeNardo et al. 2001). Moreover, Le Roux and Venderwalt (1977) found that minced ovarian tissue placed in subserosal pouches on the stomach or under the splenic capsule after ovariectomy in the bitch led to cyclic signs of pro-estrus and estrus.

In eight of twelve dogs with ROT in which histopathological examination was performed, there were cystic structures on the ovarian remnant. In a previous study such cystic structures were found in 12 of 47 bitches with ROT (Okkens et al. 2001).

Basal plasma LH concentration was significantly lower in bitches with ROT than in ovariectomized bitches and significantly higher than in bitches in anestrus, but in both cases the values overlapped those in bitches with ROT. The higher plasma LH concentration in bitches with ROT than in bitches in anestrus may indicate lower sensitivity to the negative feedback of ovarian hormones, due to changes in the hypothalamic-pituitary axis induced by partial removal of the ovaries and disruption of the blood supply of the remnants. This could reduce ovarian activity for a long time. Pituitary cells can adapt to functional demands for chronic hypersecretion of a specific trophic hormone by multiplication of the corresponding hormone-producing cells. The adenohypophyseal changes associated with insufficient secretion of a peripheral hormone have best been studied in experimental and clinical hypothyroidism. In primary hypothyroidism, multiplication of thyrotrophs provides more cells producing thyroid-stimulating hormone (TSH) (Vidal et al. 2000), which can even result in pituitary enlargement (Sarlis et al. 1997; Joshi and Woolf 2005; Diaz-Espineira et al. 2008). This leads to increased pituitary secretion of TSH, a glycoprotein with many similarities to the gonadotropins. In dogs with primary hypothyroidism, one of the attendant pituitary changes is loss of negative feedback response to thyroid hormones, resulting in a decrease in plasma TSH concentration with time (Diaz-Espineira et al. 2008). Similar changes may have occurred in some of the bitches with ROT, i.e., loss of most of the functional ovarian tissue would have resulted in a dramatic decrease in ovarian hormone feedback to the hypothalamic-pituitary axis, leading to multiplication of gonadotrophs. These may have lost some of the characteristics of normal gonadotrophs, such as sensitivity to negative feedback of ovarian hormones. When the ROT began to produce increased amounts of ovarian hormones, these might not suppress LH secretion to levels normally observed in bitches in anestrus. As a consequence, basal plasma LH concentration was significantly higher, despite high circulating estradiol and/or progesterone concentrations. This hypothesis is supported by the finding that basal plasma LH concentration was higher in bitches in which estrus appeared more than 3 years after ovariectomy.

An elevated basal LH concentration in combination with a high circulating estradiol and/or progesterone concentration was found in bitches that developed a granulosa cell

tumor in ROT (Buijtels et al. 2010). Ball et al. (2010) also found four granulosa cell tumors in 19 dogs referred for ROT and in those animals there were significantly longer intervals between ovariectomy and the diagnosis of ROT. In women, circulating gonadotropin levels in ROT can be similar to postmenopausal levels (Petit and Lee 1988).

Basal plasma LH concentration was significantly increased at both 10 and 60 minutes after administration of GnRH in bitches with ROT, as it is in intact healthy bitches (Van Haaften et al. 1994; Okkens et al. 2001; Buijtels et al. 2006; Beijerink et al. 2007), but the increase at 10 minutes was significantly lower than in healthy bitches in anestrus. This indicates that GnRH stimulation of LH secretion has been affected, possibly by the multiplication or alteration of gonadotrophs, which may have lost some characteristics during the period when ROT was not secreting excessive amounts of ovarian hormones. A similar subnormal LH response to GnRH has been described in bitches with ROT and a granulosa cell tumor (Buijtels et al. 2010). The response to GnRH may simply be delayed, so that the maximum LH concentration occurs later than 10 minutes after GnRH administration. That the decrease in plasma LH concentration was relatively limited from 10 to 60 minutes after GnRH administration supports this theory.

Basal plasma estradiol concentration was higher in bitches with ROT than in bitches in anestrus. It was also elevated in the bitches in which progesterone was clearly elevated (dogs 12, 13, 14, 15, 17 and 18), as occurs in bitches in the luteal phase or pregnancy (Onclin et al. 2002).

The basal plasma estradiol concentration was detectable in 17 of 18 bitches with ROT, whereas it was not in any of the six ovariectomized bitches. In all bitches with ROT plasma estradiol concentration was detectable at 120 minutes after stimulation with GnRH, whereas it was not in any of the six ovariectomized bitches. Axnér et al. (2008) used the measurement of circulating estradiol concentration after stimulation by GnRH to detect the presence of ovarian tissue in cats. There was no overlap in estradiol values between anestrous and ovariectomized queens and a significant stimulation by GnRH was only observed if ovarian tissue was present. Scott et al. (1995) performed a GnRH stimulation test in women with ROT and found that an increase in circulating estradiol concentration confirmed the presence of functional ovarian tissue. Our findings suggest that the plasma estradiol response to GnRH stimulation can be used to detect bitches with ROT, although additional studies are required to determine the specificity and the sensitivity of the GnRH stimulation test for this purpose.

The increase in plasma estradiol concentration at 60 and 120 minutes after GnRH administration was significantly lower in bitches with ROT than in those in anestrus. Additionally, in four bitches there was a decrease of the plasma estradiol concentration 60 min after injection of GnRH. This could be related to the cystic changes in the ROT found

in eight of the bitches and/or abnormal vascularization, but it could also conceivably be a physiological response in the follicular phase, about which we have no data. The plasma progesterone concentrations in the bitches with ROT differed considerably. The plasma progesterone concentrations in bitches 17 and 18 were high, compatible with levels found during the luteal phase (Concannon et al. 1977; Wildt et al. 1979; Okkens et al. 1985a). The bitches with a progesterone concentration below 3 nmol/l were clearly in anestrus (Okkens et al. 1985b), but the bitches with slightly elevated plasma progesterone concentrations could be in the early follicular phase or at the end of the luteal phase (De Gier et al. 2006; Schaefers-Okkens and Kooistra 2010).

In conclusion, the results of this study demonstrate that 1) bitches with ROT have significantly higher basal plasma LH concentrations than do bitches in anestrus, 2) among bitches with ROT, basal plasma LH concentration is higher in those in which the interval between ovariectomy and the appearance of estrus was more than 3 years, 3) the LH response to GnRH stimulation is lower in bitches with ROT than in ovariectomized bitches or those in anestrus, and 4) the basal and/or GnRH-stimulated plasma estradiol concentration in bitches with ROT is above the detection limit of the estradiol assay.

Acknowledgements

The authors thank Mrs. D.M. Blankenstein for technical assistance and Dr. B.E. Belshaw for editing.

References

Axnér E, Gustavsson T, Ström Holst B. Estradiol measurement after GnRH-stimulation as a method to diagnose presence of ovaries in the female domestic cat. Theriogenology 2008;70:186-191.

Ball RL, Birchard SJ, May LR, Threlfall WR, Young GS. Ovarian remnant syndrome in dogs and cats: 21 cases (2000-2007). J Am Vet Med Assoc 2010;236:548-553.

Beijerink NJ, Buijtels JJCWM, Okkens AC, Kooistra AC, Dieleman SJ. Basal and GnRH-induced secretion of FSH and LH in anestrous versus ovariectomized bitches. Theriogenology 2007;67:1039-1045.

Buijtels JJCWM, Beijerink NJ, Kooistra HS, Dieleman SJ, Okkens AC. Effects of gonadotropin releasing hormone administration on the pituitary-ovarian axis in anestrous versus ovariectomized bitches. Reprod Domest Anim 2006;41:555-561.

Buijtels JJCWM, De Gier J, Kooistra HS, Veldhuis-Kroeze EJ, Okkens AC. Alterations of the pituitary-ovarian axis in dogs with a functional granulosa cell tumor. Theriogenology 2010;73:11-19.

Concannon PW, Hansel W, McKentee K. Changes in LH, progesterone and sexual behavior associated with preovulatory luteinization in the bitch. Biol Reprod 1977;17:604-613.

Concannon PW. Biology of gonadotropin secretion in adult and prepubertal female dogs. J Reprod Fertil Suppl 1993;47:3-27.

De Gier J, Djajadiningrat-Laanen SC, Kooistra HS, Dieleman SJ, Okkens AC. Temporal relationships between plasma concentrations of LH, FSH, estradiol, progesterone, prolactin, and alpha-melanocyte stimulating hormone during the follicular, ovulatory and early luteal phase in the bitch Theriogenology 2006;65:1346-1359.

DeNardo GA, Becker K, Brown NO, Dobbins S. Ovarian remnant syndrome: Revascularization of free-floating ovarian tissue in the feline abdominal cavity. J Am Anim Hosp Assoc 2001;37:290-296.

Diaz-Espineira MM, Mol JA, van den Ingh TSGAM, van der Vlught-Meijer RH, Rijnberk A, Kooistra HS. Functional and morphological changes in the adenohypophysis of dogs with induced hypothyroidism: Loss of TSH hypersecretion, hypersomatotropism, hypoprolactinemia, and pituitary enlargement with transdifferentiation. Domest Anim Endocrinol 2008;35:98-111.

Dieleman SJ, Bevers MM. Effects of monoclonal antibody against PMSG administered shortly after the preovulatory LH surge on time and number of ovulations in PMSG/PG-treated cows. J Reprod Fertil 1987;81:533-542.

Frank LA, Rohrbach BW, Bailey EM, West JR, Oliver JW. Steroid hormone concentration profiles in healthy intact and neutered dogs before and after cosyntropin administration. Domest Anim Endocrinol 2006;24:43-57.

Jeffcoate IA. Gonadotrophin-releasing hormone challenge to test for the presence of ovaries in the bitch. J Reprod Fertil Suppl 1993;47:536-538.

Joshi AS, Woolf PD. Pituitary hyperplasia secondary to primary hypothyroidism: a case report and a review of the literature. Pituitary 2005;8:99-103.

Van Haaften B, Bevers MM, van den Brom WE, Okkens AC, van Sluijs FJ, Willemse AH, Dieleman SJ. Increasing sensitivity of the pituitary to GnRH from early to late anestrus in the beagle bitch. J Reprod Fertil 1994;101:221-225.

LeRoux PH, Venderwalt LA. Ovarian autografts as an alternative to ovariectomy in bitches. J S Afr Vet Assoc 1977;48:117-123.

Löfstedt RM, Vanleeuwen JA. Evaluation of a commercially available luteinizing hormone test for its ability to distinguish between ovariectomized and sexually intact bitches. J Am Vet Med Assoc 2002;220:1331-1335.

Magtibay PM, Magrina JF. Ovarian remnant syndrome. Clin Obstet Gynecol 2006;49:526-534.

Marretta SM, Matthiesen DT, Nichols R. Pyometra and its complications. Probl Vet Med 1989;1:50-62.

McEntee K. The ovary. In: Reproductive Pathology of Domestic Animals, McEntee K (Ed). Academic Press Inc, San Diego, 1990, pp. 31-51.

Meij BP, Mol JA, Hazewinkel HAW, Bevers MM, Rijnberk A. Assessment of a combined anterior pituitary function test in beagle dogs: rapid sequential intravenous administration of four hypothalamic releasing hormones. Domest Anim Endocrinol 1996;13:161-170.

Miller DM. Ovarian remnant syndrome in dogs and cats: 46 cases (1988-1992). J Vet Diagn Invest 1995;7:572-574.

Nett TM, Akbar AM, Phemister RD, Holst PA, Reichert LE Jr, Niswender GD. Levels of luteinizing hormone, estradiol and progesterone in serum during the estrous cycle and pregnancy in the beagle bitch. Proc Soc Exp Biol Med 1975;148:134-139.

Okkens AC, Dieleman SJ, vd Gaag I. Gynaecological complications following ovariohysterectomy in dogs, due to (1) Partial removal of the ovaries (2) Inflammation of the uterocervical stump. Tijdschr Diergeneeskd 1981;106:1142-1158.

Okkens AC, Bevers MM, Dieleman SJ, Willemse AH. Shortening of the interestrous interval and lifespan of the corpus luteum of the cyclic dog by bromocriptine treatment. Vet Quart 1985a;7:173-176.
Okkens AC, Dieleman SJ, Bevers MM, Willemse AH. Evidence for the non-involvement of the uterus in the lifespan of the corpus luteum in the cyclic dog. Vet Quart 1985b;7:169-173.
Okkens AC, Teunissen JM, Van Osch W, Van Den Brom WE, Dieleman SJ, Kooistra HS. Influence of litter size and breed on the duration of gestation in dogs. J Reprod Fertil Suppl 2001;57:193–197.
Olson PN, Bowen RA, Behrendt M, Olson JD, Nett TM. Concentrations of reproductive hormones in canine serum throughout late anestrus, prestrus and estrus. Biol Reprod 1982;27:1196-1206.
Olson PN, Mulnix JA, Nett TM. Concentrations of luteinizing hormone and follicle-stimulating hormone in the serum of sexually intact and neutered dogs. Am J Vet Res 1992;53:762-766.
Onclin K, Murphy B, Verstegen JP. Comparisons of estradiol, LH and FSH patterns in pregnant and nonpregnant beagle bitches. Theriogenology 2002;57:1957-1972.
Pearson H. The complications of ovariohysterectomy in the bitch. J Small Anim Pract 1972;14:257-266.
Petit PDM, Lee RA. Ovarian remnant syndrome. Diagnostic dilemma and surgical challenge. Obstet Gynecol 1988;71:580-583.
Reichler IM, Pfeiffer E, Piché CA, Jöchle W, Roos M, Hubler M, Arnold S. Changes in plasma gonadotropin concentrations and urethral closure pressure in the bitch during the 12 months following ovariectomy. Theriogenology 2004;62:1391-1402.
Sarlis NJ, Brucker-Davis F, Doppman JL, Skarulis MC. MRI-demonstrable regression of a pituitary mass in a case of primary hypothyroidism after a week of acute thyroid hormone therapy. J Clin Endocrinol Metab 1997;82:808-811.
Scott RT, Beatse SN, Illions EH, Snyder RR. Use of the GnRH agonist stimulation test in the diagnosis of ovarian remnant syndrome. A report of three cases. J Reprod Med 1995;40:143-146.
Schaefers-Okkens AC, Kooistra HS. Ovaries. In: Clinical Endocrinology of Dogs and Cats, Rijnberk A and Kooistra HS (Eds). Schlütersche, Hannover, 2010, pp. 203-234.
Schutte AP. Canine vaginal Cytology II. Cyclic changes. J Small Anim Pract 1976;8:307-311.
Vidal S, Horvath E, Kovacs K, Cohen SM, Lloyd RV, Scheithauer BW. Transdifferentation of somatotrophs to thyrotrophs in the pituitary of patients with protracted primary hypothyroidism. Virchows Arch 2000;436:43-51.
Wallace MS. The ovarian remnant syndrome in the bitch and queen. Vet Clin North Am Small Anim Pract 1991;21:501-507.
Wildt DE, Panko WB, Chakraborty PK, Seager SWJ. Relationship of serum estrone, estradiol-17β and progesterone to LH, sexual behavior and time of ovulation in the bitch. Biol Reprod 1979;20:648-658.

Chapter 6

Alterations of the pituitary-ovarian axis in dogs with a functional granulosa cell tumor

JJCWM Buijtels[1], J de Gier[1], HS Kooistra[1],
EJB Veldhuis Kroeze[2], AC Okkens[1]

Theriogenology 2010;73:11-19

[1] Department of Clinical Sciences of Companion Animals, Faculty of Veterinary Medicine, Utrecht University, Utrecht, The Netherlands
[2] Department of Pathobiology, Faculty of Veterinary Medicine, Utrecht University, Utrecht, The Netherlands

Abstract

Information on the pituitary-ovarian axis in dogs with a granulosa cell tumor (GCT) is lacking. Therefore, we investigated the plasma concentrations of LH and estradiol before and after GnRH administration in seven bitches with a functional GCT (GCT-total), of which three were intact (GCT-intact) and four had remnant ovarian tissue (GCT-ROT). The results of the GnRH stimulation test were compared with those in six anestrous and six ovariectomized bitches.

The most noteworthy results were as follows. The basal plasma LH concentrations of the GCT-ROT bitches were higher ($P<0.05$) than those of the anestrous bitches. The increment in the plasma LH concentration after GnRH administration of the GCT-total bitches was lower ($P<0.001$) than the increments in both the anestrous and ovariectomized bitches. The basal plasma estradiol concentrations in the GCT-total bitches were higher ($P<0.001$) than those in the anestrous and ovariectomized bitches.

In conclusion, the pituitary-ovarian axis is affected in bitches with a functional GCT which is characterized by relatively high plasma LH concentrations in GCT-ROT bitches and a subnormal LH response in all GCT bitches to GnRH stimulation compared with anestrous and ovariectomized bitches. The relatively high proportion of dogs with remnant ovarian tissue among the GCT bitches suggests a pathogenetic role for elevated gonadotropin secretion in the pathogenesis of GCT.

Introduction

Ovarian tumors are rare in mammals, but among domestic animals they appear to be most common in the bitch and cow (Cotchin and Marchant 1977). In dogs with neoplasia diagnosed at necropsy the reported incidence of canine ovarian tumors, which can be primary or secondary, has ranged from 0.5 to 6 per cent (Dow 1960; Hayes and Harvey 1979; Jergens and Shaw 1987; Madewell and Theilen 1987). Primary ovarian neoplasms can be categorized into three different groups: epithelial tumors, germ cell tumors, and sex cord-stromal tumors.

The histogenetic origin of the epithelial ovarian tumors is believed to be the ovarian surface epithelium, a single layer of flat-to-cuboidal epithelial cells covering the ovary (Auersperg et al. 2001). Epithelial tumors are the most frequently diagnosed canine ovarian neoplasms at necropsy (Patnaik and Greenlee 1987), adenocarcinomas being more common than adenomas (Dow 1970; Greene et al. 1979; Jergens and Shaw 1987; Madewell and Theilen 1987; Patnaik and Greenlee 1987; Goodwin et al. 1990; Rocken 1991; Booth 1994; Nagarajan et al. 1994). Ovarian germ cell tumors develop from primitive germ cells of the embryonic gonad. The incidence at necropsy of canine ovarian germ cell tumors is quite low, and in this category only dysgerminomas and teratomas have been reported in dogs (Patnaik and Greenlee 1987).

Sex cord-stromal tumors arise from various cell types in gonadal stroma and sex cords. The incidence at necropsy of canine sex cord-stromal tumors lies between those of the epithelial tumors and the germ cell tumors (Patnaik and Greenlee 1987). Three different types are distinguished, with the granulosa cell tumor (GCT) occurring more frequently than theca cell tumors and luteomas (Jergens and Shaw 1987).

Granulosa cell tumors appear to arise from granulosa cell cords derived from atretic follicles (McEntee 1990). Canine GCTs are not locally invasive (Dow 1960), but in 10 to 20 per cent of cases they metastasize (Madewell and Theilen 1987). Most GCTs are unilateral, although bilateral masses have been described (Madewell and Theilen 1987). The occurrence of cysts in the contralateral ovary has been reported (McEntee 2002). There are also two case reports describing GCT in three previously ovariohysterectomized dogs (Pluhar et al. 1995; Sivacolundhu et al. 2001). Granulosa cell tumors are capable of producing estrogens and small amounts of progesterone (Feldman and Nelson 1987; Schaefers-Okkens 1996; Davidson and Feldmann 2005). In most cases of GCT, the clinical signs are referable to increased estrogen and progesterone synthesis and to a lesser extent to the mass effect of the tumor. The latter may cause abdominal distension and sometimes ascites. Persistent estrus behavior with serosanguineous vulvar discharge and vulvar swelling are frequently noticed in bitches with GCT (Hayes and Harvey 1979;

McCandlish et al. 1979; Feldman and Nelson 1987; Jergens and Shaw 1987; Madewell and Theilen 1987; Malm et al. 1994; Pluhar et al. 1995). The progesterone secreted by the GCT enhances endometrial growth and glandular secretion, which can lead to the cystic endometrial hyperplasia-pyometra complex (Feldman and Nelson 1987). It has been demonstrated in humans that GCTs express gonadotropin receptors (Stouffer et al. 1984) and respond to gonadotropins (Graves et al. 1985). In this regard, it has been speculated that gonadotropins may be involved in the pathogenesis of GCT. Information on the pituitary-ovarian axis in dogs with GCT is lacking.

We report here seven bitches with a functional GCT, with the clinical signs, ultrasonographic findings in the abdomen, histopathology findings, basal plasma progesterone concentration, and plasma concentrations of luteinizing hormone (LH) and estradiol before and after administration of gonadotropin-releasing hormone (GnRH). The results of the GnRH stimulation test are compared with the results of a GnRH stimulation test in six anestrous and six ovariectomized bitches.

Materials and Methods

Case selection

All bitches referred to the Department of Clinical Sciences of Companion Animals, Utrecht University between 1994 and 2007 because of vulvar discharge, in which histopathological examination of resected ovarian tissue confirmed GCT and in which a GnRH stimulation test was performed, were included in the study.

Control dogs

Twelve control bitches, consisting of ten Beagles, one Border Collie, and one mongrel dog, were previously described by Buijtels et al. (2006). Six of them, 3 to 7 years of age and weighing 13.6 to 16.9 kg, were sexually intact. The other six, 5 to 12 years of age and weighing 13.2 to 27.0 kg, were ovariectomized bitches.

GnRH stimulation test, blood sampling, and hormone determinations

Blood samples were collected at 40 min before and 0, 10, 60, 90, and 120 min after the intravenous administration of 10 μg GnRH (Fertagyl®, Intervet, Boxmeer, The Netherlands) per kg body weight via the cephalic vein. Blood samples were collected from the jugular vein and centrifuged at 4 ºC for 10 min at 1500 *g*. Plasma samples for progesterone determination were analyzed the same day and the remaining plasma was stored at –25 ºC until analysis.

Plasma LH concentration was measured in the samples at -40, 0, 10, and 60 min using a heterologous radioimmunoassay (RIA) as previously described (Nett et al. 1975). A rabbit antiserum raised against ovine LH (CSU-204, kindly supplied by G.D. Niswender, Colorado State University, CO, USA), radioiodinated bLH-7981 as prepared for the bovine LH assay (Dieleman and Bevers 1987), and canine pituitary standard LER 1685-1 (a gift from Dr. L.E. Reichert, Albany Medical College, NY, USA) were used in this assay. The intra-assay and interassay coefficients of variation for values above 0.5 µg/l were 2.3% and 10.5%, respectively. The lower limit of quantitation was 0.3 µg/l.

Plasma estradiol-17β concentration was measured in the samples at -40, 0, 60, and 120 min using a solid-phase RIA (Count-A-Count TKE; Diagnostic Products Corporation, Los Angeles, CA) according to the manufacturer's instructions with modifications as described previously (Dieleman and Bevers 1987) and validated for the dog (Van Haaften et al. 1994). The intra-assay and interassay coefficients of variation were 14% and 11.8%, respectively. The lower limit of quantitation was 7 pmol/l.

Plasma progesterone concentration was measured in the sample at -40 min by a previously validated RIA (Okkens et al. 2001) The intra-assay and interassay coefficients of variation were 6% and 10.8%, respectively. The lower limit of quantitation was 0.15 nmol/l.

Histopathology

The surgically removed ovarian tissue was fixed in 10% neutral buffered formalin. Paraffin-embedded sections were cut at 4 µm, stained with haematoxylin and eosin (H&E), and examined with an Olympus light microscope. Macroscopically the tumors were all located unilaterally at the location of the ovary or at the remnant ovarian pedicle, since four out of seven bitches had ROT. The irregular nodular masses ranged in diameter from approximately 3 to 12 centimetres. On cut surface pale multinodular to multicystic aspects with or without haemorrhages were seen. Histological evaluation revealed that all tumors described here were composed of aggregations of neoplastic granulosa cells embedded within a supporting variable dense fibrous stroma. The various common growth patterns or combinations of these patterns encountered were: diffuse, macrofollicular, microfollicular, trabecular and tubular. The polygonal to spindle shaped or prismatic tumor cells with distinct cell borders contained spherical to oval hyperchromatic nuclei with distinct nucleoli and scant eosinophilic cytoplasm. Generally tumor cells were well differentiated without cellular atypia. In one tubular type granulosa cell tumor and in one diffuse type tumor focal areas of luteinisation of neoplastic granulosa cells were present (Figure 1). Mitotic figures were only sporadically present. These findings are consistent with the diagnoses of ovarian gonadostromal granulosa cell tumors.

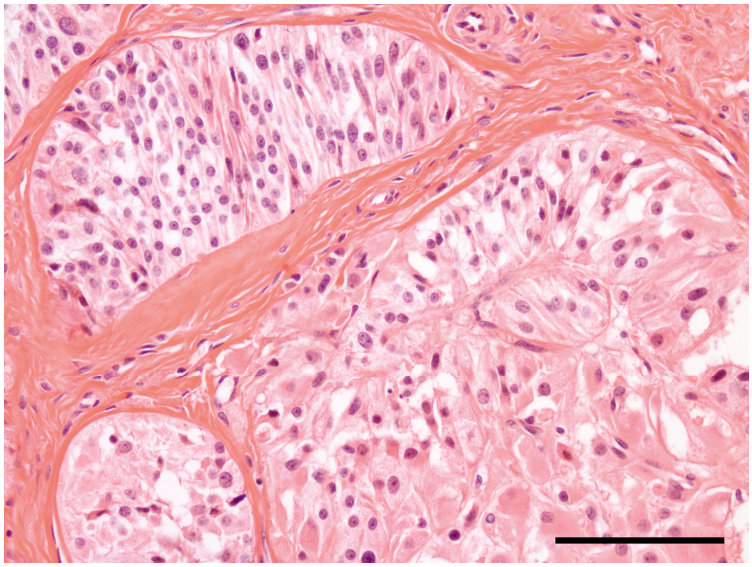

Figure 1. *High magnification photomicrograph of a canine ovarian granulosa cell tumor displaying a tubular growth pattern in which variably sized tubules are separated by a dense fibrovascular stroma. On top left tumor cells are elongated to high prismatic which mimic a Sertoli cell tumor appearance. This particular tumor showed luteinisation of tumor cells; a transition to large polygonal cells with abundant eosinophilic cytoplasm can be seen on the bottom right of the picture. Bar = 100 µm. Haematoxylin & eosin stain.*

Data analysis

In one dog (dog 3), the measured plasma LH concentration was < 2.0 µg/l and for statistical analysis this was set at 2.0 µg/l. Similarly, when the plasma estradiol concentration was below the limit of quantitation, the respective lower limit value was assigned to the sample**.**

For each bitch the mean basal plasma hormone concentration was calculated from the two values before GnRH administration. The (maximal) increment was calculated by subtracting the mean basal hormone value from the LH value at 10 min after GnRH administration and from the estradiol value at 60 min after GnRH administration.

The values in the different groups were analyzed using the non-parametric Mann-Whitney test (with Bonferroni correction). The effects of GnRH stimulation were analyzed using the non-parametric Friedman test with the Tukey test as post-hoc test. $P<0.05$ was considered significant. Results are presented as median and range.

Results

Seven bitches met the inclusion criteria (GCT-total). Three of these were intact females (GCT-intact), and the other four had remnant ovarian tissue (GCT-ROT). The time between ovario(hyster)ectomy and referral of the GCT-ROT bitches ranged between 2 and 10.5 years. The bitches were referred because of persistent vaginal discharge (n=7) and attraction of male dogs (n=5). The duration of vaginal discharge ranged from 7 weeks to 7 months. Of the four dogs with a GCT in remnant ovarian tissue, one dog (dog 7) had a history of intermittent attractiveness to males at intervals of several months for more than 10 years. None of the dogs had clinical signs related to organs other than the genital tract. Data regarding the gynecological examination, abdominal ultrasonography, appearance of the ovaries during laparotomy, and histopathological examination of the ovarian tissue of the individual bitches are given in Table 1.

The basal plasma LH concentrations of the GCT-total bitches (1.9 µg/l; range, 0.42-9.2 µg/l) tended to be higher (P=0.051) than those of the anestrous bitches and were lower (P=0.002) than those of the ovariectomized bitches (Tables 2 and 3). The median basal plasma LH concentration was lower in the GCT-intact bitches than in the GCT-ROT bitches, but this difference was not significant (P=0.23). Basal plasma LH concentrations measured in the GCT-intact bitches did not differ significantly from those in the anestrous bitches, whereas the basal plasma LH concentrations were higher (P<0.05) in the GCT-ROT bitches than in the anestrous bitches. The basal plasma LH concentrations were lower (P<0.05) in both the GCT-intact and GCT-ROT bitches than in the ovariectomized bitches (Table 3).

Taken as one group, the GCT-total bitches showed an increase (P=0.01) of the plasma LH concentrations at 10 min (3.2 µg/l; range, 0.64-16.8 µg/l) and at 60 min (4.1 µg/l; range, 0.94-16.0 µg/l) after GnRH administration compared with the basal plasma LH concentration. In the GCT-intact bitches the increase in the plasma LH concentrations after GnRH administration (Table 3) was not significant (P=0.14). In contrast, in the GCT-ROT bitches GnRH administration resulted in an increase (P=0.04) of the plasma LH concentration at 10 min (Table 3). Plasma LH concentrations at 10 and 60 min after GnRH administration in the GCT-ROT bitches were much higher than those in the GCT-intact bitches, but probably due to the low number of cases in each group this was not significant (P=0.06).

Table 1. *Data from the signalement, history, gynecological examination, abdominal ultrasonography, and appearance of the ovaries during laparotomy and histopathological examination in seven bitches with a functional granulosa cell tumor.*

Parameter	Dog 1	Dog 2	Dog 3	Dog 4	Dog 5	Dog 6	Dog 7
Breed	Bullmastiff	Boxer	Belgian Shepherd	Newfound-lander	Bouvier des Flandres	German Shepherd	Airdale Terrier
Age (years)	5	8	9	4	9	5	12
Body weight (kg)	50	30	32	50	45	33	20
Gynaecological status	Intact	Intact	Intact	OVX	OVHX	OVX	OVHX
Time between OV(H)X-referral				2 years	7 years and 8 months	3 years and 4 months	10 years and 6 months
Vaginal discharge	Yellow	Red	White	Red	Green-yellow	Red	White
Duration of discharge	7 weeks	2 months	Unknown	7 months	7 months	4 months	Unknown
Attractiveness to male dogs	Yes	No	Yes	No	Yes	No	Yes (intermittent)
Vaginoscopic appearance	Anestrus	Estradiol influence	Unknown	Estradiol influence	Estradiol influence	Estradiol influence	Estradiol influence
Ultrasonographic findings in abdomen	Mass right ovary	Mass left ovary	Mass right ovary	Cysts-containing remnant ovarian tissue on both sides	Cysts-containing remnant ovarian tissue on right side	Cysts-containing remnant ovarian tissue on left side	Cysts-containing remnant ovarian tissue on right side
Appearance of ovaries during laparotomy	Right: Mass Left: Small	Right: No abnormalities Left: Mass	Right: Mass Left: Small	Right and Left: Cystic ovarian remnant tissue	Right and Left: Cystic ovarian remnant tissue	Right: No ovarian tissue Left: Cystic ovarian remnant tissue	Right: Cystic ovarian remnant tissue Left: No abnormalities
Histopathological examination of ovaries	Right: GCT Left: Left in situ	Right: No histopathology Left: GCT	Right: GCT Left: Atrophic ovary	One side GCT (which side not known)	Right: GCT Left: Cystic ovarian remnant tissue	Left: GCT	Right: GCT

OVX = Ovariectomy, OVHX = Ovariohysterectomy, GCT = Granulosa cell tumor.

Table 2. *Plasma concentrations of LH, estradiol-17β and progesterone in three intact bitches with a granulosa cell tumor and in four bitches with remnant ovarian tissue with a granulosa cell tumor, before and after intravenous administration of 10 µg per kg body weight of GnRH (Fertagyl®).*

	Granulosa cell tumor in intact bitches			Granulosa cell tumor in remnant ovarian tissue			
	Dog 1	Dog 2	Dog 3	Dog 4	Dog 5	Dog 6	Dog 7
Mean basal LH (µg/l)	0.43	1.3	< 2.0	8.1	3.7	2.3	0.80
LH 10 min after GnRH(µg/l)	0.64	1.4	< 2.0	16.8	8.4	16.1	3.2
LH 60 min after GnRH (µg/l)	0.94	1.9	< 2.0	14.1	4.7	16	4.1
Mean basal estradiol (pmol/l)	25.3	197	328	25.4	36.7	32.1	85.9
Estradiol 60 min after GnRH (pmol/l)	40.3	365	635	33.5	40.4	38.5	96.2
Estradiol 120 min after GnRH (pmol/l)	43.0	504	554	32.0	38.9	38.2	101
Basal progesterone (nmol/l)	5.4	5.4	13.6	0.64	8.2	3.5	0.95

The mean basal plasma hormone concentration was calculated from the two values before GnRH administration.

Table 3. *Median and range of plasma concentrations of LH, estradiol-17β and progesterone in three intact bitches with a granulosa cell tumor (GCT-intact), in four bitches with remnant ovarian tissue with a granulosa cell tumor (GCT-ROT), in six anestrous bitches, and in six ovariectomized bitches, before and after intravenous administration of 10 µg per kg body weight of GnRH (Fertagyl®).*

	GCT-Intact bitches		GCT-ROT bitches		Anestrous bitches		Ovariectomized bitches	
	Median	Range	Median	Range	Median	Range	Median	Range
Basal LH (µg/l)	1.3	0.42 - 2.0	3.0	0.80 - 9.2	0.62	0.48 – 0.93	13.4	6.2 – 41.0
LH 10 min after GnRH(µg/l)	1.4	0.64 - 2.0	12.3	3.2 - 16.8	60.5	25.4 – 101	46.9	30.3 – 113
LH 60 min after GnRH (µg/l)	1.9	0.94 - 2.0	9.4	4.1 - 16.0	5.1	2.8 – 6.2	23.0	10.9 -68.9
Basal estradiol (pmol/l)	196.7	24.3 - 327.1	33.9	24.4 - 94.0	<7	< 7 – 14.1	<7	< 7
Estradiol 60 min after GnRH (pmol/l)	365.0	40.3 – 635.0	39.5	33.5 - 96.2	20.6	14.1 – 35.7	<7	< 7
Estradiol 120 min after GnRH (pmol/l)	504.3	43.0 – 554.0	38.6	32.0 - 101	28.4	12.3 – 32.4	<7	< 7
Basal progesterone (nmol/l)	5.4	5.4 - 13.6	2.2	0.64 - 8.2	1.3	0.95 - 1.9	0.63	<0.15- 2.2

The increment in plasma LH concentration from basal to 10 min after GnRH administration was lower (P<0.001) in the GCT-total bitches (2.4 µg/l; range, 0-13.8 µg/l) than in both the anestrous bitches (59.7 µg/l; range, 24.9-100.1 µg/l) and the ovariectomized bitches (34.4 µg/l; range, 17.1-80.9 µg/l). The median increment in plasma LH concentration from basal to 10 min after GnRH administration in both the GCT-intact and GCT-ROT bitches was lower (P<0.05) than in the anestrous and ovariectomized bitches. The increment in plasma LH concentration from basal to 10 min after GnRH administration was much lower in the GCT-intact bitches (0.17 µg/l; range: 0-0.21 µg/l) than that in the GCT-ROT bitches (6.8 µg/l; range, 2.4-13.8 µg/l), but this difference was not significant (P=0.06).

Basal plasma estradiol concentrations were higher (P<0.001) in the GCT-total bitches (39.0 pmol/l; range, 24.3-327.1 pmol/l) as well as in the GCT-intact bitches and the GCT-ROT bitches (P<0.05 and P<0.01, respectively) compared with the anestrous and the ovariectomized bitches (Table 3).

Taken as one group, the bitches with a GCT (GCT-total) had an increase (P=0.005) in plasma estradiol concentration at 60 min (40.4 pmol/l; range, 33.5-635 pmol/l) and at 120 min (43.0 pmol/l; range, 32.0-554 pmol/l) after GnRH administration compared with basal plasma estradiol concentration. In the GCT-intact bitches the increase in plasma estradiol concentration after GnRH administration compared with the basal value (Table 3) was not significant (P=0.10). In contrast, in the GCT-ROT bitches GnRH administration resulted in an increase (P=0.04) in plasma estradiol concentration at 60 min (Table 3). Plasma estradiol concentrations at 60 and 120 min after GnRH administration in the GCT-intact bitches were much higher than those in the GCT-ROT bitches, but this difference was not significant (P=0.06).

The increment in plasma estradiol concentration from basal to 60 min after GnRH administration was higher (P<0.001) in the GCT-total bitches (10.3 pmol/l; range 3.7-306 pmol/l) than that in the ovariectomized bitches (<7 pmol/l; range, <7 pmol/l), but did not differ (P=0.95) from that in the anestrous bitches (11.3 pmol/l; range, 5.5-28.7 pmol/l). The increment in plasma estradiol concentration from basal to 60 min after GnRH administration was much higher in the GCT-intact bitches (168 pmol/l; range, 15.0-306 pmol/l) than that in the GCT-ROT bitches (7.3 pmol/l; range, 3.7-10.3 pmol/l), but this difference was not significant (P=0.06). The median increment in plasma estradiol concentration from basal to 60 min after GnRH administration in both the GCT-intact and GCT-ROT bitches was higher (P<0.05) than that in the ovariectomized bitches, but did not differ significantly from that in the anestrous bitches.

Basal plasma progesterone concentration was higher ($P<0.05$) in the GCT-total bitches (5.4 nmol/l; range, 0.64-13.6 nmol/l) than in the ovariectomized bitches, but did not differ significantly ($P=0.18$) from that in the anestrous bitches (Table 3). Basal plasma progesterone concentration was lower in the GCT-ROT bitches than in the GCT-intact bitches, but this difference was not significant ($P=0.23$). Basal plasma progesterone concentration in the GCT-intact bitches was higher than in the anestrous bitches ($P=0.02$) and the ovariectomized bitches ($P=0.02$). Basal plasma progesterone concentration in the GCT-ROT bitches did not differ significantly from that in the anestrous bitches ($P=0.91$) and the ovariectomized bitches ($P=0.17$).

Discussion

Granulosa cell tumors occur most frequently in middle-aged to older dogs (Cotchin and Marchant 1977; Herron 1983; Patnaik and Greenlee 1987; Klein 2001), compatible to the age range of the seven bitches in the present study. These were large dogs of seven different breeds, referred because of persistent vaginal discharge (n=7) and attraction of male dogs (n=5). Consistent with these signs of persistent estrus, basal plasma estradiol concentrations in both the GCT-intact bitches and the GCT-ROT bitches were significantly higher than those of the anestrous bitches.

LH secretion increases after ovariectomy, due to the loss of negative feedback by the ovarian hormones, but remains pulsatile (Concannon 1993). It was thus not surprising that plasma LH concentrations in the ovariectomized bitches were significantly higher than those of the anestrous bitches and the bitches with GCT. Unexpectedly, however, plasma LH concentrations in the bitches with GCT tended to be higher than those in the anestrous bitches. This tendency for the entire group was mainly due to the significantly higher plasma LH concentrations in the GCT-ROT bitches. The relatively high plasma LH concentrations in the GCT-ROT bitches are remarkable, because the plasma estradiol concentrations were significantly higher in these bitches than in the anestrous bitches. Due to the negative feedback of estradiol on the hypothalamic-pituitary axis a lower plasma LH concentration could be expected in the GCT-ROT bitches. The relatively high plasma LH concentrations in the GCT-ROT bitches may indicate loss of sensitivity to the negative feedback of estradiol due to changes in the hypothalamic-pituitary axis induced by the partial removal of the ovaries and the disruption of the vascularization of the remnant ovarian tissue. This could lead to prolonged reduction in ovarian activity. Pituitary cells can adapt to functional demands for chronic hypersecretion of a specific tropic hormone by multiplication of the corresponding pituitary tropic hormone producing cells, as well as

by transdifferentiation. Transdifferentiation is the adjustment of the morphologic features and the secretory capacity of mature pituitary cell types without cell division (Vidal et al. 2001; Radian et al. 2003). The adenohypophyseal changes associated with insufficient secretion of a peripheral hormone have been studied best in experimental and clinical hypothyroidism. In primary hypothyroidism, both multiplication of thyrotropes (hyperplasia) and transdifferentiation contribute to the increased number of thyroid-stimulating hormone (TSH)-producing cells (Vidal et al. 2000), which can even lead to pituitary enlargement (Sarlis et al. 1997; Joshi and Woolf 2005; Diaz-Espineira et al. 2008). These pituitary changes may lead to alterations in pituitary secretion of TSH, a glycoprotein with many similarities to the gonadotropins. In dogs with primary hypothyroidism one of these pituitary changes is loss of negative feedback to thyroid hormones, resulting in a decrease in plasma TSH concentration with time (Diaz-Espineira et al. 2008). Similar changes may have occurred in the GCT-ROT bitches, i.e., removal of most of the ovarian tissue and disrupted vascularization of ROT resulted in a dramatic decrease in ovarian hormone feedback at the hypothalamus-pituitary axis, which subsequently caused multiplication of gonadotropes and transdifferentiation. These gonadotropes may have lost some of the characteristics of normal gonadotropes, e.g., the sensitivity to feedback of ovarian hormones. At the time the remnant ovarian tissue started to produce significant amounts of ovarian hormones, the elevated circulating ovarian hormone levels were no longer able to suppress LH secretion to plasma values known to occur in anestrous bitches. As a consequence, plasma LH concentration is relatively high despite high circulating estradiol concentrations.

Another explanation of the increased LH concentration in the bitches with a GCT is that there is a positive feedback of estradiol-17β on the release of the LH, comparable to LH release in the bitch during the late-follicular phase (De Gier et al. 2006). De Gier et al. (2006) found that the pre-ovulatory LH surge coincided with or started 4 to 16 h after the highest plasma estradiol-17β concentration. From these observations it was hypothesized that the elevation or high plasma estradiol-17β concentration via positive feedback on GnRH-release led to increased LH secretion, i.e., was the causative factor of the pre-ovulatory LH surge. Also in several other mammals increasing plasma estradiol concentrations have a positive feedback effect on LH release during the late-follicular phase (Liu and Yen 1983; Karsch et al. 1997; Evans et al. 1997). However, Concannon and coworkers (Concannon 1993; Concannon et al. 1979) have shown that administration of different amounts of estradiol-17β to ovariectomized beagle bitches induced an LH peak only after the discontinuation of estradiol treatment, suggesting that estradiol-17β exerts a negative feedback effect on LH release in the dog. Furthermore, it has been shown that administration of increasing doses of estradiol benzoate did not trigger an LH surge in

bitches during anestrus. It may therefore be concluded that the time window for estrogens to act via a positive feedback effect on LH secretion is small. It is therefore questionable whether higher basal plasma estradiol-17β concentrations are the explanation for the high LH concentrations in the GCT bitches,

As has been reported in intact healthy bitches (Chaffaux et al. 1981; Van Haaften et al. 1994; Meij et al. 1996; Buijtels et al. 2006; Beijerink et al. 2007), the plasma LH concentration could be stimulated by GnRH in all bitches with a GCT. For dog 3 an elevation in the plasma LH concentration could not be demonstrated, but the GnRH-induced rise in plasma estradiol concentration indicates increased exposure of the ovarian tissue to gonadotropins in this dog. The rise in plasma LH concentration following GnRH administration to the GCT-total bitches was less than that in both the anestrous bitches and the ovariectomized bitches, indicating less sensitivity of the pituitary gonadotropes to GnRH in the bitches with a GCT. The LH response was especially limited in the GCT-intact bitches, which may be ascribed to the strong negative feedback at the pituitary level exerted by the relatively high plasma estradiol concentrations in this group. In addition, the lower sensitivity of the gonadotropes to GnRH may be ascribed to the pituitary changes discussed above.

In four of the seven bitches with GCT, the tumor developed in remnant ovarian tissue from 2 to 10.5 years after ovari(ohyster)ectomy. Pluhar et al. (1995) and Sivacolundhu et al. (2001) also described three bitches with ROT which developed GCT. The time between neutering and referral was also long in these three bitches. Three of our four GCT-ROT bitches did not show estrus symptoms for several years, indicating low plasma estradiol concentration and consequently elevated plasma gonadotropin concentration. It may be hypothesized that the elevated plasma gonadotropin concentration plays a role in tumor genesis. In women, exposure to high gonadotropin levels, such as after menopause or due to infertility treatments, is proposed to be a risk factor for developing ovarian tumors (Konishi et al. 1999; Unkila-Kallio et al. 2000; Ness et al. 2002). Also, patients with polycystic ovary syndrome, which is associated with hypersecretion of LH, have an increased risk of developing ovarian cancer (Schildkraut et al. 1996). Moreover, circumstances that reduce circulating gonadotropin levels, such as oral contraceptives (Bosetti et al. 2002), breast feeding, and estrogen replacement therapy (La Vecchia 2001), reduce the risk of developing ovarian cancer. In rodents GCTs can be induced by exogenous gonadotropins (Tennent et al. 1990). Furthermore, development of GCT has been reported in transgenic mice with chronic LH hypersecretion (Risma et al. 1995; Keri et al. 2000). The long exposure of (remnant) ovarian tissue to high circulating gonadotropin levels may therefore explain why these dogs are more prone to develop an ovarian tumor than intact dogs.

It has been demonstrated in women that GCTs express functional gonadotropin receptors (Stouffer et al. 1984; Graves et al. 1985). In the present study, GnRH stimulation resulted in an increase in the plasma estradiol concentration in all bitches with GCT, suggesting that also canine GCT tissue expresses functional gonadotropin receptors. Consistent with our observations, Pluhar et al. (1995) also described a GCT-ROT bitch in which the elevated plasma estradiol concentration could be stimulated by human chorionic gonadotropin (hCG). The increment in the plasma estradiol concentration after GnRH administration in the GCT bitches did not differ significantly from that in the anestrous bitches, whereas the increment in plasma LH concentration after GnRH administration to the GCT bitches was significantly lower than in the anestrous bitches. This observation suggests increased sensitivity of the ovarian tumor tissue for gonadotropin stimulation. However, in the present study plasma FSH concentration was not determined and it cannot be excluded that changes in FSH secretion do not parallel LH secretion.

In two GCT-ROT bitches the contralateral ovary contained cysts. Functional ovarian neoplasia and cystic ovaries can occur simultaneously in the dog (McEntee 2002). Cysts are also regularly observed in bitches with remnant ovarian tissue without GCT (Okkens et al. 1981).

In five of the bitches with GCT the plasma progesterone concentration was higher than the upper limit of the range in anestrous bitches and ovariectomized bitches. The elevated plasma progesterone concentration may be due to the fact that partial luteinization is often present in granulosa cells during estrogen influence (Schaefers-Okkens 1996).

In conclusion, the pituitary-ovarian axis is affected in bitches with GCT characterized by relatively high plasma LH concentrations in GCT-ROT bitches and a subnormal LH response in all GCT bitches to GnRH stimulation compared to the anestrous and ovariectomized bitches. The relatively high proportion of dogs with remnant ovarian tissue among the GCT bitches may point to a pathogenetic role for elevated gonadotropin secretion in the pathogenesis of GCT.

Acknowledgment

The authors would like to acknowledge Mrs. D.M. Blankenstein and Ms. C.H.Y Oei of the Biochemical Laboratory for performing the hormone measurements. The critical reading of the manuscript by Dr. B.E. Belshaw is highly appreciated.

References

Auersperg N, Wong AS, Choi KC, Kang SK, Leung PC. Ovarian surface epithelium: biology, endocrinology and pathology. Endocr Rev 2001;22:255-288.

Beijerink NJ, Buijtels JJCWM, Okkens AC, Kooistra HS, Dieleman SJ. Basal and GnRH-induced secretion of FSH and LH in anoestrous versus ovariectomized bitches. Theriogenology 2007;67:1039-1045.

Booth JM. Canine transmissible venereal tumor and ovarian papillary cystadenocarcinoma in a bitch. J Small Anim Pract 1994;35:39-42.

Bosetti C, Negri E, Trichopoulos D, Franceschi S, Beral V, Tzonou A, Parazzini F, Greggi S, La Vecchia C. Long-term effects of oral contraceptives on ovarian cancer risk. Int J Cancer 2002;102:262-265.

Buijtels JJCWM, Beijerink NJ, Kooistra HS, Dieleman SJ, Okkens AC. Effects of gonadotrophin releasing hormone administration on the pituitary-ovarian axis in anoestrous versus ovariectomized bitches. Reprod Dom Anim 2006;41:555-561.

Chaffaux S, Chassagnite F, Thibier M. Concentration of LH après stimulation par la gonadoliberine (LRH) chez la chienne et effet de l'ovariectomie. Rec Med Vet 1981;10:725-733.

Concannon PW, Cowan R, Hansel W. LH release in ovariectomized dogs in response to estrogen withdrawal and its facilitation by progesterone. Biol Reprod 1979;20:523-531.

Concannon PW. Biology of gonadotropin secretion in adult and prepubertal female dogs. J Reprod Fertil Suppl 1993;47:3-27.

Cotchin E, Marchant J. Animal tumors of the female reproductive tract. Spontaneous and experimental. In: Pathology of the female genital tract, Blaustein A (Ed). Springer-Verlag, New York, 1977, pp. 55-56.

Davidson AP, Feldman EC. Ovarian and estrous cycle abnormalities. In: Textbook of Veterinary Internal Medicine, Ettinger SJ, Feldman EC (Eds). Elsevier Saunders, Philadelphia, 2005, pp. 1649-1655.

De Gier J, Kooistra HS, Djajadiningrat-Laanen SC, Dieleman SJ, Okkens AC. Temporal relations between plasma concentrations of luteinizing hormone, follicle-stimulating hormone, estradiol-17β, progesterone, prolactin, and α-melanocyte-stimulating hormone during the follicular, ovulatory, and early luteal phase in the bitch. Theriogenology 2006;65:1346-1359.

Diaz-Espineira MM, Mol JA, van den Ingh TSGAM, van der Vlught-Meijer RH, Rijnberk A, Kooistra HS. Functional and morphological changes in the adenohypophysis of dogs with induced hypothyroidism: Loss of TSH hypersecretion, hypersomatotropism, hypoprolactinemia, and pituitary enlargement with transdifferentation. Domest Anim Endocrinol 2008;35:98-111.

Dieleman SJ, Bevers MM. Effects of monoclonal antibody against PMSG administered shortly after the preovulatory LH surge on time and number of ovulations in PMSG/PG-treated cows. J Reprod Fertil 1987;81:533-542.

Dow C. Ovarian abnormalities in the bitch. J Comp Pathol 1960;70:59-69.

Evans NP, Dahl GE Padmanabhan V, Thrun LA. Estradiol requirements for induction and maintenance of the gonadotropin-releasing hormone surge: implications for neuroendocrine processing of the estradiol signal. Endocrinology 1997;138:5408-5414.

Feldman EC, Nelson RW. Canine female reproduction. In: Canine and feline Endocrinology and Reproduction, Feldman EC, Nelson RW (Eds). WB Saunders, Philadelphia, 1987, pp. 399-480.

Goodwin JK, Hagar D, Philips L, Lyman R. Bilateral ovarian adenocarcinoma in a dog: Ultrasonographic-aided diagnosis. Vet Radiol 1990;31:265-267.

Graves PE, Surwit EA, Davis JR, Stouffer RL. Adenylate cyclase in human ovarian cancers: sensitivity to gonadotropins and nonhormonal activators. Am J Obstet Gynecol 1985;153:877-882.

Greene JA, Richardson RC, Thornhill JA, Boon GD. Ovarian papillary cystadenocarcinoma in a bitch: Case report and literature review. J Am Anim Hosp Assoc 1979;15:351-356.

Herron MA. Tumors of the canine genital system. J Am Anim Hosp Assoc 1983;19:981-994.

Hayes A, Harvey HJ. Treatment of metastatic granulosa cell tumor in a dog. J Am Vet Med Assoc 1979;174:1304-1306.

Joshi AS, Woolf PD. Pituitary hyperplasia secondary to primary hypothyroidism: a case report and a review of the literature. Pituitary 2005;8:99-103.

Jergens AE, Shaw DP. Tumors of the canine ovary. Compend Contin Educ Pract Vet 1987;9:489-495.

Karsch FJ, Bowen JM, Caraty A, Evans NP, Moenter M. Gonadotropin-releasing hormone requirements for ovulation. Biol Reprod 1997;56:303-309.

Keri RA, Lozada KL, Abdul-Karim FW, Nadeau JH, Nilson JH. Luteinizing hormone induction of ovarian tumors: oligogenic differences between mouse strains dictates tumor disposition. Proc Natl Acad Sci USA 2000;97:383-387.

Klein MK. Tumours of the female reproductive system. In: Small Animal Clinical Oncology, Withrow SJ, MacEwen EG (Eds). WB Saunders, Philadelphia, 2001, pp. 445-454.

Konishi I, Kuroda H, Mandai M. Review: gonadotropins and development of ovarian cancer. Oncology 1999;57:45-48.

La Vecchia C. Epidemiology of ovarian cancer: a summary review. Euro J Canc Prev 2001;10:125-129.

Liu JH, Yen SSC. Induction of midcycle gonadotropin surge by ovarian steroids in women: a critical evaluation. J Clin Endocrinol Metab 1983;57:797-802.

Meij BP, Mol JA, Hazewinkel HAW, Bevers MM, Rijnberk A. Assessment of a combined anterior pituitary function test in beagle dogs: rapid sequential intravenous administration of four hypothalamic releasing hormones. Domest Anim Endocrinol 1996;13:161-170.

Madewell BR, Theilen GH. Tumours of the urogenital tract. In: Veterinary Cancer Medicine, Theilen GH, Madewell BR (Eds). Lea & Febiger, Philadelphia, 1987, pp. 567-600.

Malm C, Ferreira HI, Nascimento EF. Clinical and histopathological survey of ovarian and uterine disorders in ovariohysterectomized bitches. I. Granulosa cell tumors. Arq Bras Med Vet Zootec 1994;46:13-18.

McCandlish IAP, Munro CD, Breeze RG, Nash AS. Hormone producing ovarian tumors in the dog. Vet Rec 1979;105:9-11.

McEntee K. Ovarian Neoplasms. In: Reproductive Pathology of Domestic Mammals, McEntee K (Ed). Academic Press, California, 1990, pp. 69-93.

McEntee MC. Reproductive oncology. Clin Tech in Small Anim Prac 2002;17:133-149.

Nagarajan L, Ramani C, Ramanujam K. Ovarian serous cystadenocarcinoma in a bitch. Indian J Vet Surg 1994;15:45.

Ness RB, Cramer DW, Goodman MT, Kjaer SK, Mallin K, Mosgaard BJ, Purdie DM, Risch HA, Vergona R, Wu AH. Infertility, fertility drugs, and ovarian cancer: a pooled analysis of case-control studies. Am J Epidemiol 2002;155:217-224.

Nett TM, Akbar AM, Phemister RD, Holst PA, Reichert LE Jr, Niswender GD. Levels of luteinizing hormone, estradiol and progesterone in serum during the estrous cycle and pregnancy in the beagle bitch. Proc Soc Exp Biol Med 1975;148;134-139.

Okkens AC, Dieleman SJ, vd Gaag I. Ovario-hysterectomie bij de hond. Gynaecologische complicaties na ovario-hysterectomie bij de hond ten gevolge van: 1. Het incompleet verwijderen van de ovaria; 2. Een ontsteking van de uterus-cervixstomp (in Dutch, with English abstract). Tijdschr Diergeneesk 1981;22:1142-1158.

Okkens AC, Teunissen JM, Van Osch W, Van Den Brom WE, Dieleman SJ, Kooistra HS: Influence of litter size and breed on the duration of gestation in dogs. J Reprod Fertil Suppl 2001;57:193–197.

Patnaik AK, Greenlee PG. Canine ovarian neoplasms: A clinicopathologic study of 71 cases, including histology of 12 granulosa cell tumours. Vet Pathol 1987;24:509-514.

Pluhar GE, Memon MA, Wheaton LG. Granulosa cell tumors in an ovariohysterectomized dog. J Am Vet Med Assoc 1995;207:1063-1065.

Radian S, Coculescu M, Morris JF. Somatotrophic to thyrotroph cell transdifferentation during experimental hypothyroidism-a light and electron-microscopy study. J Cell Mol Med 2003;7:297-306.

Risma KA, Clay CM, Nett TM, Wagner T, Yun J, Nislon JH. Targeted overexpression of luteinizing hormone in transgenic mice leads to infertility, polycystic ovaries, and ovarian tumours. Proc Natl Acad Sci USA 1995;92:1322-1326.

Rocken H. A cystadenofibroma (Brenner's tumor?) of a dog (abstract). Prakt Tierarzt 1991;72:33.

Schildkraut JM, Schwingl PJ, Bastos E, Evanoff A, Hughes C. Epithelial ovarian cancer risk among women with polycystic ovary syndrome. Obstet Gynecol 1996;88:554-559.

Sarlis NJ, Bruckner-Davis F, Doppman JL, Skarulis MC. MRI-demonstrable regression of a pituitary mass in a case of primary hypothyroidism after a week of acute thyroid hormone therapy. J Clin Endocrinol Metab 1997;82:808-811.

Schaefers-Okkens AC. Ovaries. In: Clinical Endocrinology of Dogs and Cats, Rijnberk A (Ed). Kluwer Academic Publishers, Dordrecht, The Netherlands, 1996, pp.1131-1156.

Stouffer RL, Grodin MS, Davis JR, Surwit EA. Investigation of binding sites for follicle-stimulating hormone and chorionic gonadotropin in human ovarian cancers. J Clin Endocrinol Metab 1984;59:441-446.

Sivacolundhu RK, O'Hara AJ, Read RA. Granulosa cell tumor in two spayed bitches. Aust Vet J 2001;79:173-176.

Tennent BJ, Shultz KL, Sundberg JP, Beamer WG. Ovarian granulosa cell tumorigenesis in SWR-derived F1 hybrid mice: preneoplastic follicular abnormality and malignant disease progression. Am J Obstet Gynecol 1990;163:625-634.

Unkila-Kallio L, Tiitinen A, Wahlström T, Lehtovirta P, Leminen A. Reproductive features in women developing ovarian granulosa cell tumour at a fertile age. Hum Reprod 2000;15:589-593.

Van Haaften B, Bevers MM, van den Brom WE, Okkens AC, van Sluijs FJ, Willemse AH, Dieleman SJ. Increasing sensitivity of the pituitary to GnRH from early to late anoestrus in the beagle bitch. J Reprod Fertil 1994;101:221-225.

Vidal S, Horvath E, Kovacs K, Cohen SM, Lloyd RV, Scheithauer BW. Transdifferentation of somatotrophs to thyrotrophs in the pituitary of patients with protracted primary hypothyroidism. Virchows Arch 2000;436:43-51.

Vidal S, Horvath E, Kovacs K, Lloyd RV, Smyth HS. Reversible transdifferentation: interconversion of somatotrophs and lactotrophs in pituitary hyperplasia. Mod Pathol 2001;14:20-28.

Chapter 7

Dogs with a disorder of sexual development and associated changes in the pituitary-gonadal axis

JJCWM Buijtels[1], J de Gier[1], HS Kooistra[1], GCM Grinwis[2], EC Naan[1], C Zijlstra[3], AC Okkens[1]

Theriogenology; Submitted

[1] Department of Clinical Sciences of Companion Animals, Faculty of Veterinary Medicine, Utrecht University, The Netherlands
[2] Department of Pathobiology, Faculty of Veterinary Medicine, Utrecht University, The Netherlands
[3] Department of Biochemistry and Cell Biology, Faculty of Veterinary Medicine, Utrecht University, The Netherlands

Abstract

Normal sexual differentiation depends on the completion of the chromosomal sex determination, gonadal differentiation, and development of the phenotypic sex. An irregularity in any of these three steps can cause a disorder in sexual development (DSD). We examined nine dogs with DSD, including abdominal ultrasonography, laparotomy, histopathology of the gonads and reproductive tract, cytogenetic analysis, and PCR analysis of the SRY gene. Furthermore, we determined the plasma concentrations of luteinizing hormone (LH), estradiol-17β and testosterone before and after administration of gonadotropin-releasing hormone (GnRH) and compared these results with those obtained in anestrous bitches and male control dogs.

The gonads of three dogs with DSD contained testicular and ovarian tissue, and in six DSD dogs only testicular tissue was found. An uterus was found in all dogs. Based on gynecological examination, cytogenetic analysis and histopathology of the gonads, seven of the nine dogs appeared to be XX sex reversals, from which three XX true hermaphrodites and four XX males, and two dogs had incomplete XY gonadal dysgenesis. All XX sex reversed dogs were found to be negative for the SRY gene by PCR. Dogs with DSD had significantly higher basal plasma LH concentrations than anestrous bitches, while no difference was found with those in male dogs. The basal plasma LH concentration increased significantly after GnRH administration in all dogs with DSD. The basal plasma estradiol concentration in dogs with DSD was significantly higher than that in anestrous bitches, while there was no significant difference with that in male dogs. The basal plasma testosterone concentration in the dogs with DSD was lower than that in male dogs. In all dogs with DSD the basal and GnRH-induced plasma testosterone concentrations were higher than the upper limit of their respective ranges in the anestrous bitches.

In conclusion, the secretion of LH and estradiol in the dogs with DSD described in our study, which all had testicular tissue in their gonads, was similar to that in the male control dogs. These results indicate that the basal and/or GnRH-stimulated plasma testosterone concentration might be used to detect the presence of testicular tissue in dogs with DSD.

Introduction

The complex process of normal mammalian sexual differentiation depends on the completion of three genetically controlled steps that determine the chromosomal sex, gonadal differentiation, and development of the phenotypic sex (Meyers-Wallen 1993). Chromosomal sex (XX or XY) is established during fertilization. Essential in male gonadal differentiation is the expression of a dominant genetic factor localized on the Y chromosome: the SRY gene (sex-determining region of the Y chromosome). The product of the SRY gene is a transcription factor (often called testes determining factor) that is thought to play a key role in initiating the cascade of gene regulations resulting in testicular induction (Meyers-Wallen 1999a; Patel et al. 2001; Meyers-Wallen 2006). In transgenic mice SRY expression leads to male development, even when acting on a XX genetic background (Koopman et al. 1991). If the SRY gene is absent or defective, the undifferentiated gonads develop into ovaries (Koopman et al. 1991). The development of the phenotypic sex is the last genetically controlled step in normal mammalian sexual differentiation. In both XX and XY zygotes, Mullerian and Wolffian ducts as well as primitive external genitalia are present in the undifferentiated gonads (Jost et al. 1973). Gonadectomy performed before gonadal differentiation results in the development of a female phenotype (Jost et al. 1973). When the SRY gene is expressed and testes have developed from the undifferentiated gonads, Sertoli cells will secrete Mullerian inhibiting substance (MIS), also known as antiMullerian hormone (AMH), which causes regression of the Mullerian system (Marshall et al. 1982; Atilola and Pennock 1986; Belville et al. 1999; Meyers-Wallen 1999a). Subsequently, the Leydig cells secrete testosterone causing stabilization and differentiation of the Wolffian ducts into the vas deferens and epididymis. In the cells of the urogenital sinus, genital tubercle and genital swellings, 5α-reductase converts testosterone into dihydrotestosterone and this hormone mediates the androgenic action necessary for the formation of the prostate, urethra, penis, and scrotum (Wilson et al. 1980). Female organogenesis is characterized by regression of the Wolffian ducts due to absence of testosterone and stabilization of the Mullerian ducts due to the absence of AMH, which will form the oviduct, uterus, and cranial vagina (O'Rahilly 1977). The absence of dihydrotestosterone results in the formation of the caudal vagina, vestibule, clitoris, and vulva (Meyers-Wallen 1993; O'Rahilly 1977).

An irregularity in any of the three development steps described above results in abnormal sexual development. To facilitate differential diagnosis of abnormal sexual development, the irregularities are categorized according to the first step that differs from normal gonadal differentiation (Meyers-Wallen 2009). Animals in which the chromosomal sex is not, or only partially, in accordance with the gonadal sex are categorized to be sex

reversed (Meyers-Wallen 1993; Meyers-Wallen 1999a). XX sex reversed true hermaphrodites have a normal female chromosome make-up but their gonads contain variable amounts of testicular and ovarian tissue (ovotestes), whereas both gonads are entirely composed of testicular tissue in XX males (Meyers-Wallen 1999a). In mice and humans XX sex reversal has been ascribed to a translocation of the SRY gene from the Y chromosome to the X chromosome during meiosis in spermatocytes (De la Chapelle 1981). However, all XX sex-reversed dogs described until now were SRY negative (Meyers-Wallen et al. 1995a; Meyers-Wallen et al. 1995b; Hubler et al. 1999; Melniczek et al. 1999; Meyers-Wallen et al. 1999b; Kuiper et al. 2005; Buijtels et al. 2009).

In animals with a disorder of phenotypic sex, known as pseudohermaphroditism, the chromosomal and gonadal sex correspond, but the phenotype is, partly or completely, that of the opposite sex (Meyers-Wallen and Patterson 1988). Male pseudohermaphrodites can have defective Mullerian duct regression, known as persistent Mullerian duct syndrome, or a disturbance in androgen-dependent masculinization, leading to genital ducts and/or external genitalia that are incompletely masculinized, causing internal and/or external parts of the female tract (Kuiper 2010). Complete or partial XY gonadal dysgenesis can also lead to agreement in chromosomal and gonadal sex but with the phenotype of the opposite sex (Achermann and Hughes 2008).

The effects of disorders in sexual development on the pituitary-gonadal axis are unknown in dogs. In this study we present the results of clinical examination, abdominal ultrasonography, laparotomy, histopathologic analysis of the gonads and reproductive tract, cytogenetic analysis, and PCR analysis of the SRY gene in nine dogs of different breeds with a disorder in sexual development. In addition, we determined the basal plasma progesterone concentrations and the plasma concentrations of luteinizing hormone (LH), estradiol-17β and testosterone before and after administration of gonadotropin-releasing hormone (GnRH) in these dogs and compared these results with those obtained in anestrous bitches and male control dogs.

Animals, Materials and Methods

Cases

The dogs with a disorder of sexual development (DSD) included in this study were referred to the Department of Clinical Sciences of Companion Animals, Utrecht University between 2001 and 2007. Among the nine dogs, there were two English Cocker Spaniels, two Pugs, one mixed breed, one Staffordshire Bullterrier, one Hollandse

Smoushond, one Stabyhoun and one Podenco. Their ages ranged from five to 20 months, (median, 10 months). Their body weight ranged from 5.6 to 16 kg (median, 8.2 kg).

Control dogs

In total twenty-eight healthy dogs, fourteen anestrous bitches and fourteen male dogs, were used as controls. Among the bitches were five mixed breed dogs, one American Bulldog, one Australian Kelpie, one Border Collie, one Bouvier des Flandres, one Bull Terrier, one Chow Chow, one Dachshund, one Labrador Retriever and one Siberian Husky. Their age ranged between 10 and 73 months (median, 18 months) and their weight between 8.8 and 36.0 kg (median, 22.7 kg). The male dogs control group consisted of five mixed breed dogs, one Chesapeake Bay Retriever, one Golden Retriever, one Maltese, one standard Poodle, two miniature Schnauzers, one Shih Tzu, one St. Bernard and one Weimaraner. Their age ranged between 18 and 54 months (median, 38 months) and their weight between 4.2 and 79.0 kg (median, 13.0 kg). The results of the GnRH-stimulation test in the bitches and male dogs have been described by Buijtels et al. (2011).

Diagnostic imaging

Abdominal ultrasonography was performed with the dogs in dorsal recumbency, using a high-definition ultrasound system (HDI 3000, Advanced Technology Laboratories, Eindhoven, the Netherlands), equipped with an 8-5 MHz broadband curved-array transducer.

GnRH-stimulation test, blood sampling and hormone determinations

Blood samples were collected at 40 min before and 0, 10, 60, 90, and 120 min after the intravenous administration of 10 µg/kg gonadoreline (Fertagyl®; Intervet/Schering-Plough Animal Health, Boxmeer, The Netherlands). Blood samples were collected from the jugular vein and centrifuged at 4 ºC for 10 min at 1500 *g*. The plasma progesterone concentration was determined in fresh plasma; the remaining plasma was stored at –25 ºC until analysis.

Plasma LH concentration was measured in the samples collected at -40, 0, 10, and 60 min after administration of gonadoreline using a heterologous radioimmunoassay (RIA) as described previously (Nett et al. 1975) with the following modifications. A rabbit antiserum raised against ovine LH (CSU-204, kindly supplied by G.D. Niswender, Colorado State University, CO, USA), radioiodinated bLH-7981 as prepared for the bovine LH assay (Dieleman and Bevers 1987), and canine pituitary standard LER 1685-1 (a gift from Dr. L.E. Reichert, Albany Medical College, NY, USA) were used in this

assay. The intra-assay and interassay coefficients of variation (CV) for values above 0.5 µg/l were 2.3% and 10.5%, respectively. The lower limit of quantitation was 0.3 µg/l.

Plasma estradiol-17β concentration was measured in the samples collected at -40, 0, 60, and 120 min for the control bitches and dogs with DSD and at -40, 0, 60 and 90 min for the control males using a solid-phase RIA (Count-A-Count TKE; Diagnostic Products Corporation, Los Angeles, CA) according to the manufacturer's instructions with modifications as described previously (Dieleman and Bevers 1987) and validated for the dog (Van Haaften et al. 1994). The intra-assay and inter-assay CV were 14% and 11.8%, respectively. The lower limit of quantitation was 7 pmol/l.

Plasma progesterone concentration was measured in the sample collected at -40 min by a previously validated I-RIA (Okkens et al. 2001). The intra-assay and interassay CV were 6% and 10.8%, respectively. The lower limit of quantitation was 0.15 nmol/l.

Plasma testosterone concentration was determined in the samples collected at 0, 60 and 90 minutes by a RIA (Coat-A-Count® Total Testosterone, Diagnostic Product Corporation) according to the manufacturer's protocol with previously described modifications to increase the sensitivity (Buijtels et al. 2006). The intra-assay and interassay CVs were 5% and 6%, respectively. The lower limit of quantitation was 51 pmol/l.

Cytogenetic analysis

Metaphase chromosomes were prepared by culturing heparinized peripheral blood for 3 days in RPMI 1640 (Invitrogen, Breda, the Netherlands) supplemented with 10% foetal calf serum (Invitrogen), 25 µg/ml concanavalin-A (Sigma-Aldrich BV, Zwijndrecht, the Netherlands) and 1% penicillin-streptomycin v/v (Invitrogen) at 37 °C. The cells were arrested in metaphase by adding 0.2 µg colchicine (Sandoz, Basel) per 5 ml culture and incubated for another 90 min at 37 °C. Metaphase spreads were prepared following standard procedures and stained with Giemsa (Sigma-Aldrich). The total number of chromosomes and the number of X chromosomes were determined in 20 randomly chosen metaphase spreads, using a Leica DMRA microscope equipped with the GENUS software of Applied Imaging (San Jose, CA, USA).

DNA isolation

Genomic DNA was isolated from blood by the salting-out procedure for nucleated cells described by Miller et al. (1988). The amount of DNA was estimated by measuring the absorbance at $\lambda = 260$ nm in a spectrophotometer (Nanodrop, Isogen Life Science, Nieuwegein, the Netherlands). DNA was diluted to a final concentration of 30 ng/µl in dH_2O.

SRY- specific PCR

The SRY-specific PCR procedure was adapted from Meyers-Wallen et al. (1995b) and performed as previously described by Buijtels et al. (2009). Genomic DNA from randomly chosen control male (n = 3) and female dogs (n = 3) and from the dogs with DSD was used as PCR template.

Histopathology

The surgically removed gonadal tissues and uterus were fixed in 10% neutral buffered formalin. Paraffin-embedded sections were cut at 3-5 µm, stained with haematoxylin and eosin (H&E), and examined with an Olympus BX41 microscope.

Data analysis

Statistical analyses of the data on plasma concentration of LH, estradiol and testosterone were performed using SPSS® for Windows, version 16.0.1 (SPSS Inc., Chicago, Il, USA). In some dogs, the plasma concentration of LH, estradiol or testosterone was below the detection limit of the assay. To enable statistical analysis, these samples were assigned the value of the lower limit of quantitation. In one dog, the stimulated testosterone values were reported as higher than 10.4 nmol/l; this value was taken to perform statistical analysis. For each dog the mean basal plasma LH and estradiol concentration was calculated from the two values before GnRH administration.

The plasma LH, estradiol, progesterone and testosterone concentrations were not normally distributed and therefore non-parametric tests were used. To evaluate the result of the GnRH-stimulation test the ANOVA for repeated measures was used with a simple contrast, the basal plasma concentration as reference category, and a Bonferroni correction. To compare differences between the groups for basal hormone concentrations the Wilcoxon rank sum test was used. $P<0.05$ was considered significant. Results are presented as median and range.

Results

The results of gynecological examination, cytogenetic analysis, PCR for presence of SRY, abdominal ultrasonography, laparotomy and histopathology findings are presented in Table 1 and Figure 1. Eight of the nine dogs were phenotypical females and were referred to the clinic because of an abnormal structure in the vulva, which appeared to be an enlarged clitoris containing an os clitoridis. One dog (dog 9) was presented as a bilaterally cryptorchid male dog with a small penis and preputium which were oriented downwards.

Cytogenetic analysis revealed that seven dogs had a normal female diploid chromosome number (78, XX) and two dogs had a normal male diploid chromosome number (78, XY). Only the 78, XY dogs tested positive in the PCR for the SRY gene.

In six dogs abdominal ultrasonography was performed (see table 1). In three of these dogs results of ultrasonography were in agreement with findings during surgery. In two dogs both gonads and in one dog the left gonad could not be found during ultrasonographic examination, while they were found at the normal position of ovaries during laparotomy. Laparotomy and histopathology of the removed tissues were performed in all dogs. In seven dogs the macroscopic appearance of the gonads during laparotomy agreed with the results of histopathology findings. Histopathological examination revealed that gonads of all nine dogs contained testicular tissue, and in the gonads of three dogs ovarian tissue was also present. Spermatogenesis was not observed in any of the gonads. In all dogs, normal uterine tissue was found.

Based on the gynecological examination, cytogenetic analysis and histopathology findings of the gonads, three different groups of dogs with a disorder in sexual development could be distinguished. Three dogs were XX true hermaphrodites (dogs 1-3), two had incomplete XY gonadal dysgenesis (dogs 4 and 5), and four dogs were XX males of which three presented with minimal external masculinization (dogs 6-9).

The plasma progesterone concentrations in dogs with DSD ranged between <0.15-3.8 nmol/l with a median of 1.3 nmol/l and did not differ significantly from the concentrations measured in anestrous bitches (1.3 nmol/l; 0.54-2.6 nmol/l).

The results of the GnRH-stimulation test on plasma concentration of LH, estradiol and testosterone in individual DSD dogs are shown in Table 2. In all DSD dogs, administration of GnRH resulted in increased plasma LH concentrations. Taken as a group, GnRH administration in the dogs with DSD resulted in increased plasma LH concentrations both at 10 min post GnRH (33.7 μg/l, 14.7-68.5 μg/l; $P<0.001$) and 60 min post GnRH (14.4 μg/l, 3.3-40.2 μg/l; $P<0.005$) compared to the basal plasma LH concentration (2.8; 0.34-18.2 μg/l). In all dogs with DSD the plasma LH concentration at 60 min was lower ($P<0.005$) than that at 10 min after GnRH administration. Taken as a group, dogs with DSD had a higher basal plasma LH concentration ($P<0.05$) than anestrous bitches (0.76 μg/l, 0.48-3.3 μg/l). In three animals, dogs 3, 5 and 9, the basal plasma LH concentration exceeded the upper limit of the range of this hormone concentration in anestrous bitches. There was no significant difference with regard to the basal plasma LH concentration between dogs with DSD and the male control dogs (3.2 μg/l, 1.0-11.3 μg/l). In two animals, dogs 3 and 5, the basal plasma LH concentration exceeded the upper limit of the range of this hormone concentration in intact male control dogs.

Table 1. *The signalement, gynecological and ultrasonographic findings, cytogenetic analysis and PCR analysis for SRY, appearance and position of the gonads at laparotomy, and histopathology findings in nine dogs with a disorder in sexual development.*

	Breed **Body weight** **Age**	**Gynecological examination**	**Cytogenetic analysis and PCR SRY**	**Ultrasonography**	**Laparotomy**	**Histopathology**
Dog 1	Staffordshire bullterrier 16 kg 10 m	Os clitoris present	78, XX Negative	Gonads in position ovaries Uterus seen	Gonads in position of ovaries Right: appearance of testis Left: appearance as ovary Uterus present	Gonads: testicular and ovarian tissue Hemorrhagic corpus luteum and follicular cysts No spermatogenesis Oviducts and normal uterine tissue
Dog 2	Pug 7.7 kg 11 m	Os clitoris present One normal estrus observed by owner	78, XX Negative	Gonads in position ovaries Uterus seen	Gonads in position of ovaries Right and left: appearance of ovaries. Uterus present	Gonads: testicular and ovarian tissue Corpus luteum and follicles in different stages of development No spermatogenesis Oviducts, epididymis and normal uterine tissue
Dog 3	Hollandse smoushond 8 kg 6 m	Os clitoris present	78, XX Negative	Not performed	Gonads in position of ovaries Right and left: appearance of testicles. Uterus present	Gonads: testicular and ovarian tissue No spermatogenesis Epididymis and normal uterine tissue
Dog 4	Stabyhoun 10.5 kg 7 m	Os clitoris present resembling a small penis	78, XY Positive	Not performed	Gonads in position of ovaries Right: appearance of ovary Left: appearance of testis Uterus present	Gonads: testicular tissue No spermatogenesis Oviducts and normal uterine tissue
Dog 5	Mixed breed 5.6 kg 8 m	Os clitoris present resembling a small penis	78, XY Positive	Neither gonads nor uterus found	Gonads in position of ovaries Right and left: appearance of testicles. Uterus present	Gonads: testicular tissue No spermatogenesis Epididymides and normal uterine tissue
Dog 6	English cocker spaniel, 12.8 kg 11 m	Os clitoris present	78, XX Negative	Gonads in position ovaries Uterus seen	Gonads in position of ovaries Right and left: appearance of testicles. Uterus present	Gonads: testicular tissue No spermatogenesis Epididymides and normal uterine tissue
Dog 7	English cocker spaniel, 8 kg 5 m	Os clitoris present	78, XX Negative	Not performed	Gonads in position of ovaries Right and left: appearance of testicles. Uterus present	Gonads: testicular tissue No spermatogenesis Epididymides and normal uterine tissue
Dog 8	Podenco 13.5 kg 1 y 8 m	Os clitoris removed	78, XX Negative	Right gonad in position ovary, left not found Uterus seen	Gonads in position of ovaries Right and left: appearance of testicles. Uterus present	Gonads: testicular tissue No spermatogenesis Epididymides and normal uterine tissue.
Dog 9	Pug 8.2 kg 1 y 5 m	Small preputium and penis. No testicles present	78, XX Negative	No gonads found Uterus seen	Right: gonad in mid abdomen Left: gonad in inguinal canal Uterus present	Gonads: testicular tissue No spermatogenesis Epididymides and normal uterine tissue

kg = kilogram; m = month

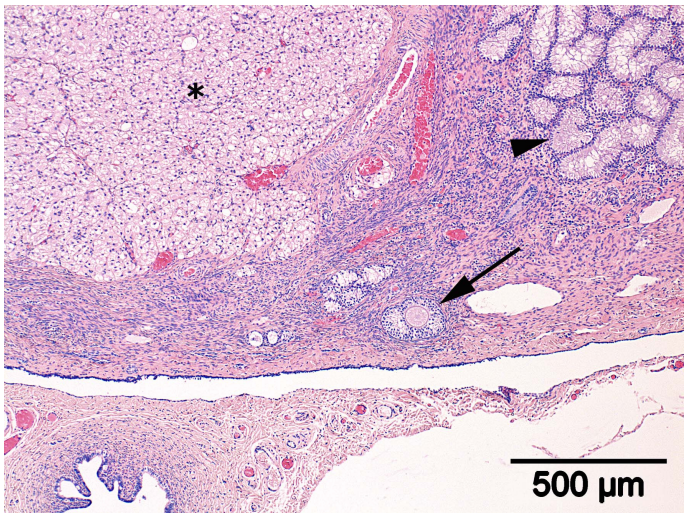

Figure 1. *Histology of an ovotestis of dog 2. The gonad contains atrophic seminiferous tubules (arrowhead), corpus luteum (asterisk) and a secondary follicle (arrow). H&E stain.*

The XX true hermaphrodites (dog 1-3), which had both ovarian and testicular tissue in their gonads, had a significantly higher ($P<0.05$) basal plasma estradiol concentration than the remaining dogs with DSD, which only had testicular tissue in their gonads. In two of the three XX true hermaphrodites, GnRH administration did not result in a rise of the plasma estradiol concentration, whereas in both dogs with incomplete XY gonadal dysgenesis (dog 4 and 5) and in three of the four XX males the plasma estradiol concentration after GnRH administration was higher than the basal concentration. Taken as a group, the basal plasma estradiol concentrations (39.5 pmol/l, 23.0-66.0 pmol/l) did not differ significantly from the plasma estradiol concentrations at 60 min post GnRH (42.4; 30.0-53.7 pmol/l) and at 120 min post GnRH (41.1; 15.5-53.1 pmol/l). Basal plasma estradiol concentrations of all but one dog with DSD were higher than the upper limit of the range in anestrous bitches. In line with this observation, the basal plasma estradiol concentration in the dogs with DSD was significantly higher ($P<0.001$) than that in anestrous bitches (17.8 pmol/l, 10.8-29.9 pmol/l). The basal plasma estradiol concentration in dogs with DSD was not significantly different from this value in the male control dogs (35.9 pmol/l, 25.1-60.1 pmol/l).

Table 2. *Plasma concentrations of LH, estradiol, and testosterone in nine dogs with a disorder in sexual development before and after intravenous administration of 10 µg GnRH (Fertagyl®) per kg body weight.*

Parameter	Dog 1	Dog 2	Dog 3	Dog 4	Dog 5	Dog 6	Dog 7	Dog 8	Dog 9
Mean basal LH (µg/l)	3.2	2.8	13.8	2.2	18.2	1.6	0.34	1.8	5.2
LH 10 min after GnRH (µg/l)	36.8	24.9	35.4	30.0	68.5	17.6	33.7	35.2	14.7
LH 60 min after GnRH (µg/l)	15.2	11.2	13.8	11.2	40.2	16.3	3.3	15.1	14.4
Mean basal estradiol (pmol/l)	45.6	57.8	66.0	47.0	39.1	32.3	34.3	23.0	39.5
Estradiol 60 min after GnRH (pmol/l)	50.3	40.4	53.7	51.4	42.4	30.0	42.0	35.8	46.9
Estradiol 120 min after GnRH (pmol/l)	53.1	41.1	48.9	52.7	41.1	15.5	38.4	27.6	44.3
Testosterone before GnRH (nmol/l)	1.3	5.2	22.8	1.7	11.1	1.2	0.12	2.7	17.1
Testosterone 60 min after GnRH (nmol/l)	2.3	8.6	13.8	6.0	12.8	3.8	5.4	>10.4	17.4
Testosterone 90 min after GnRH (nmol/l)	2.2	7.1	12.0	5.5	12.1	3.8	3.4	>10.4	17.8

In six dogs with DSD, GnRH administration resulted in a clear rise of the plasma testosterone concentration. Taken as a group, there was no significant difference between the basal plasma testosterone concentrations (2.7 nmol/l, 0.12-22.8 nmol/l) and the values measured at t=60 min (8.6 nmol/l, 2.3-17.4 nmol/l) and t=90 min (7.1 nmol/l, 2.2-17.8 nmol/l) after administration of GnRH. In six dogs with DSD, the plasma testosterone concentration at 90 min post GnRH was lower than that at 60 min post GnRH. The basal plasma testosterone concentrations of the dogs with DSD did not overlap with those of the anestrous bitches (0.06 nmol/l, 0.05-0.10 nmol/l), albeit that the basal plasma testosterone concentration of one dog with DSD (0.12 nmol/l) was only slightly higher than the upper limit of the range of the anestrous bitches. In this dog (dog 7), the plasma testosterone concentrations increased considerably after GnRH administration (5.4 and 3.4 nmol/l), whereas in the anestrous bitches GnRH-stimulated plasma testosterone concentrations never exceeded 0.15 nmol/l. The median basal plasma testosterone concentration in dogs with DSD was significantly lower ($P<0.005$) than that in the male control dogs (17.4 nmol/l; 7.5-34.8 nmol/l), only three dogs with DSD had a basal plasma testosterone concentration within the range of the male control dogs.

Discussion

Based on gynecological examination, cytogenetic analysis and histopathology findings of the gonads, seven of the nine DSD dogs were identified as XX sex reversals, of which three dogs were XX true hermaphrodites (dogs 1-3) and four dogs were XX males (dogs 6-9). In XX sex reversed animals, the chromosomal and gonadal sexes do not agree (Meyers-Wallen, 1993). Since the first review on hermaphroditism in dogs (Dain 1974), XX sex reversal has been demonstrated in various breeds (King and Garvin 1964; Selden et al. 1978; Williamson 1979; Thomas et al. 1986; Meyers-Wallen and Patterson 1988; Chaffaux et al. 1990; Sommer and Meyers-Wallen 1991; Williams et al. 1997; Hubler et al. 1999; Meyers-Wallen et al. 1999b; Kuiper et al. 2005; Buijtels et al. 2009). The present study is the first to describe XX sex reversal in the American Staffordshire Bullterrier and the Hollandse Smoushond. Of the four XX males, three (dogs 6-8) were presented with minimal external masculinization. The remaining XX male was presented with a hypoplastic penis as described by Selden et al. (1984) and Meyers-Wallen and Patterson (1988). All seven sex-reversed dogs were SRY negative, which is in agreement with all canine sex-reversed animals described so far (Meyers-Wallen et al. 1995a; Meyers-Wallen et al. 1995b; Hubler et al. 1999; Melniczek et al. 1999; Meyers-Wallen et al. 1999b; Kuiper et al. 2005; Buijtels et al. 2009). In dogs, mutations in several of the autosomal

genes leading to activation of the cascade of testis differentiation have been suggested to result in SRY-negative XX sex reversals and attempts have been made to identify the mutation resulting in XX sex reversal in the American Cocker Spaniel. Candidate genes in humans and goats, such as FOXL2, PISRT1, WT1, GATA1, FOG2, Lhx1, SF-1, SOX9, and Lhx9, have been shown not to be responsible for the XX sex reversal in the American Cocker Spaniel population (Vidal et al. 2001; Kothapalli et al. 2003; Kothapalli et al. 2004; Kothapalli et al. 2005; Meyers-Wallen 2005; Pujar et al. 2005). This supports the notion that there are still unknown genes that participate in the cascade responsible for testis differentiation.

Two dogs, dogs 4 and 5, were more difficult to classify. Both dogs presented phenotypically as females, had a male diploid chromosome number (78, XY) and only testicular tissue could be found in the gonads. Because these dogs had a uterus, testicular feminization syndrome, caused by a non-functional androgen receptor, cannot be the cause as a uterus is never present in this syndrome. Persistent Mullerian duct syndrome leads to an externally normal male, with or without cryptorchid testicles and because the dogs were presented as females this syndrome can also not explain the presentation of the dogs. As was the case in our two dogs, in humans (46, XY) gonadal dysgenesis leads to a female phenotype, bilateral testes and normal Mullerian structures. Clitoral enlargement occurs when the dysgenetic testes produce significant amounts of testosterone (Styne and Grumbach 2008). In line with the observations in humans the two dogs had an os clitoris which looked like a small penis. XY testicular dysgenesis can occur as a complete and an incomplete form. In the complete form, no Wolffian derivates are present, circulating testosterone levels are undetectable and there is no response on hCG stimulation (Kofman-Alfaro et al. 1989). The two dogs in the present study did have Wolffian structures, detectable plasma testosterone concentrations, and a response to GnRH stimulation. Therefore we suggest that both dogs had incomplete (78, XY) gonadal dysgenesis. Eighty percent of human patients with XY gonadal dysgenesis do not have a mutation or deletion of the SRY gene, indicating that also other autosomal or X-linked genes play a role in gonadal development (Sarafoglou and Ostrer 2000). Although during histopathology no ovarian tissue was found in the gonads of these two dogs, XY incomplete gonadal dysgenesis remains a challenging diagnosis, because absolute exclusion of the presence of ovarian tissue in the gonads is hardly possible. In humans 52% of patients referred to a tertiary hospital multidisciplinary intersex clinic because of disorders in sexual development appeared to be misdiagnosed (Minto et al. 2005), illustrating the difficulty in diagnosing these kind of disorders. In addition, establishing a precise diagnosis for humans with a disorder in sexual development and a XY karyotype is even less reliable than in humans with a XX karyotype (Hughes 2008).

In the present study, in all dogs testicular tissue was found in the gonads and in three dogs also ovarian tissue was present. Because all dogs also had a uterus, it is likely that insufficient production or action of Mullerian-inhibiting substance (MIS), or production during the wrong period of fetal life, play a role in the pathogenesis. Insufficient secretion of MIS has indeed been demonstrated in XX sex-reversed dogs (Meyers-Wallen et al. 1994), but it may also have happened in the dogs with incomplete 78, XY gonadal dysgenesis. Also in people with XY gonadal dysgenesis either an abnormal production or defective action of MIS during embryonic life is suspected (Kofman-Alfaro et al. 1989).

In the dogs with DSD, the plasma LH concentrations at both 10 and 60 min after administration of GnRH were significantly higher compared to basal values, as has also been demonstrated in anestrous bitches (van Haaften 1994; Meij et al. 1996; Buijtels et al. 2006; Beijerink et al. 2007; Buijtels et al. 2011) and intact male dogs (Knol et al. 1993; Buijtels et al. 2011). The median basal plasma LH concentration in the dogs with DSD was similar to that in the male control dogs, but significantly higher than that in the anestrous bitches. In three DSD dogs, the basal plasma LH concentration exceeded the upper limit of the range of the anestrous bitches. The fact that these three dogs with DSD also had the highest basal plasma testosterone concentration may be due to the high circulating LH concentration. In general, these DSD dogs had LH and estradiol concentrations comparable to the male control dogs. The variation in basal plasma concentrations of LH and gonadal steroid hormones in the dogs with DSD was considerable. Therefore comparisons with the basal values of anestrous bitches and male control dogs must be done with caution.

The median basal plasma estradiol concentration of the three true hermaphrodites (DSD with ovarian tissue; dogs 1-3) was significantly higher (57.8 pmol/l, 45.6-66.0 pmol/l) than that of the other six dogs, which is remarkable, because the basal plasma estradiol concentration of intact male dogs (35.9 pmol/l, 25.1-60.1 pmol/l) is higher than that of anestrous bitches (17.8 pmol/l, 10.8-29.9 pmol/l), albeit with a considerable overlap (Buijtels et al. 2011). Consequently, the basal plasma estradiol concentration cannot be used to determine if ovarian tissue is present in the gonads of dogs with DSD. Also in humans, basal plasma estradiol concentrations are not reliable to predict the presence of ovarian tissue in the gonads (Achermann and Hughes 2008).

The basal plasma testosterone concentration of all dogs with DSD was higher than the upper limit of the range of the anestrous bitches. Moreover, Buijtels et al. (2011) demonstrated that in anestrous bitches, GnRH-stimulated plasma testosterone concentrations never exceeded 0.15 nmol/l, whereas in the dogs with DSD the lowest plasma testosterone concentration after GnRH administration was 2.2 nmol/l. In the one dog with DSD that had a basal plasma testosterone concentration just exceeding the upper

limit of the range of the anestrous bitches, the GnRH-stimulated value undoubtedly demonstrated the presence of testicular tissue.

In conclusion, the present findings suggest that the GnRH-stimulation test with measurement of plasma testosterone concentrations is the most reliable functional test to detect the presence of testicular tissue in dogs suspected of DSD, which is in line with the limited findings in previous reports (Chaffaux et al. 1990; Buijtels et al. 2009).

Acknowledgment

The authors would like to acknowledge Mrs. D.M. Blankenstein and Ms. C.H.Y Oei of the Biochemical Laboratory for performing the hormone measurements, Ms. Ing. E van ‘t Veld of the Department of Biochemistry and Cell Biology for the cytogenetic analysis and Dr. B. Spee of the Department of Clinical Sciences of Companion Animals for PCR analysis. The critical reading of the manuscript Dr. B.E. Belshaw is highly appreciated.

References

Achermann JC, Hughes LA. Disorders of sexual development. In: Williams Textbook of endocrinology, 11th edition. Kronenberg HM, Melmed S, Polonsky KS, Larsen PR (Eds). Philadelphia, Saunders Elsevier, 2008, pp. 783-849.

Atilola MAO, Pennock PW. Cystic uterus masculinus in the dog. Six case history reports. Vet Rad 1986;27:8-14.

Belville C, Josso N, Picard JY. Persistence of Mullerian derivates in males. Am J Med Genet 1999;98:218-223.

Beijerink NJ, Buijtels JJCWM, Okkens AC, Kooistra AC, Dieleman SJ. Basal and GnRH-induced secretion of FSH and LH in anestrous versus ovariectomized bitches. Theriogenology 2007;67:1039-1045.

Buijtels JJCWM, Beijerink NJ, Kooistra HS, Dieleman SJ, Okkens AC. Effects of gonadotropin releasing hormone administration on the pituitary-ovarian axis in anoestrous versus ovariectomized bitches. Reprod Domest Anim 2006;41:555-561.

Buijtels JJCWM, De Gier J, van Haeften T, Kooistra HS, Spee B, Veldhuis Kroeze EJ, Zijlstra C. Minimal external masculinization in a SRY-negative XX male Podenco Dog. Reprod Domest Anim 2009;44:751-756.

Buijtels JJCWM, De Gier J, Wolthers CHJ, Oei CHY, Kooistra HS, Okkens AC. Effects of gonadotropin-releasing hormone administration on the pituitary-gonadal axis in male and feale dogs before and after gonadectomy. Submitted Theriogenology 2011.

Chaffaux S, Nudelmann N, Durand V, Cribiu EP. Le pseudohermaphrodisme male, a propos du cas d'un chien intersexué 78,XX. Rec Méd Vét 1990;166:125-132.

De la Chapelle A. The aetiology of maleness in XX men. Hum Genet 1981;58:105-116.

Dain AR. Intersexuality in a cocker spaniel. J Reprod Fertil 1974;39:365-371.

Dieleman SJ, Bevers MM. Effects of monoclonal antibody against PMSG administered shortly after the preovulatory LH surge on time and number of ovulations in PMSG/PG-treated cows. J Reprod Fertil 1987;81:533-542.

Van Haaften B, Bevers MM, van den Brom WE, Okkens AC, van Sluijs FJ, Willemse AH, Dieleman SJ. Increasing sensitivity of the pituitary to GnRH from early to late anestrus in the beagle bitch. J Reprod Fertil 1994;101:221-225.

Hubler M, Hauser B, Meyers-Wallen VN, Arnold S. Sry-negative XX true hermaphrodite in a Basset hound. Theriogenology 1999;51:1391-1403.

Hughes IA. Disorders of sex development: a new definition and classification. Best Pract Res Clin Endocrinol Metab 2008;22:119-134.

Jost A, Vigier B, Prepin J, Perchellet JP. Studies on sex differentiation in mammals. Rec Prog Horm Res 1973;29:1-41.

King NW, Garvin CH. Bilateral hermaphroditism in a dog. J Am Vet Med Assoc 1964;145:997-1001.

Knol BW, Dieleman SJ, Bevers MM, Brom van den WE. GnRH in the male dog: dose-response relationships with LH and testosterone. J Reprod Fertil 1993;98:159-161.

Kofman-Alfaro S, Ulloa-Aguirre A, Méndez JP, Angeles A, Schiavon R, Pérez-Palacios G. Studies on gonadal dysgenesis: variable expressivity of the XY testicular dysgenesis syndrome; two case reports. Eur J Obstet Gynecol Reprod Biol 1989;32:265-274.

Koopman P, Gubbay J, Vivian N, Goodfellow P, Lovell-Badge R. Male development of chromosomal female mice transgenic for Sry. Nature 1991;351:117-121.

Kothapalli KS, Kirkness EF, Natale LJ, Meyers-Wallen VN. Exclusion of PISRT1 as a candidate locus for canine SRY-negative XX sex reversal. Anim Genet 2003;34:467-469.

Kothapalli KS, Kirkness EF, Pujar S, Meyers-Wallen VN. Exclusion of WT1 as a candidate gene for canine SRY-negative XX sex reversal. Anim Genet 2004;35:466-467.

Kothapalli K, Kirkness E, Pujar S, van Wormer R, Meyers-Wallen VN. Exclusion of candidate genes for canine SRY-negative XX sex reversal. J Hered 2005;96:759-763.

Kuiper H, Bunck C, Günzel-Apel AR, Drögemüller C, Hewicker-Trautwein M, Distl O. SRY-negative XX sex reversal in a Jack Russel Terrier: a case report. Vet J 2005;169:116-7.

Kuiper HJ, 2010. Gonadal development and disorders of sexual differentiation. In: Clinical Endocrinology of Dogs and Cats. Rijnberk A, Kooistra HS (Eds). Hannover, Schlütersche, 2010, pp. 187-202.

Marshall LS, Oehlert ML, Haskins ME, Selden JR, Patterson DF. Persistent Mullerian duct syndrome in miniature schnauzers. J Am Vet Med Assoc 1982;81:798-801.

Meij BP, Mol JA, Hazewinkel HAW, Bevers MM, Rijnberk A. Assessment of a combined anterior pituitary function test in beagle dogs: rapid sequential intravenous administration of four hypothalamic releasing hormones. Domest Anim Endocrinol 1996;13:161-170.

Melniczek JR, Damhach D, Prociuk U, Jezyk PF, Henthorn PS, Patterson DF, Giger U. Sry-negative XX sex reversal in a family of Norwegian Elkhounds. J Inter Med 1999;13:564-569.

Meyers-Wallen VN, Patterson DF. XX sex reversal in the American cocker spaniel dog: phenotypic expression and inheritance. Hum Gen 1988;80:23-30.
Meyers-Wallen VN. Genetics of sexual differentiation and anomalies in dogs and cats. J Reprod Fertil Suppl 1993;47:441-452.
Meyers-Wallen VN, MacLaughlin D, Palmer V, Donahoe PK. Mullerian-inhibiting substance secretion is delayed in XX sex-reversed dog embryos. Mol Reprod Dev 1994;39:1-7.
Meyers-Wallen VN, Bowman L, Acland GM, Palmer VL, Schlafer D, Fajt V. Sry-negative XX sex reversal in the German shorthaired pointer dog. J Hered 1995a;*86:*369-374.
Meyers-Wallen VN, Palmer VL, Acland GM, Herschfield B. Sry-negative XX sex reversal in the American Cocker Spaniel Dog. Mol Reprod Dev 1995b;41:300-305.
Meyers-Wallen VN. Inherited disorders in sexual development. Am Gen Ass 1999a;90:93-95.
Meyers-Wallen VN, Schlafer D, Barr I, Lovell-Badge R, Keyzner A. Sry-negative XX sex reversal in purebred dogs. Mol Reprod Dev 1999b;53:266-273.
Meyers-Wallen NV. Sf1 and Mis expression: Molecular milestones in the canine sex determination pathway. Mol Reprod Dev 2005;70:383-389.
Meyers-Wallen VN. Genetics, genomics, and molecular biology of sex determination in small animals. Theriogenology 2006;66:6-7.
Meyers-Wallen VN. Review and update: Genomic and molecular advances in sex determination and differentiation in small animals. Reprod Dom Anim 2009;44:40–46.
Miller SA, Dykes DD, Polesky HF. A simple salting out procedure for extracting DNA from human nucleated cells. Nucleic Acids Res 1988;16:1215.
Minto CL, Crouch NS, Conway GS, Creighton SM. XY females: revisiting the diagnosis. BJOG 2005;112:1407-1410.
Nett TM, Akbar AM, Phemister RD, Holst PA, Reichert LE Jr, Niswender GD. Levels of luteinizing hormone, estradiol and progesterone in serum during the estrous cycle and pregnancy in the beagle bitch. Proc Soc Exp Biol Med 1975;148:134-139.
Okkens AC, Teunissen JM, Van Osch W, Van Den Brom WE, Dieleman SJ Kooistra HS. Influence of litter size and breed on the duration of gestation in dogs. J Reprod Fertil Suppl 2001;57:193–197.
O'Rahilly R. The development of the vagina in the human. In: Morphogenesis and malformation of the genital system. Blandau RJ, Bergsma D (Eds). New York, Alan Liss, 1977, pp. 123-136.
Patel M, Dorman KS, Zhang YH, Huang BL, Arnold AP, Sinsheimer JS, Vilain E, McCabe ER. Primate DAX1, SRY, and SOX9: evolutionary stratification of sex-determination pathway. Am J Hum Gen 2001;68:275-280.
Pujar S, Kothapalli KS, Kirkness E, van Wormer RH, Meyers-Wallen VN. Exclusion of Lhx9 as a candidate gene for SRY-negative XX Sex Reversal in the American Cocker Spaniel Model. J Hered 2005;96:452-454.
Sarafoglou K, Ostrer H. Familial sex reversal: a review. J Clin Endocrinol Metab 2000;85:483-493.
Selden JR, Wachtel SS, Haskins ME. Genetic basis of XX male syndrome and XX true hermaphroditism: evidence in the dog. Science 1978;18:644-646.
Selden JR, Moorhaed PS, Koo GC, Wachtel SS, Haskins ME, Patterson D. Inherited XX sex reversal in the cocker spaniel dog. Hum Gen 1984;67:62-69.
Sommer MM, Meyers-Wallen VN. XX true hermaphroditism in a dog. J Am Vet Med Assoc 1991;198:435-438.
Styne DM, Grumbach MM. Puberty: ontogeny, neuroendocrinology, physiology and disorders. In: Williams Textbook of Endocrinology 11th edition. Kronenberg HM, Melmed S, Polonsky KS, Larsen PR (Eds), Philadelphia Saunders Elsevier, 2008, pp. 969-1167
Thomas TN, Olson PN, Hoopes PJ. Lateral hermaphroditism and seminoma in a dog. J Am Vet Med Assoc 1986;189:1596-1597.
Vidal VP, Chaboissier MC, De Rooij DG, Schedl A. SOX9 induces testis development in XX transgenic mice. Nat Genet 2001;28:216-217.
Williams J, Partington BP, Smith B, Hedlund CS. Pyovagina and stump pyometra in a neutered XX sex-reversed beagle: a case report. J Am Anim Hosp Assoc 1997;33:83-90.
Williamson JH. Intersexuality in a family of Kerry Blue Terriers. J Hered 1979;70:138-139.
Wilson JD, Griffin JE, George FW. Sexual differentiation: Early hormone synthesis and action. Biol Reprod 1980;22:9-18.

Chapter 8

Minimal external masculinization in a SRY-negative XX male Podenco dog

JJCWM Buijtels[1], J de Gier[1], T van Haeften[2], HS Kooistra[1], B Spee[1], EJB Veldhuis Kroeze[3], C Zijlstra[2], AC Okkens[1]

Reproduction in Domestic Animals 2009;44:751-756

[1] Department of Clinical Sciences of Companion Animals, Faculty of Veterinary Medicine, Utrecht University, The Netherlands
[2] Department of Biochemistry and Cell Biology, Faculty of Veterinary Medicine, Utrecht University, The Netherlands
[3] Department of Pathobiology, Faculty of Veterinary Medicine, Utrecht University, The Netherlands

Abstract

Normal mammalian sex differentiation takes place in three genetically-controlled steps: chromosomal sex determination (XX or XY), gonadal differentiation, and development of the phenotypic sex. Animals are considered to be sex reversed if chromosomal sex determination and gonadal development are not in agreement. In this report, sex reversal is described in a 1½-year-old Podenco dog that was referred because of suspected recurrent growth of a previously removed os clitoridis in the vulva. With that exception the dog was phenotypically female, but had never been in estrus and exhibited male behavior. Abdominal ultrasonography showed a small tubular structure dorsal to the bladder, consistent with a uterus. An ovoid structure resembling a gonad was visible between the right kidney and inguinal canal. Plasma testosterone concentrations before and after GnRH administration indicated the presence of functional testicular tissue. Two testes, each with its epididymis and ductus deferens, and a complete bicornuate uterus were removed surgically. Cytogenetic analysis of peripheral blood lymphocytes showed a normal female karyotype (78, XX). These findings are consistent with the diagnosis of an XX male. PCR analysis of genomic DNA revealed that the SRY gene was absent.

In summary, this report describes the first SRY-negative XX male Podenco dog with an almost complete female phenotype despite high basal and stimulated plasma testosterone concentrations. It is hypothesized that the clinical observations in this dog may have been caused by reduced and delayed MIS secretion and the absence of conversion of testosterone to dihydrotestosterone due to 5α-reductase deficiency.

Introduction

Normal mammalian sex differentiation depends on the completion of three genetically controlled steps: chromosomal sex determination (XX or XY), gonadal differentiation, and development of the phenotypic sex (Meyers-Wallen 1993). The chromosomal sex, known as XX or XY, is established during fertilization. Male gonadal sex development is initiated by transcription factors of the SRY gene, located on the Y chromosome. In transgenic mice, SRY expression can induce gene transcription leading to male development, even when acting on an XX genetic background (Koopman et al. 1991). In the absence of the SRY gene, ovarian differentiation occurs (Meyers-Wallen 1993). Gonadectomy performed before gonadal differentiation results in the development of a female phenotype (Jost et al. 1973). The latter two findings indicate that the basic embryonic plan is female.

The last genetically controlled step is the development of the phenotypic sex. In the early embryo, XX and XY zygotes have both Mullerian and Wolffian ducts as well as primitive external genitalia (Meyers-Wallen 1993). In the presence of a Y chromosome, testes develop and the Sertoli cells start to secrete Mullerian inhibiting substance (MIS), also known as antiMullerian hormone (AMH), which causes regression of the Mullerian system (Marshall et al. 1982; Atilola and Pennock 1986; Belville et al. 1999; Meyers-Wallen 1999). Testosterone, produced by the Leydig cells, causes the stabilization and differentiation of the Wolffian duct into the ductus deferens and epididymis. In the cells of the urogenital sinus, genital tubercle and genital swellings, 5α-reductase converts testosterone into dihydrotestosterone and mediates the androgenic action necessary for the formation of the prostate, urethra, penis, and scrotum (Wilson et al. 1980). Female organogenesis is characterized by regression of the Wolffian ducts due to absence of the SRY gene and stabilization of the Mullerian ducts, which will form the oviduct, uterus, and cranial vagina (O'Rahilly 1977). The urogenital sinus, genital tubercle, and genital swellings differentiate into the caudal vagina, vestibule, clitoris, and vulva due to the absence of dihydrotestosterone (O'Rahilly 1977; Meyers-Wallen 1993).

A defect in any of the phases of sex differentiation results in abnormal sexual development. Animals in which chromosomal sex determination and gonadal development are not in agreement are said to be sex reversed (Meyers-Wallen 1993; Meyers-Wallen 1999). XX sex- reversed animals have a normal female chromosome makeup but their gonads contain variable amounts of both testicular and ovarian tissue. Animals having both gonads entirely composed of testicular tissue are termed XX males. More often the gonads contain both testicular and ovarian tissue (ovotestes) and the animals are then referred to as XX true hermaphrodites (Meyers-Wallen 1999). Incomplete masculinization is observed in both XX males and XX true hermaphrodites (Meyers-Wallen 1993).

In mice and humans, XX sex reversal can be due to a translocation of the SRY gene from the Y chromosome to the X chromosome during male meiosis (De la Chapelle 1981), but all XX sex-reversed dogs described thus far have been SRY negative (Meyers-Wallen et al. 1995a; Meyers-Wallen et al. 1995b; Hubler et al. 1999; Melniczek et al. 1999; Meyers-Wallen et al. 1999; Kuiper et al. 2005). The development of ovotestes or testes in XX dogs indicates that also other mutated genes can induce testicular development in the absence of SRY (Meyers-Wallen et al. 1999). XX sex reversal is inherited as an autosomal recessive trait in the American cocker spaniel, and in the beagle and German shorthaired pointer the inheritance is also consistent with an autosomal recessive trait (Meyers-Wallen and Patterson 1988; Meyers-Wallen et al. 1995a; Meyers-Wallen et al. 1995b; Melniczek et al. 1999; Meyers-Wallen et al. 1999).

We report here the first description of an XX male Podenco dog, including the clinical signs; ultrasonographic findings in the abdomen; plasma concentrations of luteinizing hormone (LH), estradiol, and testosterone before and after administration of gonadotropin releasing hormone (GnRH); cytogenetic analysis; PCR analysis for the presence of the SRY gene; and histology of the genital tract. The results are discussed with regard to the possible cause of the sex reversal.

Materials and Methods

Case description

An os clitoridis was observed in a phenotypical female Podenco dog at the age of 10 weeks and was subsequently removed. The dog was referred to the Department of Clinical Sciences of Companion Animals, Utrecht University, at the age of 1½ years because of suspected recurrent growth of an os clitoridis. The dog had never been in estrus, exhibited male behavior in the presence of bitches in estrous, urinated like a male, and had a continuous mucous vaginal discharge. The dog had seven littermates (6 males and 1 female) without any known abnormalities. The female littermate had shown normal estrus behavior.

Diagnostic imaging

Ultrasonography was performed with the dog in dorsal recumbency, using a high-definition ultrasound system (HDI 3000, Advanced Technology Laboratories, Eindhoven, the Netherlands), equipped with an 8-5 MHz broadband curved-array transducer.

Blood sampling and hormone determination

Blood samples were collected at 40 min before and 0, 10, 60, 90, and 120 min after the intravenous administration of 10 µg GnRH (Receptal®, Intervet, Boxmeer, The Netherlands) per kg body weight. Plasma LH concentration was measured in the samples at -40, 0, 10, and 60 min using a heterologous radioimmunoassay (RIA) as described previously (Nett et al. 1975) with the following modifications. A rabbit antiserum raised against ovine LH (CSU-204, kindly supplied by G.D. Niswender, Colorado State University, CO, USA), radioiodinated bLH-7981 as prepared for the bovine LH assay (Dieleman and Bevers 1987), and canine pituitary standard LER 1685-1 (a gift from Dr. L.E. Reichert, Albany Medical College, NY, USA) were used in this assay. The intra-assay and interassay coefficients of variation for values above 0.5 µg/l were 2.3% and 10.5%, respectively. The lower limit of quantitation was 0.3 µg/l.

Plasma estradiol-17β concentration was measured in the samples at -40, 0, 60, and120 min by use of a solid-phase RIA (Count-A-Count TKE; Diagnostic Products Corporation, Los Angeles, CA) according to the manufacturer's instructions with modifications as described previously (Dieleman and Bevers 1987) and validated for the dog (Van Haaften et al. 1994). The intra-assay and interassay coefficients of variation were 14% and 11.8%, respectively. The lower limit of quantitation was 7 pmol/l.

Plasma progesterone concentration was measured in the sample at -40 min by a previously validated RIA (Okkens et al. 2001). The intra-assay and interassay coefficients of variation were 6% and 10.8%, respectively. The lower limit of quantitation was 0.15 nmol/l.

Plasma testosterone concentration was measured in the samples at 0, 60, and 90 min by a RIA (Coat-A-Count® Total Testosterone, Diagnostic Product Corporation, Los Angeles, CA) according to the manufacturer's protocol. To increase sensitivity the assay was modified by extracting 1 ml plasma with 2.5 ml diethylether, evaporating the extract under nitrogen, and dissolving the residue in 125 µl of the A-serum (0-serum) provided by the manufacturer. The average recovery after extraction and evaporation was 85%. Values were corrected for volume and extraction efficiency. In addition, three additional standards (51, 255, and 1020 pmol/l) were included. The lower limit of quantitation was set at the lowest standard point, 51 pmol/l.

Cytogenetic analysis

Metaphase chromosomes were prepared from concanavalin A stimulated peripheral blood lymphocytes cultured for 3 days in RPMI at 37 °C. Chromosome preparations were made following standard procedures. The cells were arrested in metaphase by adding 0.1 mg colchicine (Sigma) per 5 ml culture and incubated for another 90 minutes. Chromosome

spreads were stained with Giemsa stain. The total number of chromosomes and the number of X chromosomes were determined in 20 randomly chosen metaphase spreads, using a Leica DMRA microscope equipped with the GENUS software of Applied Imaging (San Jose, CA, USA).

DNA isolation

Genomic DNA was isolated from blood by the salting-out procedure for nucleated cells described by Miller et al. (1988). The amount of DNA was estimated by measuring the absorbance at $\lambda = 260$ nm in a spectrophotometer (Nanodrop, Isogen Life Science, Nieuwegein, the Netherlands). DNA was diluted to a final concentration of 30 ng/µl in dH_2O.

SRY- specific PCR

The SRY-specific PCR procedure was adapted from Meyers-Wallen et al. (1995b). The consensus SRY primers, 5'-3' GTC AAG CGC CCC ATG AA upstream and CTC TGT GCC TCC TCA AAG AAA downstream, generated a 104 bp PCR product from the SRY HMG box. For each experimental sample a PCR was performed on the endogenous reference glyceraldehyde-3-phosphate dehydrogenase (GAPDH). Consensus GAPDH primers, 5'-3' TGT CCC CAC CCC CAA TGT ATC upstream and CTC CGA TGC CTG CTT CAC TAC CTT downstream were used which generated a 100 bp PCR product (Spee et al. 2005). Genomic DNA from three randomly chosen male dogs, three randomly chosen control female dogs and from the Podenco dog was used as the PCR template. PCR was performed in a thermal cycler (MJ PTC-100 Thermal Cycler, BioRad, Veenendaal, the Netherlands). For each PCR reaction, 5 µl of template DNA was used in a total reaction volume of 50 µl containing 1x manufacturer's buffer, 2 mM $MgCl_2$, 200 µM dNTP, 20 pmol of both primers, and 1.25 units of Platinum Taq Polymerase (Invitrogen, Breda, the Netherlands). All PCR protocols included a 5 min polymerase activation step and 35 cycles at 94 ^{o}C denaturation for 30 sec, annealing for 30 sec, and elongation at 72 ^{o}C for 30 sec with a final extension for 5 min at 72 ^{o}C. Annealing temperatures were optimized at 52 ^{o}C for SRY and 56 ^{o}C for GAPDH (data not shown). PCR products were separated by gel electrophoresis on a 2% agarose gel with TBE buffer, stained with ethidium bromide, and analysed in a Geldoc XR system (Biorad).

Histopathology

The surgically removed gonadal tissue and uterus were fixed in 10% neutral buffered formalin. Paraffin-embedded sections were cut at 4 µm, stained with haematoxylin and eosin (H&E), and examined with an Olympus BX41 microscope.

Results

Clinical examination revealed an abnormal, cauliflower-like growth in the vulvar mucosa at the site of a previously removed os clitoridis, but there was no palpable recurrence of the bone. Vaginoscopy required anesthesia because the vaginoscope could not be inserted beyond the vestibule without pain. A small fibrous septum was visible at the transition from vestibule to vagina and the urethral orifice was visible at the same location.

Abdominal ultrasonography revealed a small tubular structure dorsal to the bladder and an ovoid structure resembling a gonad on the right side between the kidney and the inguinal canal. The left side of the abdomen could not be examined because of gas in the colon.

The plasma progesterone concentration was 0.6 nmol/l at 40 min before the injection of GnRH. Plasma LH concentration was low at T=-40 and T=0, and increased markedly after GnRH administration (Table 1). Plasma estradiol concentration was above the low limit of detection of the assay at T=-40 and T=0 and increased slightly at T=60 and T=120 after GnRH administration. Basal plasma testosterone concentration was much higher than the low limit of detection of the assay and the concentration increased markedly at T=60 and T=90 after the administration of GnRH (Table 1).

Table 1. *Plasma concentrations of LH, estradiol, and testosterone before and after administration of GnRH (at T=0).*

Time (min)	LH (µg/l)	Estradiol (pmol/l)	Testosterone (nmol/l)
-40	1.8	23.2	n.d.
0	1.7	22.8	2.7
10	35.2	n.d.	n.d.
60	15.1	35.5	>10.4
90	n.d.	n.d.	>10.4
120	n.d.	27.6	n.d.

n.d. = not determined

In all 20 metaphases analyzed, 76 autosomes and 2 X chromosomes were found, representing a normal female karyotype (78, XX). No chromosomal abnormalities were observed.

PCR analysis revealed the presence of the SRY gene in male control dogs (Fig. 1, lanes 5-7). No PCR product was obtained in female control dogs (Fig. 1, lanes 2-4) or in the Podenco dog (Fig. 1, lane 1), indicating the absence of the SRY gene. Endogenous PCR controls (GAPDH) showed that there was no difference in the amount of templates used.

Laparotomy revealed two gonads resembling testes, each with an epididymis and plexus pampiniformis, caudal to the kidneys in the normal position of ovaries. A complete bicornuate uterus was also present. Both gonads and the uterus were removed.

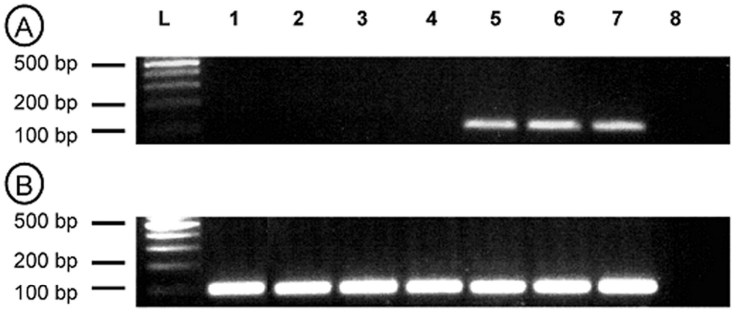

Figure 1. *Agarose gel electrophoresis of PCR products. (A) PCR products obtained with SRY-specific primers. (B) PCR products of endogenous reference gene GAPDH . Lanes: L = 100 bp size marker, 1 = Podenco dog, 2-4 = control female dogs, 5-7 = control male dogs, 8 = no-template control.*

Histological examination confirmed the identity of the small but morphologically normal uterus and two testes with their epididymis and ductus deferens. The uterus was composed of a normal perimetrium, myometrium, and endometrium, the latter with branched glands and lined by a continuous layer of cuboidal, sparsely-vacuolated epithelial cells (Fig. 2).

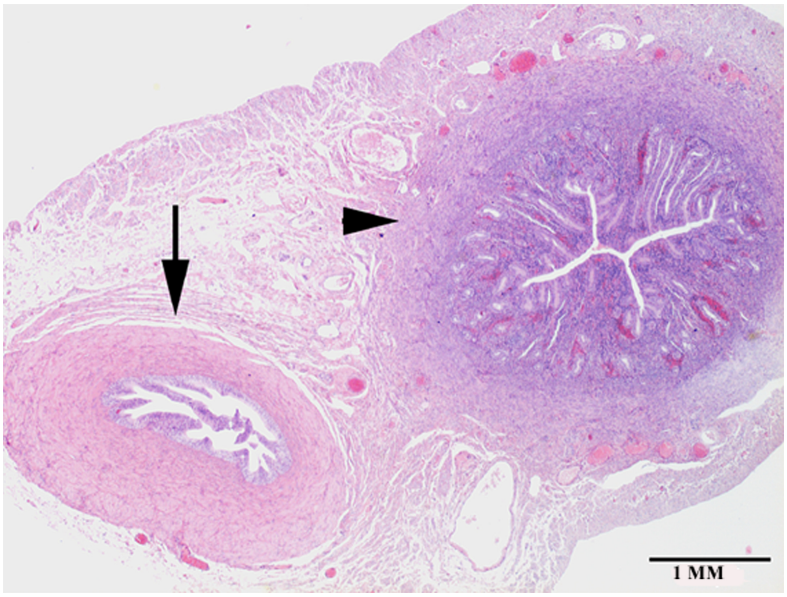

Figure 2. *Photomicrograph showing a ductus deferens (arrow) with pseudostratified epithelium and both inner circular and outer longitudinal smooth muscle layers, and the uterus (arrowhead) with thick mucosa containing glands, surrounded by myometrium and perimetrium. (H&E).*

Both testes were enclosed by a fibrous tunica albuginea and were composed of non-spermatogenic convoluted seminiferous tubules whose epithelium consisted of stratified Sertoli cells and abundant Leydig cells. No spermatozoa were seen (Figs. 3 and 4). Both epididymes consisted of loose connective tissue supporting empty tubules lined by pseudostratified non-ciliated columnar epithelium, comparable to normal efferent epididymidal ductules. Ducti deferentes, with a tunica muscularis and pseudostratified columnar epithelium with scant apical stereocilia lining the lumen, originated from the testes and passed besides the uterus.

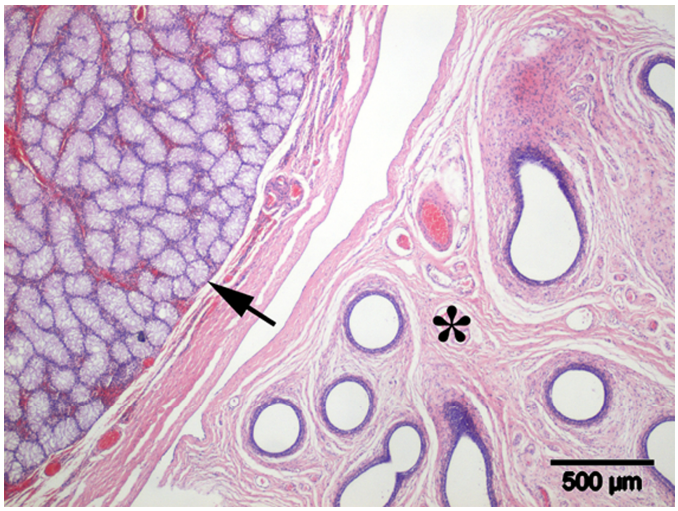

Figure 3. *Photomicrograph of one gonad, composed of non-spermatogenic testicular tissue (arrow) and adjacent tubular structures (asterisk) resembling epididymis. Note complete absence of spermatozoa. (H&E).*

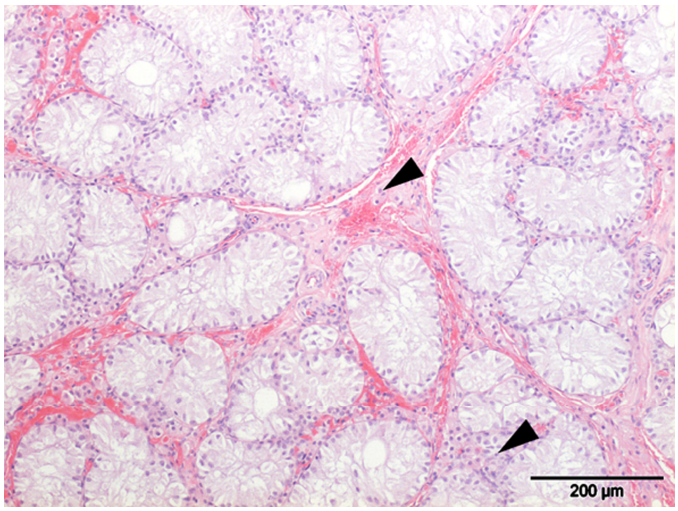

Figure 4. *Photomicrograph of a cross-section of testicular tissue, showing abundant seminiferous tubules lined by stratified Sertoli cells and separated by fibrovascular septa and prominent polyhedral eosinophilic Leydig cells (arrowheads). No spermatozoa are visible. (H&E).*

Discussion

Since the first review on hermaphroditism in dogs (Dain 1974), XX sex reversal has been demonstrated in various breeds (King and Garvin 1964; Selden et al. 1978; Williamson 1979; Thomas et al. 1986; Meyers-Wallen and Patterson 1988; Chaffaux et al. 1990; Sommer and Meyers-Wallen 1991; Williams et al. 1997; Hubler et al. 1999; Meyers-Wallen et al. 1999; Kuiper et al. 2005). In addition, there has been one report of an XY sex-reversed dog (Schelling et al. 2001). Both Selden et al. (1984) and Meyers-Wallen and Patterson (1988) investigated XX true hermaphrodites and XX male American cocker spaniels of the same family for phenotypic and gonadal histological characteristics, and they were able to identify three different groups. The first group consisted of true hermaphrodites having one normal ovary and one ovotestis, bilateral oviducts, normal female external genitalia, and reproductive capability. The second group consisted of true hermaphrodites with unilateral or bilateral ovotestes, oviducts and/or epididymes, and masculinization of external genitalia, and some were capable of reproduction. The last and smallest group consisted of XX sterile males with bilateral testes, epididymes, uterus, prostate, and male external genitalia comprising a hypoplastic penis and malformed prepuce but no scrotum. The Podenco dog described here was also an XX male with bilateral testes and a uterus, and rather than a penis and prepuce it had a vagina and vestibule, with the urethral orifice in the normal position for a bitch.

Plasma concentration of LH before injection of GnRH was low, consistent with a negative feedback of estradiol and/or testosterone on the pituitary (Knol et al. 1993; Van Haaften et al. 1994; Rijnberk 1996). The increase in plasma estradiol and testosterone, following upon the increase in plasma LH concentration after GnRH administration, is consistent with the presence of functional testicular tissue. In females, plasma testosterone concentration is low and cannot be stimulated by administration of GnRH (Buijtels et al. 2006). The plasma testosterone concentrations observed in the Podenco dog before and after GnRH stimulation resemble those reported in intact male dogs (Knol et al. 1993). In two case reports on an XX male French basset (Chaffaux et al. 1990) and an XX male Jack Russell Terrier (Kuiper et al. 2005), the external and internal genitalia were similar to those we observed in the Podenco dog. Unfortunately, the plasma testosterone concentration was not determined in the Jack Russell Terrier. The plasma testosterone concentrations in the French basset before and after hCG stimulation were between values in a normal male and female dog before and after stimulation. It was suggested that testosterone levels present during the embryonic critical period were suboptimal for supporting normal development of androgen-dependent organs. The discrepancy in the response to stimulation may be explained in part by the use of hCG rather than GnRH.

Since basal and GnRH-stimulated plasma testosterone concentrations in the Podenco were comparable to those in normal males, it is unlikely that a deficiency in testosterone during foetal development may have caused the female phenotype of this dog. Moreover, transformation of the Wolffian ducts into the ducti deferentes and epididymes, which were present in the Podenco, is testosterone dependent (Meyers-Wallen 1993). In contrast to the XX males described by Selden et al. (1984) and Meyers-Wallen and Patterson (1988), the Podenco lacked a prostate as well as masculinization of the external genitalia, which is dependent on dihydrotestosterone. Testosterone is converted to dihydrotestosterone by 5α-reductase, which is present in cells of the urogenital sinus, genital tubercle, and genital swellings. Dihydrotestosterone promotes formation of the prostate and prostatic urethra from the urogenital sinus, the penis from the genital tubercle, and the scrotum by fusion of the genital swellings (Meyers-Wallen 1993). Since the Podenco lacked all dihydrotestosterone-driven masculinization of the urogenital tract, deficient 5α-reductase activity during the critical embryonic period is a possible explanation of its phenotype. Deficiency of 5α-reductase has also been reported in men (Forest 2001). Absence of the receptor for dihydrotestosterone is an unlikely explanation, because testosterone and dihydrotestosterone bind to the same androgen receptor. The testicular feminization syndrome is caused by a partially functional or non-functional androgen receptor due to mutations in the X-linked androgen receptor gene. This syndrome, which has been reported in a domestic shorthaired cat, occurs in XY males which appear to be females but have bilateral abdominal testes without epididymes or ducti deferentes and have no uterus (Meyers-Wallen et al. 1989). Since the Podenco had epididymes, ducti deferentes, and a uterus, this syndrome is unlikely to be the explanation for its phenotype.

Histological examination of the gonads revealed the presence of Sertoli cells within the testes. Sertoli cells produce Mullerian-inhibiting substance (MIS), which is responsible for the regression of the Mullerian ducts. Mullerian duct regression starts at D36 and is completed at D46 of gestation in the dog embryo (Meyers-Wallen et al. 1991). Meyers-Wallen et al. (1994) observed that MIS secretion in XX sex-reversed dog embryos is both reduced and delayed in comparison with that in normal males, which may explain the observed incomplete Mullerian duct regression. Reduced and delayed MIS secretion appeared to be secondary to a delay in Sertoli cell and seminiferous tubule development and may explain the presence of a uterus and cranial vagina despite the presence of bilateral testes. Alternatively, inadequate and/or unequal distribution of the putative receptors for MIS between the fallopian tubes and uterus could be involved in the differential sensitivity. The cranial end of the Mullerian ducts has been reported to be more sensitive to MIS in dogs (Meyers-Wallen and Patterson 1989) and in rats (Picon 1969). This could explain the presence of a uterus and the absence of oviducts.

In mice, XX sex reversal may be due to a translocation of the SRY gene from the Y chromosome to another chromosome (Singh and Jones 1982). In humans, 10% of the XX true hermaphrodites and 80% of the XX males have been reported to be positive for the SRY gene (McElreavey et al. 1992). However, all canine XX males described thus far, including the present example, have been SRY negative (Meyers-Wallen et al. 1995a; Meyers-Wallen et al. 1995b; Hubler et al. 1999; Melniczek et al. 1999; Meyers-Wallen et al. 1999; Kuiper et al. 2005). The development of ovotestes or testes in XX dogs is therefore believed to be due to a mutation of an autosomal gene mimicking SRY activity (Meyers-Wallen et al. 1995b), but this mutation has not yet been characterized. It is also possible that in the absence of SRY, putative genes acting downstream from SRY trigger testis development if they undergo an appropriate mutation (Hunter 1995).

In summary, this report describes the first SRY-negative XX male Podenco dog with an almost complete female phenotype despite high basal and stimulated plasma testosterone concentrations.

Acknowledgment

The authors would like to acknowledge Mrs. D.M. Blankenstein and Ms. C.H.Y Oei of the Biochemical Laboratory for performing the hormone measurements and Ms. Ing. E van ‘t Veld of the Department of Biochemistry and Cell Biology for the cytogenetic analysis. The critical reading of the manuscript by Dr. B.E. Belshaw is highly appreciated.

References

Atilola MAO, Pennock PW. Cystic uterus masculinus in the dog. Six case history reports. Vet Rad 1986;27:8-14.

Belville C, Josso N, Picard JY. Persistence of Mullerian derivates in males. Am J Med Genet 1999;98:218-223.

Buijtels JJCWM, Beijerink NJ, Kooistra HS, Dieleman SJ, Okkens AC. Effects of gonadotropin releasing hormone administration on the pituitary-ovarian axis in anestrous versus ovariectomized bitches. Reprod Domest Anim 2006;41:555-561.

Chaffaux S, Nudelmann N, Durand V, Cribiu EP. Le pseudohermaphrodisme male, a propos du cas d'un chien intersexué 78,XX. Rec Méd Vét 1990;166:125-132.

De la Chapelle A. The aetiology of maleness in XX men. Human Genetics 1981;58:105-116.

Dain AR. Intersexuality in a cocker spaniel. J Reprod Fertil 1974;39:365-371.

Dieleman SJ, Bevers MM. Effects of monoclonal antibody against PMSG administered shortly after the preovulatory LH surge on time and number of ovulations in PMSG/PG-treated cows. J Reprod Fertil 1987;81:533-542.

Forest MG. Diagnosis and treatment of disorders of sexual development. In: Endocrinology, 4th ed. De Groot LJ, Jameson JL (Eds). Philadelphia, WB Saunders, 2001, pp. 1992-1993.

Van Haaften B, Bevers MM, van den Brom WE, Okkens AC, van Sluijs FJ, Willemse AH, Dieleman SJ. Increasing sensitivity of the pituitary to GnRH from early to late anestrus in the beagle bitch. J Reprod Fertil 1994;101:221-225.

Hubler M, Hauser B, Meyers-Wallen VN, Arnold S. Sry-negative XX true hermaphrodite in a Basset hound. Theriogenology 1999;51:1391-1403.

Hunter RHF. Anomalous sexual development in domestic species. In: Sex determination, differentiation and intersexuality in placental mammals. Hunter RHF (Ed). Cambridge University press, 1995, pp. 139-174.

Jost A, Vigier B, Prepin J, Perchellet JP. Studies on sex differentiation in mammals. Rec Prog Horm Res 1973;29:1-41.

King NW, Garvin CH. Bilateral hermaphroditism in a dog. J Am Vet Med Asssoc 1964;145:997-1001.

Knol BW, Dieleman SJ, Bevers MM, Brom van den WE. GnRH in the male dog: dose-response relationships with LH and testosterone. J Reprod Fertil 1993;98:159-161.

Koopman P, Gubbay J, Vivian N, Goodfellow P, Lovell-Badge R. Male development of chromosomal female mice transgenic for Sry. Nature 1991;351:117-121.

Kuiper H, Bunck C, Günzel-Apel A-R, Drögemüller C, Hewicker-Trautwein M, Distl O. SRY-negative XX sex reversal in a Jack Russell Terrier: a case report. Vet J 2005;169:116-117.

Marshall LS, Oehlert ML, Haskins ME, Selden JR, Patterson DF. Persistent Mullerian duct syndrome in miniature schnauzers. J Am Vet Med Assoc 1982;81:798-801.

McElreavey K, Rappaport R, Vilain E, Abbas N, Richaud F, Lortat-Jacob S, Berger R, Le Coniat M, Boucekkine C, Kucheria K. A minority of 46,XX true hermaphrodites are positive for the Y-DNA sequence including SRY. Hum Gen 1992;90:121-125.

Melniczek JR, Damhach D, Prociuk U, Jezyk PF, Henthorn PS, Patterson DF, Giger U. Sry-negative XX sex reversal in a family of Norwegian Elkhounds. J Inter Med 1999;13:564-569.

Meyers-Wallen VN, Patterson DF. XX sex reversal in the American cocker spaniel dog: phenotypic expression and inheritance. Hum Gen 1988;80:23-30.

Meyers-Wallen VN, Patterson DF. Sexual differentiation and inherited disorders of sexual development in the dog. J Reprod Fertil Suppl 1989;39:57-64.

Meyers-Wallen VN, Wilson JD, Griffin JE, Fisher S, Moorhead PH, Goldschmidt MH, Haskins ME, Patterson DF. Testicular feminization in a cat. J Am Vet Med Assoc 1989;195: 631-634.

Meyers-Wallen VN, Manganaro FF, Kuroda T, Concannon PW, MacLaughlin DT, Donahoe PK. The critical period for Mullerian duct regression in the dog embryo. Biol Reprod 1991;45:623-633.

Meyers-Wallen VN. Genetics of sexual differentiation and anomalies in dogs and cats. J Reprod Fertil Suppl 1993;47:441-452.

Meyers-Wallen VN, MacLaughlin D, Palmer V, Donahoe PK. Mullerian-inhibiting substance secretion is delayed in XX sex-reversed dog embryos. Mol Reprod Dev 1994;39:1-7.

Meyers-Wallen VN, Bowman L, Acland GM, Palmer VL, Schlafer D, Fajt V. Sry-negative XX sex reversal in the German shorthaired pointer dog. J Hered 1995a;86:369-374.

Meyers-Wallen VN, Palmer VL, Acland GM, Herschfield B. Sry-negative XX sex reversal in the American Cocker Spaniel Dog. Mol Reprod Dev 1995b;41:300-305.

Meyers-Wallen VN. Inherited disorders in sexual development. Amer Gen Ass 1999;90:93-95.

Meyers-Wallen VN, Schlafer D, Barr I, Lovell-Badge R, Keyzner A. Sry-negative XX sex reversal in purebred dogs. Mol Reprod Dev 1999;53:266-273.

Miller SA, Dykes DD, Polesky HF. A simple salting out procedure for extracting DNA from human nucleated cells. Nucleic Acids Res 1988;16:1215.

Nett TM, Akbar AM, Phemister RD, Holst PA, Reichert LE Jr, Niswender GD. Levels of luteinizing hormone, estradiol and progesterone in serum during the estrous cycle and pregnancy in the beagle bitch. Proc Soc Exp Biol Med 1975;148:134-139.

Okkens AC, Teunissen JM, Van Osch W, Van Den Brom WE, Dieleman SJ Kooistra HS. Influence of litter size and breed on the duration of gestation in dogs. J Reprod Fertil Suppl 2001;57:193–197.

O'Rahilly R. The development of the vagina in the human. In: Morphogenesis and malformation of the genital system. Blandau RJ, Bergsma D (Eds). Alan Liss New York, 1977, pp. 123-136.

Picon R. Action du testicule foetal sur le développement in vitro des canaux de Müller chez le rat. Arch Anat Microsc Morphol Exp 1969;58:1-19.

Rijnberk A. Protocols for function test. In: Clinical Endocrinology of dogs and cats Rijnberk A. (Ed). Kluwer Academic Publishers Dordrecht, 1996, pp. 205-212.

Schelling C, Pienkowska A, Arnold S, Hauser B, Switonski M. A male to female sex-reversed dog with a reciprocal translocation. J Reprod Fertil Suppl 2001;57:435-438.

Selden JR, Wachtel SS, Haskins ME. Genetic basis of XX male syndrome and XX true hermaphroditism:evidence in the dog. Science 1978;18:644-646.

Selden JR, Moorhaed PS, Koo GC, Wachtel SS, Haskins ME, Patterson D. Inherited XX sex reversal in the cocker spaniel dog. Hum Gen 1984;67:62-69.

Singh L, Jones KW. Sex reversal in the mouse (mus musculus) is caused by a recurrent nonreciprocal crossover involving the X and aberrant Y chromosome. Cell 1982;28:205-216.

Sommer MM, Meyers-Wallen VN. XX true hermaphroditism in a dog. J Am Vet Med Assoc 1991;198:435-438.

Spee B, Penning LC, van den Ingh TS, Arends B, Ijzer J, van Sluijs FJ, Rothuizen J. Regenerative and fibrotic pathways in canine hepatic portosystemic shunt and portal vein hypoplasia, new models for clinical hepatocyte growth factor treatment. Comp Hepatol 2005;7:4-7.

Thomas TN, Olson PN, Hoopes PJ. Lateral hermaphroditism and seminoma in a dog. J Am Vet Med Assoc 1986;189:1596-1597.

Williams J, Partington BP, Smith B, Hedlund CS. Pyovagina and stump pyometra in a neutered XX sex-reversed beagle: a case report. J Am Anim Hosp Assoc 1997;33:83-90.

Williamson JH. Intersexuality in a family of Kerry Blue Terriers. J Hered 1979;70:138-139.

Wilson JD, Griffin JE, George FW. Sexual differentiation: Early hormone synthesis and action. Biol Reprod 1980;22:9-18.

Chapter 9

Effects of gonadotropin-releasing hormone administration on the pituitary-gonadal axis in male and female dogs before and after gonadectomy

JJCWM Buijtels[1,3], J de Gier[1,3], CHJ Wolthers[1], CHY Oei[2], HS Kooistra[1], AC Okkens[1]

Theriogenology; Submitted

[1] Department of Clinical Sciences of Companion Animals, Faculty of Veterinary Medicine, Utrecht University, The Netherlands
[2] Department of Farm Animal Health, Section of Reproduction, Faculty of Veterinary Medicine, Utrecht University, The Netherlands
[3] Both authors contributed equally to the article

Abstract

Different methods have been described to differentiate gonadally intact male dogs and anestrous bitches from gonadectomized animals, but most studies were non-paired and involved low numbers of mainly beagle dogs. We performed a GnRH-stimulation test, both before and after gonadectomy, in 14 female dogs and 14 male dogs of several breeds to obtain more insight in the pituitary-gonadal axis in intact and neutered dogs and to establish reference values.

In both bitches and male dogs, basal plasma LH and FSH concentrations were significantly higher after compared to before gonadectomy. In contrast to the basal plasma LH concentrations, in both bitches and male dogs there was no overlap in basal plasma FSH concentrations before and after gonadectomy. The basal plasma LH and FSH concentrations before gonadectomy were respectively lower and higher in bitches compared to male dogs, while after gonadectomy no significant difference in these basal values were present between males and females. Before gonadectomy, GnRH administration resulted in an increase of the plasma LH and FSH concentrations in both bitches and male dogs, but the increment of FSH was less than that of LH. After gonadectomy, GnRH administration resulted in a clear rise in plasma LH concentrations in both bitches and male dogs. In contrast, GnRH did not result in a significant rise of the plasma FSH concentrations in ovariectomized bitches, whereas in castrated male dogs the increase only just reached a significant level.

GnRH administration resulted in a significant increase in plasma testosterone concentrations in both bitches and male dogs before gonadectomy. In male dogs no overlap existed in basal and GnRH-stimulated plasma testosterone concentrations before and after gonadectomy. In bitches there was overlap, although basal and GnRH-stimulated plasma testosterone concentrations were significantly higher before compared to after ovariectomy.

Basal plasma estradiol concentrations in intact male dogs were significantly higher than those in castrated dogs and did not overlap, whereas these values did not differ significantly in anestrous bitches before and after ovariectomy. In all bitches before and also in some of the ovariectomized bitches, GnRH administration resulted in increased plasma estradiol concentrations. At 120 min after GnRH administration plasma estradiol concentrations in intact bitches did not overlap anymore with those in ovariectomized bitches. In 12 of the intact male dogs, GnRH administration also resulted in a rise in the plasma estradiol concentration but the increase just failed to reach a significant level.

The basal LH to testosterone and FSH to estradiol ratios of bitches and male dogs after gonadectomy were much higher than those before gonadectomy and did not overlap.

In conclusion, the basal plasma FSH concentration seems more appropriate than the basal plasma LH concentration to verify the neuter status in male and female dogs. Measurement of the basal plasma testosterone concentration seems reliable to verify the neuter status in male dogs. The plasma estradiol concentration at 120 min after GnRH administration can be used to discriminate between bitches with and without functional ovarian tissue. The LH to testosterone and FSH to estradiol ratios allow differentiation between gonadally intact dogs from gonadectomized dogs by using only a single blood sample.

Introduction

The presence or absence of functional gonadal tissue in a male or female dog can be uncertain, for instance when the animal has an unknown reproduction history, e.g. if it has been acquired from a shelter and (early age) neutering can not be excluded. Furthermore, ovariectomy (OVX) is not always performed completely and this may result in the presence of remnant functional ovarian tissue in bitches. Additionally, disorders of sexual development, such as aneuploidism (e.g. 77, XO), or disease processes, such as oophoritis, may result in non-functional gonadal tissue (Johnston 1989; Nickel et al. 1991). Lastly, long-term treatment with GnRH agonists may also result in (reversible) non-functional gonadal tissue (Junaidi et al. 2003; Goericke-Pesch et al. 2010).

In female dogs, the question whether or not functional gonadal tissue is present becomes especially relevant when a presumed neutered bitch exhibits signs, such as vaginal discharge or attractiveness to male dogs, which may be attributed to ovarian hormones. Differentiation between a bitch with or without functional ovarian tissue is especially challenging during anestrus. Vaginal cytology and vaginoscopy, very useful in diagnosing estradiol influence during the follicular phase (Olson et al. 1982; Shille and Olson. 1989; de Gier et al. 2006; Schaefers-Okkens and Kooistra 2010; Schaefers-Okkens 2010), have no diagnostic value in anestrus. Circulating progesterone concentrations, perfect in diagnosing functional ovarian tissue during the phase of preovulatory luteinization and ovulation, and the luteal phase (Okkens et al. 1981) overlap in anestrous and OVX bitches (Buijtels et al. 2006).

In male dogs the question whether or not testicular tissue is present can usually be resolved quite easily by palpation of the testicles, but when these are not palpable, bilateral cryptorchidism has to be considered (Olson et al. 1992). In addition, palpable testicular tissue is not synonymous with functional gonadal tissue. For instance, chemical castration with GnRH implants may have resulted in (almost complete) suppression of

steroidogenesis and thus spermatogenesis. Although sexual dimorphic behavior in male dogs may change as a result of a decrease of the plasma testosterone concentrations to basal levels, differentiation between intact bilateral cryptorchid and castrated animals cannot rely on differences in behavior alone (Olson et al. 1992; Neilson et al. 1997; Goericke-Pesch et al. 2010). However, clinical examination, especially determination of prostate size mostly enables to discriminate between the presence or absence of testosterone synthesis and secretion by testicular tissue.

The circulating concentrations of the gonadotropins, follicle-stimulating hormone (FSH) and luteinizing hormone (LH), have been shown to give an indication as to whether a bitch has functional ovarian tissue and is in anestrus or has undergone OVX, since plasma LH and FSH concentrations are usually higher in OVX compared to anestrous bitches (Olson et al. 1992; Buijtels et al. 2006; Beijerink et al. 2007). Unfortunately, the pulsatile secretion pattern of these pituitary hormones may cause overlap in the plasma concentrations in gonadally intact and OVX bitches, especially with regard to the plasma LH concentration. Plasma FSH concentrations, in contrast to plasma LH concentrations, have been reported not to overlap in anestrous bitches with functional ovarian tissue and OVX bitches (Reichler et al. 2004; Beijerink et al. 2007). Similarly, in male dogs, the plasma LH and FSH concentrations are higher in castrated compared to male dogs with functional testicular tissue (DePalatis et al. 1978), although overlap, as in female dogs, has been reported concerning plasma LH concentrations, but not plasma FSH concentrations (Olson et al. 1992).

Better differentiation of dogs with and without functional gonadal tissue can be achieved by performing a challenge test using gonadotropin-releasing hormone (GnRH), a decapeptide produced by the hypothalamus which stimulates the release of LH and FSH in both bitches and male dogs (Chakraborty and Fletcher 1977; Lacoste et al. 1988; Knol et al. 1993; van Haaften et al. 1994; Buijtels et al. 2006). The relationship between GnRH and LH is dose-dependent in both male and female dogs (Knol et al. 1993; van Haaften et al. 1994). In bitches with functional ovarian tissue, GnRH administration during anestrus causes an increment in the plasma concentrations of LH, FSH and subsequently estradiol and the responses are higher in advanced than early anestrus (van Haaften et al. 1994; Buijtels et al. 2006; Beijerink et al. 2007). In OVX bitches, GnRH administration has been reported to increase only the plasma LH concentration, but not the plasma FSH, estradiol and progesterone concentrations (Chaffaux et al. 1981; Jeffcoate. 1993; Buijtels et al. 2006; Beijerink et al. 2007). In male dogs with functional gonadal tissue, administration of GnRH causes a rise in the plasma LH and testosterone concentrations (Falvo et al. 1982; Knol et al. 1993; Purswell and Wilcke. 1993), but does not result in a significant rise of the plasma FSH concentration (Purswell and Wilcke. 1993).

Unfortunately, studies describing the use of the GnRH-stimulation test in dogs with functional gonadal tissue and gonadectomized animals were non-paired and performed with low numbers of mainly beagle dogs. Therefore, this study describes the results of the GnRH-stimulation test obtained in male and female dogs of several breeds, both before and after gonadectomy, and in a higher numbers of animals than described in previous studies to establish reference values and to obtain more insight in the pituitary-gonadal axis in gonadally intact and neutered dogs.

Animals, Materials and Methods

Animals

Fourteen healthy, client-owned bitches were used in this study. According to the owners, all bitches had shown at least one estrous period. All bitches were in anestrus at the time of inclusion in the study, with a median plasma progesterone concentration of 1.3 nmol/l (range 0.5-2.6 nmol/l). The group consisted of five mix breed dogs, one American Bulldog, one Australian Kelpie, one Border Collie, one Bouvier des Flanders, one Bull Terrier, one Chow Chow, one Dachshund, one Labrador Retriever and one Siberian Husky. Their median age at the onset of the study was 18 months (range 10 to 73 months).

Furthermore 14 healthy, client-owned male dogs were used in this study. All male dogs possessed two scrotal testicles. The group consisted of five mix-breed dogs, one Chesapeake Bay Retriever, one Golden Retriever, one Maltese, one standard Poodle, two miniature Schnauzers, one Shih Tzu, one St. Bernard dog and one Weimaraner. Their median age at the onset of the study was 38 months (range 18 to 54 months).

GnRH-stimulation test, blood sampling, and hormone determinations

A GnRH-stimulation test was performed in the week before gonadectomy in both males and females. Routine bilateral ovariectomy in bitches or castration in male dogs was performed. A second GnRH-stimulation test was performed at 133 days (median, range 75 – 221 days) after gonadectomy in the bitches and at 148 days (median, range 110 – 229 days) after gonadectomy in the males. The interval between gonadectomy and the second GnRH-stimulation test did not differ significantly between males and females.

At T=0 after collecting the second blood sample a GnRH analogue was administered intravenously via the cephalic vein. In bitches 10 µg/kg B.W. gonadoreline (Fertagyl®; Intervet/Schering-Plough Animal Health, Boxmeer, The Netherlands) and in male dogs 0.4 µg/kg B.W. buserelin (Receptal®, Intervet/Schering-Plough Animal Health, Boxmeer, The Netherlands) was used. Blood samples were collected from the jugular vein.

Progesterone was analyzed in fresh plasma obtained from bitches and the remaining plasma was placed in chilled heparin-coated tubes, and centrifuged at 1500 X g for 10 min at 4 ^{o}C. Plasma was stored at –25 ºC until analysis. Plasma samples were used for determination of the concentrations of progesterone (in bitches; at -40 min), LH and FSH (at -40, 0, 10, and 60 min), testosterone (at 0, 60, and 90 min) and estradiol (in bitches; at -40, 0, 60, and 120 min; in male dogs at -40, 0, 60 and 90 min).

Plasma progesterone concentrations were determined using a ^{125}I-RIA, validated for the dog (Okkens et al. 2001). The intra-assay and interassay CVs were 6% and 10.8%, respectively. The lower limit of quantitation was 0.15 nmol/l.

Plasma LH concentrations were determined by a heterologous radioimmunoassay (RIA), as described previously (Nett et al. 1975) with the following modifications. A rabbit antiserum raised against ovine LH (CSU-204, kindly supplied by G.D. Niswender, Colorado State University, CO, USA), radioiodinated bLH-7981 as prepared for the bovine LH assay (Dieleman and Bevers. 1987), and canine pituitary standard LER 1685-1 (a gift from Dr. L.E. Reichert, Albany Medical College, NY, USA) were used in this assay. The intra-assay and interassay coefficients of variation (CVs) for values above 0.5 µg/l were 2.3% and 10.5%, respectively. The lower limit of quantitation was 0.3 µg/l.

Plasma FSH concentrations were determined by an immunoradiometric assay (IRMA) of Biocode SA (Liège, Belgium) coded AHROO4, according to the manufacturer's instructions and as described previously by Beijerink et al. (2007). The intra-assay and inter-assay CVs were 3.6% and 6.2%, respectively. The lower limit of quantitation was 0.5 µg/l.

Plasma testosterone concentrations were determined by RIA (Coat-A-Count® Total Testosterone, Diagnostic Product Corporation) according to the manufacturer's protocol with previously described modifications to increase the sensitivity (Buijtels et al. 2006). The intra-assay and interassay CVs were 5% and 6%, respectively. The lower limit of quantitation was 51 pmol/l.

Plasma estradiol-17β concentrations were determined using a solid-phase RIA (Count-A-Count TKE; Diagnostic Products Corporation, Los Angeles, CA) according to the manufacturer's instructions with modifications as described previously (Dieleman and Bevers. 1987) and validated for the dog (van Haaften et al. 1994). The intra-assay and interassay CVs were 14% and 11.8%, respectively. The lower limit of quantitation was 7 pmol/l.

Analysis and presentation of data

Statistical analysis was performed using SPSS® for Windows, version 16.0.1 (SPSS Inc., Chicago, IL, USA). When the plasma concentrations of LH, FSH, estradiol, progesterone,

or testosterone were below the limit of quantitation, the respective lower limit value was assigned to the sample. Basal LH, FSH and estradiol concentrations were calculated as the mean of the plasma concentrations in the blood samples collected 40 minutes and directly before GnRH administration. Non-parametric tests were used as the plasma LH, FSH, estradiol and testosterone data were not normally distributed. To compare differences between the groups for one hormone at a certain time point the Wilcoxon rank sum test was used. To compare the differences before and after gonadectomy within one group the Wilcoxon signed rank test was used. To evaluate the changes of the different hormones during the GnRH-stimulation tests within one group the ANOVA for repeated measures was used with a simple contrast, the basal plasma concentration as reference category, and a Bonferroni correction. $P<0.05$ was considered significant. Results are presented as median and range.

Cut-off values with corresponding sensitivity, specificity and 95% confidence intervals (95% CI) were calculated based on receiver operating characteristic (ROC) analysis with gonadectomy as the positive state. Only cut-off values with 100% sensitivity and 100% specificity are given.

Plots for the graphical presentation of data were created with Sigmaplot 11 (Systat Software Inc., Chicago, IL, USA). In the box-and-whisker plots the box represents the interquartile range from the 25th to 75th percentile. The horizontal bar through the box indicates the median, and the whiskers represent the main body of data between the 5th and 95th percentile.

Ethics of experimentation

This study was approved by the Ethical Committee of the Faculty of Veterinary Medicine, Utrecht University.

Results

The results of the GnRH-stimulation tests for the bitches and male dogs before and after gonadectomy and the derived ratios are presented in Tables 1 and 2 and Figures 1 to 6.

Basal plasma LH concentrations were significantly higher after compared to before gonadectomy in both bitches and male dogs. Moreover, in bitches there was no overlap in basal plasma LH concentrations before and after OVX (Table 1). ROC analysis of these data revealed a cut-off value for the plasma LH concentration in bitches of 3.4 µg/l. In males, however, the basal plasma LH concentrations before and after surgical castration did overlap (range 1.0 µg/l – 11.3 µg/l and range 2.5 µg/l – 17.1 µg/l, respectively)

(Table 1). In 7 of 14 bitches and 10 of 14 male dogs the highest stimulated pre-gonadectomy plasma LH concentration was higher than the basal values after gonadectomy. In all bitches and all male dogs, both before and after gonadectomy, GnRH administration resulted in increased plasma LH concentrations at 10 min (Table 1 and Figure 1). At 60 min LH was still higher than basal in all male dogs and most bitches. In four of 14 bitches after gonadectomy, however, plasma LH concentration at 60 min was not higher than the basal value. Both before and after gonadectomy, plasma LH concentrations at 60 min post GnRH were significantly lower compared to those at 10 min post GnRH in bitches, but not in male dogs. In both bitches and male dogs the GnRH-stimulated plasma LH concentrations were significantly higher after compared to before gonadectomy, but the values overlapped. Before gonadectomy the basal plasma LH concentration in bitches was significantly lower compared to that in male dogs, while after gonadectomy no significant difference was present anymore (Fig. 1).

Basal plasma FSH concentrations were higher after compared to before gonadectomy with no overlap in both bitches and male dogs (Table 1). ROC analysis of these data revealed cut-off values for bitches and male dogs of 11.0 µg/l and 7.7 µg/l, respectively. In all animals before gonadectomy and also in all male dogs after castration, GnRH administration resulted in increased plasma FSH concentrations at 10 min and 60 min (Table 1 and Figure 1). In bitches after OVX GnRH administration caused increased plasma FSH concentrations in only nine bitches at 10 min and in 11 bitches at 60 min, resulting in insignificant differences between basal plasma FSH concentrations and GnRH-stimulated values in OVX bitches. Moreover, overlap was present in GnRH-stimulated FSH concentrations at 10 min and 60 min between bitches before and after OVX (Table 1).

There was no overlap in GnRH-stimulated FSH concentrations at 10 and 60 min between the male dogs before and after castration. Taken as a group, in both bitches and male dogs the highest plasma FSH concentration after GnRH administration before gonadectomy was higher than the lowest basal FSH concentration after gonadectomy. However, in all individual bitches and all individual male dogs the basal plasma FSH concentration after gonadectomy was higher than the highest GnRH-stimulated value before gonadectomy. In male dogs before gonadectomy plasma FSH concentrations increased significantly from 10 to 60 min after GnRH administration, whereas in bitches, both before and after gonadectomy, and male dogs after gonadectomy no significant differences in plasma FSH concentrations between samples collected at 10 and 60 min after GnRH administration were found (Fig. 2). The GnRH-stimulated plasma FSH concentrations were significantly higher after compared to before gonadectomy in both

bitches and male dogs. Before, but not after gonadectomy, the basal plasma FSH concentrations in bitches were significantly higher compared to those in male dogs.

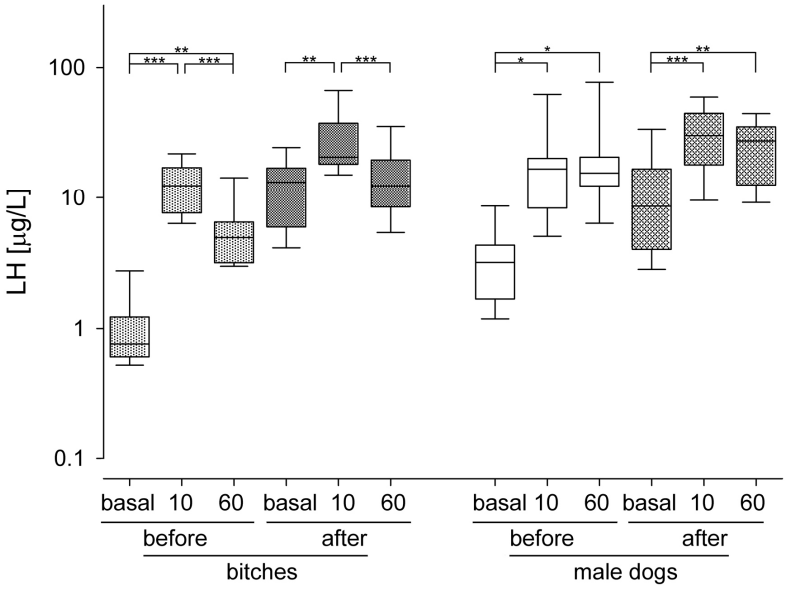

Figure 1. *Plasma LH concentrations before and at 10 and 60 min after GnRH administration in 14 bitches and 14 male dogs before and after gonadectomy.*
*Asterisks denote a significant difference: *: p<0.05; **: p < 0.01; ***: p < 0.001.*
Mind the logarithmic scale of the y-axis.

The LH to FSH ratios of bitches before and after OVX were comparable (Table 2, Fig. 3). Also the LH to FSH ratios of castrated male dogs were similar to those of the bitches. However, in gonadally intact male dogs the LH to FSH ratios were significantly higher than in castrated male dogs and bitches irrespective of the presence or absence of functional ovarian tissue. There was no overlap of the LH to FSH ratios before and after castration in male dogs. ROC analysis of these data revealed a cut-off value of 0.44. In all bitches and male dogs the LH to FSH ratios increased at 10 min post GnRH, and thereafter decreased again in 10 of 12 male dogs after gonadectomy and in all the bitches, both before and after gonadectomy.

Table 1 *Hormone concentrations during GnRH-stimulation tests performed before and after gonadectomy in bitches (n=14) and male dogs (n=14).*

	Bitches				**Male dogs**			
	anestrus		**after gonadectomy**		**with functional testicular tissue**		**after gonadectomy**	
	median	**range**	**median**	**range**	**median**	**range**	**median**	**range**
Basal LH (µg/l)	0.76	0.48 – 3.27	13.16	3.56 – 29.39	3.19	1.01 – 11.25	6.54	2.46 – 17.11
LH 10 min after GnRH (µg/l)	12.38	5.77 – 23.23	20.59	12.92 – 68.07	16.29	3.93 – 92.61	25.52	9.44 – 52.80
LH 60 min after GnRH (µg/l)	4.94	2.95 – 19.27	12.38	4.58 – 44.10	15.41	5.63 – 103.92	24.28	8.59 – 37.57
Basal FSH (µg/l)	4.17	1.18 – 8.08	53.01	13.9 – 82.88	2.17	0.50 – 6.43	26.57	8.88 – 59.66
FSH 10 min after GnRH (µg/l)	12.60	4.75 – 22.26	50.90	16.17 – 86.07	2.56	0.50 – 8.43	30.89	9.76 – 71.27
FSH 60 min after GnRH (µg/l)	12.39	5.19 – 19.54	50.64	16.57 – 89.22	3.15	0.54 – 10.16	31.92	10.94 – 75.95
Basal testosterone (nmol/l)	0.06	0.05 – 0.10	0.05	0.05 – 0.06	17.44	7.46 – 34.84	0.06	0.05 – 0.07
Testosterone 60 min after GnRH (nmol/l)	0.07	0.05 – 0.15	0.05	0.05 – 0.05	25.64	15.93 – 45.28	0.05	0.05 – 0.07
Testosterone 90 min after GnRH (nmol/l)	0.09	0.05 – 0.15	0.05	0.05 – 0.06	25.90	16.97 – 43.90	0.06	0.05 – 0.07
Basal estradiol (pmol/l)	17.82	10.76 – 29.85	12.91	8.77 – 16.45	35.94	25.11 – 60.05	11.97	9.21 – 17.64
Estradiol 60 min after GnRH (pmol/l)	27.92	18.25 – 47.65	13.73	7.05 – 19.09	39.80	30.25 – 58.95	10.38	7.92 – 18.25
Estradiol 90 / 120 min after GnRH (pmol/l)	35.10	23.86 – 54.77	14.34	8.30 – 18.72	44.40	23.94 – 62.81	13.57	9.45 – 20.45

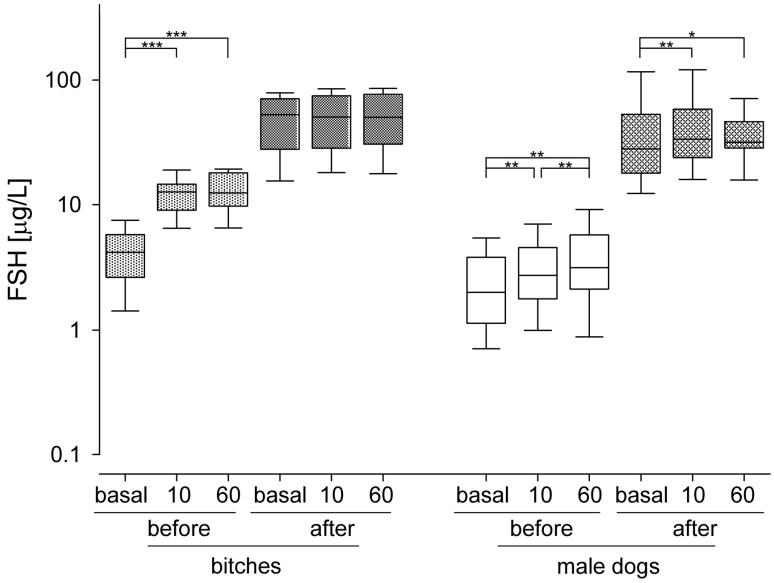

Figure 2. *Plasma FSH concentrations before and at 10 and 60 min after GnRH administration in 14 bitches and 14 male dogs before and after gonadectomy. Mind the logarithmic scale of the y-axis*
*Asterisks denote a significant difference: *: p<0.05; **: p < 0.01; ***: p < 0.001.*

Table 2. *LH to FSH ratios during GnRH-stimulation tests performed before and after gonadectomy in bitches (n=14) and male dogs (n=14).*

	Bitches			
	anestrus		**after gonadectomy**	
	median	**range**	**median**	**range**
LH to FSH Basal	0.23	0.07 – 0.60	0.24	0.16 – 0.39
LH to FSH T=10	1.02	0.48 – 1.57	0.58	0.25 – 1.28
LH to FSH T=60	0.42	0.19 – 0.99	0.27	0.15 – 0.54

	Male dogs			
	before gonadectomy		**after gonadectomy**	
	median	**range**	**median**	**range**
LH to FSH Basal	1.59	0.51 – 3.63	0.27	0.14 – 0.38
LH to FSH T=10	5.42	2.60 – 11.06	0.83	0.35 – 1.77
LH to FSH T=60	5.55	2.30 – 10.37	0.56	0.29 – 1.29

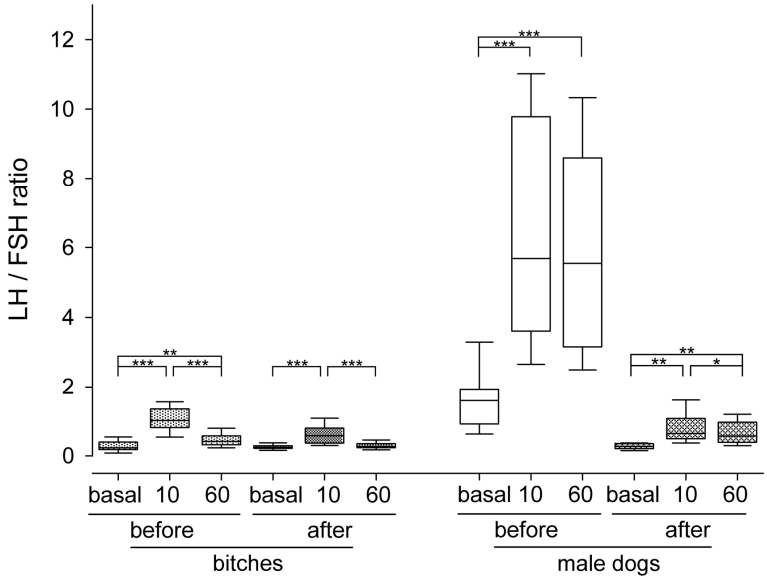

Figure 3. *LH to FSH ratio before and at 10 and 60 min after GnRH administration in 14 bitches and 14 male dogs before and after gonadectomy. Asterisks denote a significant difference: *: p<0.05; **: p < 0.01; ***: p < 0.001.*

There was no overlap at all in basal and GnRH-stimulated plasma testosterone concentrations before and after gonadectomy in male dogs. ROC analysis of the basal plasma testosterone concentration revealed a cut-off value in male dogs of 3.77 nmol/l. In contrast, in bitches basal and GnRH-stimulated plasma testosterone concentrations before and after OVX overlapped, albeit that both basal and GnRH-stimulated concentrations were significantly higher before compared to after OVX. Before gonadectomy, in the male dogs plasma testosterone concentrations increased in all but 2 animals at 60 min post GnRH and in all animals at 90 min post GnRH. In the bitches before gonadectomy, plasma testosterone concentrations had increased in all but 3 animals at 60 min post GnRH and in all but 2 animals at 90 min post GnRH compared to basal values. At 90 min after GnRH administration plasma testosterone concentrations were significantly higher compared to those at 60 min post GnRH in the bitches, but not in the male dogs. After gonadectomy GnRH administration did not result in an increase of the plasma testosterone concentration in both male and female dogs. The basal and GnRH-stimulated plasma testosterone concentrations before gonadectomy were significantly higher ($P < 0.001$) in male dogs compared to anestrous bitches (Fig. 4), with no overlap. ROC analysis of these data revealed cut-off values for the basal, T=60 min and T=90 min measurements of 3.8 nmol/l, 8.04 nmol/l, and 8.56 nmol/l respectively

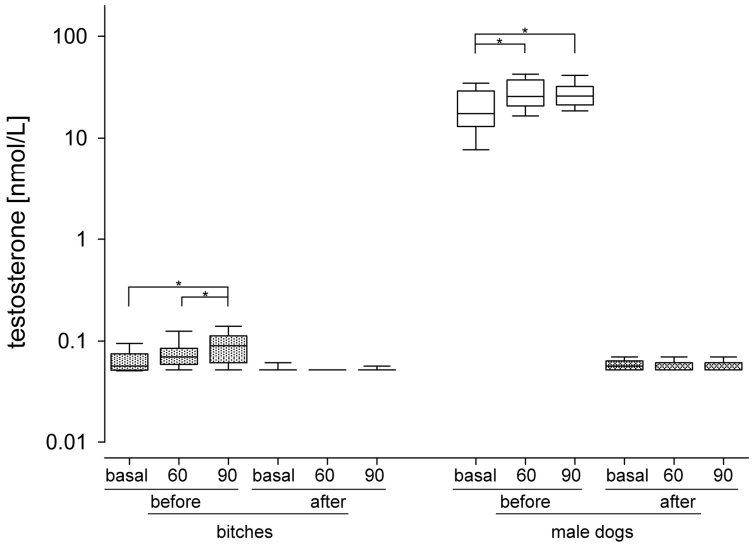

Figure 4. *Plasma testosterone concentrations before and at 60 and 90 min after GnRH administration in 14 bitches and 14 male dogs before and after gonadectomy. Mind logarithmic scale of y-axis.*
*Asterisks denote a significant difference: *: p<0.05; **: p < 0.01; ***: p < 0.001.*

Basal plasma estradiol concentrations in gonadally intact male dogs were significantly higher than those in castrated dogs and did not overlap. ROC analysis of these data revealed a cut-off value of 21.4 pmol/l. Before castration, administration of GnRH resulted in an increase of the plasma estradiol concentrations in 12 of 14 male dogs at 60 and/or 90 min. Taken as a group, however, the median plasma estradiol concentrations did not increase significantly. After castration, the low plasma estradiol concentrations slightly increased in only 8 male dogs at 60 and/or 90 min. The basal plasma estradiol concentrations of anestrous bitches and neutered bitches did not differ significantly. In all bitches before gonadectomy administration of GnRH resulted in increased plasma estradiol concentrations at 60 and 120 min and the plasma estradiol concentrations at 120 min post GnRH were significantly higher than those at 60 min post GnRH (Fig. 5).

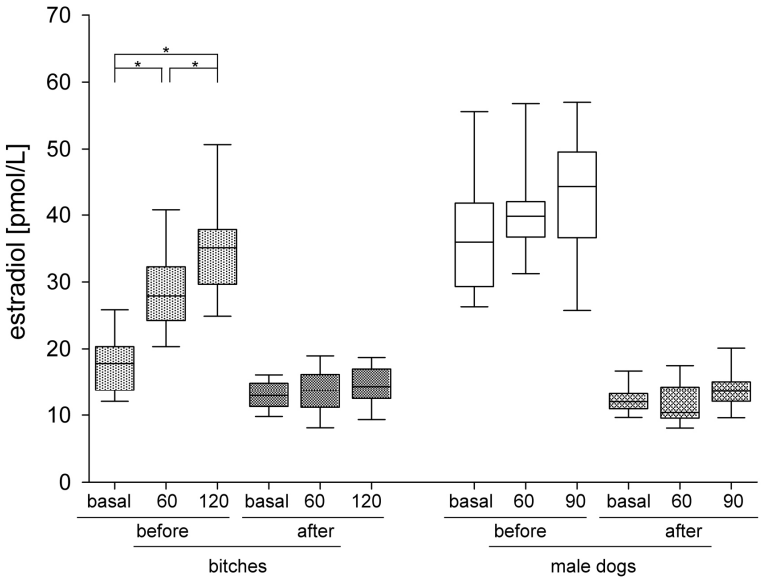

Figure 5. *Plasma estradiol concentrations before and at 60 and 120 min in 14 bitches and at 60 and 90 min in 14 male dogs after GnRH administration before and after gonadectomy.*
*Asterisks denote a significant difference: *: p<0.05; **: p < 0.01; ***: p < 0.001.*

In the bitches after OVX GnRH administration did not cause an increase of plasma estradiol concentrations in 3 bitches at 60 min post GnRH and in 4 bitches at 120 min post GnRH, resulting in insignificant differences between basal values and values after GnRH administration. The plasma estradiol concentrations at both 60 and 120 min after GnRH administration were significantly higher in the bitches before compared to after OVX. There was, however, minimal overlap in the plasma estradiol concentrations at 60 min after GnRH administration between the bitches before and after OVX (range 18.3 – 47.7 pmol/l and range 7.1 – 19.1 pmol/l respectively); in one individual bitch the plasma estradiol concentration at 60 min post GnRH was higher after OVX compared to before gonadectomy. There was no overlap in plasma estradiol concentrations at 120 min post GnRH between both groups (Table 1) and ROC analysis revealed a cut-off value of 21.3 pmol/l. The basal plasma estradiol concentrations before gonadectomy were higher (p<0.001) in male dogs compared to bitches; after gonadectomy these values did not differ significantly.

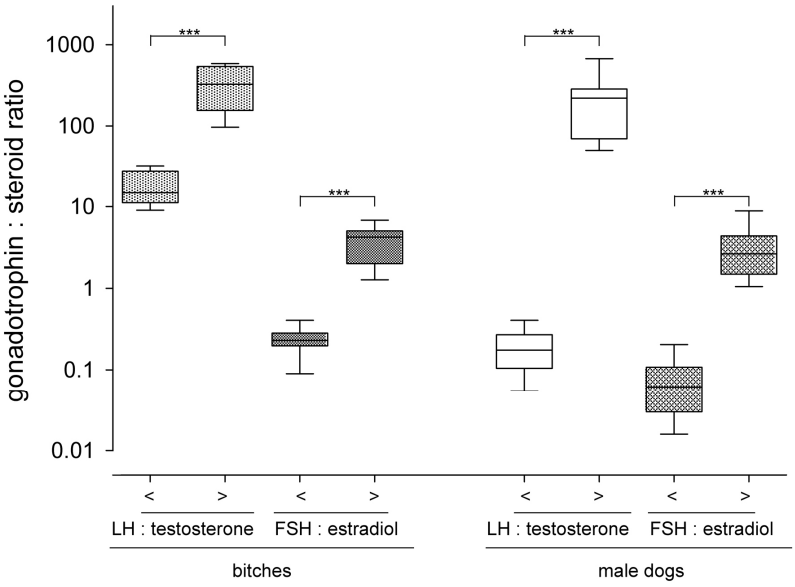

Figure 6. *LH to testosterone and FSH to estradiol ratios, before (<) and after (>) gonadectomy in bitches and male dogs. Mind the logarithmic scale of y-axis. Asterisks denote a significant difference: ***: p < 0.001.*

The basal LH to testosterone ratios of bitches (median 325, range 89 – 587) and male dogs (median 197, range 48 – 309) after gonadectomy were much higher than those in bitches (median 14.8, range 7.9 – 32.7) and male dogs (median 0.21, range 0.05 – 0.49) before gonadectomy and did not overlap. ROC analysis of these data revealed a cut-off value of 61 in bitches and 24 in male dogs. In all intact male dogs the basal LH to testosterone ratios were lower than in castrated male dogs and bitches, irrespective of the presence or absence of functional ovarian tissue (Figure 6). The LH to testosterone ratios in bitches and male dogs after gonadectomy did not differ significantly.

The basal FSH to estradiol ratios of bitches (median 4.22, range 0.84 – 7.03) and male dogs (median 2.63, range 0.96 – 9.69) after gonadectomy were higher than those in bitches (median 0.23, range 0.08 – 0.47) and male dogs (median 0.06, range 0.01 – 0.23) before gonadectomy and did not overlap. ROC analysis of these data revealed a cut-off value of 0.66 in bitches and 0.60 in male dogs. Before, but not after, gonadectomy, basal FSH to estradiol ratios were significantly higher ($p<0.001$) in bitches than those in male dogs.

Discussion

In agreement with previous findings (Chaffaux et al. 1981; Olson et al. 1992; Concannon. 1993; Jeffcoate 1993; Lofstedt and VanLeeuwen. 2002; Reichler et al. 2004; Buijtels et al. 2006; Beijerink et al. 2007), the basal plasma concentrations of both FSH and LH were significantly higher in gonadectomized bitches and male dogs compared to these values before gonadectomy due to the loss of negative feedback of gonadal steroid and protein hormones, who mainly influence the hypothalamus-pituitary-gonadal axis probably via the KiSS-1/gpr-54 system (Chaffaux et al. 1981; Olson et al. 1992; Concannon. 1993; Jeffcoate 1993; Lofstedt and VanLeeuwen. 2002; Reichler et al. 2004; Buijtels et al. 2006; Beijerink et al. 2007; Oakley et al. 2009; Roseweir and Millar 2009; Pineda et al. 2010; Tsutsui et al. 2010). When the basal plasma concentrations of LH and FSH are compared with each other, the basal plasma FSH concentration seems more appropriate to verify the neuter status in dogs. Although in the bitches of the present study there was no overlap in basal plasma LH concentrations before and after OVX, in the male dogs these basal values overlapped substantially before and after castration, which is in agreement with the results of Olson et al. (1992). In contrast, in both bitches and male dogs there was no overlap in basal plasma FSH concentrations before and after gonadectomy. In line with these findings, Beijerink et al. (2007) published that a single plasma FSH concentration can be used to verify the neuter status in bitches. Similarly, in women the basal plasma FSH concentration is more informative regarding ovarian reserve than the basal plasma LH concentration (Toner 1993; Scott and Hofmann 1995; Bulun and Adashi 2003; Genuth 2004).

Reichler et al. (2004) showed that in bitches the elevated basal plasma LH and FSH concentrations after OVX slowly decrease with a nadir at 10 weeks after OVX, after which the basal plasma gonadotropin concentrations rise again. In the present study the interval between gonadectomy and the second GnRH-stimulation test in the bitches ranged between 75-221 days. In line with the observations of Reichler et al. (2004), the neutered bitch which had the lowest basal plasma LH and FSH concentrations underwent OVX only 75 days before the second GnRH-stimulation test. The study of Beijerink et al. (2007), however, was performed in bitches that had been gonadectomized more than one year previous to determination of plasma FSH concentrations. These observations suggest that using the basal plasma FSH concentration as a diagnostic tool for neuter status may be more reliable if the interval between gonadectomy and blood sampling is longer than 6 months.

Our results suggest that basal plasma LH (in bitches) or FSH (in bitches and male dogs) concentrations above their respective cut-off value indicate that the animal has been

gonadectomized. However, the cut-off values in the bitches were based on measurements in the anestrous phase. Higher values of the basal plasma gonadotropin concentration can occur in different phases of the estrous cycle, e.g. during the preovulatory LH and FSH surges. Furthermore, gonadotropins are secreted in a pulsatile fashion (Concannon 1993; Kooistra et al. 1999) and blood sampling during a pulse may result in high LH and FSH values. Indeed, in the present study plasma LH and FSH concentrations after GnRH administration in animals before gonadectomy, which are a measure for the potential height of a gonadotropin pulse, were sometimes higher than basal plasma LH and FSH concentrations after gonadectomy. Consequently, the basal plasma LH and FSH concentrations should be used with caution to differentiate gonadally intact dogs from gonadectomized dogs. In order to diminish the influence of pulsatile hormone secretion we used the mean of two samples collected 40 minutes apart as basal plasma concentration.

In agreement with previous findings, GnRH administration resulted in a clear increase of the plasma LH concentration in both bitches and male dogs, both before and after gonadectomy (Chakraborty and Fletcher 1977; Reimers et al. 1978; Jeffcoate 1993; Knol et al. 1993; Purswell and Wilcke 1993; van Haaften et al. 1994; Buijtels et al. 2006; Beijerink et al. 2007). A significant decrease of the plasma LH concentration 60 min after GnRH administration compared to 10 min post GnRH could however only be noticed in bitches, both before and after OVX. The absence of such a decrease in male dogs is not in agreement with previous studies performed by Knol et al. (1993) and Junaidi et al. (2003). Even when a gonadorelin dosage as high as 100 µg/kg B.W. i.v. was administered to male dogs, a sharp increase in plasma LH concentration at 10 min post GnRH was followed by a decrease at 60 min post GnRH. An explanation could be that we used buserelin in the male dogs and gonadorelin in the bitches, because gonadorelin was not available at the start of data collection in male dogs. In several species it has been demonstrated that buserelin is more potent with regard to LH and FSH release than gonadorelin; 19 times more potent in rats, 20 to 40 times more potent in humans, and more than 50 times more potent in bovines (Sandow et al. 1973; Kuhl et al. 1976; Dericks-Tan et al. 1977; Chenault et al. 1990). Therefore, we administered a 25-fold lower dosage of buserelin compared to gonadorelin in order to correct for the difference in potency. However, the longer plasma half-life of buserelin compared to gonadorelin could be responsible for the prolonged increase of the plasma LH concentration after GnRH administration, rather than a potential biological difference between bitches and male dogs. This is supported by findings of Grootenhuis et al. (1990) who also administered buserelin to male dogs and observed no difference between the plasma LH and FSH concentration at 10 and 60 min after intravenous administration of 0.5 µg/kg B.W. buserelin. In addition, Hoffmann and Schneider (1993) administered buserelin to bitches in the same dose as we used in the

male dogs and found that the peak plasma LH concentration in bitches occurs between 25 and 40 min after administration of buserelin during early anestrus, which is later than the LH peak value after administration of gonadorelin (Purswell and Wilcke. 1993; van Haaften et al. 1994). As a consequence, differences between bitches and male dogs in the present study are only discussed if a biological relevant difference, independent of the type of GnRH that was used, was found.

GnRH administration also resulted in an increase of the plasma FSH concentration in both bitches and male dogs before gonadectomy, but the increment was less than that of the plasma LH concentration. In line with observations of Beijerink et al. (2007), GnRH administration did not at all result in a significant rise of the plasma FSH concentration in bitches after OVX, whereas in male dogs after castration the increase only just reached a significant level. Purswell and Wilcke (1993) reported no stimulation of FSH within the first hour after GnRH administration in intact male dogs, although the dosage of gonadorelin that was used in the latter study was quite low (0.7 µg/kg). The relative lower response to GnRH stimulation of FSH compared to LH may be ascribed to differential regulation of pituitary gonadotropin secretion. The intracellular mechanisms for storage and release are different for LH and FSH. This view is supported by in vitro studies that have shown that although LH and FSH are produced in the same cell type they are stored in different granules (Moyle and Campbell 1995; Ascoli and Puett 2009), and the magnitude of FSH secretion in response to secretagogues is smaller than that of LH (Chowdhury and Steinberger 1975; Muyan et al. 1994).

GnRH-stimulated plasma FSH concentrations declined more slowly than plasma LH concentrations. This can be ascribed to the longer half-life of FSH than LH, which is probably due to differences in the pattern of glycosylation of FSH compared to LH (Schwartz 1995), and consequently the clearance from the circulation of LH is faster than that of FSH (Flack et al. 1994).

Interestingly, the basal plasma LH and FSH concentrations before gonadectomy were respectively lower and higher in bitches compared to male dogs, while after gonadectomy no significant difference in the basal LH and FSH concentration was present between males and females. This finding is reflected in the LH to FSH ratio, which was significantly higher in male dogs before castration compared to the ratios in the other three groups. The fact that the LH to FSH ratio did not differ between gonadectomized female and male dogs suggests a primary role of gonadally produced steroids and proteins in the differential regulation of gonadotropin secretion. The relative high LH to FSH ratio in gonadally intact male dogs may therefore be explained by their relatively high plasma estradiol concentrations compared to those in anestrous bitches and gonadectomized animals. Via negative feedback at the hypothalamus-pituitary axis both estradiol and

inhibin specifically suppress FSH synthesis and secretion (Shupnik 1996; Roseweir and Millar 2009). The relatively high plasma LH concentration in gonadally intact male dogs is more difficult to explain. Kumar et al. (1980) found that the hypothalamus of the gonadally intact male dog contained significantly higher GnRH concentrations compared to those in anestrous bitches, possibly leading to higher basal LH concentrations in intact male dogs. Other important factors in the differential control of gonadotropin secretion are the frequency and amplitude of GnRH pulses. A higher frequency of GnRH results in relatively more LH gene expression as well as LH secretion (Vizcarra et al. 1997; Ferris and Shupnik 2006; Ascoli and Puett 2009). It may be hypothesized that the circulating gonadal hormones in male dogs result in a pulsatile secretion pattern of GnRH that preferentially stimulates LH secretion probably mediated via the KiSS-1/gpr-54 system (Roseweir and Millar 2009).

The basal plasma testosterone concentrations were significantly higher before gonadectomy compared to after gonadectomy in both bitches and male dogs, indicating that the gonads are the main source of circulating testosterone in intact dogs. The amount of testosterone produced by the ovary depends on the phase of the reproductive cycle, and appears to be highest on the day of the preovulatory LH surge (Olson et al. 1984; Concannon and Castracane 1985). In male dogs, the highest stimulated plasma testosterone concentration after gonadectomy at 60 and 90 min after GnRH administration was much lower than the lowest basal plasma testosterone concentration before gonadectomy, indicating that when the basal testosterone concentration is below the cut-off value a male dog can be considered as having no or insufficient functional testicular tissue. Measurement of a single basal plasma testosterone concentration therefore seems reliable to verify the neuter status in males.

GnRH administration resulted in a significant increase in plasma testosterone concentrations in both bitches and male dogs before gonadectomy. For male dogs this has been reported before (Knol et al. 1993; Purswell and Wilcke 1993; Junaidi et al. 2007), but to the best of our knowledge no such data have been reported for bitches. After gonadectomy basal and GnRH-stimulated plasma testosterone concentrations were low, but levels were often still detectable, indicating an extra-gonadal source of the testosterone. Most likely, the circulating testosterone in gonadectomized animals originated from the (reticular zone of the) adrenal cortex.

The basal plasma estradiol concentrations of anestrous bitches and neutered bitches did not differ significantly, indicating that the basal plasma estradiol concentration cannot be used as a tool to differentiate between intact and gonadectomized bitches, as has been described previously (Frank et al. 2003; Buijtels et al. 2006).

In a study of Buijtels et al. (2006) all six anestrous bitches responded with a clear increase in plasma estradiol concentration after GnRH administration whereas all six OVX bitches had undetectable plasma estradiol concentrations after GnRH administration, which led to the conclusion that in bitches the plasma estradiol concentration can only be stimulated significantly when functional ovarian tissue is present. Also in bitches with remnant ovarian tissue after (incomplete) ovariectomy, which frequently have higher basal plasma estradiol concentrations than anestrous bitches, a significant rise in the plasma estradiol concentration after GnRH administration could be noticed (Buijtels et al. 2010). However, in the present study the low plasma estradiol concentration also slightly increased after GnRH administration in several of the ovariectomized bitches, indicating that a GnRH-induced increase in plasma estradiol concentration is not a prove for the presence of functional ovarian tissue. Our results show however that at 120 min after GnRH administration plasma estradiol concentrations in intact bitches did not overlap anymore with those in ovariectomized bitches, indicating that GnRH-induced plasma estradiol concentrations at this time point can be used to discriminate between bitches with and without functional ovarian tissue. The detectable plasma estradiol concentrations in the OVX bitches may be explained by conversion of androstenedione, produced in the adrenal cortex, into estradiol. In addition, estradiol can also be produced from aromatization in fat, hair follicles, and the liver (Nelson and Bulun.2001).

In male dogs basal plasma estradiol concentrations did not overlap when gonadally intact and castrated animals were compared. Surprisingly, before castration GnRH administration did not result in a significant increase of the plasma estradiol concentrations, although in most dogs the plasma estradiol concentrations were higher post GnRH and the P-value of 0.08 indicated a tendency to increase. A possible explanation for the lack of a significant increase after GnRH-administration in gonadally intact male dogs could be that estradiol is aromatized from testosterone, which may have caused a slower increase in estradiol concentrations after GnRH-administration compared to bitches. Furthermore, the longest interval from GnRH administration to measurement of the plasma estradiol concentration in the male dogs in this study was 90 min, compared to 120 min in bitches, and at 90 min post GnRH the highest plasma estradiol concentration might not yet have been reached. When a larger number of male dogs was used, a significant increase of the plasma estradiol concentration after GnRH administration was present (unpublished data), which further strengthens the hypothesis that GnRH administration in gonadally intact male dogs does result in increased plasma estradiol concentrations

To diagnose endocrine disturbances often dynamic tests are used, such as the ACTH-stimulation test to diagnose Addison's disease and the TSH-stimulation test to diagnose hypothyroidism (Rijnberk and Kooistra 2010). The results of the present study

demonstrate that the GnRH-stimulation test can be used to differentiate animals with functional gonadal tissue and animals after gonadectomy. However, it would be easier if this differentiation could be based on measurements in a single basal blood sample. The basal plasma LH and FSH concentrations should however be used with caution to differentiate gonadally intact dogs from gonadectomized dogs. The solution may be in the measurement of endogenous hormone pairs in a single blood sample, such as the cortisol to adrenocorticotropin hormone ratio in the diagnosis of Addison's disease (Javadi et al. 2006) and the aldosterone to renin ratio in the diagnosis of primary hyperaldosteronism (Javadi et al. 2005). Taking into account the opposite directions in which the circulating gonadotropin and steroid hormone concentrations move after gonadectomy, the results of the present study demonstrate that the LH to testosterone and FSH to estradiol ratios allow differentiation between gonadally intact dogs from gonadectomized dogs by using only a single blood sample. Moreover, the LH to testosterone and FSH to estradiol ratios had the highest discriminatory power in differentiating gonadally intact from gonadectomized dogs.

Acknowledgements

The authors would like to acknowledge Mr. H.G.H. van Engelen and Miss L.A. Kramer for their assistance in performing the experiments. The critical reading of the manuscript by Dr. B.E. Belshaw is highly appreciated.

References

Ascoli M, Puett D. The Gonadotropin Hormones and Their Receptors. In: Reproductive Endocrinology, Strauss JF, Barbieri RL (Eds). Saunders Elsevier, Philadelphia, 2009, pp. 35-55.

Beijerink NJ, Buijtels JJCWM, Okkens AC, Kooistra HS, Dieleman SJ. Basal and GnRH-induced secretion of FSH and LH in anestrous versus ovariectomized bitches. Theriogenology 2007;67:1039-1045.

Buijtels JJCWM, Beijerink NJ, Kooistra HS, Dieleman SJ, Okkens AC. Effects of gonadotropin releasing hormone administration on the pituitary-ovarian axis in anoestrous vs ovariectomized bitches. Reprod Domest Anim 2006;41:555-561.

Buijtels JJCWM, de Gier J, Kooistra HS, Naan EC, Oei CH, Okkens AC. The pituitary-ovarian axis in dogs with remnant ovarian tissue. Theriogenology 2010.

Bulun SE, Adashi EY. The physiology and pathology of the female reproductive axis, Larsen PR, Kronenberg HM, Melmed S, Polonsky KS (Eds). Saunders, Philadelphia, 2003, pp. 587-664.

Chaffaux S, Chassagnite F, Thibier M. Concentration of LH après stimulation par la gonadoliberine (LRH) chez la chienne et affet de l'ovariectomie. Rec Med Vet 1981;10:725-733.

Chakraborty PK, Fletcher WS. Responsiveness of anestrous Labrador bitches to GnRH. Proc Soc Exp Biol Med 1977;154:125-126.

Chenault JR, Kratzer DD, Rzepkowski RA, Goodwin MC. LH and FSH response of Holstein heifers to fertirelin acetate, gonadorelin and buserelin. Theriogenology 1990;34:81-98.

Chowdhury M, Steinberger E. Biosynthesis of gonadotrophins by rat pituitaries in vitro. J Endocrinol 1975;66:369-374.

Concannon PW, Castracane VD. Serum androstenedione and testosterone concentrations during pregnancy and nonpregnant cycles in dogs. Biol Reprod 1985;33:1078-1083.

Concannon PW. Biology of gonadotropin secretion in adult and prepubertal female dogs. J Reprod Fertil Suppl 1993;47:3-27.

De Gier J, Kooistra HS, Djajadiningrat-Laanen SC, Dieleman SJ, Okkens AC. Temporal relations between plasma concentrations of luteinizing hormone, follicle-stimulating hormone, estradiol-17beta, progesterone, prolactin, and alpha-melanocyte-stimulating hormone during the follicular, ovulatory, and early luteal phase in the bitch. Theriogenology 2006;65:1346-1359.

DePalatis L, Moore J, Falvo RE. Plasma concentrations of testosterone and LH in the male dog. J Reprod Fertil 1978;52:201-207.

Dericks-Tan JS, Hammer E, Taubert HD. The effect of D-ser (TBU)6-LH-RH-EA10 upon gonadotropin release in normally cyclic women. J Clin Endocrinol Metab 1977;45:597-600.

Dieleman SJ, Bevers MM. Effects of monoclonal antibody against PMSG administered shortly after the preovulatory LH surge on time and number of ovulations in PMSG/PG-treated cows. J Reprod Fertil 1987;81:533-542.

Falvo RE, Gerrity M, Pirmann J, Winter M, Vincent DL, Miller J. Testosterone pretreatment and the response of pituitary LH to Gonadotropin-releasing hormone (GnRH) in the male dog. J Androl 1982;3:193-198.

Ferris HA, Shupnik MA. Mechanisms for pulsatile regulation of the gonadotropin subunit genes by GNRH1. Biol Reprod 2006;74:993-998.

Flack MR, Bennet AP, Froehlich J, Anasti JN, Nisula BC. Increased biological activity due to basic isoforms in recombinant human follicle-stimulating hormone produced in a human cell line. J Clin Endocrinol Metab 1994;79:756-760.

Frank LA, Rohrbach BW, Bailey EM, West JR, Oliver JW. Steroid hormone concentration profiles in healthy intact and neutered dogs before and after cosyntropin administration. Domest Anim Endocrinol 2003;24:43-57.

Genuth SM. The hypothalamus and pituitary gland. In: Physiology. Berne RM, Levy MN, Koeppen BM, Stanton BA (Eds). Mosby, St. Louis, 2004, pp. 819-859.

Goericke-Pesch S, Wilhelm E, Ludwig C, Desmoulins PO, Driancourt MA, Hoffmann B. Evaluation of the clinical efficacy of Gonazon implants in the treatment of reproductive pathologies, behavioral problems, and suppression of reproductive function in the male dog. Theriogenology 2010;73:920-6.

Grootenhuis AJ, van Sluijs FJ, Klaij IA, Steenbergen J, Timmerman MA, Bevers MM, Dieleman SJ, de Jong FH. Inhibin, gonadotrophins and sex steroids in dogs with Sertoli cell tumours. J Endocrinol 1990;127:235-242.

Hoffmann B, Schneider S. Secretion and release of luteinizing hormone during the luteal phase of the oestrous cycle in the dog. J Reprod Fertil Suppl 1993;47:85-91.

Javadi S, Djajadiningrat-Laanen SC, Kooistra HS, van Dongen AM, Voorhout G, van Sluijs FJ, van den Ingh TS, Boer WH, Rijnberk A. Primary hyperaldosteronism, a mediator of progressive renal disease in cats. Domest Anim Endocrinol 2005;28:85-104.

Javadi S, Galac S, Boer P, Robben JH, Teske E, Kooistra HS. Aldosterone-to-renin and cortisol-to-adrenocorticotropic hormone ratios in healthy dogs and dogs with primary hypoadrenocorticism. J Vet Intern Med 2006;20:556-61.
Jeffcoate IA. Gonadotrophin-releasing hormone challenge to test for the presence of ovaries in the bitch. J Reprod Fertil Suppl 1993;47:536-538.
Johnston SD. Premature gonadal failure in female dogs and cats. J Reprod Fertil Suppl 1989;39:65-72.
Junaidi A, Williamson PE, Cummins JM, Martin GB, Blackberry MA, Trigg TE. Use of a new drug delivery formulation of the gonadotrophin-releasing hormone analogue Deslorelin for reversible long-term contraception in male dogs. Reprod Fertil Dev 2003;15:317-322.
Junaidi A, Williamson PE, Martin GB, Stanton PG, Blackberry MA, Cummins JM, Trigg TE. Pituitary and testicular endocrine responses to exogenous gonadotropin-releasing hormone (GnRH) and luteinising hormone in male dogs treated with GnRH agonist implants. Reprod Fertil Dev 2007;19:891-898.
Knol BW, Dieleman SJ, Bevers MM, van den Brom WE. GnRH in the male dog: dose-response relationships with LH and testosterone. J Reprod Fertil 1993;98:159-161.
Kooistra HS, Okkens AC, Bevers MM, Popp-Snijders C, van Haaften B, Dieleman SJ, Schoemaker J. Concurrent pulsatile secretion of luteinizing hormone and follicle-stimulating hormone during different phases of the estrous cycle and anestrus in beagle bitches. Biol Reprod 1999;60:65-71.
Kuhl H, Kaplan HG, Taubert HD. Effects of a new analogue of LH-RH, D-Ser(TBU)6- EA10-LH-RH, on gonadotropin liberation in males (author's transl). Dtsch Med Wochenschr 1976;101:361-364.
Kumar MS, Chen CL, Kalra SP. Distribution of luteinizing hormone releasing hormone in the canine hypothalamus: effect of castration and exogenous gonadal steroids. Am J Vet Res 1980;41:1304-1309.
Lacoste D, St-Arnaud R, Belanger A, Labrie F. A pure antiandrogen does not interfere with the LHRH agonist-induced blockade of testicular androgen secretion in the dog. Mol Cell Endocrinol 1988;56:141-147.
Löfstedt RM, VanLeeuwen JA. Evaluation of a commercially available luteinizing hormone test for its ability to distinguish between ovariectomized and sexually intact bitches. J Am Vet Med Assoc 2002;220:1331-1335.
Moyle WR, Campbell RK. Gonadotropins. In: Reproductive Endocrinology, Surgery and Technology. Adashi EY, Rock JA, Rosenwaks Z (Eds). Lippincott-Raven Publishers, Philadelphia, 1995, pp. 683-724.
Muyan M, Ryzmkiewicz DM, Boime I. Secretion of lutropin and follitropin from transfected GH3 cells: evidence for separate secretory pathways. Mol Endocrinol 1994;8:1789-1797.
Neilson JC, Eckstein RA, Hart BL. Effects of castration on problem behaviors in male dogs with reference to age and duration of behavior. J Am Vet Med Assoc 1997;211:180-182.
Nelson LR and Bulun SE. Estrogen production and action. J Am Acad Dermatol 2001;45:116-124.
Nett TM, Akbar AM, Phemister RD, Holst PA, Reichert LE, Niswender GD. Levels of luteinizing hormone, estradiol and progesterone in serum during the estrous cycle and pregnancy in the Beagle bitch. Soc Exptl Biol Med 1975;148:134-139.
Nickel RF, Okkens AC, van der Gaag I, van Haaften B. Oophoritis in a dog with abnormal corpus luteum function. Vet Rec 1991;128:333-334.
Oakley AE, Clifton DK, Steiner RA. Kisspeptin signaling in the brain. Endocr Rev 2009;30:713-743.
Okkens AC, Dieleman SJ, v.d. Gaag I. Gynaecological complications following ovariohysterectomy in dogs, due to: (1) partial removal of the ovary (2) inflammation of the uterocervical stump. Tijdschr Diergeneeskd 1981;106:1142-1158.
Okkens AC, Teunissen JM, Van Osch W, Van Den Brom WE, Dieleman SJ, Kooistra HS. Influence of litter size and breed on the duration of gestation in dogs. J Reprod Fertil Suppl 2001;57:193-197.
Olson PN, Bowen RA, Behrendt MD, Olson JD, Nett TM. Concentrations of reproductive hormones in canine serum throughout late anestrus, proestrus and estrus. Biol Reprod 1982;27:1196-1206.
Olson PN, Bowen RA, Behrendt MD, Olson JD, Nett TM. Concentrations of testosterone in canine serum during late anestrus, proestrus, estrus, and early diestrus. Am J Vet Res 1984;45:145-148.
Olson PN, Mulnix JA, Nett TM. Concentrations of luteinizing hormone and follicle-stimulating hormone in the serum of sexually intact and neutered dogs. Am J Vet Res 1992;53:762-766.
Pineda R, Garcia-Galiano D, Sanchez-Garrido MA, Romero M, Ruiz-Pino F, Aguilar E, Dijcks FA, Blomenrohr M, Pinilla L, van Noort PI, Tena-Sempere M. Characterization of the inhibitory roles of RFRP3, the mammalian ortholog of GnIH, in the control of gonadotropin secretion in the rat: in vivo and in vitro studies. Am J Physiol Endocrinol Metab 2010;299:39-46.
Purswell BJ, Wilcke JR. Response to gonadotrophin-releasing hormone by the intact male dog: serum testosterone, luteinizing hormone and follicle-stimulating hormone. J Reprod Fertil Suppl 1993;47:335-341.
Reichler IM, Pfeiffer E, Piche CA, Jochle W, Roos M, Hubler M, Arnold S. Changes in plasma gonadotropin concentrations and urethral closure pressure in the bitch during the 12 months following ovariectomy. Theriogenology 2004;62:1391-1402.

Reimers TJ, Phemister RD, Niswender GD. Radioimmunological measurement of follicle stimulating hormone and prolactin in the dog. Biol Reprod 1978;19:673-679.
Rijnberk A and Kooistra HS. Protocols for Function Tests. In: Clinical Endocrinology of Dogs and Cats. Rijnberk A, Kooistra HS (Eds). Schlütersche, Hannover, 2010, pp. 305-314.
Roseweir AK, Millar RP. The role of kisspeptin in the control of gonadotropin secretion. Hum Reprod Update 2009;15:203-212.
Sandow J, Rechenberg WV, Konig W, Hahn M, Jerzabek G, Fraser H. Physiological studies with highly active analogs of LH-RH. In: Hypothalamic Hormones - Chemistry, Physiology and Clinical Applications. Gupta D, Voelter W (Eds). Exerpta Medica, Amsterdam, 1973, pp. 307-326.
Schaefers-Okkens AC. Estrous cycle and breeding management of the healthy bitch. In: Textbook of Veterinary Internal Medicine. Ettinger SJ, Feldman EC (Eds). Saunders Elsevier, Missouri, 2010, pp. 1873-1883.
Schaefers-Okkens AC, Kooistra HS. Ovaries. In: Clinical Endocrinology of Dogs and Cats, Rijnberk A, Kooistra HS (Eds). Schlütersche, Hannover, 2010, pp. 203-234.
Schwartz NB. The 1994 Stevenson Award Lecture. Follicle-stimulating hormone and luteinizing hormone: a tale of two gonadotropins. Can J Physiol Pharmacol 1995;73:675-84.
Scott RT, Hofmann GE. Prognostic assessment of ovarian reserve. Fertil Steril 1995;63:1-11.
Shille VM, Olson PN. Dynamic testing in reproductive endocrinology. In: Current Veterinary Therapy X, Kirk RW (Ed). WB Saunders, Philadelphia, 1989, pp. 1282-1288.
Shupnik MA. Gonadal hormone feedback on pituitary gonadotropin genes. Trends in endocrinology & metabolism 1996;7:272-276.
Toner JP. The significance of elevated FSH for reproductive function. Baillieres Clin Obstet Gynaecol 1993;7:283-295.
Tsutsui K, Bentley GE, Kriegsfeld LJ, Osugi T, Seong JY, Vaudry H. Discovery and evolutionary history of gonadotrophin-inhibitory hormone and kisspeptin: new key neuropeptides controlling reproduction. J Neuroendocrinol 2010;22:716-727.
Van Haaften B, Bevers MM, van den Brom WE, Okkens AC, van Sluijs FJ, Willemse AH, Dieleman SJ. Increasing sensitivity of the pituitary to GnRH from early to late anoestrus in the beagle bitch. J Reprod Fertil 1994;101:221-225.
Vizcarra JA, Wettemann RP, Braden TD, Turzillo AM, Nett TM. Effect of gonadotropin-releasing hormone (GnRH) pulse frequency on serum and pituitary concentrations of luteinizing hormone and follicle-stimulating hormone, GnRH receptors, and messenger ribonucleic acid for gonadotropin subunits in cows. Endocrinology 1997;138:594-601.

Chapter 10

Summarizing discussion and conclusions

The reproductive cycle of the bitch is regulated by the hormonal activity of the hypothalamic-pituitary-ovarian axis. The gonadotroph cells in the anterior lobe of the pituitary gland produce and secrete follicle-stimulating hormone (FSH) and luteinizing hormone (LH) in a pulsatile fashion. Each pulse of FSH and LH is induced by a pulse of the hypothalamic peptide gonadotropin-releasing hormone (GnRH). Although both FSH and LH are produced in the same cell, differential regulation of FSH and LH has been reported in the bitch (Kooistra et al. 1999; De Gier et al. 2006). The granulosa, theca and luteal cells in the ovary are capable of secreting hormones, such as estradiol, testosterone and progesterone, in response to LH and FSH. The ovarian hormones exhibit a feedback mechanism on the hypothalamic-pituitary axis, thereby influencing the secretion of LH and FSH. The type and amount of gonadal hormones released vary according to the stage of the estrous cycle and anestrus (Schaefers-Okkens and Kooistra 2010).

The bitch is a nonseasonal, mono-estrous animal in which the estrous cycle can be classified according to both behavior and ovarian function. The behavior-oriented classification distinguishes proestrus, estrus, and metestrus (diestrus). The classification based on ovarian function distinguishes the follicular phase, the preovulatory luteinization and ovulation phase, the luteal phase and the anestrus (Schaefers-Okkens and Kooistra 2010).

In the general introduction of this thesis (**Chapter 2**) an overview is given of current knowledge concerning 1) the pituitary-ovarian axis, with a focus on the effects of ovariectomy on the function of this axis, and 2) some of the main gynecological abnormalities with a potential to influence the pituitary-ovarian axis in the bitch.

Estrus can be prevented medically or surgically. The surgical option, ovariectomy (OVX), has the advantages of decreasing the risk for mammary cancer and preventing the development of disorders such as pyometra and progesterone-induced growth hormone excess. Although side effects may occur most dog owners consider the procedure to be the method of choice for estrus prevention. The certainty of whether or not OVX has been performed in a bitch can be unclear if for instance, the animal has had previous owners or has been acquired from a shelter. Furthermore, some ovarian tissue may remain after surgery and the presence of remnant ovarian tissue can be a challenge. Proving the presence of ovarian tissue in bitches is especially challenging during anestrus. The use of GnRH in a provocation test of the pituitary-ovarian axis as a means to distinguish between bitches with or without ovarian tissue has been suggested in the literature. Therefore, in **Chapter 3** the basal and GnRH-stimulated plasma concentrations of LH, estradiol, progesterone and testosterone are compared in six anestrous and six OVX bitches. The data presented in the study show that the mean basal plasma LH concentrations were significantly higher in OVX bitches than in anestrous bitches and that there was no overlap

between the two groups. The higher basal plasma LH concentrations in the OVX dogs are in agreement with previous studies (Chaffaux et al. 1981; Olson et al. 1992; Concannon 1993; Jeffcoate 1993; Löfstedt and Vanleeuwen 2002; Reichler et al. 2004) and can be ascribed to the loss of the negative feedback mechanism of the ovarian hormones. However, taking into account the pulsatile nature of LH release (Concannon 1993; Kooistra et al. 1999), overlapping of plasma LH concentrations between larger groups of intact and OVX bitches may be expected. Moreover, this overlap was indeed shown by Löfstedt and Vanleeuwen (2002). In addition, there was overlap in the basal plasma LH concentrations in the OVX bitches when compared with the GnRH-induced plasma LH concentrations in anestrous bitches. Consequently, the presence or absence of ovarian tissue cannot be based solely upon the results of a single basal plasma LH measurement.

The basal plasma estradiol concentration was below the detection limit of the assay in all OVX dogs and 5 of the 6 anestrous dogs. There was, however, a significant increase in plasma estradiol concentration following GnRH administration in all anestrous bitches but in none of the OVX bitches. This led to the conclusion that in bitches GnRH administration causes a significant rise in the plasma estradiol concentration only if ovarian tissue is present. In other words, the results of the study presented in **Chapter 3** suggest that the plasma estradiol response to an adequate dose of GnRH (Fertagyl®; 10 µg/kg) may be a useful test to distinguish bitches with and without ovarian tissue. The plasma progesterone concentration and the plasma testosterone concentrations before and after GnRH stimulation played no role in distinguishing between OVX and anestrous bitches.

Research in women revealed that plasma FSH concentrations are more reliable than plasma LH concentrations in distinguishing inactive or removed ovaries from functional ovaries and therefore the study described in **Chapter 4** compared the basal and GnRH-induced plasma concentrations of FSH and LH in four OVX bitches with four in anestrus. The loss of ovarian feedback after OVX resulted in increased plasma concentrations of FSH and LH in all OVX bitches, as has been reported earlier (Chaffaux et al. 1981; Olson et al. 1992; Concannon 1993; Jeffcoate 1993; Löfstedt and Vanleeuwen 2002; Reichler et al. 2004). In the OVX bitches, GnRH elicited a significant response in the plasma LH concentration only. Since there was no significant rise in plasma FSH concentration, it can be concluded that the pituitary response to GnRH in OVX bitches differs from that in anestrous bitches. It may be hypothesized that this is the consequence of different intracellular mechanisms for storage and release for FSH and LH. This view is supported by in vitro studies with pituitary cells of other mammalian species, which have shown that although FSH and LH are produced in the same cell type, they are stored in different secretory granules (Moyle and Campbell 1995), newly synthesized FSH is secreted at a

greater rate than LH (Chowdhury and Steinberger 1975), and that the magnitude of the FSH response to secretagogues is less than that of LH (Chowdhury and Steinberger 1975; Muyan et al. 1994).

Overlap was observed in the basal plasma LH concentrations in the OVX bitches compared with the GnRH-induced plasma LH concentrations in anestrous bitches, again indicating that a single plasma LH concentration is not reliable for differentiation between OVX bitches and anestrous bitches. In contrast, the results reported in Chapter 4 indicate that a single measurement of the plasma FSH concentration, determined by a FSH IRMA released in 2006 may well prove reliable the neutered status. Even after GnRH administration, the maximum plasma FSH level in the intact anestrous bitches did not exceed the lowest plasma FSH level during the entire GnRH-stimulation test in the OVX bitches. Other investigators have also suggested that the pituitary capacity to secrete FSH in the absence of ovarian negative feedback is far greater than what is observed in the intact bitch (Olson et al. 1992; Concannon 1993). Also in women, the plasma FSH level usually increases more than does the plasma LH level when the ovaries are functionally inactive or surgically removed (Bulun and Adashi 2003; Genuth 2004). This indicates that differences in circulating FSH concentration between intact and OVX bitches could be greater than within-group variability.

Taken together, the results of the studies described in Chapters 3 and 4 provide a basis for the verification of the neutered status of the bitch, although additional studies with larger numbers of bitches and different dog breeds are warranted, especially to investigate the potential of a single plasma FSH concentration as a diagnostic marker of the neutered status.

Disorders affecting the ovary can be congenital or acquired of which remnant ovarian tissue and hormone-producing tumors are seen most common in referring institutions as are disorders in sexual development. There is only a limited knowledge about the pituitary-ovarian axis in bitches with these ovarian abnormalities.

Remnant ovarian tissue (ROT) is due to the incomplete surgical removal of one or both ovaries. Bitches with ROT present with periodic or continuous signs of estrus at highly variable intervals after OVX. As with dogs not showing estrus behavior with unknown reproductive status, the diagnostic challenge is to differentiate asymptomatic bitches with ROT from bitches in anestrus. The usefulness of a GnRH-stimulation test in distinguishing anestrous bitches from bitches with ROT is described in **Chapter 5**. The GnRH-stimulation test is evaluated in 18 bitches with ROT and the results are compared to the results of the six anestrous and six OVX bitches described in Chapter 3.

Bitches in this study with ROT were all relatively large, presuming a higher risk for ROT in dogs with a greater body weight as suggested previously by Okkens et al. (1981).

Ultrasonography and macroscopic inspection of the ovarian stump during laparoscopy was not reliable for predicting the presence or absence of ovarian tissue, because both resulted in both false positive and false negative findings compared to histopathology findings. Therefore, if there is any suspicion of ROT at one of the sites both ovarian pedicles, including granulation tissue, need to be removed during surgery to remove ROT.

Despite significantly higher plasma estradiol concentrations in the bitches with ROT compared to those in anestrous bitches, the basal LH concentration was higher than that in anestrous bitches. The higher plasma LH concentration in bitches with ROT than in bitches in anestrus may indicate a diminished sensitivity to the negative feedback of ovarian hormones, due to changes in the hypothalamic-pituitary axis induced by partial removal of the ovaries and disruption of the blood supply to the ovarian remnants. Pituitary cells can adapt to functional demands for chronic hypersecretion of a specific trophic hormone by multiplication of the corresponding hormone-producing cells. The adenohypophyseal changes associated with insufficient secretion of a peripheral hormone have been studied in experimental and clinical hypothyroidism. In primary hypothyroidism, multiplication of thyrotrophs provides more cells producing thyroid-stimulating hormone (TSH) (Vidal et al. 2000), which can result in pituitary enlargement (Sarlis et al. 1997; Joshi and Woolf 2005; Diaz-Espineira et al. 2008). This leads to increased pituitary secretion of TSH, a glycoprotein with many similarities to the gonadotropins. In dogs with primary hypothyroidism, one of the pituitary changes is loss of negative feedback response to thyroid hormones, resulting in a decrease in plasma TSH concentration over time (Diaz-Espineira et al. 2008). Similar changes may have occurred in some of the bitches with ROT, i.e. non-functional c.q. inactive remnant ovarian tissue for a long period could have resulted in a dramatic decrease in ovarian hormone feedback to the hypothalamic-pituitary axis, leading to multiplication of gonadotrophs. These may have lost some of the characteristics of normal gonadotrophs, such as sensitivity to negative feedback from ovarian hormones. When the ROT begins to produce increased amounts of ovarian hormones, these might not suppress LH secretion to levels normally observed in bitches in anestrus. As a consequence, basal plasma LH concentration was significantly higher, despite high circulating estradiol concentrations. This hypothesis is strengthened by the finding that basal plasma LH concentration was higher in bitches in which estrus symptoms appeared for the first time more than 3 years after incomplete OVX.

Plasma LH concentrations were significantly increased at both 10 and 60 min after administration of GnRH in bitches with ROT, as they are in intact anestrous bitches (Van Haaften et al. 1994; Okkens et al. 2001), but the increase at 10 min was significantly lower than in healthy bitches in anestrus. This indicates that GnRH stimulation of LH secretion

has been altered in bitches with ROT, possibly by the multiplication or alteration of gonadotrophs, which may have lost some characteristics during the period when ROT was not secreting excessive amounts of ovarian hormones. A similar subnormal LH response to GnRH has been described in bitches with a granulosa cell tumor (Chapter 6). The response to GnRH may simply be delayed, so that the maximum LH concentration occurs later than 10 min after GnRH administration. That the decrease in plasma LH concentration was relatively limited from 10 to 60 min after GnRH administration supports this theory.

The basal plasma estradiol concentration was detectable in 17 of 18 bitches with ROT, whereas it was not detectable in any of the six OVX bitches. In all bitches with ROT plasma estradiol concentration was detectable at 120 min after stimulation with GnRH, whereas it was not detectable in any of the six OVX bitches. Axnér et al. (2008) used the circulating estradiol concentration after stimulation by GnRH to detect the presence of ovarian tissue in cats. There was no overlap in estradiol values between anestrous and ovariectomized queens and a significant stimulation by GnRH was only observed if ovarian tissue was present. Scott et al. (1995) performed a GnRH-stimulation test in women with ROT and found that an increase in circulating estradiol concentration confirmed the presence of functional ovarian tissue. Our findings suggest that the plasma estradiol response to GnRH stimulation can be used to detect bitches with ROT, although additional studies are required to determine the specificity and the sensitivity of the GnRH-stimulation test for this purpose.

The increase in plasma estradiol concentration at 60 and 120 min after GnRH administration was significantly lower in bitches with ROT than in those in anestrus. Additionally, in four bitches there was a decrease of the plasma estradiol concentration 60 min after administration of GnRH. This could be related to the cystic changes in the ROT found in eight of the bitches and/or abnormal vascularization of ROT, but it could also be a physiological response in the follicular phase, about which no data are available.

Taken together, the results of the study described in Chapter 5 demonstrate that in dogs ROT is associated with noticeable changes in function of the pituitary-ovarian axis and suggest that a GnRH-stimulation test may be used to distinguish between completely ovariectomized bitches and those with ROT.

Granulosa cell tumors (GCTs) are the most frequently encountered hormone-producing ovarian tumors in middle-aged and older dogs (Cotchin and Marchant 1977; Herron 1983; Patnaik and Greenlee 1987; Klein 2001). There is general lack of information about the effect of a GCT on the function of the pituitary-ovarian axis. In **Chapter 6** the results of a GnRH-stimulation test in seven dogs with GCT are reported. These dogs were referred because of signs of persistent estrus and the results of the

stimulation test are compared with the results of the six anestrous bitches and six OVX bitches described in Chapter 3. Three of the dogs with a GCT were intact females (GCT-intact). In the other four dogs the GCT developed in remnant ovarian tissue after incomplete OVX (GCT-ROT). Consistent with the signs of persistent estrus, basal plasma estradiol concentrations in both the GCT-intact bitches and the GCT-ROT bitches were significantly higher than those in the anestrous bitches.

Despite these high plasma estradiol concentrations the plasma LH concentrations in the bitches with GCT tended to be higher than those in the anestrous bitches. This tendency for the entire group was mainly due to the significantly higher plasma LH concentrations in the GCT-ROT bitches. Due to the negative feedback of estradiol on the hypothalamic-pituitary axis a lower plasma LH concentration could be expected in the GCT-ROT bitches as it was expected in the ROT bitches. The relatively high plasma LH concentrations in the GCT-ROT bitches may also indicate a loss of sensitivity to the negative feedback of estradiol due to changes in the hypothalamic-pituitary axis induced by the partial removal of the ovaries and the disruption of the vascularization of the remnant ovarian tissue, as discussed above.

Another explanation for the increased basal plasma LH concentration in the bitches with a GCT could be a positive feedback of estradiol-17β on the release of LH, comparable to the LH release in the bitch during the late-follicular phase (De Gier et al. 2006). However, the time window for estrogens to act via a positive feedback effect on LH secretion is small. It is therefore very questionable if higher basal plasma estradiol-17β concentrations can explain the high LH concentrations in the GCT bitches.

In four of the seven bitches with GCT, the tumor developed in remnant ovarian tissue (2 to 10.5 years after incomplete ovari(ohyster)ectomy). Pluhar et al. (1995) and Sivacolundhu et al. (2001) also described three bitches with ROT which developed GCT. The interval between neutering and referral was also long in these three bitches. Three of our four GCT-ROT bitches did not show estrus symptoms for several years, indicating low plasma estradiol concentration and consequently elevated plasma gonadotropin concentration. It may be hypothesized that the elevated plasma gonadotropin concentration played a role in tumorigenesis. In women, exposure to high gonadotropin levels, such as after menopause or due to infertility treatments, is proposed to be a risk factor for developing ovarian tumors (Konishi et al. 1999; Unkila-Kallio et al. 2000; Ness et al. 2002). Also, patients with polycystic ovary syndrome, which is associated with hypersecretion of LH, have an increased risk of developing ovarian cancer (Schildkraut et al. 1996). Moreover, circumstances that reduce circulating gonadotropin levels, such as oral contraceptives (Bosetti et al. 2002), breast feeding, and estrogen replacement therapy (La Vecchia 2001), reduce the risk of developing ovarian cancer. In rodents GCTs can be

induced by exogenous gonadotropins (Tennent et al. 1990). Furthermore, development of GCT has been reported in transgenic mice with chronic LH hypersecretion (Risma et al. 1995; Keri et al. 2000). The long exposure of (remnant) ovarian tissue to high circulating gonadotropin levels may therefore explain why these dogs are more prone to develop an ovarian tumor than intact dogs.

As has been reported in intact healthy bitches (Van Haaften et al. 1994; Chaffaux et al. 1981; Meij et al. 1996), the plasma LH concentration could be stimulated by GnRH in bitches with a GCT. The rise in plasma LH concentration following GnRH administration in the GCT bitches was less than that in both the anestrous bitches and the OVX bitches, indicating less sensitivity of the pituitary gonadotropes to GnRH in the bitches with a GCT.

In women, GCTs express functional gonadotropin receptors (Stouffer et al. 1984; Graves et al. 1985) and the same is likely to be true in dogs, because GnRH stimulation resulted in an increase in the plasma estradiol concentration in all bitches with a GCT. The increment in the plasma estradiol concentration after GnRH administration in the GCT bitches did not differ significantly from that in the anestrous bitches, whereas the LH increment was significantly lower, which may suggest increased sensitivity of the ovarian tumor tissue for gonadotropin stimulation. However, in the study described in Chapter 6 plasma FSH concentrations could not be determined and the possibility that changes in FSH secretion do not parallel LH secretion cannot be excluded.

Normal mammalian sex differentiation depends on the completion of the chromosomal sex determination, gonadal differentiation, and the development of the phenotypic sex. An irregularity in any of these three genetically controlled steps results in abnormal sexual development, which may lead to gonads containing both testicular and ovarian tissue or containing tissue of the opposite chromosomal sex or to animals with phenotypic sexual disorders. In **Chapter 7** nine dogs with a disorder in sexual development (DSD) are described and the effect of the disorder on the pituitary-gonadal axis were studied and compared to the results in fourteen anestrous bitches and fourteen male control dogs described in Chapter 9. The gonads of all dogs with DSD contained testicular tissue and in three of them ovarian tissue was also found. An uterus was found in all dogs. Based on gynecological examination, karyotyping and histopathology findings of the gonads, seven of the nine dogs appeared to be XX sex reversals, from which three XX true hermaphrodites and four XX males, and two dogs had XY gonadal dysgenesis. All XX hermaphrodites were SRY negative, which is in agreement with all canine sex reversed animals described so far (Meyers-Wallen et al. 1995a; Meyers-Wallen et al. 1995b; Hubler et al. 1999; Melniczek et al. 1999; Meyers-Wallen et al. 1999; Kuiper et al. 2005). The remaining two dogs were difficult to classify, but were thought to have

XY gonadal dysgenesis leading to a female phenotype, bilateral testes and Mullerian structures.

In the dogs with DSD, the plasma LH concentrations at both 10 and 60 min after administration of GnRH were significantly higher compared to basal values, as has also been demonstrated in anestrous bitches (van Haaften 1994; Meij et al. 1996) and intact male dogs (Knol et al. 1993). The median basal plasma LH and estradiol concentration in the dogs with DSD were higher than that in anestrous bitches, but comparable with corresponding concentrations in male dogs, which suggests that the dogs with DSD, which all had testicular tissue in their gonads, behave similar as intact males. The three DSD dogs, which had the highest basal plasma LH concentration also had the highest basal plasma testosterone concentration, which may be due to the high circulating LH concentration. The variation in basal plasma concentrations of LH and gonadal steroid hormones in the dogs with DSD was however considerable, which makes comparisons with the basal values of anestrous bitches and male control dogs, in which the variation was not as wide, difficult.

The basal plasma estradiol concentration cannot be used to determine if ovarian tissue is present in the gonads of dogs with DSD. Also in humans, basal plasma estradiol concentrations are not a reliable predictor for the presence of ovarian tissue in the gonads (Achermann and Hughes 2008).

The basal plasma testosterone concentration of all dogs with DSD was higher than the upper limit of the range of the anestrous bitches. Moreover, as shown in Chapter 9 in the anestrous bitches GnRH-stimulated plasma testosterone concentrations never exceed 0.15 nmol/l, whereas in the dogs with DSD the lowest plasma testosterone concentration after GnRH administration was 2.2 nmol/l. These findings suggest that the GnRH-stimulation test with measurement of plasma testosterone concentrations can be used to detect the presence of testicular tissue in dogs with DSD.

In **Chapter 8** a case report is presented that describes the first SRY-negative XX male Podenco dog, with an almost completely female phenotype despite high basal and stimulated plasma testosterone concentrations. The testosterone concentrations were comparable to those in normal males and therefore a deficiency in testosterone during fetal development cannot have caused the female phenotype of this dog. The Podenco lacked a prostate as well as masculinization of the external genitalia, which are dihydrotestosterone-dependent. Testosterone is converted to dihydrotestosterone by 5α-reductase, present in the cells of the urogenital sinus, genital tubercle, and genital swellings. Since the Podenco lacked all dihydrotestosterone-driven masculinization of the urogenital tract, deficient 5α-reductase activity during the critical embryonic period could explain this phenotype. The Podenco also had an uterus. Sertoli cells within the testes,

present in the Podenco, normally produce Mullerian-inhibiting substance (MIS), which causes regression of the Mullerian ducts. Reduced or delayed MIS secretion or decreased effect of MIS at the receptor level may explain the presence of a uterus and cranial vagina despite the presence of bilateral testes.

The results of the studies presented in this thesis demonstrate the need for proper reference values. Until recently, studies describing the use of the GnRH-stimulation test in dogs with functional gonadal tissue and gonadectomized animals were non-paired and performed with low numbers of mainly beagle dogs. Therefore, the study described in **Chapter 9** reports the results of a GnRH-stimulation test in male and female dogs of several breeds, both before and after gonadectomy, and in a higher numbers of animals than in previous studies to establish reference values and to get more insight in the pituitary-gonadal axis in gonadally intact and neutered dogs. The results of this study demonstrate, as already described in Chapters 3 and 4 and previously (Chaffaux et al. 1981; Olson et al. 1992; Concannon 1993; Jeffcoate 1993; Löfstedt and VanLeeuwen 2002; Reichler et al. 2004), that the basal plasma concentrations of both FSH and LH were significantly higher in gonadectomized bitches and male dogs. The basal plasma FSH concentration seems however more appropriate to verify the neuter status in dogs, because there was no overlap in basal plasma FSH concentrations before and after gonadectomy. This finding corresponds with the results in women, in whom the basal plasma FSH concentration is more informative about the ovarian reserve than the plasma LH concentration (Toner 1993; Scott and Hofmann 1995; Bulun and Adashi 2003, Genuth 2004). Because both the elevated basal plasma LH and FSH concentrations after OVX slowly decrease with a nadir at 10 weeks after OVX, after which the basal plasma gonadotropin concentrations rise again (Reichler et al. 2004), the use of the basal plasma FSH concentration as a diagnostic tool for the neuter status may be more reliable if the interval between gonadectomy and blood sampling is longer than 6 months.

In agreement with previous findings (Chakraborty and Fletcher 1977; Reimers et al. 1978; Jeffcoate 1993; Knol et al. 1993, Purswell and Wilcke 1993; van Haaften et al. 1994), administration of GnRH resulted in a clear increase of the plasma LH concentration in both bitches and male dogs, both before and after gonadectomy. GnRH administration also resulted in an increase of the plasma FSH concentration in both bitches and male dogs before gonadectomy, but the increment was less than that of the plasma LH concentration. As described in Chapter 4, administration of GnRH did not result in a significant rise of the plasma FSH concentration in bitches after OVX, whereas in male dogs after castration the increase only just reached a significant level. The relative lower response of FSH than LH to stimulation may be ascribed to differential regulation of pituitary gonadotropin secretion as discussed before. The slower decline in the stimulated plasma FSH

concentrations compared to the plasma LH concentrations could be ascribed to the longer half-life of FSH than LH, which is probably due to differences in the pattern of glycosylation of FSH compared to LH (Schwartz 1995) and consequently the clearance from the circulation of LH is faster than that of FSH (Flack et al. 1994).

In the study reported in Chapter 3 all six anestrous bitches responded with a clear increase in plasma estradiol concentration after GnRH administration whereas all six OVX bitches had undetectable plasma estradiol concentrations after GnRH administration, which led to the conclusion that in bitches the plasma estradiol concentration can only be stimulated significantly when functional ovarian tissue is present. Also in bitches with ROT after incomplete OVX, which frequently have higher basal plasma estradiol concentrations than anestrous bitches, a significant rise in the plasma estradiol concentration after GnRH administration could be noticed (Chapter 5). However, in the study reported in Chapter 9 the low plasma estradiol concentration also slightly increased after GnRH administration in several of the OVX bitches, indicating that a GnRH-induced increase in plasma estradiol concentration is not a prove for the presence of functional ovarian tissue. The results show however that at 120 min after GnRH administration plasma estradiol concentrations in intact anestrous bitches no longer overlapped with those in OVX bitches, indicating that GnRH-induced plasma estradiol concentrations at this time point can be used to discriminate between bitches with and without functional ovarian tissue. The detectable plasma estradiol concentrations in the OVX bitches may be explained by conversion of androstenedione, produced in the adrenal cortex, into estradiol. In addition, estradiol can also be produced from aromatization in fat, hair follicles, and the liver (Nelson and Bulun 2001).

Different from the findings reported in Chapter 3, the basal plasma testosterone concentrations were significantly higher before compared to after gonadectomy in both bitches and male dogs, indicating that the gonads are the main source of circulating testosterone. In male dogs, measurement of a single basal plasma testosterone concentration seems reliable to verify the neuter status. Administration of GnRH resulted in a significant increase in plasma testosterone concentrations in both bitches and male dogs before gonadectomy. This has been previously reported in males (Knol et al. 1993; Purswell and Wilcke 1993; Junaidi et al. 2007), but no such data have been reported for bitches.

The results of the study presented in Chapter 9 demonstrate that the GnRH-stimulation test can be used to differentiate animals with functional gonadal tissue and animals after gonadectomy. It would however be easier if this differentiation could be based on measurements in a single basal blood sample. Taking into account the opposite directions in which the circulating gonadotropin and steroid hormone concentrations move after

gonadectomy, the results of the study reported in Chapter 9 demonstrate that the LH to testosterone and FSH to estradiol ratios allow differentiation between gonadally intact dogs and gonadectomized dogs by using only a single blood sample. Moreover, the LH to testosterone and FSH to estradiol ratios had the highest discriminatory power in differentiating gonadally intact from gonadectomized dogs.

The following conclusions can be drawn:

- The basal plasma LH and FSH concentrations are significantly higher in ovariectomized bitches than in anestrous bitches
- The basal plasma FSH concentration seems most appropriate to verify the neuter status in dogs, because there was no overlap in basal plasma FSH concentrations before and after gonadectomy
- The plasma LH and FSH concentrations increase after GnRH administration in anestrous bitches, while in ovariectomized bitches only the plasma LH concentration increases significantly
- The basal plasma estradiol concentrations overlap between anestrous and ovariectomized bitches
- The plasma estradiol concentration at 120 min after GnRH administration can be used to discriminate between bitches with and without functional ovarian tissue
- Bitches with remnant ovarian tissue have significantly higher basal plasma LH concentrations than do bitches in anestrus, despite higher estradiol concentrations
- The basal plasma LH concentration in bitches with remnant ovarian tissue is significantly higher in those in which the interval between ovariectomy and the appearance of estrus is more than 3 years
- The LH response to GnRH stimulation is lower in bitches with remnant ovarian tissue than in ovariectomized bitches or those in anestrus
- In bitches with remnant ovarian tissue, basal and/or GnRH-stimulated plasma estradiol concentrations are above the detection limit of the estradiol assay
- In bitches with a granulosa cell tumor (GCT), the pituitary-ovarian axis is affected, characterized by relatively high plasma LH concentrations and a subnormal LH response to GnRH stimulation compared to anestrous and ovariectomized bitches, despite higher estradiol concentrations
- The relatively high proportion of dogs with remnant ovarian tissue among the GCT bitches may point to a pathogenetic role for elevated gonadotropin secretion in the pathogenesis of GCT

- The secretion of LH and estradiol in the dogs with a disorder in sexual development (DSD) described in this thesis, which all had testicular tissue in their gonads, was similar to that in male control dogs
- The GnRH-stimulation test with measurement of plasma testosterone concentrations is very useful to identify the presence of testicular tissue in the gonads of dogs with DSD
- The GnRH-stimulation test with measurement of plasma estradiol concentrations cannot be used to identify the presence of ovarian tissue in the gonads of dogs with DSD
- The basal plasma testosterone concentrations are significantly higher before compared to after gonadectomy in bitches
- Administration of GnRH results in a significant increase in plasma testosterone concentrations in bitches before gonadectomy
- The FSH to estradiol and LH to testosterone ratios allow differentiation between gonadally intact dogs from gonadectomized dogs by using only a single blood sample

References

Achermann JC, Hughes LA. Disorders of sexual development. In: Williams Textbook of endocrinology, 11th edition. Kronenberg HM, Melmed S, Polonsky KS, Larsen PR (Eds). Philadelphia, Saunders Elsevier, 2008, pp. 783-849.

Axnér E, Gustavsson T, Ström Holst B. Estradiol measurement after GnRH-stimulation as a method to diagnose presence of ovaries in the female domestic cat. Theriogenology 2008;70:186-191.

Bosetti C, Negri E, Trichopoulos D, Franceschi S, Beral V, Tzonou A, Parazzini F, Greggi S, La Vecchia C. Long-term effects of oral contraceptives on ovarian cancer risk. Int J Cancer 2002;102:262-265.

Bulun SE, Adashi EY. The physiology and pathology of the female reproductive axis. In: Williams Textbook of Endocrinology 10th edition. Larsen PR, Kronenberg HM, Melmed S, Polonsky KS (Eds.). Saunders, Philadelphia, PA, USA, 2003, pp. 587-664.

Chaffaux S, Chassagnite F, Thibier M. Concentration of LH après stimulation par la gonadoliberine (LRH) chez la chienne et effet de l'ovariectomie. Rec Med Vet 1981;10:725-733.

Chakraborty PK, Fletcher WS. Responsiveness of anoestrus Labrador bitches to GnRH. Proc Soc Exp Biol Med 1977;154:125-126.

Chowdhury M, Steinberger E. Biosynthesis of gonadotropins by rat pituitaries in vitro. J Endocrinol 1975;66:369-374.

Concannon PW. Biology of gonadotropin secretion in adult and prepubertal female dogs. J Reprod Fertil Suppl 1993;47:3-27.

Cotchin E, Marchant J. Animal tumours of the female reproductive tract. Spontaneous and experimental. In: Pathology of the female genital tract, Blaustein A (Ed). Springer-Verlag, New York, 1977, pp. 55-56.

Diaz-Espineira MM, Mol JA, van den Ingh TSGAM, van der Vlught-Meijer RH, Rijnberk A, Kooistra HS. Functional and morphological changes in the adenohypophysis of dogs with induced hypothyroidism: Loss of TSH hypersecretion, hypersomatotropism, hypoprolactinemia, and pituitary enlargement with transdifferentiation. Domest Anim Endocrinol 2008;35:98-111.

Flack MR, Bennett AP, Froehlich J, Anasti JN, Nisula BC. Increased biological activity due to basic isoforms in recombinant human follicle-stimulating hormone produced in a human cell line. J Clin Endocrinol Metab 1994;79:756-760.

Genuth SM. The hypothalamus and pituitary gland. In: Physiology, 5th edition, Berne RM, Levy MN, Koeppen BM, Stanton BA (Eds). Mosby, St. Louis, MO, USA, 2004, pp. 819-859.

De Gier J, Djajadiningrat-Laanen SC, Kooistra HS, Dieleman SJ, Okkens AC. Temporal relationships between plasma concentrations of LH, FSH, estradiol, progesterone, prolactin, and alpha-melanocyte stimulating hormone during the follicular, ovulatory and early luteal phase in the bitch Theriogenology 2006;65:1346-1359.

Graves PE, Surwit EA, Davis JR, Stouffer RL. Adenylate cyclase in human ovarian cancers: sensitivity to gonadotrophins and nonhormonal activators. Am J Obstet Gynecol 1985;153:877-882.

Herron MA. Tumours of the canine genital system. J Am Anim Hosp Assoc 1983;19:981-994.

Hubler M, Hauser B, Meyers-Wallen VN, Arnold S. Sry-negative XX true hermaphrodite in a Basset hound. Theriogenology 1999;51:1391-1403.

Jeffcoate IA. Gonadotropin-releasing hormone challenge to test for the presence of ovaries in the bitch. J Reprod Fertil Suppl 1993;47:536-538.

Joshi AS, Woolf PD. Pituitary hyperplasia secondary to primary hypothyroidism: a case report and a review of the literature. Pituitary 2005;8:99-103.

Junaidi A, Williamson PE, Martin GB, Stanton PG, Blackberry MA, Cummins JM, Trigg TE. Pituitary and testicular endocrine responses to exogenous gonadotropin-releasing hormone (GnRH) and luteinizing hormone in male dogs treated with GnRH agonist implants. Reprod Fertil Dev 2007;19:891-898.

Keri RA, Lozada KL, Abdul-Karim FW, Nadeau JH, Nilson JH. Luteinizing hormone induction of ovarian tumors: oligogenic differences between mouse strains dictates tumor disposition. Proc Natl Acad Sci USA 2000;97:383-387.

Klein MK. Tumours of the female reproductive system. In: Small Animal Clinical Oncology, Withrow SJ, MacEwen EG (Eds). WB Saunders, Philadelphia, 2001, pp. 445-454.

Knol BW, Dieleman SJ, Bevers MM, Brom van den WE. GnRH in the male dog: dose-response relationships with LH and testosterone. J Reprod Fertil 1993;98:159-161.

Konishi I, Kuroda H, Mandai M. Review: gonadotrophins and development of ovarian cancer. Oncology 1999;57:45-48.

Kooistra HS, Okkens AC, Bevers MM, Popp-Snijders C, van Haaften B, Dieleman SJ, Schoemaker J. Concurrent pulsatile secretion of luteinizing hormone and follicle-stimulating hormone during different phases of the estrous cycle and anestrus in beagle bitches. Biol Reprod 1999;60:65-71.

Kuiper H, Bunck C, Günzel-Apel AR, Drögemüller C, Hewicker-Trautwein M, Distl O. SRY-negative XX sex reversal in a Jack Russel Terrier: a case report. Vet J 2005;169:116-7.
La Vecchia C. Epidemiology of ovarian cancer: a summary review. Euro J Canc Prev 2001;10:125-129.
Liu JH, Yen SSC. Induction of midcycle gonadotrophin surge by ovarian steroids in women: a critical evaluation. J Clin Endocrinol Metab 1983;57:797-802.
Löfstedt RM, Vanleeuwen JA. Evaluation of a commercially available luteinizing hormone test for its ability to distinguish between ovariectomized and sexually intact bitches. J Am Vet Med Assoc 2002;220:1331-1335.
Meij BP, Mol JA, Hazewinkel HAW, Bevers MM, Rijnberk A. Assessment of a combined anterior pituitary function test in beagle dogs: rapid sequential intravenous administration of four hypothalamic releasing hormones. Domest Anim Endocrinol 1996;13:161-170.
Melniczek JR, Damhach D, Prociuk U, Jezyk PF, Henthorn PS, Patterson DF, Giger U. Sry-negative XX sex reversal in a family of Norwegian Elkhounds. J Inter Med 1999;13:564-569.
Meyers-Wallen VN, Bowman L, Acland GM, Palmer VL, Schlafer D, Fajt V. Sry-negative XX sex reversal in the German shorthaired pointer dog. J Hered 1995a;*86:*369-374.
Meyers-Wallen VN, Palmer VL, Acland GM, Herschfield B. Sry-negative XX sex reversal in the American Cocker Spaniel Dog. Mol Reprod Dev 1995b;41:300-305.
Meyers-Wallen VN, Schlafer D, Barr I, Lovell-Badge R, Keyzner A. Sry-negative XX sex reversal in purebred dogs. Mol Reprod Dev 1999;53:266-273.
Moyle WR, Campbell RK. Gonadotropins. In: Reproductive Endocrinology, Surgery and Technology, Adashi EY, Rock JA, Rosenwaks Z (Eds), Lippincott-Raven Publishers, Philadelphia, 1995, pp. 683-724.
Muyan M, Ryzmkiewicz DM, Boime I. Secretion of lutropin and follitropin from transfected GH cells: evidence for separate secretory pathways. Mol Endocrinol 1994;8:1789-1797.
Nelson LR, Bulun SE. Estreogen production and action. J Am Acad Dermatol Suppl 2001;45:116-124.
Ness RB, Cramer DW, Goodman MT, Kjaer SK, Mallin K, Mosgaard BJ, Purdie DM, Risch HA, Vergona R, Wu AH. Infertility, fertility drugs, and ovarian cancer: a pooled analysis of case-control studies. Am J Epidemiol 2002;155:217-224.
Okkens AC, Dieleman SJ and vd Gaag I. Gynaecological complications following ovariohysterectomy in dogs, due to (1) Partial removal of the ovaries (2) Inflammation of the uterocervical stump. Tijdschr Diergeneeskd 1981;106:1142-1158.
Okkens AC, Teunissen JM, Van Osch W, Van Den Brom WE, Dieleman SJ & Kooistra HS. Influence of litter size and breed on the duration of gestation in dogs. J Reprod Fertil Suppl 2001;57:193–197.
Olson PN, Mulnix JA, Nett TM. Concentrations of luteinizing hormone and follicle-stimulating hormone in the serum of sexually intact and neutered dogs. Am J Vet Res 1992;53:762-766.
Patnaik AK, Greenlee PG. Canine ovarian neoplasms: A clinicopathologic study of 71 cases, including histology of 12 granulosa cell tumours. Vet Pathol 1987;24:509-514.
Pluhar GE, Memon MA, Wheaton LG. Granulosa cell tumour in an ovariohysterectomized dog. J Am Vet Med Assoc 1995;207:1063-1065.
Purswell BJ, Wilcke JR. Response to gonadotrophin-releasing hormone by the intact male dog: Serum testosterone, luteinizing hormone and follicle-stimulating hormone. J Reprod Fertil 1993;47:335-341.
Reichler IM, Pfeiffer E, Piché CA, Jöchle W, Roos M, Hubler M, Arnold S. Changes in plasma gonadotropin concentrations and urethral closure pressure in the bitch during the 12 months following ovariectomy. Theriogenology 2004;62:1391-1402.
Reimers TJ, Phemister RD, Niswender GD. Radioimmunological measuremnt of follicle stimulating hormone and prolactin in the dog. Biol Reprod 1978;19:673-679.
Risma KA, Clay CM, Nett TM, Wagner T, Yun J, Nislon JH. Targeted overexpression of luteinizing hormone in transgenic mice leads to infertility, polycystic ovaries, and ovarian tumours. Proc Natl Acad Sci USA 1995;92:1322-1326.
Sarlis NJ, Brucker-Davis F, Doppman JL and Skarulis MC. MRI-demonstrable regression of a pituitary mass in a case of primary hypothyroidism after a week of acute thyroid hormone therapy. J Clin Endocrinol Metab 1997;82:808-811.
Scott RT, Hofmann GE. Prognostic assessment of ovarian reserve. Fertil Steril 1995;63:1-11.
Scott RT, Beatse SN, Illions EH, Snyder RR. Use of the GnRH agonist stimulation test in the diagnosis of ovarian remnant syndrome. A report of three cases. J Reprod Med 1995;40:143-146.
Schaefers-Okkens AC, Kooistra HS. Ovaries. In: Clinical Endocrinology of Dogs and Cats. Rijnberk A, Kooistra HS (Eds). Hannover, Schlütersche, 2010, pp. 203-234.
Schildkraut JM, Schwingl PJ, Bastos E, Evanoff A, Hughes C. Epithelial ovarian cancer risk among women with polycystic ovary syndrome. Obstet Gynecol 1996;88:554-559.

Schwartz NB. The 1994 Stevenson Award Lecture. Follicle-stimulating hormone and luteinizing hormone: a tale of two gonadotropins. Can J Physiol Pharmacol 1995;73:675-684.

Sivacolundhu RK, O'Hara AJ, Read RA. Granulosa cell tumour in two spayed bitches. Aust Vet J 2001;79:173-176.

Stouffer RL, Grodin MS, Davis JR, Surwit EA. Investigation of binding sites for follicle-stimulating hormone and chorionic gonadotropin in human ovarian cancers. J Clin Endocrinol Metab 1984;59:441-446.

Tennent BJ, Shultz KL, Sundberg JP, Beamer WG. Ovarian granulosa cell tumorigenesis in SWR-derived F1 hybrid mice: preneoplastic follicular abnormality and malignant disease progression. Am J Obstet Gynecol 1990;163:625-634.

Toner JP. The significance of elevated FSH for reproductive function. Baillieres Clin Obstet Gynaecol 1993;7:283-295.

Unkila-Kallio L, Tiitinen A, Wahlström T, Lehtovirta P, Leminen A. Reproductive features in women developing ovarian granulosa cell tumour at a fertile age. Hum Reprod 2000;15:589-593.

Van Haaften B, Bevers MM, van den Brom WE, Okkens AC, van Sluijs FJ, Willemse AH, Dieleman SJ. Increasing sensitivity of the pituitary to GnRH from early to late anoestrus in the beagle bitch. J Reprod Fertil 1994;101:221-225.

Vidal S, Horvath E, Kovacs K, Cohen SM, Lloyd RV and Scheithauer BW. Transdifferentation of somatotrophs to thyrotrophs in the pituitary of patients with protracted primary hypothyroidism. Virchows Arch 2000;436:43-51.

Chapter 11

Samenvatting en conclusies

De voortplantingscyclus van ieder vrouwelijk individu, mens of dier, wordt gereguleerd door het hypothalamus-hypofyse-ovarium systeem. Het decapeptide “gonadotrophin-releasing hormone” (GnRH) speelt een centrale rol in de regulatie van de voortplantingscyclus. GnRH wordt gemaakt in de hypothalamus en daar pulsatiel afgegeven aan het poortadersysteem van de hypofyse. GnRH beïnvloedt de productie en afgifte van twee hormonen die geproduceerd worden in de gonadotrofe cellen van de hypofysevoorkwab. Deze cellen produceren luteïniserend hormoon (LH) en follikel-stimulerend hormoon (FSH) die ook pulsatiel, namelijk in reactie op een GnRH puls, aan de systemische circulatie worden afgegeven. Ondanks de gemeenschappelijke regulatie via GnRH, zijn er ook wel degelijk verschillen in de aansturing van deze twee hypofysaire hormonen (Kooistra et al. 1999; De Gier et al. 2006). FSH en LH beïnvloeden beide de afgifte van oestradiol, progesteron en testosteron, die in de granulosa, luteale en theca cellen van het ovarium worden gemaakt. Deze hormonen kunnen op hun beurt weer invloed hebben op de hypofysaire afgifte van LH en FSH. Of de beïnvloeding remmend of stimulerend is, is onder andere afhankelijk van het cyclusstadium (Schaefers-Okkens en Kooistra 2010).

De voortplantingscyclus van de teef is niet seizoensgebonden, dit in tegenstelling tot de situatie bij vele andere diersoorten. De indeling van de voortplantingscyclus kan zowel berusten op gedragskenmerken van de teef als op functionele kenmerken van de ovaria. De indeling op basis van gedragskenmerken onderscheidt pro-oestrus, oestrus, metoestrus en anoestrus. Bij de indeling op basis van functionele kenmerken van de ovaria wordt gesproken van de folliculaire fase, pre-ovulatoire luteïnisatie en ovulatie fase, luteale fase en de anoestrus (Schaefers-Okkens en Kooistra 2010).

In de algemene inleiding van dit proefschrift (**Hoofdstuk 2**) wordt een overzicht gegeven van de huidige kennis omtrent de hypofyse-ovarium as, waarbij de nadruk ligt op het effect van ovariëctomie op deze as. Daarnaast worden enkele belangrijke gynaecologische aandoeningen besproken die deze as mogelijk kunnen beïnvloeden bij de teef.

Voor vele hondeneigenaren is het optreden van een loopsheid bij de teef niet wenselijk. De loopsheid kan zowel medicamenteus als via een ovariëctomie (OVX) worden voorkomen. Een OVX, het chirurgische verwijderen van de ovaria, wordt frequent in Nederland toegepast als methode om de loopsheid te voorkomen. De voordelen van een OVX zijn onder andere 1) een verlaagd risico op melkkliertumoren, 2) het voorkómen van een baarmoederontsteking, en 3) het niet meer kunnen optreden van een progesteron-geïnduceerde overmaat aan groeihormoon. De nadelen verbonden aan OVX zijn onder andere 1) het anesthesie- en operatierisico, 2) een verhoogde kans op het ontstaan van urine-incontinentie, en 3) vachtveranderingen. De vraag of een teef wel of niet

geovariëctomeerd is, is niet altijd eenvoudig te beantwoorden, bijvoorbeeld als de voorgeschiedenis van de hond onduidelijk is en deze teef meerdere eigenaren heeft gehad of uit een asiel komt. Ook kan een hond, waarvan de eigenaar weet dat er een OVX heeft plaatsgevonden, symptomen gaan vertonen die passen bij een loopsheid, wat leidt tot de vraag of er mogelijk sprake kan zijn van rest ovarieel weefsel. Het antwoord op deze vraag is met name lastig te geven tijdens de anoestrus. Volgens de literatuur zou een GnRH-stimulatietest mogelijk onderscheid kunnen maken tussen anoestrsiche en OVX honden. Om deze reden is in **Hoofdstuk 3** gekeken naar de basale en GnRH-gestimuleerde plasmaconcentraties van LH, oestradiol, progesteron en testosteron bij 6 anoestrische en 6 OVX honden. Hieruit kwam naar voren dat de gemiddelde plasma-LH-concentratie bij OVX honden significant hoger was dan die bij anoestrische honden en dat er geen sprake was van overlap tussen beide groepen. Deze bevinding komt overeen met de bevindingen van eerdere onderzoeken (Chaffaux et al. 1981; Olson et al. 1992; Concannon 1993; Jeffcoate 1993; Löfstedt en Vanleeuwen 2002; Reichler et al. 2004) en wordt veroorzaakt door het wegvallen van de negatieve terugkoppeling van ovariële hormonen op de hypothalamus en de hypofyse. Alhoewel er in het onderzoek geen sprake was van overlap is deze, vanwege de pulsatiele afgifte van LH, wel te verwachten (Concannon 1993; Kooistra et al. 1999) en mogelijk komt deze overlap wel naar voren als er grotere groepen anoestrsiche en OVX honden worden gebruikt zoals is beschreven in een artikel van Löfstedt en Vanleeuwen (2002). Dit vermoeden wordt gesterkt door de waarneming dat er wel degelijk overlap was tussen de gemiddelde basale plasma-LH-concentraties bij de OVX honden en de GnRH-gestimuleerde plasma-LH-concentraties bij de intacte honden. Dit rechtvaardigt de conclusie dat het onwaarschijnlijk is dat de aan- of afwezigheid van ovarieel weefsel bij een teef bevestigd kan worden door het bepalen van een enkele basale plasma-LH-concentratie.

De basale plasma-oestradiol-concentratie lag onder de detectielimiet van de oestradiolassay bij alle OVX honden en bij 5 van de 6 anoestrische honden. Na toediening van GnRH werd alleen een significante toename gezien van de plasma-oestradiol-concentratie bij de anoestrische honden, terwijl bij alle OVX honden de oestradiolconcentratie onder de detectielimiet bleef. Op basis van deze bevindingen is geconcludeerd dat er alleen sprake is van een significante toename van de plasma-oestradiol-concentratie na toediening van GnRH als er ovarieel weefsel bij een teef aanwezig is. Dit geeft aan dat de GnRH-stimulatietest een bruikbare methode is om onderscheid te maken tussen OVX honden en anoestrische honden. De plasmaconcentraties van progesteron en testosteron, zowel voor als na stimulatie met GnRH, bleken niet bruikbaar om onderscheid tussen beide groepen te maken.

Onderzoek bij vrouwen bracht aan het licht dat de basale plasma-FSH-concentratie een uitstekende parameter is om onderscheid te maken tussen vrouwen voor en na de menopauze. Na de menopauze zijn de ovaria niet meer hormonaal actief; een situatie die in grote lijnen vergelijkbaar is met die na OVX bij de teef. Om deze reden zijn in **Hoofdstuk 4** de basale en GnRH-gestimuleerde plasmaconcentraties van FSH en LH vergeleken tussen vier anoestrische honden en vier OVX honden. De basale plasmaconcentraties van zowel LH als FSH bij de OVX honden waren significant hoger dan de waarden bij anoestrische honden en deze bevindingen komen overeen met die in eerder beschreven onderzoek (Chaffaux et al. 1981; Olson et al. 1992; Concannon 1993; Jeffcoate 1993; Löfstedt en Vanleeuwen 2002; Reichler et al. 2004). Bij anoestrische honden was er zowel een significante stijging van de plasma-LH- als de plasma-FSH-concentratie te zien na toediening van GnRH, terwijl bij OVX honden alleen de plasma-LH-concentratie significant steeg. De reden voor het verschil in reactie van LH en FSH kan gelegen zijn in een ander intracellulair mechanisme voor opslag en afgifte van deze twee hormonen. Deze redenering wordt ondersteund door *in vitro* onderzoek met hypofysaire cellen bij andere zoogdieren, waaruit naar voren kwam dat FSH en LH in verschillende secretieblaasjes worden opgeslagen in dezelfde (gonadotrofe) cel (Moyle en Campbell 1995). Daarnaast bleek dat nieuwgevormd FSH sneller wordt uitgescheiden dan nieuwgevormd LH (Chowdhury en Steinberger 1975) en dat de stimuleerbaarheid van de FSH-secretie minder is dan die van de LH-secretie (Chowdhury en Steinberger 1975; Muyan et al. 1994).

Alhoewel in hoofdstuk 3 geen overlap werd waargenomen in de basale plasma-LH-concentratie tussen OVX honden en anoestrische honden, bleek deze overlap wel aanwezig te zijn bij de honden beschreven in hoofdstuk 4. Dit geeft eens te meer aan dat het bepalen van een eenmalige basale plasma-LH-concentratie geen sluitend bewijs oplevert voor de aan- of afwezigheid van ovarieel weefsel. De basale plasma-FSH-concentratie, die gemeten werd met een FSH IRMA die in 2006 op de markt werd gebracht, bleek echter wel een goede parameter te zijn om aan te kunnen geven of de ovaria wel of niet verwijderd waren, aangezien er geen overlap was tussen de basale plasma-FSH-concentratie van OVX honden en de GnRH-gestimuleerde waarden van FSH bij anoestrische teven. Deze bevinding geeft aan dat de capaciteit van de hypofyse na OVX, dus na het wegvallen van de negatieve terugkoppeling van ovariële hormonen, om FSH af te geven aan de circulatie groter is dan bij intacte honden, iets dat reeds door meerdere onderzoekers is gesuggereerd (Olson et al. 1992; Concannon 1993). Ook bij vrouwen stijgt de plasma-FSH-concentratie sterker dan de plasma-LH-concentratie als de ovaria worden verwijderd of als deze na de menopauze niet meer hormonaal actief zijn (Bulun en Adashi 2003; Genuth 2004).

Met de onderzoeken, beschreven in de hoofdstukken 3 en 4, is een goede basis gelegd voor het diagnosticeren van de aan- of afwezigheid van ovaria. Aanvullend onderzoek is echter wel nodig met grotere groepen honden van verschillende rassen, met name als het er om gaat of de basale plasma-FSH-concentratie bij een eenmalige bepaling het definitieve bewijs levert of er (functionele) ovaria aanwezig zijn bij een teef.

Ovariële aandoeningen kunnen zowel congenitaal als verkregen zijn, en daarvan zijn rest ovarieel weefsel en granulosaceltumoren frequent voorkomende aandoeningen die in verwijsklinieken worden gezien, evenals afwijkingen in de seksuele ontwikkeling. De kennis omtrent het hypofyse-gonade systeem bij deze drie aandoeningen is echter zeer beperkt en mede om deze reden zijn deze aandoeningen in relatie tot de hypofyse-gonade as nader bekeken in dit proefschrift.

Van rest ovarieel weefsel (ROW) wordt gesproken als blijkt dat een of beide ovaria onvolledig zijn verwijderd na een OVX. De symptomen van rest ovarieel weefsel, namelijk het weer optreden van verschijnselen van een loopsheid of schijnzwangerschap bij een teef die geovariëctomeerd is, kunnen periodiek aanwezig zijn of continu spelen. Daarnaast is het tijdsinterval tussen de OVX en het moment waarop voor de eerste keer weer loopsheidverschijnselen worden waargenomen zeer uiteenlopend. De diagnostische uitdaging is om honden met ROW te onderscheiden van OVX honden en, zoals eerder vermeld, is deze uitdaging verreweg het grootst tijdens de anoestrus, aangezien tijdens de folliculaire fase de oestradiol-invloeden en tijdens de luteale fase de plasma-progesteron-concentratie het bewijs leveren dat er nog ROW aanwezig is. Tijdens de anoestrus kan d.m.v. de bepaling van basale plasmaconcentraties van oestradiol en progesteron geen onderscheid worden gemaakt tussen anoestrische en OVX honden, dus ook ROW kan zo niet worden gediagnosticeerd. Om deze reden is in **Hoofdstuk 5** nagegaan of de GnRH-stimulatietest gebruikt kan worden om onderscheid te maken tussen honden met ROW en teven tijdens de anoestrus. Achttien honden met ROW zijn vergeleken met 6 honden in anoestrus en 6 OVX honden.

Alle 18 honden met ROW bleken relatief zwaar te zijn wat mogelijk een verhoogd risico impliceert, iets dat reeds eerder is gesuggereerd door Okkens et al. (1981). Daarnaast bleek dat zowel echografisch onderzoek als macroscopische inspectie van de ovaria door de chirurg zowel vals-positieve als vals-negatieve resultaten opleverden in vergelijking met histopathologisch onderzoek. Mede om deze reden wordt aangeraden om bij honden die worden geopereerd vanwege ROW altijd beide ovariële stompen in te korten als er enige verdenking is op ROW.

Honden met ROW hadden hogere plasma-oestradiol-concentraties in vergelijking met anoestrische honden, wat echter niet leidde tot een lagere plasma-LH-concentratie, wat wel verwacht mocht worden op basis van de negatieve terugkoppeling van oestradiol op

de afgifte van LH. De gevoeligheid voor negatieve terugkoppeling lijkt dus verminderd te zijn bij honden met ROW, mogelijk veroorzaakt door veranderingen in de hypothalamus-hypofyse as geïnduceerd door de gedeeltelijke verwijdering van de ovaria en/of de veranderde bloedvoorziening naar het resterende ovariële weefsel, wat soms tot een langdurige inactiviteit leidt. Hypofysaire cellen kunnen zich aanpassen aan situaties waarbij de vraag naar een specifiek hypofysair hormoon toeneemt door vermenigvuldiging van deze specifieke cellijn. De veranderingen die in de hypofyse optreden door een tekort aan een specifiek perifeer hormoon zijn het best bekend bij experimentele en klinische hypothyreoïdie. Bij primaire hypothyreoïdie, waarbij er een tekort ontstaat aan T_4 en T_3, zal de plasmaconcentratie van het schildklier-stimulerend hormoon TSH, dat geproduceerd wordt in de thyrotrofe cellen van de hypofyse, toenemen door het wegvallen van de negatieve terugkoppeling van de schildklierhormonen. Door vermenigvuldiging van deze thyrotrofe cellen zullen meer cellen TSH gaan maken (Vidal et al. 2000) wat kan leiden tot een vergroting van de hypofyse (Sarlis et al. 1997; Joshi en Woolf 2005; Diaz-Espineira et al. 2008) en zal leiden tot een verhoogde plasma-TSH-concentratie. Bij honden met primaire hypothyreoïdie is beschreven dat de negatieve terugkoppeling op schildklierhormonen met de tijd vermindert, hetgeen op een gegeven moment resulteert in een daling van de verhoogde plasma-TSH-concentratie (Diaz-Espineira et al. 2008). Een vergelijkbare verandering in de hypofyse kan ook hebben plaatsgevonden bij honden met ROW, namelijk een niet functioneel of gedurende een lange periode inactief restant ovarieel weefsel, kan hebben geleid tot een dramatische vermindering van de negatieve terugkoppeling van ovariële hormonen en dientengevolge tot een vermenigvuldiging van de gonadotrofe cellen in de hypofyse. Door deze proliferatie kunnen de karakteristieke kenmerken van normale gonadotrofe cellen (deels) verloren zijn gegaan, zoals de gevoeligheid voor negatieve terugkoppeling van ovariële hormonen. Op het moment dat het ROW toch weer significante hoeveelheden hormonen gaat produceren kan het zijn dat de plasma-LH-concentratie niet meer daalt tot waarden die gebruikelijk zijn bij intacte honden. Dit heeft tot gevolg dat de basale plasma-LH-concentratie significant hoger is bij honden met ROW, ook al is de plasma-oestradiol-concentratie bij deze honden veel hoger dan bij anoestrische honden. Deze veronderstelling werd kracht bijgezet door de bevinding van significant hogere plasma-LH-concentraties bij honden met ROW die een interval van meer dan drie jaar hadden tussen de OVX en de eerste keer dat verschijnselen van loopsheid werden waargenomen door de eigenaar.

Net als bij de anoestrische honden (Van Haaften et al. 1994; Okkens et al. 2001) was ook bij de honden met ROW een stijging te zien van de plasma-LH-concentratie, zowel 10 als 60 minuten na toediening van GnRH, alhoewel de stijging significant lager was in vergelijking met die bij de anoestrische honden. Dit wijst erop dat de LH afgifte na

toediening van GnRH anders is bij honden met ROW, wat mogelijk veroorzaakt wordt door de hierboven beschreven proliferatie en veranderingen van de gonadotrofe cellen. Het is mogelijk dat een aantal karakteristieke eigenschappen van deze cellen verloren zijn gegaan op het moment dat het resterende ovariële weefsel minimale hoeveelheden of geen hormonen meer produceerde. Een soortgelijke reactie na GnRH-toediening werd ook waargenomen bij teven met een granulosaceltumor (hoofdstuk 6). Een mogelijke verklaring is ook dat de maximale stimulatie van LH na GnRH-toediening bij deze honden later optreedt dan 10 minuten na GnRH toediening. De bevinding dat de daling in de plasma-LH-concentratie van 10 naar 60 minuten relatief beperkt was bij de honden met ROW maakt deze verklaring plausibeler.

De basale plasma-oestradiol-concentratie lag boven de onderste detectielimiet van de assay bij 17 van de 18 honden met ROW, terwijl bij alle OVX honden de plasma-oestradiol-concentratie onder het detectiebereik lag. Bij alle honden met ROW was de plasma-oestradiol-concentratie 120 minuten na toediening van GnRH detecteerbaar met de oestradiolassay, terwijl er nooit een detecteerbare plasma-oestradiol-concentratie werd gemeten na toediening van GnRH bij de OVX honden. Een soortgelijk onderzoek is uitgevoerd bij katten door Axnér et al. (2008), en in dat onderzoek werd geen overlap waargenomen in de basale plasma-oestradiol-concentratie tussen anoestrische en geovariectomeerde katten, en alleen bij de katten met ovarieel weefsel leidde GnRH-toediening tot een significante stijging van de plasma-oestradiol-concentratie. Een zelfde type waarneming werd gedaan door Scott et al. (1995), die vaststelden dat een stijgende oestradiol-concentratie na GnRH-toediening bij vrouwen impliceerde dat er functioneel ovarieel weefsel aanwezig was. De stijging in de plasma-oestradiol-concentratie van 60 naar 120 minuten na toediening van GnRH was significant lager bij honden met ROW in vergelijking met anoestrische honden. Vier honden met ROW lieten zelfs een daling in plaats van een stijging zien. Mogelijke verklaringen hiervoor zijn de aanwezigheid van cysteuze veranderingen in de ovaria of een abnormale vascularisatie van het resterende ovariële weefsel. Het zou echter ook een fysiologische reactie kunnen zijn in de folliculaire fase, maar daar is bij de hond geen aanvullende informatie over beschikbaar.

De resultaten van het onderzoek beschreven in hoofdstuk 5 leidden tot de conclusie dat de GnRH-stimulatietest gebruikt kan worden om honden met ROW op te sporen, alhoewel aanvullend onderzoek nodig is om de sensitiviteit en specificiteit van de test voor dit doeleinde in kaart te brengen en dat ROW gepaard gaat met waarneembare veranderingen in de hypofyse-ovarium as.

Granulosaceltumoren (GCT) zijn de frequentst voorkomende hormoonproducerende tumoren van het ovarium bij de hond en ze komen voor bij honden van middelbare tot oudere leeftijd (Cotchin en Marchant 1977; Herron 1983; Patnaik en Greenlee 1987; Klein

2001). Wat het effect is van zo'n hormoonproducerende tumor op de functie van de hypofyse-ovarium as is onbekend en om deze reden is in **Hoofdstuk 6** gekeken naar de resultaten van de GnRH-stimulatietest bij zeven honden met een GCT en deze resultaten zijn vergeleken met die van 6 anoestrische en 6 OVX honden. Drie van de zeven teven met een GCT waren intact (GCT-intact), terwijl bij de andere vier deze tumor in ROW ontwikkelde (GCT-ROW). Aangezien de honden met een GCT werden aangeboden met tekenen van een persisterende oestrus, was het niet verrassend dat de basale plasma-oestradiol-concentratie bij beide groepen (GCT-intact en GCT-ROW) significant hoger was in vergelijking met die in anoestrische honden.

De basale plasma-LH-concentraties van de GCT honden tendeerden daarentegen hoger te zijn dan de waarden gemeten bij anoestrische honden, ook al hadden de GCT honden een hoge plasma-oestradiol-concentratie. Deze tendens werd vooral veroorzaakt door de GCT-ROW honden die een significant hogere plasma-LH-concentratie hadden. Deze plasma-LH-concentratie, die dus hoger was ondanks een hoge plasma-oestradiol-concentratie, kan veroorzaakt worden door een verminderde gevoeligheid voor negatieve terugkoppeling van oestradiol ter hoogte van de hypothalamus-hypofyse as door de gedeeltelijk verwijdering van de ovaria en/of de veranderde vascularisatie van het resterend ovariële weefsel, zoals beschreven in hoofdstuk 5.

Een mogelijke andere verklaring voor de verhoogde plasma-LH-concentraties bij honden met een GCT is dat oestradiol op bepaalde momenten tijdens de cyclus een positieve terugkoppeling heeft op de secretie van LH, zoals bij honden tijdens de late folliculaire fase (De Gier et al. 2006). Het optreden van de positieve terugkoppeling is echter beperkt tot een korte periode en het is daarom minder aannemelijk dat dit de verhoogde plasma-LH-concentraties verklaart.

Vier honden met een GCT ontwikkelden deze in ROW, variërend tussen de 2 en 10,5 jaar na de incompleet uitgevoerde OVX. Dit is niet de eerste keer dat dit beschreven is, aangezien Pluhar et al. (1995) en Sivacolundhu et al. (2001) hetzelfde al beschreven hebben bij drie teven. Ook deze drie honden vertoonden een lang interval tussen de incomplete OVX en het optreden van verschijnselen van loopsheid. Dit betekent dat de plasma-oestradiol-concentratie aanvankelijk laag waren, hetgeen aanleiding gaf tot verhoogde plasmaconcentraties van LH en FSH. Deze verhoogde concentraties zouden mogelijk een rol kunnen spelen in het ontstaan van de tumor. Bij vrouwen is namelijk bekend dat blootstelling aan hoge concentraties LH en FSH, zoals na de menopauze of na een vruchtbaarheidsbehandeling, mogelijk een verhoogd risico geeft op het ontwikkelen van ovariumtumoren (Konishi et al. 1999; Unkila-Kallio et al. 2000; Ness et al. 2002). Daarnaast blijkt dat vrouwen met polycysteuze ovaria, hetgeen gepaard gaat met een hypersecretie van LH, een verhoogde kans hebben op het krijgen van ovariumkanker

(Schildkraut et al. 1996). Omstandigheden waarbij sprake is van verlaagde plasmaconcentraties van LH en FSH, zoals bij orale anticonceptie (Bosetti et al. 2002), borstvoeding en oestrogeentherapie (La Vecchia 2001), geven een verminderd risico op het ontwikkelen van ovariumkanker. Bij knaagdieren kunnen GCTs worden geïnduceerd door toediening van exogene gonadotrofe hormonen (Tennent et al. 1990) en ook bij transgene muizen met chronische LH hypersecretie is de ontwikkeling van GCTs beschreven (Risma et al. 1995; Keri et al. 2000). Het is daarom mogelijk dat de langdurige blootstelling van het ROW aan hoge concentraties gonadotrofe hormonen heeft geleid tot een verhoogde gevoeligheid voor het ontwikkelen van GCTs bij honden met ROW in vergelijking met intacte teven.

Net als bij intacte teven (Van Haaften et al. 1994; Chaffaux et al. 1981; Meij et al. 1996) leidde GnRH-toediening ook bij de honden met GCT tot een verhoogde plasma-LH-concentratie. De toename was echter minder in vergelijking met anoestrische en OVX honden, hetgeen duidt op een verminderde gevoeligheid van de gonadotrofe cellen voor GnRH.

Bij vrouwen is beschreven dat GCTs functionele receptoren voor gonadotrofe hormonen tot expressie brengen (Stouffer et al. 1984; Graves et al. 1985). Waarschijnlijk is dit ook het geval bij honden aangezien GnRH-toediening leidde tot een stijging van de plasma-oestradiol-concentratie. De stijging van de plasma-oestradiol-concentratie kwam overeen met de stijging waargenomen bij anoestrische teven, terwijl de toename in de plasma-LH-concentratie na GnRH-toediening significant lager was bij honden met een GCT, hetgeen een verhoogde gevoeligheid van het tumorweefsel voor gonadotrofe hormonen lijkt te betekenen. De plasma-FSH-concentratie is in deze studie niet bepaald en het kan niet uitgesloten worden dat de verandering in de plasma-FSH-concentratie niet gelijk loopt met de plasma-LH-concentratie.

Geslachtsdifferentiatie verloopt in grote lijnen in drie opeenvolgende stappen, namelijk de vaststelling van het chromosomale geslacht, de differentiatie van de gonaden, en de ontwikkeling van fenotypische geslachtskenmerken. Als er een fout optreedt in een van de drie stappen zal dat leiden tot een abnormale geslachtsontwikkeling, met als mogelijke gevolgen dat de gonaden zowel testiculair als ovarieel weefsel bevatten, gonadaal weefsel bezitten dat tegenovergesteld is aan dat van het chromosomale geslacht, of dieren met afwijkende fenotypische geslachtskenmerken. In **Hoofdstuk 7** worden negen honden beschreven met een stoornis in de geslachtsontwikkeling (SGO) en het effect dat deze stoornis heeft op de hypofyse-gonade as werd bestudeerd en vergeleken met de resultaten van veertien anoestrische teven en veertien intacte reuen die als controledieren dienden en beschreven zijn in hoofdstuk 9. De gonaden van de honden met SGO bevatten alle testiculair weefsel, terwijl in drie daarvan ook ovarieel weefsel werd

gevonden. Op basis van gynaecologisch onderzoek, cytogenetische analyse en histopathologisch onderzoek, bleken zeven honden “sex reversals” te zijn, waarvan drie “XX ware hermafrodieten” en vier “XX reuen” waren. Alle “XX sex reversals” bleken SRY negatief te zijn, wat overeenkomt met alle “sex reversals” die tot dusver bij de hond beschreven zijn (Meyers-Wallen et al. 1995a; Meyers-Wallen et al. 1995b; Hubler et al. 1999; Melniczek et al. 1999; Meyers-Wallen et al. 1999; Kuiper et al. 2005). De overige twee honden waren lastig te classificeren, hadden een vrouwelijk fenotype, bilaterale testikels en de aanwezigheid van Müllerse structuren en zijn uiteindelijk geclassificeerd als honden met “incomplete XY gonadal dysgenesis”.

Na toediening van GnRH stegen zowel de plasmaconcentraties van LH op 10 en 60 minuten in vergelijking met de basale waarde, wat overeenkomt met de bevindingen bij anoestrische teven (van Haaften 1994; Meij et al. 1996) en intacte reuen (Knol et al. 1993). De basale plasma-LH-concentratie bij honden met SGO bleek hoger te zijn dan die bij anoestrische teven, maar kwam overeen met de waarde gemeten bij intacte reuen. Alle honden met SGO bleken, zoals eerder aangegeven, testiculair weefsel in de gonaden te hebben en qua plasma-LH-concentraties gedroegen zij zich ook als intacte reuen. De drie hoogste plasma-LH-concentraties bleken afkomstig van honden die ook de hoogste plasma-testosteron-concentraties hadden, hetgeen een oorzakelijk verband suggereert. De spreiding in de basale plasmaconcentraties van LH en de gonadale steroïden was echter groot bij honden met SGO, wat een vergelijking met de basale waarden waargenomen bij anoestrische teven en intacte reuen lastig maakt, aangezien de spreiding daar veel beperkter was.

De basale plasma-oestradiol-concentratie bleek niet bruikbaar om na te gaan of de gonaden ovarieel weefsel bevatten bij de honden met SGO en deze bevinding komt volledig overeen met hetgeen is beschreven bij mensen (Achermann en Hughes 2008).

De basale plasma-testosteron-concentratie bij honden met SGO bleek hoger te zijn dan de hoogste waarde gemeten bij anoestrische teven. In hoofdstuk 9 wordt beschreven dat de hoogste GnRH-gestimuleerde waarde bij anoestrische teven niet boven de 0.15 nmol/l uitkwam, terwijl bij honden met SGO de laagste GnRH-gestimuleerde waarde niet beneden de 2.2 nmol/l lag. Op basis van deze resultaten kan geconcludeerd worden dat het meten van de plasma–testosteron-concentratie na toediening van GnRH een nuttige test is om na te gaan of er testiculair weefsel aanwezig is bij honden met SGO.

In **Hoofdstuk 8** wordt een casus beschreven. Het betreft de beschrijving van de eerste SRY-negatieve XX Podenco reu met een vrijwel compleet vrouwelijk uiterlijk, ondanks hoge basale en GnRH-gestimuleerde plasma-testosteron-concentraties. De plasma-testosteron-concentraties kwamen overeen met die bij intacte reuen en een testosterontekort tijdens de foetale ontwikkeling is daarom onwaarschijnlijk als reden voor

het vrouwelijke uiterlijk. Zowel de prostaat als de masculinisatie van de externe genitalia waren afwezig bij de Podenco en deze zijn beide dihydrotestosteron-afhankelijk. Door het enzym 5α-reductase wordt testosteron omgezet in dihydrotestosteron en dit gebeurt in de cellen van de urogenitale sinus, de genitale tuberkel en de genitale zwellingen. Aangezien dihydrotestosteron-afhankelijke masculinisatie afwezig was bij de Podenco is een 5α-reductase deficiëntie tijdens de gevoelige embryonale periode een verklaring voor het fenotype. Bij de Podenco was echter tevens een uterus aanwezig. De Sertoli-cellen van de testes, die aanwezig waren bij de Podenco, produceren "Müllerian-inhibiting substance" (MIS), dat normaliter een regressie van de Müllerse structuren veroorzaakt. Bij een individu met testiculair weefsel kan een onvoldoende afgifte van MIS, een te laat op gang komende MIS secretie, of een stoornis van de MIS-receptor de aanwezigheid van een uterus en het craniale deel van de vagina verklaren.

De onderzoeken die tot recent gepubliceerd zijn over het gebruik van een GnRH-stimulatietest bij honden met functionele gonaden en gecastreerde honden zijn niet gepaard uitgevoerd en ook het aantal honden (en dan ook nog met name Beagles) was laag. Om goede referentiewaarden voor de GnRH-stimulatietest te krijgen en om meer inzicht te krijgen in de hypofyse-gonade as zijn grotere aantallen honden van verschillende rassen nodig en bovendien moeten de testen dan gepaard worden uitgevoerd. In **Hoofdstuk 9** worden de resultaten van de GnRH-stimulatietest voor en na gonadectomie bij reuen en teven van verschillende rassen beschreven. Zoals reeds beschreven in de hoofdstukken 3 en 4 en in eerder gepubliceerde onderzoeken (Chaffaux et al. 1981; Olson et al. 1992; Concannon 1993; Jeffcoate 1993; Löfstedt en VanLeeuwen 2002; Reichler et al. 2004) bleken de basale plasmaconcentraties van LH en FSH significant hoger te zijn bij gecastreerde teven en reuen. De basale plasma-FSH-concentratie levert een beter onderscheid op tussen intacte en gecastreerde teven en reuen dan de basale plasma-LH-concentratie, aangezien er geen overlap aanwezig was tussen beide groepen in de basale plasma-FSH-concentratie. Dit komt overeen met onderzoeksbevindingen bij vrouwen waar de basale plasma-FSH-concentratie duidelijk meer informatie geeft over de ovariële reservecapaciteit dan de basale plasma-LH-concentratie (Toner 1993; Scott en Hofmann 1995; Bulun en Adashi 2003, Genuth 2004). De gestegen plasmaconcentraties van LH en FSH dalen na OVX bij de teef tot een laagste punt dat bereikt wordt rond 10 weken na de OVX, waarna de plasmaconcentraties van zowel LH als FSH weer stijgen (Reichler et al. 2004). Om deze reden is het raadzaam om pas minimaal 6 maanden na de OVX de basale plasma-FSH-concentratie te gebruiken om duidelijkheid te verkrijgen of het functionele gonadale weefsel wel of niet succesvol is verwijderd.

Zoals reeds eerder beschreven (Chakraborty en Fletcher 1977; Reimers et al. 1978; Jeffcoate 1993; Knol et al. 1993, Purswell en Wilcke 1993; van Haaften et al. 1994), werd

ook in dit onderzoek waargenomen dat de basale plasma-LH-concentratie zowel bij teven als reuen en zowel voor als na gonadectomie steeg na toediening van GnRH. Ook de basale plasma-FSH-concentratie steeg na toediening van GnRH bij teven en reuen voor gonadectomie, maar de stijging was minder dan de stijging van de plasma-LH-concentratie. Na OVX was er bij de teven geen significante stijging van de plasma-FSH-concentratie waar te nemen na GnRH-toediening, zoals reeds beschreven in hoofdstuk 4, terwijl bij reuen na castratie de stijging van de plasma-FSH-concentratie net significant bleek te zijn. Dit verschil in stimuleerbaarheid van LH en FSH kan veroorzaakt worden door verschillen in de hypofysaire secretie van de beide hormonen, zoals reeds eerder bediscussieerd is. De daling richting basale waarden van de door GnRH gestimuleerde plasma-FSH-concentratie bleek trager te gaan dan die van de gestimuleerde plasma-LH-concentratie, wat waarschijnlijk veroorzaakt is door de langere halfwaardetijd van FSH in vergelijking met LH . als gevolg van verschillen in de glycosylering van FSH (Schwartz 1995), wat leidt tot een snellere klaring van LH vergeleken met FSH (Flack et al. 1994).

Uit het onderzoek beschreven in hoofdstuk 3 kwam naar voren dat de plasma-oestradiol-concentratie steeg bij alle 6 anoestrische honden na toediening van GnRH, terwijl de plasma-oestradiol-concentraties bij de OVX teven zowel voor als na stimulatie niet detecteerbaar waren. Dit leidde tot de conclusie dat de plasma-oestradiol-concentratie alleen significant door GnRH gestimuleerd kan worden als er ovarieel weefsel aanwezig is. Hetzelfde werd waargenomen bij teven met rest ovarieel weefsel (hoofdstuk 5), die een significante stijging van de plasma-oestradiol-concentratie lieten zien na toediening van GnRH. In hoofdstuk 9 werd echter waargenomen dat ook enkele geovariectomeerde teven een lichte stijging van de plasma-oestradiol-concentratie lieten zien na toediening van GnRH, waarmee de stelling dat de plasma-oestradiol-concentratie alleen stijgt als er ovarieel weefsel aanwezig is geen stand meer kan houden. Wel werd in hoofdstuk 9 waargenomen dat 120 minuten na stimulatie met GnRH geen overlap meer aanwezig was tussen de gestimuleerde plasma-oestradiol-concentraties van anoestrische en OVX teven, wat aangeeft dat 120 minuten na GnRH toediening wel een goed onderscheid gemaakt kan worden tussen beide groepen. Een verklaring voor een detecteerbare plasma-oestradiol-concentratie bij de OVX honden kan gelegen zijn in het feit dat androstenedion, afkomstig uit de bijnierschors, omgezet kan worden in oestradiol. De aromatisering tot oestradiol kan onder andere plaatsvinden in vet, haarfollikels en de lever (Nelson en Bulun 2001).

In tegenstelling met wat in hoofdstuk 3 is gevonden, bleek dat niet alleen bij reuen maar ook bij teven de basale plasma-testosteron-concentratie voor gonadectomie significant hoger was dan na gonadectomie, wat aangeeft dat de gonaden de belangrijkste leveranciers zijn van het circulerend testosteron in intacte honden. Bij reuen bleek zelfs een eenmalige basale plasma-testosteron-concentratie betrouwbaar te zijn in het aangeven

of een castratie wel of niet had plaatsgevonden. Toediening van GnRH leidde tot een significante stijging van de plasma-testosteron-concentratie zowel bij teven als bij reuen voor neutralisatie. Dit komt overeen met eerdere onderzoeksbevindingen bij reuen (Knol et al. 1993; Purswell en Wilcke 1993; Junaidi et al. 2007), maar dergelijke gegevens waren nog niet eerder gepubliceerd voor teven.

Uit het onderzoek beschreven in hoofdstuk 9 komt naar voren dat de GnRH-stimulatietest gebruikt kan worden om onderscheid te maken tussen honden met functioneel gonadeweefsel en honden die een gonadectomie hebben ondergaan. Het zou echter nog gemakkelijker zijn als zo'n onderscheid met behulp van één enkel bloedmonster gemaakt zou kunnen worden. Rekeninghoudend met het feit dat FSH en LH enerzijds en de gonadale steroïden anderzijds in tegengestelde richting bewegen na een gonadectomie, komt in dit onderzoek naar voren dat de LH/testosteron en de FSH/oestradiol ratio's in een enkelvoudig bloedmonster zeer goed gebruikt kunnen worden om onderscheid te maken tussen beide groepen.

Naar aanleiding van dit proefschrift kunnen de volgende conclusies worden getrokken:

- De basale plasmaconcentraties van LH en FSH van geovariëctomeerde teven zijn significant hoger dan die van anoestrische honden
- Om na te gaan of een ovariëctomie bij een hond wel of niet heeft plaatsgevonden, is bepaling van de basale plasma-FSH-concentratie een geschikte methode, aangezien er geen overlap was in de basale plasma-FSH-concentratie bij honden voor en na ovariëctomie
- Zowel de plasmaconcentraties van LH als FSH stijgen na toediening van GnRH bij anoestrische honden, terwijl bij geovariëctomeerde honden alleen een significante stijging van de plasma-LH-concentratie is waar te nemen
- De basale plasma-oestradiol-concentraties vertonen overlap tussen anoestrische en geovariëctomeerde honden
- De plasma-oestradiol-concentratie 120 minuten na toediening van GnRH kan gebruikt worden om onderscheid te maken tussen honden met en zonder functioneel ovarieel weefsel
- Teven met rest ovarieel weefsel hebben in vergelijking met anoestrische teven significant hogere basale plasma-LH-concentraties, ondanks een hogere plasma-oestradiol-concentratie

- Honden met rest ovarieel weefsel hebben een significant hogere basale plasma-LH-concentratie als het interval tussen de ovariëctomie en het voor het eerst optreden van verschijnselen van loopsheid meer dan 3 jaar bedraagt
- De stijging van de plasma-LH-concentratie na toediening van GnRH is lager bij honden met rest ovarieel weefsel in vergelijking met anoestrische en geovariëctomeerde honden
- Bij honden met rest ovarieel weefsel is de basale en/of GnRH-gestimuleerde plasma-oestradiol-concentratie hoger dan de laagste detectielimiet van de oestradiolassay
- Bij honden met een granulosaceltumor (GCT) is de hypofyse-ovarium as veranderd, wat wordt gekenmerkt door relatief hoge plasma-LH-concentraties, ondanks de aanwezigheid van een hoge plasma-oestradiol-concentratie, en een subnormale toename van de plasma-LH-concentratie na toediening van GnRH in vergelijking met anoestrische en geovariëctomeerde teven
- Het relatief hoge percentage honden met rest ovarieel weefsel onder de honden met een GCT wijst mogelijk op een rol voor de verhoogde plasmaconcentraties van LH en/of FSH in de pathogenese van een GCT
- De afgifte van LH en oestradiol bij de honden die met een stoornis in de geslachtsontwikkeling (SGO) die in dit proefschrift beschreven zijn en die alle testiculair of testiculair en ovarieel weefsel in hun gonaden hadden, komt overeen met die van intact mannelijke honden
- De GnRH-stimulatietest met bepaling van de plasma-testosteron-concentratie is zeer bruikbaar om de aanwezigheid van testiculair weefsel in de gonaden van honden met een SGO te identificeren
- De GnRH-stimulatietest met bepaling van de plasma-oestradiol-concentratie kan niet gebruikt worden bij honden met een SGO om na te kunnen gaan of er ovarieel weefsel aanwezig is in de gonade
- De basale plasma-testosteron-concentratie voor gonadectomie is significant hoger dan die na gonadectomie
- GnRH-toediening leidt tot een significante stijging van de plasma-testosteron-concentratie bij teven vóór gonadectomie
- De FSH/oestradiol en LH/testosteron ratio's, bepaald in een enkelvoudig bloedmonster, zijn geschikt om onderscheid maken tussen intacte honden en honden na gonadectomie

Referenties

Achermann JC, Hughes LA. Disorders of sexual development. In: Williams Textbook of endocrinology, 11th edition. Kronenberg HM, Melmed S, Polonsky KS, Larsen PR (Eds). Philadelphia, Saunders Elsevier, 2008, pp. 783-849.

Axnér E, Gustavsson T, Ström Holst B. Estradiol measurement after GnRH-stimulation as a method to diagnose presence of ovaries in the female domestic cat. Theriogenology 2008;70:186-191.

Bosetti C, Negri E, Trichopoulos D, Franceschi S, Beral V, Tzonou A, Parazzini F, Greggi S, La Vecchia C. Long-term effects of oral contraceptives on ovarian cancer risk. Int J Cancer 2002;102:262-265.

Bulun SE, Adashi EY. The physiology and pathology of the female reproductive axis. In: Williams Textbook of Endocrinology 10th edition. Larsen PR, Kronenberg HM, Melmed S, Polonsky KS (Eds.). Saunders, Philadelphia, PA, USA, 2003, pp. 587-664.

Chaffaux S, Chassagnite F, Thibier M. Concentration of LH après stimulation par la gonadoliberine (LRH) chez la chienne et effet de l'ovariectomie. Rec Med Vet 1981;10:725-733.

Chakraborty PK, Fletcher WS. Responsiveness of anoestrus Labrador bitches to GnRH. Proc Soc Exp Biol Med 1977;154:125-126.

Chowdhury M, Steinberger E. Biosynthesis of gonadotropins by rat pituitaries in vitro. J Endocrinol 1975;66:369-374.

Concannon PW. Biology of gonadotropin secretion in adult and prepubertal female dogs. J Reprod Fertil Suppl 1993;47:3-27.

Cotchin E, Marchant J. Animal tumours of the female reproductive tract. Spontaneous and experimental. In: Pathology of the female genital tract, Blaustein A (Ed). Springer-Verlag, New York, 1977, pp. 55-56.

Diaz-Espineira MM, Mol JA, van den Ingh TSGAM, van der Vlught-Meijer RH, Rijnberk A, Kooistra HS. Functional and morphological changes in the adenohypophysis of dogs with induced hypothyroidism: Loss of TSH hypersecretion, hypersomatotropism, hypoprolactinemia, and pituitary enlargement with transdifferentiation. Domest Anim Endocrinol 2008;35:98-111.

Flack MR, Bennett AP, Froehlich J, Anasti JN, Nisula BC. Increased biological activity due to basic isoforms in recombinant human follicle-stimulating hormone produced in a human cell line. J Clin Endocrinol Metab 1994;79:756-760.

Genuth SM. The hypothalamus and pituitary gland. In: Physiology, 5th edition, Berne RM, Levy MN, Koeppen BM, Stanton BA (Eds). Mosby, St. Louis, MO, USA, 2004, pp. 819-859.

De Gier J, Djajadiningrat-Laanen SC, Kooistra HS, Dieleman SJ, Okkens AC. Temporal relationships between plasma concentrations of LH, FSH, estradiol, progesterone, prolactin, and alpha-melanocyte stimulating hormone during the follicular, ovulatory and early luteal phase in the bitch Theriogenology 2006;65:1346-1359.

Graves PE, Surwit EA, Davis JR, Stouffer RL. Adenylate cyclase in human ovarian cancers: sensitivity to gonadotrophins and nonhormonal activators. Am J Obstet Gynecol 1985;153:877-882.

Herron MA. Tumours of the canine genital system. J Am Anim Hosp Assoc 1983;19:981-994.

Hubler M, Hauser B, Meyers-Wallen VN, Arnold S. Sry-negative XX true hermaphrodite in a Basset hound. Theriogenology 1999;51:1391-1403.

Jeffcoate IA. Gonadotropin-releasing hormone challenge to test for the presence of ovaries in the bitch. J Reprod Fertil Suppl 1993;47:536-538.

Joshi AS, Woolf PD. Pituitary hyperplasia secondary to primary hypothyroidism: a case report and a review of the literature. Pituitary 2005;8:99-103.

Junaidi A, Williamson PE, Martin GB, Stanton PG, Blackberry MA, Cummins JM, Trigg TE. Pituitary and testicular endocrine responses to exogenous gonadotropin-releasing hormone (GnRH) and luteinizing hormone in male dogs treated with GnRH agonist implants. Reprod Fertil Dev 2007;19:891-898.

Keri RA, Lozada KL, Abdul-Karim FW, Nadeau JH, Nilson JH. Luteinizing hormone induction of ovarian tumors: oligogenic differences between mouse strains dictates tumor disposition. Proc Natl Acad Sci USA 2000;97:383-387.

Klein MK. Tumours of the female reproductive system. In: Small Animal Clinical Oncology, Withrow SJ, MacEwen EG (Eds). WB Saunders, Philadelphia, 2001, pp. 445-454.

Knol BW, Dieleman SJ, Bevers MM, Brom van den WE. GnRH in the male dog: dose-response relationships with LH and testosterone. J Reprod Fertil 1993;98:159-161.

Konishi I, Kuroda H, Mandai M. Review: gonadotrophins and development of ovarian cancer. Oncology 1999;57:45-48.

Kooistra HS, Okkens AC, Bevers MM, Popp-Snijders C, van Haaften B, Dieleman SJ, Schoemaker J. Concurrent pulsatile secretion of luteinizing hormone and follicle-stimulating hormone during different phases of the estrous cycle and anestrus in beagle bitches. Biol Reprod 1999;60:65-71.

Kuiper H, Bunck C, Günzel-Apel AR, Drögemüller C, Hewicker-Trautwein M, Distl O. SRY-negative XX sex reversal in a Jack Russel Terrier: a case report. Vet J 2005;169:116-7.
La Vecchia C. Epidemiology of ovarian cancer: a summary review. Euro J Canc Prev 2001;10:125-129.
Liu JH, Yen SSC. Induction of midcycle gonadotrophin surge by ovarian steroids in women: a critical evaluation. J Clin Endocrinol Metab 1983;57:797-802.
Löfstedt RM, Vanleeuwen JA. Evaluation of a commercially available luteinizing hormone test for its ability to distinguish between ovariectomized and sexually intact bitches. J Am Vet Med Assoc 2002;220:1331-1335.
Meij BP, Mol JA, Hazewinkel HAW, Bevers MM, Rijnberk A. Assessment of a combined anterior pituitary function test in beagle dogs: rapid sequential intravenous administration of four hypothalamic releasing hormones. Domest Anim Endocrinol 1996;13:161-170.
Melniczek JR, Damhach D, Prociuk U, Jezyk PF, Henthorn PS, Patterson DF, Giger U. Sry-negative XX sex reversal in a family of Norwegian Elkhounds. J Inter Med 1999;13:564-569.
Meyers-Wallen VN, Bowman L, Acland GM, Palmer VL, Schlafer D, Fajt V. Sry-negative XX sex reversal in the German shorthaired pointer dog. J Hered 1995a;*86:*369-374.
Meyers-Wallen VN, Palmer VL, Acland GM, Herschfield B. Sry-negative XX sex reversal in the American Cocker Spaniel Dog. Mol Reprod Dev 1995b;41:300-305.
Meyers-Wallen VN, Schlafer D, Barr I, Lovell-Badge R, Keyzner A. Sry-negative XX sex reversal in purebred dogs. Mol Reprod Dev 1999;53:266-273.
Moyle WR, Campbell RK. Gonadotropins. In: Reproductive Endocrinology, Surgery and Technology, Adashi EY, Rock JA, Rosenwaks Z (Eds), Lippincott-Raven Publishers, Philadelphia, 1995, pp. 683-724.
Muyan M, Ryzmkiewicz DM, Boime I. Secretion of lutropin and follitropin from transfected GH cells: evidence for separate secretory pathways. Mol Endocrinol 1994;8:1789-1797.
Nelson LR, Bulun SE. Estreogen production and action. J Am Acad Dermatol Suppl 2001;45:116-124.
Ness RB, Cramer DW, Goodman MT, Kjaer SK, Mallin K, Mosgaard BJ, Purdie DM, Risch HA, Vergona R, Wu AH. Infertility, fertility drugs, and ovarian cancer: a pooled analysis of case-control studies. Am J Epidemiol 2002;155:217-224.
Okkens AC, Dieleman SJ and vd Gaag I. Gynaecological complications following ovariohysterectomy in dogs, due to (1) Partial removal of the ovaries (2) Inflammation of the uterocervical stump. Tijdschr Diergeneeskd 1981;106:1142-1158.
Okkens AC, Teunissen JM, Van Osch W, Van Den Brom WE, Dieleman SJ & Kooistra HS. Influence of litter size and breed on the duration of gestation in dogs. J Reprod Fertil Suppl 2001;57:193–197.
Olson PN, Mulnix JA, Nett TM. Concentrations of luteinizing hormone and follicle-stimulating hormone in the serum of sexually intact and neutered dogs. Am J Vet Res 1992;53:762-766.
Patnaik AK, Greenlee PG. Canine ovarian neoplasms: A clinicopathologic study of 71 cases, including histology of 12 granulosa cell tumours. Vet Pathol 1987;24:509-514.
Pluhar GE, Memon MA, Wheaton LG. Granulosa cell tumour in an ovariohysterectomized dog. J Am Vet Med Assoc 1995;207:1063-1065.
Purswell BJ, Wilcke JR. Response to gonadotrophin-releasing hormone by the intact male dog: Serum testosterone, luteinizing hormone and follicle-stimulating hormone. J Reprod Fertil 1993;47:335-341.
Reichler IM, Pfeiffer E, Piché CA, Jöchle W, Roos M, Hubler M, Arnold S. Changes in plasma gonadotropin concentrations and urethral closure pressure in the bitch during the 12 months following ovariectomie. Theriogenology 2004;62:1391-1402.
Reimers TJ, Phemister RD, Niswender GD. Radioimmunological measuremnt of follicle stimulating hormone and prolactin in the dog. Biol Reprod 1978;19:673-679.
Risma KA, Clay CM, Nett TM, Wagner T, Yun J, Nislon JH. Targeted overexpression of luteinizing hormone in transgenic mice leads to infertility, polycystic ovaries, and ovarian tumours. Proc Natl Acad Sci USA 1995;92:1322-1326.
Sarlis NJ, Brucker-Davis F, Doppman JL and Skarulis MC. MRI-demonstrable regression of a pituitary mass in a case of primary hypothyroidism after a week of acute thyroid hormone therapy. J Clin Endocrinol Metab 1997;82:808-811.
Scott RT, Hofmann GE. Prognostic assessment of ovarian reserve. Fertil Steril 1995;63:1-11.
Scott RT, Beatse SN, Illions EH, Snyder RR. Use of the GnRH agonist stimulation test in the diagnosis of ovarian remnant syndrome. A report of three cases. J Reprod Med 1995;40:143-146.
Schaefers-Okkens AC, Kooistra HS. Ovaries. In: Clinical Endocrinology of Dogs and Cats. Rijnberk A, Kooistra HS (Eds). Hannover, Schlütersche, 2010, pp. 203-234.
Schildkraut JM, Schwingl PJ, Bastos E, Evanoff A, Hughes C. Epithelial ovarian cancer risk among women with polycystic ovary syndrome. Obstet Gynecol 1996;88:554-559.

Schwartz NB. The 1994 Stevenson Award Lecture. Follicle-stimulating hormone and luteinizing hormone: a tale of two gonadotropins. Can J Physiol Pharmacol 1995;73:675-684.

Sivacolundhu RK, O'Hara AJ, Read RA. Granulosa cell tumour in two spayed bitches. Aust Vet J 2001;79:173-176.

Stouffer RL, Grodin MS, Davis JR, Surwit EA. Investigation of binding sites for follicle-stimulating hormone and chorionic gonadotropin in human ovarian cancers. J Clin Endocrinol Metab 1984;59:441-446.

Tennent BJ, Shultz KL, Sundberg JP, Beamer WG. Ovarian granulosa cell tumorigenesis in SWR-derived F1 hybrid mice: preneoplastic follicular abnormality and malignant disease progression. Am J Obstet Gynecol 1990;163:625-634.

Toner JP. The significance of elevated FSH for reproductive function. Baillieres Clin Obstet Gynaecol 1993;7:283-295.

Unkila-Kallio L, Tiitinen A, Wahlström T, Lehtovirta P, Leminen A. Reproductive features in women developing ovarian granulosa cell tumour at a fertile age. Hum Reprod 2000;15:589-593.

Van Haaften B, Bevers MM, van den Brom WE, Okkens AC, van Sluijs FJ, Willemse AH, Dieleman SJ. Increasing sensitivity of the pituitary to GnRH from early to late anoestrus in the beagle bitch. J Reprod Fertil 1994;101:221-225.

Vidal S, Horvath E, Kovacs K, Cohen SM, Lloyd RV and Scheithauer BW. Transdifferentation of somatotrophs to thyrotrophs in the pituitary of patients with protracted primary hypothyroidism. Virchows Arch 2000;436:43-51.

Dankwoord

Mijn proefschrift is tot stand gekomen dankzij de enthousiaste inzet, grondigheid en volhardendheid van velen, die ik hierbij graag hartelijk wil bedanken. In dit dankwoord wil ik stilstaan bij een aantal van hen, zonder de inzet van de niet-genoemde te onderschatten.

Mijn co-promotor, Dr. Auke Schaefers-Okkens.
Beste Auke, wat is het geweldig dat de "GnRH-ordner" zoveel fantastische bevindingen heeft opgeleverd, waarvan vele ook in de kliniek toepasbaar zijn! Ik wil je ontzettend bedanken voor je begeleiding, kritische commentaar en wetenschappelijke aanvullingen. Maar ook voor de goede en confronterende gesprekken over de balans tussen privé en werk, het belang van het gezin, en de zorg voor de kinderen. Je bent voor mij een goed voorbeeld hoe je de zorg voor het gezin en toewijding aan het werk uitstekend kunt combineren, hetgeen onder andere blijkt uit de overvloed aan wetenschappelijke artikelen die op je naam staan. Ik vind het een groot voorrecht om met je te mogen werken en van je te leren.

Mijn co-promotor, Dr. Hans Kooistra.
Beste Hans, je wetenschappelijke gedrevenheid, zorgvuldigheid, en perfectionisme zijn een voortreffelijk voorbeeld voor mij. Als ik weer eens dacht dat een manuscript het eindstadium wel had bereikt, kwam ik vaak bedrogen uit als ik, na jouw kritische blik, de aanvullingen en suggesties voor aanpassing ontving. Soms frustrerend, maar aan de andere kant had ik geen betere leerschool kunnen hebben. Ik ben je daar zeer dankbaar voor. Maar dat is niet het enige. Al geruime tijd ben je mijn leidinggevende en ik voel me bevoorrecht om iemand te hebben die zo voor mijn belangen vecht en mijn loopbaan, waar mogelijk, voortreffelijk ondersteunt. Ik vind het ontzettend prettig om met je samen te werken, niet alleen voor wat betreft het onderzoek, maar ook als collega in de endocrinologie. De goede sfeer bij deze discipline bepalen een zeer belangrijk deel van mijn werkvreugde.

Mijn promotor, Prof. Dr. Jan Rothuizen.
Beste Jan, ik wil je hartelijk danken voor de onvoorwaardelijke steun die ik van je heb gekregen in het voltooien van mijn proefschrift, de vrijheid die je me daarbij gegeven hebt, en je grenzeloze vertrouwen in een goede afloop. Daarnaast ben ik je ook veel dank verschuldigd voor de rol die je gespeeld hebt in mijn loopbaan. Zo heb je me de mogelijkheid gegeven om een specialistenopleiding te volgen en vertrouwde je me het trekkerschap van de patiëntenzorgkliniek toe. Je progressieve en vooruitstrevende manier van leidinggeven zijn zeer inspirerend voor mij.

Mijn paranimf, Sara Galac.
Beste Sara, onze samenwerking, zowel binnen als buiten de endocrinologie, is geweldig. We hebben er beide veel plezier in en vullen elkaar op verschillende gebieden aan. Het is ontzettend prettig om met je samen te werken en ik ben blij dat we een goede vriendschap hebben opgebouwd, waar ik veel waarde aan hecht. Je bent een gedreven collega, een geweldige persoonlijkheid, en een fantastische onderzoekster.

Mijn paranimf, Kees Schellens.
Beste Kees, ik vind het erg leuk dat jij mijn paranimf wil zijn. Onze vriendschap startte in 2003 toen je begon met de specialistenopleiding “interne geneeskunde van gezelschapsdieren”. We hebben een aantal roulaties gezamenlijk doorlopen, wat echt een geweldige tijd was. Je opgewektheid, vrolijkheid en spontaniteit zijn verademend. Je staat altijd klaar om iemand te helpen en bent nergens te beroerd voor. Ook kan ik altijd bij je terecht om weer eens lekker bij te kletsen onder het genot van een lekker “kopske” koffie!

Jeffrey de Gier.
Beste Jeffrey, we hebben elkaar leren kennen in de Dierenkliniek in Eersel, waar ik als je dierenartsassistente werkzaam was in de weekenden en vakanties. Daar hebben we beide kennis gemaakt met de grote variëteit op het gebied van de voortplanting van de hond. We maken allebei een proefschrift op dit interessante gebied waardoor we opnieuw intensief zijn gaan samenwerken. Het is altijd prettig om met je te werken. Je relativeringsvermogen, enthousiasme, en kritische houding waren zeer welkom tijdens het maken van de manuscripten en je hulp bij de statistische analyses kwam als een zegen. Dank je wel voor de gezelligheid en leuke werksfeer en ik wil je heel erg veel succes wensen met de laatste loodjes van je proefschrift.

Niek Beijerink.
Beste Niek, tijdens je excellent tracé hebben we elkaar leren kennen en dit heeft geleid tot de publicatie van twee mooie manuscripten. Nu werken we vol enthousiasme samen in de patiëntenzorgkliniek wat ik heel erg prettig vind. Je werkhouding en gedrevenheid zouden een voorbeeld moeten zijn voor vele van ons. Ik vind het erg jammer dat je ons gaat verlaten, maar begrijp je keuze volledig. Ik wil je het allerbeste toewensen met de nieuwe stappen in je carrière en wie weet kruisen onze paden nog eens.

Christine Oei.
Beste Christine, alle hormoonbepalingen die in dit proefschrift beschreven zijn, zijn allemaal met veel bezieling door jou bepaald. Maar daarnaast heb je ook veel werk verricht in het valideren van nieuwe assays, waarbij je met allerlei oplossingen kwam voor problemen waarvan we even niet meer wisten hoe deze aan te pakken. Ik wil je hier hartelijk voor bedanken.

Stef Dieleman, Carla Zijlstra, Theo van Haeften, Elaine Naan, Edwin Veldhuis Kroeze, Guy Grinwis, Bart Spee en Karin Wolthers.
Beste medeauteurs, ik wil jullie allen hartelijk danken voor de onmisbare toevoegingen aan en inzet in het perfectioneren van de manuscripten.

Harry van Engelen en Manon Kramer.
Beste Harry en Manon, ik wil jullie beide innig danken voor het perfect coördineren en zorgvuldig afnemen van de stimulatietesten bij de honden van mijn laatste onderzoek. Zonder al jullie werk was dit manuscript nooit tot stand gekomen.

Anjolieke Dertien en Harry Otter.
Beste Anjolieke en Harry, dank jullie wel voor de prachtige cover en gedegen opmaak van mijn proefschrift. Het is geworden zoals ik voor ogen had.

Mijn collega's en oud-collega's van het Departement Geneeskunde van Gezelschapsdieren.
In al de jaren dat ik nu werkzaam ben op het Departement heb ik vele collega's mogen ontmoeten, waarvan een aantal de kliniek inmiddels ook weer hebben verlaten. Er zijn allerlei gesprekken gevoerd over het wel en wee van het promotieonderzoek, het kliniekwerk, de privésituatie en het specialistenwerk, waarbij sommige gesprekken aangrijpend waren, andere juist verlichtend, en weer andere zakelijk of juist heel gezellig.

Het is erg fijn om in een prettige sfeer met elkaar samen te kunnen werken en daar dragen veel van jullie aan bij, waarvoor mijn grote dank.

Francine en Marco Timmer.
Beste Francine en Marco, waar zou ik zijn zonder jullie? Mijn dank is heel erg groot voor jullie liefdevolle steun aan en opvang van de meiden, als ik weer eens weg moest voor mijn werk, vast stond in de file, of een van de twee meisjes ziek was terwijl ik geen vrij kon nemen. Zonder jullie zou dit allemaal niet haalbaar zijn geweest. Het is ontroerend om te zien hoe dol jullie op de kinderen zijn en zij op jullie. Ze hadden geen betere “noma” en “nopa” kunnen treffen!

Mijn familie, schoonfamilie en beste vriendinnen.
Dank jullie wel voor het luisteren naar mijn verhalen, waarschijnlijk niet altijd boeiend voor jullie, over de gang van zaken aangaande mijn proefschrift. De steun en het begrip die ik van jullie heb gekregen heeft mij heel erg goed gedaan. Jullie zijn mijn basis, mijn veilige haven, waar ik altijd op terug kan vallen.

Lieve pap en mam.
Er zijn te weinig woorden om uit te drukken hoe ontzettend dankbaar ik ben voor alles wat jullie doen. Er werd buitengewoon hard gewerkt om ons, de kinderen, alle mogelijkheden en kansen te geven en jullie ondersteunen en stimuleren ons om alles eruit te halen wat erin zit. Ik prijs me zeer rijk dat ik zoveel liefde, ondersteuning en motivering heb gekregen. Oneindig veel dank gaat uit naar jullie.

Lieve Isabelle en Annelie.
Mijn meisjes, mijn prinsesjes, mijn oogappeltjes, mijn alles. Het leven heeft geen gouden randje gekregen sinds jullie er zijn, maar is geklonken in puur goud. Wat maken jullie mij intens blij, dankbaar, verwonderd, en ontzettend kwetsbaar.

Lieve Laurens.
Ik heb nooit durven dromen zo gelukkig te kunnen zijn met iemand, maar mijn dromen zijn ver, ver overtroffen. Je liefde, steun, eerlijkheid, humor en relativeringsvermogen zijn geweldig en een enorme houvast geweest bij het maken en afronden van mijn proefschrift. Ik hou ontzettend veel van je; je bent de liefde van mijn leven en wat voel ik me compleet als ik bij je ben. Ik hoop met heel mijn hart dat wij altijd zo gelukkig blijven en ons heerlijke, fantastische leven samen door mogen zetten.

Curriculum Vitae

De schrijfster van dit proefschrift is op 17 december 1974 in Eindhoven geboren. Zij is de derde dochter in een gezin bestaande uit vier meisjes en een jongen. Ze is opgegroeid in het Brabantse dorpje Luyksgestel, waar haar ouders een boerenbedrijf runden. Daarnaast was haar vader voltijds buschauffeur, terwijl haar moeder zorgde voor de boerderij. Opa, die bij de familie inwoonde, maakte gedurende 21 jaar deel uit van het gezin. Ze heeft de lagere school doorlopen in Luyksgestel, waarna ze naar het VWO ging (Hertog Jan College te Valkenswaard). Na uitgeloot te zijn voor de studie Diergeneeskunde in Nederland vetrok ze naar de Rijksuniversiteit van Gent in België om daar de opleiding tot dierenarts te volgen. In 2001 heeft ze deze opleiding met onderscheiding afgerond. Na haar opleiding begon ze als roulant aan dezelfde universiteit en daarnaast werkte ze in het weekend als dierenarts in een eerstelijns-praktijk. In 2002 startte ze met haar specialistenopleiding Interne Geneeskunde van Gezelschapsdieren bij het Departement Geneeskunde van Gezelschapsdieren van de Faculteit Diergeneeskunde, Universiteit Utrecht. In 2006 heeft ze deze opleiding met succes afgerond door het behalen van het Europees specialistenexamen waarna ze zich Diplomate of the European College of Veterinary Internal Medicine mag noemen. In datzelfde jaar is ze begonnen met haar promotieonderzoek en sinds 2010 is ze verbonden als staflid aan ditzelfde departement. Ze is daarnaast sinds 2006 actief als bestuurslid van de Groep Geneeskunde Gezelschapsdieren en ze zit in de programma-commissie van de Permanente Educatie Gezelschapsdieren (PEGD). In 2006 is ze getrouwd met Laurens van Zuijlen. In 2007 werd Isabelle en in 2009 werd Annelie geboren en in augustus van dit jaar verwachten zij hun derde kindje.

Curriculum Vitae

The author of this thesis was born on December 17th 1974 in Eindhoven, the Netherlands. She is the third daughter in a family consisting of four girls and a boy. She grew up in Luyksgestel, a village in the south of the Netherlands where her parents had a farm. Her father had a fulltime job as bus driver and her mother managed the farm. Her grandfather lived with the family for 21 years. She attended primary school in Luyksgestel and high school at the Hertog Jan College in Valkenswaard. She studied veterinary medicine at the University of Ghent, Belgium, and graduated in 2001. She started an Internship at the same university, while she worked in a primary care private practice during the weekends. In 2002 she commenced a residency in Internal Medicine at the Department of Clinical Sciences of Companion Animals, Utrecht University. She passed the European exam in 2006 and was awarded the title Diplomate of the European College of Veterinary Internal Medicine. She started her PhD study in that same year and since 2010 has been a staff member at the Department of Clinical Sciences of Companion Animals at Utrecht University. She is a board member of the Netherland's Association of Companion Animal Medicine (NACAM). In 2006 she married Laurens van Zuijlen. They have two daughters Isabelle born in 2007 and Annelie born in 2009. They are expecting their third child in august of this year.

List of Publications:

JJCWM Buijtels, S Daminet. Chronische Nierinsufficiëntie bij de hond en de kat. Deel 1: Etiologie, symptomen en pathofysiologie, Vlms Diergeneeskd Tijdschr 2002;71: 295-304

JJCWM Buijtels, S Daminet. Chronische Nierinsufficiëntie bij de hond en de kat Deel 2: Behandeling, prognose en Conclusie, Vlms Diergeneeskd Tijdschr 2002;71:305-316.

JJCWM Buijtels, IAPG Kurvers, S Galac, EA Winter, HS Kooistra. Carbimazolzalf ter behandeling van hyperthyreoïdie bij de kat. Tijdschr Diergeneeskd 2006;131:478-482.

JJCWM Buijtels, EJB Veldhuis-Kroeze, G Voorhout, CJMM Schellens, JJ van Nes. Cerebellaire corticale degeneratie bij een Amerikaanse Staffordshire terriër. Tijdschr Diergeneeskd 2006;131:518-522.

JJCWM Buijtels, NJ Beijerink, HS Kooistra, SJ Dieleman, AC Okkens. Effects of gonadotrophin releasing hormone administration on the pituitary-ovarian axis in six anoestrous versus six ovariectomized bitches. Reprod Dom Anim 2006;41:555-61.

NJ Beijerink**, JJCWM Buijtels**, AC Okkens, HS Kooistra, SJ Dieleman. Basal and GnRH-induced secretion of FSH and LH in anestrous versus ovariectomized bitches. Theriogenology 2007;67:1039-45.

JJCWM Buijtels, J de Gier, T van Haeften, HS Kooistra, B Spee, EJB Veldhuis Kroeze, C Zijlstra, AC Okkens. Minimal external masculinisation in a SRY-negative XX male Podenco dog. Reprod Dom Anim 2009;44:751-6

HS Kooistra, S Galac, **JJCWM Buijtels,** BP Meij. Endocrine diseases in animals. Horm Res 2009;71:144147.

S Galac, **JJCWM Buijtels,** HS Kooistra. Urinary corticoid:creatinine ratios in dogs with pituitary-dependent hypercortisolisme during trilostane treatment. J Vet Intern Med 2009;23:1214-1219.

S Galac, **JJCWM Buijtels**, JA Mol, HS Kooistra. Effects of trilostane on the pituitary-adrenocortical and renin-aldosterone axis in dogs with pituitary-dependent hypercortisolism. Vet J 2010;183:75-80.

BP Meij, E Auriemma, G Grinwis, **JJCWM Buijtels,** HS Kooistra. Successful treatment of acromegaly in a diabetic cat with transsphenoidal hypophysectomy. J Fel Med Surg 2010;12:406-410.

JJCWM Buijtels, J De Gier, HS Kooistra, EJB Veldhuis Kroeze, AC Okkens. Alterations of the pituitary-ovarian axis in dogs with a functional granulosa cell tumor. Theriogenology 2010;73:11-19.

JJCWM Buijtels, J de Gier, HS Kooistra, EC Naan, CHY Oei, AC Okkens. The pituitary-ovarian axis in dogs with remnant ovarian tissue. Theriogenology 2011;75:742-751.