J. Comp. Path. 2006, Vol. 134, 182–189

Available online at www.sciencedirect.com

SCIENCE DIRECT®

ELSEVIER

www.elsevier.com/locate/jcpa

E-cadherin Expression in Canine Malignant Mammary Tumours: Relationship to Other Clinico-Pathological Variables

A. J. F. Matos*, C. Lopes*, J. Carvalheira*, M. Santos*, G. R. Rutteman† and F. Gärtner*‡

**Institute of Biomedical Sciences of Abel Salazar (ICBAS) and ‡Institute of Pathology and Molecular Immunology (IPATIMUP), University of Porto, Portugal, and †Clinic of Companion Animals, Utrecht University, Utrecht, The Netherlands*

Summary

The relationship between E-cadherin epithelial expression, as detected by immunohistochemical methods, and other clinico-pathological characteristics of canine malignant mammary tumours was studied in 77 tumours surgically removed from 45 female dogs. The immunohistochemical assessment was based on the estimated percentage of epithelial cells with membranous labelling. Reduction of E-cadherin expression was significantly related to size and ulceration of tumours but not to fixation to skin or underlying tissue; it was also related to lymph node metastasis, necrosis and infiltrative growth. Histological type (but not histological grade) was related to E-cadherin expression, with solid tumours more frequently lacking expression and tubulopapillary tumours showing increased expression as compared with the other types. The significant relationship between E-cadherin and other known factors of poor prognosis suggests that the loss of E-cadherin expression may have prognostic value in canine malignant mammary tumours.

Keywords: dog; E-cadherin; malignancy; mammary tumours; tumour

Introduction

Cadherins are calcium-dependent adhesion molecules, mediating homotypic cell–cell adhesion. Their main function is the maintenance of normal tissue architecture, particularly as components of the adherents junctions. The classical cadherins include E-, P- and N-cadherin. By virtue of its presence as a component of the adherents junctions, E-cadherin is the major cadherin involved in epithelial cellular adhesion. It has an extra-cellular domain (N terminal) that binds with high specificity to similar domains on adjacent cells, and an intracellular domain (C terminal) that binds to cytoskeleton proteins through catenins.

Since the majority of animal tumours, including those of man and the dog (Priester and MacKay, 1980) are of epithelial origin, E-cadherin has been widely studied in relation to its role in tumorigenesis. The expression and function of E-cadherin are frequently altered in human epithelial tumours, including those of the breast (Gamallo *et al.*, 1993; Lipponen *et al.*, 1994; Guriec *et al.*, 1996; Siitonen *et al.*, 1996; Charpin *et al.*, 1997; Zschiesche *et al.*, 1997; Asgeirsson *et al.*, 2000; Heimann *et al.*, 2000; Reis-Filho *et al.*, 2002; Kowalsky *et al.*, 2003).

The relationships between E-cadherin expression, other prognosticators of human breast cancer, and outcome in affected patients are, however, debatable.

Correspondence to: F. Gärtner.

0021-9975/$ - see front matter
doi:10.1016/j.jcpa.2005.10.004

Thus, some authors demonstrated significant associations between E-cadherin expression and histological type (Gamallo *et al.*, 1993; Guriec *et al.*, 1996; Charpin *et al.*, 1997; Zschiesche *et al.*, 1997), grade (Gamallo *et al.*, 1993; Guriec *et al.*, 1996; Siitonen *et al.*, 1996; Charpin *et al.*, 1997; Zschiesche *et al.*, 1997) hormone receptor status (Siitonen *et al.*, 1996; Charpin *et al.*, 1997; Gillet *et al.*, 2001), lymph node metastasis (Siitonen *et al.*, 1996; Zschiesche *et al.*, 1997), and growth fraction (MIB1), P53 and c-erbB-2 expression (Charpin et al., 1997); others could find no significant associations with hormone receptors (Guriec *et al.*, 1996; Kovacs *et al.*, 2003), expression of c-erbB-2 (Zschiesche *et al.*, 1997), lymph node status, grade (Kovacs *et al.*, 2003), or clinical factors such as age of the patients, menopausal status and size of the tumour (Guriec *et al.*, 1996; Kovacs *et al.*, 2003).

The loss of E-cadherin expression was associated with low survival in some human breast cancer studies (Guriec *et al.*, 1996; Siitonen *et al.*, 1996; Asgeirsson *et al.*, 2000). One study demonstrated that E-cadherin expression was a better identifier, in terms of disease-free interval, of patients with a poor prognosis than those with a good prognosis (Heimann *et al.*, 2000). In two other studies, expression of E-cadherin, in grade I infiltrating ductal carcinomas and in grade III breast carcinomas, was associated with poor survival (Tan *et al.*, 1999; Gillet *et al.*, 2001).

Two studies of canine mammary tumours found an association between E-cadherin expression and tumour type and differentiation (Restucci *et al.*, 1997; Reis *et al.*, 2003) but the possible influence of other prognostic variables was not examined. The aim of the present study was to examine the relationship between E-cadherin epithelial expression, as detected by immunohistochemical methods, and other clinico-pathological characteristics of canine malignant mammary tumours.

Materials and Methods

Specimens

Seventy-seven malignant mammary tumours and 131 local and regional lymph nodes were surgically removed from 45 female dogs aged from 5 to 14 years (mean, 10.5 years), of various pure or mixed breeds. The specimens were fixed in 10% neutral buffered formalin.

Before removal, each tumour was observed clinically and palpated, and the following data were recorded: location in the mammary chain, dimensions, skin ulceration and cutaneous and underlying tissue fixation. Small tumours (<1 cm) were included in their entirety, while in larger tumours sequential segments 5 mm apart were cut to provide tissue blocks. After dehydration and embedment in paraffin wax, sections (3 μm) were cut from each block. One section was stained with haematoxylin and eosin and selected sections, representative of the tumour type (and free of necrosis, haemorrhage and inflammatory cell infiltrates) were used for E-cadherin immunohistochemistry (IHC).

From each local and regional lymph node, longitudinal sections (3 μm) were cut, one being stained with haematoxylin and eosin (HE) and adjacent sections being used for cytokeratin IHC.

Histological Examination of the Tumours

The tumours were classified independently by two observers from HE-stained sections on the basis of the diagnostic criteria of the World Health Organization classification of tumours in domestic animals (Misdorp *et al.*, 1999). The same sections were used to determine the histological grade (grades I, II or III), according to the Nottingham method for human breast tumours (Elston and Ellis, 1998); the grade was based on the assessment of three morphological features, namely, tubule formation, nuclear pleomorphism and mitotic counts. Each feature was assessed and scored as 1 (slight), 2 (moderate) or 3 (marked) giving possible totals of 3 to 9 points. A total of 3,4 or 5 points was considered to indicate grade I; 6 or 7 points indicated grade II and 8 or 9 points indicated grade III.

The presence of intra-tumoral necrosis was also registered. Each tumour was assessed for the mode of growth and classified as either (1) expansive, when it was contained within a capsule, or (2) infiltrative, when there was either no capsule or the capsule (but not lymphatic or blood vessels) showed signs of invasion by tumour cells, or (3) invasive, when invasion of lymphatic or blood vessels was observed.

Lymph Node Cytokeratin IHC

Lymph node sections adjacent to those used for HE staining were immunolabelled by the modified avidin–biotin-peroxidase complex (ABC) method (Hsu *et al.*, 1981). The following primary antibodies were used: anti-pancitokeratin antibody AE1/AE3 (Zymed Laboratories, S. Francisco, California, USA), diluted 1 in 50; and anti-cytokeratin 14 (clone LL002-Serotec Laboratories, Oxford, UK), diluted 1 in 10. Sections (3 μm) thick were cut from formalin-fixed paraffin wax-embedded tissue and dewaxed; antigen was then recovered by immersion

in target retrieval solution (Dako, Glostrup, Denmark) diluted 1 in 10 in distilled water, for 30 min at 100 °C in a water bath. The slides were cooled for 20 min at room temperature and rinsed twice in triphosphate buffered saline (TBS) for 5 min. Endogenous peroxidase activity was blocked by treating with hydrogen peroxide 3% in methanol for 10 min. Non-specific staining was eliminated by incubating the sections with normal rabbit serum diluted 1 in 5 in TBS containing bovine serum albumin (BSA) 10% (Dako), in a humid chamber for 20 min at room temperature. Excess serum was removed and the sections were incubated with the specific primary antibody overnight at 4 °C, in a humid chamber. They were then incubated for 30 min with a 1 in 200 dilution of biotin-labelled anti-mouse secondary antibody (Dako), followed by incubation for 30 min with the avidin–biotin complex (Dako) diluted 1 in 100. Sections were rinsed thoroughly with phosphate-buffered saline between each step of the procedure. Colour was developed for up to 7 min at room temperature with a freshly prepared solution of 3,3′-diaminobenzidine and the sections were then lightly counterstained with haematoxylin, dehydrated, and mounted. For negative control purposes the primary antibody was replaced by a mouse IgG1 antibody-clone Dak-Go1 (Dako). Positive controls consisted of sections from canine mammary tissue known to express AE1/AE3 and cytokeratin 14.

Lymph nodes were classified independently by two observers from sections stained with HE and from those immunolabelled for cytokeratins, according to the presence of cancer cells (positive or negative). When there was disagreement, a consensus diagnosis was reached with a multihead microscope.

E-cadherin IHC

Tumour sections adjacent to those used for HE-staining were examined immunohistochemically as described above, except that (1) after dewaxing and rehydration the sections were treated with Extran (Merck, Frankfurt, Germany) 0.05% in distilled water for 10 min in a microwave oven at 750 W, (2) the primary antibody consisted of monoclonal mouse anti-human E-cadherin, clone 4A2C7 (Zymed, S. Francisco, California, USA), and (3) the positive controls consisted of sections from normal canine mammary tissue and from mammary tissue adjacent to neoplastic tissue.

The IHC results were assessed on the basis of the estimated percentage of epithelial cells with membranous labelling (positive cells). The slides were examined independently by two observers (A.M. and F.G.) and when there was disagreement, a consensus was reached by means of a multihead microscope. Normal mammary tissue adjacent to the tumour was used in each slide as an internal control. On the basis of the percentage of positive cells, the tumours were grouped as follows: >75%; 50–75%; 25–50%; <25%.

Statistical Methods

One-way non-parametric analysis of variance (ANOVA) procedures (SAS, 1989) were used. Ranks were obtained by the Wilcoxon scores method and the significance of the difference between the medians of the groups was assessed

Table 1
E-cadherin expression in canine malignant mammary tumours and its relation to clinical variables

		Number (and %) of tumours showing E-cadherin immunolabelling in the stated percentage of cells				
Clinical variables	*Number of tumours*	*<25%*	*25–50%*	*50–75%*	*> 75%*	*P value**
Size						<0.01
<3 cm	55	3 (5%)	7 (13%)	14 (25%)	31 (56%)	
3–5 cm	10	1 (10%)	1 (10%)	2 (20%)	6 (60%)	
> 5 cm	12	4 (33%)	5 (42%)	0	3 (35%)	
Ulceration						<0.03
Absent	68	6 (9%)	11 (16%)	14 (21%)	37 (54%)	
Present	9	3 (33%)	2 (22%)	2 (22%)	2 (22%)	
Skin fixation						NS
No	61	6 (10%)	9 (15%)	14 (23%)	32 (52%)	
Yes	16	3 (19%)	4 (25%)	2 (13%)	7 (43%)	
Underlying tissue fixation						NS
No	71	7 (10%)	11 (16%)	16 (23%)	37 (52%)	
Yes	6	2 (33%)	2 (33%)	0	2 (33%)	

*Chi-square test for differences between medians of the groups. NS, not significant ($P<0.05$).

Table 2
E-cadherin expression in canine malignant mammary tumours and correlation with pathological variables

Pathological variables	*Number of tumours*	*Number (and %) of tumours showing E-cadherin immunolabelling in the stated percentage of cells*				*P* value*
		<25%	*25–50%*	*50–75%*	*>75%*	
Histological type						<0.002
Carcinosarcoma	12	4 (33%)	2 (17%)	1 (8%)	5 (42%)	
Solid carcinoma	17	2 (12%)	5 (29%)	7 (41%)	3 (18%)	
Mucinous carcinoma	4	2 (50%)	1 (25%)	0	1 (25%)	
Complex carcinoma	16	0	2 (13%)	5 (31%)	9 (56%)	
Tubulopapillary carcinoma	19	0	2 (11%)	3 (16%)	14 (74%)	
Carcinoma in benign tumour	4	0	1 (25%)	0	3 (75%)	
Spindle cell carcinoma	2	0	0	0	2 (100%)	
In-situ carcinoma	2	0	0	0	2 (100%)	
Anaplastic carcinoma	1	1 (100%)	0	0	0	
Mode of growth						<0.002
Expansive	25	0	4 (16%)	3 (12%)	18 (72%)	
Infiltrative	42	4 (10%)	8 (19%)	9 (21%)	21 (50%)	
Vessel invasion	10	4 (40%)	1 (10%)	4 (40%)	1 (10%)	
Lymph node metastasis						<0.002
No	51	1 (2%)	7 (14%)	12 (24%%)	31 (61%)	
Yes	18	3 (17%)	6 (33%)	3 (17%)	6 (33%)	
Histological grade						NS
I	16	0	1 (6%)	3 (19%)	12 (75%)	
II	34	3 (9%)	8 (24%)	10 (29%)	13 (38%)	
III	27	6 (22%)	4 (15%)	3 (11%)	14 (52%)	
Necrosis						<0.02
Absent	36	1 (3%)	6 (17%)	6 (17%)	23 (63%)	
Present	41	8 (20%)	7 (17%)	10 (24%)	16 (39%)	

with the Kruskal-Wallis test (chi-square), after a correction for continuity of 0.5.

Results

In this series of 77 malignant tumours, 37 (48%) showed reduction of E-cadherin expression. In eight (10.4%) of these 37 tumours, <25% of epithelial cells were E-cadherin positive; in 13 (16.9%), 25–50% were positive; and in 16 (20.7%), 50–75% were positive. In all slides, adjacent normal mammary tissue showed intense labelling in >75% of epithelial cells.

The expression of E-cadherin according to clinical variables is summarized in Table 1, and according to pathological variables in Table 2.

Reduction of E-cadherin expression was significantly related to size and ulceration but not to fixation to skin or underlying tissue. Tumours with diameter of <3 cm differed from larger tumours in showing significantly higher expression ($P<0.012$). Furthermore, tumours larger than 5 cm differed from smaller tumours in showing significantly less E-cadherin expression ($P<0.003$). Ulcerated tumours showed less expression than did non-ulcerated tumours (Table 1).

Significant reduction of E-cadherin expression was also associated with the presence of lymph node metastasis and of necrosis (Table 2).

When each histological type or tumour was compared with the other histological types taken together, solid tumours showed significantly less E-cadherin expression ($P<0.009$) (Fig. 1), while

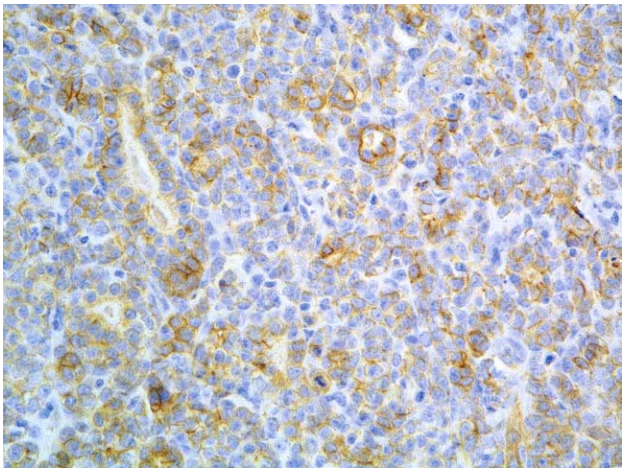

Fig. 1. Solid carcinoma. Heterogeneous membranous E-cadherin expression in 25–50% of epithelial tumour cells. (IHC. × 200).

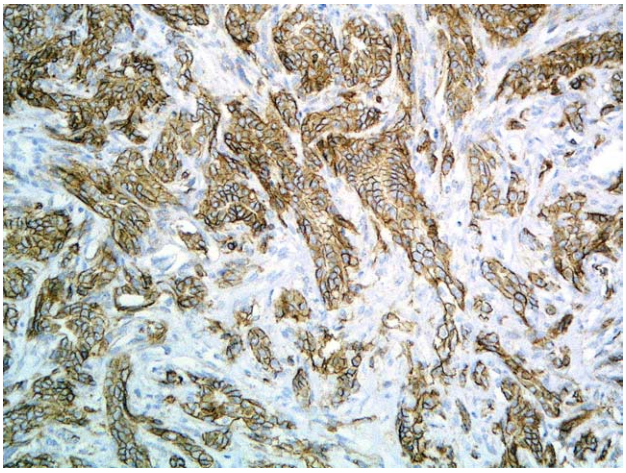

Fig. 2. Tubulopapillary carcinoma. Strong membranous E-cadherin expression in more than 75% of epithelial tumour cells. (IHC. X 200).

tubulopapillary carcinomas showed significantly more ($P<0.02$) (Fig. 2). Tumours characterized by infiltrative growth showed significant lower E-cadherin expression than did tumours with an expansive growth pattern ($P<0.005$). Vessel invasion in itself was also found to be associated with reduced E-cadherin expression when compared with expansive growth ($P<0.005$) or infiltrative growth without vessel invasion ($P=0.03$). E-cadherin expression was not precisely related to increases in histological grade. However, higher E-cadherin expression was shown by well-differentiated tumours (grade I) than by less differentiated ones (grades II and III) ($P< 0.02$).

Discussion

In the present study, E-cadherin expression was significantly related to the histological type of canine malignant mammary tumours. Low expression was found in solid type tumours, but this observation was less striking than that made by Restucci *et al.* (1997), who reported complete absence of expression in six canine solid carcinomas. The tubulopapillary carcinomas in our study showed comparatively high E-cadherin expression. These are not surprising results since the formation of tubular and papillary structures, albeit neoplastic, requires some degree of morphological organization, which largely depends on adhesion molecules (cadherins and catenins) (Takeichi, 1991), while tumoural proliferation, in the absence of E-cadherin expression, leads to the formation of non-organized tissue (solid tumours).

A reduction in E-cadherin expression was significantly associated with infiltrative growth and vessel invasion. This accords with some in–vitro studies, in which loss of E-cadherin expression was associated with acquisition of invasive capacity, and restoration of E-cadherin expression suppressed invasion *in vitro* and in a mouse tumour model (Frixen *et al.*, 1991; Vleminckx *et al.*, 1991; Perl *et al.*, 1998). However, expression of E-cadherin plus catenins is not always inhibitory to invasion, as was demonstrated for canine mammary tumour cell lines in an embryonic chicken heart assay of invasiveness; this suggested that other micro-environmental factors play a role (Spieker *et al.*, 1995). Studies on the relation between E-cadherin expression and vessel invasion in human breast cancer patients gave contradictory results (Parker *et al.*, 2001; Gupta *et al.*, 2003).

In the present study E-cadherin expression was not decreased in a stepwise fashion with increases in histological grade, as had been suggested, albeit not statistically proved, in a previous study of canine mammary neoplasms (Restucci *et al.*, 1997). Nevertheless, grade I tumours showed significantly higher E-cadherin expression than did grade II and III tumours taken together. This was reminiscient of our earlier finding of a significant difference between a group of poorly differentiated and a group of moderately and well-differentiated tumours (Reis *et al.*, 2003). In human breast cancer, conflicting results are also to be found in the literature. Thus, significant differences were reported by some authors (Siitonen *et al.*, 1996; Charpin *et al.*, 1997; Gonzalez *et al.*, 1999; Parker *et al.*, 2001; Cobanoglu *et al.*, 2004) but not by others (Jones *et al.*, 1996; Kovacs *et al.*, 2003; Howard *et al.*, 2005). Gamallo *et al.* (1993) demonstrated greater immunoreactivity in grade I carcinomas than in grade II and grade III, giving support to our results.

A significant association was shown between the presence of tumour necrosis and loss of E-cadherin expression. In human breast cancer, tumour necrosis is associated with poor survival (Parham *et al.*, 1992; Gilchrist *et al.*, 1993; Carlomagno *et al.*, 1995) and rapid recurrence (Gilchrist *et al.*, 1993).

This study revealed a significant association between large tumours (size >5 cm) and loss of E-cadherin expression. This contrasted with some studies in human breast cancer in which either no such association was demonstrated (Charpin *et al.*, 1997; Parker *et al.*, 2001; Kovacs *et al.*, 2003; Cobanoglu *et al.*, 2004) or increased E-cadherin immunolabelling was observed as tumour size increased (Howard *et al.*, 2005). Heimann *et al.* (2000), however, concluded that in breast cancer there was a trend towards decreased E-cadherin

expression with increased tumour size. In attempting to compare canine and human studies of mammary tumours, however, it must be borne in mind that large size may reflect either rapid growth or a prolonged period between manifestation and presentation, the latter steadily creating an advanced clinical stage.

In this study, low E-cadherin expression was significantly associated with tumour ulceration. Ulceration may be due to factors other than tumour invasion, such as self-mutilation, skin ischaemia, trauma or infection; it is recognized, however, that the more aggressive malignant tumours are particularly likely to be ulcerated (Rutteman et al., 2001) and, moreover, ulceration has been related to poor prognosis (Hellmén *et al.*, 1993; Peña *et al.*, 1998).

The study also showed that loss of E-cadherin expression was associated with lymph node metastasis, as revealed by cytokeratin IHC. In a previous study of canine mammary cancer, five of 41 tumours with confirmed regional lymph node metastasis showed reduced or absent expression of E-cadherin (Restucci *et al.*, 1997). In human breast cancer a significant association between the presence of E-cadherin expression and absence of lymph node metastasis was reported in some (Jones *et al.*, 1996; Hunt *et al.*, 1997; Zschiesche *et al.*, 1997; Madhavan *et al.*, 2001) but not in other studies (Charpin *et al.*, 1997; Burkholm *et al.*, 1998; Gonzalez *et al.*, 1999; Parker *et al.*, 2001; Kovacs *et al.*, 2003). In three studies of human breast cancer, however, it was found that high E-cadherin expression was associated with a larger number of lymph nodes considered positive for metastasis (Siitonen et al., 1996; Gillett *et al.*, 2001; Howard *et al.*, 2005). Extended studies, for instance on matrix composition, will be needed to gain insight into the fine-tuning of E-cadherin functions by the tumour microenvironment.

In conclusion, it would appear that there is a significant relationship between loss of E-cadherin expression and other known factors of poor prognosis in canine mammary tumours, such as tumour size (Bostock, 1975; Yamagami *et al.*, 1996; Pérez–Alenza *et al.*, 1997; Peña *et al.*, 1998; Philibert *et al.*, 2003), ulceration (Hellmén *et al.*, 1993; Peña *et al.*, 1998), histological type (Bostock, 1975; Shofer *et al.*, 1989), type of growth (Bostock, 1975; Shofer *et al.*, 1989; Sarli *et al.*, 2002), lymph node metastasis (Hellmén *et al.*, 1993; Pérez–Alenza *et al.*, 1997; Peña *et al.*, 1998; Nieto *et al.*, 2000) and necrosis. This indicates that the loss of E-cadherin expression may have prognostic value in canine malignant mammary tumours. Proof should be sought in future studies in which the clinical course of the disease is carefully monitored.

Acknowledgments

Grant support: Fundação para a Ciência e Tecnologia, project POCI/CVT/57795/2004.

References

Asgeirsson, K. S., Jonasson, J. G., Tryggvadorttir, L., Olafsdottir, K., Sigurgeirsdottir, J. R., Ingvarsson, S. and Ogmundsdottir, H. M. (2000). Altered expression of E-cadherin in breast cancer: patterns, mechanisms and clinical significance. *European Journal of Cancer*, **36,** 1098–1106.

Bostock, D. E. (1975). The prognosis following the surgical excision of canine mammary neoplasms. *European Journal of Cancer*, **11,** 389–396.

Burkholm, I. K., Nesland, J. M., Karesen, R., Jacobsen, U. and Borresen-Dale, A. L. (1998). E-cadherin and α-, β-, and γ-catenin protein expression in relation to metastasis in human breast carcinoma. *Journal of Pathology*, **185,** 262–266.

Carlomagno, C., Perrone, F., Lauria, R., de Laurentiis, M., Gallo, C., Morabito, A., Pettinato, G., Panico, L., Bellelli, T. and Apicella, A. (1995). Prognostic significance of necrosis, elastosis, fibrosis and inflammatory cell reaction in operable breast cancer. *Oncology*, **52,** 272–277.

Charpin, C., Garcia, S., Bouvier, C., Devictor, B., Andrac, L., Choux, R. and Lavaut, M. (1997). E-cadherin quantitative immunocytochemical assays in breast carcinomas. *Journal of Pathology*, **181,** 294–300.

Cobanoglu, U., Ersoz, S., Turgutalp, H., Reis, A. and Ozoran, Y. (2004). Correlation of E-cadherin expression with clinicopathological parameters in breast carcinoma. *Saudi Medical Journal*, **25,** 1024–1027.

Elston, C. W. and Ellis, I. O. (1998). Assessment of histological grade. In: Rosen's Breast Pathology, P. P. Rosen, Ed., Lippincott-Raven, Philadelphia, pp. 365–384.

Frixen, U. H., Behrens, J., Sachs, M., Eberle, G., Voss, B., Warda, A., Lochner, D. and Birchmeier, W. (1991). E-cadherin-mediated cell–cell adhesion prevents invasiveness of human carcinoma cells. *Journal of Cell Biology*, **113,** 173–185.

Gamallo, C., Palacios, J., Suarez, A., Pizarro, A., Navarro, P., Quintanilla, M. and Cano, A. (1993). Correlation of E-cadherin expression with differentiation grade and histological type in breast carcinoma. *American Journal of Pathology*, **142,** 987–993.

Gilchrist, K. W., Gray, R., Fowble, B., Tormey, D. C. and Taylor, S. G. (1993). Tumor necrosis is a prognostic predictor for early recurrence and death in lymph

node-positive cancer: a 10-year follow-up study of 728 Eastern Cooperative Oncology Group patients. *Journal of Clinical Oncology*, **11,** 1929–1935.

Gillett, C. E., Miles, D. W., Ryder, K., Skilton, D., Liebman, R. D., Springall, R. J., Barnes, D. M. and Hanby, A. M. (2001). Retention of the expression of E-cadherin and catenins is associated with shorter survival in grade III ductal carcinoma of the breast. *Journal of Pathology*, **193,** 433–441.

Gonzalez, M. A., Pinder, S. E., Wencyk, P. M., Bell, J. A., Elston, C. W., Nicholson, R. I., Robertson, J. F. R., Blamey, R. W. and Ellis, I. O. (1999). An immunohistochemical examination of the expression of E-cadherin, α-and β/γ-catenins, and α2- and β1-integrins in invasive breast cancer. *Journal of Pathology*, **187,** 523–529.

Gupta, A., Deshpande, C. G. and Badve, S. (2003). Role of E-cadherins in development of lymphatic tumor emboli. *Cancer*, **97,** 2341–2347.

Guriec, N., Marcellin, L., Gairard, B., Caldéroli, H., Wilk, A., Renaud, R., Bergerat, J. P. and Oberling, F. (1996). E-cadherin mRNA expression in breast carcinomas correlates with overall and disease-free survival. *Invasion and Metastasis*, **16,** 19–26.

Heimann, R., Lan, F., McBride, R. and Hellman, S. (2000). Separating favourable from unfavourable prognostic markers in breast cancer: the role of E-cadherin. *Cancer Research*, **60,** 298–304.

Hellmén, E., Bergström, R., Holmberg, L., Spångberg, I.-B., Hansson, K. and Lindgren, A. (1993). Prognostic factors in canine mammary tumors: a multivariate study of 202 consecutive cases. *Veterinary Pathology*, **30,** 20–27.

Howard, E. M., Lau, S. K., Lyles, R. H., Birdsong, G. G., Umbreit, J. N. and Kochhar, R. (2005). Expression of e-cadherin in high-risk breast cancer. *Journal of Cancer Research and Clinical Oncology*, **131,** 14–18.

Hsu, S. M., Faine, L. and Fanger, H. (1981). A comparative study of the peroxidase–antiperoxidase method and the avidin–biotin complex method for studying polypeptide hormones with radioimmunoassay antibodies. *American Journal of Clinical Pathology*, **75,** 734–738.

Hunt, N. C., Douglas-Jones, A. G., Jasani, B., Morgan, J. M. and Pignatelli, M. (1997). Loss of E-cadherin expression associated with lymph node metastases in small breast carcinomas. *Virchows Archiv*, **430,** 285–289.

Jones, J. L., Royall, J. E. and Walker, R. A. (1996). E-cadherin relates to EGFR expression and lymph node metastasis in primary breast carcinoma. *British Journal of Cancer*, **74,** 1237–1241.

Kovacs, A., Dhillon, J. and Walker, R. A. (2003). Expression of P-cadherin, but not E-cadherin or N-cadherin, relates to pathological and functional differentiation of breast carcinomas. *Molecular Pathology*, **56,** 318–322.

Kowalsky, P. J., Rubin, M. A. and Kleer, C. G. (2003). E-cadherin expression in primary carcinomas of the breast and its distant metastases. *Breast Cancer Research*, **5,** 217–222.

Lipponen, P., Saaelainen, E., Ji, H., Aaltomaa, S. and Syrjanen, K. (1994). Expression of E-cadherin is related to other prognostic factors and survival in breast cancer. *Journal of Pathology*, **174,** 101–109.

Madhavan, M., Srinivas, P., Abraham, E., Ahmed, I., Mathew, A., Vijayalekshmi, N. R. and Balaram, P. (2001). Cadherins as predictive markers of nodal metastasis in breast cancer. *Modern Pathology*, **14,** 423–427.

Misdorp, W., Else, R. W., Hellmén, E. and Lipscomb, T. P. (1999). Histological classification of the mammary tumours of the dog and the cat. In: *World Health Organization International Histological Classification of Tumours of Domestic Animals*, F. I. Shulman, Ed., Armed Forces Institute of Pathology, Washington DC, pp. 16–29.

Nieto, A. I., Peña, L., Pérez-Alenza, M. D., Sánchez, M. A., Flores, J. M. and Castaño, M. (2000). Immunohistologic detection of estrogen receptor alpha in canine mammary tumors: clinical and pathologic associations and prognostic significance. *Veterinary Pathology*, **37,** 239–247.

Parham, D. M., Hagen, N. and Brown, R. A. (1992). Simplified method of grading primary carcinomas of the breast. *Journal of Clinical Pathology*, **45,** 517–520.

Parker, C., Rampaul, R. S., Pinder, S. E., Bell, J. A., Wencyk, P. M., Blamey, R. W., Nicholson, R. I. and Robertson, J. F. (2001). E-cadherin as a prognostic indicator in primary breast cancer. *British Journal of Cancer*, **85,** 1958–1963.

Peña, L. L., Nieto, A. I., Pérez-Alenza, D., Cuesta, P. and Castaño, M. (1998). Immunohistochemical detection of Ki-67 and PCNA in canine mammary tumors: relationship to clinical and pathologic variables. *Journal of Veterinary Diagnostic Investigation*, **10,** 237–246.

Pérez-Alenza, M. D., Peña, L., Nieto, A. I. and Castaño, M. (1997). Clinical and pathological prognostic factors in canine mammary tumors. *Annali dell'Instituto Superiori di Sanità*, **33,** 581–585.

Perl, A. K., Wilgenbus, P., Dahl, U., Semb, H. and Christofory, G. (1998). A causal role for E-cadherin in the transition from adenoma to carcinoma. *Nature*, **392,** 190–193.

Philibert, J. C., Snyder, P. W., Glickman, N., Glickman, L. T., Knapp, D. W. and Waters, D. J. (2003). Influence of host factors on survival in dogs with malignant mammary gland tumors. *Journal of Veterinary Internal Medicine*, **17,** 102–106.

Priester, W. A. and MacKay, F. W. (1980). The occurrence of tumours in domestic animals. *National Cancer Institute Monograph 54*, NCI, Bethesda, pp. 152–184.

Reis, A. L., Carvalheira, J., Schmitt, F. C. and Gärtner, F. (2003). Immunohistochemical study of the expression of E-cadherin in canine mammary tumours. *Veterinary Record*, **152,** 621–624.

Reis-Filho, J. S., Paredes, J., Milanezi, F. and Schmitt, F. C. (2002). Clinicopathological implications of E-cadherin reactivity in patients with lobular carcinoma in situ of the breast. *Cancer*, **94,** 2114–2115.

Restucci, B., Papparella, S., De Vico, G. and Maiolino, P. (1997). E-cadherin expression in normal and neoplastic canine mammary gland. *Journal of Comparative Pathology*, **116,** 191–202.

Rutteman, G. R., Withrow, S. J. and MacEwen, E. G. (2001). Tumors of the mammary gland. In: *Small Animal Clinical Oncology*, 3rd Edit., S. J. Withrow and E. G. MacEwen, Eds, W.B. Saunders Company, Philadelphia, pp. 455–477.

Sarli, G., Preziozi, R., Benazzi, C., Castellani, G. and Marcato, P. S. (2002). Prognostic value of histologic stage and proliferative activity in canine malignant mammary tumors. *Journal of Veterinary Diagnostic Investigation*, **14,** 25–34.

SAS (1989). *SAS/STAT® User's Guide, Version 6,* 4th Edit., SAS Institute Inc., Cary, NC, USA.

Shofer, F. S., Sonnenshein, E. G., Goldschmidt, M. H., Laster, L. L. and Glickman, L. T. (1989). Histopathologic and dietary prognostic factors for canine mammary carcinoma. *Breast Cancer Research and Treatment*, **13,** 49–60.

Siitonen, S. M., Kononen, J. T., Helin, H. J., Rantala, I. S. and Isola, J. J. (1996). Reduced E-cadherin expression is associated with invasiveness and unfavourable prognosis in breast cancer. *American Journal of Clinical Pathology*, **105,** 394–402.

Spieker, N., Mareel, M., Bruyneel, E. A. and Nederbraght, H. (1995). E-cadherin expression and in vitro invasion of canine mammary tumour cells. *European Journal of Cell Biology*, **68,** 427–436.

Takeichi, M. (1991). Cadherin cell adhesion receptors as a morphogenetic regulator. *Science*, **251,** 1451–1455.

Tan, D. S. P., Potts, H. W. W., Leong, A. C. K., Gillett, C. E., Skilton, D., Harris, W. H., Liebmann, R. D. and Hanby, A. M. (1999). The biological and prognostic significance of cell polarity and E-cadherin in grade I infiltrating ductal carcinoma of the breast. *Journal of Pathology*, **189,** 20–27.

Vleminckx, K., Vakaet, L., Mareel, M., Fiers, W. and van Roy, F. (1991). Genetic manipulation of E-cadherin expression by epithelial tumour cells reveals an invasion suppressor role. *Cell*, **66,** 107–119.

Yamagami, T., Kobayashi, T., Takahashi, K. and Sugiyama, M. (1996). Prognosis for canine malignant tumors based on TNM and histologic classification. *Journal of Veterinary Medical Sciences*, **58,** 1079–1083.

Zschiesche, W., Schonborn, I., Behrens, J., Herrenknecht, K., Hartveit, F., Lilleng, P. and Birchmeier, W. (1997). Expression of E-cadherin and catenins in invasive mammary carcinomas. *Anticancer Research*, **17,** 561–568.

[*Received*, *May 11th*, *2005*
Accepted, *October 30th*, *2005*]